

Question 1

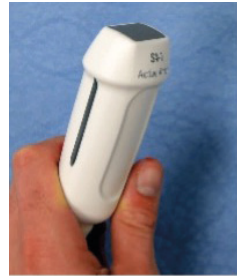· Complete the following sentence: The correct name for "dark" areas on an ultrasound image is:

· Complete the following sentence: The correct name for "bright" areas on an ultrasound image is:

Question 2

Which transducer is shown here?

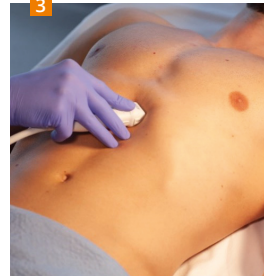
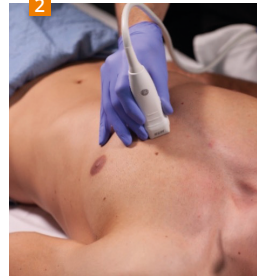
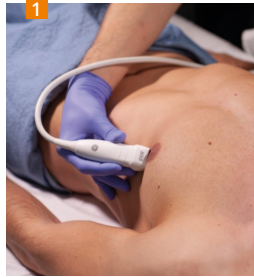
Transducer:



Question 3

Which sectional scan planes are shown here? Label them on the images:

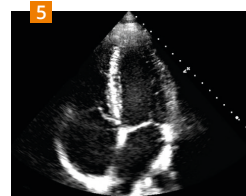
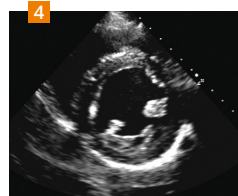
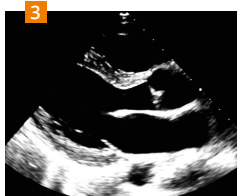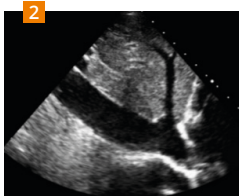
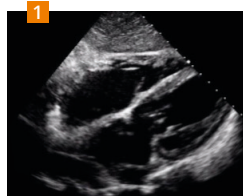
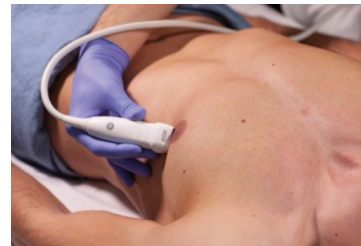1. Sectional scan plane:
2. Sectional scan plane:
3. Sectional scan plane:



Question 4

Which ultrasound image results from the scanning approach seen here?

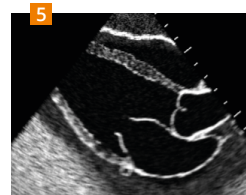
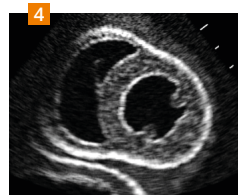
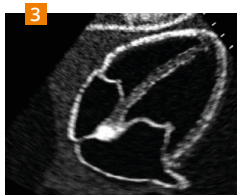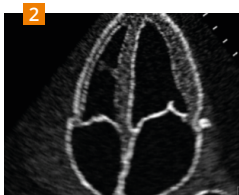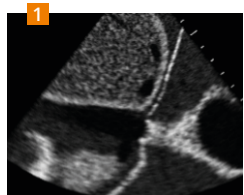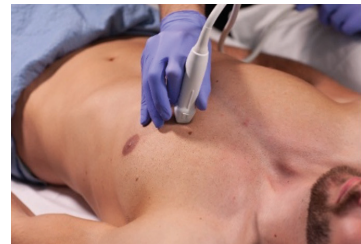- 1: 2: 3: 4: 5:



Question 5

Which image on the ultrasound simulator results from the scanning approach seen here?

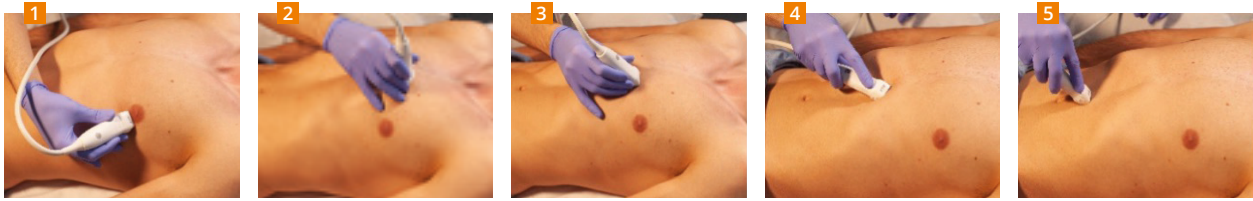
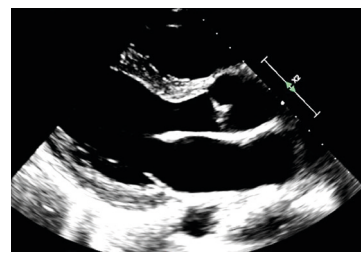
- 1: 2: 3: 4: 5:



Question 6

Through which scanning approach is the ultrasound image, seen here, obtained?

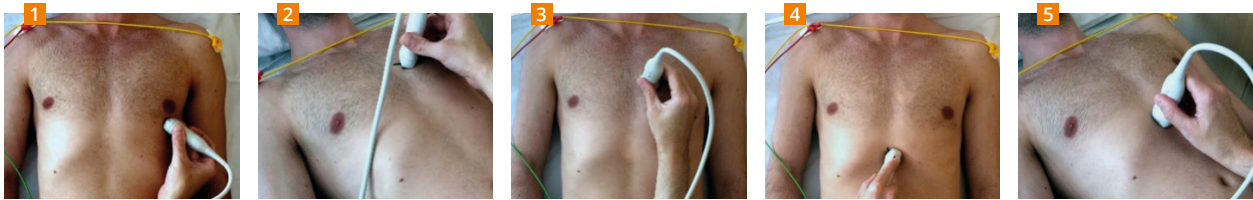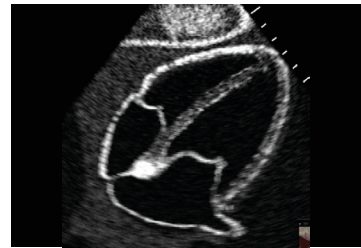- 1: 2: 3: 4: 5:



Question 7

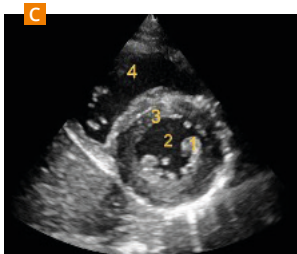
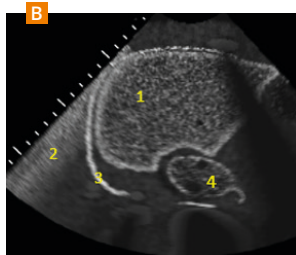
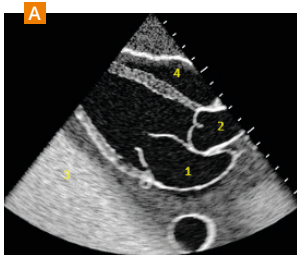
Through which scanning approach is the image on the ultrasound simulator, seen here, obtained?

- 1: 2: 3: 4: 5:



Question 8

Which structures are marked on the image? Describe exactly.



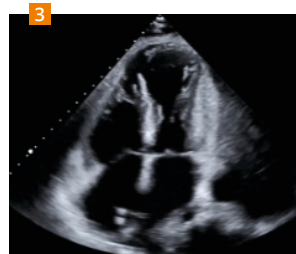
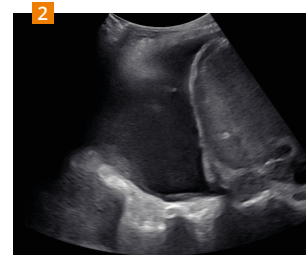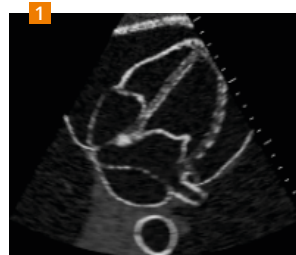- A1: A2:
A3: A4:

B1: B2:
B3: B4:

C1: C2:
C3: C4:

Question 9

Which pathologies are marked on the image? Describe exactly.



1. Pathology:
2. Pathology:
3. Pathology: