

## The effects of ovariectomy and subsequent progesterone replacement on the uterus of the pregnant mouse

R. SHARMA AND D. BULMER

*Human Morphology, University of Southampton,  
Medical and Biological Sciences Building, Bassett Crescent East,  
Southampton SO9 3TU*

(Accepted 10 March 1983)

### INTRODUCTION

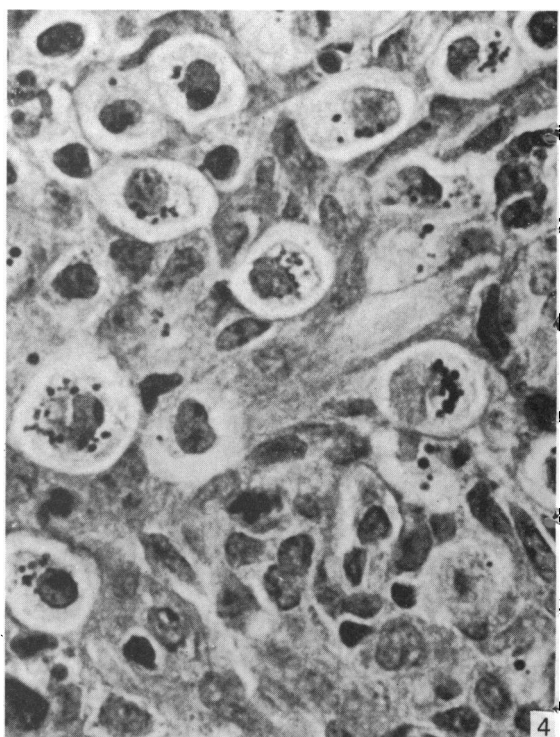
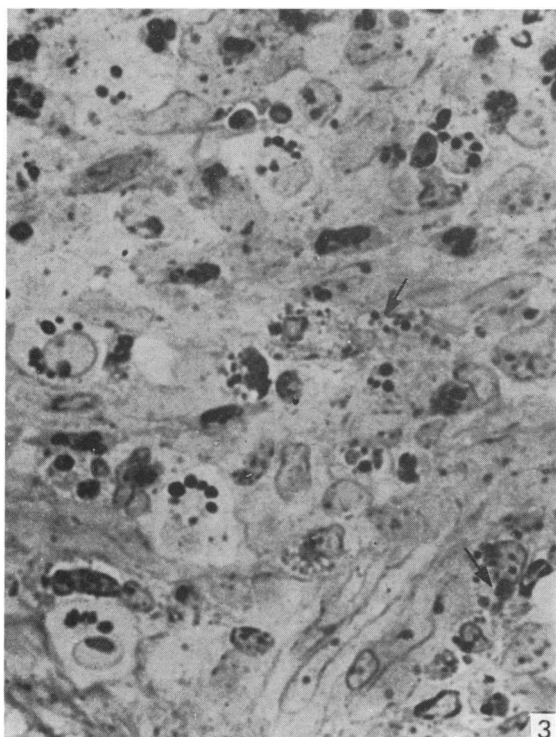
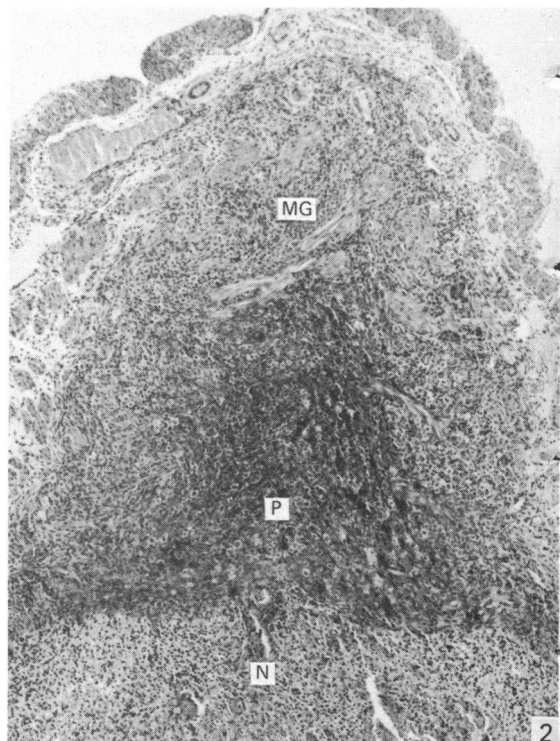
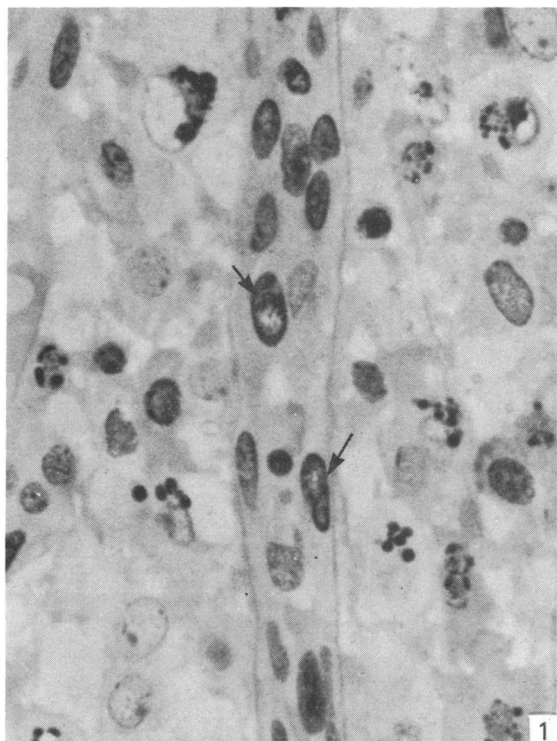
In rodents pregnancy may be maintained after ovariectomy during the early stages of gestation by the administration of steroids, particularly of progesterone (Alexander, Frazer & Lee, 1955; Carpent, 1962; McLaren, 1971). However, apart from the reports by Deanesly (1972, 1973) that the rapid decidual degeneration after ovariectomy in early gestation in the guinea-pig and the rat can be prevented by exogenous progesterone, there is little information on the progesterone dependency of the individual elements of the placenta and pregnant uterus. Of particular recent interest is the relationship of ovarian hormones to the development and function of the metrial gland, a structure now proposed to be of importance in the immunology of pregnancy (Bulmer & Peel, 1977; Mitchell, Craggs & Peel, 1980). It is known that the life of the granulated cells of the metrial gland in deciduomata of pseudopregnancy is prolonged by the administration of progesterone (Velardo, Dawson, Olsen & Hisaw, 1953), and that progesterone prolongs the life of granulated cells cultured *in vitro* (Adam, 1980). There is no direct information, however, on the effects of progesterone on the various developmental processes involved in the formation of the metrial gland.

The present study reports an attempt to elucidate the effects of progesterone on the origin, differentiation and proliferation of the granulated metrial gland cells in the mouse. Animals were ovariectomised at day 8 of gestation, a stage when granulated cells are well established in the decidua basalis and are first beginning to appear amongst the circular muscle fibres at the base of the mesometrial triangle. The effects on the implantation sites were studied, in comparison with control animals subjected to a sham operation and with animals subjected to two different levels of progesterone replacement.

### MATERIALS AND METHODS

Sixty three mice of the Porton strain were used. Animals were mated overnight, the finding of a vaginal plug was taken as the start of day 0 of pregnancy and the pregnant animals were subjected to bilateral ovariectomy under ether anaesthesia on day 8. In control mice, sham ovariectomy was carried out on day 8 of pregnancy by removing a portion of peri-ovarian fat.

One group of ovariectomised animals was subjected to no further treatment. In



two other groups, progesterone in 0.1 ml sesame oil was injected intramuscularly, beginning immediately after ovariectomy. Animals in one group received 0.5 mg progesterone twice daily and those in the other group 1 mg twice daily. Animals were killed 6 hours, 12 hours, 24 hours, 2 days, 3 days and 5 days after operation and the ovariectomised animals were examined post mortem to confirm the absence of ovarian remnants. The majority of implantation sites from experimental animals and at least three from each control animal were examined. Tissues were fixed in a mixture of 2% glutaraldehyde and 4% formaldehyde in 0.1 M phosphate buffer, pH 7.2–7.4, modified from Karnovsky (1965), dehydrated in ethanol and embedded in glycol methacrylate or paraffin. Sections were stained with the periodic acid–Schiff (PAS) technique, with or without previous diastase digestion, and counter-stained with haematoxylin.

#### OBSERVATIONS

At day 8 of pregnancy in the mouse, the decidua basalis was well developed and contained numerous large granulated metrial gland cells. Among the circular muscle fibres dispersed across the base of the mesometrium there were sparsely distributed granulated cells, smaller and with fewer cytoplasmic granules than those in the decidua.

#### *Ovariectomy at day 8*

Implantation sites from animals killed six hours after ovariectomy showed no evidence of degeneration in fetal, placental or maternal tissues. As in the sham-operated control animals, there were large granulated cells in the decidua basalis, with fewer and smaller granulated cells, some of them showing mitotic figures, among the muscle fibres at the base of the mesometrium.

By twelve hours after ovariectomy there was obvious retardation in fetal development, and some cells in the trophoblast and the inner part of the decidua basalis showed degenerative changes. The central vessels of the decidua basalis often appeared to have collapsed (Fig. 1). Granulated cells among the muscle fibres at the base of the mesometrium were still apparently as numerous as in the control implantation sites, and occasional mitoses could be identified. The most striking result of the ovariectomy in this region was an extensive infiltration by extravascular polymorphonuclear leucocytes, most of them neutrophils.

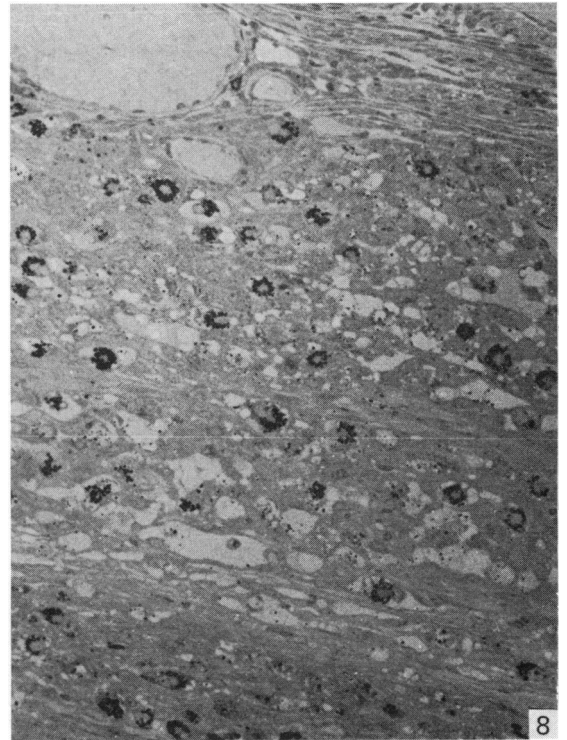
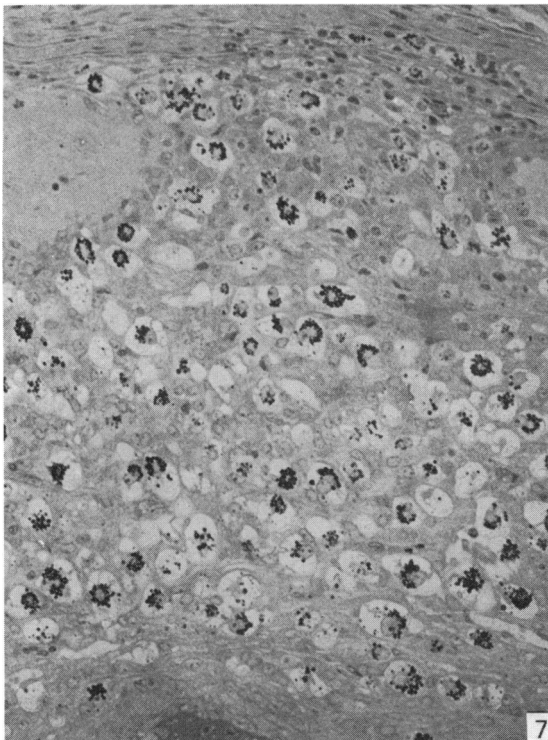
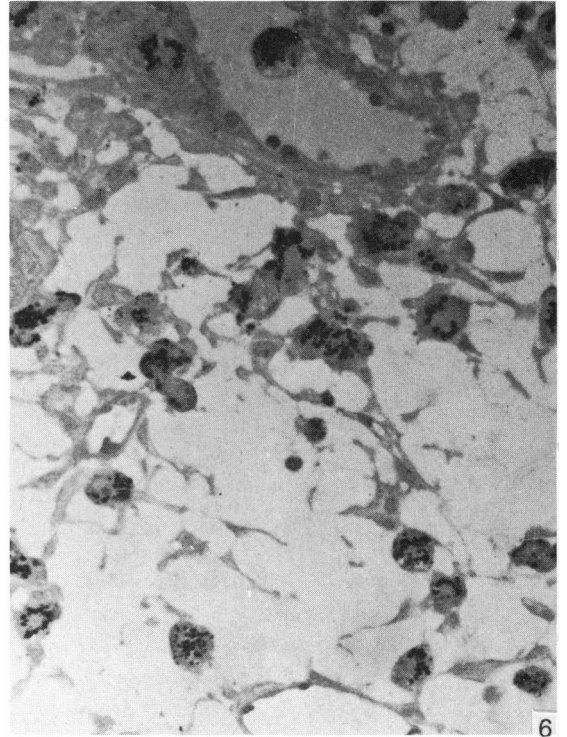
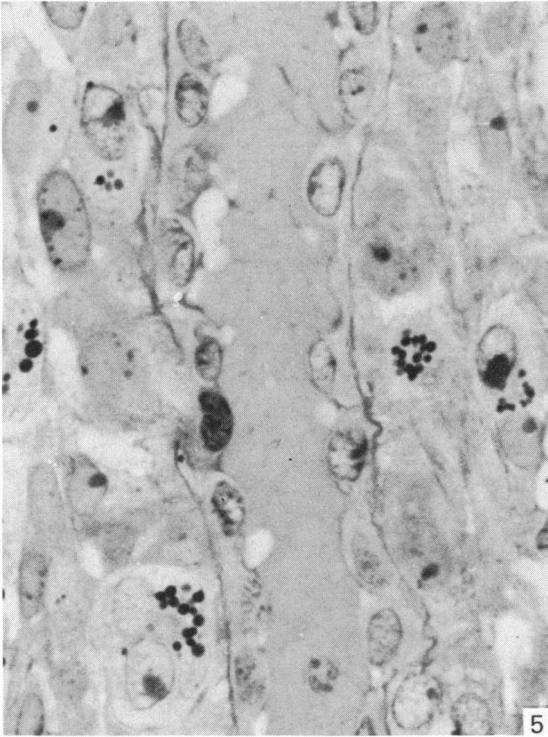
By one day after ovariectomy the implantation sites were smaller than those of control animals, and there was necrosis of both fetus and trophoblast. There were two clearly distinguished regions in the decidua basalis (Fig. 2). In the inner and larger area there was massive necrosis, with no evidence of any surviving decidual cells or granulated cells. Sharply distinguished from this was a peripheral layer,

Fig. 1. Collapsed central vessel of the decidua basalis 12 hours after ovariectomy; endothelial cells are arrowed. Diastase PAS, haematoxylin.  $\times 740$ .

Fig. 2. Mesometrial part of pregnant uterus 24 hours after ovariectomy. The metrial gland (MG) and peripheral decidua (P) appear healthy but the inner decidua (N) is necrotic. Diastase PAS, haematoxylin,  $\times 46$ .

Fig. 3. Metrial gland 24 hours after ovariectomy, showing granulated cells, stromal cells and polymorphonuclear leucocytes. Some of the stromal cells contain PAS-positive granules (arrows). Diastase PAS, haematoxylin,  $\times 740$ .

Fig. 4. Metrial gland 24 hours after ovariectomy, showing granulated cells and small round cells. Diastase PAS, haematoxylin,  $\times 740$ .



just beneath the circular muscle layer, where apparently normal stromal and granulated cells could be identified. Between the circular muscle fibres at the base of the mesometrium there were numerous granulated cells, apparently larger and with more granules than in the earlier specimens. Some of the stromal cells in this situation contained small PAS-positive cytoplasmic granules (Fig. 3). There was extensive infiltration with polymorphonuclear leucocytes, and occasional small round cells could be identified among them (Fig. 4). In contrast with the earlier specimens, and with the sham-operated control 9 day implantation sites, there were no mitotic figures.

At two and three days after ovariectomy the implantation sites were relatively very small. The necrotic decidua basalis was almost completely detached, projecting into the uterine lumen. The stromal cells in the peripheral area of decidua and at the base of the mesometrium contained small PAS-positive granules, not present in control implantation sites, and granulated cells were either very sparse or completely absent. The leucocytic infiltration was no longer evident in the mesometrial triangle. In animals killed five days after ovariectomy there was no gross evidence of any implantation sites. Histological examination showed necrotic material in the uterine lumen, and in some cases subepithelial and intra-epithelial polymorphonuclear leucocytes were present. No granulated cells were identified, but some stromal cells contained PAS-positive cytoplasmic granules.

#### *Effects of progesterone treatment*

Implantation sites from the animals which had received the larger dose of progesterone (1 mg twice daily) showed few differences from the control specimens. At twelve hours after ovariectomy, progesterone administration had prevented collapse of the central vessels of the decidua basalis (Fig. 5). However, in some specimens the lateral venous sinusoids were unusually distended and the outer part of the decidua basalis was oedematous (Fig. 6). There was no leucocytic infiltration at the base of the mesometrium, and mitotic activity in the granulated cells was comparable with that of the controls. Granulated metrial gland cells were apparently of normal morphology and, as in the controls, they were frequently seen in the vessels of the metrial gland and decidua. The numbers and distribution of granulated cells in the metrial gland and decidua (Fig. 7) were similar to those of normal and control implantation sites.

In the ovariectomised animals which received the lower dose of progesterone (0.5 mg twice daily), the fetuses, placentae, decidua and granulated metrial gland cells appeared to be normal up to two days after the ovariectomy. Beyond that stage, however, there was considerable variation, with fetal survival in only a minority of the implantation sites. Of the four animals killed three days after ovariectomy, one contained apparently normal fetuses and placentae, with numerous

---

Fig. 5. Decidua basalis from ovariectomised mouse treated with 1 mg progesterone and killed 12 hours later. The central vessel is wide open. Diastase PAS, haematoxylin,  $\times 740$ .

Fig. 6. Oedema in the peripheral part of the decidua basalis in ovariectomised mouse killed on day 13 after treatment with 1 mg progesterone twice daily. Diastase PAS, haematoxylin,  $\times 290$ .

Fig. 7. Granulated cells in the metrial gland and decidua in ovariectomised mouse treated with 1 mg progesterone twice daily and killed on day 13. Diastase PAS, haematoxylin,  $\times 180$ .

Fig. 8. Metrial gland and decidua in ovariectomised mouse treated with 0.5 mg progesterone twice daily and killed on day 13. The area shown is comparable with that illustrated in Fig. 7, from an animal given the higher dosage of progesterone. Diastase PAS, haematoxylin.  $\times 180$ .

granulated metrial gland cells throughout the decidua basalis and metrial gland. In the other three, the fetuses, though intact, showed extensive cell death, without any evidence of fetal vessels in the placenta. There was some cell degeneration in the area adjacent to the placenta, but the remainder of the decidua basalis and the metrial gland appeared healthy, with numerous granulated cells. Some PAS-positive granules could be identified in stromal cells.

In two animals killed four days after ovariectomy, all the implantation sites showed death and disruption of the fetus and placenta, with degeneration in the inner part of the decidua. Numerous granulated cells persisted in the larger, outer part of the decidua and in the metrial gland. In some implantation sites there was dilatation of the lateral venous sinusoids, which often contained blood clot, incorporating intact and disrupted granulated cells. In the metrial gland, many stromal cells contained cytoplasmic granules which stained positively with the PAS technique after diastase digestion. Most of the granulated cells, both in the decidua and in the metrial gland, appeared normal in structure, though in some there was variation in granule size and staining intensity.

One of the five animals killed five days after ovariectomy showed surviving fetuses and placentae, with numerous granulated cells throughout the decidua basalis and metrial gland (Fig. 8). They were obviously less numerous, however, than in implantation sites either from the control animals or from the ovariectomised animals subjected to the higher dosage of progesterone (Fig. 7). In the implantation sites from the four other animals killed at day 13 the fetuses, placentae and most of the decidua basalis had degenerated. In the peripheral layer of surviving decidua and in the region of the metrial gland, however, there were numerous granulated cells. Though in some areas they were apparently disrupted and there was some variation in granule size and staining, most of them showed apparently normal morphology. Some stromal cells contained fine cytoplasmic granules, giving a positive reaction with the PAS technique after diastase digestion.

#### DISCUSSION

In mice ovariectomised on day 8 of pregnancy, differences from the control animals are evident twelve hours after operation. By one day after ovariectomy, there is extensive degeneration of the embryo, placenta and a large part of the decidua basalis. Mitotic activity is abolished in both granulated cells and stromal cells, and there is a marked infiltration by polymorphonuclear leucocytes in the region of the metrial gland. The numbers of granulated cells in the metrial gland area at first increase after ovariectomy but thereafter the existing granulated cells degenerate so that only very few persist by day 10. Cytoplasmic granules, apparently glycoprotein in composition, are evident in stromal cells of the metrial gland. The effects of ovariectomy at day 8 of pregnancy in the mouse appear to be similar to those of ovariectomy at day 10 in the rat (Bulmer & Peel, 1979; Stewart & Peel, 1979), though infiltration of the metrial gland by polymorphonuclear leucocytes has not been described in the rat. The reasons for the leucocytic infiltration of the metrial gland in the mouse are not clear, and it appears to precede morphological evidence of degenerative changes in that area.

Deanesly (1973) attributes the rapid termination of pregnancy after early ovariectomy in the rat to decidual collapse resulting from vascular impairment. Pijnenborg, Robertson & Brosens (1975) have described the pronounced effects of ovariectomy

on the central vessels of the decidua in the hamster. The massive degeneration of embryo, placenta and most of the decidua basalis by 24 hours after ovariectomy at day 8 in the mouse, together with the collapsed appearance of the decidual vessels (Fig. 1), suggest a rapid onset of vascular insufficiency. It is possible that the outer part of the decidua basalis is supplied from peripheral vessels which, like the vessels of the mesometrial triangle, are less affected by the deficiency of ovarian hormones. The less dramatic and less immediate changes in the mesometrial triangle, with continued increase in the granulated cell numbers for 24 hours after ovariectomy, may be due to a less pronounced vascular impairment or to a direct effect of ovarian hormone deficiency.

The higher dose of replacement progesterone is effective in maintaining pregnancy throughout the five day period after ovariectomy. Apart from the occurrence in some specimens of venous dilation and decidual oedema, the morphological appearance of the fetus, placenta, decidua and metrial gland does not differ from those of the control implantation sites. While the lower dose of progesterone maintains apparently normal implantation sites for two days after ovariectomy, in only a minority of specimens was a live fetus present after three days. Though the placenta and decidua are apparently normal in these mice, there are markedly fewer granulated cells than in specimens either from control animals or from animals subjected to the higher dosage of progesterone (Figs. 7, 8). In the implantation sites from the animals which have been subjected to the lower dosage of progesterone and where the fetus has not survived, granulated cells persist both in the surviving part of the decidua basalis and in the metrial gland. The PAS-positive granules in the cytoplasm of the stromal cells of the metrial gland are a marked feature of the ovariectomised animals during the period when the granulated cells are degenerating. Their appearance is prevented by administration of progesterone at the higher dosage and they are less numerous in animals subjected to the lower dosage than they are in untreated animals. Their significance is not clear, but it is possible that they are secondary to granulated cell degeneration rather than a direct result of progesterone deficiency. They may be comparable with the PAS-positive granules reported by Stewart & Peel (1979) in stromal cells of the metrial gland of ovariectomised rats. These authors suggest that some of the stromal cell granules may represent phagocytosed material from degenerate granulated cells. Endocytotic activity has been demonstrated in stromal cells of the rat metrial gland by Sharma & Peel (1979).

The addition of progesterone to cultures of metrial gland tissue maintains the survival of granulated cells *in vitro* (Adam, 1980), and it is apparent that the administration of exogenous progesterone *in vivo* maintains the survival and proliferation of granulated metrial gland cells in the mouse for at least five days after ovariectomy at day 8. Moreover, a lower dosage of progesterone is required for the maintenance of the granulated metrial gland cells than is necessary to ensure the continuation of normal pregnancy. It is not clear from the results of this investigation whether the administration of progesterone to the ovariectomised animals also stimulates the migration to the uterus of granulated cell precursors, now established to be of bone marrow origin (Peel, Stewart & Bulmer, 1983), or the differentiation of granulated cells from them. Precursor cells appear to accumulate in the metrial gland of rats ovariectomised at day 10 of pregnancy (Stewart & Peel, 1979). There is no striking accumulation of precursors in the ovariectomised mice, but small round cells can be identified in the metrial gland 24 hours after ovariectomy, inter-

mingled with the more numerous polymorphonuclear leucocytes. Further studies will be required to analyse the effects of progesterone on the early stages of granulated cell development.

#### SUMMARY

The effects of ovariectomy at day 8 of pregnancy were studied on the granulated metrial gland cells of the mouse uterus, with and without subsequent progesterone replacement. By one day after the ovariectomy the fetuses were dead and there was extensive decidual necrosis. Though numerous granulated cells were still present after one day, accompanied by an extensive polymorphonuclear leucocytosis in the mesometrial triangle, granulated cells virtually disappeared within three days.

In animals injected with 1 mg progesterone twice daily over five days, starting at the time of ovariectomy, the pregnancies survived. There was no decidual necrosis, and the numbers, morphology and distribution of the granulated metrial gland cells were normal. In ovariectomised animals injected with 0.5 mg progesterone twice daily most implantation sites after three, four and five days were associated with fetal death, though numerous granulated metrial gland cells survived. In implantation sites where the fetus had survived to thirteen days, there were markedly fewer granulated cells than in implantation sites either from control animals or from animals treated with the higher dosage of progesterone. Cytoplasmic granules in stromal cells of the metrial gland were prominent in the ovariectomised animals. They were much less numerous in animals given the lower dosage of progesterone and absent from those given the higher dosage.

We are grateful to Dr S. Peel for her advice and criticism.

#### REFERENCES

- ADAM, E. (1980). The effects of progesterone treatment on rat metrial gland *in vitro*. *Journal of Anatomy* **131**, 753.
- ALEXANDER, D. P., FRAZER, J. F. D. & LEE, J. (1955). The effect of steroids on the maintenance of pregnancy in the spayed rat. *Journal of Physiology* **130**, 148–155.
- BULMER, D. & PEEL, S. (1977). The demonstration of immunoglobulin in the metrial gland cells of the rat placenta. *Journal of Reproduction and Fertility* **49**, 143–145.
- BULMER, D. & PEEL, S. (1979). The effects on the rat uterus and placenta of ovariectomy at day 10 of pregnancy. *Journal of Anatomy* **128**, 185–194.
- CARPENT, G. (1962). Le déséquilibre hormonal gravidique et ses répercussions sur la morphologie du foetus chez le rat. *Archives d'anatomie microscopique et de morphologie expérimentale* **51**, 459–539.
- DEANESLY, R. (1972). Retarded embryonic development and pregnancy termination in ovariectomised guinea pigs: progesterone deficiency and decidual collapse. *Journal of Reproduction and Fertility* **28**, 241.
- DEANESLY, R. (1973). Termination of early pregnancy in rats after ovariectomy is due to immediate collapse of progesterone dependent decidua. *Journal of Reproduction and Fertility* **35**, 183–186.
- KARNOVSKY, M. J. (1965). A formaldehyde–glutaraldehyde fixative of high osmolality for use in electron microscopy. *Journal of Cell Biology* **27**, 137A.
- MCLAREN, A. (1971). Blastocysts in the mouse uterus: the effect of ovariectomy, progesterone and oestrogen. *Journal of Endocrinology* **50**, 515–526.
- MITCHELL, B. S., CRAGGS, R. & PEEL, S. (1980). Localisation of immunoglobulin (IgG) within the rat metrial gland. *Journal of Reproductive Immunology* **2**, 235–244.
- PEEL, S., STEWART, I. & BULMER, D. (1982). The morphology of granulated metrial gland cells in lethally-irradiated, bone marrow-reconstituted mice. *Journal of Anatomy* **135**, 849.
- PIJNENBORG, R., ROBERTSON, W. B. & BROSENS, I. (1975). The role of ovarian steroids in placental development and endovascular trophoblast migration in the golden hamster. *Journal of Reproduction and Fertility* **44**, 43–51.
- SHARMA, R. & PEEL, S. (1979). Uptake of marker proteins by glycoprotein-containing cells of the pregnant rat uterus and placenta. *Journal of Anatomy* **129**, 707–718.



- STEWART, I. & PEEL, S. (1979). Changes in the metrial gland of the rat uterus following ovariectomy on day 10 of pregnancy. *Anatomy and Embryology* **156**, 103–114.
- VELARDO, J. T., DAWSON, A. B., OLSEN, A. G. & HISAW, F. L. (1953). Sequence of histological changes in the uterus and vagina of the rat during prolongation of pseudopregnancy associated with the presence of decidualomata. *American Journal of Anatomy* **93**, 273–305.