

Can J Vet Res 2000;64:254-258

Pacing induced sustained atrial fibrillation in a pony

Gunther van Loon, René Tavernier, Mattias Duytschaever, Winoc Fonteyne, Piet Deprez, Luc Jordaens

Due to a printing error, Figures 2 and 3 on page 256 were reversed. They should be as shown below. The editors and staff of the CJVR apologize to the authors and to the readers for this error.

CJVR eds.

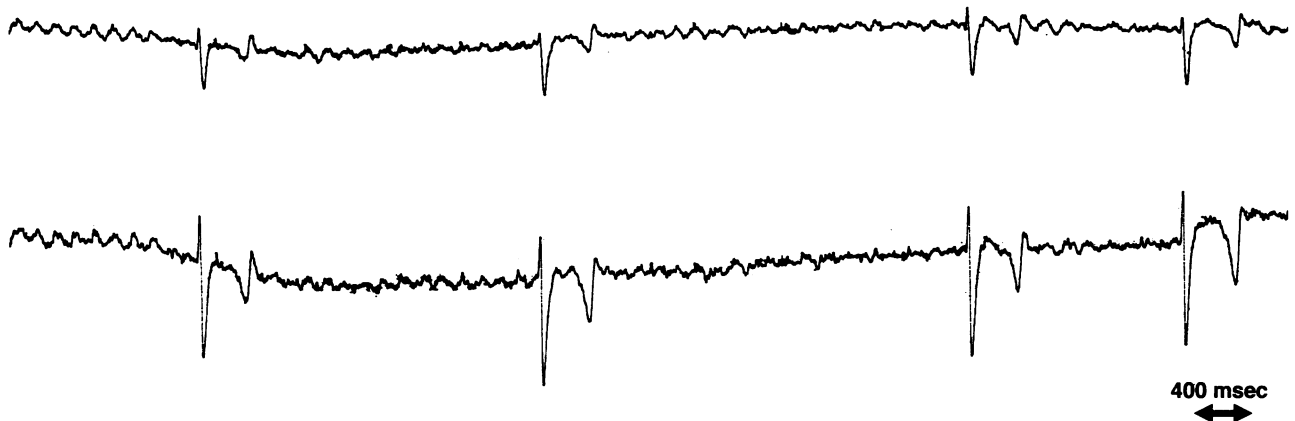


Figure 2. Surface ECG (unipolar lead on the upper trace and lead II on the lower trace) after 1 d of burst pacing. The pulse generator is just turned off. AF is present.

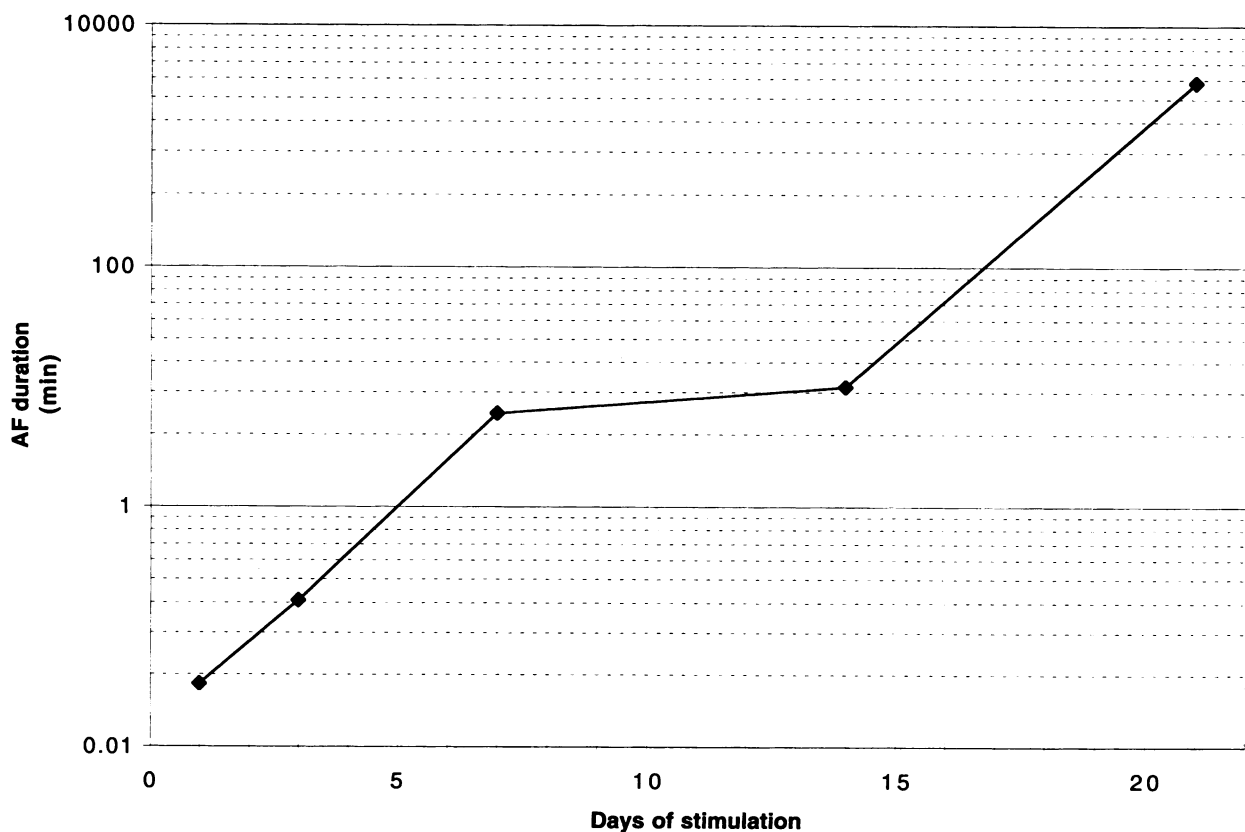


Figure 3. Duration of AF in the ordinate (logarithmic scale) versus the time atrial burst pacing is applied. The longer burst pacing is continued, the longer the induced AF episodes. On Day 21 sustained AF is present.