

*Communications*

# Congenital endothelial corneal dystrophy

## Clinical, pathological, and genetic study

W. G. PEARCE

*M.R.C. Population Genetics Research Unit, Oxford, and St. Mary's and Western Ophthalmic Hospitals, London*

RAMESH C. TRIPATHI AND GWYN MORGAN

*Department of Pathology, Institute of Ophthalmology, University of London*

The hereditary corneal dystrophies are remarkable in that only rarely do sufficient opacifications exist at birth or appear during infancy to merit both the prefix "congenital", *i.e.* a disturbance present at birth, and "dystrophy", *i.e.* a disturbance developing on a hereditary basis in apparently normal tissue. The term as used has referred to a bilateral symmetrical diffuse opacification of the cornea, with oedema but without vascularization, present from an early age and accompanied by marked impairment of vision. This disorder was originally described by Laurence (1863) as *corneitis interstitialis in utero* and later by Saltini (1887) as "congenital opacity of the cornea". Although there existed some similarities in appearance with syphilitic interstitial keratitis, the absence of any of the accompanying stigmata of syphilis was well recognized by early investigators, who also commented on the absence of corneal opacification in stillborn foetuses with widespread syphilitic infection (Armaignac, 1911). More recently it has been termed diffuse "degenerative congenital corneal dystrophy" (Waardenburg, Franceschetti, and Klein, 1961), "hereditary congenital corneal dystrophy" (Maumenee, 1960; Kenyon and Maumenee, 1968), and "congenital macular opacity" (Duke-Elder, 1964). Despite agreement concerning the clinical picture, no well-documented and readily confirmed histological changes considered responsible for the condition have yet been described. This report presents the clinical, pathological, and genetic findings obtained from a family with an hereditary congenital corneal dystrophy in which distinctive histological changes have been detected.

### **Methods**

Several members of the family to be described were attending hospital for eye treatment. Others were examined in their homes. 20 ml. intravenous blood were taken for blood group, serum protein, and enzyme estimations to be used as genetic markers for linkage analysis (to be reported separately). Photographs were taken with a portable single lens reflex camera. Three individuals *without previous corneal surgery* had penetrating grafts and the corneal buttons were examined by light microscopy. Two of the specimens were also processed for electron microscopy. Three further

corneal buttons, obtained by penetrating grafts performed before the present study from other members of the family, who at the time of this graft had experienced no previous corneal surgery, were also studied by light microscopy.

**Kindred**

24 affected and sixteen unaffected classifiable living members of the family were examined. These individuals provided the pedigree (Fig. 1). As the clinical phenotype and its effect on vision are so readily apparent, statements concerning its presence or absence in deceased members of the family have been accepted as accurate when confirmed by others in the family. There was therefore a total of 78 classifiable individuals, of whom 39 were affected and 39 unaffected. The 39 affected consisted of 26 females and thirteen males, while the unaffected were the converse, thirteen females and 26 males. This segregation is a highly significant departure from expected ratios ( $\chi^2 = 8.24$ ;  $0.001 < P < 0.01$ ) when dominant autosomal inheritance is assumed. Sex ratios of the offspring of affected individuals are shown in Table I.

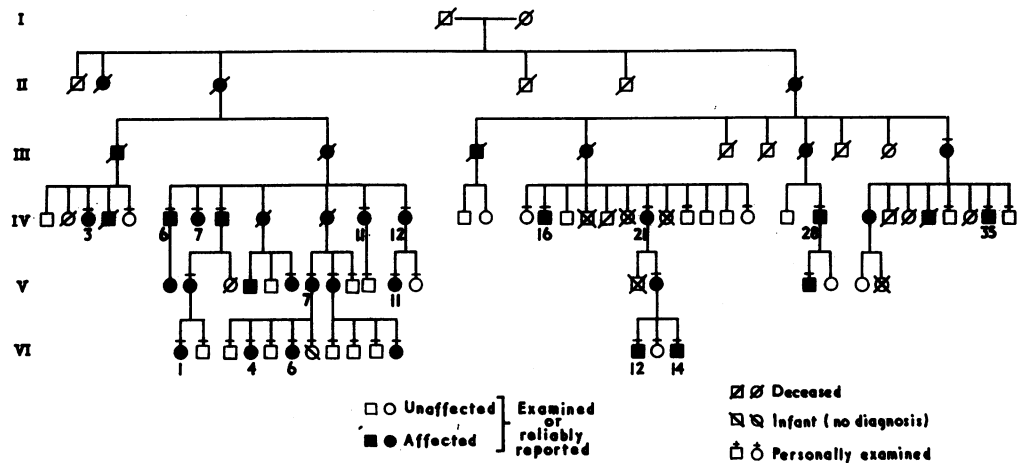


FIG. 1 Pedigree showing 39 affected persons in five generations

**Table I** Segregation of offspring from affected parents

Parents	Affected males (5)				Affected females (16)			
	Affected (5)		Normal (5)		Affected (31)		Normal (29)	
Offspring	Male	Female	Male	Female	Male	Female	Male	Female
	2	3	2	5	11	20	21	8

$\chi^2 = 1.42$ ;  $P > 0.05$

$\chi^2 = 8.38$ ;  $0.001 < P < 0.01$

Among the offspring of affected males, the presence of affected sons and unaffected daughters excluded X-linked inheritance but were consistent with the 1 : 1 expected ratio of dominant autosomal inheritance. The assumed distortion from the 1 : 1 expected ratio is seen to be produced within the offspring of affected females, where both an increased number of affected daughters and a reduced number of sons are observed, while the total expected numbers of males and females are equal. This distortion is also significant ( $\chi^2 = 8.38$ ;  $0.001 < P < 0.01$ ).

Among the affected individuals no significant difference in clinical appearance between siblings or between parents and offspring was detected. Similarly, no difference in the phenotype between males and females was observed, although in two patients one cornea was much less severely affected.

### **Clinical Features**

The characteristic feature was an irregular milky opacification and thickening of the cornea extending over the full corneal diameter. Fine epithelial oedema, producing a slightly roughened appearance, was also present. In these individuals the degree of stromal thickening and opacification prevented satisfactory examination of the endothelium with the slit lamp (Fig. 2*a*). Some variation in this appearance was noted in young children and in those over 45 years of age. Two infants were observed regularly for 2 to 4 years. No corneal opacities were noted at birth but photophobia and epiphora were observed by the mother in the immediate post-natal period. Examination revealed diffuse stromal and epithelial oedema (Fig. 2*b*), while milky opacification became apparent only towards the end of the first and during the second year (Fig. 2*c*). The increasing opacification was accompanied by a reduction in photophobia and epiphora. In those children in whom opacification progressed less rapidly, a few small irregular white opacities were present within the hazy stroma. Occasionally vision had been adequate for learning to read and write before further deterioration occurred (Fig. 2*d*). The cornea of middle-aged and elderly patients often showed episodes of previous ulceration with resultant superficial vascularization, scarring, and band-shaped keratopathy (Figs 2*e* and 2*f*). In general, this picture of gradual deterioration in vision was noted in most patients (see Figs 2*a-f*, overleaf).

In two individuals the corneal disturbance was considerably less in one eye, while in the remainder virtually identical changes were present in each cornea. Careful examination of these less affected eyes with the slit lamp showed the features outlined in Fig. 3.

Descemet's membrane appeared as a clearly-defined thickened structure, which could be focused upon as a distinct tissue with the direct beam of the slit lamp. By this method the membrane appeared grey and thickened, while occasional irregular white areas were noted on its posterior surface. On retroillumination the beaten copper appearance, similar to that of early Fuchs's dystrophy, was noted. The most striking feature, however, was the absence of the hexagonal endothelial cell pattern in the zone of specular reflection, which appeared smooth but faintly granular. Minimal epithelial oedema was also present.

The visual acuity in all unoperated eyes, save the two mentioned above, was counting fingers. No other ocular manifestations of the disorder were detectable, although congenital nystagmus of the horizontal ocular type was present in four of the 24 observed affected individuals. In two of these patients corneal opacification had occurred during the early neo-natal period, and was therefore considered secondary to visual impairment. Nystagmus was not detectable in those with similar densities of opacities but in whom the visual deterioration had occurred later in childhood.

### **Corneal Grafts**

These had been performed in a number of patients. Initially lamellar grafts were performed but these had little success and rapidly developed the stromal haze characteristic of the pre-operative state. More recently partial penetrating corneal grafts were performed in a number of cases. As Table II (overleaf) shows, the results have generally

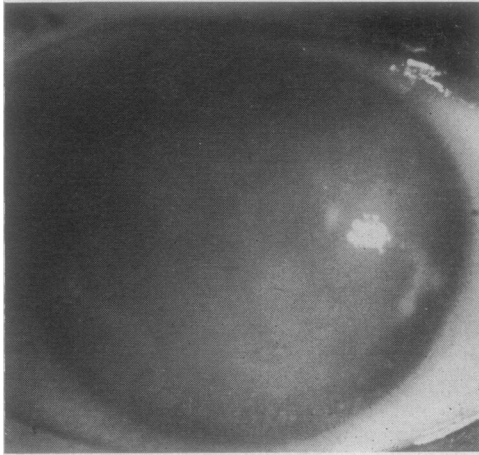


FIG. 2A Case V 11, aged 14 years, left eye

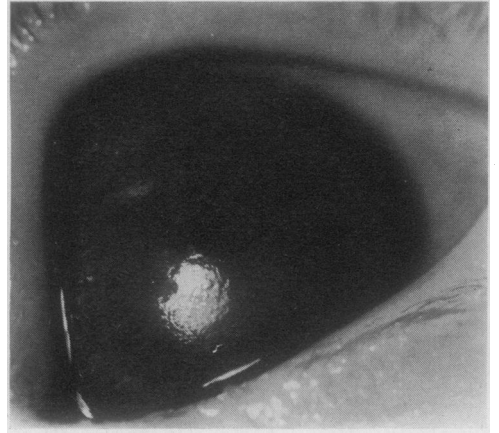


FIG. 2B Case VI 14, aged 7 months, left eye

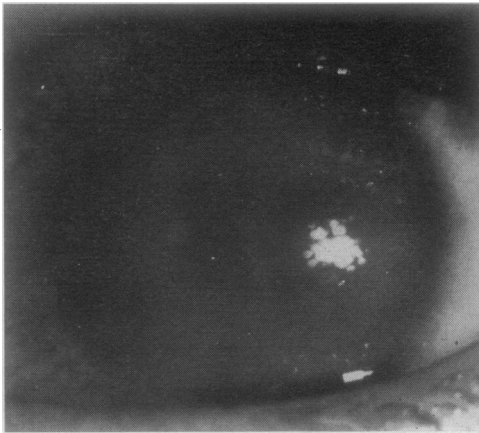


FIG. 2C Case VI 12, aged 3 years, left eye

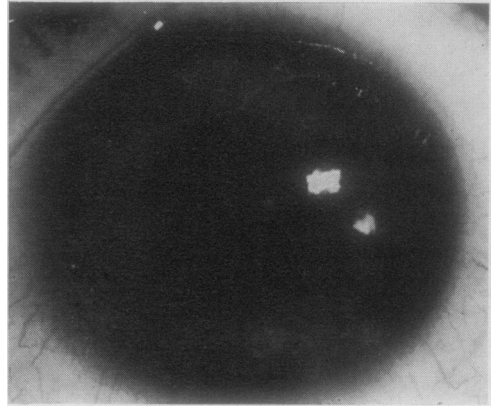


FIG. 2D Case VI 1, aged 11 years, left eye

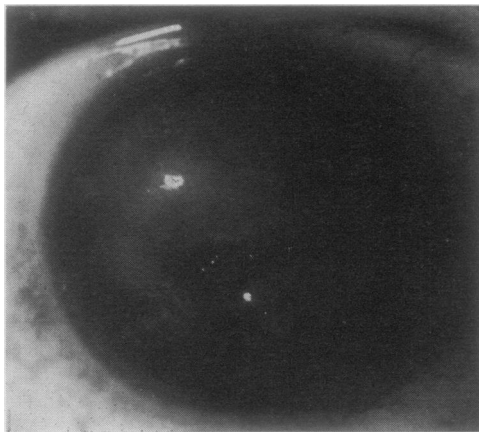


FIG. 2E Case IV 12, aged 40 years, right eye

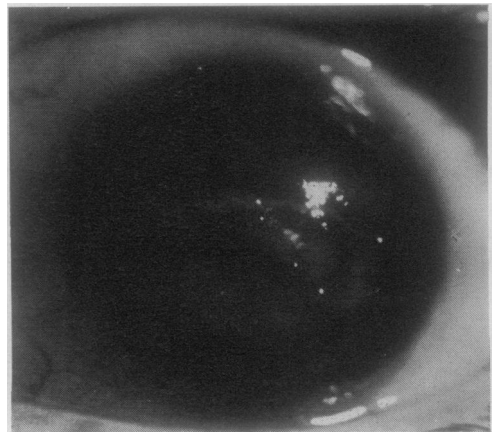


FIG. 2F Case IV 11, aged 46 years, left eye

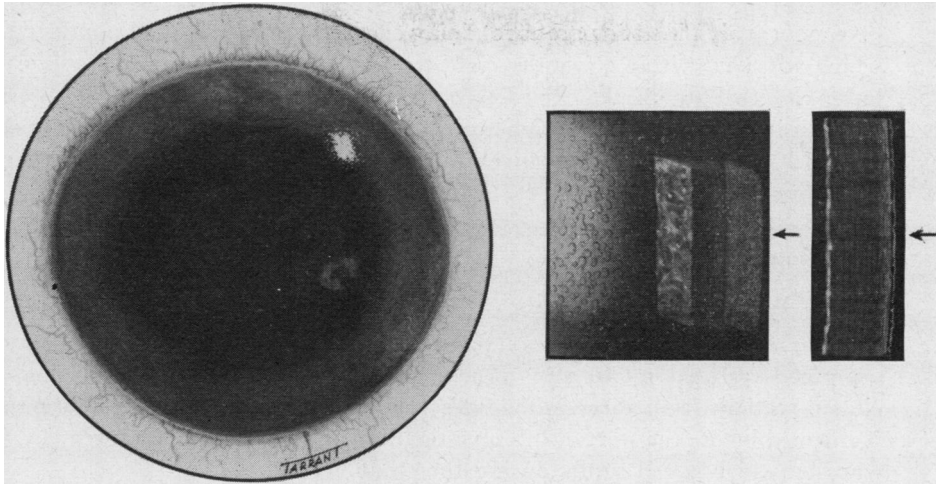


FIG. 3 Case V 7, aged 37 years, right eye. Painting of the cornea, showing thickened Descemet's membrane, fine opacities of Descemet's membrane, and stroma

**Table II** Results of 21 perforating grafts in 10 subjects (5 eyes grafted twice)

Pedigree no.	Present age (yrs)	Number of grafts	Right			Left		
			Size (mm.)	Duration clear (mths)	Present state	Size (mm.)	Duration clear (mths)	Present state
IV 3	54	2 2	7	26	—	7	< 3	—
			7	4	Clear	7	72	Clear
IV 6	65	1				7	9	Clear
IV 7	63	1	7	< 3	Opaque Secondary glaucoma			
IV 16	71	2	5	18	Clear	5	< 3	Opaque Secondary glaucoma
IV 21	61	2	7	36	Opaque	7	< 3	Opaque Secondary glaucoma
IV 28	47	2	5	< 3	Opaque Secondary glaucoma	5	< 3	Opaque Secondary glaucoma
IV 35	32	2 1	5	6	Opaque	7	< 3	—
						5	< 3	Opaque Secondary glaucoma
V 7	37	1				7	< 3	Opaque Secondary glaucoma
VI 4	29	2 2	5	< 3	—	5	18	—
			7	24	Opaque	7	< 3	Opaque
VI 5	22	1				5	< 3	Opaque Secondary glaucoma

been poor, only nine of 21 grafts retaining clarity for longer than 3 months. Of the twelve which opacified within 3 months, eight were attributable to surgical complication. These latter cases eventually developed secondary glaucoma with peripheral anterior synechiae as a result of pupil block (peripheral iridectomy not performed), persistent shallowness of the anterior chamber postoperatively, or loss of the anterior chamber and wound separation on suture removal.

## Pathology

### LIGHT MICROSCOPY

Sections from the corneal discs removed at the initial penetrating keratoplasty were examined by light microscopy after staining with haematoxylin and eosin. These included sections from three individuals (IV 3, IV 16, IV 21) in whom keratoplasty was performed before the start of this investigation, as well as from the three (IV 6, IV 7, V 7) who had their initial grafts during the study.

The anterior cornea in all cases showed atrophy and irregularity of the epithelium and deficiencies in Bowman's membrane. The stroma exhibited a variable degree of hyaline degeneration with superficial vascularization, scarring, and calcium deposition (Fig. 4).

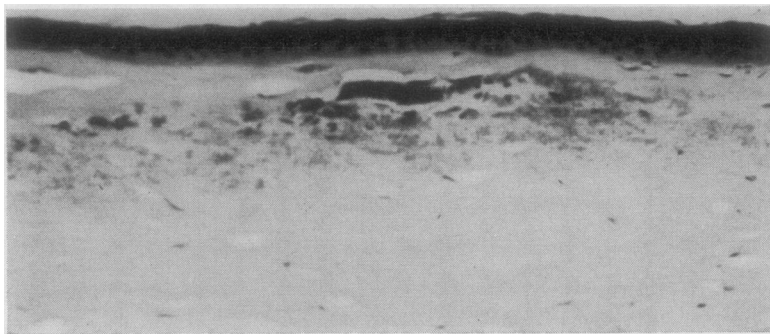


FIG. 4 Case IV 21. Light photomicrograph, showing hyaline degeneration and calcification of stroma.  $\times 130$

The posterior cornea in two cases (IV 6 and IV 16) showed absence of Descemet's membrane and endothelial cells. In the remaining four cases, Descemet's membrane was diffusely and irregularly thickened with a markedly reduced number of endothelial cells (Fig. 5, opposite). In places the membrane was separated from the overlying stroma (Fig. 6, opposite).

### ELECTRON MICROSCOPY

The corneal discs were immediately fixed in 2.5 per cent. glutaraldehyde in Tyrode buffer and the required pieces of tissue were post-fixed in 1 per cent. Zetterqvist's osmium tetroxide solution. After the usual dehydration and clearing processes, the tissue blocks were embedded in araldite. A few blocks were impregnated with phosphotungstic acid in absolute alcohol before the clearing process in toluene. Sections were cut on a Huxley ultramicrotome using a glass knife, and the electron micrographs were taken with an A.E.I. EM6 microscope.

The electron microscopy of the corneal sections from Case IV 7 (aged 63) and Case V 7 (aged 37) showed virtually identical changes in the stroma, Descemet's membrane, and endothelium.

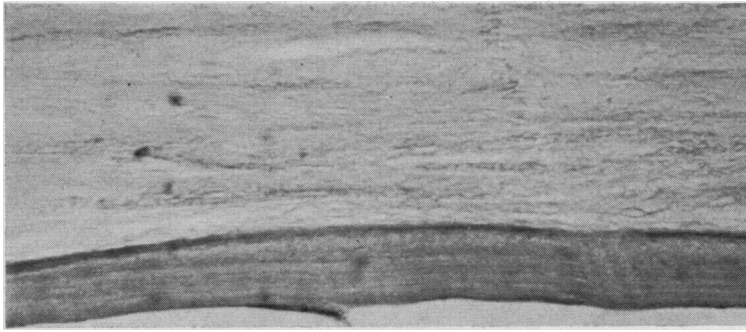


FIG. 5 Case IV 21. Light photomicrograph, showing thickened Descemet's membrane with single endothelial cell.  
× 530

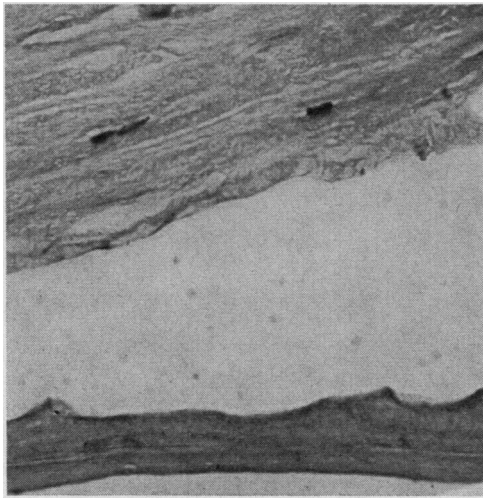


FIG. 6 Case IV 21. Light photomicrograph, showing thickened Descemet's membrane which has separated from the stroma.  
× 400

### *Stroma*

The notable features were separation of collagen lamellae, fragmentation and disorganization of collagen fibres, and degeneration of keratocytes. There was some increase in stromal thickness, with numerous "water clefts", but only a few collagen fibres showed an increased diameter. Small amounts of granulofibrillar material and occasional foci of the 1000 Å banded structure (long-spacing collagen) were randomly scattered among the collagen fibres (Fig. 7, overleaf). In the superficial stroma of the older of the two corneae, occasional foci of amyloid fibres and a few blood vessels were observed; Bowman's membrane was irregular and in places showed small deposits of calcium.

### *Descemet's membrane*

The most striking finding was the increase in thickness of Descemet's membrane caused by the formation of collagen fibres with a 640 Å periodicity.

In both corneae, the banded zone of Descemet's membrane appeared normal, although abnormally well demarcated from the non-banded zone. The increase in the total thickness of Descemet's membrane was due to an increase in the thickness of the non-banded zones which were heavily impregnated with typical collagen fibres. Whereas, in the normal cornea, the non-banded zone is about 1-3 times thicker than the banded zone, in our younger case it was 4-5 times thicker (Fig. 8, overleaf) and in our older case 8-15 times thicker (Fig. 9, overleaf). The formation of typical collagen fibres was particularly

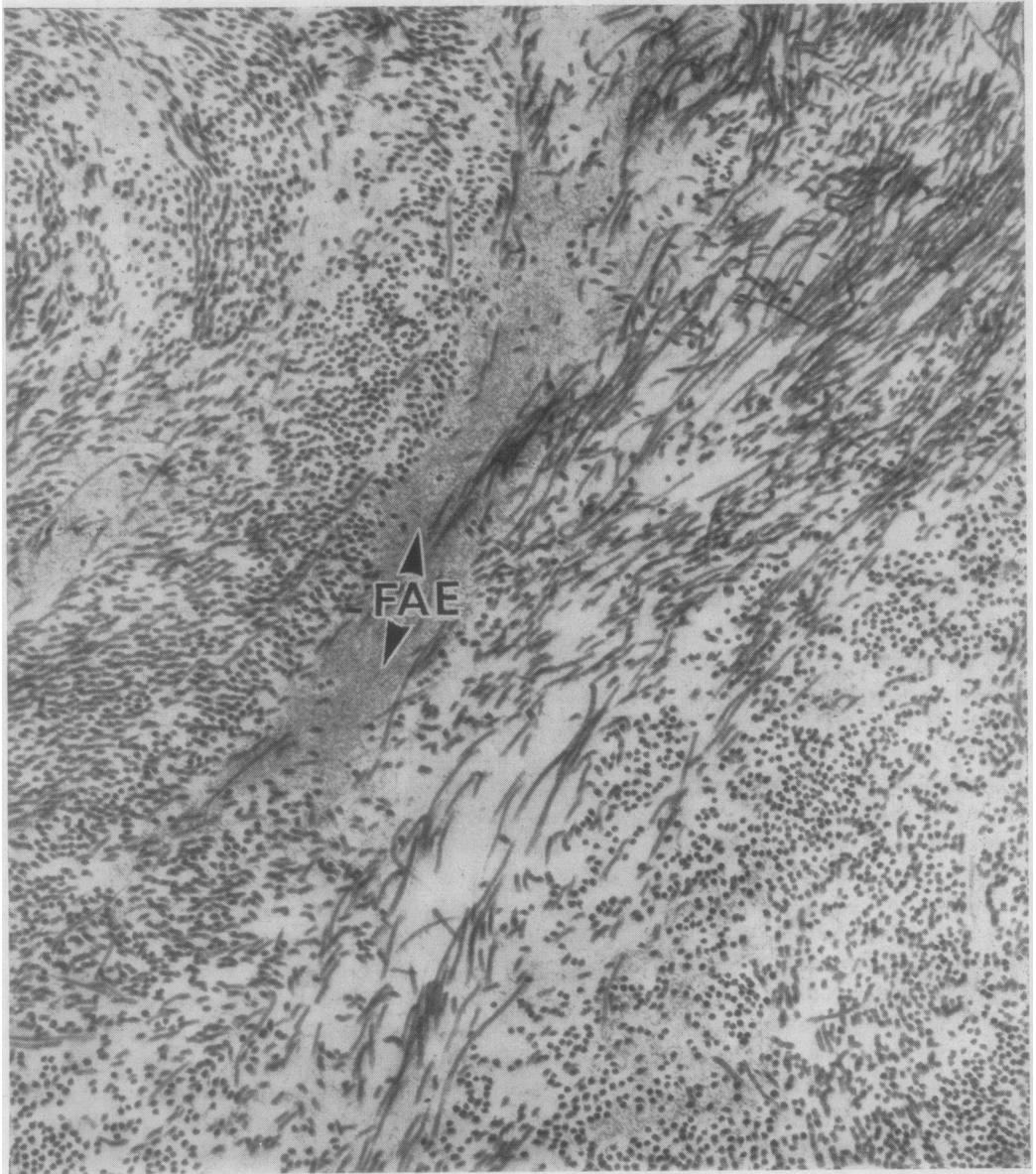


FIG. 7 Case V 7. Electron micrograph of corneal stroma, showing irregular deposition of a fibrillo-amorphous element (FAE); the collagen fibres are disorganized and, in places, unduly separated. Phosphotungstic acid stained.  $\times 30,000$

prominent in the older cornea, where the non-banded zone of Descemet's membrane was almost completely replaced by typical collagen fibres.

#### *Endothelium*

In both eyes only occasional endothelial cells were found. These appeared atrophic and the cell cytoplasm of most cells contained melanin granules.



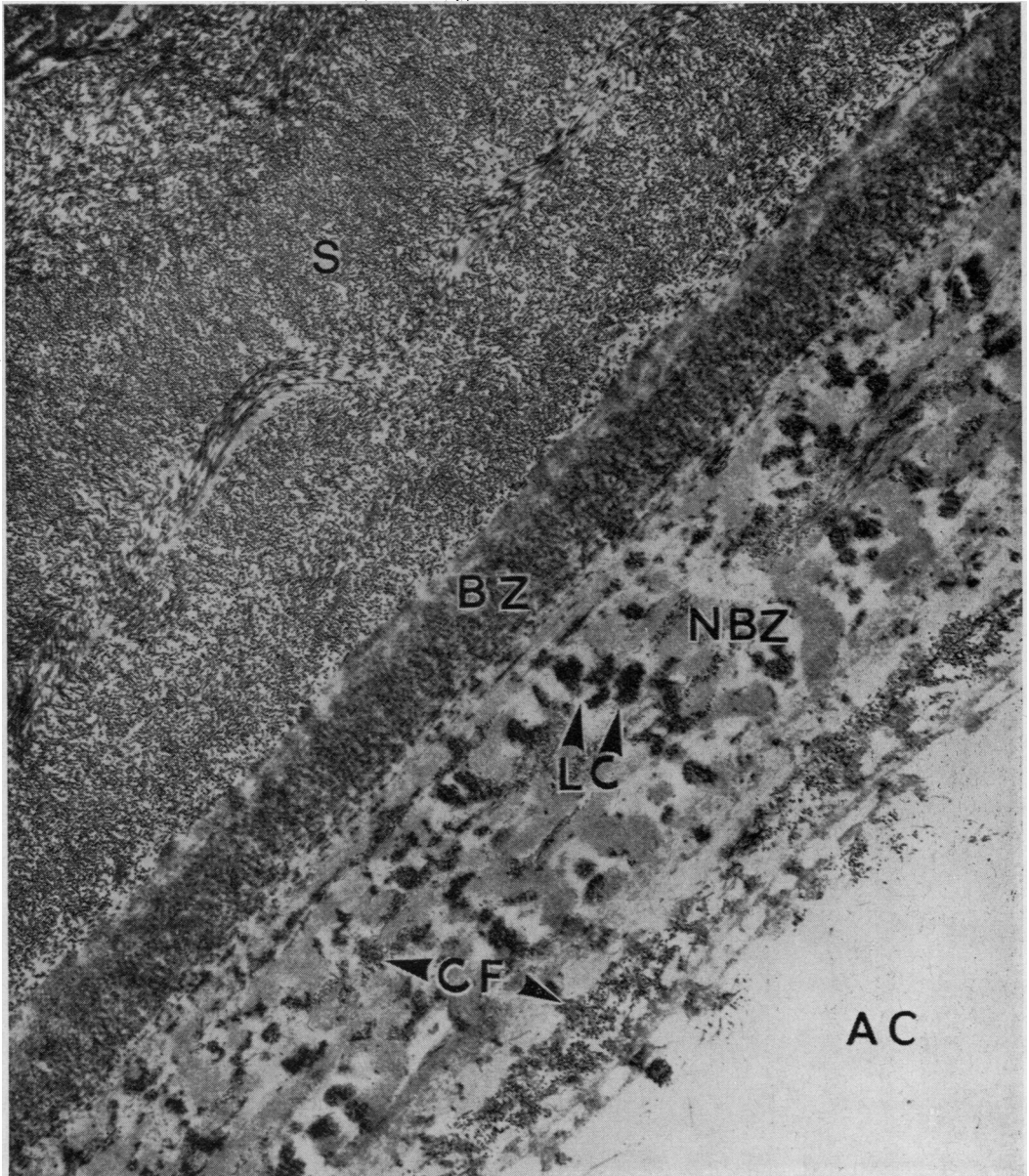


FIG. 8 Case V 7. Low-power electron micrograph of Descemet's membrane and adjacent stroma. In the non-banded zone (NBZ) of Descemet's membrane, the presence of typical collagen fibres (CF) and some increase in the long-spacing collagen (LC) is evident. The banded zone (BZ) appears rather abnormally well demarcated from the non-banded zone. In the stroma (S) some irregularity of collagen fibre arrangement can be seen. AC = anterior chamber. Phosphotungstic acid stained.  $\times$  approx. 4,000

## Discussion

### GENETICS

The corneal dystrophy is clearly hereditary, and by its rarity most probably due to a gene or point mutation. This gene or length of DNA-coded polypeptide chain appears to be




FIG. 9 Case IV 7. Low-power electron micrograph of Descemet's membrane and adjacent stroma. The non-banded zone of Descemet's membrane is almost completely replaced by typical collagen fibres (CF), but the banded zone (BZ) appears normal, although abnormally well demarcated from the non-banded zone. In the stroma (S) some disorganization of collagen fibres is apparent. AC = anterior chamber. Phosphotungstic acid stained  $\times$  approx. 4,000

inherited in a dominant manner. Alternatively, one may say that all those individuals heterozygous at the locus, manifest the disorder. Despite the numbers of affected males and females observed being consistent with the location of the gene on the X chromosome, male-to-male inheritance excludes this possibility (illegitimacy virtually

excluded by blood group analysis). If a single autosomal locus is to be considered, the ratio of affected to unaffected (39 : 39) is as expected, but difficulties arise in accounting for the male-to-female ratios, which are expected approximately once in 500 occasions. It is difficult to account for this departure from expected ratios. Two non-allelic autosomal loci may interact to distort expected ratios, such as the ABO-secretor situation (Thompson and Thompson, 1966), but cannot account for the observed ratios in the corneal dystrophy family.

It is likely then that a single autosomal locus is responsible for both the corneal dystrophy and the sex ratio distortion. Genes always appear to have multiple effects, as is seen in *Drosophila melanogaster*, where all mutant genes affect viability, and even those responsible for such minimal effects as eye colour and bristle number are also found to impair reproductive function, length of life, and survival under unfavourable conditions (Clarke, Evans, Harris, McConnell, and Woodrow, 1968). In *D. melanogaster*, Sandler, Hiraizumi, and Sandler (1959) have demonstrated cytogenetically a segregation-distorter locus which, when present in heterozygous male parents, is recovered more frequently than its normal allele among progeny. This phenomenon, where a heterozygote produces two gametes in a ratio other than 1 : 1, is known as meiotic drive. In mammals other phenomena have been found responsible for segregation distortion such as at the T-locus of the house mouse, where time of mating affects the ratio of normal to short tails among progeny of males heterozygous for a t-allele (Braden, 1958; Dunn, 1960). Specific sex-ratio distortions have been found in human kindreds where a single mutant gene has been segregating. In the recent study of X-linked retinoschisis in Finland, Eriksson, Vainio-Mattila, Krause, Fellman, and Forsius (1967) found a significant excess of males, both affected and unaffected, among offspring of heterozygous female carriers, where meiotic drive cannot be the explanation. In the present study the distortion is also among the offspring of heterozygous females to a similar level of significance. However, to account for the excess of affected female offspring and of unaffected male offspring of heterozygous females, one must assume that ova bearing the corneal dystrophy locus are preferentially fertilized by X-bearing sperms, while those ova carrying the normal allele are preferred by the Y-bearing sperms! It seems likely then that, despite the very low probability, the disturbed sex-ratio amongst offspring of affected females has occurred by chance rather than arising by some unknown process of pre-gametic selection or preferential fertilization.

#### CLINICO-PATHOLOGY

The clinical picture of affected individuals was similar to that seen in advanced Fuchs's dystrophy, where involvement of the cornea extends to the limbus. Despite the extensive widespread involvement, the symptomatology was never severe enough to be called bullous keratopathy where pain and photophobia from rupture of epithelial bullae occur. Although mild photophobia and epiphora were present in some of the children during the early stages of the dystrophy, increasing opacification was often associated with reduction of the symptoms. This may have been due to the thickening of Bowman's membrane and greater adhesion to it of the basal layer of epithelium, as suggested by Kenyon and Maumenee (1968).

The most notable difference in slit-lamp appearance from that in Fuchs's dystrophy was the complete absence of cornea guttata and endothelial cells. Although most cases of Fuchs's dystrophy have cornea guttata with a relatively normal pattern of endothelial cells between the excrescences, Stocker (1953) in a histological study found no cornea guttata and a markedly reduced number of endothelial cells in five of 25 cases with the

clinical picture of Fuchs's dystrophy. The slit-lamp appearance of these cases, as reproduced by Vogt (Stocker, 1965), is similar to that in our two cases in which the endothelial surface could be clearly seen.

The light microscopy sections are virtually indistinguishable from those five cases of Stocker (1953). Other reports on the histological appearance of the cornea in patients with the clinical picture of congenital corneal dystrophy are to be found in the literature (Desvignes and Vigo, 1955; Franceschetti and Babel, 1945; Maumenee, 1960; Keates and Cvintal, 1965; Kenyon and Maumenee, 1968). These authors have concentrated on the stromal changes, while often the posterior corneal layers have been missing, or have not been included in the report, or have shown inconstant abnormalities. One reason for this may be the ease with which Descemet's membrane separates from the oedematous stroma during the corneal grafting procedure, as suggested by Brown, Dohlman, and Boruchoff (1965) and Hagedoorn (1967). Of three corneal buttons originally submitted for light microscopy from previously unoperated cases, Descemet's membrane was present in only two, and during the present study, when three further patients received grafts, Descemet's membrane separated during dissection in one case despite foreknowledge of this possibility.

Electron microscopy has confirmed the relative absence of endothelial cells, the complete absence of cornea guttata, and the increased thickness of Descemet's membrane. The stromal changes are most unlikely to be primary in nature, although Kenyon and Maumenee (1968) did suggest that a primary defect in fibrillogenesis may be responsible for the stromal alterations found in congenital corneal dystrophy. The increased diameter of collagen fibrils, which these authors considered to be due to defective fibrillogenesis and to be of diagnostic significance, was noted occasionally in our present investigation, but this change is interpreted as the result of chronic stromal oedema. Furthermore, increased diameter of collagen fibrils has been noted in other corneal disorders (Tripathi, 1969). The oedema is probably secondary to the structural alterations noted in Descemet's membrane and the lack of endothelial cells. Although both corneal buttons show a similarly marked reduction in the number of endothelial cells, the increased thickening of Descemet's membrane is much more marked in one cornea which is 25 years older than the other. The progressive alterations might well have started in a Descemet's membrane of normal thickness. If so, these changes might also be secondary to the absence of endothelial cells, resulting in degeneration of the non-banded zone from direct contact with the aqueous humour. The increased thickness and unusual morphology of the non-banded zone of Descemet's membrane has not previously been described. Increased thickness of Descemet's membrane has been noted in the closely related condition of Fuchs's dystrophy, but it is the banded zone wherein the increase occurs in the latter disorder while the non-banded zone becomes thinner (Kayes and Holmberg, 1964). Furthermore, in congenital corneal dystrophy, only the occasional normal appearing endothelial cell is found, while in Fuchs's dystrophy the endothelium is uninterrupted and the cells often show vacuoles in the cytoplasm (Kayes and Holmberg, 1964).

In the most recent report of a patient with congenital corneal dystrophy (Kenyon and Maumenee, 1968), thinning of Descemet's membrane was noted. However, the only Descemet's membrane present was the anterior banded portion, while there was complete absence of the non-banded layer as well as of endothelial cells. Owing to the friability of the oedematous cornea, it may be that the cornea separated through Descemet's membrane leaving the non-banded layer and endothelium. This would explain the dissection difficulties encountered by the authors.

Those few individuals with less severely affected corneae are likely to have a greater number of functioning endothelial cells, although the pattern as it appears in the zone of specular reflection is abnormal. In the most severely affected cases, the cornea appeared normal at birth but rapidly became oedematous. The endothelial cells, therefore, probably never function normally. Whether or not the sequence is that normal numbers of dysplastic endothelial cells are laid down during embryogenesis, secrete an abnormal Descemet's membrane, and then atrophy, or whether only a few relatively normal endothelial cells secrete a Descemet's membrane which becomes abnormal as a result of direct contact with the aqueous humour is unknown; this will be resolved only by obtaining sections from an affected neonate. But as the endothelial cells are either quantitatively and/or qualitatively abnormal, the dystrophy should be described as primarily endothelial.

The secondary stromal disturbances could have contributed to the frequent surgical complications associated with grafting. It may be that the insertion of a corneal button thinner than the host cornea is an important factor in contributing to wound leakage. The laying down of fibrous tissue across the donor-host junction is also likely to be impaired or delayed in these patients as a result of the chronic stromal oedema (Hughes and Hurt, 1966).

In the remaining cases, however, technical factors could not be implicated. The onset of stromal and epithelial oedema in many of them was considered to be due to donor-host reaction, and the patient therefore received short-term treatment with large doses of systemic steroids in the hope that this would produce clearing of the cornea. Recently, failure of the donor endothelial cells has been advanced as a cause of opacification of a previously clear graft. Work by Polack, Smelser, and Rose (1964), using tritiated thymidine to label donor endothelial cells, and by Chi, Teng, and Katzin (1965), using sex chromatin as a marker, has demonstrated in rabbits that clarity of corneal grafts was associated with persistence of the donor endothelium while in cases which had opacified the donor endothelium had been replaced by that of the host. In congenital endothelial corneal dystrophy, an adequate number of endothelial cells which could cover the donor is not found. It seems likely, therefore, that the development of oedema in a previously clear graft is due to the failure of the donor cells. The present results, with approximately 40 per cent. of grafts clear at 6 months and only 15 per cent. at 2 years, are inferior to those reported in early cases of Fuchs's dystrophy. Stocker (1965) reported 80 per cent. of grafts clear at 6 months and similarly Paton and Swartz (1959) reported 83 per cent. clear grafts, although these authors recorded lower rates of success in advanced Fuchs's dystrophy (Stocker, 1956—20 per cent.; Paton and Swartz, 1959—50 per cent.). These results pose the question whether the procedure should be performed at all in cases of endothelial dystrophy. The most favourable results in Fuchs's dystrophy are found where the most heavily involved central corneal area can be excised. In endothelial dystrophy it is not possible to get beyond the limits of abnormal endothelium and graft clarity therefore depends on survival of the donor endothelium which will eventually fail.

Whether one should advise grafting to patients affected with endothelial dystrophy appears debatable. At the best the donor endothelium will persist for only a few years. At the worst opacification will occur within a few months of grafting or there will be surgical complications leading to chronic secondary glaucoma. As the latter course appears at least equally likely, decisions as to grafting should not be made without the patient or those responsible being made aware of the risks involved. Should the decision to proceed with grafting be made, more rigid criteria concerning the age of the donor, and the period of time allowed to elapse between the donor's death and fixation of the

donor graft into the host, might well be considered. At present the donor's age is not considered vital, and corneae are accepted for penetrating keratoplasty having been kept at 4°C. for up to 24 hours from the time of enucleation. While these criteria may well be adequate for the majority of corneal disorders requiring penetrating grafts, in endothelial dystrophy and advanced Fuchs's dystrophy one is dependent on functioning donor cells in the same manner as with organ transplants. It would therefore seem desirable to reduce the period of acceptability of donor corneae to within 4 hours from the death of the donor to incorporation in the host eye, and—knowing the frequency with which cornea guttata appears with increasing age (Kaufman, Kapella, and Robbins, 1966)—to accept corneae only from donors under 50 years of age. As an alternative and preferable procedure, the period during which the donor cornea suffers from circulatory arrest may be reduced to an hour or less by using healthy corneae from eyes enucleated for posterior segment pathology.

### Summary

A family wherein 39 members were affected with an hereditary congenital corneal dystrophy has been described. The disorder was most likely the result of a single autosomal gene mutation inherited in a dominant manner, although a significant difference in expected ratios of affected and unaffected sons and daughters of affected females was present. The clinical picture, similar to that of Fuchs's dystrophy, developed during the post-natal period and was usually well established by early childhood. Histology of several corneal discs removed at the time of initial penetrating keratoplasty showed changes in the posterior cornea—a marked reduction in the number of endothelial cells and thickening of the non-banded zone of Descemet's membrane. These were considered primary and responsible for the stromal changes of oedema with separation, fragmentation, and disorganization of collagen fibrils. The indifferent results of penetrating keratoplasty were due to the frequency of surgical complications and to the inability of technically satisfactory grafts to remain clear. This latter development probably results from a failure of the donor endothelial cells and their replacement by the defective cells of the host.

We are particularly grateful to the late Mr. A. G. Leigh for his interest and encouragement when starting this project and to Miss Kay Major and Miss Rita Mason, Health Visitors to the Population Genetics Research Unit, for their assistance with home visiting. We should also like to thank Prof. Norman Ashton and Dr. A. C. Stevenson for their helpful criticism in the preparation of this paper.

### References

- ARMAIGNAC, H. (1911) *Bull. Soc. franç Ophthal.*, **28**, 164  
 BRADEN, A. W. H. (1958) *Nature (Lond.)*, **181**, 786  
 BROWN, S. I., DOHLMAN, C. H., and BORUCHOFF, S. A. (1965) *Amer. J. Ophthal.*, **60**, 43  
 CHI, H. H., TENG, C. C., and KATZIN, H. M. (1965) *Ibid.*, **59**, 186  
 CLARKE, C. A., EVANS, D. A. PRICE, HARRIS, R., MCCONNELL, R. B., and WOODROW, J. C. (1968) *Quart. J. Med.*, **37**, 1  
 CONTINO, F. (1941) *Ann. Ottal.*, **69**, 438  
 DESVIGNES, P., and VIGO (1955) *Bull. Soc. Ophthal. Fr.*, p. 220  
 DUKE-ELDER, S. (1964) "System of Ophthalmology", vol. 3, Part 2, p. 529. Kimpton, London  
 DUNN, L. C. (1960) *Amer. Naturalist*, **94**, 385  
 ERIKSSON, A. W., VAINIO-MATTILA, B., KRAUSE, U., FELLMAN, J., and FORSIUS, H. (1967) *Hereditas (Lund)*, **57**, 373

- FRANCESCHETTI, A., and BABEL, J. (1945) *Ophthalmologica (Basel)*, **109**, 169
- HAGEDOORN, A. (1967) *Amer. J. Ophthalm.*, **64**, 433
- HUGHES, W. F., and HURT, A. C. (1966) *Ibid.*, **61**, 1171
- KAUFMAN, H. E., CAPELLA, J. A., and ROBBINS, J. E. (1966) *Ibid.*, **61**, 835
- KAYES, J., and HOLMBERG, A. (1964) *Invest. Ophthalm.*, **3**, 47
- KEATES, R. H., and CVINTAL, J. (1965) *Amer. J. Ophthalm.*, **60**, 892
- KENYON, K. R., and MAUMENEE, A. E. (1968) *Invest. Ophthalm.*, **7**, 475
- LAURENCE, G. Z. (1863) *Klin. Mbl. Augenheilk.*, **1**, 351
- MAUMENEE, A. E. (1960) *Amer. J. Ophthalm.*, **50**, 1114
- PATON, R. T., and SWARTZ, G. (1959) *A.M.A. Arch. Ophthalm.*, **61**, 366
- POLACK, F. M., SMELSER, G. K., and ROSE, J. (1964) *Amer. J. Ophthalm.*, **57**, 67
- SALTINI, G. (1887) *Rendiconto Soc. oftal. ital.*, p. 101 (cited by Contino, 1941)
- SANDLER, L., HIRAIZUMI, Y., and SANDLER, I. (1959) *Genetics*, **44**, 233
- STOCKER, F. W. (1953) *Trans. Amer. ophthal. Soc.*, **51**, 669
- (1956) *Trans. Amer. Acad. Ophthal. Otolaryng.*, **60**, 567
- (1965) In "The Cornea: World Congress, Washington, 1964," ed. J. H. King and J. W. McTigue, p. 133. Butterworths, London
- THOMPSON, J. S., and THOMPSON, M. W. (1966) "Genetics in Medicine", p. 63, Saunders, Philadelphia and London
- TRIPATHI, R. C. (1969) Unpublished observations
- VOGT, A. (1930) "Lehrbuch and Atlas der Spaltlampenmikroskopie des lebenden Auges", 2nd ed. Springer, Berlin. (Quoted by Stocker (1965))
- WAARDENBURG, P. J., FRANCESCHETTI, A., and KLEIN, D. (1961) "Genetics and Ophthalmology", vol. 1, p. 457. Blackwell, Oxford