

New implant for drainage in glaucoma

Clinical trial

A. C. B. MOLTENO

Department of Ophthalmology, University of the Witwatersrand and Baragwanath Hospital, Johannesburg, South Africa

The implant described in this communication is an adaptation for human use of that used by the author in rabbit eyes (Molteno, 1969).

Its basic principles are identical, namely:

- (1) A patent translimbal fistula is maintained by an acrylic tube.
- (2) A thin acrylic plate is rigidly attached to this tube in such a way that the lumen of the tube opens onto the upper surface of the plate. This plate (8 mm. in diameter and approximately circular in outline) is curved to fit and firmly sutured to the sclera. When covered by a flap of conjunctiva and Tenon's capsule, the plate forms the floor of a bleb which is in *free communication* with the anterior chamber and *cannot shrink to an area less than that of the plate*.

Implants

Those first used had the following specifications:

- (1) TRANSLIMBAL TUBE Length from 0.75 to 1.0 mm.
 External diameter 1.4 mm.
 Internal diameter 0.75 mm.
- (2) EPISCLERAL PLATE Length 8.5 mm.
 Breadth 8.5 mm.
 Radius of curvature of under surface 11 mm.
 Greatest thickness 0.9 mm.
 Suture holes placed as in Fig. 1.

As experience was gained subsequent implants were modified. The most important modification was the grinding of a flat facet on the anterior two-thirds of the upper surface of the plate. This facet allowed aqueous to drain even when the bleb wall became heavily fibrosed (Figs 1 and 2, opposite).

Additional modifications were made as follows:

- (1) Bevelling the outer end of the translimbal tube to prevent erosion through the limbal conjunctiva.
- (2) Adding to the facet a gutter leading back from the translimbal tube to distribute aqueous and prevent thinning of the bleb immediately over the "fistula".

- (3) Adding to the upper end of each suture hole a radial groove to allow fine sutures to lie flush with the upper surface of the plate so as not to erode through the bleb.

The currently used implant has all the features shown in Fig. 1.

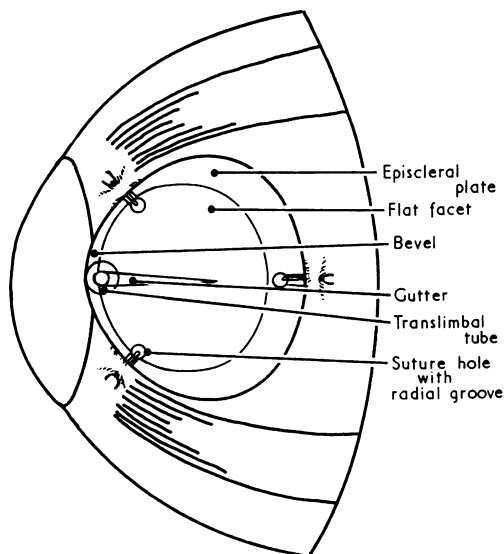


FIG. 1 Diagram showing features of implant and position on sclera

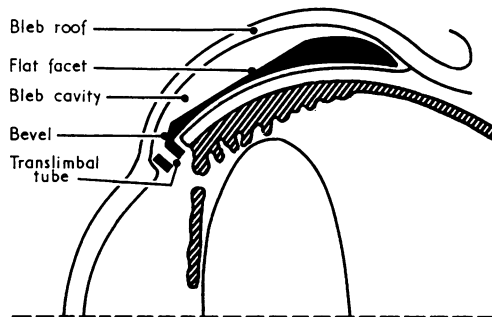


FIG. 2 Diagrammatic cross-section of eye, showing implant in position

Material

All implants used were made of "Stellon" brand dental and neurosurgical acrylic*. Before use they were boiled for 6 hours in three changes of distilled water in order to remove traces of Acrylic Monomer and catalyst and to sterilize them.

Design of clinical trial

All cases were personally examined on admission to hospital, where an attempt was made to control the glaucoma by medical therapy. Maximal therapy for primary open-angle glaucoma consisted of:

- (1) Gutt. Epitrate 2 per cent. four times a day.
- (2) Either gutt. Phospholine Iodide 0.125 per cent. twice a day or, if tolerated, gutt. Tosmeline 0.5 per cent. twice a day.
- (3) Diamox 250 mg. four times a day with potassium supplement.
- (4) Some cases received in addition to the above medicaments oral glycerol 150 ml. four times a day.

Cases in which the visual acuity had fallen to less than 6/60 and the intraocular pressure could not be reduced to 20 mm. Hg were admitted to the trial. All remained in hospital under close observation for a minimum of 3 months after the insertion of the implants.

* At present a trial is being undertaken using implants made of Transpex 1 sterilized by Ridley's caustic soda method (supplied by Rayner Optical Co., 100 New Bond Street, London, W.1). Results are promising and will be reported when sufficient data are available.

With the exception of two Hottentots all the patients were African Negroes. For details of age, sex, and diagnosis see Table I.

Table I *Age and sex distribution of eyes, by diagnosis*

<i>Diagnosis</i>	<i>Sex</i>		<i>Age (yrs)</i>	
	<i>Male</i>	<i>Female</i>	<i>Mean</i>	<i>Range</i>
Primary open-angle glaucoma	8	5	52	14-78
Same but with systemic steroids	6	3	65	54-78
Buphthalmos	3	6	3·2	1 mth-7 yrs
Aphakic glaucoma	4	0	66	59-70
Uveitis	3	1	38·5	26-48
Other secondary glaucoma	1	2	31	16-60
Total	42		42·9	

Methods

Preoperative and postoperative intraocular pressures were recorded weekly with a Goldmann applanation tonometer fitted to a Haag-Streit 900 slit lamp. Facility of outflow was measured over 4 minutes, by means of a Schwartzer electronic tonometer and recorder. Patients with buphthalmos who were too young to co-operate were examined under light fluothane anaesthesia, the intraocular pressure being measured with a Maklakoff applanation tonometer.

Surgical technique for insertion of implants

ANAESTHESIA AND HYPOTONY

General anaesthesia was preferred, but when not available local analgesia and akinesia as for a cataract extraction was used. The intraocular pressure was lowered as much as possible by intravenous infusion of mannitol 10 per cent. or oral administration of Diamox 500 mg., together with glycerol 150 ml. 2 hours before operation.

OPERATIVE PROCEDURE

- (1) Exposure was obtained by means of a lid speculum and superior rectus stitch. Implants were placed in both supero-nasal and supero-temporal quadrants, but the nasal quadrant was preferred as the conjunctiva and Tenon's capsule are thicker there.
- (2) Conjunctiva and Tenon's capsule were separately incised to expose the sclera. This incision was placed along the equator of the globe and extended from superior to medial (or lateral) rectus.
- (3) A flap of conjunctiva together with the full thickness of Tenon's capsule was dissected up to the limbus and the superficial corneal lamellae split for 2 mm. In order to obtain sufficient exposure of the limbus it was frequently necessary to extend the original incision through conjunctiva and Tenon's capsule across the insertion of the medial (or lateral) rectus.
- (4) A 2 mm. disc of "corneo-sclera" was removed by a trephine and a large peripheral iridectomy performed.
- (5) An implant with a translimbal tube of length equal to the thickness of the corneo-scleral disc was selected and placed with its tube in the trephine opening.

(6) The implant was then *firmly* sutured to the sclera with 7-0 silk. These sutures were placed so that they occupied the grooves in the plate and the knots were well away from the plate. Each suture was tied tight so as to raise a ridge of sclera next to the plate (Fig. 3).

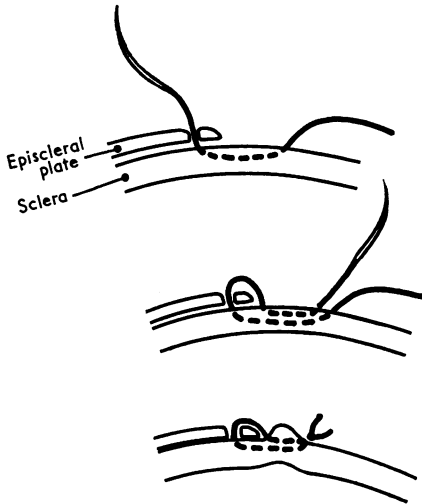


FIG. 3 *Mattress suture used to attach implant to sclera*

(7) The incision in Tenon's capsule was sutured, using five or six interrupted horizontal mattress sutures of 7-0 silk and tying the knots on the posterior margin of the incision. The conjunctival incision was tightly closed by a continuous stitch.

(8) An injection of Lincomycin and Depot-Medrol was given beneath the conjunctiva away from the bleb.

POSTOPERATIVE PROCEDURE

The eyes were padded for 24 hours, after which the patient was allowed up wearing dark glasses. All hypotensive therapy was discontinued from the time of operation and gutt. phenylephrine 10 per cent. and Sofradex were given as a routine until the eyes became quiet—i.e. *from 3 to 6 months later*.

Undue post-operative iritis was treated by atropinization and subconjunctival injection of Depot-Medrol. Nine eyes were given systemic steroids for 2 to 3 months after operation in addition to the above regime.

Complications

- (1) Vitreous loss in four eyes in which the intraocular pressure could not be reduced to safe levels preoperatively.
- (2) Persistent flat anterior chamber occurred in two eyes; one reformed spontaneously, and the other after drainage of suprachoroidal fluid.
- (3) Early perforation of the bleb occurred in six eyes, through buttonholing of the conjunctival flap at operation. In three of these eyes the implant was removed; in three the bleb was successfully repaired.
- (4) Late buttonholing of the bleb occurred in two cases which are discussed below.
- (5) Late corneal changes were not observed, but a dellen always formed next to heaped blebs and lasted for between 2 and 12 weeks.
- (6) Late lens changes occurred in one patient whose pre-existing cataract became mature one year after the insertion of an implant.

Results of insertion

After insertion of the implant a very constant course was followed in all uncomplicated cases:

- (1) The stage of hypotony, lasting 10 days.
- (2) The hypertensive stage, lasting from 6 to 12 weeks.
- (3) The stable stage in which the intraocular pressure remained steady or fell very slowly. This began after 8 to 12 weeks and has been observed so far for periods of up to 20 months (Figs 4 and 5).

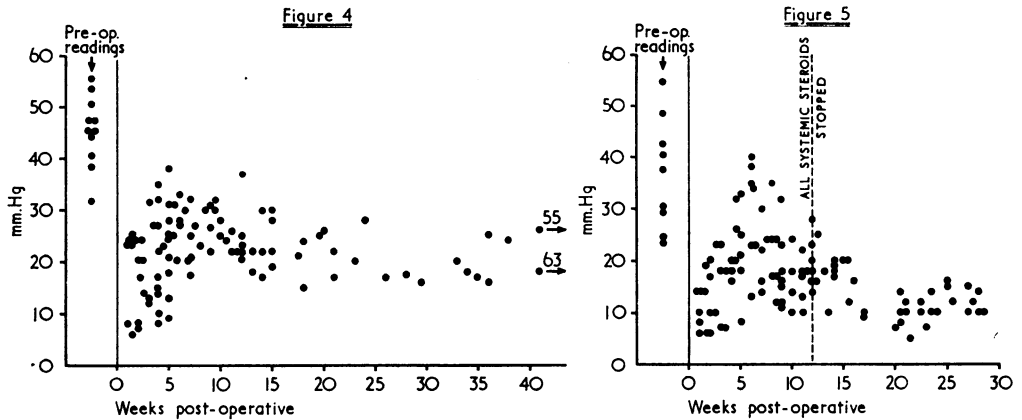


FIG. 4 Post-operative intraocular pressure readings in eleven eyes with open-angle glaucoma and no post-operative complications

FIG. 5 Post-operative intraocular pressure readings in nine eyes with primary open-angle glaucoma treated with systemic steroids

The “hypertensive” stage of increased intraocular pressure coincided with the formation of a thick-walled hyperaemic bleb and the occurrence of a mild iridocyclitis (Fig. 6).

After 6 to 8 weeks the intraocular pressure fell, and the bleb became less hyperaemic and iritis less severe (Fig. 7).

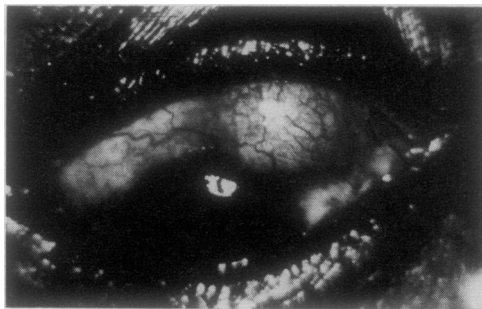


FIG. 6 Eye showing hyperaemic bleb 3 weeks after insertion of implant

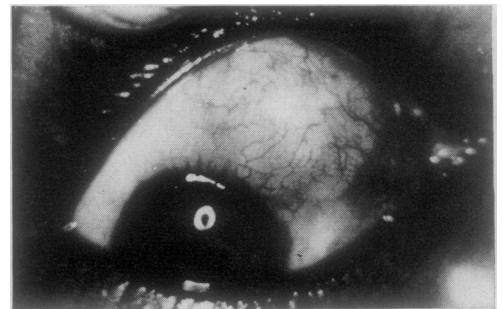


FIG. 7 12 weeks after insertion of implant. Eye quiet, bleb no longer hyperaemic

Eyes in the stable stage had the following characteristics:

- (1) Intraocular pressure of between 16 and 37 mm. Hg without hypotensive therapy (Table II).

Table II Mean results in 13 eyes with primary open-angle glaucoma

Measurement	Preoperative values on treatment		Postoperative values after 3 months without hypotensive therapy	
	Mean	Range	Mean	Range
Intraocular pressure	42	32-59	23.2	16-37
C.	.049	.01-.14	.13	.08-.20
Po/C	1,249	227-3,700	210	97-462

- (2) Liability to attacks of moderately severe iridocyclitis; with the passage of time, these attacks became milder and less frequent.
- (3) Anomalous response to miotics, in that the intraocular pressure did not fall as expected but rose by 3 to 5 mm. Hg; Diamox and Epitrate had their usual hypotensive effect and were well tolerated.
- (4) Thick-walled vascular bleb either heaped up or flat and more diffuse (Figs 8 and 9).

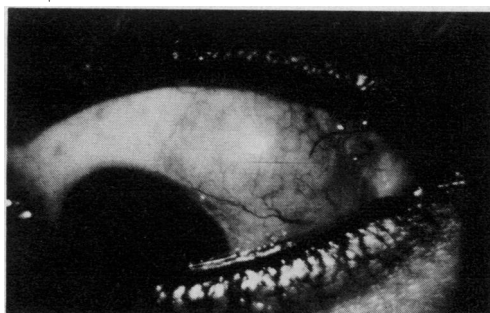


FIG. 8 Eye in stable stage 15 months after insertion of implant; there is a moderately vascular "heaped" bleb

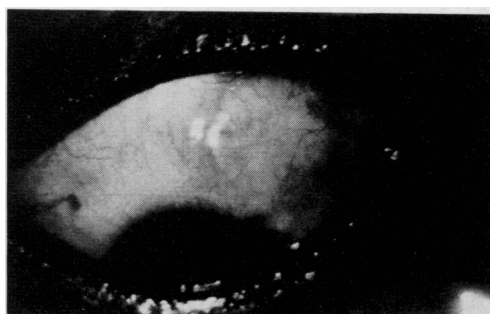


FIG. 9 Eye in stable stage 5 months after insertion of implant, showing "flat" bleb closely applied to episcleral plate

EFFECT OF SYSTEMIC STEROIDS

Nine eyes with primary open-angle glaucoma (in seven patients) were given, in addition to topical steroids, a course of systemic steroids in an attempt to limit the hypertensive stage and produce a lower stable intraocular pressure.

In each case 30 mg. prednisone was given daily, beginning one week after operation and maintained in gradually diminishing dosage until the eye became completely quiet after 6 to 12 weeks. During this period, if flare and cells appeared in the anterior chamber or if the intraocular pressure rose unduly (above 35 mm. Hg), subconjunctival injections of Depot-Medrol were given and the dosage of prednisone was temporarily increased if necessary to 45 or even 60 mg. daily.

Systemic steroids exerted a marked effect in every case, giving a shorter hypertensive phase, a thinner bleb, and a stable intraocular pressure of between 10 and 23 mm. Hg without hypotensive medication (Table III, overleaf).

Table III Mean results in 9 eyes with primary open-angle glaucoma on systemic steroids

Measurement	Preoperative values on treatment		Postoperative values after 3 months without hypotensive therapy	
	Mean	Range	Mean	Range
Intraocular pressure	36.9	24-55	13.8	10-23
C	—	—	.29	.20-.46
Po/C	—	—	53	26-110

RESULTS IN BUPHTHALMOS AND SECONDARY GLAUCOMA

Because of the relatively large diameter (0.75 mm.) of the translimbal tube and the "forced" maintenance of the bleb, the implant has been used in advanced cases of buphthalmos (9) and in glaucoma following lens extraction (4), uveitis (4), and trauma (3). The course after insertion was the same as that described above for primary open-angle glaucoma. In these cases systemic steroids were not used except to control pre-existing uveitis (Table IV). The salient features in this group were:

Table IV Results in 20 eyes with buphthalmos and secondary glaucoma

Diagnosis	No. of Eyes	Measurement	Preoperative values		Postoperative values after 3 months without hypotensive therapy	
			Mean	Range	Mean	Range
Buphthalmos	9	Intraocular pressure	43*	26-50	19.7	14.6-25.8
Aphakic glaucoma	4	Intraocular pressure	42.5	35-60	18	15-22
		C	—	—	0.085	0.08-0.09
		Po/C	—	—	189†	177-200
Glaucoma secondary to uveitis	4	Intraocular pressure	52	50-59	18†	12-28
Other secondary glaucoma	3	Intraocular pressure	38	37-39	28	26-30

* No hypotensive therapy

† Two eyes received hypotensive therapy

- (1) The excellent results achieved in advanced buphthalmos where the implants were well tolerated and attacks of iridocyclitis did not occur.
- (2) The ability of the implants to function to some extent even when the translimbal tube was buried in vitreous (as it was in all four aphakic cases); where the vitreous was liquid drainage was good.
- (3) The implants inserted in cases of uveitis became blocked by exudate during periods of exacerbation, but as soon as the inflammation was overcome drainage was re-established.

Overall clinical results

The results of 47 operations are given in Table V (opposite). Implants were successfully inserted in 42 eyes and control of the intraocular pressure was achieved in 39 over an average follow-up period of 5½ months. The chief cause of failure was early bleb perforation which required the removal of three implants. Two cases discussed below developed

late bleb perforations; one required removal of the implant. Two of the five cases of uveitis were failures. One patient died with absolute glaucoma due to uncontrollable sympathetic ophthalmitis 6 weeks after the insertion of an implant (and is therefore omitted from Tables II to IV). The other failure is an irregular visitor to the outpatients' department, who is maintaining an intraocular pressure between 20 and 28 mm. Hg on irregular hypotensive medication 7 months after insertion.

Table V *Clinical results of forty-seven operations*

Diagnosis	Control*		Failure
	Without hypotensive therapy	With hypotensive therapy	
Primary open-angle glaucoma	3	9 one shallow anterior chamber two bleb buttonholes repaired: one developed a late cataract	1 excessive bleb fibrosis
Same, but with systemic steroids	8 one shallow anterior chamber	1	—
Buphthalmos	5	4	—
Aphakic glaucoma	1 one vitreous loss	2 one bleb buttonhole repaired one vitreous loss	2 one tube in solid vitreous one bleb buttonhole— implant removed
Glaucoma secondary to uveitis	2	1 one late bleb buttonhole repaired	2 one died one excessive bleb fibrosis
Other secondary glaucoma	—	3	3 three bleb buttonholes— implants removed two also vitreous loss
Totals	19	20	8

* Intraocular pressure not exceeding 20 mm. Hg

The single failure in the primary open-angle glaucoma group *not* treated with systemic steroids was due to massive bleb fibrosis, which caused the bleb to become bound down to the convex upper surface of the plate. Study of this case led to the faceting of all subsequent implants.

EFFECT OF IMPLANTS ALONE IN 42 CASES IN WHICH 3 OR MORE MONTHS FOLLOW-UP IS AVAILABLE (Tables II, III, IV, and VI)

In cases of primary glaucoma and buphthalmos no hypotensive medication was given for 3 months after insertion. This was done primarily to produce a large distended bleb, but it also allowed an assessment to be made of the effect of the implant alone in different groups, without having to take into account the effect of hypotensive therapy.

In primary open-angle glaucoma the implant produced a mean intraocular pressure of 23.5 mm. Hg at 3 months. In a similar group treated in an identical manner except for the use of systemic steroids, the mean intraocular pressure at 3 months was 13.8 mm. Hg.

In the case of buphthalmos the mean intraocular pressure at 3 months was 19.7 mm. Hg.

Table VI *Follow-up period (42 eyes)*

<i>Length of follow-up (mths)</i>	<i>No. of eyes</i>
3-6	28
6-9	8
9-12	2
12-18	2
18+	2
<hr/>	
Mean follow-up	5½ mths
(range 3 to 20)	

Table VII *Long-term trend of intraocular pressure (27 eyes)*

Six eyes with the longest post-operative follow-up are included, those with pre-existing uveitis are omitted

<i>Postoperative time (mths)</i>	<i>Mean intraocular pressure</i>	<i>No. of eyes</i>
3	22.1	6
6	20	6
9	19	6
12	18.25	5
15	19	3
18	16	1
<hr/>		

} 27

LONG-TERM TRENDS IN INTRAOCULAR PRESSURE

In individual eyes the long-term trend has been for the intraocular pressure to fall gradually together with a corresponding rise in the coefficient of outflow (Table VII).

The only exceptions to this rule were a single case of primary open-angle glaucoma in a young woman aged 26 years whose intraocular pressure remained unchanged over a period of 15 months, and the cases of uveitis. In the latter, exacerbations caused temporary increases in intraocular pressure but the trend was for the intraocular pressure as measured between attacks of uveitis to fall, provided that the uveitis received prompt and effective treatment.

Discussion

Possible late extrusion of an implant requires consideration. In the present series only two eyes developed late buttonholes of the blebs (5 and 20 months respectively after insertion). The factors responsible in these cases were:

- (1) Both implants had not been firmly sutured to the sclera with mattress sutures and therefore tended to rise up into the "roof" of the bleb.
- (2) In both cases the translimbal tube became blocked: one by exudate during an exacerbation of a pre-existing uveitis and the other by organized lens material (this was a case of post-traumatic glaucoma with disruption of the lens).
- (3) In the first case, as a result of massive and prolonged steroid therapy used to control the pre-existing uveitis, the bleb became extremely thin.

The case of uveitis had the "buttonhole" repaired and at present shows no tendency to extrude 12 months after insertion. The case of post-traumatic glaucoma had the implant removed as it was thought that the membrane separated it from the interior of the eye.

In the remaining cases there has been no tendency for late bleb thinning or elevation of the plate. The essential factor for long-term retention of the implant seems to be *that aqueous should drain freely into the bleb*. Free drainage produces a heaped bleb which tends to spread beyond the margins of the plate (Fig. 8). A flat bleb closely applied to the episcleral plate results if free flow of aqueous through the translimbal tube is interrupted at some stage (Fig. 9).

An implant beneath a heaped bleb is most unlikely to extrude, while the flat bleb remains safe because draining aqueous produces oedema of its wall which keeps the implant well buried. However, as heaped blebs are probably safer and both types drain equally well, the author tries to produce heaped blebs by attention to the following points:

- (1) Firm suturing of implant to sclera, using mattress sutures.
- (2) Large clean peripheral iridectomy.
- (3) Stopping all hypotensive medication from the date of operation until the hypertensive stage is over.
- (4) Watching for and treating energetically any iridocyclitis which may occur.

In this series twelve flat blebs and thirty heaped ones were obtained.

This series of operations is consecutive, beginning with the first human implant. The relatively short follow-up of many of the cases is due to the fact that at the beginning of the project implants were routinely removed 3 to 4 months after insertion. However, with the current design, removal is usually not necessary, particularly when systemic steroids have been used. The overall control rate after insertion of an implant is 83 per cent. (including cases of early bleb perforation). With systemic steroids all nine cases were easily controlled—eight of the nine (88 per cent.) with no hypotensive therapy.

Long-term local steroids were needed in 32 per cent. of all cases to suppress uveitis (excluding cases of pre-existing uveitis). The cases which received systemic steroids became quiet sooner and in eight of the nine eyes (88 per cent.), it was possible to discontinue all local steroids 4 months after insertion, without uveitis occurring.

In eyes with persistent uveitis, or in which the intraocular pressure remained uncontrolled, removal of the implant resulted in cessation of the uveitis and (in selected cases) a marked improvement in drainage.*

Summary

- (1) An acrylic implant for drainage in glaucoma is described, together with surgical technique for insertion and management.
- (2) The results of 47 operations are reported.
- (3) Long-term retention of the implants is discussed.

I wish to thank Prof. M. H. Luntz for his help and encouragement at all times. My thanks are due to the Superintendents of Baragwanath Hospital and St. John's Eye Hospital for their co-operation and assistance and to Miss E. F. Andrews for drawing the three diagrams.

This work was assisted by grants from the University of the Witwatersrand and the Council for Scientific and Industrial Research.

Reference

- MOLTENO, A. C. B. (1969) *Brit. J. Ophthalm.*, **53**, 161

* Indications, techniques, and results of removal will be reported in a separate communication.