

# Ocular complications after therapeutic irradiation

P. A. MACFAUL AND M. A. BEDFORD

*Moorfields Eye Hospital and St. Bartholomew's Hospital, London*

At one time radiotherapy had a sinister reputation amongst ophthalmologists because of the frequent and often disastrous sequelae of ocular irradiation; cataract was common, the eyelids and the eye-ball sometimes underwent necrosis, and very occasionally malignant changes developed in irradiated tissues. Over the years increasing knowledge of the effects of radiation, refinements in techniques and dosage, and the development of protective devices associated with increasing liaison between eye surgeons, radiotherapists, and physicists have established the place of radiation in the treatment of eye disease.

Radiotherapy now has an accepted and increasingly important place in the treatment of intraocular tumours, particularly retinoblastoma, malignant melanoma of the choroid, and secondary deposits from primary tumours elsewhere in the body (Bedford, 1968) rhabdomyosarcoma of the orbit (Sagerman, Cassady, and Tretter, 1968), and also external ocular neoplasms such as basal and squamous-cell carcinoma of the eyelids and certain melanotic lesions (Lederman, 1958). Apart from these malignant conditions, several non-malignant diseases have been treated in the past, but at present radiotherapy is being used in only a few, such as certain cases of vernal catarrh and rosacea keratitis (Lederman, 1957), pterygium (Hilgers, 1966), and corneal vascularization following keratoplasty (Leigh, 1966).

Complications may arise with all forms of radiotherapy but vary with the different ocular tissues involved and the form of radiation used. Some of these effects are transient and insignificant; others are permanent and may or may not impair the structure or function of the eye. This account is based on a study of side-effects observed in cases of eyelid and ocular tumours treated in the Tumour Unit of Moorfields and St. Bartholomew's Hospital, London.

Clinically, the complications which may arise in some patients after therapeutic irradiation of the eye and adjacent structures may be divided into two groups:

- (1) *Acute* Those of early or rapid onset are usually reversible;
- (2) *Chronic* Those of delayed onset are usually irreversible.

The present study is mainly concerned with these delayed effects, and it is convenient to consider this problem on an anatomical basis.

## EPILATION

Loss of eyelashes frequently follows the treatment of rodent ulcers of the eyelids with *x* rays; in most cases this is likely to be permanent but apart from cosmetic considerations

is of no consequence (Fig. 1). Epilation of scalp hair is common at the exit portal after cobalt beam therapy using a direct anterior field for the treatment of retinoblastoma (Skeggs and Williams, 1966), but usually the hair grows again (Fig. 2). Loss of eyebrow hair (Fig. 3) may result from the application of a cobalt plaque for treatment of a malignant melanoma of the choroid, but this complication is extremely rare and is usually accompanied by evidence of damage to the lacrimal gland which will be discussed later.

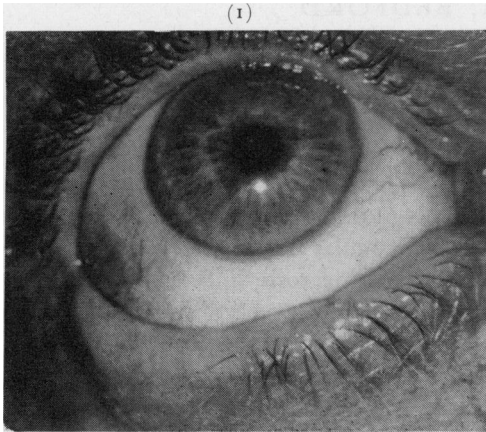


FIG. 1 *Localized loss of eyelashes after radiotherapy for basal cell carcinoma of eyelid*

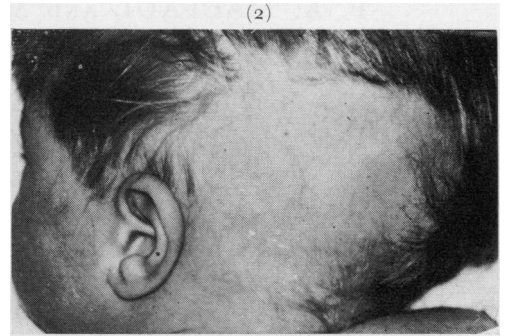


FIG. 2 *Epilation after cobalt beam therapy using an anterior field*

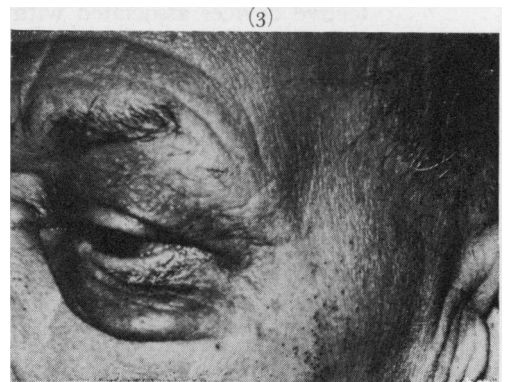

FIG. 3 *Loss of the outer half of the eyebrow due to application of a cobalt plaque for a malignant melanoma of the choroid*

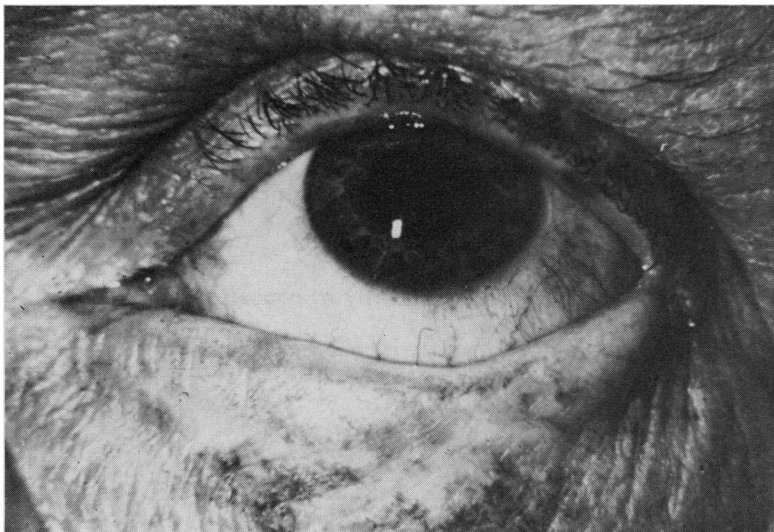

FIG. 4 *Skin changes after irradiation for basal cell carcinoma of the eyelid, showing epilation, depigmentation, telangiectasia, and atrophy*

## SKIN

Most palpebral tumours treated by radiation show the well-known acute radiation erythematous reaction which generally settles within a few weeks. At a later stage permanent changes may appear, such as depigmentation, atrophy, and telangiectasia, but these effects are usually relatively minor and harmless (Fig. 4). Shrinkage of the tissue of the lid is rare with modern techniques, but ectropion and entropion may develop in this way. In the past occasional cases of postradiation cancer developing in the periocular tissues have been reported (Cade, 1957; Forrest, 1962), but no such cases have occurred in our experience nor have we seen radiation necrosis of the eyelids.

## CONJUNCTIVA

In the treatment of a cutaneous basal or squamous cell carcinoma with  $x$  rays, the whole thickness of the lid receives a tumour-lethal dose, which may, in addition to the dermal changes previously mentioned, be followed by changes in the palpebral conjunctiva. These may take two forms:

(1) *Telangiectasia*, which is of no significance (Fig. 5);

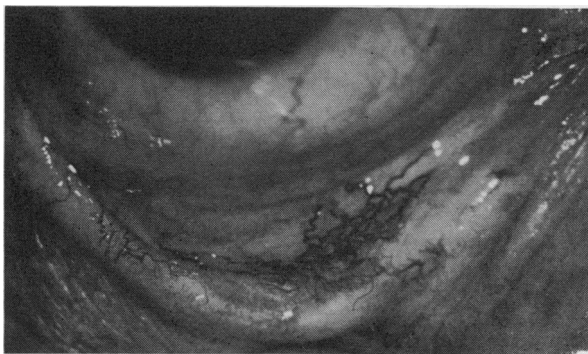


FIG. 5 *Localized telangiectasia of the palpebral conjunctiva*

(2) *Formation of keratin plaques* (Fig. 6), which, particularly if in the centre of the upper eyelid, may cause abrasion of the cornea with discomfort (Lederman, 1957; Bedford, 1966).

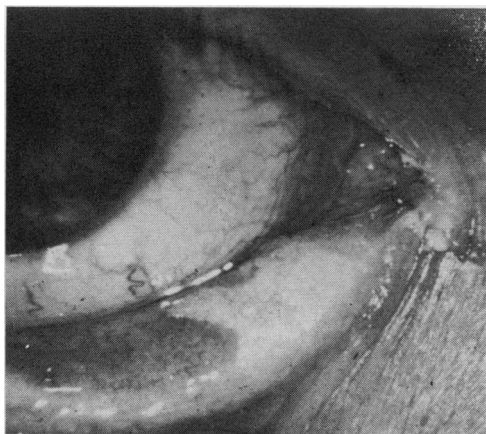


FIG. 6 *Keratin plaque*

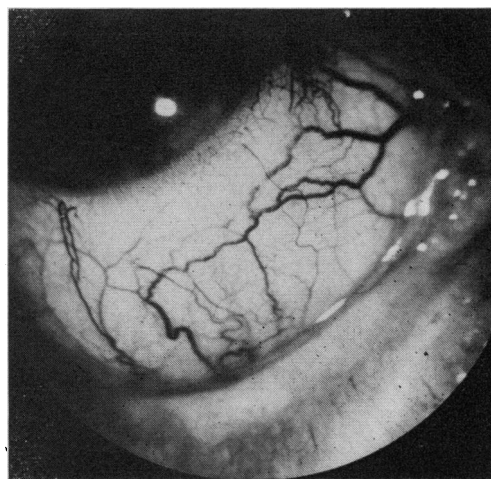


FIG. 7 *Extensive telangiectasia involving the whole of the bulbar conjunctiva and associated with secondary open-angle glaucoma*

Similar telangiectasia can develop in the bulbar conjunctiva and if generalized (Fig. 7)

may be associated with secondary open-angle glaucoma (Bedford, 1966). Localized telangiectasia has also followed the application of an anteriorly placed cobalt plaque but apparently without any harmful effect. These vascular changes have also been seen after the use of beta-radiation for localised conjunctival lesions, but not when such treatment has been applied for corneal disease. The additional effects on the conjunctiva when lacrimal secretion is defective will be discussed later. As a very rare complication, because of the enormous dose of radiation emanating from the back of an anteriorly-placed cobalt plaque, conjunctival necrosis has been followed by the formation of symblepharon.

#### CORNEA

Apart from the temporary punctate epithelial erosions seen commonly as an acute radiation reaction, delayed corneal complications may arise either as a direct result of radiation on the corneal tissues or as a complication of the "dry-eye" syndrome due to reduced or absent lacrimal secretion. Corneal necrosis has been described as an early result of high doses of radiation, but this is very rare and is more likely to appear some months after the completion of treatment (Blodi, 1958; Linnell and Wolter, 1967). Decrease of corneal sensitivity to the point of complete anaesthesia is a typical early sign of radiation keratopathy; the concomitant absence of ocular pain may give rise to a false sense of security and delay the recognition of corneal ulceration. Such ulceration is characteristically indolent involving the greater thickness of the cornea and may be central or marginal and in the latter case either localized or circumferential in extent (Fig. 8). Eventually healing may take place with much neovascularization and scarring of the cornea, or rarely the tissue destruction may progress insidiously to complete necrosis with perforation of the eye and possibly with extrusion of the intraocular contents. These serious complications are likely to occur only after high dosages with  $x$  rays but have also been seen with beta-radiation. A rare type of corneal dystrophy has also been seen after beta-radiation, characterized by epithelial and stromal oedema (Fig. 9) with loss of corneal sensation but without any rise of the intraocular pressure. Such changes are probably due to interference with the integrity of Descemet's membrane (Bedford 1966).

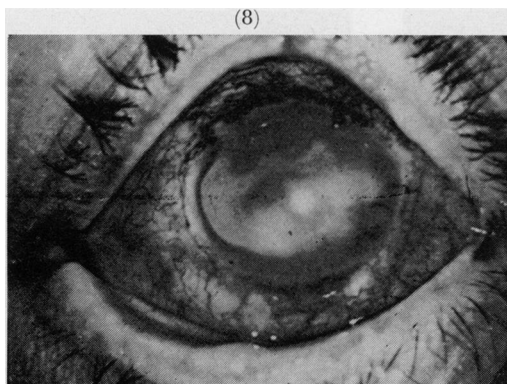


FIG. 8 *Severe keratopathy after  $\beta$ -irradiation for conjunctival cancerous melanosis. There is an indolent peripheral gutter-like ulcer on the nasal side and extensive opacification of the corneal stroma*

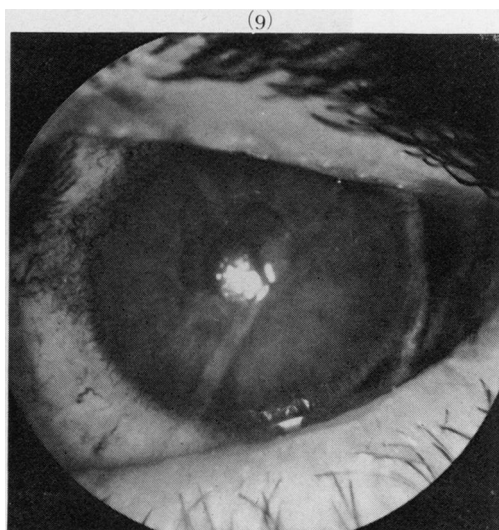


FIG. 9 *Earlier stage of condition seen in Fig. 8, showing epithelial and stromal oedema*

Finally, radiation damage to the lacrimal gland may result in decreased or absent lacrimal secretion with consequent drying of the surface of the eye; when this happens the cornea loses its characteristic clarity, the surface becomes rough and shows staining points with Bengal rose, and filaments can be seen on the surface of the cornea and conjunctiva, these changes giving rise to considerable ocular discomfort (Fig. 10).

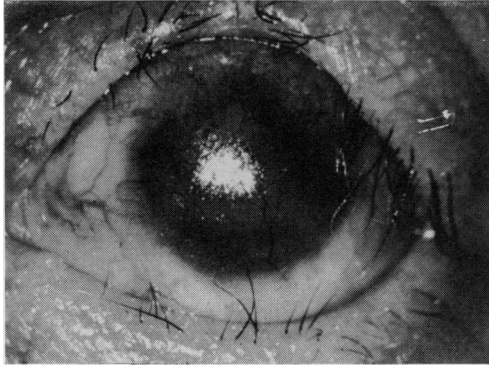


FIG. 10 *Extreme example of radiation keratopathy associated with diminished lacrimal secretion after cobalt beam therapy (using a direct anterior field) for a malignant melanoma in an only eye when all other conservative therapy had failed. Histological examination of the enucleated eye showed that the tumour had satisfactorily regressed but such heroic therapy is clearly of little clinical value*

#### SCLERA

Complications after irradiation rarely affect the sclera because this avascular tissue is remarkably radioresistant. Scleral necrosis occasionally followed the use of radon seeds or tantalum wire implants. We have, however, seen such a condition in a woman treated for a choroidal melanoma with a large cobalt plaque (15 mm.) applied on two occasions leading to a very high dose of radiation to the sclera (approximately 80,000 r. (Fig. 11)). The eye was subsequently removed. Scleral necrosis has also been described after beta-radiation for a localized lesion near the limbus, again after very high dosage in the region of at least 10,000 r (Jones and Reese, 1953).

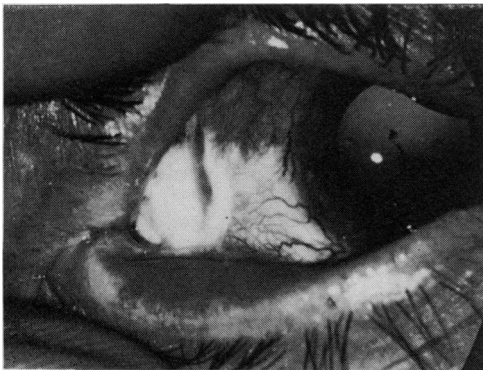


FIG. 11 *Scleral necrosis adjacent to lateral canthus after application of a large cobalt plaque on two occasions for a malignant melanoma in an only eye*

#### ANTERIOR CHAMBER

Complications are rare except after high dosages of radiation for intraocular tumours. Thus, if a cobalt plaque is applied after irradiation of the whole eye with cobalt beam therapy for retinoblastoma, iridocyclitis may lead to extensive posterior synechiae (Fig. 12, overleaf); rubeosis of the iris has been seen and may cause bleeding into the anterior chamber; a rare and harmless side-effect is a peculiar form of sectoral iris atrophy (Fig. 13, overleaf), probably due to localized ischaemia resulting from the application of a cobalt plaque close to the iris root.

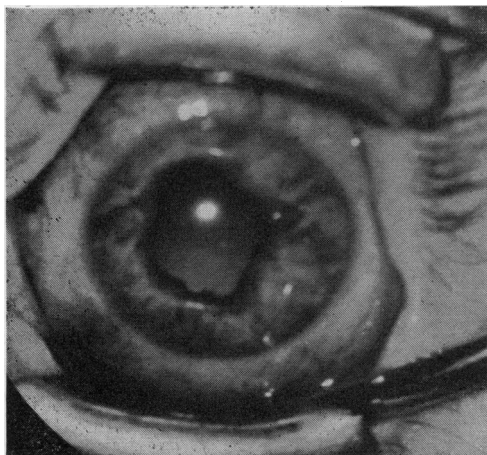


FIG. 12 Extensive posterior synechiae after repeated irradiation for recurrent retinoblastoma

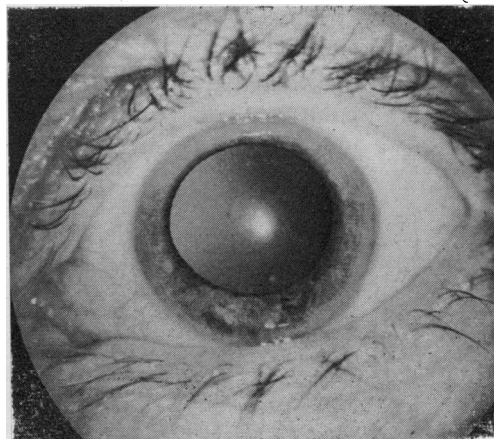


FIG. 13 Localized iris atrophy extending from 5 to 8 o'clock after treatment of a peripheral choroidal malignant melanoma in this sector. A marked degree of pigmentary iridopathy was apparent on retroillumination

#### LENS

Opacification of the lens is the classical change described in eyes subjected to therapeutic radiation. However, such opacities—which must be distinguished from pre-existing senile or congenital lens opacities—are not always complete, and if they progress at all may do so only very slowly. Lens opacities can be expected to occur after high voltage therapy, 500 to 1,000 r being cataractogenic, but cataract has resulted from a single dose of as little as 200 r (Merriam and Focht, 1957), and with certain forms of treatment their times of appearance can be forecast with considerable accuracy. Four main types of cataract may be seen:

- (1) *The doughnut cataract* This is the classical type following exposure to radiation from nuclear explosions, and in our experience usually occurs about 2 years after cobalt beam therapy for retinoblastoma delivering over 4,000 r with the direct anterior field (Fig. 14). In those cases where gross visual loss results from the opacity, surgical treatment gives good results.
- (2) *Posterior sub-capsular cataract* In this type the whole posterior part of the lens becomes opacified, resulting in considerable reduction in visual acuity. This change can also occur after the use of cobalt beam therapy (Fig. 15).

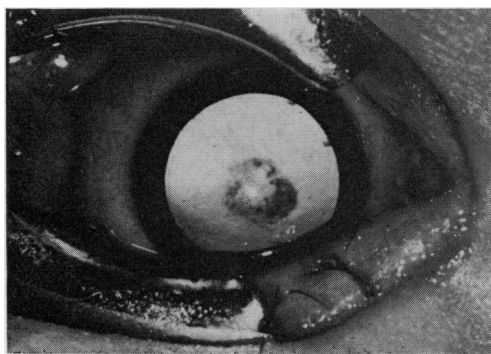


FIG. 14 Classical doughnut radiation cataract

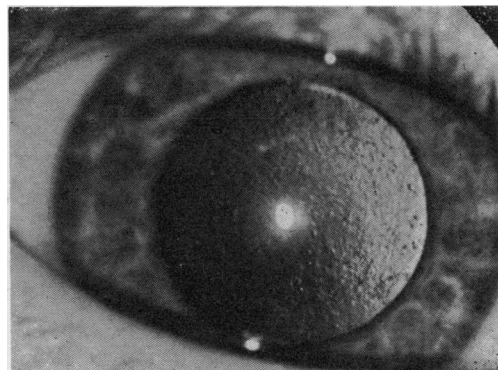


FIG. 15 Posterior sub-capsular lens opacity

(3) *Sectoral lens opacities* These occur occasionally when a cobalt plaque has been placed near the ora serrata and therefore close to the equator of the lens where the germinative epithelium is situated (Fig. 16). Similar localized nonprogressive lens opacities may also be seen after beta-radiation for a lesion at the limbus. Both these types of localized lens opacity are hidden behind the iris and do not impair vision; thus they will not be found unless the pupil is dilated. According to Hilgers (1966) these localized lens changes are unlikely to appear with a fractionated total dose of under 5,000 r and they do not as a rule progress to complete opacification unless subsequent radiation boosts the total dose received by the lens.

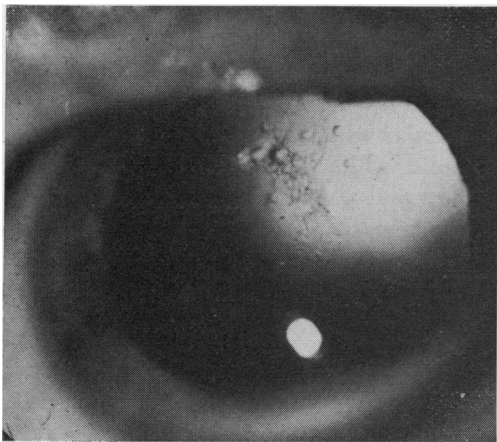


FIG. 16 *Localized lens opacity (which is apparently non-progressive and does not interfere with vision) following the application of a cobalt plaque*

(4) *Complete total cataract* Complete opacification of the lens is rare but may follow about 2 to 3 years after irradiation of the whole eye; for example, in the treatment of paranasal sinus disease (Fig. 17), or when radiation has been given to an eye in which secondary retinal detachment is present, as for instance with a retinoblastoma (Fig. 18).

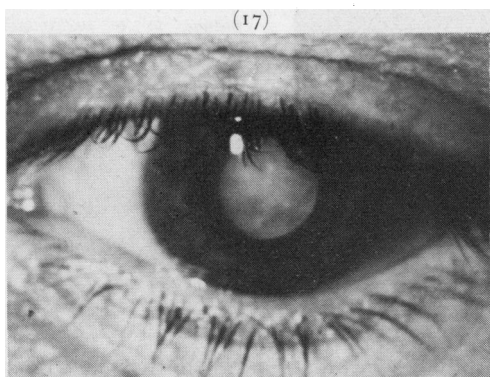


FIG. 17 *Total cataract 2 years after irradiation for carcinoma of the sphenoid sinus*

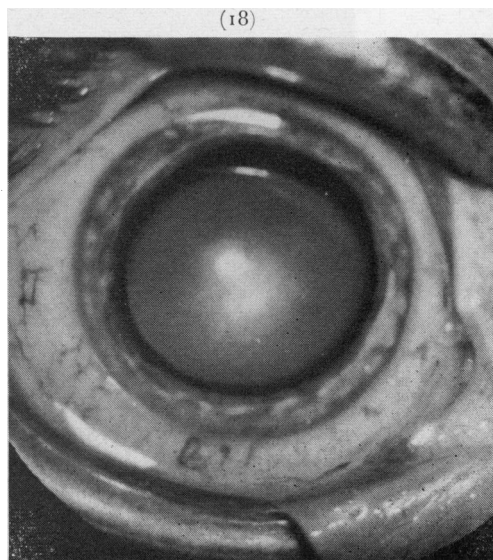


FIG. 18 *Total opacification of the lens associated with an extensive retinal detachment secondary to a retinoblastoma treated with the cobalt beam*

## RETINA, CHOROID, AND OPTIC DISC

In our experience radiation retinopathy rarely occurs after irradiation of the whole eye and such changes are uncommon unless doses in the region of 6,000 r or more are used (Chee, 1968). Retinal and choroidal changes, however, are commonly seen after local irradiation for retinoblastoma and choroidal malignant melanoma when these tissues receive doses ranging between 20,000 and 40,000 r. Increasing awareness of these side-effects, which may not be apparent until some months after the completion of treatment, has helped to define more closely the indications for the use of cobalt plaques in the treatment of intraocular tumours.

The effects on the choroid, retina, and optic disc may be as follows:

(1) *Vascular changes* Narrowing and obliteration of the retinal arteries, veins, and capillaries is frequently found up to a year after the use of a cobalt plaque for a malignant melanoma. In cases in which massive radiation to the retinal vessels has necessarily been incurred, the vessels may show perivascular white sheathing and may later even become completely occluded, appearing as solid white cords. The resulting ischaemia of the retinal neuro-epithelium leads to progressive visual loss and optic nerve atrophy which may be complete if a cobalt plaque has been placed within a few millimetres of the optic disc. In several of our cases destruction of the tumour in this way has been followed by complete loss of sight in the affected eye 15 to 18 months after treatment (Fig. 19).

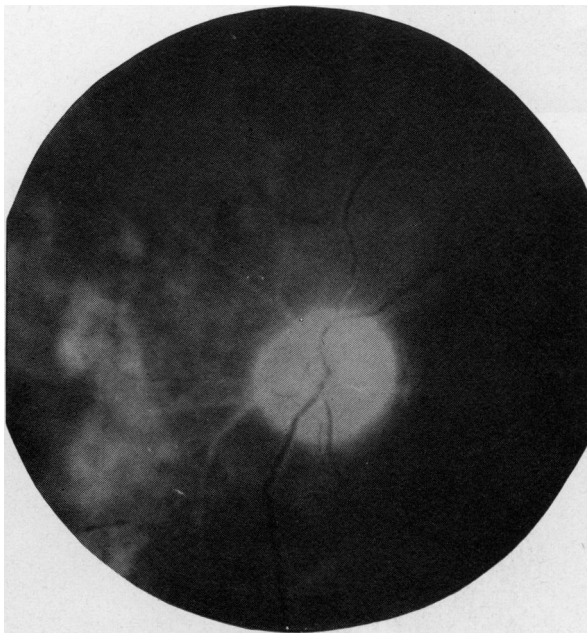


FIG. 19 *Gross optic atrophy and complete obliteration of central retinal artery after successful application of a cobalt plaque to a juxtapapillary malignant melanoma, the debris of which can be seen on the left. The eye was blind*

(2) *Appearance of exudates* Haemorrhages in and around the treated area appear at an early stage and are not uncommonly seen about 12 months after focal irradiation with a cobalt plaque for a juxtapapillary retinoblastoma. Such haemorrhages, which are rarely seen with peripheral tumours, may break into the vitreous causing a decrease in vision, but as a rule spontaneous clearing takes place. With a peripheral tumour also telangiectasia often develops, but does not usually give rise to intraocular haemorrhage. Exudates are generally hard and white presumably the result of phagocytosis of tumour debris or



haemorrhage together with infarction of choroid and retinal tissue close to the tumour. They may also appear at the macula in the form of a star pattern or as a circinate retinopathy (Fig. 20). These exudates persist and may cause a serious decrease in vision, even when the tumour is situated some distance from the posterior pole. Soft white exudates or cotton-wool spots may be seen at an early stage after treatment but rapidly disappear.

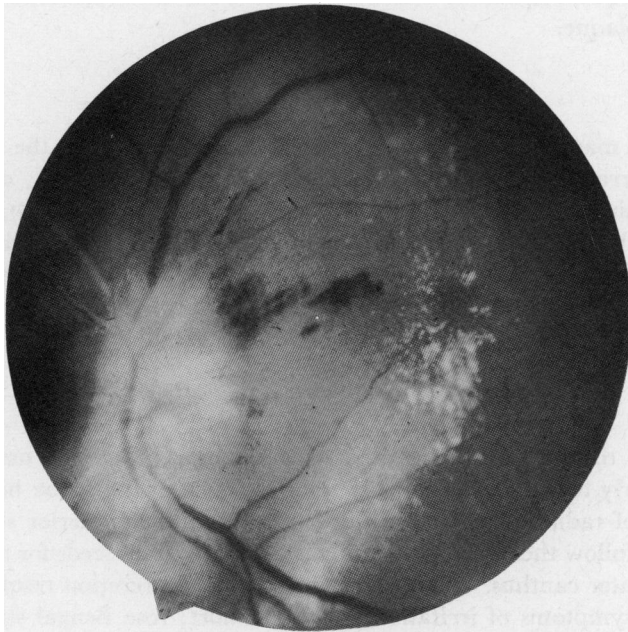


FIG. 20 *Radiation retinopathy: haemorrhages, exudates, and arterial occlusion after application of a C-shaped cobalt plaque*

(3) *Disturbance of the pigment epithelium* The pigment epithelium reacts in two ways—first, by migration of pigment giving discrete fine stippling in the area around the base of the tumour (Fig. 21), and secondly, by a more generalized pigment dispersal if whole-eye irradiation has been used. The latter change may be more related to repositioning of a pre-existing long-standing retinal detachment rather than to irradiation. Changes in the choroidal vessels progress from telangiectasia through varying degrees of obliteration to complete disappearance and this sequence combined with retinal vessel and pigmentary

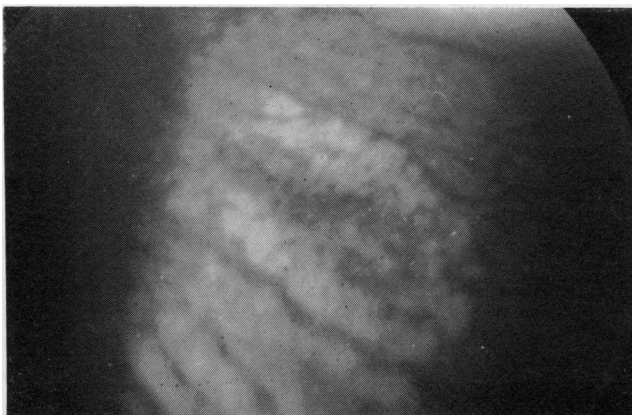


FIG. 21 *Pigmentary changes after application of a cobalt plaque. The edge of the melanoma is seen on the left; normal retina and choroid are seen on the right; there is patchy depigmentation and attenuation of the choroidal vessels in the centre*

changes may give rise to the appearance of massive choroido-retinal atrophy, leaving bare sclera exposed, as used to be seen commonly with radon seeds.

Because of the vascular changes in the choroid and retina already mentioned and the associated retinal neuro-epithelial degeneration, atrophy of the optic nerve is inevitable when a massive dose of radiation is applied adjacent to the optic disc. These irreversible changes and the consequent dramatic loss of vision have led us to discontinue the use of the C-shaped cobalt plaque.

#### GLAUCOMA

Secondary glaucoma may occur when generalized telangiectasia of the conjunctival vessels has followed irradiation of the anterior segment (Bedford, 1966), or it may be associated with rubeosis of the iris and anterior chamber angle (Jones, 1958), or occasionally it may result from haemolytic changes associated with intraocular haemorrhage causing obstruction of the outflow channels. Whereas, in the first condition, a drainage operation may help to control the ocular hypertension, in the other two conditions the eye is seriously damaged and no treatment is likely to be permanently successful.

#### LACRIMAL GLAND

Radiation damage to the lacrimal gland and its ducts may follow the use of a cobalt plaque placed anteriorly to the equator on the temporal side of the globe because of the tremendous amount of radiation emanating from the edge and posterior surface of the plaque. It may also follow the use of conventional x rays or radon seeds for the treatment of neoplasms of the outer canthus. Decreased or absent tear secretion results in a "dry-eye" syndrome with symptoms of irritation and discomfort; rose Bengal staining of the conjunctiva and cornea can be seen together with epithelial filaments.

#### LACRIMAL PASSAGES

When radiation is used for the treatment of neoplasms at the inner end of the eyelids and in the region of the lacrimal sac, occlusion of the canaliculus, sac, and naso-lacrimal duct commonly results. However, this does not seem to be a serious problem and watering of the eye does not in fact occur as often as is commonly thought. Syringing of the lacrimal passages is of little value in the prevention or treatment of this complication and in our experience surgical treatment has not been indicated.

#### ORBIT

Irradiation in a child is likely to interfere with the ossification centres, leading to retardation of growth on the affected side and subsequent asymmetry of the orbits. When radiotherapy follows the removal of an eye, postradiation contracture of the conjunctiva leading to a shrunken socket is less likely to occur if a plastic shell is in place during treatment; however, some degree of contracture of the socket must be expected, especially if radiation has been used before enucleation. Postradiation malignant change in bone has been described (Forrest, 1962; Soloway, 1966; Sagerman, Cassady, Tretter, and Ellesworth, 1969), but we have not seen any cases of bone sarcoma in the past 5 years. It is, however, possible that such malignant change may develop in the future as a result of the high dosage from a cobalt plaque placed under the medial rectus muscle close to the ethmoid bone.

## Summary

Radiotherapy has a valuable place in the treatment of neoplastic disease of the eye and orbit.

Conventional x rays and modern radiotherapeutic techniques may lead to complications, the majority of which are of relatively minor importance.

Cobalt plaques are being increasingly used in centres throughout the world and are proving of considerable value for otherwise incurable conditions. Increasing awareness of their side-effects, particularly on the optic nerve, should lead to careful consideration not only of the size but also of the site of the neoplasm, bearing in mind the very high radiation dose inevitable with this technique.

Further work is being done to define more closely the indications for the application of cobalt plaques in the area of the optic disc and to elucidate the pathology of the vascular changes in radiation retinopathy.

We should like to thank the Medical Illustration Department at the Institute of Ophthalmology, London, for help with the illustrations and Miss Heather Payne for secretarial assistance.

## References

- BEDFORD, M. A. (1966) *Proc. roy. Soc. Med.*, **59**, 529  
 ——— (1968) *Ibid.*, **61**, 1041
- BLODI, F. (1958) *Trans. Amer. ophthal. Soc.*, **56**, 413
- CADE, S. (1957) *Brit. J. Radiol.*, **30**, 393
- CHEE, P. H. Y. (1968) *Amer. J. Ophthal.*, **66**, 860
- FORREST, A. W. (1962) *Int. Ophthal. Clin.*, **2**, 543
- HILGERS, J. H. C. (1966) *Arch. Ophthal. (Chicago)*, **76**, 329
- JONES, I. S., and REESE, A. B. (1953) *A.M.A. Arch. Ophthal.*, **49**, 633
- JONES, R. F. (1958) *Brit. J. Ophthal.*, **42**, 636
- LEDERMAN, M. (1957) *Ibid.*, **41**, 1  
 ——— (1958) *Trans. ophthal. Soc. U.K.*, **78**, 147
- LEIGH, A. G. (1966) "Corneal Transplantation", p. 300. Blackwell, Oxford
- LINNELL, P. C., and WOLTER, J. R. (1967) *Eye, Ear, Nose Thr. Mthly*, **46**, 328
- MERRIAM, G. R., and FOCHT, E. F. (1957) *Amer. J. Roentgenol.*, **77**, 759
- SAGERMAN, R. H., CASSADY, J. R., and TRETTER, P. (1968) *Trans. Amer. Acad. Ophthal. Otolaryng.*, **72**, 849  
 ———, ———, ———, and ELLESWORTH, R. (1969) *Amer J. Roentgenol.*, **105**, 529
- SKEGGS, D. B. L., and WILLIAMS, I. G. (1966) *Clin. Radiol.*, **17**, 169
- SOLOWAY, H. B. (1966) *Cancer (Philad.)*, **19**, 1984