

# Visual fields in diabetic retinopathy

K. I. WISZNIA, T. W. LIEBERMAN, AND I. H. LEOPOLD

*From the Department of Ophthalmology, Mount Sinai School of Medicine, City University of New York*

Little attention has been given until recently to the visual field defects occurring in diabetic retinopathy.

Scott (1957) considered diabetes mellitus to be an extremely rare cause of scotomata. Livingston (1943) found similar scotomata within the central field which were unassociated with visible retinopathy and were thought to be caused by areas of local anoxia. Dubois-Poulsen (1952) described altitudinal field defects corresponding to major retinal arterial obliterations. Harrington (1964) considered the field defects occurring in diabetic patients to be non-specific.

Recently Roth (1969) has reported scotomata occurring within 20° of fixation in the presence of very mild diabetic retinopathy or without visible fundus lesions. Cotton-wool spots have been shown to cause scotomata (Williams, Drance, Harris, and Fairclough, 1970). Caird, Pirie, and Ramsell (1969) have pointed out the possibility that small visual field defects unassociated with visible retinopathy may precede observable fundus changes. It has been taken for granted and is common clinical experience that proliferative retinopathy and large haemorrhages cause significant field loss.

The purpose of this work was to study the visual field defects of patients with different grades of diabetic retinopathy and to correlate these defects with anatomical lesions in the fundus as seen by ophthalmoscopy, on fundus photographs, or on fluorescein angiography.

## Material and methods

24 diabetic patients showing various levels of diabetic retinopathy were selected on the basis of their willingness to participate in the study and their ability to cooperate in the tests required.

Three patients who showed no ophthalmoscopic evidence of diabetic retinopathy all currently require insulin therapy and have had blood sugars above 250 mg./100 ml. serum. The visual acuity was 20/15 or 20/20 in all eyes.

Thirteen patients showed non-proliferative diabetic retinopathy in one or both eyes (microaneurysms, exudates, and/or small intraretinal haemorrhages). The visual acuities in these patients varied from 20/15 to no worse than 20/40.

Eight patients had advanced retinopathy (proliferative retinopathy, old vitreous haemorrhages, and secondary fibrosis) with visual acuities ranging from hand movements to 20/20.

Each patient underwent a complete ocular examination. The visual fields were examined with a Goldmann perimeter using the appropriate distance and addition for age in plotting the central isopters. The peripheral isopters were plotted with the patient wearing no correction. Before each examination the perimeter was checked for standardization of illumination. When small white targets (1/1, 1/2) showed no defects, red targets were used.

This study was supported by PHS Research Grant No. EY00340 from the National Eye Institute, National Institutes of Health, Bethesda, Maryland, U.S.A.

An ophthalmoscopic examination was performed after dilatation of the pupils with phenylephrine (Neo-Synephrine®) 10 per cent. and tropicamide (Mydracil®) 1 per cent. Kodachrome fundus photographs were taken using the Zeiss fundus camera. Fluorescein angiography was performed using an intravenous injection of 5 ml. 10 per cent. sodium fluorescein solution.\* Kodak Tri-X Pan black-and-white film was used. The fluorescein angiograms corresponding to the visual field defects were enlarged.

All patients with non-proliferative diabetic retinopathy showing significant visual field defects have undergone retesting one or two months after the initial examination. Visual field abnormalities were found to be reproducible.

## Results

The three patients without diabetic retinopathy showed no visual field abnormalities.

The group of thirteen patients with non-proliferative retinopathy included six without demonstrable visual field defects and seven (9 eyes) with a similar arcuate-type field defect (Figs 1, 2, 3, and 4). With small targets this abnormality appeared to be a partial constriction of the central isopter. These field defects arose from or close to the blind spot and extended nasally, arching either upwards or downwards towards the macula. It appeared that a slightly larger or brighter test object would have converted the defect into an arcuate scotoma, but arcuate scotomata could not be plotted in this way. Static perimetry showed a slight decrease in the light threshold in the area of the field loss, but responses were variable.

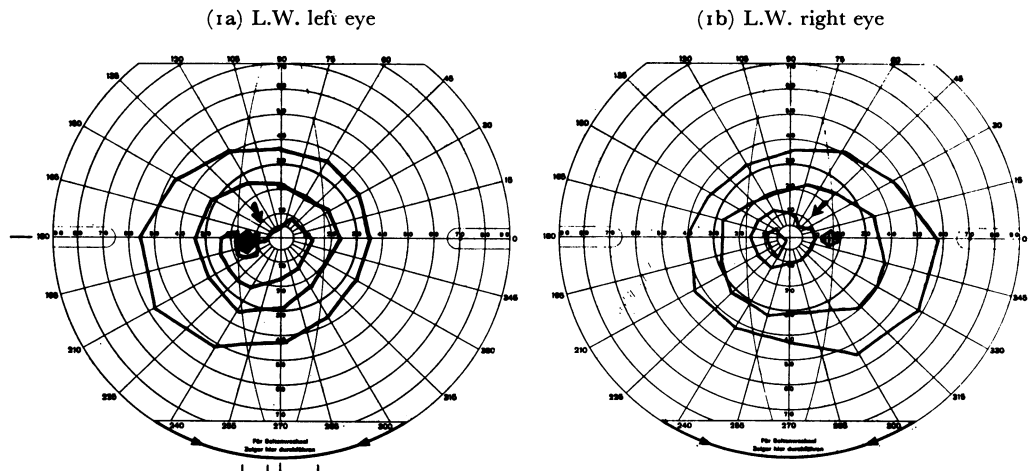
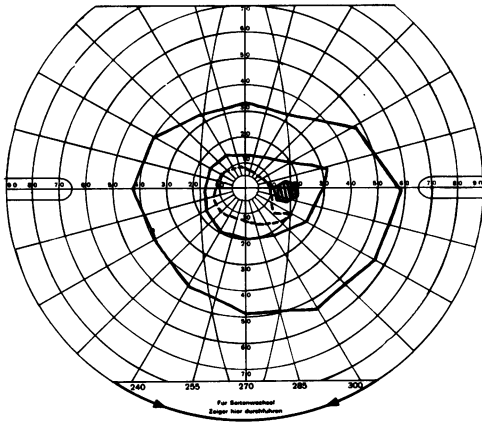


FIG. 1 Goldmann visual fields from three patients with non-proliferative diabetic retinopathy. Note localized constriction of central isopters arising from or close to the blind spot. Solid lines represent white targets; broken lines represent red targets.

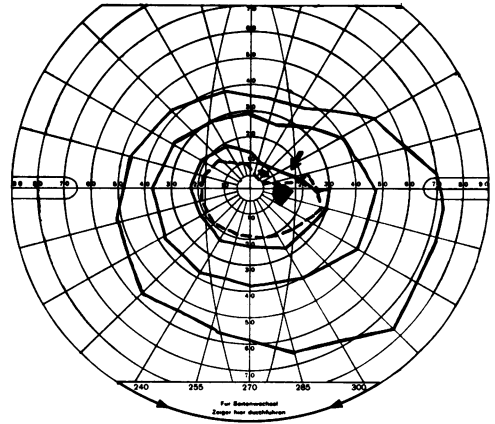
Although fluorescein angiograms revealed a much more extensive retinopathy than was seen on ophthalmoscopy or on the ordinary fundus photographs (Fig. 2), the printed enlargements of the areas of the fluorescein angiogram which corresponded to the visual field defect did not differ significantly in regard to type or degree of retinopathy from enlargements of retinal areas in the opposite half of the field with normal visual function

\* Fluorescein sodium solution 10 per cent., Smith, Miller and Patch, Inc., New York.

(1c) A.F. right eye



(1d) O.L. right eye



(2a)

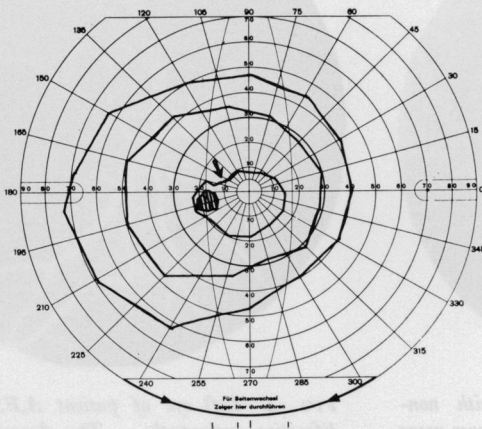
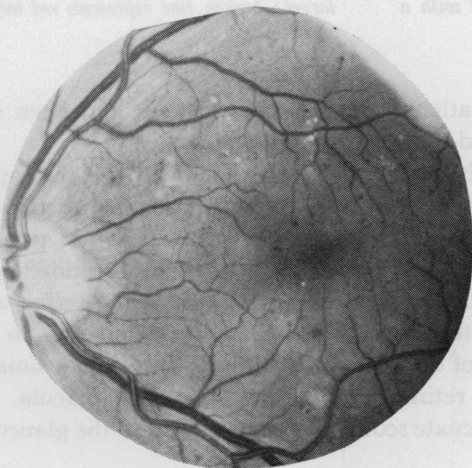
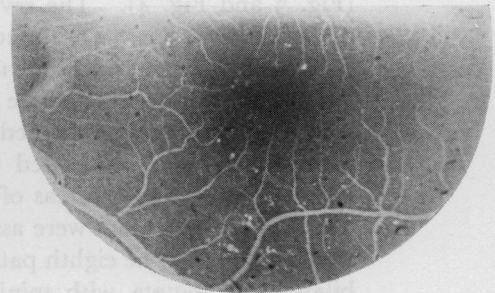

FIG. 2 Left eye of patient N.L. with non-proliferative retinopathy. The fundus photograph and fluorescein angiogram show no specific vascular lesion infero-temporal to the optic disc which would correspond to the field defect supero-nasal to the blind spot.

(2b)



(2c)



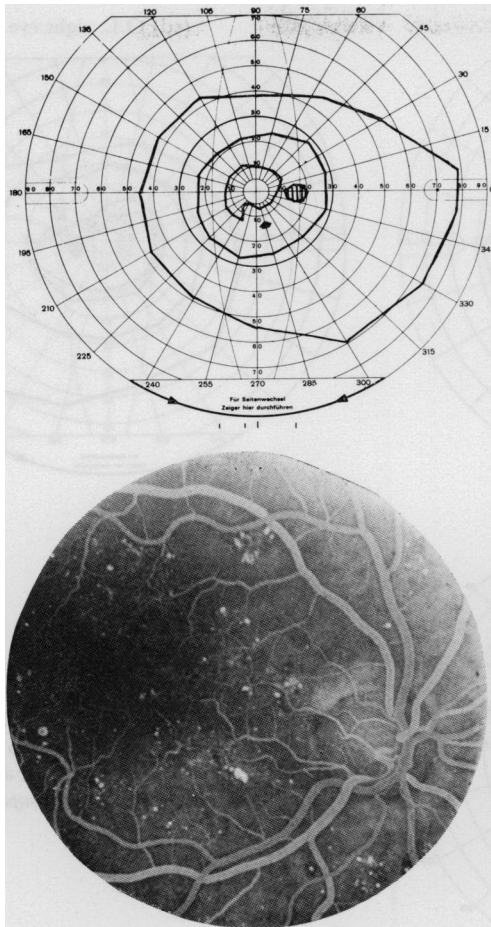


FIG. 3 Right eye of patient G.S. with non-proliferative retinopathy. The upper and lower areas of the fundus as seen on the fluorescein angiogram show no significant differences in degree or type of lesion although the superior area is associated with a field defect.

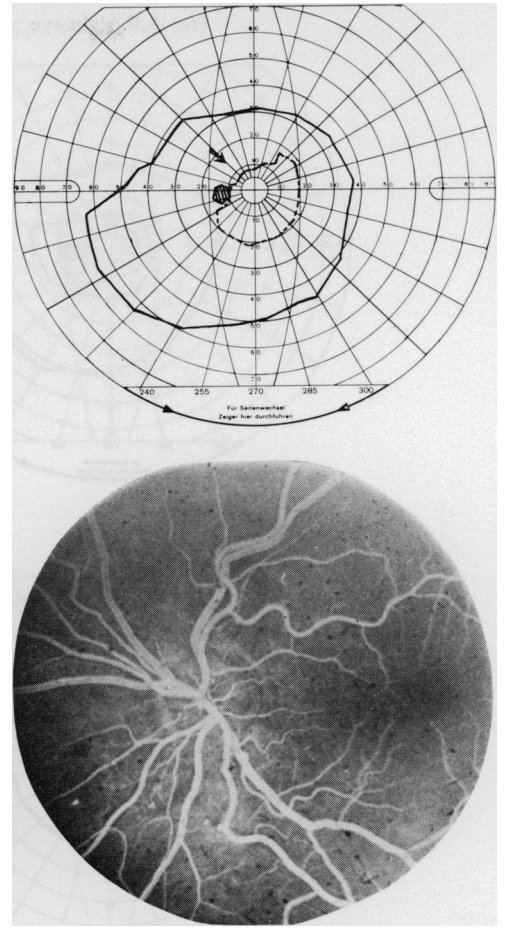


FIG. 4 Left eye of patient A.F. with non-proliferative retinopathy. The fluorescein angiogram shows no specific vascular lesion corresponding to the visual field defect. Solid line represents white target; broken line represents red target.

(Fig. 3 and Fig. 4). The seven patients showing these defects had been diagnosed as diabetics for 1, 9, 10, 11, 12, 20, and 24 years respectively.

Seven of the eight patients with advanced proliferative haemorrhagic retinopathy showed visual field defects which were easily explained by the appearance of the diabetic lesions: central scotomata were related to macular haemorrhages and oedema; peripheral visual field defects were associated with large retinal or preretinal haemorrhages, vitreous haemorrhages, and/or areas of fibrous or neovascular lesions in the retina and vitreous; and arcuate scotomata were associated with lesions of retinitis proliferans in contact with the optic disc. The eighth patient of this group had chronic simple glaucoma and showed bilateral scotomata with minimal retinitis proliferans about the macula. It was not possible to tell to what extent the arcuate scotomata were related to the glaucoma or to the diabetic retinopathy.

## Discussion

Partial constrictions of the central visual isopters in patients with non-proliferative diabetic retinopathy have not been described previously. It was not possible to determine any specific vascular abnormality associated with this type of visual dysfunction. A vascular lesion responsible for these defects might be beyond the resolution of clinical fluorescein angiography.

The type of defect plotted in patients with non-proliferative diabetic retinopathy shows some similarities to the arcuate scotoma of glaucoma. However, all patients showing this type of defect had normal optic discs and the intraocular pressures recorded in this group were normal. One current theory suggests that abnormalities in the radial peripapillary capillaries might be responsible for arcuate scotomata in glaucoma (Henkind, 1967; Kornzweig, Eliasoph, and Feldstein, 1968). With the present method of fluorescein angiography, detailed photographs of the radial peripapillary capillary network are not usually obtained but, as seen in Fig. 5, the location of this capillary system makes its involvement suspect in the particular type of defect found in this study. It is of interest that new vessels arising from the disc usually follow the pathway of the radial peripapillary capillaries.

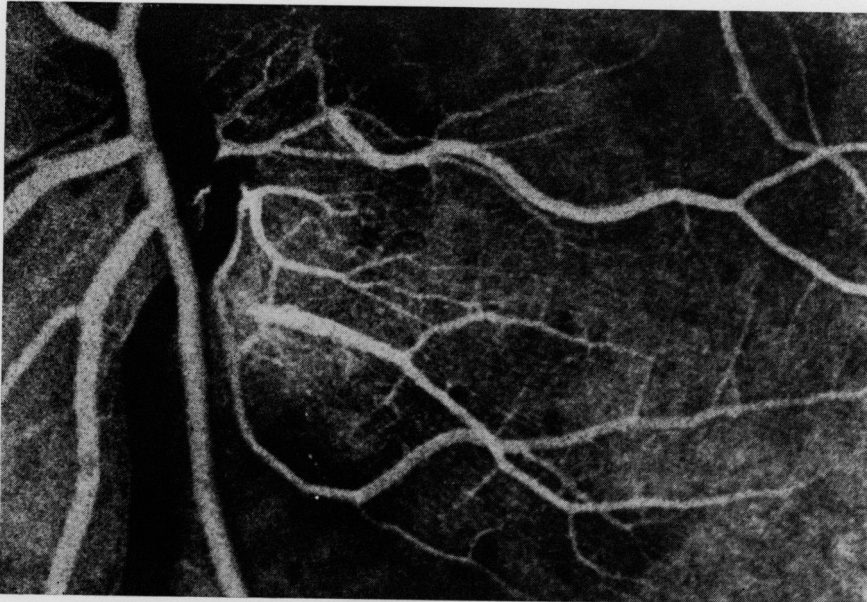


FIG. 5 *Arterial phase of normal fluorescein angiogram, showing straight radial peripapillary capillaries arising from the infero-temporal border of the disc.*

A non-vascular metabolic defect within the nerve fibre layer could be responsible for visual field abnormalities. All of the above explanations are conjectural. There is not as yet convincing clinical or investigative evidence favouring any one of these possibilities.

Since the arcuate field defect may be a precursor to proliferative vascular changes, patients showing this defect will continue to be examined periodically.

## Summary

Visual field defects in the form of partial constriction of the central isopters were found and studied in diabetic patients with non-proliferative diabetic retinopathy.

We thank Mr. Donald Wong and Miss Muriel Laban for the photography throughout the investigation. We also thank Drs. Henry Dolger and Stanley Mirsky for referring patients for the study.

### References

- CAIRD, F. I., PIRIE, A., and RAMSELL, I. G. (1969) "Diabetes and the Eye". Blackwell Scientific Publications, Oxford and Edinburgh
- DUBOIS-POULSEN, A. (1952) "Le Champ Visuel", p. 654. Masson, Paris
- HARRINGTON, D. O. (1964) "The Visual Fields", 2nd ed., p. 184. Mosby, St. Louis
- HENKIND, P. (1967) *Invest. Ophthalm.*, **6**, 103
- KORNZWEIG, A. L., ELIASOPH, I., and FELDSTEIN, M. (1968) *Arch. Ophthalm. (Chicago)*, **80**, 696
- LIVINGSTON, P. C. (1943) *Trans. ophthalm. Soc. U.K.*, **63**, 51
- ROTH, J. A. (1969) *Brit. J. Ophthalm.*, **53**, 16
- SCOTT, G. I. (1957) "Traquair's Clinical Perimetry", 7th ed., pp. 165 and 190. Kimpton, London
- WILLIAMS, D. K., DRANCE, S. M., HARRIS, G. S., and FAIRCLOUGH, M. (1970) *Canad. J. Ophthalm.*, **5**, 68