

# Electrophysiology of the retraction syndromes

A. HUBER

*Zürich, Switzerland*

With the aid of modern electromyography, numerous authors (Pabst and Esslen, 1960; Sato, 1960; Orłowski and Wójtowicz, 1962; Burger, 1963; Blodi, van Allen, and Yarbrough, 1964; Huber and Esslen, 1969) have recently come to the (surprisingly) unanimous conclusion that a *paradoxical innervation of the external rectus muscle of the affected eye represents the pathogenetic principle of all the retraction syndromes* (Stilling-Türk-Duane) (Duane, 1905) and that the explanations given by the majority of earlier authors based on mechanical concepts (birth injury, congenital or acquired musculo-facial anomaly, etc.) are either insufficient or are at variance with the facts (Krüger, 1969). In this connection it must be emphasized that to accept a disorder of the antagonistic interaction of the extraocular muscles as the primary cause of the retraction syndromes does not exclude anatomical alterations of the muscular tissues, the more so as primary innervational disturbances are known to induce pathological changes in the muscles. An analysis of published cases (Lyle and Bridgman, 1959; Malbrán, 1953) and of our own series, has enabled us to distinguish three types of Duane's retraction syndrome:

## **Duane I** (corresponding to Lyle's Type B or Malbrán's Type I)

Marked limitation or complete absence of abduction, normal or only slightly defective adduction, narrowing of the palpebral fissure and retraction of the affected eyeball on adduction, widening of the palpebral fissure on attempted abduction (Fig. 1).

## **Duane II** (corresponding to Lyle's Type C or Malbrán's Type II)

Instead of an impairment of abduction there is a limitation or complete defect of adduction with exotropia of the affected eye. Abduction appears to be normal or only slightly limited. There is further distinct narrowing of the palpebral fissure and retraction of the globe on attempted adduction (Fig. 2).

## **Duane III** (corresponding to Lyle's Type A or C)

Combination of limitation or absence of both abduction and adduction of the affected eye (If abduction and adduction are defective in the same degree, the affected eye is in the parallel position; if adduction is more defective than abduction, the affected eye diverges). There is further characteristic retraction of the globe and narrowing of the palpebral fissure on attempted adduction (Fig. 3).

It is well known that *the retraction syndromes of Type I, II, and III, apart from the disorders of motility in the horizontal plane, frequently produce additional vertical motor anomalies*. These are mostly evident as sursum- or deorsumductions on adduction (sometimes also on attempted abduction) of the affected eye. Some retraction syndromes, especially Duane I, are characterized by changes in the ocular axes on looking up or down, which cause an *A-pattern*, a

*V-pattern*, or an *X-pattern*. With convergent strabismus in the primary position, there is always compensatory head tilting either backwards or forwards. *Electromyographic analysis of these special forms of the retraction syndrome shows that the paradoxical innervation of the lateral rectus muscle comprises variable synergistic innervations not only with the medial rectus, but also with the superior or inferior rectus or both.*

The retraction syndromes always show the phenomenon of *paradoxical synergistic innervation of the eye muscles which are innervated by different nerves*, as is demonstrated by the following electrophysiological observations.

### Duane I

On attempted abduction of the affected eye, an insufficient activation of motor units in the lateral rectus muscle leads to a progressive diminution of electrical discharge, sometimes interrupted by short nystagmoid innervational outbursts of 10-20 msec. duration. On adduction, however, the lateral rectus, which under normal conditions should be inhibited, manifests a distinct paradoxical electric activity progressing to a nearly normal interference pattern. *The lateral rectus muscle of the affected eye has its peak of innervation on adduction and its minimum on attempted abduction.* The medial rectus behaves normally, with a peak of innervation on adduction and inhibition on abduction. The clinically observed limitation of abduction is explained by the insufficient or absent innervation of the lateral rectus on attempted abduction; the co-contraction produces the retraction of the globe (Fig. 1).

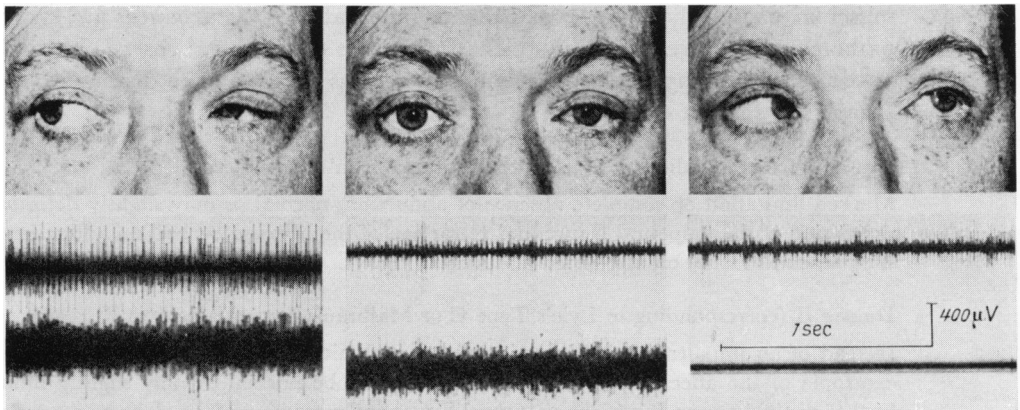


FIG. 1 *Duane syndrome I.*

Limitation of abduction of left eye, normal adduction. Narrowing of palpebral fissure and retraction of globe on adduction.

Electromyogram:

Simultaneous recording of lateral rectus (upper curve) and medial rectus (lower curve) of left eye. Paradoxical innervation of lateral rectus shows peak innervation on adduction and defective innervation on attempted abduction.

Normal electrical behaviour of medial rectus: maximum innervation on adduction, complete inhibition on abduction.

### Duane II

In spite of impaired or absent adduction, we find a normal innervational pattern of the

medial rectus of the affected eye, with full electrical activity on attempted adduction and normal inhibition on abduction. *The lateral rectus, however, has two peaks of innervation: one on attempted adduction and the other on abduction.* The limitation of adduction is not caused by a paresis of the medial rectus; its contraction is ineffective because it is counterbalanced by an equally strong activity of the lateral rectus on adduction. The resulting co-contraction of antagonistic muscles again leads to retraction of the globe. Duane II shows no limitation or absence of abduction (as is the case in Duane I), because on attempted abduction the lateral rectus of the affected eye activates a normal number of motor units (Fig. 2).

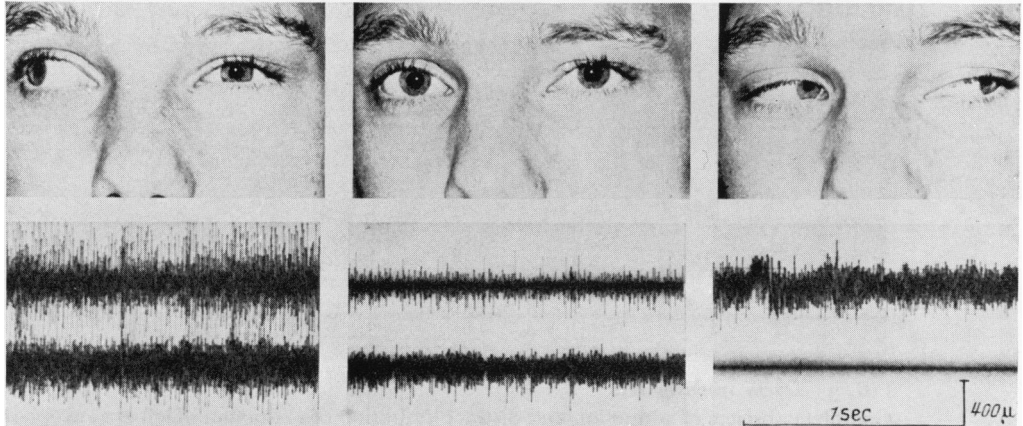


FIG. 2 *Duane syndrome II.*

Complete absence of adduction of left eye, normal abduction. Narrowing of palpebral fissure and retraction of globe on attempted adduction.

Electromyogram:

Simultaneous recording of lateral rectus (upper curve) and medial rectus (lower curve) of left eye. Lateral rectus shows peak innervation on abduction and a second paradoxical peak on attempted adduction.

Normal electrical behaviour of medial rectus: maximum innervation on attempted adduction and complete inhibition on abduction.

### Duane III

The phenomenon of paradoxical synergistic innervation of the lateral and medial rectus muscles here reaches its climax. The usual agonist-antagonist relationship between the two muscles is completely abolished, so that they behave like parts of one and the same muscle. In the primary position both manifest equal intense innervation.

On attempted adduction, there is intense simultaneous activity of both muscles with a striking similarity of the discharge pattern. We see again the phenomenon of paradoxical co-contraction which produces retraction of the globe and makes adduction impossible.

On attempted abduction, both muscles show complete inhibition of the asynchronous discharges; instead they manifest completely synchronous discharges (3-4 per sec.) of 30-60 msec. duration. These synchronous discharges in both the medial and lateral rectus muscles appear so strikingly similar in every respect that the recording seems to come from two electrodes placed close together on the same muscle. The short nystagmoid outbursts

in the lateral rectus on attempted abduction are naturally insufficient to produce any movement and this explains the absence of abduction (Fig. 3).

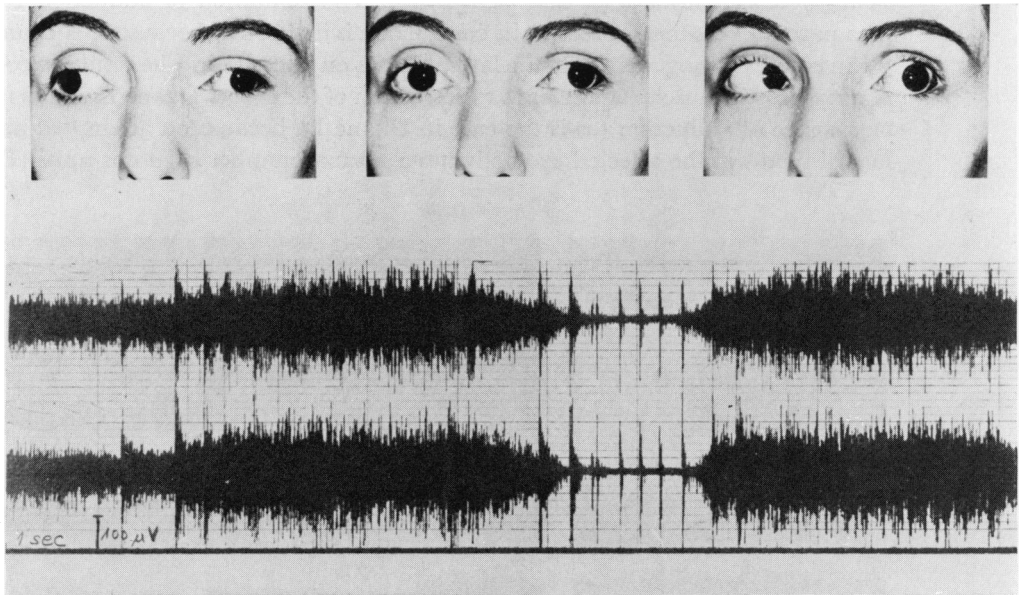


FIG. 3 *Duane syndrome III.*

Complete absence of adduction and distinct limitation of abduction of left eye: exophoria of affected eye with primary position of normal eye. Narrowing of palpebral fissure and retraction of globe on attempted adduction.

Electromyogram:

Simultaneous recording of lateral and medial rectus muscles of left eye. Primary position of right fixing eye: intense innervation of both rectus muscles in affected eye with slight preference for lateral rectus (left outer part of both curves).

On attempted adduction (gaze to the right) intense activation of both rectus muscles with striking similarity of discharge pattern.

On abduction (gaze to the left) complete inhibition of asynchronous discharges and appearance of completely synchronous discharges (3–4 per sec.) of 30–60 msec. duration in both muscles.

#### **Narrowing of the palpebral fissure on adduction**

This constant and characteristic symptom of all the different types of retraction syndrome, is due not to a contraction of the orbicularis muscle, but to a decrease in electrical activity in the levator muscle on adduction; this can be demonstrated by simultaneous electromyographical recordings of the levator and medial rectus muscles (Esslen and Papst, 1961).

#### **Retraction syndrome with A-pattern**

The electromyogram shows a peak innervation of the lateral rectus on looking down (explaining the outward deviation of the affected eye in this position) and an antagonistic inhibition on looking up (leading possibly to convergence of this eye). On adduction and attempted abduction there is medium grade innervation of the lateral rectus not much different from the electrical activity in the primary position (Fig. 4, opposite), which explains the abduction defect. Considering this synergistic innervation of the lateral rectus with the inferior rectus, one may say that in these cases the lateral rectus behaves electrically like an inferior rectus!

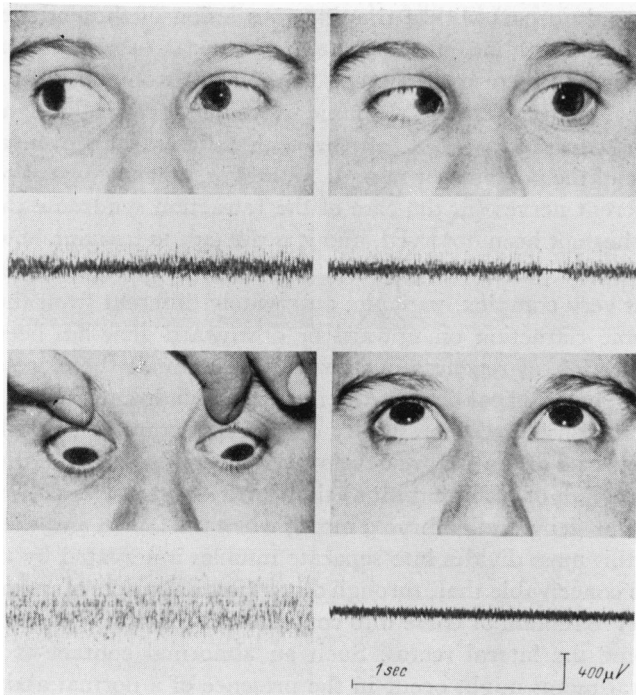

FIG. 4 *Duane syndrome with A-pattern.*

Distinct defect of abduction of left eye, slight retraction of left eye and narrowing of palpebral fissure on attempted adduction. On looking down left eye manifests distinct abduction.

Electromyogram:

Lateral rectus of left eye shows peak innervation on looking down (which explains divergence of left eye). Lateral rectus shows little innervation on adduction (explaining retraction of left eye), and a medium pattern of innervation on abduction.

#### Retraction syndrome with V-pattern

There is a synergistic innervation of the lateral rectus with the superior rectus of the affected eye. The lateral rectus shows a peak innervation on looking up and inhibition on looking down; in fact, it behaves electrically like a superior rectus.

#### Retraction syndrome with X-pattern

The electromyogram manifests two peaks of innervation of the lateral rectus, one on looking up and the other on looking down. On attempted abduction of the affected eye, there is no increase in innervation which explains the abduction defect. This involves a synergistic innervation of the lateral and superior rectus as well as the inferior rectus. In other words, the lateral rectus behaves electrically like the inferior and superior rectus muscles.

The retraction syndromes are thus characterized by variable symptoms, *but always with paradoxical synergistic innervation of extraocular muscles which are normally innervated by different nerves*. We ascribed this paradoxical co-innervation to a supranuclear oculomotor defect localized in the connections of the medial longitudinal bundle. In spite of numerous accompanying developmental anomalies (Klippel-Feil syndrome, ptosis, heterochromia, Horner syndrome, Marcus Gunn phenomenon, nystagmus, etc.), associated brainstem signs are seldom found in the retraction syndromes.

Huber, Esslen, Klöti, and Martenet (1964) discussed the possibility of a peripheral innervational anomaly in the branches of the oculomotor nerves to the extraocular muscles. The phenomenon of non-physiological co-innervation of muscles due to the misdirection of regenerating nerve fibres is a common observation after facial palsy and also after third nerve palsy (Walsh, 1947; Esslen and Pabst, 1961; Holland 1964). Misdirection of re-

generating nerve fibres only occurs with a simultaneous lesion of the endoneurium: the regenerating axons cannot grow into the original endoneurial tube, but reach foreign endoneurial tubes which guide them to the wrong muscles. It is obvious that this type of acquired misdirection is limited to fibres of the same nerve and is clinically significant only if it concerns nerves that operate a set of muscles with different and even antagonistic functions (as in the case of the oculomotor nerve). Moreover, an exchange of regenerating fibres between two different nerves (in the case of the retraction syndrome the abducens and oculomotor nerve) has not been observed, and it is difficult to imagine how this could happen. Finally, the clinical picture of acquired misdirection of regenerating fibres in the oculomotor nerve is very complex, variable, and widely different from the retraction syndrome, although some retraction on upward or downward gaze has been observed. Simple acquired misdirection of regenerating nerve fibres cannot therefore explain the clinical signs and electrophysiological data in the retraction syndrome.

We therefore began to consider the possibility of a misdirection of nerve branches in embryo. The extrinsic muscles of the eye are developed by a condensation of the mesoderm round the eye. At first (length of embryo 7 mm.) they form one mass which is supplied by the third nerve only. Later (length of embryo 9 mm.), when the fourth and the sixth nerve grow towards the eye, this mass divides into separate muscles innervated by the different oculomotor nerves. It is conceivable that, through disturbing influences of unknown origin, branches of the third nerve remain or come into contact with that part of the muscle mass which is later to become the lateral rectus. Such an abnormal contact of third nerve branches with the lateral rectus might occur in the presence of a normal abducens nerve or in compensation for an aplastic or absent abducens nerve. When first considering such a misdirection of third nerve branches due to embryological maldevelopment, we were unaware of any neuroanatomical proof of our hypothesis. Hoyt and Nachtigäller (1965a, b), going through the widely scattered literature of the anatomy of the orbit, succeeded in finding about half a dozen observations of anomalous branches of the third nerve entering the lateral rectus, both when the abducens nerve was normal and when it was aplastic or absent (Generali, 1842; Fäsebeck, 1842; Tillack and Winer, 1962; Heubner, 1900; Bremer, 1921). Other anatomical studies also mention anastomoses between the oculomotor and abducens nerves within the cavernous sinus or the orbit. These were casual observations in the anatomy theatre, unrelated to the clinical notion of a retraction syndrome, but they show that the postulated congenital misdirection of branches of the third nerve does exist.

On the basis of these anatomical observations, the clinical and electromyographical symptomatology of *Duane III* is the easiest to explain. The similar discharge patterns of the lateral and medial rectus muscles can be explained by the assumption that an anomalous branch of that part of the third nerve which innervates the medial rectus also supplies the lateral rectus, and that the latter receives no innervation from the abducens nerve because it is weak or absent. The "substitute" innervation of the lateral rectus muscle by a branch of the third nerve when the abducens nerve was absent or aplastic has been observed in two cadavers (Generali, 1842; Tillack and Winer, 1962).

It is more difficult to apply this theory to *Duane II*, in which the lateral rectus has a dual character (on adduction it behaves like the medial rectus innervated by elements of the oculomotor nerve, and on abduction like a lateral rectus innervated by the abducens nerve). Here one must assume a dual nerve supply in the sense that the single muscle fibres have two end-plates, one innervated by an end-twig of the third nerve and the other by an end-twig of the sixth nerve. For this double innervation there exist well-

documented anatomical findings of an anomalous branch from the third nerve to the lateral rectus with a normal abducens nerve (Fäsebeck, 1842; Henle, 1879).

*Duane I* may be explained by a partial double innervation of the lateral rectus; only some of the fibres have a dual supply, and the quantitative relation between those supplied by the sixth nerve only and those supplied by both the sixth and the third nerve can vary from case to case. This explains not only the varying degree of abduction defect, but also the occasional occurrence of an adduction defect.

In the *retraction syndromes with A, V, and X patterns*, one must assume that the additional nerve supply to the lateral rectus, apart from the abducens nerve, derives either from the superior rectus division of the oculomotor nerve (V-pattern), from the inferior rectus division (A-pattern), or from both (X-pattern). Anomalous branches of the third nerve of this type have also been reported in anatomical specimens (Fäsebeck, 1842; Henle, 1879).

### Differential diagnosis

Other anomalies which have to be considered, especially for *Duane I*, are *congenital absence of the sixth nerve* (Generali, 1842; White, 1935) and *congenital agenesis of the lateral rectus muscle*.

In both instances the electromyogram is unable to register any electrical activity within the area of the lateral rectus muscle, whereas in the retraction syndrome one sees pronounced electrical activity in the lateral rectus on adduction.

Long-standing *peripheral-neurogenic abducens nerve palsies* with partial or total denervation and secondary muscle fibre degeneration within the lateral rectus may sometimes simulate a retraction syndrome. However, there is no narrowing of the palpebral fissure on adduction and only a slight degree of retraction of the globe (due to structural alterations of the paretic lateral rectus). The electromyogram reveals no paradoxical innervation of the lateral rectus on adduction, but there are typical signs of loss of motor units (with loss of the interference pattern on abduction) and symptoms of denervation (fibrillation potentials).

### Conclusion

The main pathogenetic principle of the retraction syndromes is a paradoxical anomalous innervation of the lateral rectus muscle of the affected eye, a synergistic innervation of the extraocular muscles which are normally innervated by different nerves. In correlating the electromyographic data with anatomical reports, we have been able to provide a logical interpretation of the different retraction syndromes, based on the concept of a misdirection of peripheral branches of the third nerve to the lateral rectus muscle in embryo. Conclusive proof of such misdirection by necropsy studies of cases of the retraction syndromes has still to be obtained. Two patients with *Duane's syndrome* (Phillips, Dirion, and Graves, 1932; Matteucci, 1946) showed aplasia or absence of the abducens nerve, but the peripheral branches of the oculomotor nerves in these cases were not examined.

The causes of these defects of embryogenesis are not yet known, but the incidence of the retraction syndromes in children whose mothers were exposed to thalidomide poisoning during the first months of pregnancy is significant.

It is also of interest that, in cases of the *Marcus Gunn jaw-winking phenomenon*, electromyograms from the levator and masseter muscles also show simultaneous electrical activity (Pabst and Rossmann, 1966). The levator thus appears to be innervated from both the third and the fifth nerve, but where this abnormal connection between the two nerves is located or how the misdirection of the fifth nerve occurs, is still a matter of speculation.

As in the retraction syndromes, electromyography furnishes important data for the hypothesis of misdirection of nerves during embryogenesis.

### Summary

Three types of retraction syndromes (Duane, 1905) can be distinguished: Duane I with defective abduction, Duane II with defective adduction, and Duane III with defective adduction and abduction. All show more or less pronounced narrowing of the palpebral fissure and retraction of the globe on adduction. Some patients also manifest A, V, or X patterns.

Electromyography reveals that a paradoxical anomalous innervation of the lateral rectus muscle is the underlying cause. This paradoxical innervation may be due to an anomalous contact of the lateral rectus with branches of the third nerve if the abducens nerve is absent or defective, or to a double innervation by the abducens nerve and anomalous branches of the oculomotor nerve. The electromyographic findings correspond with anatomical observations of abnormal innervations of this kind.

### Discussion

HART How is it that the Marcus Gunn phenomenon improves with time?

HUBER It is known that the Marcus Gunn phenomenon can disappear with time. There is no doubt that in our case we have been able to show a direct connection of co-contraction between the levator and masseter muscles. Exactly where the connection between these two is taking place is not certain.

LYLE Have any electrophysiological investigations been carried out on cases of Brown's ('superior oblique tendon sheath') syndrome?

HUBER Paradoxical innervation occurs in Brown's syndrome and this has been proved electromyographically.

STRACHAN If the muscle was primarily innervated through the spindle, and if the muscle was primarily fibrotic, then the electromyographical changes could be explained in this manner. I do not really agree with Dr. Huber's concept. I have found frequency changes in the electromyograph pointing to a dispersion of fibres in motor units, perhaps by fibrous tissue. My idea of the situation is rather that the muscle changes occur first and that all the electrophysiological changes are secondary.

HUBER Retraction changes occur in internuclear ophthalmoplegia. About a year ago we found that some co-contraction of the lateral rectus occurs but not to the same extent or with the same intensity as in the retraction syndromes. I am almost certain that the intense co-contraction of the lateral rectus has a great deal to do with the retraction. It is also the reason why the eye cannot move in adduction in Duane Type II. I agree that certain things are not explained, but I am still certain that this is an innervational disorder.

MAURER In view of the significance of Hering and Sherrington's Laws, and since some authorities claim that the anomalous innervation is confined to the affected eye, has anyone done any studies in Duane's syndrome, fixing the sound eye and studying the affected eye simultaneously? If so, what were the results?

HUBER If there is movement there is innervation, and if there is no movement there is no innervation. Duane's syndrome is therefore not a disturbance of outflow from the higher centres, but a disturbance of the motor neurones of the extraocular muscles.

ABRAHAMS and WATSON Has Dr. Huber found any cases in which there were no electromyographical changes in Duane's syndrome?

HUBER These changes are found universally, and without exception.