

Surgical management of Duane's syndrome

M. H. GOBIN

University Eye Clinic, Leyden, Holland

Ten years ago I introduced a surgical technique for the correction of Duane's syndrome.

I perform a temporal displacement of the superior and inferior rectus combined with a recession of the medial rectus of the affected eye (Fig. 1).

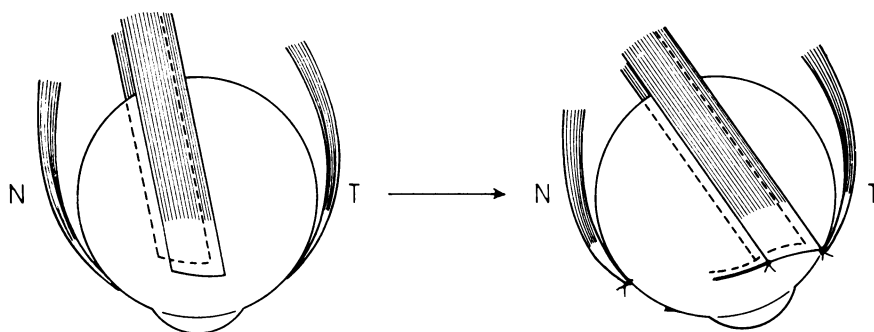


FIG. 1 Superior and inferior rectus muscles are displaced temporally, the nasal tip of each muscle being attached at the temporal end of the original insertion and the temporal tip being attached at the upper or lower end of the lateral rectus. The direction of the vertical rectus muscles is thereby changed, so that they abduct instead of adducting. The operation is completed with a recession of the medial rectus

I prefer a recession of the medial rectus to a resection of the lateral rectus for the following reasons:

- (1) A recession of the medial rectus can be carried out in Duane's syndrome as well as in cases of sixth nerve palsy, whereas a resection of a fibrotic lateral rectus in Duane's syndrome would increase the retraction of the eye and result in a gross limitation of adduction or even in a fixation of the eye in abduction.
- (2) A recession creates less risk of an unsightly enophthalmos.
- (3) My experience suggests that a recession is less traumatic than a resection and decreases the risk of postoperative adhesions.

The results of 67 operations have been analysed and I will discuss those first.

(1) *Deviation of the eyes in the primary position*

The cover test was carried out in the primary position taking care that the patient was not adopting an abnormal head posture (Table I, overleaf).

(2) *Horizontal and vertical excursion of the affected eye*

The horizontal range of movement was measured on the synoptophore (Figs 2 and 3, overleaf).

TABLE I Deviation in the primary position before and after operation in 67 patients

No. of patients	Preoperative	Postoperative		
		Straight	Esophoric	Exophoric
11	Straight	8	—	3
56	Esophoric	38	9	9
67	Total	46	9	12




FIG. 2

FIG. 2 Preoperative horizontal excursion of affected eye. The lines are arranged in the same order as in Fig. 3, each line representing a case




FIG. 3

FIG. 3 Postoperative horizontal excursion. The cases are arranged with the minimum abduction at the top and the maximum at the bottom

A limitation of adduction may often appear or increase postoperatively. In 56 of our cases there was a limitation of adduction postoperatively. It seems that the improvement in abduction takes place at the cost of adduction. So, in fact, the excursion is shifted from the nasal area to straight ahead. This is an important improvement because the excursion of the affected eye is moved towards the physiological field of gaze.

It might be thought that a displacement of a complete vertical rectus would limit the vertical movement of the eye. This rarely happens. On comparing the excursion of the

sound eye with that of the affected eye in extreme elevation and depression, it was found that in eight cases the operated eye showed limitation in extreme depression (Table II).

TABLE II *Postoperative ocular movements*

Average abduction	: 20.8°
Average improvement	: 20.6°
Limitation of elevation	: No patients
Limitation of depression	: 8 patients

(3) *Findings during the operation*

In most cases a forced duction test was carried out during the operation. In 44 cases the abduction was limited, but became normal after the medial rectus was detached from the globe.

This indicates that the elasticity of the medial rectus is restricted in most cases. This also is a major reason for recessing this muscle, as otherwise the abducting effect of the temporal displacement is reduced by the inelastic medial rectus.

To find out whether this fibrosis of the medial rectus is primary or secondary to the limitation of abduction, other anatomical anomalies were looked for. Although they were not sought in the earlier cases, abnormal strands or insertions which had an unusual shape or localization were found in 23 cases. It is obvious that such anatomical anomalies are not due to the limitation of abduction. It may therefore be asked whether the fibrosis of the medial rectus is a primary anatomical anomaly.

(4) *Influence of surgery on the anterior segment of the eye*

There is a risk of necrosis of the anterior segment when three rectus muscles of one eye are detached, but I have never observed any sign of necrosis, even in the 23 patients who were examined with the slit lamp.

This could perhaps be explained by the fact that the majority of patients are operated on at an early age when collateral circulation easily develops, but my adult patients showed no sign of necrosis either. This may be because I always take the greatest care to avoid trauma, so that swelling and chemosis do not impede the bloodflow and increase the risk of necrosis.

General principles

Before discussing the surgical technique I wish to stress some general principles concerning the surgery of the ocular muscles. It is very important to avoid trauma, because oedema easily induces adhesions which become strongly established when eye movements are avoided after the operation. Adhesions in turn lead to a limitation of ocular movement and prevent the restoration of binocular vision.

Besides the dexterity of the surgeon two factors are important: the duration of the procedure and the amount of bleeding.

We must save time and avoid unnecessary manipulations because otherwise chemosis appears.

The ciliary vessels, which bleed much more than conjunctival vessels, should not be touched until the last possible moment before detaching the muscles from the sclera. They then do not bleed so much because the muscle retracts, so that the bloodflow slackens.

Surgical technique (Fig. 4)

TRANSPLANTATION OF THE VERTICAL RECTUS MUSCLES

The conjunctiva is incised between the vertical and lateral rectus muscles, so that they can each be detached and re-attached through the same opening. The incisions should not be too large because of the danger of their gaping open and becoming circular. As the medial rectus is to be recessed, a third incision will be needed; this is discussed below.

A silk thread is passed through each vertical rectus 1 mm. from its temporal margin and 1 mm. away from the sclera. It is left unknotted to avoid reaction and adhesions.

A second thread is passed in the same way through the nasal border of each vertical rectus tendon. Important ciliary vessels running along the vertical rectus muscles are picked up with the suture and pinched off later when the thread is knotted.

The vertical rectus tendons are severed from the globe as close to the sclera as possible and the intermuscular membrane is cut along the border of each muscle. The nasal suture is now re-inserted through the temporal edge of the original insertion and knotted.

In re-attaching the vertical rectus muscles care must be taken not to damage the ciliary vessels of the lateral rectus, as they are the only ones remaining when the other three rectus muscles have been cut.

The conjunctival openings are closed with two separate catgut stitches. A continuous suture is not used as this means leaving additional foreign material in the tissues.

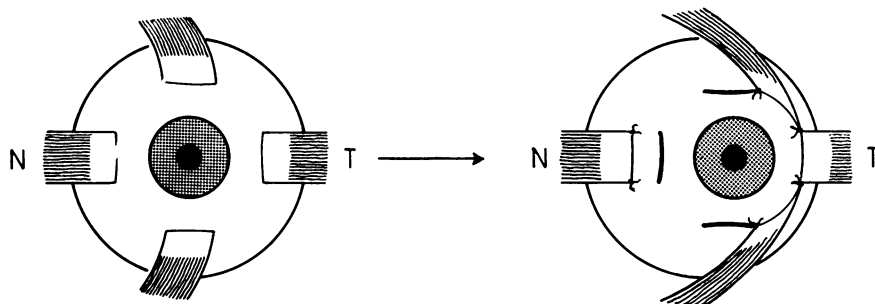


FIG. 4 Another view of the operation. The tendon of each vertical rectus is spread out between the original insertion and the lateral rectus

RECESSION OF THE MEDIAL RECTUS

In many cases of Duane's syndrome, not only abduction but also adduction is limited to some extent. In extreme lateroversion to the sound side, alternating cover testing shows an exodeviation. This seems to be due to abnormal strands or fibrotic check-ligaments, and we must therefore cut the check-ligaments very carefully when recessing the muscle. Nevertheless, limitation of adduction is often increased.

The recession must therefore not be too large, and the medial rectus must be re-attached at the place where it comes to rest when the eye is fully abducted.

The results of this double operation in a patient with Duane's syndrome are shown in Figs 5 to 9 (opposite).

Discussion

NUTT Duane's syndrome should be called the Stilling-Türk-Duane syndrome, as the condition was described by each author separately in 1887, 1896, and 1905 respectively. I feel that there are

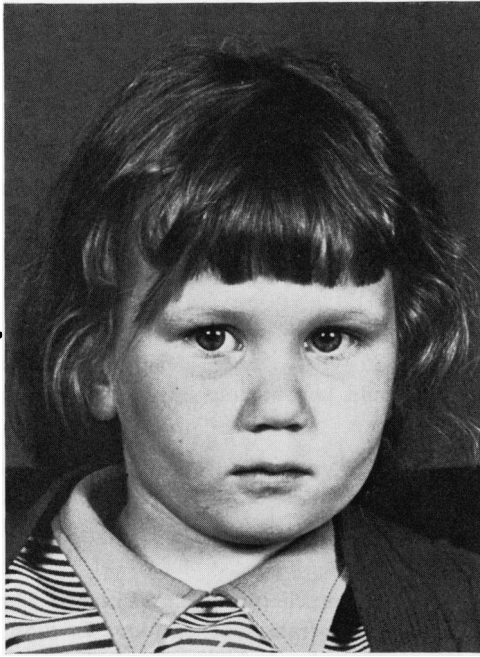

FIG. 5 5-year-old girl with Duane's syndrome of the left eye, looking straight ahead with abnormal head posture

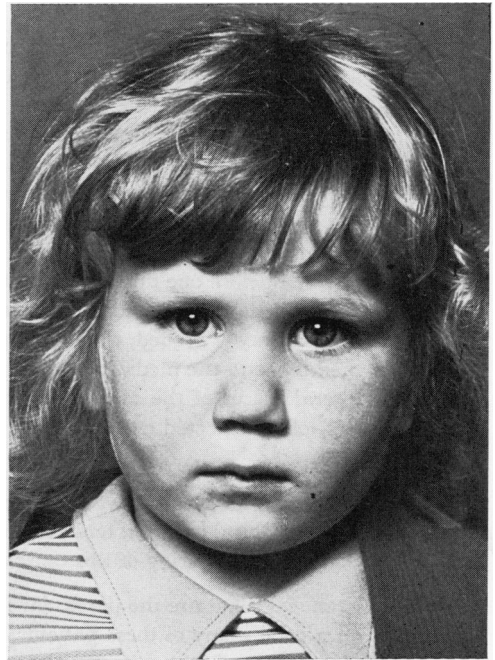


FIG. 6 The same girl after operation, with normal head posture

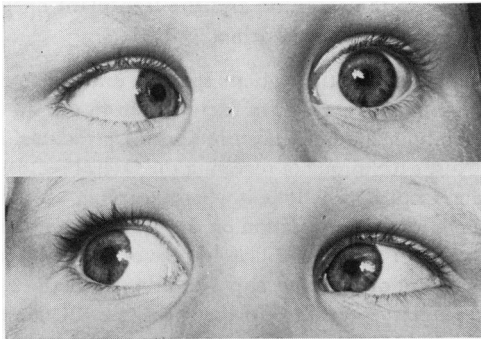


FIG. 7 Same girl before operation, showing limitation of abduction from the midline with widening of the palpebral fissure on looking left (top)

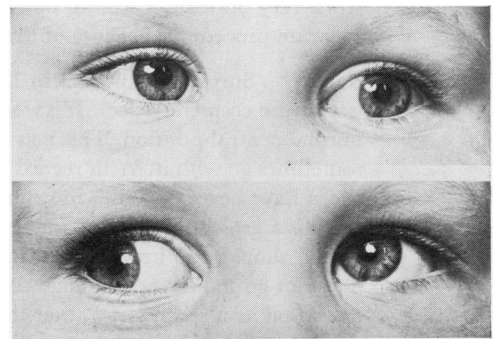


FIG. 8 Same girl after transplantation of vertical rectus muscles of left eye. The left eye can now be abducted to 30° (top) but there is limitation of adduction on looking right with an upshoot of the left eye (bottom)

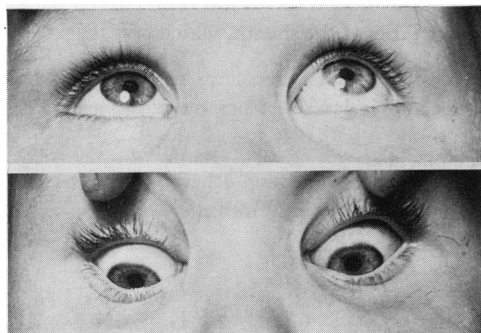


FIG. 9 Elevation and depression after operation

two types of Duane's syndrome, one due to anomalous muscular fascial anomaly and one due to anomalous nervous innervation, in which case the treatment and approach must be different. Many such patients should be left alone if they have binocular single vision and no diplopia. They learn to turn their head instead of turning their eyes, and on the whole surgical results are poor in these patients.

In many cases requiring surgery, if the medial rectus is explored, it is quite impossible to abduct the eye with forceps. The sheath is bound down and the muscle itself is fibrotic. There is a sheath of fibrous tissue above and below, and this sheath has to be removed and the muscle cleaned and recessed before one does anything to the lateral rectus. Recession of the lateral rectus of the opposite eye limits lateral rotation in the unaffected eye.

If surgery is needed, the first step should be a medial rectus recession of the affected eye. I would then move to the medial or lateral rectus of the good eye. Only occasionally would I operate on the lateral rectus of the affected eye, because this would tend to increase the contraction on adduction of the affected eye.

DUNLAP In cases of Duane's retraction syndrome Type I requiring surgery, I recess the medial rectus of both eyes followed by a recession of the lateral rectus of the affected eye. I consider that the latter is logical in that it tends to decrease the amount of lid narrowing on adduction, and also reduces the effect of co-firing of this muscle.

LYLE What are the particular indications for your muscle transplant operation? I have operated on a good many of these patients, and I tend to reserve transplant technique for those who have a gross defect of adduction or abduction, as the case may be, and who in consequence have adopted an unsightly compensatory head posture. Many patients with Duane's syndrome can be relieved of their angle of deviation quite well by simple recession or resection. This, however, must be assisted by muscle transplantation if there is a gross defect of adduction which makes reading or other near work very difficult. I would, however, always do the recession and the transplant operation as two separate procedures because of the dangers of anterior segment necrosis.

GOBIN Surgery is justified in Duane's syndrome if the patient squints, and if the head posture is a severe cosmetic defect. It is worth while to move the range of excursion from the side to the more normal central position. This gets rid of the abnormal head posture and the structural changes that sometimes go with it. With regard to Mr. Nutt's technique of recessing the lateral rectus of the sound eye, I have never done this in cases of Duane I but I have done it when exotropia was present. When there is a gross limitation of adduction, I do a recession-resection on the sound eye which works very well. I should also imagine that it would work in an uncomplicated case of Duane I, provided one does not go too far and change the head posture over to the opposite side. I therefore perform this operation as a secondary rather than as a primary procedure. I do not recess the lateral rectus of the affected eye unless there is very gross retraction of the eyeball. Recessing the lateral rectus naturally has no effect on improving abduction. It is difficult to recognize true musculo-fascial anomalies which could not have been due to secondary changes, but I have noticed that the insertion of the superior and inferior rectus muscles have been very far back, perhaps even 1 cm. behind their usual place of insertion, and also that the insertion of the medial rectus has been curved backwards instead of forwards. Some patients certainly have anomalies of the sheath, which can be very thick in parts.

DUNLAP What is the effect of surgery on the vertical movements of the eye? I have noticed in photographs of patients that a marked vertical deviation often persists after surgery. Have you any method of treating the vertical upshoot?

GOBIN When there is a marked upshoot in the affected eye I bring the medial rectus 0.5 cm. downwards. This is effective, in that it makes the medial rectus pull slightly downwards and so compensates for the elevation in adduction.