

Federov iris-supported intraocular acrylic lens

P. JARDINE AND J. H. SANDFORD-SMITH

Bristol Eye Hospital, Bristol

The use of intraocular lenses in the correction of aphakia was first described by H. Ridley (1951), and subsequently numerous designs have been described and their use enthusiastically recommended.

The problems of spectacle correction for aphakia are well known and have been described in detail (Editorial, 1952; Linksz, 1965), and many ophthalmic surgeons are only too familiar with the patient with unilateral aphakia and partial lens opacities in the other eye who cannot understand the surgeon's satisfaction, since the vision is blurred in one eye, and distorted in the other, and fusion is quite impossible because of aniseikonia. The use of contact lenses is usually recommended, but Pearce (1972) has recorded that in three separate series of patients fitted with contact lenses over 50 per cent. had abandoned their wear after some time.

The optical advantages of an intraocular lens for all patients with aphakia are obvious, but particularly so in cases of unioocular aphakia. Nevertheless their use is not widespread because of the possibility of serious postoperative complications. This report describes a series of patients in whom Federov-type iris-supported intraocular acrylic lenses were implanted as a primary procedure at the time of extraction, with particular attention to the postoperative complications.

The iris-supported method of fixation was chosen because of the advantages of a one-stage procedure, and because of favourable long-term reports from several sources (Binkhorst and Leonard, 1967; Dallas, 1970; Federov, 1965); the pattern designed by Federov was used because the arrangement of the fixation loops seemed easier to insert and the lens less likely to dislocate subsequently (Fig. 1, opposite).*

Selection of patients for surgery

The basic criterion for selection was a predominantly unioocular cataract, but in five cases the operation was done bilaterally, either at the patient's request initially or because of lens opacities developing later in the second eye. One patient had a unilateral lens opacity following uveitis and systemic steroid treatment for ankylosing spondylitis; one patient had a previous penetrating injury with a retained foreign body in the lens; and one patient was diabetic. The remainder had idiopathic acquired cataracts.

During the period under consideration (February, 1968, to December, 1971), 58 lenses were inserted in 53 patients. Only 53 lenses (37 in men and 16 in women) are included in the results. One patient moved away, one did not attend for follow-up after 3 months, one (2 eyes) was mentally disturbed and

Address for reprints: P. Jardine, F.R.C.S., as above

*All the implants were manufactured and supplied by Messrs. Rayner & Co. of Sheraton House, Lower Road, Chorleywood, Herts, to a pattern designed by Federov.

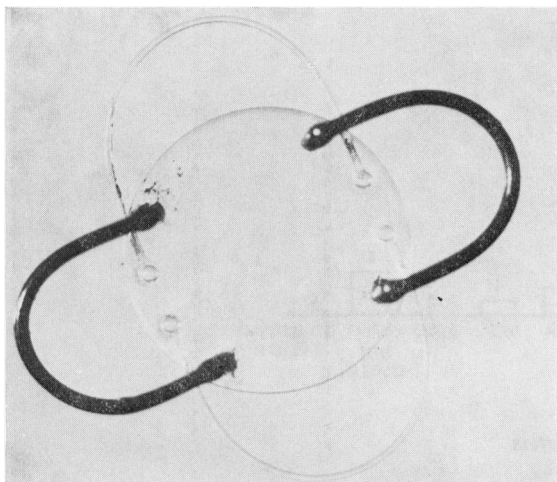


FIG. 1 *Federov iris-supported lens*

could not be examined, and one died 9 months after the operation. The two eyes of a patient who survived for 3 years are included.

The average age at the time of operation was 61.8 years and the preponderance of males probably reflects the great need for binocularity in late middle-aged and elderly men who are still at work; 24 eyes were right and 29 were left.

Surgical technique and postoperative care

All the operations were carried out under local anaesthesia with premedication and all except three were performed by the senior author (P. J.). The eye was entered with an *ab externo* incision using a limbus-based conjunctival flap. Two peripheral iridotomies were made and the lens removed with cryoextraction or forceps after zonulysis. The acrylic lens was then held with capsule forceps so that the posterior black loops were pointing up and down, and the prosthesis was inserted immediately after extraction by sliding the lower black loop behind the lower pole of the iris, and then by lifting the upper pole of the iris in front of the upper black loop. The anterior transparent loops lay naturally in front of the iris in the 3 o'clock and 9 o'clock meridians. The three pre-placed corneal sutures were then tied and the anterior chamber re-formed with intracameral pilocarpine and air; further sutures were then placed as necessary. Betnesol with neomycin ointment was applied and the eye padded.

Postoperatively pilocarpine drops and Betnesol ointment with neomycin were applied twice daily, and the patients were discharged from hospital after a week. Afterwards they were seen routinely in the out-patients department and the steroid ointment was discontinued after 6 to 8 weeks if there were no significant signs of inflammation. At this time they were also refracted. After about a year the pilocarpine was also discontinued.

Results

The corrected visual acuity when the patients were refracted 6 weeks postoperatively is shown in Fig. 2. The most recent visual acuity recorded in 1973 is shown in Fig. 3. All patients have been followed up for at least 1½ years, the average length of follow-up being 2.7 yrs.

Since all the complications developed during the first 18 months postoperatively (all except two during the first 9 months), it was felt that there would not be much advantage in delaying presentation of this study.

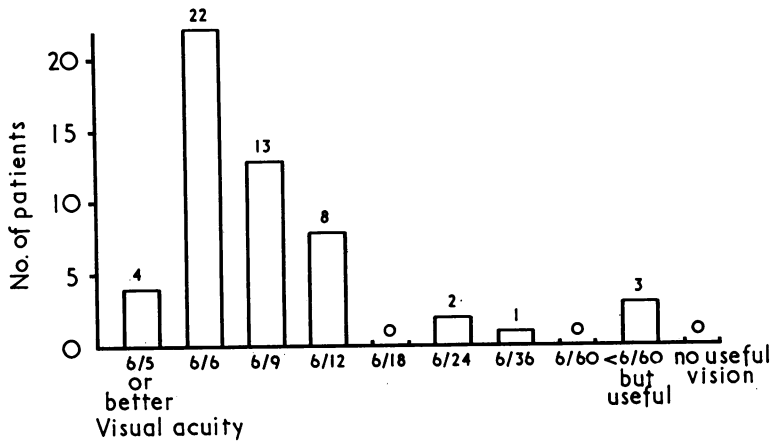


FIG. 2 Corrected visual acuity 2 months after operation

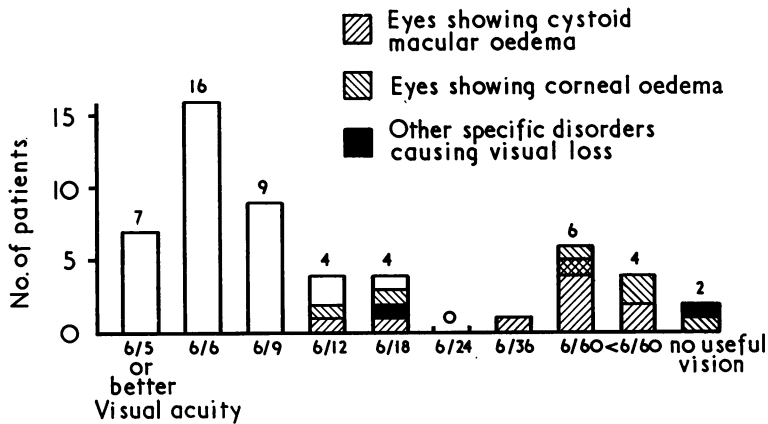


FIG. 3 Final corrected visual acuity

COMPLICATIONS

The complications and their effect upon the final result are considered in detail as this appears to be the most controversial aspect concerning the use of intraocular lenses.

(1) Vitreous loss

This was the only significant operative complication (the other complications being post-operative). It occurred in six cases and might have been avoided if a lens had not been inserted. In three of these cases there were no subsequent complications. In one the pupil became slightly updrawn and the corrected acuity was 6/18. In one the anterior chamber subsequently became flat and required re-formation. The loops of the prosthesis came in contact with the posterior corneal surface for a time, causing localized corneal oedema which slowly cleared, and the final visual acuity was 6/12. In one case iritis and iris *bombé* ensued—an iridectomy was done and the implant removed. This gave satisfactory vision for a time (6/9 with an aphakic spectacle correction) but 9 months later a retinal detachment occurred, surgical treatment was not successful, and the eye became blind.

(2) Inflammatory changes

Generally the eyes appeared to tolerate the lenses very well and there was both subjectively

and objectively very little evidence of any different amount of postoperative inflammation from a standard cataract extraction. A few eyes which were otherwise normal showed occasional cells circulating in the anterior chamber and some keratic precipitates on the lens were noted three times. Two of these eyes were otherwise normal and one developed slight macular oedema and a visual acuity of 6/12. One case had some synechiae of the iris to the vitreous face and a visual acuity of 6/4. In one case a blood clot formed behind the acrylic lens and this became organized to leave a fibrinous membrane which was incised satisfactorily, the final visual acuity being 6/9. In one case already mentioned iris *bombé* and iritis occurred after vitreous loss. In one case significant iris atrophy was noted in an eye which also developed cystoid macular changes and delayed corneal oedema. In two instances a marked vitreous haze was noted and in one instance there was persistent circumcorneal injection and subjective irritability of the eye; cystoid macular changes subsequently occurred in all these three eyes.

(3) *Retinal detachment*

This occurred in two patients. Of these one was successfully treated with a silicone rod encirclement, but in the other patient (already described under vitreous loss) this was unsuccessful and no useful vision was obtained.

(4) *Dislocation of the lens*

This was not noted in this series in spite of discontinuing pilocarpine drops after a year. An incidence of 11 per cent. had been recorded with the Binkhorst lens (Pearce, 1972). The different design of the fixation loops in the Federov lens may be the reason for this improvement. In one instance the inferior loop was found at first dressing to have been incorrectly placed in front of the iris and this was easily corrected.

(5) *Glaucoma*

Two patients developed glaucoma postoperatively; in both cases "pupil block" was the cause. In one this occurred after vitreous loss and iritis (this patient has already been described). In the other case pupil block was noted 3 weeks postoperatively and was successfully treated with a posterior sclerotomy and peripheral iridectomy. However, there were residual peripheral anterior synechiae with an intraocular pressure of 35 mm. and a further drainage operation was required to bring the pressure to normal. The final visual acuity was 6/12 and the visual field full.

(6) *Corneal changes*

Owing to the increased manipulation compared with a straightforward cataract extraction, the usual transient striate keratopathy after lens extraction appeared to be slightly more marked, but it cleared rapidly within the first 2 days.

Seven cases were noted which still showed some corneal oedema on discharge from hospital or in which corneal oedema developed later.

One case (already described) had vitreous loss and subsequently a flat anterior chamber; corneal oedema developed but this gradually cleared, leaving a visual acuity of 6/12.

Four cases showed persistent corneal oedema from the time of surgery. Two have received penetrating grafts; one of these was not successful because of oedema of the graft and one was clear for 3½ years and has recently become slightly oedematous.

Two cases had a normal early postoperative course and perfectly clear cornea for at least 1 year, and then fairly rapidly developed corneal oedema. One of these has had a successful

penetrating graft; the other had cystoid macular changes noted before the cornea became oedematous. The final visual acuity of this group is shown in Fig. 3.

(7) *Macular changes*

In ten eyes cystoid macular degenerative changes were noted on slit-lamp examination with the Hruby lens. (In one of these the changes were atypical as there was some pigmentary degeneration at the macula and a tiny paramacular haemorrhage with a normal macula in the other eye.)

In one case oedema of the disc was also noted.

In all cases the operative and immediate postoperative course was uneventful and the first signs of visual deterioration occurred from 1 to 9 months after operation. The corrected visual acuity in this group 2 months postoperatively was 6/6 in six cases, 6/9 in one, 6/18 in two, and 6/24 in one, and it is probable that in some of these cases early macular oedema was already present, although we were not aware of it at the time.

The final visual acuity is shown in Fig. 3.

In two instances the macular changes developed after a noticeable vitreous haze; in one there was associated circumcorneal injection and in one there were some keratic precipitates on the acrylic lens. In one case corneal oedema and iris atrophy developed after the macular changes had occurred.

(8) *Others*

In one case the capsule ruptured during extraction and there were no subsequent complications. One patient developed a partial retinal vein thrombosis 9 months postoperatively causing the acuity to fall from 6/6 to 6/18. Astigmatism was often present from the pupil becoming slightly eccentric or the lens tilted, but this did not seem to cause any visual problems.

Discussion

Apart from the one eye which became blind after a retinal detachment and one which developed a partial retinal vein thrombosis, the significant complications are vitreous loss at surgery, postoperative corneal oedema, and postoperative cystoid macular degenerative changes. (The incidence of retinal detachment does not seem any greater than after routine extraction and the management of retinal detachments in patients with iris-supported or iris-clip lenses has recently been discussed (Jungschaffer, 1972).)

It is our impression that the incidence of vitreous loss (11 per cent.) could be reduced by not inserting the lens in any patient in whom the vitreous face was not well back after lens extraction. Osmotic diuretics may be helpful in reducing vitreous loss, although in this series they were not used. Half the cases of vitreous loss developed later complications, although only one had no useful vision.

Corneal oedema was at first a frequent complication of intraocular acrylic prostheses. However, the adoption of stringent safety measures in manufacture and sterilization proposed by F. Ridley (1957) is said to produce an end-product which is without toxicity to the corneal endothelium.

The overall incidence of corneal oedema in this series is 13 per cent. In five of the seven cases in which it developed the onset occurred at the time of surgery, and this would suggest that excessive corneal manipulation at operation was the prime cause. (It is significant that the first two implants in the series both developed corneal oedema.)

The other two cases of corneal oedema which developed over a year after surgery cannot be so easily explained. In one there were other signs of inflammatory intraocular changes (macular oedema and iris atrophy) and in the other, which was grafted, vitreous strands were found to have come through the iridectomy and to be adherent to the endothelium. These two cases, however, raise the possibility that either the acrylic lens or its supramid fixing loops can in certain circumstances become toxic or irritant, or else that some eyes will react to any foreign body even if it is truly "inert".

The final visual acuity in this group was poor. Three of these eyes had penetrating grafts; one graft never cleared, one was clear for over 3 years and then gradually became oedematous, and one recently grafted is clear with good vision. The presence of an iris-clip lens and intact iris diaphragm makes a penetrating corneal graft in an aphakic eye easier to perform.

Macular oedema and cystoid changes were noted in ten cases (19 per cent.). These changes after cataract extraction were first described by Irvine (1953) and there have since been various reports in which an assessment of the incidence and nature of this unfortunate but interesting condition has been attempted.

Undoubtedly aphakia seems to predispose to macular oedema, as is shown by such changes being produced by adrenaline drops in aphakic eyes (Kolker and Becker, 1968). The incidence after routine cataract extraction is generally thought to be from 1 to 2 per cent. (Gass and Norton, 1966; Maumenee, 1967; Tolentino and Schepens, 1965). However, a careful study has shown an incidence of 7.6 per cent. (Gehring, 1968) and a recent report concerning combined cataract extraction and keratoplasty gives an incidence of over 50 per cent. (West, Fitzgerald, and Sewell, 1973); the true incidence is possibly considerably more than 2 per cent.

Macular oedema has been reported only with the iris-clip type of intraocular acrylic lens, the incidence being recorded as 12 per cent. (Binkhorst and Leonard, 1967) and 5 per cent. (Pearce, 1972).

The incidence of macular oedema in this series seems to be significantly high in spite of the uncertainty of its true incidence after routine cataract extraction. In addition, the final visual acuity in cases with cystoid macular oedema seems worse in this series than others. Gehring (1968), for instance, recorded a final visual acuity of 20/30 or better in 83 per cent. of his cases and in Pearce's report on the Binkhorst lens four of his five patients with macular oedema saw 6/18 or better; whereas only two of our ten cases can see better than 6/36.

The aetiology of macular oedema is uncertain. Vascular instability (Nicholls, 1955), vitreo-retinal traction (Tolentino and Schepens, 1965), and inflammatory changes (Gass and Norton, 1966) have all been suggested as possible factors. As three of our patients showed marked inflammatory changes before developing macular oedema (two had a vitreous haze and one had persistent circumcorneal injection), and as the presence of an acrylic lens would be likely to prevent changes in the position of the anterior vitreous and hence traction, it would seem that the inflammatory factor is significant in this series.

Two of the patients with bilateral implants developed macular oedema in one eye only, which would point to a local rather than a constitutional factor in its cause. In the other eight patients there was no evidence of any macular abnormality in the other (unoperated) eye.

It is of great interest that Gehring (1968) reported excellent results from the use of steroids in this condition and West and others (1973) noted that macular oedema did not occur in those patients who were having systemic steroid treatment; and steroids may well be of great therapeutic value for cystoid macular oedema following cataract extraction.

In conclusion, we find it hard to adopt an unduly optimistic or pessimistic attitude to

these controversial devices. These results are less satisfactory than many other reports, the main problems being corneal oedema and cystoid macular changes. However, greater surgical experience and a determination to insert a lens only in the most favourable conditions may lessen the incidence of corneal oedema, and similarly prompt and energetic steroid treatment may lessen the visual damage from cystoid macular oedema.

Summary

A series of 53 cataract extractions with simultaneous insertion of an iris-supported intra-ocular acrylic lens designed by Federov is described.

The operative and postoperative complications are detailed.

The only significant causes of an unsatisfactory visual result are corneal oedema and cystoid macular oedema.

The causes, means of prevention, and treatment of these two complications are discussed.

References

- BINKHORST, C. D., and LEONARD, P. A. M. (1967) *Amer. J. Ophthalm.*, **64**, 947
 DALLAS, N. L. (1970) *Trans. ophthalm. Soc. U.K.*, **90**, 725
 EDITORIAL (1952) *Amer. J. Ophthalm.*, **35**, 118
 FEDEROV, S. N. (1965) *Vestn. Oftal.*, **78**, No. 5, p. 76
 GASS, J. D. M., and NORTON, E. W. D. (1966) *Arch. Ophthalm. (Chicago)*, **76**, 646
 GEHRING, J. R. (1968) *Ibid.*, **80**, 626
 IRVINE, S. R. (1953) *Amer. J. Ophthalm.*, **36**, 599
 JUNGSCHAFFER, O. (1972) *Arch. Ophthalm. (Chicago)*, **88**, 594
 KOLKER, A. E., and BECKER, B. (1968) *Ibid.*, **79**, 552
 LINKSZ, A. (1965) "Complications after Cataract Surgery", ed. F. H. Theodore, p. 597. Churchill, London
 MAUMENEE, A. E. (1967) *Arch. Ophthalm. (Chicago)*, **78**, 151
 NICHOLLS, J. V. V. (1954) *Amer. J. Ophthalm.*, **37**, 665
 PEARCE, J. L. (1972) *Brit. J. Ophthalm.*, **56**, 319
 RIDLEY, F. (1957) *Ibid.*, **41**, 359
 RIDLEY, H. (1951) *Trans. ophthalm. Soc. U.K.*, **71**, 617
 TOLENTINO, F. I., and SCHEPENS, C. L. (1965) *Arch. Ophthalm. (Chicago)*, **74**, 781
 WEST, C. E., FITZGERALD, C. R., and SEWELL, J. H. (1973) *Amer. J. Ophthalm.*, **75**, 77