

Geographical choroidopathy

A. M. HAMILTON AND A. C. BIRD

From the Retinal Unit, Institute of Ophthalmology, University of London

Atrophy of the retinal pigment epithelium and choriocapillaris takes many forms, and attempts have been made to identify distinct clinical entities within this group of diseases: central senile areolar choroidal sclerosis, peripapillary choroidal sclerosis, generalized choroidal sclerosis (Sorsby, 1939), subacute multifocal placoid pigment epitheliopathy (Gass, 1968), pigment epitheliitis (Krill and Deutmann, 1972), and serpiginous choroidopathy (Gass, 1970).

Franceschetti (1962) collected sixteen cases of circumscribed atrophy of the posterior pigment epithelium and choroid from his own practice and from the previous literature, and he termed the condition "helicoid peripapillary chorioretinal degeneration". Some patients included in this category had progressive disease (Kraffel, 1955; Maumenee, 1968), whilst in others the disease was static (Rubino, 1940; Sveinsson, 1939); some patients were considered to have congenital defects (Rubino, 1940; Sveinsson, 1939) and others were shown to have infective disease (Brown, 1937; Hsin-Hsiang, 1948; Weve, 1957). In those cases considered to be infective in origin, the lesions frequently corresponded to the retinal veins, and pigment migration into the retina was a feature. In cases of "degenerative" and "congenital" disease, it was noted that the lesions did not underly the retinal vessels and that there was no pigment migration into the retina. It is clear that helicoid degeneration, as described, is not a single disease entity, and that this term has been used to denote separate diseases with similar ophthalmoscopic features.

It is the purpose of this paper to present the morphological characteristics and evolution of a disease formally included in the "helicoid" group of disorders, which has an acute onset, and in which the initial changes are seen at the level of the pigment epithelium. Fluorescein fundus angiography has been used as an aid to define the features of the disease.

Material and methods

The patients described in this paper were referred to the Retinal Unit from the ophthalmic practice in Moorfields Eye Hospital.

Fluorescein angiography

Five ml. of 20 per cent sodium fluorescein were injected into the antecubital vein, and photographs were taken at 1-second intervals during the initial transit of dye through the ocular fundus with a Zeiss (Oberkochen) fundus camera using Ilford FP4 film. A Baird Atomic interference filter with an 80 per cent. transmission at 4,800 Å and a broad transmission band of 400 Å was used for excitation, and an Ilford 110 gelatin filter as a barrier.

Patient 1, a 42-year-old female clerical assistant, presented in February, 1972, having noticed a paracentral defect in the visual field of the right eye 1 month previously. The referring letter stated

that 9 years before, during a routine eye examination, a small patch of choroidal atrophy had been noticed between the disc and macula of the right eye, and on the nasal side of the disc in the left; visual acuity at that time was unaffected and no action taken.

Examination The visual acuity with the right eye was 6/36 and with the left 6/5. No inflammatory cells were seen in the aqueous or vitreous humours of either eye.

In the right fundus were several well-defined areas of pigment epithelial atrophy, and extending from the temporal edge of one was a patch of pigment epithelial and retinal swelling (Plate 1, overleaf).

Fluorescein angiography was performed and the area of swelling was hypofluorescent during the initial transit of dye (Fig. 1*a*), but at 5 minutes was indistinguishable from the surrounding normal fundus (Fig. 1*b*). In May, 1972, 3 months after the initial referral, the temporal lesion was no longer swollen, and had taken on a darker appearance (Plate 2). On fluorescein angiography the centre of the lesion was dark, and the margin hyperfluorescent (Fig. 1*c*). After a further 3 months a fresh diseased area appeared as an extension of the earlier lesion (Plate 3). As before, the new lesion presented with swelling of the retina and pigment epithelium. The swelling slowly subsided and the lesion appeared grey by September, 1972 (Plate 4). Fluorescein angiography in December, 1972 (10 months after the original presentation and 6 months after the second lesion had appeared), showed marginal hyperfluorescence of the newest lesion; the original area of acute disease had taken on a similar appearance to the old lesions (Fig. 1*d*, overleaf).

In the left eye there were pigment epithelial changes on presentation (Fig. 2*a*) and during the subsequent 10 months new areas of involvement appeared (Fig. 2*b*).

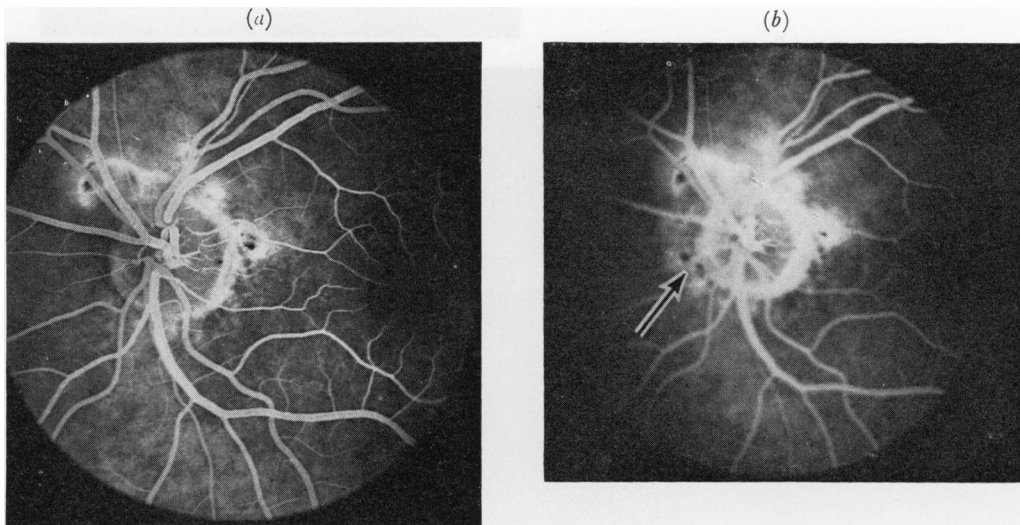


FIG 2 *Patient 1, left eye*

(a) *At presentation 5 min. after initial dye entry, showing hyperfluorescence and areas around optic disc*

(b) *10 mths after presentation at 5 min., showing hyperfluorescence of fresh lesions (arrowed)*

Despite progression of the disease process during the year of observation, there were no additional visual symptoms or loss of acuity.

A full medical examination revealed no abnormalities and the results of the following investigations were normal: haemoglobin, white blood cell count, erythrocyte sedimentation rate, serum calcium, plasma proteins and electrophoresis, serum cholesterol, blood sugar, Paul-Bunnell screening test and chest x ray. Serological tests for syphilis (CWR, RPCFT, and VDRL) were negative.

The light-induced rise in ocular potential was normal in both eyes at the time of the last visit.

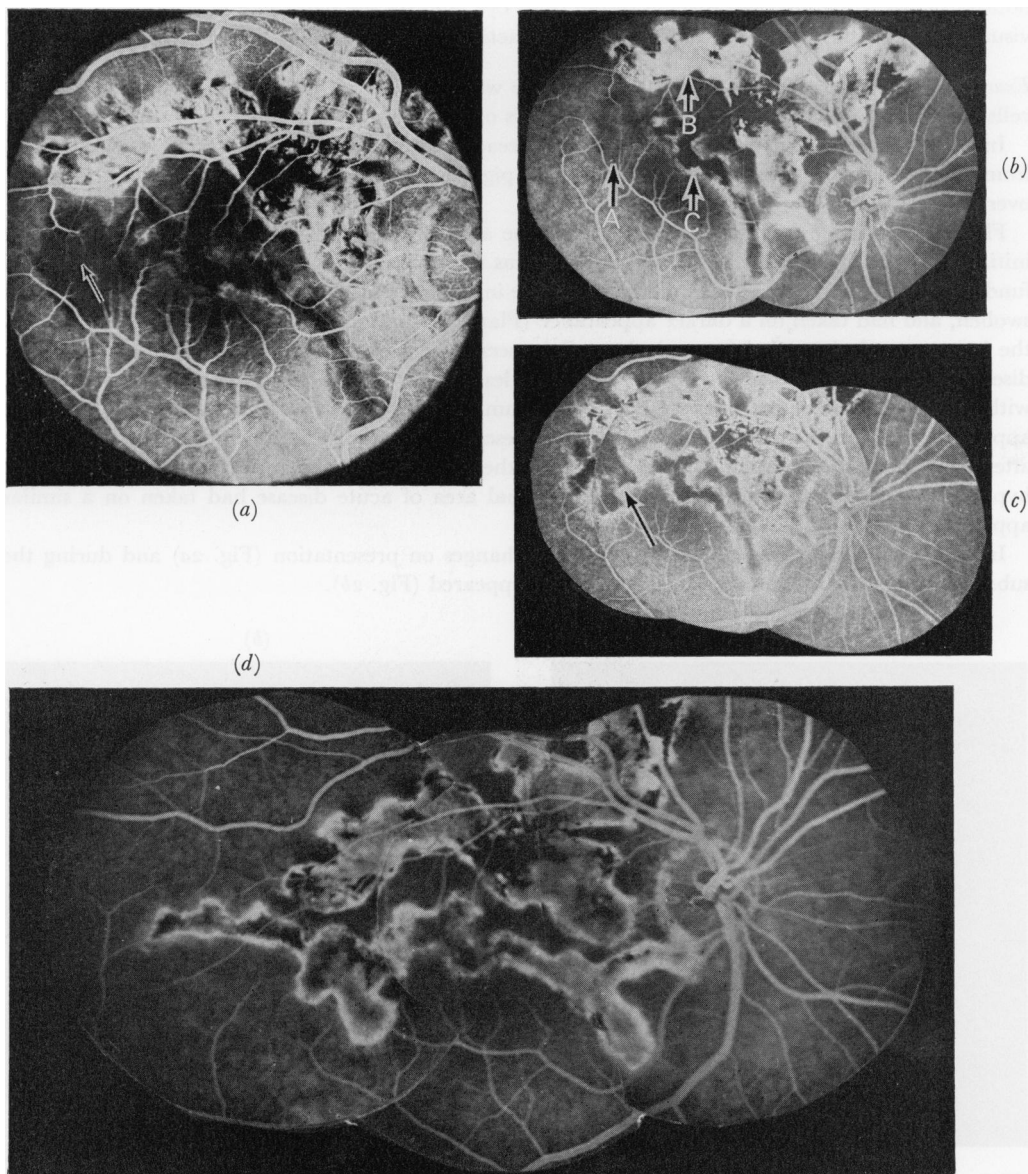


FIG 1 *Patient 1, right eye*

- (a) *At presentation during initial transit of dye, showing hypofluorescence of fresh lesion (arrowed)*
- (b) *5 min. after initial dye entry, showing area of fresh lesion resembling surrounding normal choroidal fluorescence. (A) Old lesions above show fairly uniform hyperfluorescence. (B) Lesion at intermediate stage of evolution. (C) Central hypofluorescence and marginal hyperfluorescence*
- (c) *3 mths later at 5 min., showing the central hypofluorescence and marginal hyperfluorescence (arrowed) of acute lesion*
- (d) *10 mths after presentation and 5 min. after initial dye entry, showing similarity of all lesions*

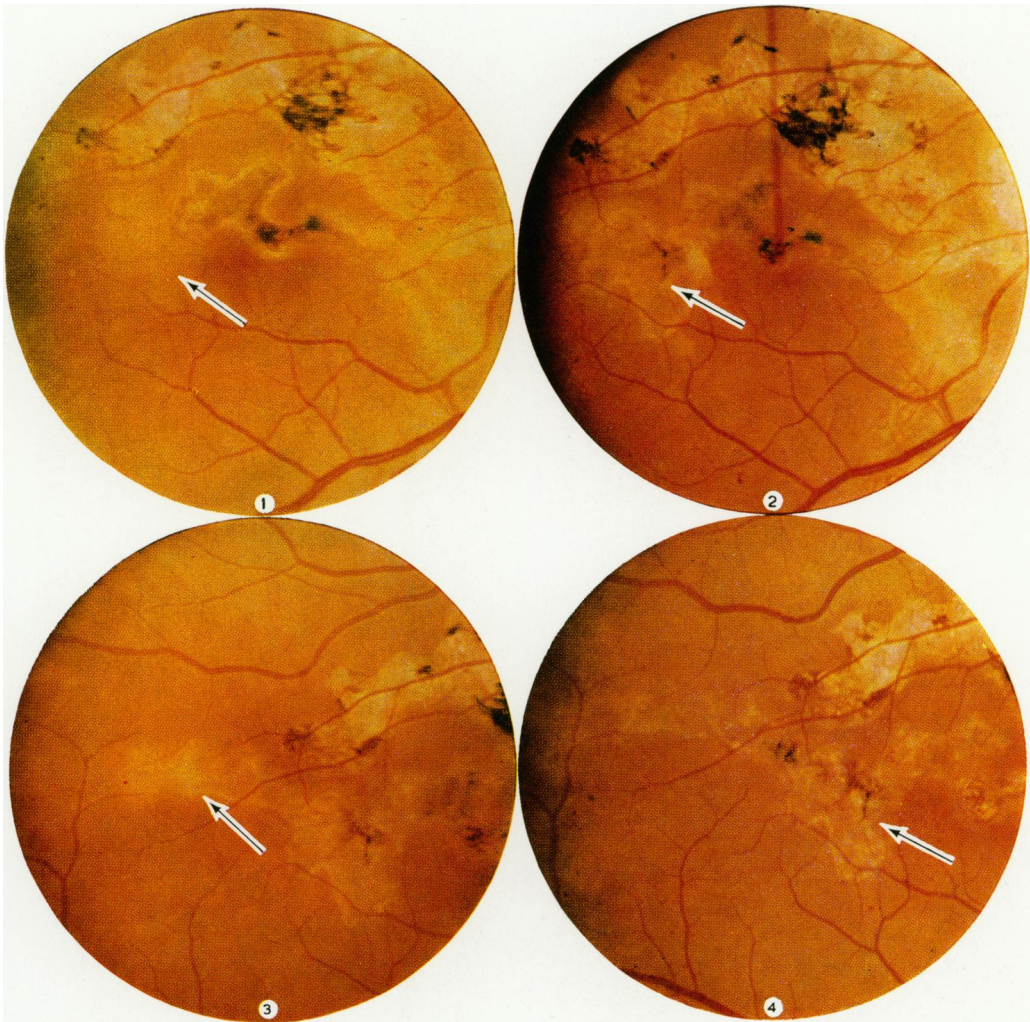


PLATE 1 *Patient 1, right eye at presentation showing acute lesion (arrowed) adjacent to existing lesions. Acute lesion shows swelling of pigment epithelium with overlying retinal oedema*

PLATE 2 *Patient 1, right eye 3 mths after appearance of acute lesion (arrowed), showing grey appearance with surrounding whitish margin and early pigment epithelial hypertrophy. At this stage there is no swelling of the pigment epithelial lesion and the overlying retina appears to be normal*

PLATE 3 *Patient 1, right eye showing acute lesion (arrowed) confluent with existing lesions in region temporal to the macula. This lesion shows swelling at level of pigment epithelium with overlying retinal oedema*

PLATE 4 *Patient 1, right eye 7 mths after presentation and one mnth after Plate 3. The new lesion has developed a greyish central area and lighter margin and the swelling of the pigment epithelium and retina has subsided. The previous acute lesion (arrowed) is paler with increased pigment epithelial hypertrophy and is beginning to resemble the existing lesions above*

Patient 2, a 44-year-old housewife, presented in December, 1971, with a 3-month history of blurred vision in the left eye. The visual acuity was 6/5 in the right eye and finger-counting in the left. No inflammatory cells were seen in the aqueous or vitreous humours.

In the right fundus juxtapapillary pigment epithelial atrophy was seen.

In the left fundus there was an irregular pale lesion at the level of the pigment epithelium nasal to the macula, and well-defined pigment epithelial atrophy on the temporal side. On fluorescein angiography the atrophic lesions were uniformly hyperfluorescent (Figs 3a and 4a), whilst the pale

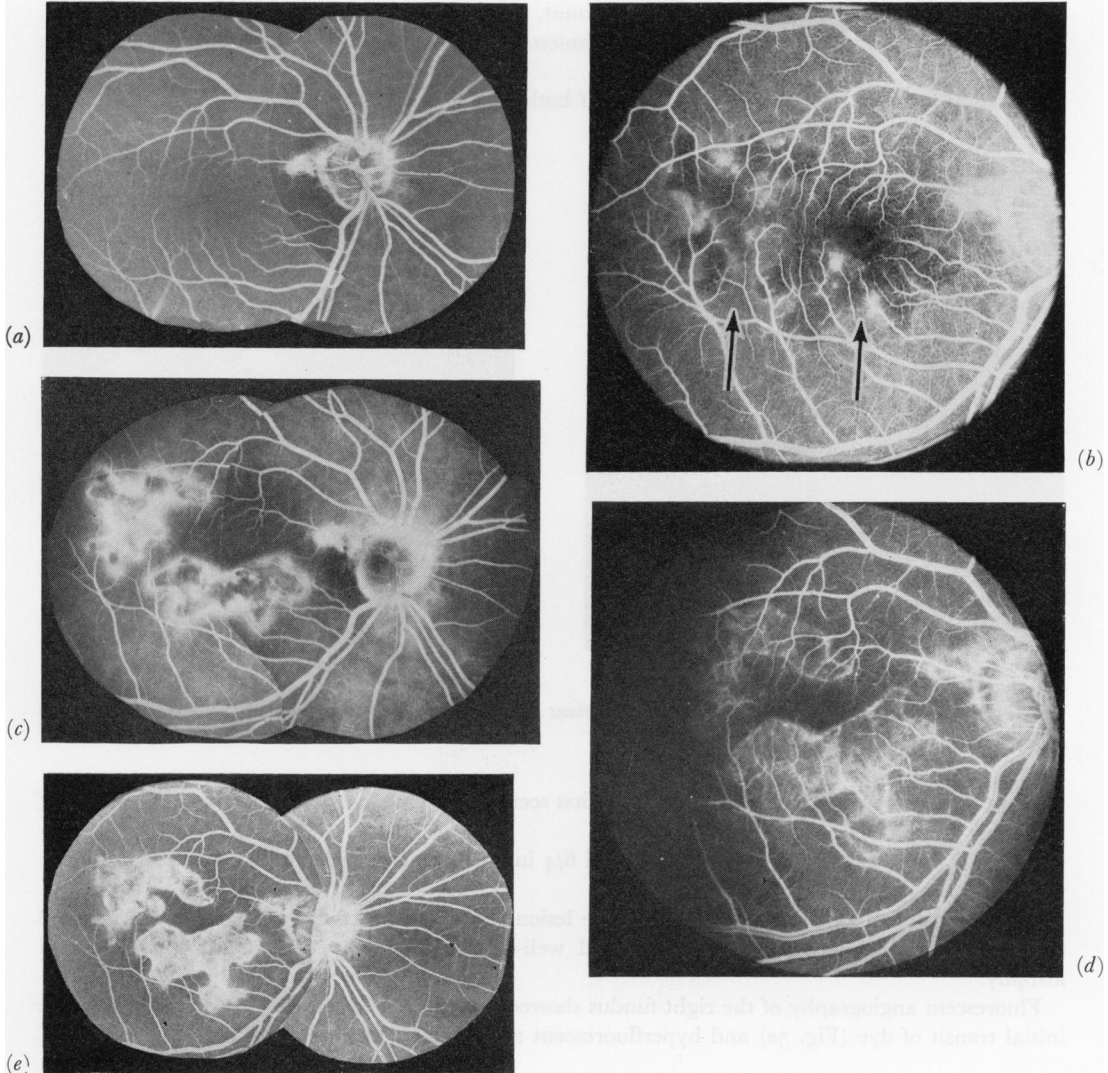


FIG. 3 Patient 2, right eye

- (a) At presentation 5 min. after initial dye entry, showing hyperfluorescence of lesion adjacent to disc margin
- (b) 12 mths after presentation during initial transit of dye, showing hypofluorescence of acute lesions (arrowed)
- (c) At 5 min., showing hypofluorescence of central area and marginal hyperfluorescence
- (d) 9 mths after presentation, showing relative hyperfluorescence of involved area during initial transit of dye
- (e) At 3 min., showing fairly uniform hyperfluorescence of lesions but with further extension as compared with (b) and (c)

lesion was hypofluorescent centrally and had bright borders (Fig. 4a).

During the following year there were no additional visual symptoms, but progression of the disease process was recorded in both eyes. Fluorescein angiograms showed hypofluorescence of the fresh lesions in the right eye during the initial transit of dye (Fig. 3b), and marginal hyperfluorescence at 5 minutes (Fig. 3c), while in the left eye all lesions appeared similar to the atrophic areas (Fig. 4b).

A further 9 months later (September, 1972), fresh lesions were seen in the right eye (Figs 3d, e), but the left eye was unaltered.

A full medical examination revealed no abnormalities and the results of the following investigations were normal: haemoglobin, white blood cell count, erythrocyte sedimentation rate, serum calcium, plasma proteins and electrophoresis, serum cholesterol, blood sugar, and Paul-Bunnell screening test.

The light-induced rise in ocular potential of both eyes was normal at the time of the last visit.

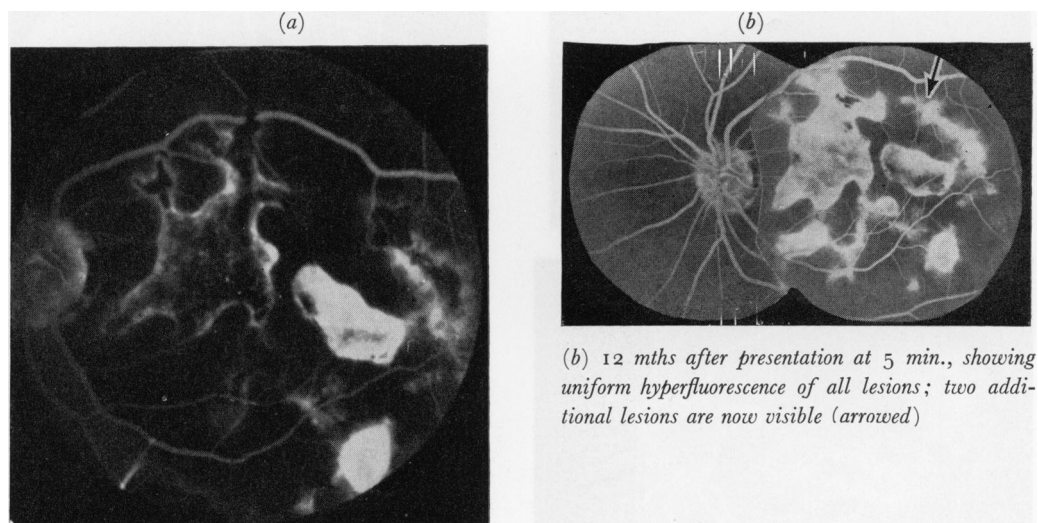


FIG. 4 *Patient 2, left eye*

(a) *At 3 min., showing extent of pigment epithelial lesions at posterior pole; in fresh lesion between disc and macula hyperfluorescence was limited to the borders*

Patient 3, a 41-year-old truck driver, was first seen in September, 1971, with a 3-week history of a shadow in the vision of the right eye.

Visual acuity was 6/60 in the right eye and 6/4 in the left. The aqueous and vitreous humours were normal.

At the right posterior pole there was a pale lesion with swelling of the pigment epithelium and overlying retina, while the left fundus showed well-demarcated peripapillary pigment epithelial atrophy.

Fluorescein angiography of the right fundus showed hypofluorescence of the pale area during the initial transit of dye (Fig. 5a) and hyperfluorescent margins at 5 minutes (Fig. 5b).

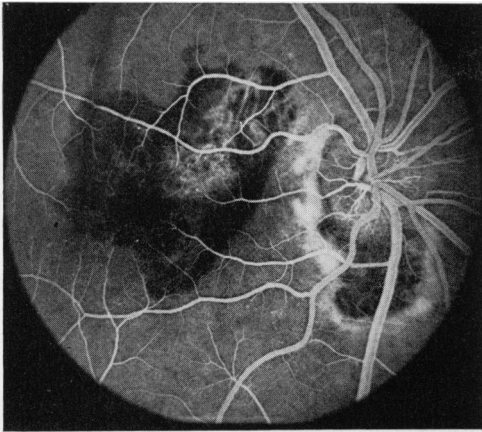
FIG. 5 *Patient 3, right eye*

(a) *At presentation during initial transit of dye, showing hypofluorescence of lesion underlying macula*

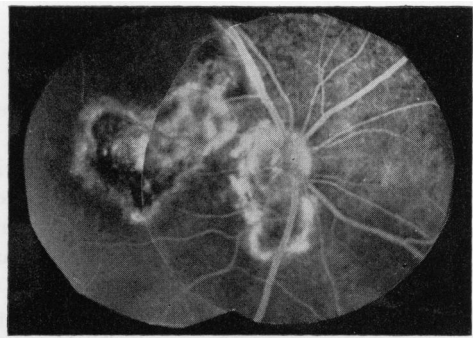
(b) *At 5 min., showing central hypofluorescence and marginal hyperfluorescence. Remaining lesions are hyperfluorescent*

(c) *3 wks later at 5 min., showing no changes in size as compared with (b)*

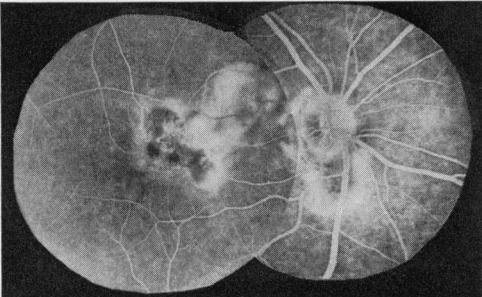
(d) *16 mths after presentation, during the initial transit of dye, showing marginal hyperfluorescence and further extension of lesion*



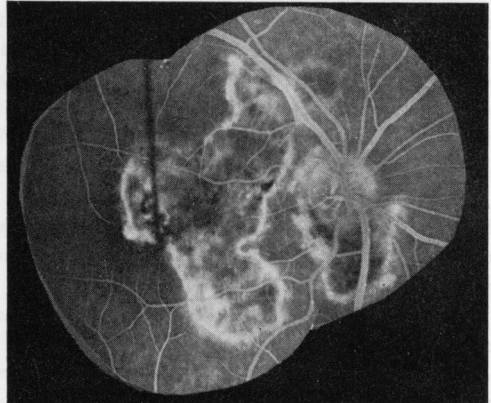
(a)



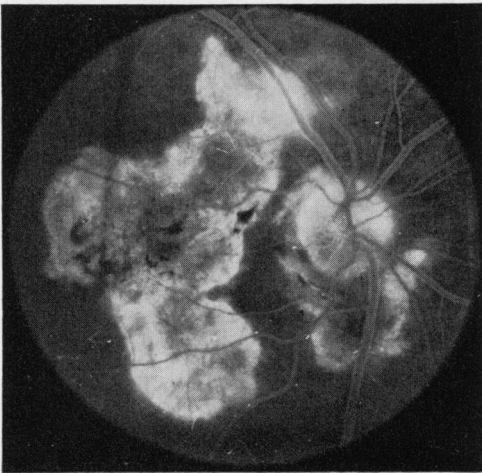
(c)



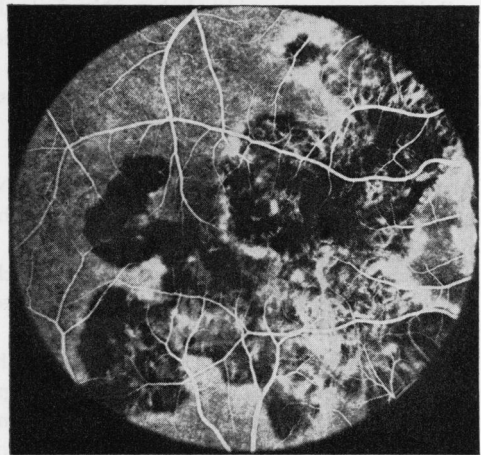
(b)



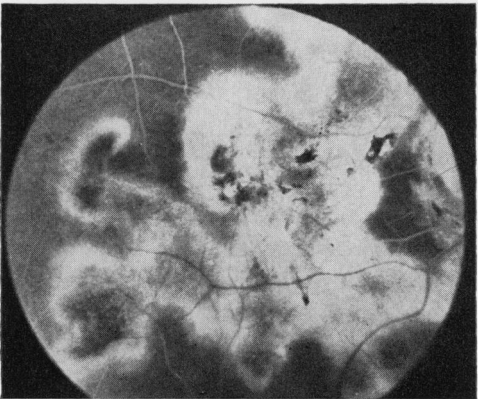
(d)



(e)



(f)



(g)

(e) At 5 min., showing fairly uniform hyperfluorescence of lesion

(f) 2 yrs after presentation, showing exposure of larger choroidal vessels and further extension of lesion during initial transit of dye

(g) At 5 min., showing even hyperfluorescence of entire lesion

Other areas of hyperfluorescence were seen around the optic disc of the right eye, and there were three hyperfluorescent lesions in the left posterior pole (Fig. 6a).

Within 3 weeks the visual activity in the right eye improved to 6/36, but that in the left fell to finger-counting, and fresh pale lesions were seen in the left posterior pole which were confluent with the old scars. The new lesions were centrally hypofluorescent on fluorescein angiography with bright margins (Figs 6b, c). The right fundus was unaltered (Fig. 5c).

By February, 1972, vision had improved to 6/9 in the right eye and 6/12 in the left, and this level of acuity has been maintained despite the appearance of new lesions which the patient noticed by auto-ophthalmoscopy. Fluorescein fundus angiography in January, 1973 (Figs 5d, e and 6d, e), and in January, 1974 (Figs 5e, f and 6e), showed progression of the disease.

A full medical examination revealed no abnormalities and the results of the following tests were within normal limits: haemoglobin, white blood cell count, erythrocyte sedimentation rate, serum calcium, plasma proteins and electrophoresis, serum cholesterol, blood urea, and glucose tolerance test. Serological tests for syphilis (CWR, RPCFT, VDRL) were negative.

The light-induced rise in ocular potential was normal in each eye.

Patient 4, a 50-year-old man, presented in October, 1971, with a history of blurred vision in both eyes. The visual acuity was 6/9 in the right eye and 6/6 in the left. The aqueous and vitreous humours were normal.

There was pigment epithelial atrophy in each fundus and a small patch of pigment epithelial swelling in the left.

One year later, the visual acuity was unaltered but there was progression of the disease process in the left eye. Fluorescein fundus angiography at that time demonstrated disseminated patches of well-defined pigment epithelial atrophy in both eyes (Fig. 7a, b, overleaf).

A full medical examination revealed no abnormalities and the results of the following tests were within normal limits: haemoglobin, white blood cell count, erythrocyte sedimentation rate, serum calcium and cholesterol, plasma proteins and electrophoresis, blood urea and glucose. Serological tests for syphilis (CWR, RPCFT, VDRL) and the toxoplasma dye test were negative.

Patient 5, a 46-year-old man, presented in November, 1971, with a history of blurred vision in the left eye. The visual acuity was 6/5 in the right eye and 6/9 in the left. The aqueous and vitreous humours were normal.

Pigment epithelial changes were seen in each posterior fundus (Figs 8a and 9a, pp. 793, 794).

3 months later the visual acuity in the left eye had improved but there was further extension of the lesions in each eye (Figs 8b and 9b).

After a further 7 months (August, 1972), the visual acuity was 6/5 in each eye, but fluorescein angiography revealed new lesions in both (Figs 8c and 9c).

A full medical examination revealed no abnormalities and the results of the following tests were within normal limits: haemoglobin, white blood cell count, erythrocyte sedimentation rate, and Paul-Bunnell screening test.

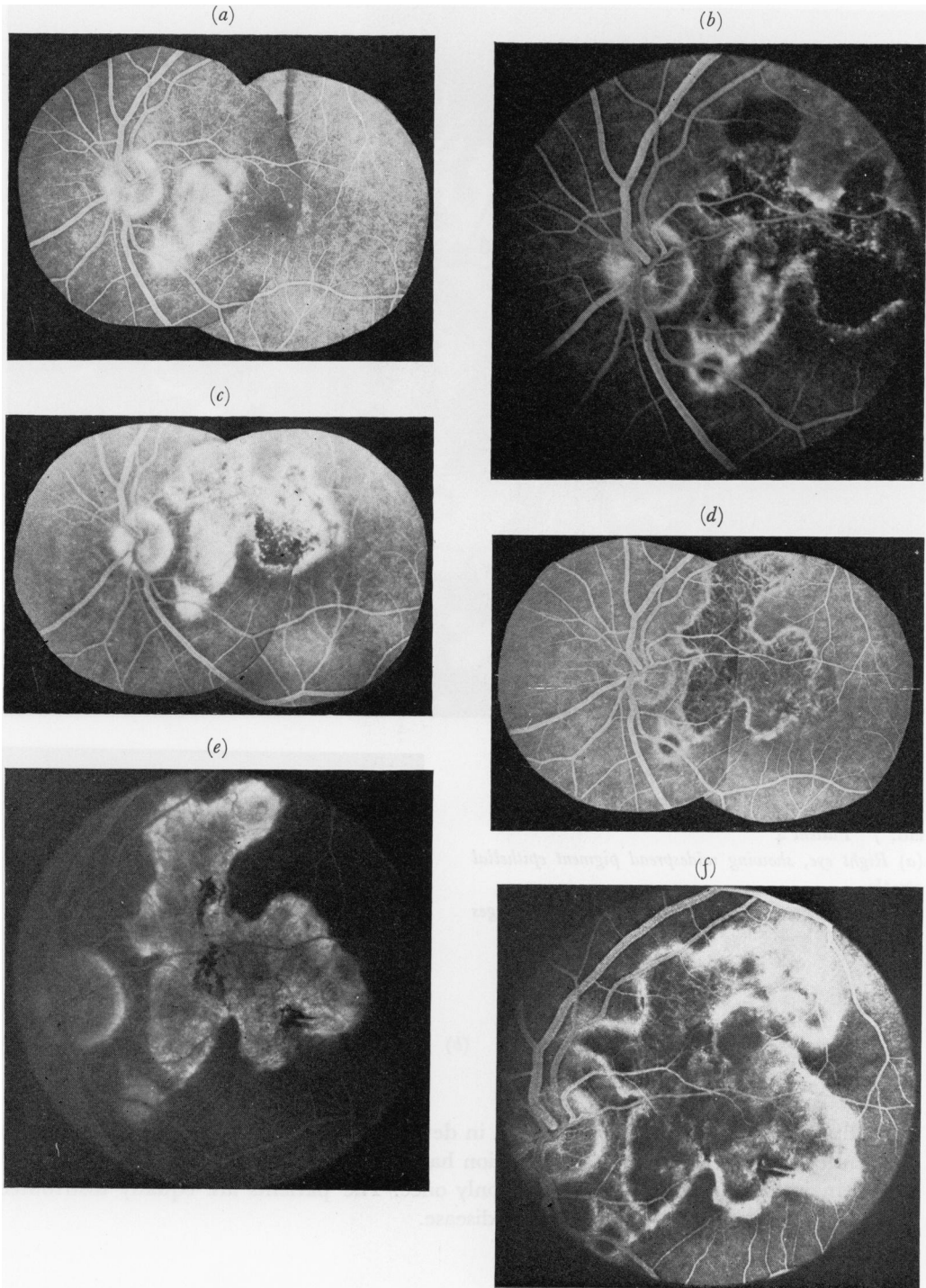
The light-induced rise in ocular potential was subnormal (150 per cent. in each eye) at the time of the last visit.

FIG. 6 *Patient 3, left eye*

(a) *At presentation 5 min. after entry of dye, showing uniform hyperfluorescence of lesions between disc and macula*
 (b) *3 wks after presentation at 3 min., showing fresh lesion with central hypofluorescence and marginal hyperfluorescence*

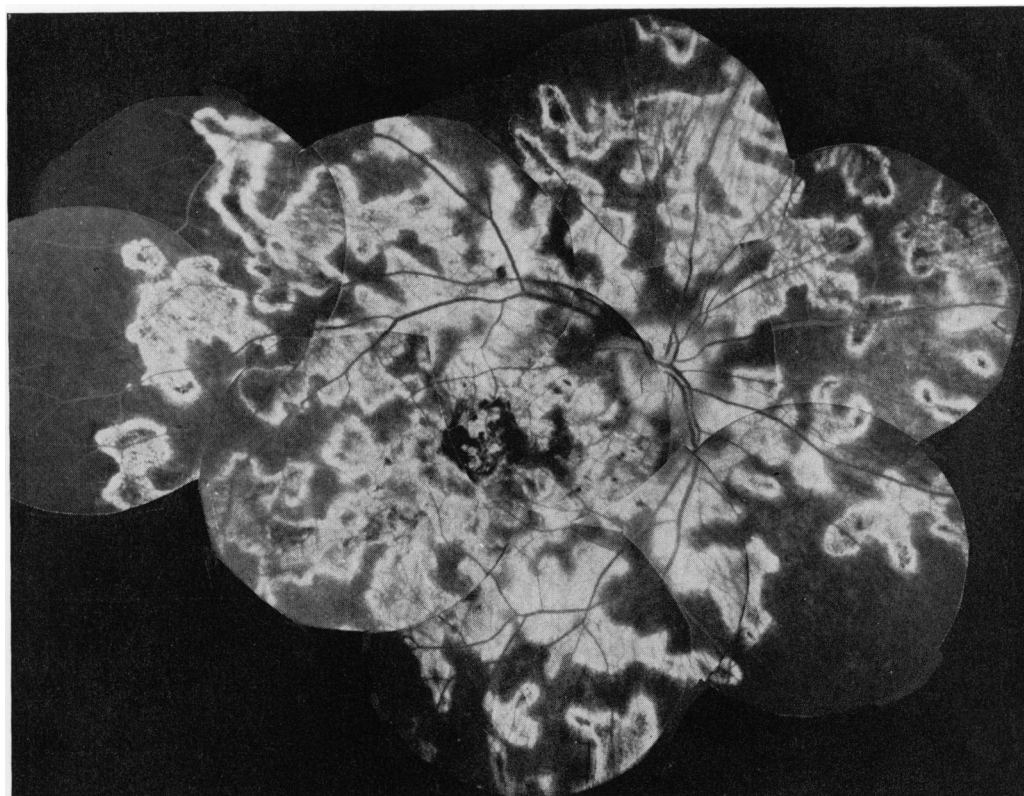
(c) *At 5 min., showing fairly uniform hyperfluorescence*

(d) *16 mths after presentation showing hyperfluorescence of marginal zone and exposure of larger choroidal vessels centrally during initial transit of dye*



(e) At 5 min, showing uniform hyperfluorescence of lesions

(f) 2 yrs after presentation at 5 min., showing marginal hyperfluorescence and further extension of lesion

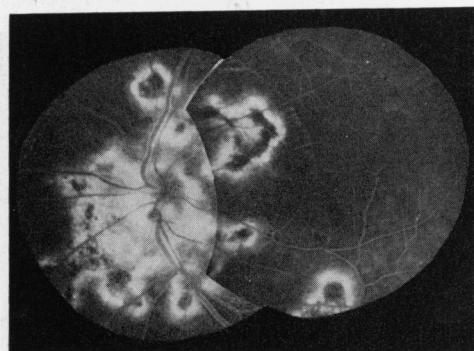


(a)

FIG. 7 Patient 4

(a) Right eye, showing widespread pigment epithelial atrophy

(b) Left eye, showing similar but less extensive changes



(b)

In addition to the five patients presented in detail, fourteen patients have been seen with an identical fundus appearance. Progression has been documented in six cases and eight have remained static or have been seen only once. The patients are equally distributed between the sexes and all have bilateral disease.

Comment

In the patients described the morphological characteristics and evolution of the lesions were identical. The earliest changes consisted of yellowish-grey areas at the level of the pigment

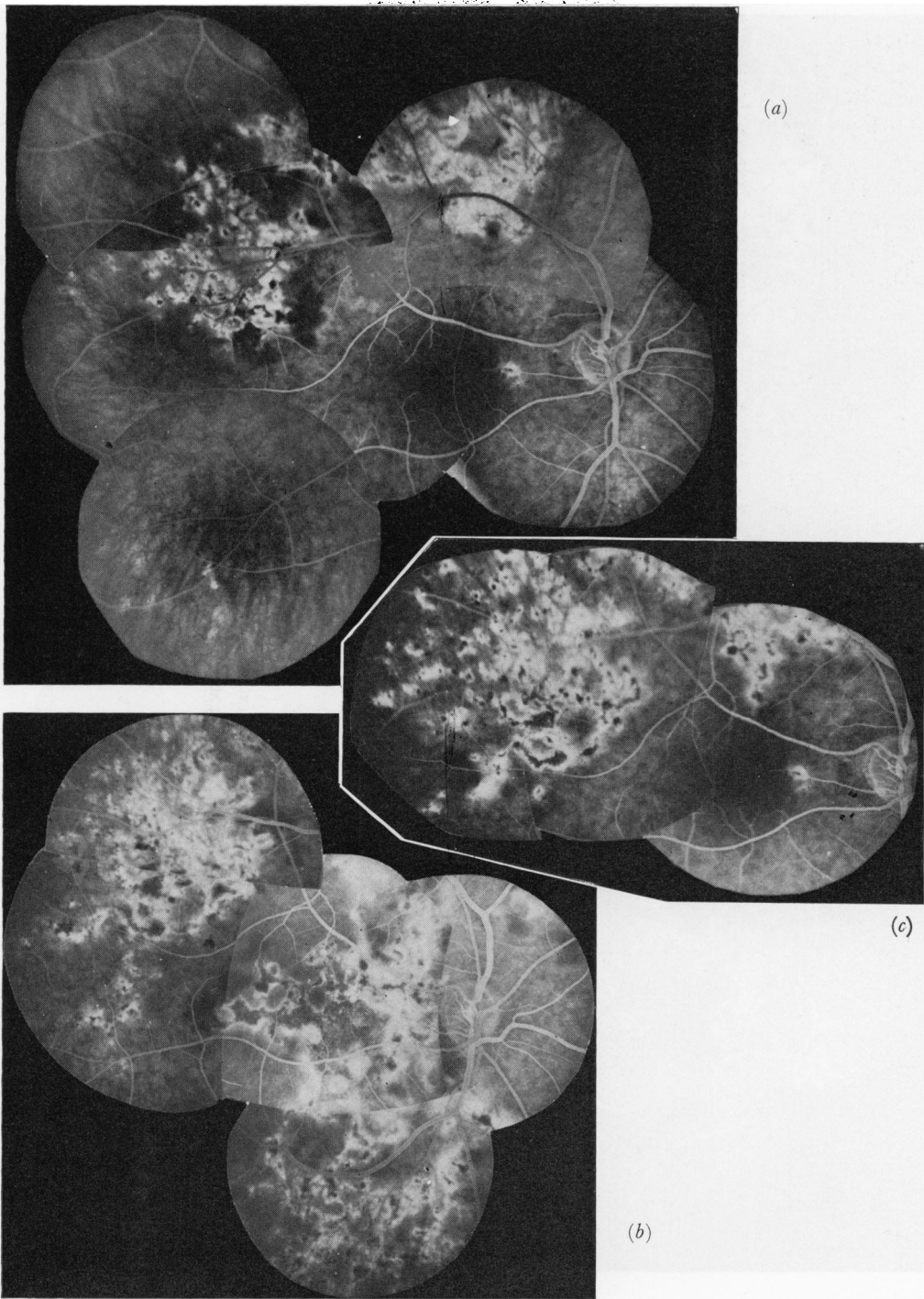
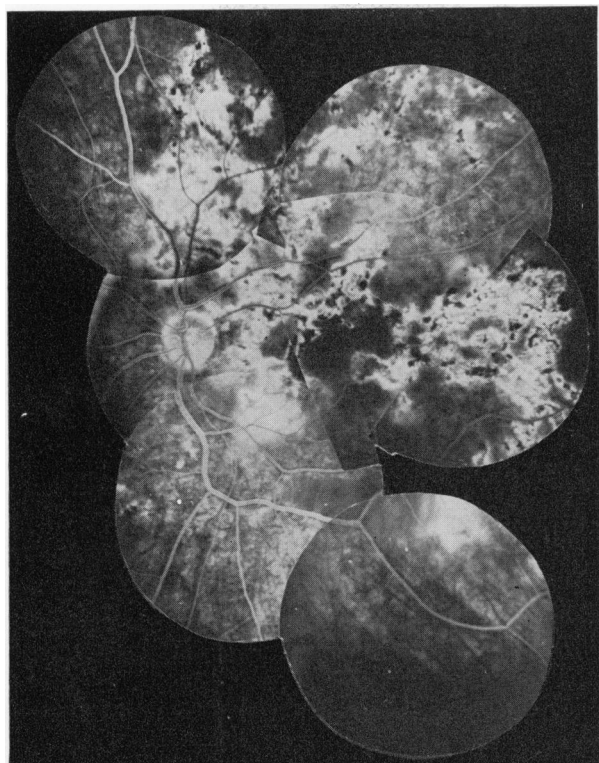
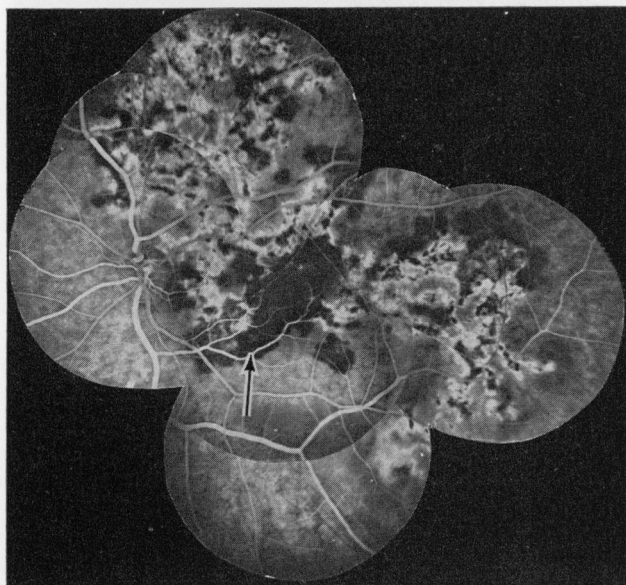


FIG. 8 *Patient 5, right eye*
(a) At presentation.
(b) 3 mths later, showing further extension of lesions
(c) 10 mths after presentation, showing still further extension



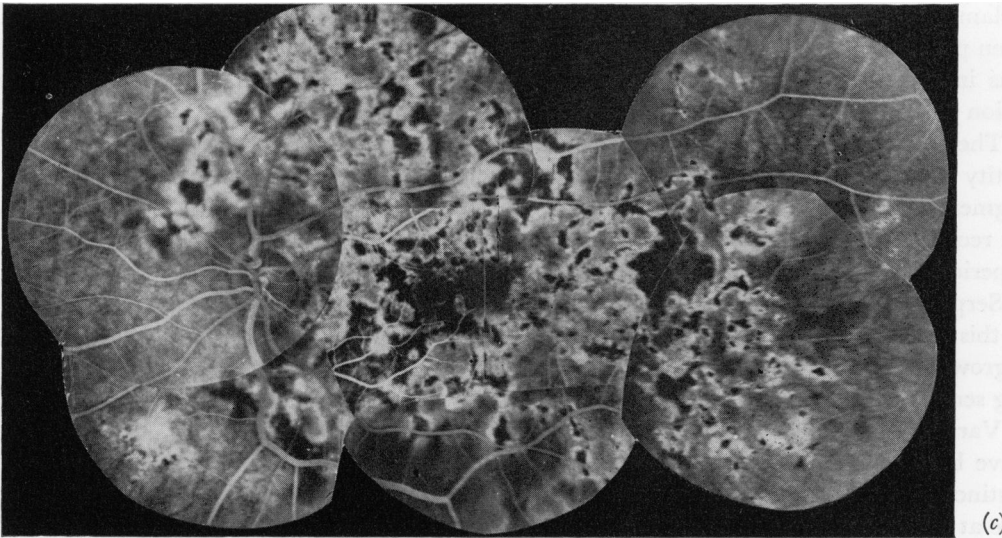
(a)



(b)

FIG. 9 Patient 5, left eye
(a) At presentation
(b) 3 mths later, showing further extension of lesions (arrowed)
(c) (opposite) 10 mths after presentation, showing still further extension

epithelium associated with some swelling of the overlying retina, but no inflammatory cells were seen in the vitreous at the time of examination. Fluorescein angiography revealed relative hypofluorescence corresponding with the grey lesion, during the 2 minutes after initial transit, but at 5 minutes the lesion was indistinguishable from the surrounding fundus.



The earliest lesion had a somewhat irregular poorly-defined outline. Over the next 3 to 4 months pigment epithelial and retinal swelling subsided and the centre of the lesion took on a grey appearance and the margin a lighter colour. Fluorescein angiography at this stage showed a relative hyperfluorescence at the margin of the lesion, whilst the centre of the lesion remained hypofluorescent throughout the study.

After a further 3 to 4 months the lesion had an overall greyish-brown appearance; fluorescein studies showed uniform hyperfluorescence of the lesion and this hyperfluorescence lasted throughout the angiogram.

Old lesions showed atrophy of the pigment epithelium and choriocapillaris revealing the larger choroidal vessels. The margin of the lesion was clearly defined with irregular hyperpigmentation.

The lesions had well-defined borders and each lesion remained the same size and shape during its evolution. The pigment epithelium appeared normal immediately adjacent to the margins of an existing lesion, so that there was a sharp contrast between affected and non-affected areas. It is likely that a number of contiguous cells were affected simultaneously, and that the disease process evolved in the affected cells, without involving the neighbouring tissues. This is in contradistinction to the concept of gradual growth implied in the description of serpiginous choroidopathy (Maumenee, 1968). New lesions frequently but not always appeared to be extensions of older lesions. At no stage was the retina or pigment epithelium detached, and invasion of the subpigment epithelial space by choroidal blood vessels did not occur.

Both eyes were always involved though the disease was often asymmetrical, and in all eyes, however mildly affected, peripapillary lesions were seen.

The overall fundus appearance late in this disease is not clear, since the disease progresses slowly and no patient has been followed for more than 3½ years. If the subsequent course of the disease mirrors the early changes, one might expect a final appearance of well-demarcated atrophy of the pigment epithelium and choriocapillaris occupying the whole of the posterior fundus, such as is seen in the total choroidal sclerosis of the posterior fundus described by Krill and Archer (1971).

General ocular inflammatory changes were not a prominent feature of the disease in that

inflammatory cells were not identified in the vitreous in any patient, though uveitis had been previously recognized in one patient. Visual acuity was affected only when the lesion was immediately beneath the fovea, and in some cases the acuity recovered after the lesion had passed through its acute stage.

The morphological characteristics suggest that these patients were suffering from a disease entity which differs from placoid pigment epitheliopathy as described by Gass (1968) and pigment epitheliitis as described by Krill and Deutman (1972), in that it is characterized by recurrent acute exacerbations over a period of years, and that each lesion evolves over a period of months or years rather than weeks.

Serpiginous choroidopathy (Gass, 1970) has been described as a "creeping" lesion and in this it differs from geographical choroidopathy. Histological studies (Gass, 1970) showed ingrowth into the subpigment epithelial space of choroidal blood vessels, further differentiating serpiginous from geographical choroidopathy.

Various other forms of choroidal and pigment epithelial atrophy at the posterior pole have been described. Gyrate atrophy and central areolar choroidal sclerosis are plainly distinct from geographical choroidopathy, in that the distribution of the lesion and the age at onset are different. However, it is difficult to recognize geographical choroidopathy without identifying the evolution of a single lesion or recognizing different stages of the disease at a single examination. Many examples of widespread pigment epithelial atrophy have been described in the literature and some may represent the end-stage of geographical choroidopathy. In a few cases sufficient information is available to indicate a disease identical to that affecting the patients described here. A patient described by Maumenee (1968) and later by Hyvarinen, Maumenee, George, and Weinstein (1969) certainly has a similar morphology, though the gradual growth of the lesion implied by "leading margin", may be misleading. Case 5 of Krill and Archer (1971) demonstrates well the typical changes and was included with patients with "total choroidal vascular atrophy of the posterior eye-grounds", though we would dispute their conclusion that depression of the ocular electrophysiological responses was in excess of that expected from the apparent structural damage by the disease.

The aetiology of geographical choroidopathy is unknown. None of the patients presented in this paper gave any family history of eye disease and there was no parental consanguinity. Thus there was no indication that this condition is genetically determined.

All patients studied had a normal light-induced rise in ocular potential until there was widespread disease, and this makes it unlikely that there was any generalized metabolic defect of the pigment epithelium.

Absence of inflammatory signs in the vitreous overlying the lesions excludes all but an extremely low-grade inflammatory process, or an infective process which excites only a local inflammatory response. Serological studies in ten patients did not reveal high antibody titres to viruses.

No systemic abnormality has been demonstrated in any patient, and no patient complained of any systemic manifestation before the onset of ocular symptoms.

Because of atrophy late in the disease, it has been suggested that the pathogenesis is related to the primary closure of choroidal blood vessels (Hyvarinen and others, 1969). However, it is likely that the hypofluorescence seen early in the disease is due to blocking of choroidal fluorescence rather than to choroidal capillary closure. In older lesions central hyperfluorescence occurs during the initial transit of dye, indicating integrity of the choriocapillaris. Furthermore, it is difficult to conceive that a lesion due to infarction would show progressive morphological changes over so long a period as one year.

It is important to recognize distinct diseases of the pigment epithelium and chorio-capillaris and we propose that the use of the term 'geographical choroidopathy' be limited to a disease with the specific characteristics described.

Summary

Geographical choroidopathy appears to be a distinct clinical entity in which there are acute, well-defined lesions affecting the pigment epithelium. During the evolution of the lesion, which occurs over several months, there is no change in its shape or size. The disease progresses over several years, and is characterized by the occurrence of further acute lesions. Nineteen patients with this disease entity have been seen at Moorfields Eye Hospital. Five patients are described in detail; the fundus appearances are identical and in each case the disease affected both eyes. The aetiology is unknown.

We should like to thank the consultants at Moorfields Eye Hospital for referring cases to the Retinal Unit. We also express gratitude to Mr. K. Sehmi for the photographs and Miss A. M. Rutter for secretarial assistance.

References

- BROWN, T. H. (1937) *Brit. J. Ophthalm.*, **21**, 645
 FRANCESCHETTI, A. (1962) *Docum. Ophthalm. (Den Haag)*, **16**, 81
 GASS, J. D. M. (1968) *Arch. Ophthalm. (Chicago)*, **80**, 177
 ——— (1970) "Stereoscopic Atlas of Macular Disease. A Fundoscopic and Angiographic Presentation". Mosby, St Louis
 HSIN-HSIANG, C. (1948) *Amer. J. Ophthalm.*, **31**, 1485
 HYVARINEN, L., MAUMENEE, A. E., GEORGE, T., and WEINSTEIN, G. W. (1969) *Ibid.*, **67**, 653
 KRAFFEL, G. (1955) *Klin. Mbl. Augenheilk.*, **127**, 664
 KRIIL, A. E., and ARCHER, D. (1971) *Amer. J. Ophthalm.*, **72**, 562
 ——— and DEUTMAN, A. F. (1972) *Ibid.*, **74**, 193
 MAUMENEE, A. E. (1968) *Trans. ophthalm. Soc. U.K.*, **88**, 529
 RUBINO, A. (1940) *Boll. Oculist.*, **19**, 318
 SORSEY, A. (1939) *Brit. J. Ophthalm.*, **23**, 433
 SVENSSON, K. (1939) *Acta ophthalm. (Kbh)*, **17**, 73
 WEVE, H. (1957) "Modern Problems in Ophthalmology," vol. 1, p. 664. Karger, Basel and New York