

Pigmented paravenous retino-choroidal atrophy

Helicoid retino-choroidal atrophy

IAN A. CHISHOLM AND JOHN DUDGEON

Tennent Institute of Ophthalmology, Western Infirmary, Glasgow

The occurrence of bilateral patchy retino-choroidal atrophy in relation to the retinal venous system has been described as "retino-choroiditis radiata" (Brown, 1937; Hsin-Hsiang, 1948), "chorio-retinitis striata" (Kraffel, 1955), and "pigmented paravenous choroidal atrophy" (Weve, 1957). The reported examples of this curious affection of the fundus all came to light as incidental findings on routine ophthalmoscopy. We wish to record a further example of this condition which was uncovered in the same way.

Case report

A boy aged 13 years was referred when an abnormality of the retina in each eye was noted during examination for a refractive problem. A satisfactory standard of visual acuity was achieved and normal pupillary responses were noted. Ophthalmoscopy revealed the presence of patchy areas of retinal pigment atrophy in relation to the retinal veins, superimposed on a poorly pigmented fundus background. The atrophic areas did not extend closer to the optic disc or macula than three disc diameters. Pigment clumps were present on the vein walls, sufficient in places to obscure the blood column. The choroid in the base of the atrophic areas was also atrophic (Fig. 1, opposite). An area of peripapillary atrophy was present at the upper edge of the right optic disc.

Some constriction of the visual field was found on kinetic perimetry, and a marked loss of retinal sensitivity was found commencing at 30° from fixation on quantitative perimetry. Colour discrimination examination by the Farnsworth Munsell One Hundred Hue Test, while revealing no recognizable hue discrimination loss pattern, showed a gross error score at the upper limit of normality for a patient of this age. Serum vitamin A and carotene concentrations were within normal limits (Vitamin A 66 µg./100 ml.; carotene 40 µg./100 ml.). Electro-oculography gave a borderline result with light maximum/dark minimum ratios of 165 per cent. in both eyes and electro-retinography also gave a normal result although the 5-minute dark-adapted b-wave amplitude was reduced to 250 µV. Repeat electro-oculography 4 months later gave a normal result with a light maximum/dark minimum ratio of 200 per cent.

The patient had been a healthy child and, apart from a measles infection at the age of 3 years, there was no significant past history. There was no familial ocular disease and the fundi of the parents and other siblings were normal.

Fluorescein angiography revealed the presence of large geographical areas of partial atrophy, and scattered smaller areas of complete atrophy of the retinal pigment epithelium. The areas of complete atrophy lay in close relation to the retinal venous system and exposed the underlying choroidal blood vessels. Some delay occurred in the filling of the retinal veins which suggested that there was a "capillary free" zone corresponding to the areas of complete atrophy. Normal "choroidal show"




FIG. 1 Composite retinal photographs of right and left fundi

was present in the base of the atrophic areas. The retinal veins showed patchy obliteration of the fluorescing blood column corresponding to pigmentary deposits in the vessel wall. At no time during the dye transit was dye leakage visible into the retina (Fig. 2, overleaf).

Discussion

The occurrence of bilateral patchy retino-choroidal atrophy in relation to the retinal venous system has been described by various authors, who have attempted to ascribe the condition to a specific cause (Table).

Table *Aetiology suggested by various authors*

<i>Author</i>	<i>Year</i>	<i>Patient's age</i>	<i>Central vision</i>	<i>Presumed aetiology</i>
Brown	1937	47	Good	Inflammatory—tuberculosis
Hsin-Hsiang	1948	36	Good	Inflammatory—syphilis
Brogno	1949	16	Good	Congenital dysgenesis
Weve	1957	25	Good	Degenerative
Present patient	1972	13	Good	?Dysgenesis ?post-inflammatory

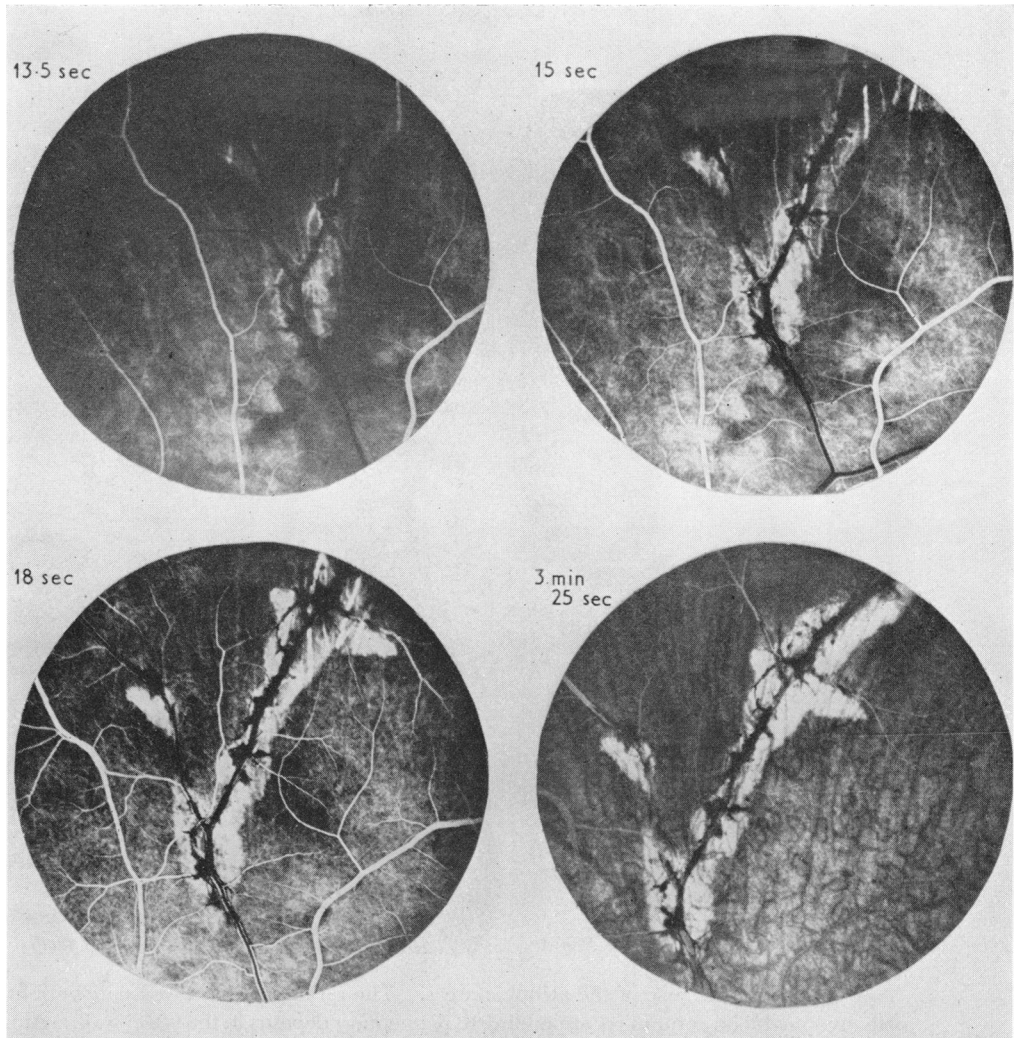


FIG. 2 *Serial fluorescein angiography of area in upper left fundus. Photographs at 13.5, 15, and 18 sec., and 3 min. 25 sec. after dye injection*

Typically, the areas of retino-choroidal atrophy extend half to one disc diameter on either side of the vein, follow its course, and branch when the vein does (Brown, 1937). Pigment aggregations collect in the vein wall, causing areas of patchy sheathing and pigmentary muffs. A variable amount of peripapillary choroidal atrophy may be present; the atrophic areas then radiate from the disc but do not extend to involve the macula.

Franceschetti (1962) felt that the published accounts by Brown (1937) and Hsin-Hsiang (1948) suggested that the pathological process in the condition was primary rather than secondary to an inflammatory periphlebitis-like affection. Brognoli (1949) felt that his patient was an example of a congenital dysgenesis of the pigment epithelium. This congenital aetiology was supported by the reports of Morgan (1948) and Law (1948), who described patients showing atypical pigment aggregations in relation to the retinal venous system. Bucklers (1942), however, described a patient with a fundus appearance indis-

tinguishable from that of pigmentary paravenous retino-choroidal atrophy, which he reported as pseudoretinitis pigmentosa following measles.

The recent paper of Amalric and Schum (1968) highlighted the findings on fluorescence angiography. Although we confirm their findings of retinal pigment atrophy and choroidal atrophy accompanied by a disturbance in the electrophysiological readings, the clinical appearance of our patient differs. He fulfils the criteria of pigmented paravenous-retino-choroidal atrophy as described by Weve (1957). The condition is bilateral and symmetrical with retention of good central visual acuity. The absence of inflammatory signs, both locally in the retina and in the eye generally, help to confirm that this condition is the result of a dysgenesis of the retinal pigment epithelium.

We are grateful to Dr. T. Wilson, Ophthalmologist, Stirling, for referring the patient to us for investigation and for allowing us to publish the clinical details, and to Dr. J. Wallace for performing the fluorescein angiographic study. The illustrations are the work of Mr. J. Watt and Mrs. A. Currie. We are grateful to Prof. W. S. Foulds for permission to use the facilities of the Tennent Institute of Ophthalmology.

References

- AMALRIC, P., and SCHUM, U. (1968) *Klin. Mbl. Augenheilk.*, **153**, 770
BROWN, T. H. (1937) *Brit. J. Ophthalm.*, **21**, 645
BROGNOLI, C. (1949) *Arch. Ottal.*, **53**, 99
BUCKLERS, M. (1942) *Klin. Mbl. Augenheilk.*, **108**, 380
HSIN-HSIANG, C. (1948) *Amer. J. Ophthalm.*, **31**, 1485
FRANCESCHETTI, A. (1962) *Docum. Ophthalm. (Den Haag)*, **16**, 81
KRAFFEL, G. (1955) *Klin. Mbl. Augenheilk.*, **127**, 664
LAW, F. (1948) *Proc. roy. Soc. Med.*, **41**, 726
MORGAN, O. G. (1948) *Ibid.*, **41**, 727
WEVE, H. (1957) *Mod. Probl. Ophthalm.*, **1**, 664. (Bibliotheca ophthalmologica, Fasc. 47)