

Communications

Hereditary crystalline stromal dystrophy of Schnyder

I. Clinical features of a family with hyperlipoproteinaemia

A. J. BRON,* H. P. WILLIAMS,† AND M. E. CARRUTHERS‡

From the Departments of Clinical Ophthalmology and Pathology, Institute of Ophthalmology, University of London, and Moorfields Eye Hospital, City Road, London

An interest in the possibility of a systemic lipid disturbance in Schnyder's corneal dystrophy stems from the work of Bonnet, Paufique, and Bonamour (1934), who first suggested that the needle-shaped corneal deposits in this condition consisted of cholesterol. The present study is of great interest since it describes a family in which Schnyder's central crystalline stromal dystrophy coexisted with an inherited disorder of the plasma lipoproteins. The significance of this association is discussed in detail.

Case reports

STANLEY C. (II-3)

The proband, a 47-year-old white male labourer, presented at Moorfields Eye Hospital in October, 1969, complaining of deteriorating vision in each eye over the past 10 years. Vision had been poor since childhood and a diagnosis of congenital corneal disease had been made at a previous attendance 21 years earlier. Apart from a history of "back strain" 4 years previously, there were no relevant medical complaints.

Ocular examination

The visual acuity was 6/24 in each eye uncorrected, improving to 6/18 with a pin hole. Near vision was N.10 with a correction. There were no periocular xanthelasmata. A left divergent squint of 5-10° was present, but ocular movements were full. The globes were white and pupil responses were normal. Each cornea showed a macroscopically visible greyish central opacity and dense arcus lipoides (Fig. 1, overleaf). Axially the corneal reflex and sensitivity were slightly diminished.

Biomicroscopy

The corneal features were essentially the same in each eye. Axial thickness was recorded as 0.64 mm. on the right and 0.65 mm. on the left (Goldmann pachometer). This is thicker than the normal value of 0.52 mm. (Maurice, 1969), but the generalized corneal haze made these estimations difficult. Immediately deep to the epithelium and extending into the anterior third of the stroma was a generalized opacification composed of numerous minute needle-like crystals and greyish-white whorl-shaped opacities, which were polychromatic in focal illumination (Fig. 2, overleaf).

Received for publication July 26, 1971

Reprint requests to: A. J. Bron, F.R.C.S., Institute of Ophthalmology, Judd Street, London WC1H 9QS

*Department of Clinical Ophthalmology, Institute of Ophthalmology

†Moorfields Eye Hospital, City Road, London EC1V 2PD

‡Department of Pathology, Institute of Ophthalmology

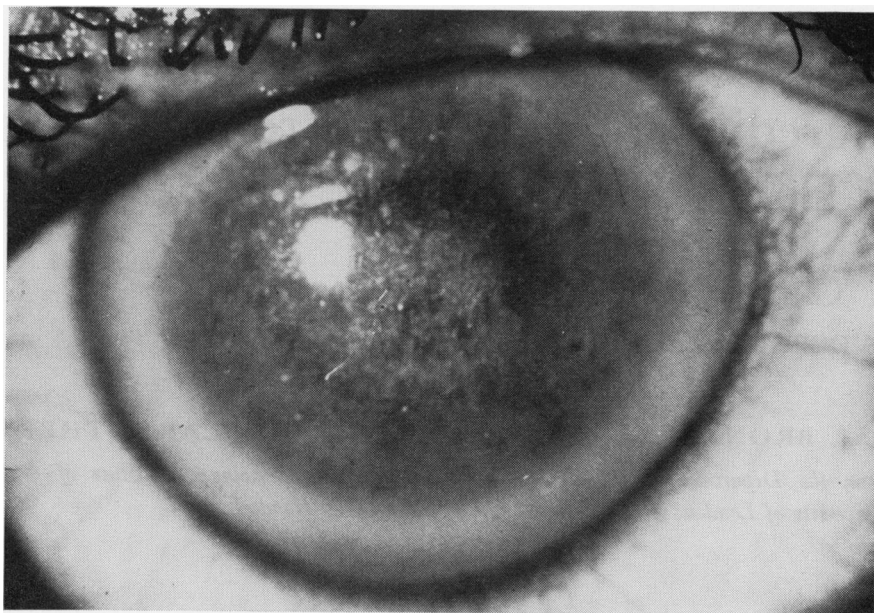


FIG. 1 Patient S.C. (II-3). Survey picture to show right cornea

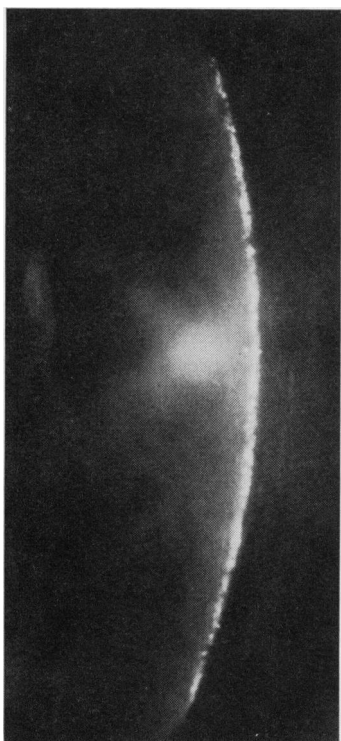


FIG. 2 Patient S.C. (II-3). Slit-lamp view of right cornea. The crystals are aggregated in the anterior stroma. There is a suggestion of haze in the posterior stroma

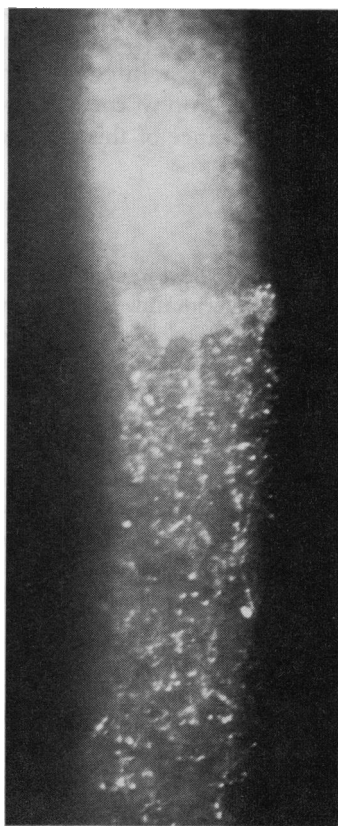


FIG. 3 Patient S.C. (II-3). Slit-lamp view to show junction of crystalline stromal disc and arcus lipoides of right upper cornea in the 12 o'clock meridian. The crystal garland at this junction has a smooth outer and a scalloped inner margin

These crystals were most densely packed centrally, giving the appearance of almost circular white discoid lesions, the vertical and horizontal diameters of which were 8.5×7.0 mm. in the right eye and 8.4×6.8 mm. in the left eye respectively. The crystals were densely aggregated at the margin of each disc and here they were aligned radially in a palisade fashion (Fig. 3). The inner border of this zone was minutely scalloped. The stroma posterior to the crystalline changes was not normal, but showed a faint milky opalescent haze.

A dense arcus lipoides, measuring between 1.0 and 1.4 mm. in width, encircled the crystalline dystrophy and was contiguous with its outer edge. The arcus extended through the whole corneal thickness but appeared less dense in the midstromal zone. A double arcus was present above.

Surrounding the arcus was a relatively clear rim approximately 0.2 mm. wide of corneal tissue which separated it from the limbus. Changes in Vogt's limbus girdle were present nasally and temporally.

The epithelium was normal and did not stain and the endothelium appeared normal although the view was partly obscured by the corneal opacity.

No corneal vascularization was seen microscopically and none was demonstrated by fluorescein angiography. The anterior chambers were deep and showed no signs of previous intraocular disease. The lenses and irides were normal. The intraocular pressures were 15 mm.Hg (applanation) in each eye.

At a later examination the patient was found to exhibit a distinct lipaemia of the limbal capillaries which was well seen in the lucid interval outside the arcus lipoides, against the background of a brown iris. A lipaemia of the vessels of the globe was less easily demonstrated. The details of these findings have been reported elsewhere (Bron and Williams, 1972).

General medical examination

The patient weighed 77 kg. No systemic abnormalities were found and in particular there was no hepato-splenomegaly and no arthropathy. An electrocardiogram was within normal limits. Examination by Dr. P. Borrie, however, revealed the presence of a solitary eruptive xanthoma on the right forearm. The lesion was biopsied and sent for histological examination.

Haematological and biochemical investigations

A full blood count, erythrocyte sedimentation rate, and blood film examination were normal. Laboratory tests for syphilis (W.R., R.P.C.F.T., C.W.R., and V.D.R.L.) were negative and the blood urea was normal. The uric acid level was 5.9 mg. per cent. Fasting blood sugars, recorded on three occasions, were 120, 118, and 106 mg./100 ml. A glucose tolerance test on June 2, 1970, showed mild intolerance. When the patient's blood was allowed to stand, the serum separated as an opaque milk-white layer and it was evident from this gross appearance that the patient must have a markedly elevated serum triglyceride. This was confirmed on blood lipid analysis, which demonstrated a complex dyslipoproteinaemia. The details of these lipid findings and those of the patient's three sisters are reported below (Tables I-IV, pp. 390-392).

Urine analyses for glucose, keto-acids, cystine, homocystine, excess amino acids, mucopolysaccharides, calcium, and copper, and for Bence Jones protein were all negative. A trace of protein was present.

Radiological studies

Moderate degenerative changes were seen in the right wrist. An oral cholecystogram was normal. The mid-dorsal spine showed severe degenerative changes, considerable anterior wedging of the vertebral bodies, and consequent kyphosis. There was no evidence of osteochondrodystrophy.

Treatment

On July 7, 1970, a left 7-mm. lamellar keratoplasty was performed by one of us (H.P.W.) and the excised disc was sent for histological examination. Postoperative progress was uneventful. Sutures were removed after one month and topical steroids were used in decreasing dosage for 4 months and then stopped. The donor corneal disc remained clear and the previously noted stromal haze of the host was clearly seen to extend to Descemet's membrane.

Postoperative fundus examination permitted details to be seen. Lipaemia retinalis was present but otherwise no gross abnormality was found.

Treatment for the dyslipoproteinaemia was begun in September, 1970, with a 1,500 calorie diet low in carbohydrate and high in polyunsaturated fatty acids. In addition to this, the patient received clofibrate 2 g. daily. On this regime he lost 11 kg. in 2 months and there was a marked fall in both the triglyceride and cholesterol levels in the blood (Table I). Subsequently the carbohydrate content of the diet was increased as the patient had difficulty in keeping to the original diet.

At the time of writing, after 7 months' treatment, there has been no change in the appearance of the right corneal dystrophy. Furthermore, in the left cornea, fine polychromatic crystals have appeared peripherally in the bed of the graft and also along many of the suture-track scars. The appearances of the host cornea have remained unaltered.

Follow-up

In May, 1971, the corrected visual acuity in each eye was 6/18. Delleman and Winkelman (1968) have remarked on the poorer results of lamellar keratoplasty in this condition. The degree of opacity in the posterior stroma of the host cornea of the left eye was greater than expected and must have contributed to the poor visual result. The possibility that the left eye is amblyopic must also be considered since a small-angle squint was present pre-operatively. A contact lens trial was abandoned because of intolerance.

Histopathological report

- (a) Corneal disc: The salient features were an absence of Bowman's membrane, infiltration of the anterior stromal layers with cholesterol crystals, and the stromal deposition of neutral fat and non-crystalline cholesterol. Details are reported in the following paper by Garner and Tripathi (1972).
- (b) Eruptive xanthoma (Dept. of Pathology, St Bartholomew's Hospital, London): Paraffin sections showed a focal collection of pale histiocytes and fibroblasts. Frozen sections, stained for fat, showed a dense accumulation of finely dispersed lipid droplets in the centre of the lesion. With polarized light this appeared to be almost entirely neutral fat. Minute fat droplets were present even in the basal layers of the epidermis.

In view of the findings in this patient and the known hereditary nature of the corneal dystrophy, the three sisters of the proband were invited to attend hospital for examination in July, 1970. The pedigree of this family is shown in Fig. 4.

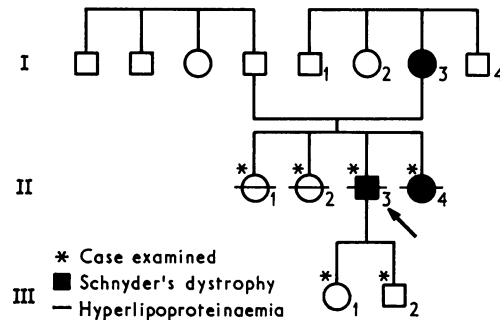


FIG. 4 Pedigree of Family C

AUDREY C. (II-4)

This 45-year-old woman complained of life-long poor vision in each eye, slightly more pronounced in the left. There had been no apparent change over the past 20 years. She received glasses at the age of 9 years and a left divergent squint was noted at the age of 19 years. At this time both corneae were reported as showing innumerable subepithelial crystals centrally. The right visual acuity was recorded as 6/12 unaided; that of the left eye was not recorded.

Past medical history

Birth was premature and at the age of 2 years a spastic diplegia was diagnosed. The patient subsequently underwent multiple orthopaedic procedures. She exhibited a marked kyphosis in adult life.

Ocular examination

The uncorrected visual acuity was 6/18 in each eye and could not be improved. Near vision was N.6 corrected. No periocular xanthelasmata were noted. A left divergent squint of 35° was present. Adduction of each eye was slightly limited. The globes were white and exhibited obvious bilateral greyish central corneal opacities without vascularization. Pupil responses were normal and the anterior chambers were deep and clear. The lens and vitreous were clear in each eye and the fundi were normal. Observation on a number of occasions showed no lipaemia retinalis. The intraocular pressures were 15 mm.Hg in the right eye and 18 mm.Hg in the left. The visual fields were full to confrontation.

Biomicroscopic examination

The bulbar conjunctiva was normal in each eye apart from small fusiform and saccular dilatations shown by some of the paralimbal vessels. No lipaemia was visible in the limbal capillary arcades.

The changes found in each cornea were similar (Fig. 5). Corneal sensation and reflex response were diminished but the epithelium appeared normal and did not stain.

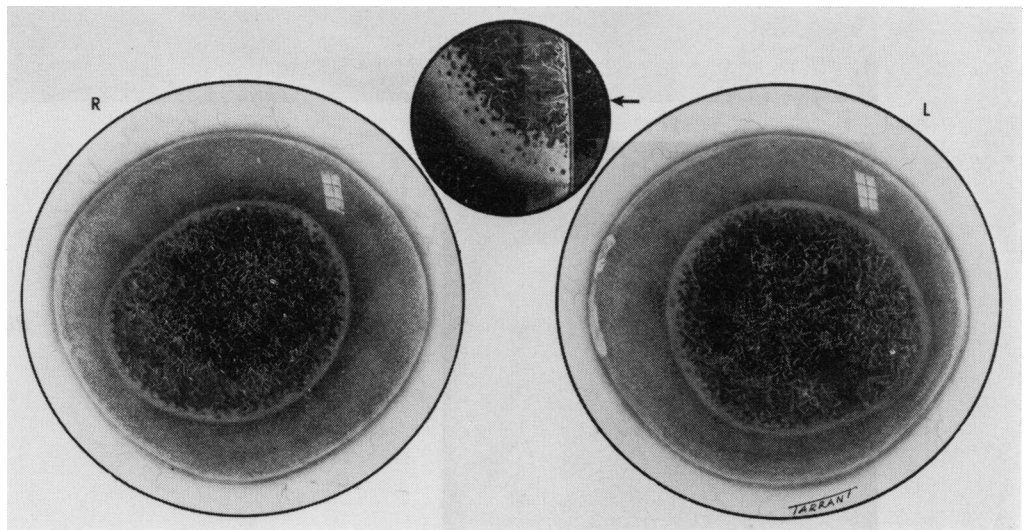


FIG. 5 Patient A.C. (II-4). Drawing to show right and left corneae

The stroma, as in the case of Stanley C., had a faint milky haze which was denser in the subepithelial zone. A dense, roughly circular, greyish-white opacity was present in the immediately subepithelial layers of the stroma and occupied the anterior quarter of its thickness. In its widest vertical and horizontal dimensions it measured 6.8 × 7.0 mm. in the right eye and 6.0 × 6.5 mm. in the left. The opacity was made up of an irregular feltwork of tiny polychromatic needle-like crystals when viewed in diffuse and focal illumination (Fig. 6, overleaf). The crystals were finer but more densely assembled at the periphery of the opacity, where they appeared to be aligned in a more or less radial fashion (Fig. 7, overleaf). The inner border of the denser peripheral band of crystals was scalloped, and the outer border was sharply demarcated.

A moderately dense arcus approximately 0.3 mm. wide ran circumferentially within the limbus but was separated from it by a clear interval of 0.2–0.4 mm. Situated superficially in this arcus were bilateral nasal and temporal white limbus girdles of Vogt.

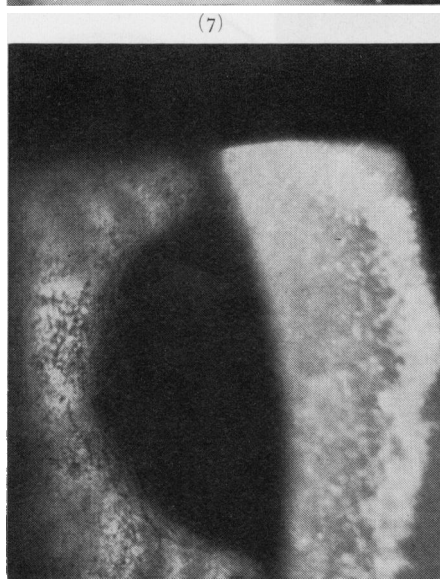
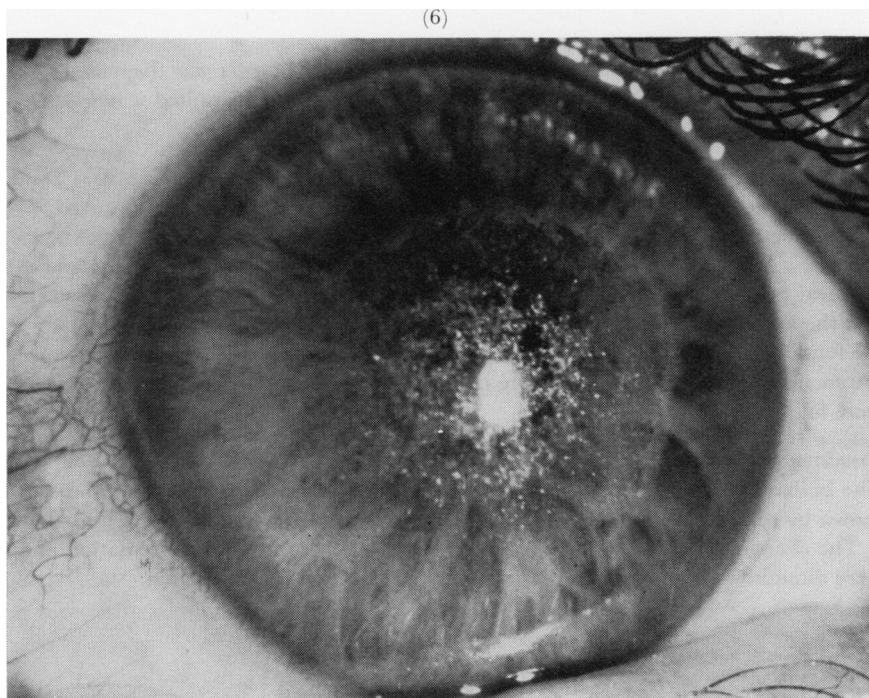

FIG. 6 Patient A.C. (II-4). Right cornea seen in diffuse illumination

FIG. 7 Patient A.C. (II-4). Right cornea. Focal illumination in the broad slit beam

The stroma between the arcus and central opacity showed a slight milky opalescence throughout its thickness and Descemet's membrane and the endothelium appeared normal.

General medical examination

The patient was a slightly obese, intelligent female with some dysarthria. There was a kyphoscoliosis and spastic wasting of the lower limbs with muscular hypertrophy of the shoulders and arms. No evidence of xanthomatosis was found. Minimal evidence of myocardial ischaemia was indicated by S-T segment and T wave changes. The blood pressure was 154/100.

Radiological studies

Apart from a dorsal kyphoscoliosis, minor osteoarthritic changes were found in the hands and left ankle.

Lipoprotein analysis

Fasting serum showed marked elevation of the triglyceride, cholesterol, and phospholipid levels. The details are discussed below (Table II).

HILDA C. (II-2)

Ophthalmic examination of the second sister of Stanley C., who was aged 54, revealed normal visual acuities with correction of low myopia. Bilateral nasal and temporal limbus girdles of Vogt were present. No other corneal or ocular abnormality was found.

Past medical history

In March, 1969, she was investigated for the symptoms of intermittent claudication. A random blood sugar level of 170 mg./100 ml. and a cholesterol level of 350 mg./100 ml. were recorded at this time. No further lipid studies were done. After an aortogram she underwent an aorticoiliac dacron graft. During her stay in hospital glycosuria and a fasting blood sugar of 160 mg./100 ml. were found and a glucose tolerance test showed a diabetic curve. Dietary treatment was begun with no specific restrictions on fat or protein. She has since remained well.

General medical examination

Nothing abnormal was found. An electrocardiogram was normal and there were no xanthomata.

Radiological studies

Minor osteoarthritic changes were present in hands and feet.

Biochemical investigation

The blood urea and electrolyte levels were normal, as was a full blood count and film (March, 1969).

Blood lipid analysis

This revealed normal phospholipid and triglyceride levels, but raised cholesterol. Detailed lipid studies are reported below (Table III).

MABEL C. (II-1)

This 56-year-old woman is the eldest sister of the proband. There were no symptoms and her vision was normal with correction of hypermetropic astigmatism. There were bilateral nasal Vogt's white limbus girdles. No other corneal pathology was found and the eyes were otherwise normal.

Past medical history

No illness relevant to this report.

General medical examination

No xanthomata were found, but there was evidence of minimal myocardial ischaemia on the electrocardiogram.

Radiological studies

Minimal osteoarthritic changes were present in the hands and ankles in addition to minor lumbar spinal degenerative changes.

Blood lipid analysis

Marked elevation of fasting serum triglyceride, cholesterol, and phospholipid levels was found. The details are reported below (Table IV).

JANICE C. (III-1) and MARTIN C. (III-2)

These are the 19-year-old daughter and 15-year-old son of the proband. No ocular abnormality was found in either patient and their fasting serum lipoprotein analyses were normal (Table V).

MABEL BEATRICE C. (I-3)

This patient was the mother of the proband. In July, 1953, when she was 70 years old, she was first seen at the North Middlesex Hospital, complaining of diminished vision in both eyes; the visual acuity was 6/60 in each eye. She was described as having "bilateral epithelial dystrophy" but no drawing was made. In November, 1953, she was admitted for a left 5 mm. penetrating graft, but the operation was complicated by lens opacification and swelling and the end-result was a leucoma adherens and corneal vascularization. When seen finally, in 1967, it was noticed by a new observer that the patient had a "crystalline degeneration of the cornea".

She was not seen again by an ophthalmologist and died at the age of 86 years. We may reasonably assume that this patient had a bilateral superficial corneal dystrophy of a crystalline appearance.

Blood lipid analyses

Blood lipid analyses were made on the proband, his three siblings, and his two children by Dr. J. Slack in the M.R.C. Clinical Genetics Unit, Institute of Child Health (Tables I-V).

Blood was taken after at least 12 hours fasting. Except where stated, no modification of normal diet was made. Expected lipid values are expressed in mg./100 ml. as the mean plus or minus the standard deviation, quoted for the age and sex of the patient (Nevin and Slack, 1968).

STANLEY C.

An initial fasting serum cholesterol of 700 mg./100 ml. was found and the serum was lipaemic. The following are the results of subsequent lipid analyses:

Table 1 (a)

<i>Lipid (mg./100 ml.)</i>	<i>Expected level</i>	<i>July, 1970</i>	<i>August, 1970</i>
Cholesterol	223 ± 53	852	760
Triglyceride	106 ± 59	6400	5240
Phospholipid	—	965	680

Both cholesterol and triglyceride levels were found to be grossly raised (Table Ia). Significant findings on electrophoresis of serum in July, 1970, were the presence of chylomicrons and of a dense and broad beta band extending well into the pre-beta zone. After ultracentrifugation, a lipoprotein of beta mobility was identified in the very low density lipoprotein (V.L.D.L.) fraction on agarose gel electrophoresis (Noble, Hatch, Mazrimas, Lindgren, Jensen, and Adamson, 1969). In normal serum this fraction contains chylomicrons and pre-beta lipoprotein only. The presence of a "floating beta" is characteristic of Type II hyperlipoproteinaemia (Fredrickson, Levy, and Lees, 1967). The patient also showed a gross chylomicronaemia which possibly accounts for his eruptive xanthoma containing neutral fat.

After diet and clofibrate therapy starting in September, 1970, further lipid levels were obtained (Table Ib), and it was observed that the initial response of the cholesterol and triglyceride levels to diet was not maintained.

Table I (b)

<i>Lipid (mg./100 ml.)</i>	<i>November, 1970</i>	<i>May, 1971</i>
Cholesterol	302	400
Triglyceride	719	1295

AUDREY C.

Table II

<i>Lipid (mg./100 ml.)</i>	<i>Expected level</i>	<i>July, 1970</i>	<i>October, 1970</i>
Cholesterol	229 ± 43	368	399
Triglyceride	75 ± 30	288	207
Phospholipid		346	

Both cholesterol and triglyceride levels were raised above the upper limit of normal (Table II). Electrophoresis in July, 1970, showed a broad beta band which extended well into the pre-beta zone. The V.L.D.L. fraction contained a lipoprotein of intermediate mobility between the beta and pre-beta lipoproteins. For this reason it was not possible to classify the lipoprotein disorder with certainty as either Type III or IV.

HILDA C.

Table III

<i>Lipid (mg./100 ml.)</i>	<i>Expected level</i>	<i>July, 1970</i>	<i>October, 1970</i>
Cholesterol	235 ± 43	332	348
Triglyceride	82 ± 30	94	193
Phospholipid		230	—

Table III shows that the cholesterol level was raised on two occasions and the triglyceride level on one occasion. In July, 1970, the electrophoretic pattern was normal, but in October, 1970, a broad beta band was present and a lipoprotein of mobility intermediate between beta and pre-beta was present in the V.L.D.L. fraction. Since this patient was on a long term diabetic diet over the period of examination, it is not possible to come to any firm conclusion about the nature of her blood lipid disorder though it is likely that a hyperlipoproteinaemia is present and partly controlled by diet. In view of the advanced nature of her vascular disease it was thought unwise to suggest a period without dietary restriction as a means of establishing the nature of her hyperlipoproteinaemia.

MABEL C.

Table IV

<i>Lipid (mg./100 ml.)</i>	<i>Expected level</i>	<i>July, 1970</i>	<i>October, 1970</i>
Cholesterol	245 ± 43	294	240
Triglyceride	84 ± 30	435	316
Phospholipid		313	

The cholesterol level in July, 1970, was 49 mg./100 ml. above the mean for the patient's age and sex. This is only just above the upper limit of normal. On the other hand, the triglyceride levels were markedly raised on two occasions (Table IV). Electrophoresis in July, 1970, showed chylomicrons

to be present, a normal beta band and a distinct increase in the pre-beta band. This finding and the analysis of the V.L.D.L. fraction were in keeping with a Type IV hyperlipoproteinaemia.

JANICE C. and MARTIN C.

Both children of the proband were found to have normal blood lipid levels and electrophoretic patterns (Table V).

Table V

<i>Lipid (mg./100 ml.)</i>	<i>Janice</i>	<i>Martin</i>
Cholesterol	217	170
Triglyceride	70	37
Phospholipid	154	139

Discussion

Central stromal crystalline corneal dystrophy was first described by van Went and Wibaut (1924) and later by Schnyder (1927, 1929, 1939). Before considering a possible relationship between hyperlipoproteinaemia and the dystrophy, the features of the corneal disorder will be discussed.

Schnyder's corneal dystrophy is inherited as an autosomal dominant disorder. It is bilateral and usually symmetrical. Onset is in early life, but a congenital onset has yet to be established. The chief feature of the disorder is a round or oval, discoid, or ring-shaped central opacity made up predominantly of fine needle-shaped polychromatic crystals (Waardenburg, Franceschetti, and Klein 1961, Franceschetti and Forni, 1951). This opacity occupies the anterior portion of the stroma including Bowman's layer, and although deeper, pre-Descemet deposits have been observed (von Hippel, 1929). The epithelium is normal and in most descriptions the stroma outside the crystalline lesion is clear. However, Luxenberg (1967) mentions the occurrence of small white punctate opacities scattered throughout the stroma. The cornea is not vascularized.

The lesion may be visible to the naked eye as a yellowish-white opacity. In most instances vision is only mildly disturbed and there is little or no progression of the corneal disorder. Corneal sensation is disturbed in some instances. In a few cases there is a severe disturbance of vision sufficient to warrant corneal grafting, and it is these patients who have provided material for histological study. Histological examination of the disc from our patient (Garner and Tripathi, 1972) has confirmed the findings of Bonnet and others (1934), Sédan and Vallès (1946), and Delleman and Winkelman (1968) that the crystals within the corneal stroma are composed of cholesterol. The demonstration of neutral fat within the stroma may perhaps explain the findings of Malbrán, Paunessa, and Vidal (1953), who suggested on the basis of staining with Sudan IV that the crystals themselves were made up of neutral fat.

Delleman and Winkelman, in their extensive genealogical study, have described five morphological phenotypes of the disorder:

- TYPE A A disc-shaped central opacity lacking crystals;
- TYPE B A central crystalline disc-shaped opacity with an ill-defined edge;
- TYPE C A crystalline discoid opacity with a garland-like margin of sinuous contour;
- TYPE D A ring opacity which exhibits local crystal agglomerations: with a clear centre;
- TYPE E A crystalline ring opacity with a clear centre.

The paper of Delleman and Winkelman has been important in establishing that the discoid forms may exist in the same pedigree as that exhibiting the ring-shaped forms.

The biomicroscopic features of Case II-4 of our study are those of a typical Type C form of Schnyder's dystrophy. The corneal appearances of Case II-3 are best interpreted as a severe form of the same type, since there is both a discoid crystalline component and a garland-like fringe. The occurrence of the dystrophy in the mother of these two patients is in keeping with the dominant mode of inheritance of Schnyder's dystrophy.

The appearances of Case II-3 of this study are atypical in the extent of involvement of the anterior stroma by the crystalline disc. The crystals were present diffusely and extended in all directions to the internal margin of the arcus lipoides. Such extensive involvement of the anterior stroma has only occasionally been reported (Offret, Payrau, Pouliquen, Faure, and Bisson, 1966). The case of Sherman (1942) cannot be regarded as unquestionably one of Schnyder's dystrophy, since it is an isolated report, unsupported by family history. Cavara (1940) reported diffuse bilateral corneal opacity in one of his cases, but this patient was not examined with the slit lamp.

Another atypical feature, shown by both our cases of dystrophy, is the cloudy appearance of the stroma outside the main crystalline lesions. This was most marked in Case II-3, where it could be examined closely after the lamellar graft had been performed in the left eye. This must be regarded as a rare occurrence in Schnyder's dystrophy. The relationship of the stromal clouding to the abnormal blood lipid levels will be discussed in a later section. Although the corneae of both patients were thicker than normal, the appearances of clouding were not those produced by stromal oedema, and this was affirmed by the fact that in the proband the donor stroma of the healed corneal graft was clear while the cloudiness of the host stroma persisted.

Both Vogt's limbus girdle and arcus lipoides (either arcus senilis or juvenilis) have been described with sufficient frequency in association with Schnyder's corneal dystrophy to be included as a part of the general features of the disorder. Although both may occur commonly in the older age groups in the population at large, each has been noted in children with Schnyder's dystrophy, arcus juvenilis having been recorded at the age of 14 years and Vogt's limbus girdle at the age of 7 years. Marty (1957) has stated that Vogt's limbus girdle does not occur before the age of 20 years. Both our cases of Schnyder's dystrophy exhibited these changes, and in Case II-3 the arcus lipoides was doubled and the main component was unusually dense and broad. As Delleman and Winkelman (1968) have pointed out, both features may be lacking in the presence of the crystalline corneal changes.

There are certain other clinical features of interest exhibited by members of families with Schnyder's dystrophy. Two of the patients described by Fry and Pickett (1950) had xanthelasma. Case 1 of that study, a male aged 42 years, showed a normal blood cholesterol. Case 6 of that study, a woman aged 36 years, had no lipid studies at that time; however, when she was reported by Luxenburg (1967) at the age of 51 years, mild elevations in the serum cholesterol and phospholipid were found together with a slightly raised beta-lipoprotein and reduced alpha-lipoprotein concentration. At this time, a 'dense arcus' was observed which had not been recorded in the earlier paper. The occurrence together of three different forms of lipid deposition, manifesting as arcus lipoides, the crystalline stromal corneal change of Schnyder's dystrophy, and xanthelasma, is of great interest. Xanthelasma was also noted by Tsopelas (1948) in a patient with Schnyder's dystrophy, and the sister of this patient who did not have the dystrophy also showed xanthelasma. Although xanthelasma may be associated with hypercholesterol-

aemia, normo-cholesterolaemic xanthelasma is also common. Epstein, Rosenman, and Gofman (1952) found a high serum cholesterol in 47 per cent. of their cases. It is worth noting that arcus lipoides and xanthelasma resemble one another in having a high content of esterified cholesterol (Rodger and Sinclair, 1969).

Another clinical feature, exhibited by more than one pedigree, is joint disease. Sixteen of the 21 cases of Schnyder's dystrophy cited by Delleman and Winkelman (1968) in their pedigree H-P 132 showed genu valgum. Three of the nine cases of Fry and Pickett (1950) suffered from joint disease which was characterized in one case as chondrodystrophy. Both patients with Schnyder's dystrophy in the present study showed joint disease; but in the man (II-3) these were osteoarthritic changes of minor degree, and in the woman (II-4) the changes were thought to be secondary to a congenital spastic diplegia.

Ulbrich (1914) considered that cholesterol might be the basis of crystalline changes observed in the cornea. Kusama (1921) identified cholesterol in a case of 'primary' fatty change of the cornea, and Meesman (1927) noted an association between 'fatty degeneration' of the cornea and hypercholesterolaemia. Kohashi (1929) reported corneal opacities in animals fed on a cholesterol-rich diet. The early descriptions of Schnyder's dystrophy, therefore, came at a time when there was increasing interest in the origins of crystalline changes in the cornea. The corneal crystals in Schnyder's dystrophy were shown histologically to be cholesterol by Bonnet and others (1934) on the basis of ether solubility and examination under polarized light, and they were also the first to measure the blood cholesterol in this condition. A normal value of 160 mg./100 ml. was obtained in this instance. Further studies have since appeared in which blood lipid levels have been estimated.

Table VI (pp. 396 and 397) shows that a raised cholesterol level has been found in nine, or possibly eleven, of 26 cases reported in the literature in which the lipids have been assessed, and that the family of Sverak and Kindernay (1969), in which individual cholesterol levels were not given, nevertheless provides additional cases with abnormal serum cholesterol levels. The highest abnormal cholesterol value recorded was 433 mg./100 ml. in a woman aged 35 years and the lowest 287 mg./100 ml. in a child under 10 years (Sysi, 1950).

Karseras and Clewett Price (1970) have argued that such values cannot be appraised since they do not necessarily represent fasting levels. However, although the criticism is entirely valid with regard to chylomicrons, neutral fat, free fatty acid, and phospholipid levels, serum cholesterol levels are not greatly affected by overnight fasting and probably the levels cited for cholesterol in the literature can be accepted. Thus the literature provides a number of studies showing raised serum cholesterol levels in association with Schnyders' dystrophy with inadequate data to allow the blood lipid abnormalities to be further characterized. The fuller study of Luxenburg (1967), which indicated a mild disturbance of lipoprotein metabolism, may probably be accepted, as may the study of Karseras and Clewett Price (1970), in which no abnormality of lipid was detected.

With such a small body of information supporting a connection between the occurrence of the lipid stromal dystrophy and a disturbance of the blood lipids it would be easy to reject the suggestion that the two may be linked in some way. Abnormalities of lipid metabolism are common and are found increasingly in the higher age groups. Even the finding of more than one member of a family with both the corneal dystrophy and the blood lipid abnormality does not strengthen the connection, since many of the dyslipoprotein-aemias themselves are known to be genetically inherited (Fredrickson, 1971). On the other hand, arcus lipoides, which is so much a part of the total clinical picture of Schnyder's

dystrophy, and in particular arcus juvenilis, is known to be associated with raised serum cholesterol or lipoprotein levels. Thus it is encountered in Type II hyperlipoproteinaemia where raised beta lipoprotein is found and possibly in Type III where a broad beta zone may be demonstrated on electrophoresis. Forsius (1954) found a direct relationship between the degree of arcus lipoides and the level of the serum cholesterol, which was maintained only in those subjects below 50 years of age.

In the light of these findings it seems worth considering some possibilities of the relationship between Schnyder's dystrophy and the blood lipid disturbances. The first is that both Schnyder's dystrophy and the hyperlipoproteinaemia are determined by the same gene. This seems unlikely, since the concordance between these two features both within and between reported families is poor. In our own family, for instance, a systemic hyperlipoproteinaemia was present in all four sibs but the corneal dystrophy was present in only two.

The second possibility is that the corneal dystrophy is secondary to a disturbance of blood lipids alone. This suggestion may also be rejected for a variety of reasons. Despite the intensive study which the hyperlipoproteinaemias have received in recent years (Fredrickson and others, 1967), no reports of a central corneal crystalline change have been made in patients with such disorders. It is unlikely that such changes would be missed, since Schnyder's dystrophy may be visible to the naked eye and physicians concerned with the study of blood lipid disorders are aware of the possibility of corneal manifestations in the form of arcus lipoides (Vinger and Sachs, 1970). On the other hand, though fine stromal opacities have been noted in the central cornea in patients with an-alpha-lipoproteinaemia (Tangier disease) and lecithin: cholesterol acyltransferase deficiency, the blood lipid findings in our patients are not in keeping with either of these two disorders (Fredrickson, 1966; Hamnström, Gjone, and Norum, 1969). It may be emphasized that typical cases of Schnyder's dystrophy have been observed in the absence of raised blood cholesterol levels, raised triglyceride, and phospholipids, and of raised lipoprotein levels. Also, of the cases of Schnyder's dystrophy which have been severe enough to warrant corneal grafting, the cholesterol levels were normal in the cases of Bonnet and others (1934), Delleman and Winkelman (1968), and Sédan and Vallès (1946), and only mildly raised in the cases of Malbrán and others (1953) and Paufigue, Ravault, Bonnet, and Laurent (1964) (see Table VI).

The third possibility is that, when Schnyder's dystrophy occurs in conjunction with a disturbance of blood lipoproteins, the evolution of the dystrophy may be modified. An analogy may be drawn with arcus lipoides and xanthelasma, both of which may be found in normo-cholesterolaemic subjects but which are seen with high frequency in patients with raised beta lipoprotein levels. The suggestion here is that a local disorder of lipid metabolism may give rise to either of these conditions in the presence of normal blood lipids but that the same condition may result when raised blood lipids overload the tissues and the capacity of the tissues to dispose of lipid is exceeded. In the same way it may be proposed that the basic fault in Schnyder's dystrophy is a local defect in the handling of lipid by stromal keratocytes, leading to its local deposition, and that the systems responsible for removal of lipid are capable of further overloading by lipid derived from the blood stream. This would lead to increased lipid deposition in the stroma. Such a hypothesis might explain some of the atypical features of the dystrophy in Case II-3 of our study, who showed a gross hyperlipoproteinaemia and in whom the cholesterol deposition in the stroma was peculiarly extensive in the coronal plane. It might also explain the more diffuse and homogeneous stromal clouding noted in both our dystrophic subjects.

Table VI Particulars of 26 cases reported in the literature, 1934-1972

Authors	Dates	Case no.	Age (yrs)	Sex	Blood cholesterol levels (mg./100 ml.)	Other lipid levels (mg./100 ml.)	Comments
Bonnet and others	1934	1	31	M	160		
Cavara	1940	1	26	M	138 (free 55, ester 141)		
Sherman	1942	1	45	M	167		Probably not Schnyder's dystrophy
Sédan and Vallès	1946	1	26	M	145	Total lipid 1,100	
Tsopoulos	1948	1	42	M	340		Xanthelasma (sister without Schnyder's dystrophy also had xanthelasma)
Perez Llorca	1949	1	12	M	free 181 ester 320		
		2	?	?	400		
Fry and Pickett	1950	1	42	M	138		Xanthelasma: normal joints
		6	36	F	*See Luxenburg (1967)		Xanthelasma: generalized chondrodystrophy
Sysi	1950	1	35	F	437		
		2	47	M	274		
		3	30	M	257		
		4	~3-8	M	285		
Malbrán and others	1953	1	37	F	260	Total lipid 755	

Gillespie and Covelli	1963	I		48	F	348			
Paufique and others	1964	—		?	M	300	Serum lipid 80		
Offret and others	1966	3		70	F	252			
Luxenburg	1967	I		51	F	*See Fry and Pickett (1950), Case 6			
						(a) 324	1963		
						(b) 290	1964	Xanthelasma present	
						(c) 311	1965		
						(d) 254	1966	Phospholipid 305. Raised immobile lipid and beta lipoprotein. Reduced alpha lipoprotein.	
Delleman and Winkelman	1968	H.P.132	IV 28	40	M	220			
			V 4	23	M	219	Phospholipid 180 Total lipid 583		
			V 29	20	F	225	Phospholipid 260 Total lipid 600		
			A.P.150	IV 5	M	268			
Sverak and Kindernay	1969	—		—		"Raised cholesterol in 3 of cases"			
Karseras and Clewett Price	1970	I		14	F	174	Triglyceride 86 Phospholipid 270 Total 620 Beta lipoprotein 87 per cent. of normal		
		2		42	F	242	Triglyceride 80 Phospholipid 311 Total 750 Beta lipoprotein 98 per cent. of normal		
Bron, Williams, and Carruthers	1972	1		47	M	852	Triglyceride 6,400 Triglyceride 288	Both the patients and their two sisters all have hyperlipoproteinaemia	
		2		45	F	368			

In the presence of hyperlipoproteinaemia it would be expected that many suitable lipid precursors would be available in the plasma with access to the corneal tissues, capable of stimulating lipid synthesis. It is suggested that the stromal cells in Schnyder's dystrophy are incapable of removing such excess lipid so that the dystrophy may be exacerbated. The arcus lipoides would be expected to be enhanced as well as the central crystalline change. If this hypothesis is correct, it should be possible to diminish the corneal changes by bringing the blood lipids back to normal.

The effects of reducing the blood lipid levels are being studied in Case II-3. Sysi (1950) reported the case of a 33-year-old woman with Schnyder's dystrophy whose crystalline opacities diminished markedly while she was on a vegetable diet and took fat only in the form of butter. During this time the blood cholesterol, which had been 437 mg./100 ml., fell to a normal value of 243 mg./100 ml. However, when she resumed her former diet, the blood cholesterol rose to 328 mg./100 ml. and within a year the corneal opacities had once again increased in size. In our own subject it is still too early to make comment but it has been notable that, despite a fall both in the triglyceride and cholesterol fractions of the blood on therapy, crystals, presumably cholesterol in nature, have appeared in relation to the graft. The appearance of cholesterol crystals in the bed of a lamellar graft is not uncommon (Maumenee, 1960). Delleman and Winkelman (1968) have described the occurrence of crystals in both lamellar and penetrating grafts carried out for Schnyder's dystrophy. They regard this as a recurrence of the disorder in the graft. Of particular interest is the subepithelial accumulation noted in one of their cases. So far this has not occurred in our case.

Although it is clear that Schnyder's dystrophy is caused by an autosomal dominant gene, it is not so certain what the nature of the inherited defect is. Sédan and Vallès (1946) suggested that the deposition of cholesterol in the central cornea might be related to earlier dystrophic changes. The extensive destruction of Bowman's membrane encountered in this disorder would be in keeping with this suggestion, as would the observation by Delleman and Winkelman (1968) of their "Types A and D" Schnyder's dystrophy in which a disc-shaped opacity was crystal-free and a superficial ring-shaped stromal opacity showed only patchy crystal deposition. However, extensive lipid deposition in the cornea in the absence of vascularization is unusual without gross corneal disease, so that a special mechanism in Schnyder's dystrophy leading to the accumulation of lipid must still be sought.

For the time being, then, it would seem a reasonable hypothesis that Schnyder's dystrophy is due to a local metabolic defect in the cornea and that the morphological features may be modified by co-existing plasma lipoprotein abnormalities. It is, however, recommended that blood lipoprotein analyses be performed on all patients with Schnyder's dystrophy so that in time the true relationship between the systemic and local lipid abnormalities may be determined.

Summary

Hereditary crystalline stromal dystrophy of Schnyder is described in a brother and sister. Both they and two further siblings exhibit a complex hyperlipoproteinaemia. The nature of this inherited corneal disorder and the blood lipid findings are discussed.

Our thanks are due to Prof. B. R. Jones and Mr. D. Ainslie for permission to study patients under their care. The authors also wish to express their gratitude to Dr. Joan Slack of the M.R.C. Clinical Genetic Unit, Institute of Child Health, London, who performed the majority of the lipid determinations and provided much valuable advice, and to Dr. P. Borrie for clinical assessment of the patients. The corneal drawings were made by Mr. T. Tarrant of the Institute of Ophthalmology.

References

- BONNET, P., PAUFIQUE, L., and BONAMOUR, G. (1934) *Bull. Soc. Ophtal. Paris*, p. 225
- BROCKHURST, R. J., HYNES, E. A., and COGAN, D. G. (1954) *A.M.A. Arch. Ophthalmol.*, **52**, 458
- BRON, A. J., and WILLIAMS, H. P. (1972) *Brit. J. Ophthalmol.*, **56**, 343
- CAVARA, V. (1940) *Boll. Oculist.*, **19**, 967
- DELLEMAN, J. W., and WINKELMAN, J. E. (1968) *Ophthalmologica (Basel)*, **155**, 409
- EPSTEIN, N. N., ROSENMAN, R. H., and GOFMAN, J. W. (1952) *A.M.A. Arch. Derm. Syph.*, **65**, 70
- FRANCESCHETTI, A., and FORNI, S. (1951) "Acta XVI Conc. Ophthalm. 1950, Britannia Acta", vol. 1, p. 193. B.M.A., London
- , KLEIN, D., and BARTH, J. (1960) "The Transparency of the Cornea. A Symposium", ed. S. Duke-Elder and E. S. Perkins, p. 165. Blackwell, Oxford
- FREDRICKSON, D. S. (1966) "Familial high-density lipoprotein deficiency: Tangier disease", in "Metabolic Basis of Inherited Disease", by J. B. Stanbury, J. B. Wyngaarden, and D. S. Fredrickson, 2nd. ed., p. 486. McGraw-Hill, New York
- (1971) *Brit. med. J.*, **2**, 187
- , LEVY, R. I., and LEES, R. S. (1967) *New Engl. J. Med.*, **276**, 34, 94, 148, 215, 273
- FORSIUS, H. (1954) "Arcus senilis corneae", *Acta ophthalm. (Kbh.)*, Suppl. 42
- FRY, W. E., and PICKETT, W. E. (1950) *Trans. Amer. ophthalm. Soc.*, **48**, 220
- GARNER, A., and TRIPATHI, R. C. (1972) *Brit. J. Ophthalmol.*, **56**, 400
- GILLESPIE, F. D., and COVELLI, B. (1963) *Amer. J. Ophthalmol.*, **56**, 465
- HAMNSTRÖM, B., GJONE, E., and NORUM, K. R. (1969) *Brit. med. J.*, **2**, 283
- HIPPEL, E. VON (1929) *Klin. Mbl. Augenheilk.*, **84**, 115
- KARSERAS, A. G., and CLEWETT PRICE, D. (1970) *Brit. J. Ophthalmol.*, **54**, 659
- KOHASHI, M. (1929) *Okayama Igakkai-Zasshi*, **41**, 1105, 1435 (Cited by Sysi, 1950)
- KUSAMA (1921) *Klin. Mbl. Augenheilk.*, **66**, 111
- LUXENBURG, M. (1967) *Amer. J. Ophthalmol.*, **63**, 507
- MALBRÁN, J. L., PAUNESSA, J. M., and VIDAL, F. (1953) *Ophthalmologica (Basel)*, **126**, 369
- MARTY, F. (1957) *Arch. Ophtal. (Paris)*, **17**, 5
- MAUMENEE, A. E. (1960) In "Transparency of the Cornea", ed. S. Duke-Elder and E. S. Perkins, p. 158. Blackwell, Oxford
- MAURICE, D. M. (1969) "The Eye", ed. H. Davson, vol. 1, p. 489. Academic Press, New York and London
- MEESMAN, A. (1927) "Die Mikroskopie des lebenden Auges". Berlin
- NEVIN, N. C., and SLACK, J. (1968) *J. med. Genet.*, **5**, 9
- NOBLE, R. P., HATCH, F. T., MAZRIMAS, J. A., LINDGREN, F. T., JENSEN, L. C., and ADAMSON, G. L. (1969) *Lipids*, **4**, 55
- PEREZ LLORCA, J. (1949) *Arch. Soc. oftal. hisp-amer.*, **9**, 280
- OFFRET, G., PAYRAU, P., POULIQUEN, Y., FAURE, J. P., and BISSON, J. (1966) *Arch. Ophtal. (Paris)*, **26**, 171
- PAUFIQUE, L., RAVAUULT, M. P., BONNET, M., and LAURENT, C. (1964) *Bull. Soc. Ophtal. Fr.*, p. 104
- RODGER, F. C., and SINCLAIR, H. M. (1969) "Metabolic and Nutritional Eye Diseases". Thomas, Springfield, Ill.
- SCHNYDER, W. F. (1927) *Schweiz. med. Wschr.*, **57**, 403
- (1929) *Ibid.*, **59**, 559
- (1939) *Klin. Mbl. Augenheilk.*, **103**, 494
- SÉDAN, J., and VALLÈS, A. (1946) *Bull. Soc. franç. Ophtal.*, **59**, 127
- SHERMAN, A. R. (1942) *Arch. Ophthalmol. (Chicago)*, **27**, 692
- SVERAK, J., and KINDERNAY, S. (1969) *Čs. Oftal.*, **25**, 283
- SYSI, R. (1950) *Brit. J. Ophthalmol.*, **34**, 369
- TSOPELAS, B. (1948) *Bull. Soc. hellén. Ophtal.*, **16**, 262 (Cited by Franceschetti and others, 1960)
- ULBRICH, H. (1914) *Klin. Mbl. Augenheilk.*, **52**, 289
- VINGER, P. F., and SACHS, B. A. (1970) *Amer. J. Ophthalmol.*, **70**, 563
- WAARDENBURG, P. J., FRANCESCHETTI, A., and KLEIN, D. (1961) "Genetics and Ophthalmology", vol. 1, p. 468. Blackwell, Oxford
- WENT, J. VAN, and WIBAUT, F. (1924) *Ned. T. Geneesk.*, **68**, 2996