

# Atrioventricular septal defect in prenatal life

M VIRGINIA L MACHADO, DIANE C CRAWFORD, ROBERT H ANDERSON,\*  
LINDSEY D ALLAN

*From the Department of Perinatal Cardiology, Guy's Hospital, and \*the Cardiothoracic Institute, London*

**SUMMARY** In a series of more than 3500 pregnancies referred for fetal echocardiography, 29 cases of atrioventricular septal defect were detected in the fetus. There was a chromosomal anomaly in 14 of these cases, left atrial isomerism in 12, and right atrial isomerism in two. Complete heart block was found in 11 of the cases with left atrial isomerism. Many associated cardiac abnormalities were found, particularly in the fetuses with atrial isomerism; the most common were double outlet right ventricle or aortic arch anomalies. The prognosis was poor in all patients with atrioventricular septal defect detected prenatally. Fifteen pregnancies went to term but there are only four survivors. Two of those have trisomy 21, a further patient has inoperable defects, and only one remains well and is awaiting corrective surgery for a partial atrioventricular septal defect.

The morphological characteristics of atrioventricular septal defect were first described by Peacock in 1846<sup>1</sup> and the association with trisomy 21 was noted by Abbott in 1924.<sup>2</sup> The accurate delineation of the atrioventricular defect by echocardiography is well recognised.<sup>3</sup> In recent years, fetal echocardiography has become established as a reliable predictor of congenital heart disease in prenatal life.<sup>4,5</sup> We have selected the cases of atrioventricular septal defect detected over the past seven years in order to present the associations in and outcome of these cases.

## Patients and methods

From the start of 1980 to the end of 1986 we echocardiographically examined more than 3500 pregnancies in our department. We used either an Advanced Technical Laboratories Mark 3 sector scanner or a Hewlett-Packard 77020A phased array system with a 5 MHz transducer. The fetal heart was examined from multiple projections to identify all the cardiac connections. After Doppler examination of the heart became available in early 1985 this too was performed. Of 153 cases of structural cardiac abnormality identified in this sample, 29 were found to have deficiencies of the atrioventricular septum.

## Results

Of the 29 cases, 28 had a common valve orifice (the complete form) and one had separate valve orifices (the partial form or ostium primum defect). The gestational age ranged from 16 to 36 weeks. The reason for referral was non-immune fetal hydrops in 11 cases, previous family history of congenital heart disease in seven cases, fetal bradycardia in five cases, and the identification of extracardiac fetal abnormality in six cases. In the 26 cases where the sex of the fetus was known, 13 were male and 13 female. The diagnosis of atrioventricular septal defect was confirmed at postmortem examination in 21 cases. Postmortem was refused in four cases. Four patients are alive and the diagnosis has been confirmed by echocardiography in all and by cardiac catheterisation in three. In the first two years of the study, there was one false negative and one false positive prediction of partial atrioventricular septal defects.<sup>4</sup>

The atrioventricular septal defect was the only cardiac lesion in 8 cases. An example is shown in the figure. There was associated left atrial isomerism in 12 cases and right isomerism in two cases. There were seven patients with normal atrial arrangement and atrioventricular septal defect with other cardiac anomalies. Complete heart block was found prenatally in 11 of the 12 cases that had left atrial isomerism. Tubular hypoplasia of the aortic arch, aortic coarctation, or arch interruption was found in six cases. Double outlet right ventricle was found in seven cases—one of these also had right atrial isomerism and three had left isomerism. A discordant

Requests for reprints to Dr Lindsey D Allen, Department of Perinatal Cardiology, 15th Floor, Guy's Tower, St Thomas's Street, London SE1 9RT.

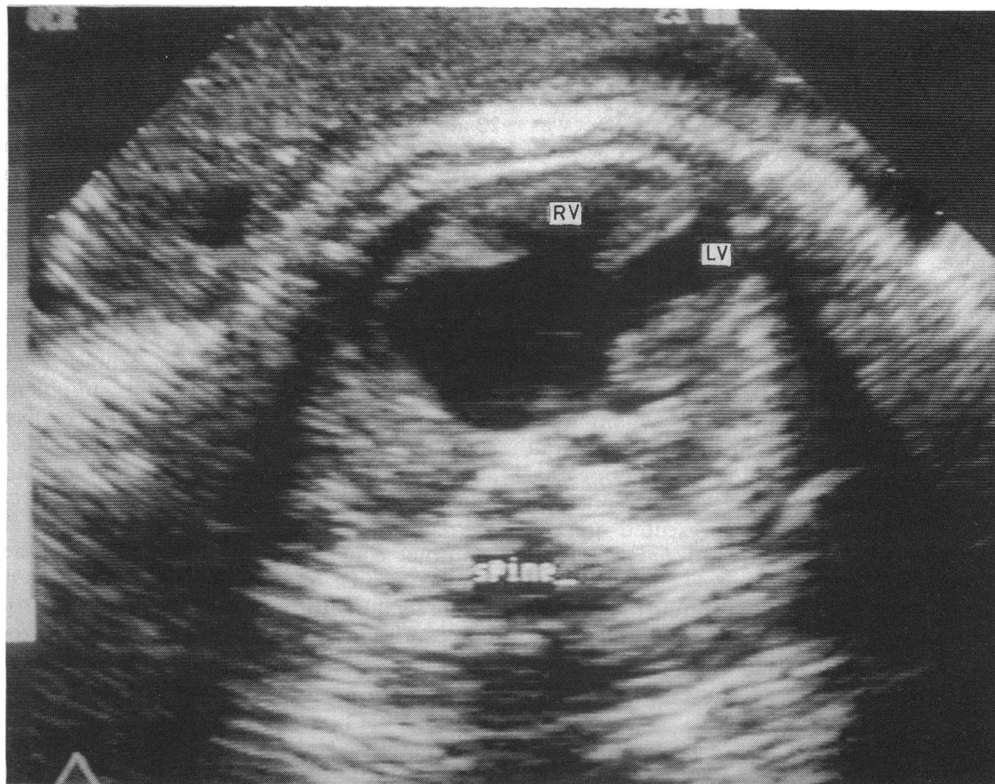


Figure A heart in the four chamber projection showing opening of the common atrioventricular valve in diastole. The atrioventricular septal defect was the only cardiac lesion in this case.

ventriculoarterial connection was present in two cases, aortic atresia in one case, and pulmonary atresia in three cases. Aortic (3) or pulmonary stenosis (3) was a feature of six cases. There was ventricular dominance to such a degree that the common valve was more than 50% committed to the right ventricle in two cases. Total anomalous pul-

monary venous connection was found in both cases of right atrial isomerism.

The following chromosomal abnormalities were found in 14 cases: trisomy 21 in nine, trisomy 18 in three, extra fragment 22 in one, and Turner's syndrome in one. In this group there were two cases of diaphragmatic hernia, one case of duodenal atresia,

Table The recurrent lesions in the patients with a family history of congenital heart disease

Case No.	Diagnosis in index case	Diagnosis in recurrent case	Associated anomalies in recurrent case
1	TAPVC (+ fragment 22)	AVSD	Absent right lung, fragment 22
2	Critical PS	AVSD	Trisomy 21
3	TOF + anencephaly	AVSD	Trisomy 21
4	(a) VSD (b) PDS, PA	AVSD, DORV, PAtresia	Trisomy 18
5	Ebstein's, PS	AVSD, DORV, AAtresia, LAI	Hydrocephaly, polysplenia
6	(a) MAtresia, PAtresia, RAI	AVSD, PAtresia, TAPVC, RAI	Asplenia
7	(b) MAtresia, PAtresia, RAI DORV, VSD, PS	AVSD, DORV, RAI	None (patient alive)

In cases 4 and 6 there had been two previously affected children.

AVSD, atrioventricular septal defect; AAtresia, aortic atresia; DORV, double outlet right ventricle; LAI, left atrial isomerism; RAI, right aortic isomerism; PAtresia, pulmonary atresia; PS, pulmonary stenosis; PDA, patent ductus arteriosus; MAtresia, mitral valve atresia; TAPVC, total anomalous pulmonary venous connection; TOF, tetralogy of Fallot.

one case of exomphalos, one case with right pulmonary agenesis, and one case of cystic hygroma. There was one case of diaphragmatic hernia and atrioventricular septal defect with normal chromosomes. The atrioventricular septal defect was isolated in seven of the cases with trisomy 21. No case of chromosomal abnormality had atrial isomerism.

In seven cases the reason for referral for fetal echocardiography was a family history of congenital heart disease. In none of these families was the previous lesion an atrioventricular septal defect. The table summarises data on these cases.

Fourteen pregnancies were terminated. Six of these fetuses had fetal hydrops and 11 had associated extracardiac or complex cardiac anomalies. There were four intrauterine deaths, all of whom were hydropic. There were four neonatal deaths (all within the first week of life) and three infant deaths. There are four survivors. Two of the survivors have trisomy 21 and one survivor presented in late pregnancy with fetal hydrops and has a partial atrioventricular septal defect with complete heart block and left atrial isomerism. The fourth survivor has right atrial isomerism with double outlet right ventricle, total anomalous pulmonary venous connection, and pulmonary stenosis.

## Discussion

Nearly half of the cases of atrioventricular septal defect detected in this series had chromosomal anomalies, predominantly trisomy 21. The cardiac lesion tended to be isolated when a chromosomal abnormality was present but there were associated arch anomalies in some cases and frequently extracardiac anomalies. On the other hand, atrioventricular septal defects occurring with atrial isomerism tended to be associated with multiple and various cardiac anomalies and the extracardiac anomalies of asplenia or polysplenia that are expected with isomerism. As noted previously,<sup>6</sup> we never found Down's syndrome and isomerism in any of our cases. Only one case in the series had neither chromosome anomalies nor atrial isomerism; a diaphragmatic hernia caused early neonatal death in this fetus. Overall there was an association with conotruncal abnormalities in 10 (34%) cases of atrioventricular septal defect, which is consistent with other studies.<sup>7,8</sup> Complete heart block producing bradycardia was found in a total of 11 cases. But in only five of these 11 had fetal bradycardia been noticed by the referring obstetrician. There was a surprisingly strong association between complete heart block and left atrial isomerism (11 of 12 cases).

It is interesting that the pattern of recurrence of congenital heart disease was not concordant with the

defect found in the previous child. In two young mothers the recurrence of congenital heart disease was associated with trisomy 21. One mother is a known carrier of a balanced translocation of trisomy 22 and she has now has three affected children, one with an atrioventricular septal defect and two with total anomalous pulmonary venous connection. In three of the remaining four patients in whom there was a recurrence of a defect, atrial isomerism was a feature, although isomerism was present in only one index case.

In the first two years of our study one false negative and one false positive diagnosis was made. Increased experience, modification of the echocardiographic method, and improved ultrasound equipment have prevented repetition of these errors. For example, complete diagnosis of structural heart disease is not attempted before 18 weeks' gestation and a defect must be confidently seen in at least two projections.

Pregnancies were terminated mainly because of multiple congenital abnormalities or when an atrioventricular septal defect was associated with severe fetal hydrops in early pregnancy. Those with this condition are known to have a poor prognosis and there were intrauterine deaths in four cases in which there was no intervention. Three of the four neonates who died had multiple congenital abnormalities and the fourth had complex heart disease. Two of the three infants who died had an operation. Only one of the four survivors has relatively minor heart disease that is amenable to surgery (partial atrioventricular septal defect with left atrial isomerism with no chromosome defect).

Thus patients with atrioventricular septal defect who come to the attention of the fetal echocardiographer are a biased sample who are more likely to have a chromosomal anomaly or complex heart disease and atrial isomerism. In both these circumstances the prognosis is very poor.

MVLM is supported by CNPq (Brazilian Government), RHA by the British Heart Foundation and the Joseph Levy Foundation, and DCC and LDA by the British Heart Foundation.

## References

- 1 Peacock TB. Malformation of the heart consisting of an imperfection of the auricular and ventricular septum. *Transactions of the Pathological Society of London* 1846;1:61-2.
- 2 Abbott ME. New accessions in cardiac anomalies. Pulmonary atresia of inflammatory origin; persistent ostium primum with Mongolian idiocy. *International Association of Medical Museums Bulletin* 1924; 10:111-6.

- 3 Smallhorn JF, Tommasini G, Anderson RH, Macartney FJ. Assessment of atrioventricular septal defects by two dimensional echocardiography. *Br Heart J* 1982;47:109-21.
- 4 Allan LD, Crawford DC, Anderson RH, Tynan MJ. Echocardiographic and anatomical correlations in fetal congenital heart disease. *Br Heart J* 1984; 52:542-8.
- 5 Allan LD, Crawford DC, Anderson RH, Tynan M. Spectrum of congenital heart disease detected echocardiographically in prenatal life. *Br Heart J* 1985;54:523-6.
- 6 Tenckoff L, Stamm SJ. An analysis of 35 cases of the complete form of persistent common atrioventricular canal. *Circulation* 1973;48:416-27.
- 7 Bharati S, Kirklin JW, McAllister HA, Lev M. The surgical anatomy of common atrioventricular orifice associated with tetralogy of Fallot, double outlet right ventricle and complete regular transposition. *Circulation* 1980;61:1142-9.
- 8 Thiene G, Frescura C, Di Donato R, Gallucci V. Complete atrioventricular canal associated with conotruncal malformations: anatomical observations in 13 specimens. *Eur J Cardiol* 1979;913:199-213.