

## Case report

# Coronary ostial stenosis after radiotherapy: angioplasty or coronary artery surgery?

C E HANDLER,\* S LIVESEY,† P A LAWTON‡

From the Departments of \*Cardiology, †Cardiac Surgery, and ‡Radiotherapy, Middlesex Hospital, London

**SUMMARY** A thirty year old man underwent coronary angioplasty for an isolated ostial stenosis of the ostium of the right coronary artery after mediastinal radiotherapy given ten years previously. Despite an angiographically acceptable angioplasty result, he had a myocardial infarction two months later and coronary artery surgery was performed.

The most effective form of myocardial revascularisation for radiotherapy related coronary artery lesions remains to be established.

Pericardial disease is the most frequent cardiac complication of radiotherapy, but coronary artery lesions, myocardial fibrosis, and conduction disorders are also recognised.<sup>1,2</sup> We report a rare coronary lesion—an isolated stenosis of the ostium of the right coronary artery—in a young man who had been treated with radiotherapy 10 years before. The patient underwent angioplasty but later sustained a myocardial infarction and coronary artery surgery was performed.

### Case report

In 1976 when he was 20, a white man presented with left supraclavicular and right axillary lymphadenopathy. After a staging laparotomy and lymph node biopsy, stage IIA mixed cellularity Hodgkin's disease was diagnosed. He was treated with radiotherapy to a mantle field and initially had 6 Gy (600 rad) in two fractions to the mid-mediastinum and six weeks later received 40 Gy (4000 rad) given in 20 fractions over 28 days to the mid-mediastinum. The radiotherapy was administered as a single anterior radiation field by a telecobalt machine. Since then, he has remained in complete remission and has never been treated with cytotoxic drugs.

In 1978 he developed bilateral pleural effusions

and a pericardial effusion with cardiac tamponade. Bloodstained pericardial fluid (760 ml) was aspirated but investigations showed no evidence of pericardial infection or malignancy. In May 1979 he presented with pleurisy, and cytological examination of the pleural fluid showed pleomorphic cellular deposits with atypical lymphoid cells, plasma cells, and eosinophils but no Reed-Sternberg cells. After aspiration of the effusion, the chest x ray showed bilateral upper zone fibrosis and elevation of both hila.

In November 1979 he developed pericardial pain associated with another small pericardial effusion which resolved spontaneously. Recurrent small pleural and pericardial effusions were diagnosed in March 1980 and computerised tomography of the chest showed paramediastinal fibrosis but no lymphadenopathy. The pericardial fluid was straw coloured and yielded no malignant cells.

In July 1980 he presented with shock due to cardiac tamponade and underwent emergency pericardiectomy and a pericardial window was made. One litre of pericardial fluid was withdrawn. Pericardial biopsy showed fibrous tissue, reactive mesothelium, and focal aggregates of lymphoid and plasma cells with the occasional neutrophil cells but no malignant cells.

During the next six years the patient was well enough to play tennis and lead an active life. In November 1986 while walking to work he developed severe bilateral arm and interscapular pain, vomited,

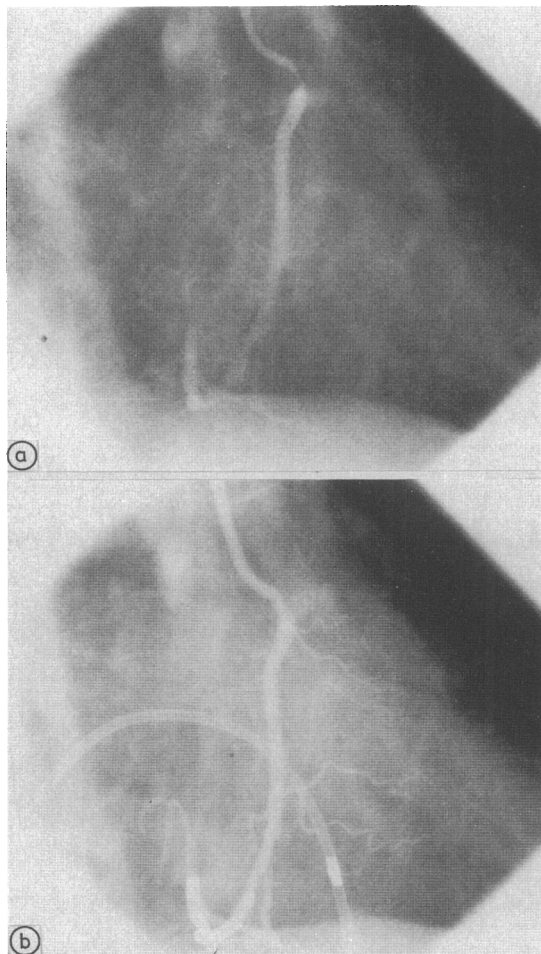


Fig 1 (a) Right coronary artery ostial stenosis before angioplasty. (b) Right coronary ostial stenosis after angioplasty.

and collapsed unconscious. The electrocardiogram showed widespread ST and T wave inversion. Serial measurements of cardiac enzymes were normal. He had no risk factors for coronary artery disease. Computed tomography of his chest showed no aortic dissection or relapse of his Hodgkin's disease. Coronary angiography and left ventriculography showed only an isolated stenosis of the right coronary ostium (fig 1a), which was not reversed by intracoronary nitrates or oral nifedipine. He was limited by fatigue and angina after nine minutes on the Bruce treadmill protocol and developed 4 mm of ST depression with a fall in systolic blood pressure at peak exercise.

Exercise thallium-201 myocardial scintigraphy showed a reversible perfusion defect in the inferior

wall of the left ventricle. Coronary angioplasty of the right coronary ostial stenosis was performed with a 3.5 mm balloon. It produced a fall in the transtenotic gradient from 45 to 15 mm Hg and a satisfactory angiographic result (fig 1b). Two days later he completed 11 minutes on the Bruce treadmill exercise protocol, was limited by fatigue, and developed 3 mm of ST depression in leads V1-V3 (fig 2a and b) without angina. Repeat exercise thallium-201 myocardial scintigraphy again showed a reversible perfusion defect in the inferior left ventricular wall. Nifedipine was prescribed and he was discharged from hospital. Two months after angioplasty, in January 1987, he presented with an inferior Q wave myocardial infarct. Coronary angiography showed near total occlusion of the right coronary artery and inferior left ventricular hypokinesia. Because of continuing post-infarction angina and exercise induced reversible myocardial ischaemia, saphenous vein coronary artery bypass grafting to the right coronary artery was performed in April 1987. At operation, dense adhesions were found all around the heart and the pericardium was grossly thickened. The patient made an uneventful recovery and remains symptom free.

## Discussion

Cardiac complications of radiotherapy are dose related and may not become apparent for several years. Because patients with serious neoplasms may die before cardiac complications are manifest, the true incidence of radiotherapy related coronary artery disease is difficult to determine but has been estimated as about 6%.<sup>3</sup>

Except in young patients without recognisable risk factors for coronary artery disease, it may be difficult to incriminate radiotherapy as the sole cause of coronary artery lesions. We believe that radiotherapy was the most likely cause of our patient's coronary artery lesion for several reasons: he was young and had no risk factors for atheromatous coronary artery disease, the appearance of the pericardium at operation, the large total dose of radiation administered (the dose to the right coronary artery was estimated to be 55 Gy owing to the use of a single anterior field), and the proximal site of the lesion.<sup>2</sup> In addition, an isolated coronary ostial lesion is a rare lesion in atheromatous coronary artery disease and it occurs predominantly in young and middle aged women.

We are aware of 39 reported cases of coronary ostial stenoses.<sup>4,5</sup> These were associated with radiation, syphilis, Takayasu's aortitis, congenital anomalies of the coronary arteries, hypercholesterolaemia, and as a complication of coronary angiography.

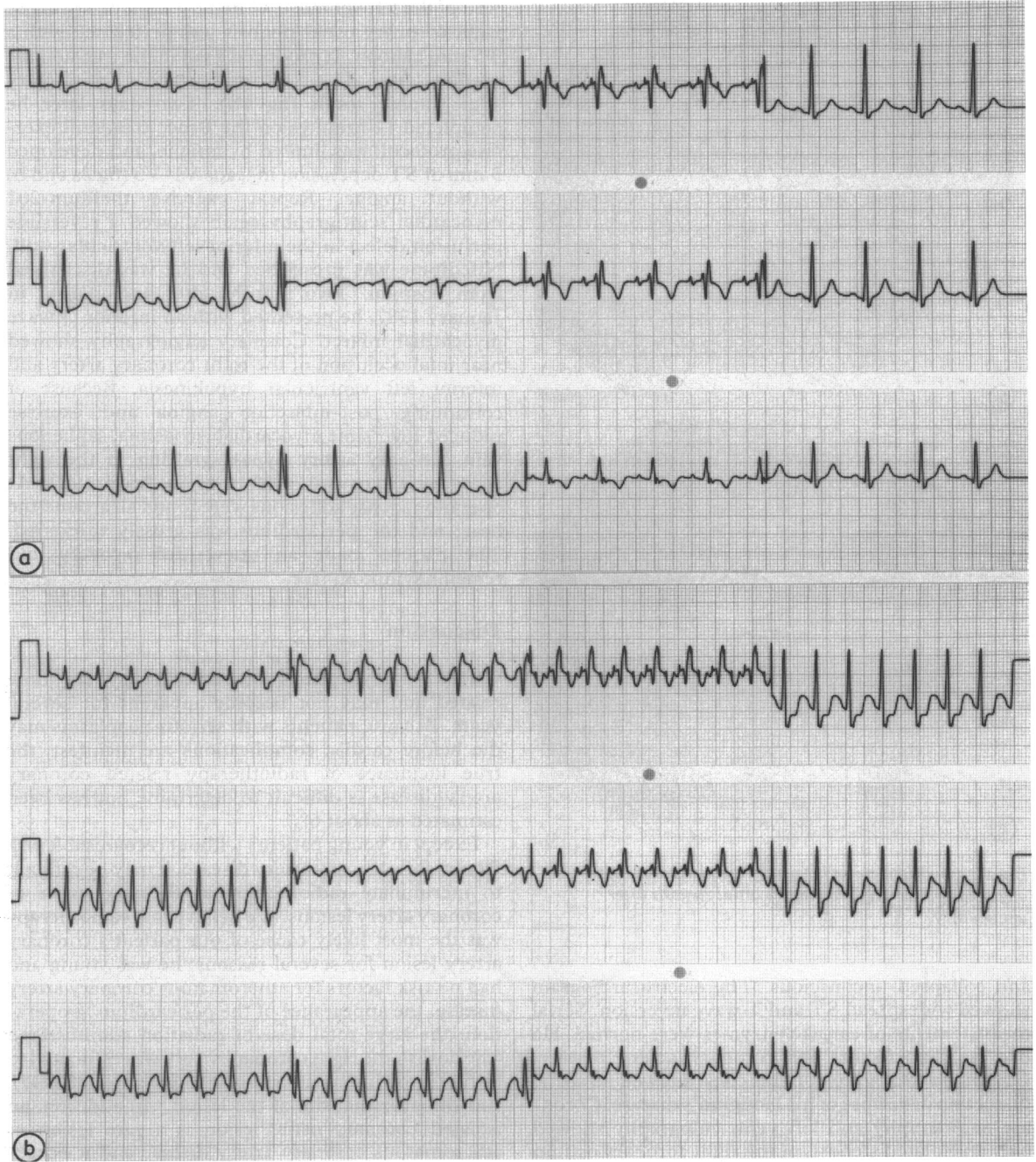


Fig 2 12 lead electrocardiogram recorded at rest after angioplasty. (b) 12 lead electrocardiogram recorded at peak exercise after angioplasty showed 2 mm of ST segment depression in leads II, III, aVF, and V3-V6.

The mechanism of radiation induced coronary artery disease is unclear. Animal studies with electron microscopy have shown damage to the cytoplasm of the capillary endothelial wall.<sup>6</sup> This may

lead to degeneration of the cell with thrombosis or capillary rupture (or both) and possibly with endothelial proliferation and a tendency for thrombosis. The characteristic histological appearance is that of

pure intimal fibrosis (although there may be adventitial fibrosis), most often without foam cells, cholesterol clefts, or extracellular lipid deposits.<sup>2</sup>

We are aware of two other reports of the use of angioplasty in coronary artery lesions presumably related to radiotherapy, but neither report provides follow up details. Nakhjavan *et al* performed angioplasty for an ostial stenosis of the right coronary artery in a 54 year old man<sup>7</sup> and Sande and colleagues reported the use of angioplasty to a lesion of the mid-portion of the left anterior descending coronary artery in a 50 year old woman with hypercholesterolaemia.<sup>8</sup>

Saphenous vein coronary artery bypass grafting has been performed for radiotherapy related stenosis of the coronary artery ostium.<sup>9</sup> It is possible that radiation damage to the internal mammary arteries may make this form of myocardial revascularisation technically difficult, but we are unaware of information on this surgical approach in this condition. Our patient sustained a myocardial infarction associated with a slight residual stenosis of the ostium of the right coronary artery. Because of technical problems associated with angioplasty for ostial stenoses and the nature of radiotherapy related lesions, coronary artery surgery may be a more effective form of revascularisation for these lesions.

With the improving survival of patients with mediastinal tumours relating from radiotherapy, recognition and appropriate management of potential cardiac complications are important; however, the optimal management of radiotherapy related coronary artery lesions remains to be established.

We are grateful to Dr Howard Swanton, Mr M F Sturridge, and Dr A Jelliffe for help in preparing this report.

#### References

- 1 McReynolds RA, Gold GL, Roberts WC. Coronary heart disease after mediastinal irradiation for Hodgkin's disease. *Am J Med* 1976;60:39-45.
- 2 Dunsmore LD, LoPonte MA, Dunsmore RA. Radiation-induced coronary artery disease. *J Am Coll Cardiol* 1986;8:239-44.
- 3 Vacheron A, Heulin A, Metzger JPh, *et al*. Complications cardiaques de la radiothérapie. *Ann Cardiol Angéiol (Paris)* 1983;32:465-72.
- 4 Grollier G, Commeau P, Bertrand JH, *et al*. Les sténoses ostiales isolées: une forme anatomique particulière d'insuffisance coronaire de la femme. *Arch Mal Coeur* 1987;80:1479-86.
- 5 Grollier G, Commeau P, Mercier V, *et al*. Post-radiotherapeutic left main coronary ostial stenosis: clinical and histological study. *Eur Heart J* 1988;9:567-70.
- 6 Fajardo LF, Stewart JR. Pathogenesis of radiation-induced myocardial fibrosis. *Lab Invest* 1973;29:244-57.
- 7 Nakhjavan FK, Yazdanfar S, Frieman A. Percutaneous transluminal coronary angioplasty for stenosis of the ostium of the right coronary artery after irradiation for Hodgkin's disease. *Am J Cardiol* 1984;53:341-2.
- 8 Sande LM, Casariego J, Llorian AR. Percutaneous transluminal coronary angioplasty for coronary stenosis following radiotherapy. *Int J Cardiol* 1988;20:129-32.
- 9 Iqbal SM, Hanson EL, Gensini GG. Bypass graft for coronary arterial stenosis following radiation therapy. *Chest* 1977;5:664-6.