

Synaptic distribution of centripetal and centrifugal nerve fibres in the olfactory system of the rat. An experimental anatomical study

LENNART HEIMER

*Department of Anatomy,
University of Göteborg, Göteborg (Sweden) and Department of Psychology,
Massachusetts Institute of Technology, Cambridge, Mass. (U.S.A.)**

INTRODUCTION

The central fibre connexions of the mammalian olfactory bulb have long been a matter of conflicting opinions. The earliest interpretations of the olfactory system as it presents itself macroscopically in normal brains led to a delineation of the 'rhinencephalon' that now generally is considered unduly wide. The results of later studies by the Golgi method (Cajal, 1911), the Marchi technique (Elliot Smith, 1909; Fox & Schmitz, 1943) and electrophysiological methods (Hasama, 1934; Adrian, 1942; Allen, 1943; Rose & Woolsey, 1943; Fox, McKinley & Magoun, 1944) tended to restrict the distribution field of olfactory bulb fibres to the primitive cortex of the piriform lobe, specifically to the 'anterior olfactory nucleus' of the olfactory peduncle and the prepiriform and periamygdaloid fields, with some disagreement as to whether this distribution also involved the olfactory tubercle. In all these studies the entorhinal area—that most caudal subdivision of the piriform lobe—was implicitly or explicitly excluded from the distribution field of bulbofugal fibres.

Le Gros Clark & Meyer's (1947) study of the central olfactory connexions in the rabbit appears as something like a landmark, for it represents the first attempt to identify the terminations of these connexions by an experimental silver method. By the aid of the newly developed Glees technique (1946), Clark & Meyer identified the synaptic terminals of degenerating bulbofugal fibres in the olfactory tubercle, the prepiriform and periamygdaloid fields (Brodal, 1947) as well as in the cortico-medial group of amygdaloid nuclei. They also reported terminations of bulbofugal fibres in the central amygdaloid nucleus and in the bed nucleus of stria terminalis as well as a commissural component terminating in the contralateral olfactory bulb. In subsequent experimental studies the much-used 1954 method of Nauta & Gyax (Nauta, 1957) has proved to be of limited value for the identification of the synaptic fields of degenerating bulbofugal fibres. Although furnishing clear pictures of degenerating axons in the olfactory tract, this method has been largely inadequate for the impregnation of the corresponding synaptic end-structures in the olfactory lobe. In view of this shortcoming it is somewhat surprising that the original, non-suppressive Nauta method (Nauta, 1950; Nauta & Gyax, 1951) which was used successfully

* Present address: Department of Psychology, Massachusetts Institute of Technology, Cambridge, Massachusetts, U.S.A.

in determining the synaptic distribution of the hippocampal commissure (Blackstad, 1956), has been used only recently in studies of the central olfactory connexions, viz. by Powell, Cowan & Raisman (1965) in the rat and by White (1965) in the same species. Although the results of these studies are in mutual agreement on major points, some noteworthy differences, possibly related to the use of two different modifications of the original Nauta method, prompted a new investigation of the problem. Of particular interest in the controversy is White's claim that the olfactory bulb projection, contrary to earlier reports, extends caudally beyond the periamygdaloid region into the entorhinal area. If confirmed, this finding would indicate a greater proximity of the hippocampus to the olfactory system than appears compatible with generally accepted notions.

The present study was undertaken with two further objectives in mind, viz. (1) a clarification of the controversial subject of interbulbar connexions in the anterior commissure; and (2) more detailed information concerning the centrifugal connexions noted first by Cajal in Golgi material and demonstrated recently in experimental studies by Cragg (1962) and Powell & Cowan (1963).

MATERIALS AND METHODS

Surgical lesions were placed, under direct vision, in the olfactory bulb, the lateral olfactory tract and in different parts of the olfactory cortex in altogether 34 adult albino rats and three young (2-4 weeks old) rats anaesthetized with Nembutal or Equithesin.* Lesions in the olfactory bulb were made with a surgical knife blade or with a specially designed scalpel in combination with suction. Lesions in the lateral olfactory tract, as well as in different parts of the olfactory cortex, were made via an infratemporal approach with the animal's head fixed in an apparatus that offered free access to the lateral side of the head. The laminar coagulation technique of Dusser de Barenne (1933, *a, b*) was used for superficial lesions in the olfactory cortex. This technique has proven especially valuable in the basal forebrain regions, where penetrating blood vessels often make it impossible to obtain superficial suction lesions without causing additional ischemic necrosis of deeper brain regions. After survival times varying from 1 to 20 d, the animals were sacrificed by an overdose of Nembutal and perfused transcardially with physiological saline followed by 10% formalin. The brains were removed and subjected to further fixation in 10% formalin for periods varying between 1 and 3 weeks. The whole forebrain was serially sectioned frontally, horizontally or sagittally, either on the freezing microtome at 15-40 μm , or after previous paraffin embedding at 5-10 μm . Every 6th section was stained by the suppressive Nauta & Gyax method (Nauta, 1957) and the original Nauta (1950) technique, or a recent modification of the latter (Fink-Heimer, 1967), respectively. Another series from each brain was stained with the Nissl or the Klüver & Barrera (1953) technique.

* A combined sodium pentobarbital-chloral hydrate anaesthetic manufactured by Jensen-Salsbery Laboratories, Kansas City, Mo., U.S.A.

RESULTS

Synaptic distribution of the centripetal olfactory bulb fibres

As the results of the present study are in general agreement with the results obtained and described in detail recently by White (1965), only a pictorial survey of the major features of the olfactory bulb projections will be presented.

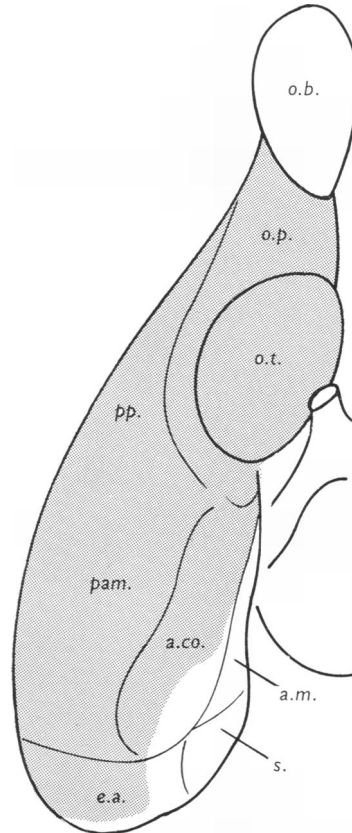


Fig. 1. A schematic representation of the projection field (stippled area) of olfactory bulb fibres in the rat. Almost all basal regions, including the ventro-lateral entorhinal area in the caudal part of the brain, represent primary olfactory cortex. *a.co.*, Cortical amygdaloid nucleus; *a.m.*, medial amygdaloid nucleus; *e.a.*, entorhinal area; *o.b.*, olfactory bulb; *o.p.*, olfactory peduncle; *o.t.*, olfactory tubercle; *pam.*, periamygdaloid cortex; *pp.*, prepiriform cortex; *s.*, subiculum.

As indicated in stippling in Fig. 1, almost the entire basal aspect of the rat's hemisphere appears to represent primary olfactory cortex. Exceptions are the posterior part of the medial amygdaloid nucleus, the postero-medial part of the cortical amygdaloid nucleus bordering the subiculum, and most of the entorhinal area in the caudal part of the brain. The distribution and appearance of terminal

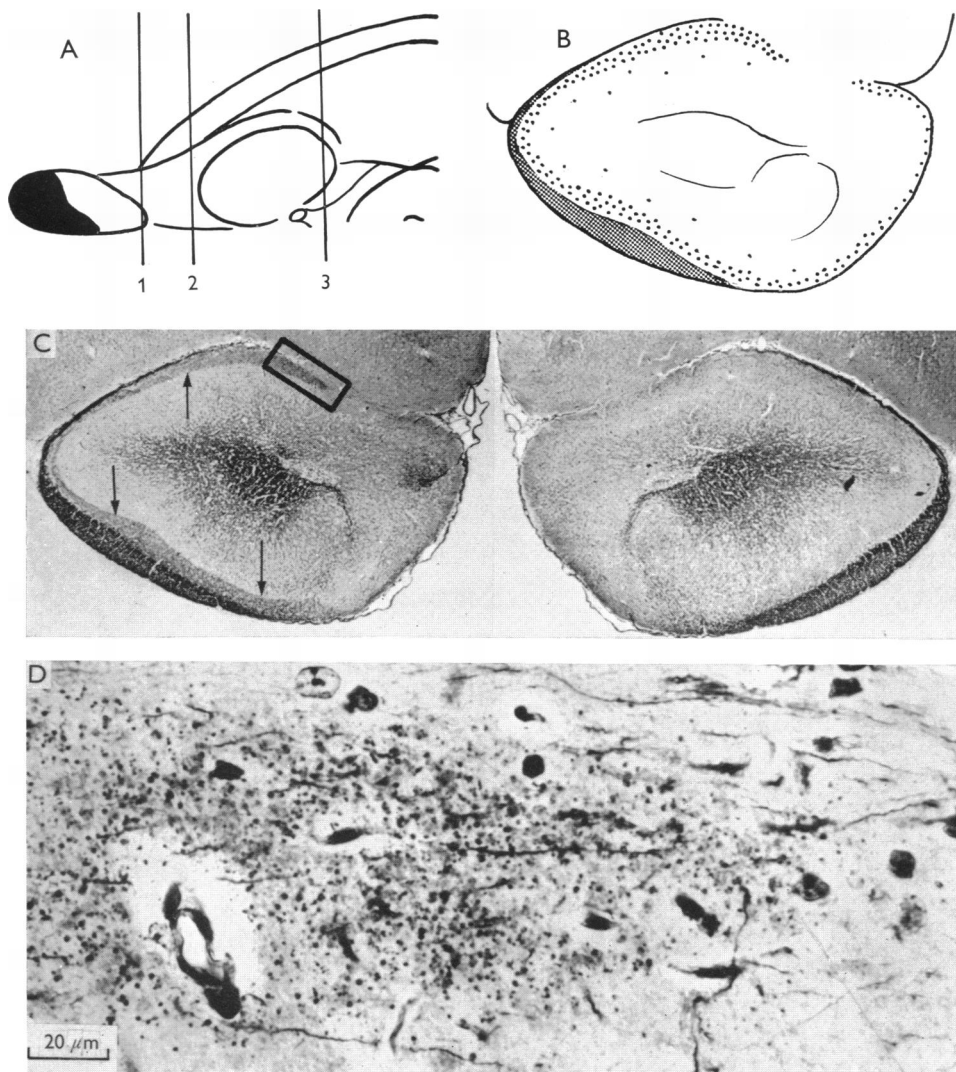


Fig. 2. Terminal degeneration in the olfactory peduncle following an ipsilateral olfactory bulb lesion 2 d before sacrifice. The rostral part of the brain, in front of the olfactory tubercle, was paraffin embedded, whereas frozen sections were prepared from the rest of the brain. A. Schematic representation of the lesion (jet black) on a drawing of the basal surface of the rat forebrain. B. Schematic representation of the terminal degeneration (dots) in a frontal section corresponding to section 2 in A. Degeneration, largely confined to the superficial part of the plexiform layer, is seen in all parts of the cortical mantle in the peduncle. C. Low-power photograph of the section shown in B. Compare with the unoperated side (right half of the photograph). Note the laminated termination pattern of olfactory tract fibres ipsilateral to the lesion (left). Arrows point to the deep border of heavy terminal degeneration. D. Photomicrograph corresponding to the rectangle in C, showing a dense terminal degeneration. Original Nauta method on paraffin-embedded material.

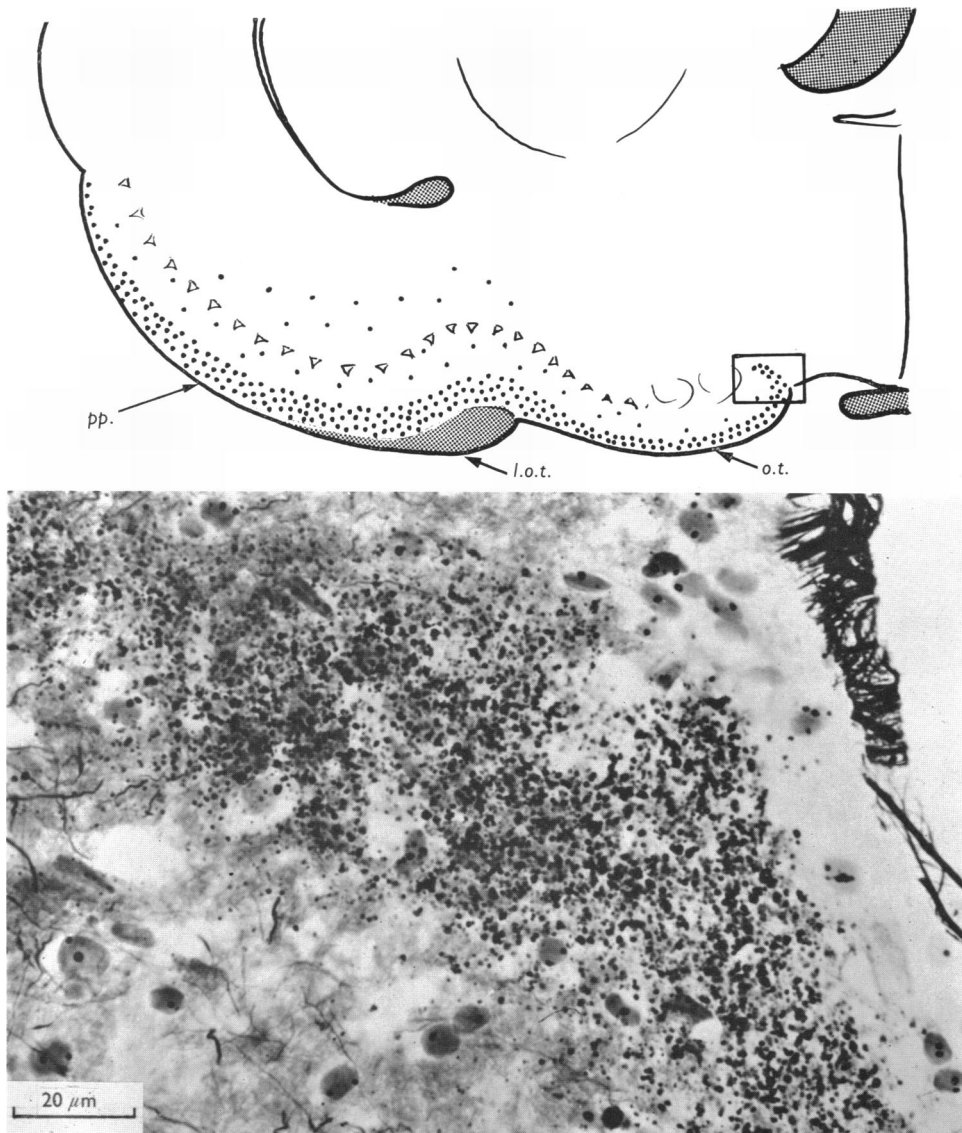


Fig. 3. Terminal degeneration in the caudal part of the olfactory tubercle, same brain as in Fig. 2, following ipsilateral olfactory bulb lesion. The high-power photograph was taken from the insert rectangle in the medial part of the olfactory tubercle. Original Nauta method on frozen sectioned material. *pp.*, Prepiriform cortex; *l.o.t.*, lateral olfactory tract; *o.t.*, olfactory tubercle.

degeneration* in different parts of the olfactory cortex 2 days after ipsilateral olfactory bulb lesions is shown in Figs. 2-7.

In the olfactory peduncle, terminal degeneration can be seen throughout the extent of the cortical mantle. The extent of the synaptic distribution in the retro-

* The term 'terminal degeneration' is used for the degeneration in both the axon arborizations and their synaptic endings (Heimer, 1967).

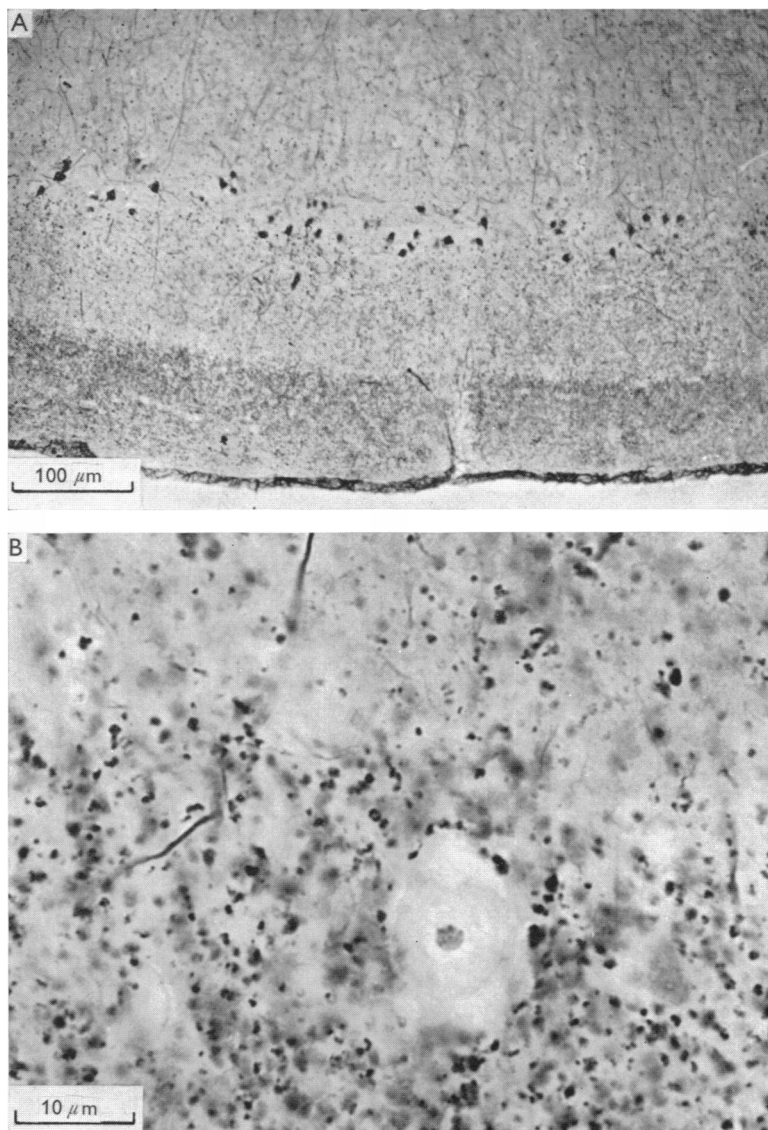


Fig. 4. A. Low-power photograph from prepiriform cortex of a rat whose ipsilateral olfactory bulb was removed 5 d before sacrifice. The well-defined dark lamina at the bottom of the figure represents dense terminal degeneration. The black cell bodies in the superficial part of the pyramidal cell layer are believed to represent the origin of centrifugal fibres to the olfactory bulb. Although a transneuronal degenerative phenomenon cannot be excluded, it seems more likely that the pronounced argyrophilia of the neurons represents a retrograde reaction following transection of the distal parts of their axons in the olfactory bulb. The increased argyrophilia is apparent very soon after large as well as small olfactory bulb lesion. B. High-power photograph of terminal degeneration in the border zone between the superficial and deep part of the plexiform layer. Modified original Nauta method (Fink-Heimer) on frozen sectioned material.

bulbar area is shown in Fig. 2B, which is a frontal section corresponding to level 2 in Fig. 2A. The dense laminar termination of olfactory bulb fibres in the superficial half of the plexiform layer, clearly demonstrated for the first time by White, is readily apparent even under low power, as shown by Fig. 2C (left half), taken from a paraffin section impregnated by the original Nauta method. Figure 2D is a high-power view of the region within the insert rectangle shown in Fig. 2C.

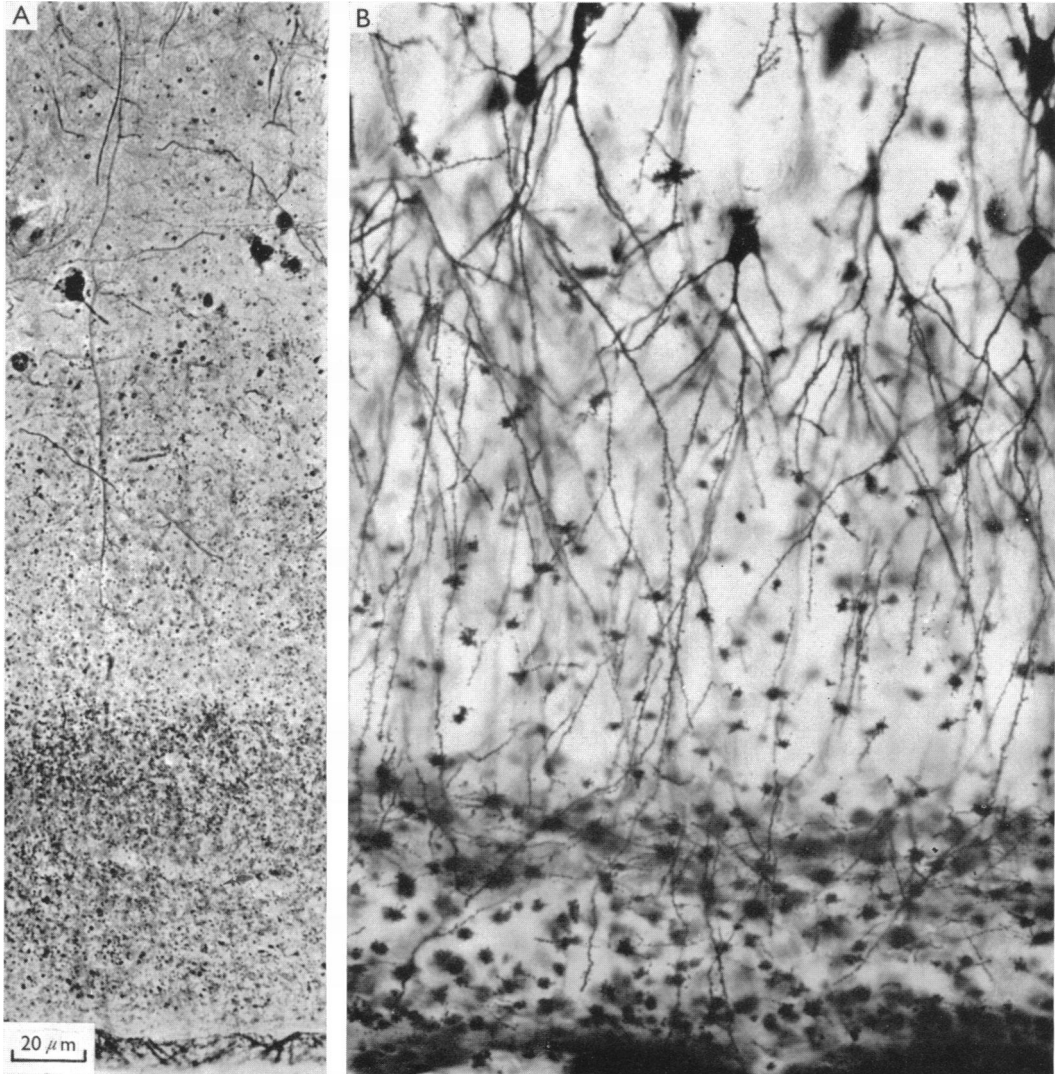


Fig. 5. A. Enlargement from Fig. 4A showing the termination pattern of olfactory tract fibres in the plexiform layer of the prepiriform cortex. The pial surface is seen at the bottom. B. A Golgi picture of the prepiriform cortex of a normal rat showing the distribution of olfactory bulb fibres in a superficial zone of the plexiform layer, among the distal arborizations of long dendrites emanating from the pyramidal cell layer. This zone corresponds to the lamina of dense terminal degeneration shown in A.

Figure 3 shows the distribution pattern of olfactory bulb fibres in a frontal section through the caudal part of the olfactory tubercle (same brain as in Fig. 2). The photomicrograph, corresponding to the insert rectangle in the semi-schematic upper figure, shows a dense terminal degeneration in the postero-medial part of the olfactory tubercle in a frozen section impregnated by the original Nauta method. (The part of the brain rostral to the olfactory tubercle was embedded in paraffin, whereas frozen sections were prepared from the rest of the brain.)

Although inspection under low power suggests that the synaptic distribution of olfactory bulb fibres is confined to the superficial part of the plexiform layer throughout the extent of the olfactory cortex, higher magnification reveals a less massive termination in the deeper part of the plexiform layer, especially in more rostral parts

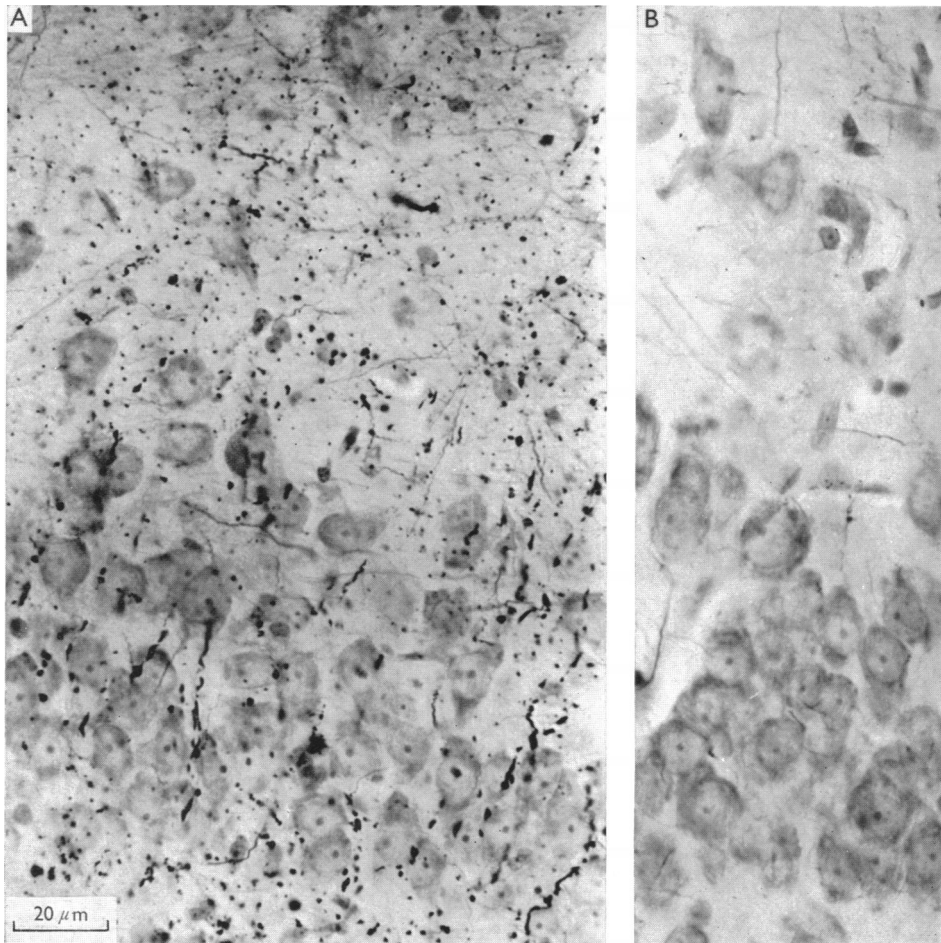


Fig. 6. A. Photomicrograph showing the deep layers of the anterior prepiriform cortex of a rat 5 d after ipsilateral olfactory bulb removal. Several degenerating fibres penetrate the pyramidal cell-layer and terminate in the deep multiform layer at the top of the figure. Modified original Nauta method (Fink-Heimer, Procedure 11) counter-stained with cresylechtviolet. B. The corresponding area on the side contralateral to the lesion.

of the piriform cortex (Figs. 4, 5). Furthermore, in the prepiriform cortex where terminating olfactory bulb fibres appear to be particularly numerous, many degenerating bulbofugal fibres penetrate the pyramidal cell layer and terminate in the deeper multiform layer (Fig. 6).

Terminal degeneration in the amygdaloid complex following an ipsilateral olfactory bulb lesion is almost completely restricted to the cortical nucleus. Although some bulbofugal fibres seem to reach the anterior part of the medial amygdaloid nucleus, by far the densest terminal degeneration following an olfactory bulb lesion is seen in

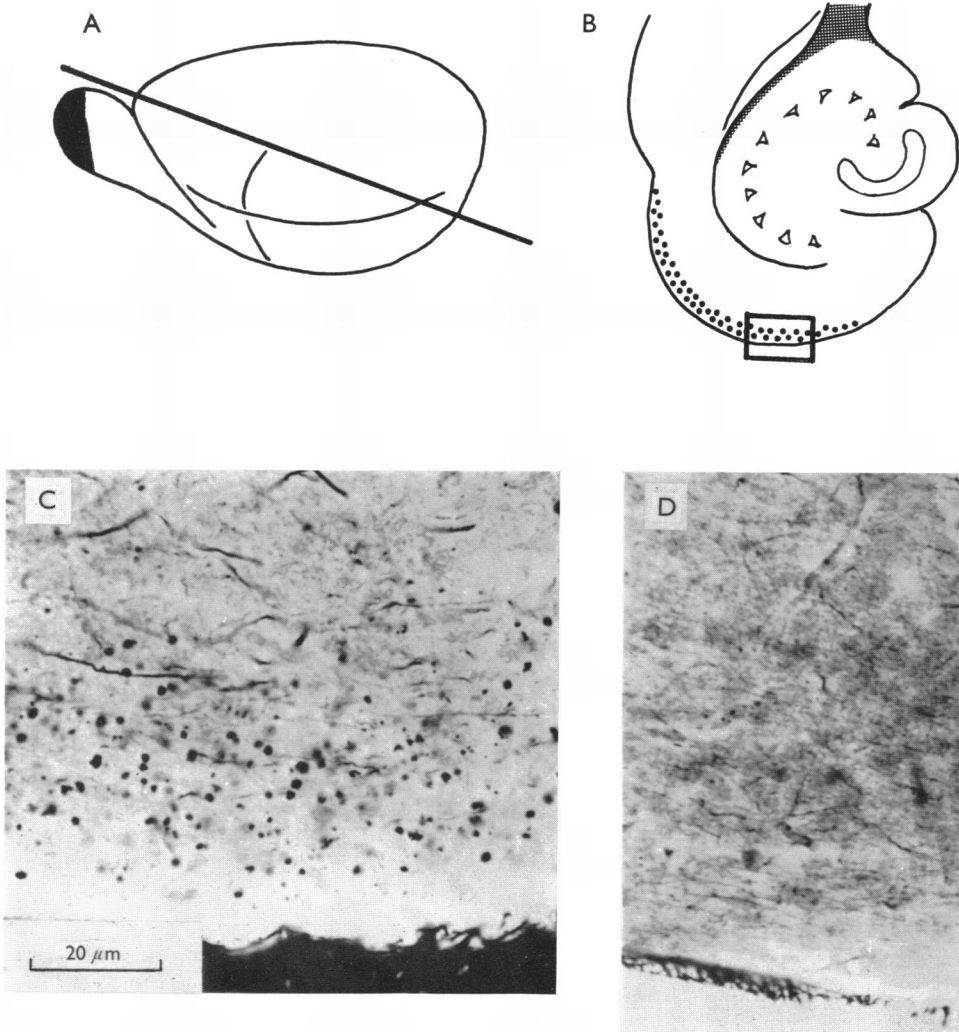


Fig. 7. Terminal degeneration in the entorhinal area following ipsilateral olfactory bulb lesion (jet black in A) 3d before sacrifice. The photomicrograph shown in C is taken from inlet rectangle in B. The plane of sectioning as well as the approximate level is indicated in A. The corresponding area contralateral to the lesion is shown in D. Original Nauta method on frozen sectioned material.

the cortical amygdaloid nucleus. A significant number of olfactory bulb fibres reach as far caudally as the ventral entorhinal area, where terminal degeneration is seen especially in its lateral part (Fig. 7).

Although some degenerating fibres can be traced across the midline in the anterior commissure in the rats with postsurgical survival times of more than 2 weeks, terminal degeneration is never seen in the contralateral olfactory bulb if the lesion is restricted to olfactory bulb tissue. On neither side can fibre degeneration be identified in the central amygdaloid nucleus, the bed nucleus of the stria terminalis, or in any other forebrain region outside the olfactory cortex.

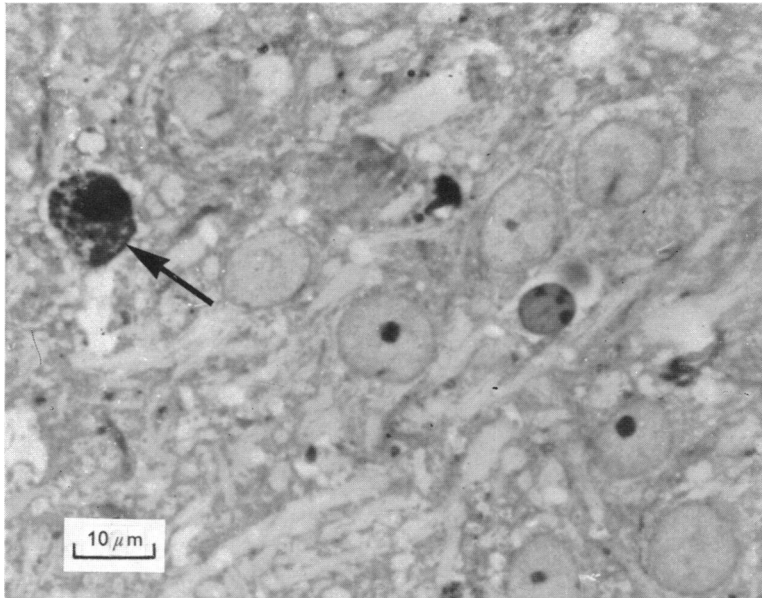


Fig. 8. A photomicrograph from the cell layer in the anterior prepiriform cortex of a rat whose ipsilateral olfactory bulb was removed 3d before sacrifice. The perikaryon to the left (arrow) is stippled with silver, and is believed to be in the degenerated state after injury to its axon as a result of the olfactory bulb lesion. The neuron corresponds to a black neuron similar to those shown in Figs. 4A and 5A. The section (about $1\ \mu\text{m}$ thick) was prepared from a previously hand-cut section which had been impregnated with the Fink-Heimer modification and embedded in an epon-araldite mixture.

An interesting finding following olfactory bulb lesions is the heavy argyrophilia of certain neurons (Fig. 4A) in the anterior part of the ipsilateral prepiriform cortex. These heavily impregnated neurons correspond to small pyramidal cells located in the superficial part of the pyramidal cell layer (Fig. 5) in the anterior part of area 51B and adjacent part of area 51A (Brodmann, 1909; Flores, 1911; Rose, 1912; Krieg, 1946). The increased argyrophilia appears a few days after the lesion and is still evident several weeks later. Besides a dense accumulation of argyrophilic granules in the cell body and proximal parts of the dendrites, pyknosis and peripheral displacement of the nucleus (Fig. 8) are often seen in such neurons, especially in cases of longer standing. The significance of this apparently degenerative phenomenon will be discussed below.

Synaptic distribution of ipsilateral centrifugal fibres

Lesions in the prepiriform cortex or the olfactory tubercle invariably result in degeneration of rostrally directed fibres, many of which extend forward into the olfactory bulb where they appear to terminate as far peripherally as the periglomerular level. Figure 9 shows degenerating fibres, impregnated with the suppressive Nauta-Gygax method, surrounding a glomerulus. The lesion in this case is a transection through the lateral olfactory tract and the prepiriform cortex lateral to the posterior part of the olfactory tubercle which has sustained slight damage in its most lateral part.

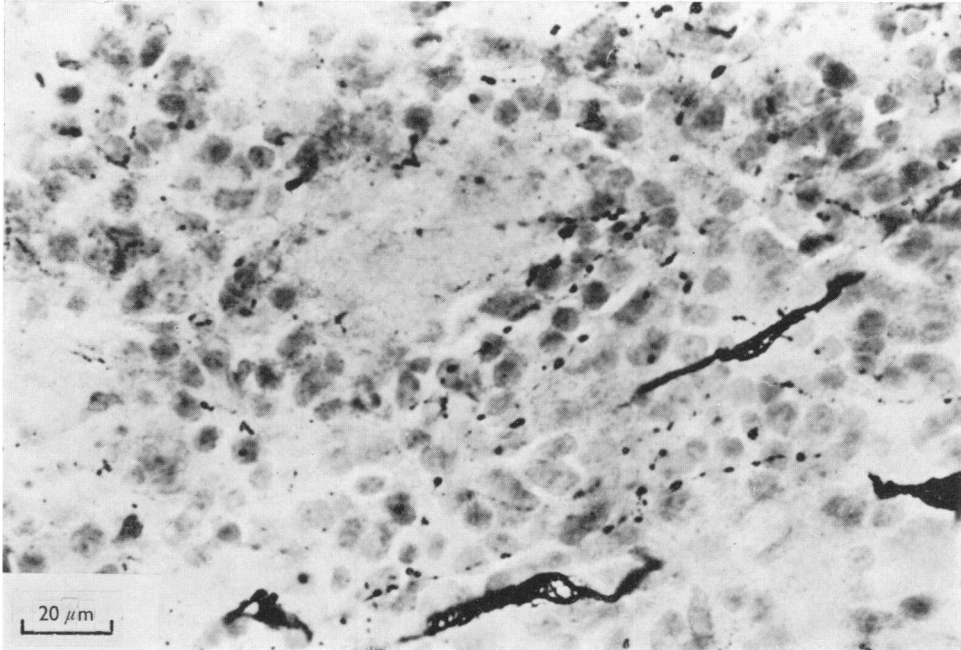


Fig. 9. Degenerating fibres around a glomerulus as a result of an ipsilateral lesion in the prepiriform cortex and the lateral olfactory tract at the level of the posterior part of the olfactory tubercle. Suppressive Nauta-Gygax method.

Attempts to determine the exact site of intrabulbar termination of the ipsilateral centrifugal fibres so far have been only partly successful in our hands. Appropriate modifications of the original Nauta method often produce convincing evidence of degenerating axon terminals in the internal granular layer, and the appearance of degenerating fibres and scattered argyrophilic particles in more superficial layers of the bulb suggests that centrifugal fibres in the olfactory system may extend as far forward as the external granule cells or even into the glomeruli. It must be emphasized, however, that the interpretation of our material is hampered by the frequency with which argyrophilic particles appear even in the olfactory bulbs of unoperated rats.

If the synaptic distribution of ipsilateral centrifugal fibres is scattered and partly indistinct in the olfactory bulb, the termination of such rostrally directed fibres in the retrobulbar area by contrast is clear-cut and massive. The dark lamina in Fig. 10C,

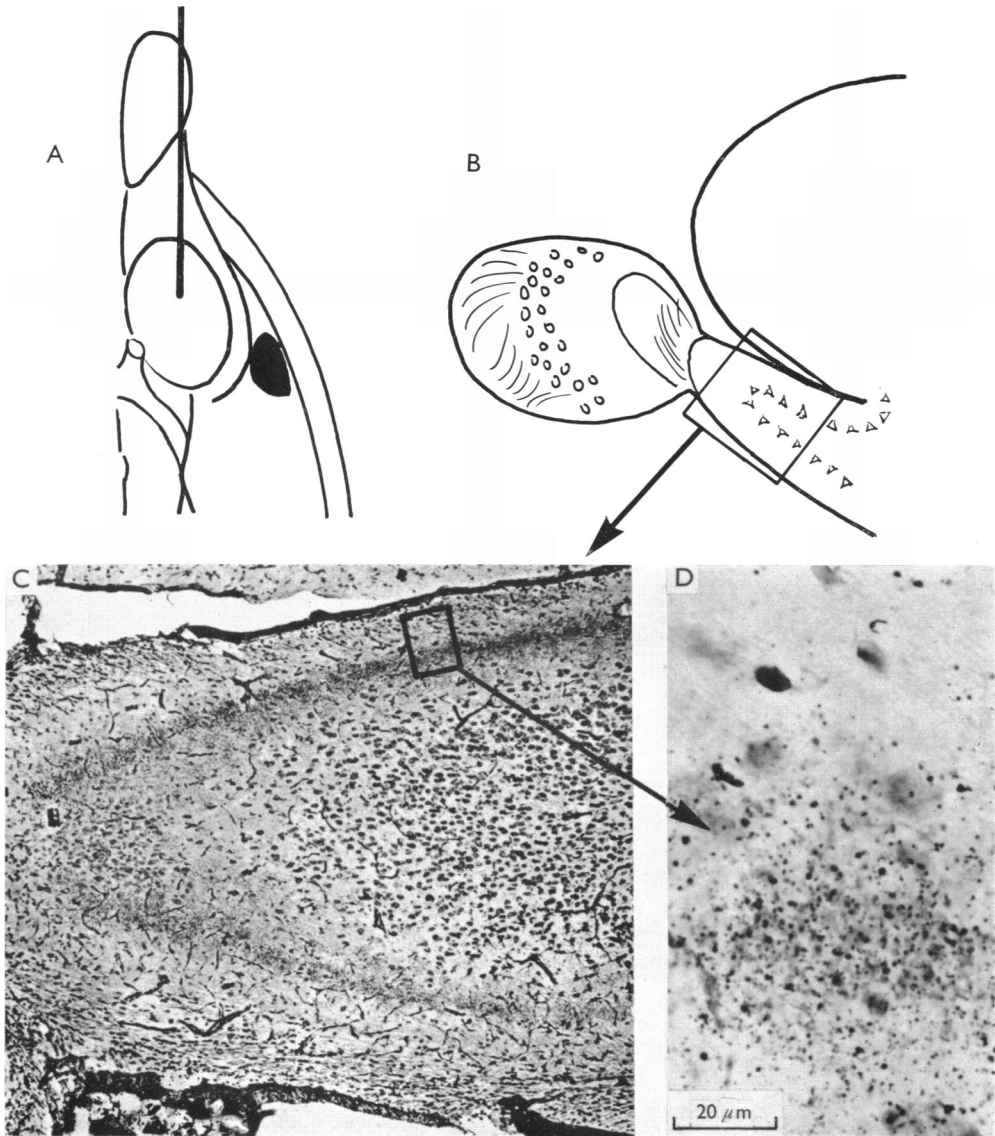


Fig. 10. Terminal degeneration in the olfactory peduncle following an ipsilateral lesion (jet black, A) in the prepiriform cortex 5d before sacrifice. The level of the schematic sagittal section in B is indicated in A. The dark band, confined to the deep part of the plexiform layer in C, represents heavy terminal degeneration. The high-power photograph in D demonstrates a relatively sharp boundary between the deep part of the plexiform layer with massive terminal degeneration and the superficial part of the plexiform layer free of degeneration (Fink-Heimer modification, Procedure 1).

a sagittal section through the olfactory peduncle, represents terminal degeneration following a lesion in the anterior part of the prepiriform cortex 5d before sacrifice (Fig. 10A). Throughout the peduncle, the major synaptic field of the centrifugal fibres occupies a distinct deep zone of the plexiform layer, but less dense

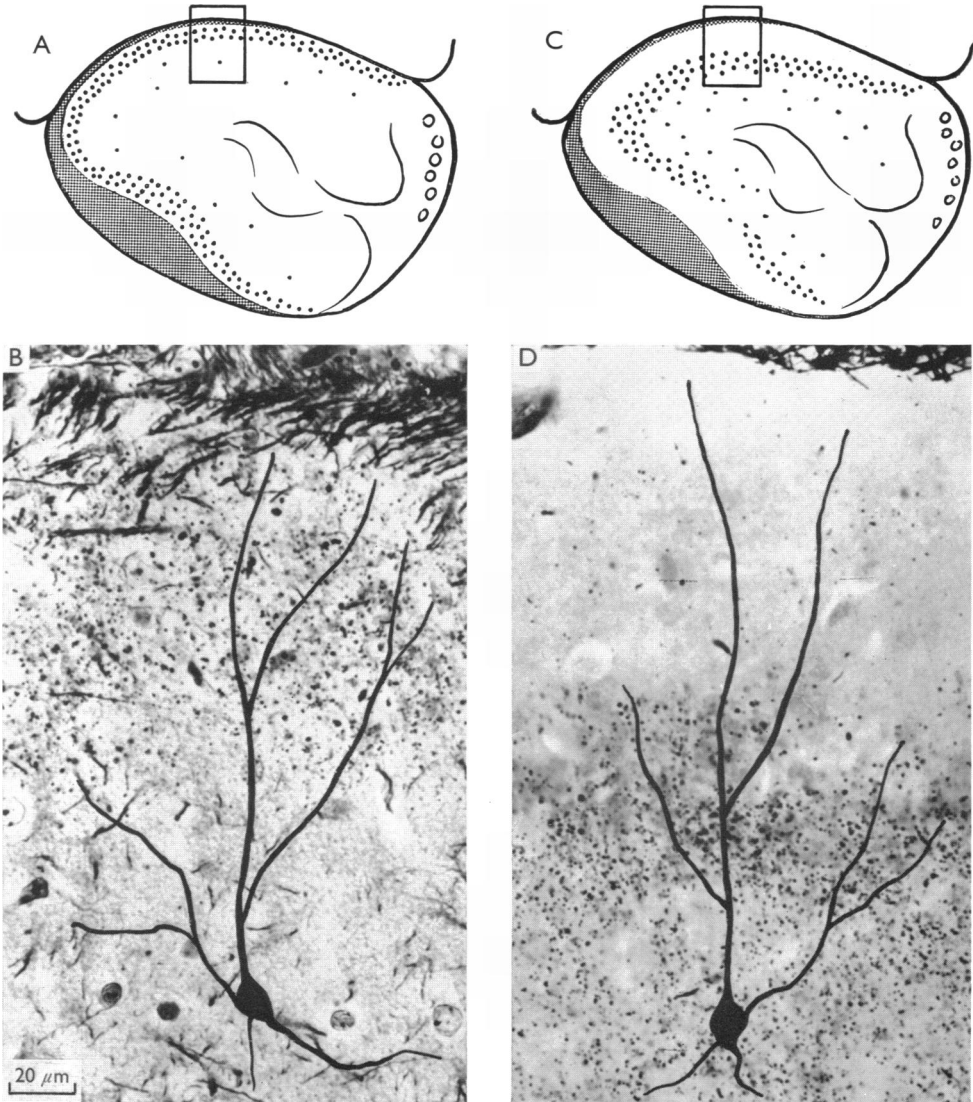


Fig. 11. A comparison between the synaptic fields of, respectively, the centripetal (A and B) and centrifugal (C and D) fibres as they appear in frontal sections through the rostral part of the olfactory peduncle (section 1 in Fig. 1). In A is shown the terminal degeneration following an olfactory bulb lesion, and in B the terminal degeneration following a lesion in the prepiriform cortex. Two neurons, drawn from Golgi-sections, are outlined on the photographs to give an idea of the dendritic fields of the pyramidal cells in the olfactory peduncle. The centripetal and the centrifugal fibres seem to affect different segments of the dendritic tree.

terminal degeneration is also seen among the cell bodies deep to the plexiform layer. The corresponding parent axons course forwards from the lesion both through the plexiform layer and as components of the lateral olfactory tract. A large number of fine and dispersed degenerating fibres, moreover, passes forwards in the cell-poor central core of the olfactory peduncle; these deepest axons are especially numerous in the zone lateral to the anterior extension of the anterior commissure.

Lesions in the olfactory tubercle result in a degeneration pattern similar to that described above. It seems impossible, however, to produce lesions in the olfactory tubercle that do not destroy a significant number of centrifugal fibres originating in basal forebrain regions caudal to the tubercle.

It is of interest to note, finally, that fibre degeneration extending into the olfactory bulb is evident in the present experiments only in cases of cortical lesions at the level of, or rostral to, the anterior amygdaloid area. No intrabulbar fibre degeneration appears following lesions in more caudal parts of the periamygdaloid fields, although such lesions cause terminal degeneration in the olfactory peduncle, especially in the latter's medial cortex.

DISCUSSION

Synaptic distribution of centripetal olfactory bulb fibres

It is generally accepted that the fibres from the olfactory bulb project on four main regions: (1) the olfactory peduncle, (2) the olfactory tubercle, (3) the prepiriform and periamygdaloid fields, and (4) the cortico-medial amygdaloid complex. A bilateral projection to the bed nucleus of stria terminalis and to the central amygdaloid nucleus, described in earlier studies with the Glees method in marsupials, carnivores, rodents and primates (Le Gros Clark & Meyer, 1947; Meyer & Allison, 1949; Adey, 1953; Allison, 1953) could not be confirmed in the present study. Nor have such connexions generally been confirmed by investigators using the original non-suppressive Nauta method (Powell, Cowan & Raisman, 1965; White, 1965) or the suppressive Nauta-Gygax method (Cragg, 1961; Lohman, 1963; Lohman & Lammers, 1967; Powell *et al.* 1965; Scalia, 1966; Mascitti & Ortega, 1966; Girgis & Goldby, 1967). Olfactory bulb projections to the bed nucleus of the stria terminalis have also been denied in a recent Glees study in the cat (Mascitti & Ortega, 1966). The positive findings obtained with the Glees method in this cell region have been attributed to a so-called pseudo-degeneration appearing in these nuclei even under apparently normal conditions (Cowan & Powell, 1956), but this explanation was refuted by Adey, Rudolph, Hine & Harris (1958), with the result that the controversy surrounding this connection persists.

The question of interbulbar connexions through the anterior commissure has also been the subject of much debate. Most text-books, in agreement with early Marchi studies in the rabbit by Probst (1901) and Cajal (1911), describe a direct connexion between the two olfactory bulbs. Already in the late nineteenth century, however, Ganser (1882) was the first among a continuously increasing number of investigators (van Gehuchten, 1904; Young, 1941; Morin, 1950; Lohman, 1963) to cast doubt upon the existence of a commissural connexion between the two olfactory bulbs, in the rabbit as well as in other mammals. Experiments by Lohman in the guinea-pig seem to indicate that the commissural fibres terminating in the

olfactory bulb have their origin in the anterior olfactory nucleus rather than in the olfactory bulb on the contralateral side. The lack of evidence for commissural connexions between the two olfactory bulbs in the present study as well as in recent studies by Powell *et al.* (1965) and by White (1965) seem to indicate that the same conclusion is justified in the rat. This is also in agreement with the results of Valverde's (1964) recent Golgi studies in the cat. In hindsight, it appears that earlier descriptions of an interbulbar connexion may have referred to a small number of degenerating fibres that can be followed across the midline in the anterior commissure in rats that have survived an olfactory bulb lesion for more than 2 weeks. In a recent study A. H. M. Lohman (personal communication) has observed that these 'late-degenerating' bulbar efferents terminate in the rostro-lateral region of the contralateral olfactory peduncle, and thus appear not to represent a true interbulbar commissure.

Although most investigators thus seem to restrict the projection fields of the olfactory bulb fibres to the primitive cortex of the ipsilateral piriform lobe including the cortical amygdaloid nucleus, there is still disagreement regarding the limits of the projection. It is, unfortunately, not always clear whether the existing controversies should be explained by inter-specific differences or by dissimilarities in the capacities of the methods employed to demonstrate terminal degeneration. The importance of technological factors is well illustrated by a comparison of two recent publications dealing with olfactory bulb projections in the rat (White, 1965; Powell *et al.* 1965). Although both studies were performed with the original non-suppressive Nauta technique for the impregnation of degenerating axon terminals, White, in agreement with the present study, describes a more extensive distribution field of olfactory bulb fibres than was identified by Powell *et al.* With respect to the rostral part of the olfactory cortex, Powell *et al.*, in agreement with most previous investigators, limit olfactory bulb projections to the lateral part of the anterior olfactory nucleus, and to the antero-lateral part of the olfactory tubercle. The present study, confirming White's results, shows the whole cortical mantle of the olfactory peduncle, as well as the entire olfactory tubercle, to be within the field of olfactory bulb projections. White's finding of bulbofugal fibres terminating in the ventral entorhinal area is likewise confirmed in the present study, and appears not to have been confirmed by Powell *et al.*

It seems difficult to explain the controversies just reported. The differences, however, may partly be explained on the basis of different embedding media. Powell *et al.* applied the original Nauta method on paraffin embedded material, whereas frozen sections were used in the study of White and in the present study. Although degenerating axon terminals can be impregnated in paraffin sections (Blackstad, 1958; Heimer, 1967), in many regions terminal degeneration seems to be more easily revealed in frozen sections. Differences in surgical approach as well as in post-surgical survival time, both of which undoubtedly are of importance in experimental neuro-anatomical studies, may also have played a role in the apparent discrepancies.

The results of several recent physiological and behavioural experiments have indicated a close relationship between the olfactory apparatus and hypothalamic functions, in particular the regulation of reproduction (Lee & Boot, 1955; Whitten,

1956; Bruce & Parrott, 1960; Parker & Bruce, 1961; Barraclough & Cross, 1963; Heimer & Larsson, 1967). Cajal considered the stria terminalis to be an important pathway by which olfactory impulses could influence the activity of the hypothalamus. At least part of the stria terminalis appears to originate in the cortico-medial amygdaloid region (Cowan, Raisman & Powell, 1965; Valverde, 1965), which has been shown to receive a significant afflux of olfactory bulb fibres. A large extent of the medial hypothalamus back to and including the ventral premammillary region appears to lie within the distribution field of stria terminalis fibres (Heimer & Nauta, 1967). Impulses originating in the cortico-medial amygdaloid region as a result of activity in the olfactory system, and propagated via stria terminalis, may therefore be of immediate significance for the functional state in the medial zone of the hypothalamus.

The olfactory tubercle may be another important link in the relationship between the olfactory system and the hypothalamus. It appears likely that fibres originating in the olfactory bulb, especially those terminating in the caudo-medial part of the tubercle, establish synaptic contacts with neurons projecting into the rostral part of the medial forebrain bundle, and thus form part of an oligosynaptic pathway between the olfactory bulb and the lateral hypothalamus. Evidence of additional connexions between the olfactory bulb and the medial forebrain bundle via the prepiriform cortex have been reported both from Golgi studies of normal material and from experimental studies (Valverde, 1965; Powell, Cowan & Raisman, 1963).

Partly as the result of experimental analysis of the projections from the olfactory bulb, the traditional view of a close relationship between the hippocampus and the sense of smell has come under severe criticism during the recent decades (see, for example, Brodal, 1947). It is therefore of interest that both White's (1965) study and the present experiments have disclosed a projection, however moderate, of olfactory bulb fibres to the ventral entorhinal area. As the entorhinal area has long been known to be the origin of a massive projection to the hippocampal formation (Cajal, 1911), this finding suggests that, in the rat at least, the olfactory bulb indeed stands in close neural proximity to the hippocampal mechanism. It is, of course, conceivable that the relatively oligosynaptic connexion in the rat is supplemented, and in higher animals even supplanted, by more polysynaptic pathways (Cragg, 1961; Powell *et al.* 1965).

Synaptic distribution of centrifugal fibres in the olfactory system

In addition to the thin centrifugal fibres in the anterior commissure, Cajal's Golgi studies revealed a system of thick centrifugal fibres running in or near the lateral olfactory tract. Several recent electro-physiological studies (Green, Mancina & von Baumgarten, 1962; Kerr & Hagbarth, 1955; Shepherd, 1963; Phillips, Powell & Shepherd, 1963) have re-activated interest in the morphology of these centrifugal fibres within the olfactory system.

The ipsilateral centrifugal fibre system has recently been verified in experimental anatomical studies in rodents, and its terminal distribution has been reported to involve all parts of the olfactory bulb and to reach peripherally as far as the periglomerular level (Cragg, 1962; Powell *et al.* 1965). Interruption of the proximal

parts of the centrifugal axons in the basal forebrain regions in the present study results in the appearance of a moderate number of degenerating fibres throughout the olfactory bulb; some of these can be traced into the immediate vicinity of glomeruli. Although unquestionable terminal degeneration is seen in the internal granular layer, no definitive conclusions as to the sites of termination in the superficial layers can be reached. This may be due in part to the small quantity of degeneration discernible within the superficial layers of the olfactory bulb, but the difficulty of accurate identification of synaptic sites in the bulb is greatly augmented by the erratic appearance of argyrophilic bodies in apparently normal olfactory bulb tissue.

The present study has not included a systematic analysis of the various fibre systems distributed to the olfactory bulb from more caudal ipsi- as well as contralateral olfactory structures. However, in agreement with Cragg's (1962) report, the present findings indicate that uncrossed fibres to the olfactory bulb arise in the anterior prepiriform cortex. The field of origin of such bulbo-petal fibres appears to have its caudal limit a short distance behind the olfactory tubercle; it corresponds in extent to the anterior part of area 51 B together with the adjoining part of 51 A which is covered by the lateral olfactory tract. A contribution of the tubercle to this projection is suggested by our findings, but the evidence is entirely inconclusive because of the difficulty of producing lesions of the tubercle that do not involve deep-lying fibres of passage originating elsewhere.

It is of interest to note that the region of prepiriform cortex identified as the most likely site of origin of bulbo-petal fibres corresponds to the area in which olfactory bulb lesions cause a heavy argyrophilia of certain small and superficially located pyramidal cells. The dark appearance of these neurons in silver-impregnated sections (see Figs. 4-5) is due to a corpuscular silver deposit in the perikarya and proximal dendrite segments. The frequent observation of eccentric displacement and pyknosis of the nucleus (Fig. 8) suggests that the cells in question are exhibiting a retrograde reaction and, hence, are the originators of bulbo-petal fibres. Electron microscopic study shows that the normally fine structure of these cells has been replaced by electron dense amorphous material. A somewhat comparable phenomenon of increased argyrophilia was observed recently by Grant (1965) in the perikarya of brainstem neurons undergoing retrograde chromatolysis.

Although characterized by their distribution to the olfactory bulb, and by their relatively circumscribed locus of origin, the bulbopetal fibres here discussed could nevertheless be interpreted as components of a more general system of forward conduction in the central olfactory apparatus. This associative fibre system involves at least the entire extent of the prepiriform and periamygdaloid cortices, the olfactory tubercle and the primitive cortex of the olfactory peduncle. Despite its widespread origin and distribution, this fibre system exhibits a remarkable specificity in the form of a synaptic termination which involves almost exclusively the deep stratum of the plexiform layer, in the prepiriform cortex as well as in the olfactory tubercle and olfactory peduncle. From a comparison of the experimental material with appropriate Golgi sections it must be concluded that the synaptic contacts of the forward-conducting association fibres favour proximal segments of the pyramidal cells, in contrast to olfactory tract fibres which have their main synaptic termination

on more peripheral dendrite ramifications. In Fig. 11 this difference is emphasized by superimposing a projection drawing of pyramidal cells on photographs of silver-impregnated sections. It is tempting to suggest that the deep-terminating association fibres could have a modulating effect upon the response of pyramidal cells to their afflux of olfactory impulses.

SUMMARY

1. The central fibre connexions of the olfactory bulb in the rat were studied with reduced silver methods.

2. A dense laminar termination of olfactory bulb fibres was demonstrated in the plexiform layer of: (1) the olfactory peduncle, (2) the olfactory tubercle, (3) the prepiriform and periamygdaloid fields, (4) the cortical amygdaloid nucleus and (5) the ventro-lateral entorhinal area. A moderate terminal degeneration was also found in the multiform layer of the prepiriform cortex (anterior part of area 51B and adjacent part of area 51A). No evidence was found for the existence of a commissural connexion between the two olfactory bulbs.

3. A bulbo-petal fibre system, originating in the prepiriform cortex, is part of a forward directed association system in the olfactory apparatus that involves at least the entire extent of the prepiriform and periamygdaloid cortices, the olfactory tubercle and the olfactory peduncle. In contrast to the olfactory tract fibres, which have their main synaptic termination on peripheral dendrite ramifications in the plexiform layer, the forward-conducting association fibres favour proximal segments of the pyramidal cells.

Part of this work was done while the author was supported by a Training Fellowship from the Foundations Fund for Research in Psychiatry, New Haven, Conn.

This work was supported by PHS Grant no. NB-06542-01 and by a Grant from the Medical Faculty at the University of Göteborg.

The author is indebted to Dr Walle J. H. Nauta for his generous help and encouragement, and to Dr A. H. M. Lohman for helpful discussions. Skilful assistance was provided by Marja Rydberg and Anneliese Hanf.

REFERENCES

- ADEY, W. R. (1953). An experimental study of the central olfactory connections in a Marsupial (*Trichosurus vulpecula*). *Brain* **76**, 311-336.
- ADEY, W. R., RUDOLPH, A. F., HINE, T. F. & HARRIS, N. J. (1958). Glees staining of the monkey hypothalamus: a critical appraisal of normal and experimental material. *J. Anat.* **92**, 219-235.
- ADRIAN, E. D. (1942). Olfactory reactions in the brain of the hedgehog. *J. Physiol., Lond.* **100**, 459-473.
- ALLEN, W. F. (1943). Distribution of cortical potentials from insufflation of vapors into the nostrils and from stimulation of the olfactory bulb and the pyriform lobe. *Am. J. Physiol.* **139**, 553-555.
- ALLISON, A. C. (1953). The structure of the olfactory bulb and its relationship to the olfactory pathways in the rabbit and the rat. *J. comp. Neurol.* **98**, 309-352.
- BARRACLOUGH, C. A. & CROSS, B. A. (1963). Unit activity in the hypothalamus of the cyclic female rat: effect of genital stimuli and progesterone. *J. Endocr.* **26**, 339-359.
- BLACKSTAD, T. W. (1956). Commissural connections of the hippocampal region in the rat, with special reference to their mode of termination. *J. comp. Neurol.* **105**, 417-537.
- BLACKSTAD, T. W. (1958). On the termination of some afferents to the hippocampus and fascia dentata. An experimental study in the rat. *Acta anat.* **35**, 202-214.
- BRODAL, A. (1947). The hippocampus and the sense of smell. *Brain* **70**, 179-222.

- BRODMANN, K. (1909). *Vergleichende Lokalisationslehre der Grosshirnrinde in ihren Prinzipien dargestellt auf Grund der Zellenbau*. Leipzig: J. A. Barth.
- BRUCE, H. M. & PARROTT, D. V. M. (1960). Role of olfactory sense in pregnancy block by strange males. *Science, N. Y.* **131**, 1526.
- CAJAL, S. RAMON Y. (1911). *Histologie du système nerveux de l'homme et des vertébrés*. Tome 11. Paris: A. Maloire.
- CLARK, W. E. LE GROS & MEYER, M. (1947). The terminal connections of the olfactory tract in the rabbit. *Brain* **70**, 304–328.
- COWAN, W. M. & POWELL, T. P. S. (1956). A note on terminal degeneration in the hypothalamus. *J. Anat.* **90**, 188–192.
- COWAN, W. M., RAISMAN, G. & POWELL, T. P. S. (1965). The connexions of the amygdala. *J. Neurol. Neurosurg. Psychiat.* **28**, 137–151.
- CRAGG, B. G. (1961). Olfactory and other afferent connections of the hippocampus in the rabbit, rat and cat. *Expl Neurol.* **3**, 588–600.
- CRAGG, B. G. (1962). Centrifugal fibres to the retina and olfactory bulb, and composition of the supra-optic commissures in the rabbit. *Expl Neurol.* **5**, 406–427.
- DUSSER DE BARENNE, F. G. (1933a). Laminal destruction of the nerve cells of the cerebral cortex. *Science, N. Y.* **77**, 546–547.
- DUSSER DE BARENNE, F. G. (1933b). Selektive Abtötung der Nervenzellschichten der Grosshirnrinde. Die Methode der laminaren Thermokoagulation der Rinde. *Z. ges. Neurol. Psychiat.* **147**, 280–290.
- ELLIOT SMITH, G. (1909). The tuberculum olfactorium. *Anat. Anz.* **34**, 200–206.
- FINK, R. P. & HEIMER, L. (1967). Two methods for selective silver impregnation of degenerating axons and their synaptic endings in the central nervous system. *Brain Res.* **4**, 369–374.
- FLORES, A. (1911). Die Myeloarchitektonik und die Myelogenie des Cortex Cerebri beim Igel. *J. Psychol. Neurol., Lpz.* **17**, 215–247.
- FOX, C. A., MCKINLEY, W. A. & MAGOUN, H. W. (1944). An oscillographic study of the olfactory system of cats. *J. Neurophysiol.* **7**, 1–16.
- FOX, C. A. & SCHMITZ, J. T. (1943). A Marchi study of the distribution of the anterior commissure in the cat. *J. comp. Neurol.* **79**, 297–314.
- GANSER, S. (1882). Vergleichende anatomische studien über das Gehirn des Maulwurfs. *Morph. Jb.* **7**, 591–725.
- GEHUCHTEN, A. VAN (1904). Contribution à l'étude des voies olfactives. *Névrxaxe*. vi, 193–200.
- GIRGIS, M. & GOLDBY, F. (1967). Secondary olfactory connexions and the anterior commissure in the coypu (*Myocastor coypus*). *J. Anat.* **101**, 33–44.
- GLEES, P. (1946). Terminal degeneration within the central nervous system as studied by a new silver method. *J. Neuropath. exp. Neurol.* **5**, 54–59.
- GRANT, G. (1965). Degenerative changes in dendrites following axonal transection. *Experientia* **21**, 1–4.
- GREEN, J. D., MANCIA, M. & VON BAUMGARTEN, R. (1962). Recurrent inhibition in the olfactory bulb. I. Effects of antidromic stimulation of the lateral olfactory tract. *J. Neurophysiol.* **25**, 467–488.
- HASAMA, BUN-ICHI (1934). Über die elektrischen Begleiterscheinungen an der Riechosphäre bei der Geruchsempfindung. *Pflügers Arch. ges. Physiol.* **234**, 748–755.
- HEIMER, L. (1967). Silver impregnation of terminal degeneration in some forebrain fiber systems: a comparative evaluation of current methods. *Brain Res.* **5**, 86–108.
- HEIMER, L. & LARSSON, K. (1967). Mating behaviour of male rats after olfactory bulb lesions. *Physiol. Behav.* **2**, 207–209.
- HEIMER, L. & NAUTA, W. J. H. (1967). The hypothalamic distribution of the stria terminalis in the rat. *Anat. Rec.* **157**, 259.
- KERR, D. T. B. & HAGBARTH, K. E. (1955). An investigation of olfactory centrifugal fibre system. *J. Neurophysiol.* **18**, 362–374.
- KRIEG, W. J. S. (1946). Connections of the cerebral cortex. I. The albino rat. A. Topography of the cortical areas. *J. comp. Neurol.* **84**, 221–276.
- LEE, S. VAN DER & BOOT, L. M. (1955). Spontaneous pseudopregnancy in mice. *Acta physiol. pharmac. neerl.* **4**, 442.
- LOHMAN, A. H. M. (1963). The anterior olfactory lobe of the guinea pig. Thesis. Nijmegen.
- LOHMAN, A. H. M. & LAMMERS, H. J. (1967). On the structure and fibre connections of the olfactory centres in mammals. In *Sensory Mechanisms. Prog. in Brain Res.* **23**, 65–82.
- MASCITTI, T. A. & ORTEGA, S. N. (1966). Efferent connections of the olfactory bulb in the cat. *J. comp. Neurol.* **127**, 121–135.
- MEYER, M. & ALLISON, A. C. (1949). An experimental investigation of the connections of the olfactory tract in the monkey. *J. Neurol. Neurosurg. Psychiat.* **12**, 274–286.

- MORIN, F. (1950). An experimental study of hypothalamic connections of the guinea pig. *J. comp. Neurol.* **92**, 193–213.
- NAUTA, W. J. H. (1950). Über die sogenannte terminale Degeneration im Zentralnervensystem und ihre Darstellung durch Silberimprägnation. *Schweizer Arch. Neurol. Psychiat.* **66**, 353–376.
- NAUTA, W. J. H. (1957). Silver impregnation of degenerating axons. In *W. F. Windle New Research Techniques of Neuroanatomy*. Springfield.
- NAUTA, W. J. H. & GYGAX, P. A. (1951). Silver impregnation of degenerating axon terminals in the central nervous system: (1) Technic. (2) Chemical notes. *Stain Technol.* **126**, 5–11.
- PARKER, A. S. & BRUCE, H. M. (1961). Olfactory stimuli in mammalian reproduction. *Science, N.Y.* **134**, 1049–1054.
- PHILLIPS, C. G., POWELL, T. P. S. & SHEPHERD, G. M. (1963). Responses of ventral cells to stimulation of the lateral olfactory tract in the rabbit. *J. Physiol., Lond.* **168**, 65–88.
- POWELL, T. P. S. & COWAN, W. M. (1963). Centrifugal fibers in the lateral olfactory tract. *Nature, Lond.* **199**, 1296–1297.
- POWELL, T. P. S., COWAN, W. M. & RAISMAN, G. (1963). Olfactory relationships of the diencephalon. *Nature, Lond.* **199**, 710–712.
- POWELL, T. P. S., COWAN, W. M. & RAISMAN, G. (1965). The central olfactory connections. *J. Anat.* **99**, 791–813.
- PROBST, M. (1901). Zur Kenntniss des Faserverlaufes des Temporallappens des Bulbus olfactorius, der vorderen Commissur und des Fornix nach entsprechenden Exstirpationen und Durchschneidungsversuchen. *Arch. Anat. Physiol.* pp. 338–356.
- ROSE, M. (1912). Histologische Lokalisation der Grosshirnrinde bei kleinen Säugetieren. *J. Psychol. Neurol., Lpz.* **19**, 391–479.
- ROSE, J. E. & WOOLSEY, C. N. (1943). Potential changes in the olfactory brain produced by electrical stimulation of the olfactory bulb. *Fedn Proc. Fedn Am. Socs exp. Biol.* **2**, 42.
- SCALIA, F. (1966). Some olfactory pathways in the rabbit brain. *J. comp. Neurol.* **126**, 285–310.
- SHEPHERD, G. M. (1963). Neuronal system controlling mitral cell excitability. *J. Physiol., Lond.* **168**, 101–117.
- VALVERDE, F. (1964). The commissura anterior, pars bulbaris. *Anat. Rec.* **148**, 406–407.
- VALVERDE, F. (1965). *Studies on the Piriform Lobe*. Cambridge, Mass.: Harvard University Press.
- WHITE, L. E. JR. (1965). Olfactory bulb projections of the rat. *Anat. Rec.* **152**, 465–480.
- WHITTEN, W. K. (1956). The effect of removal of the olfactory bulbs on the gonads of mice. *J. Endocr.* **14**, 160–163.
- YOUNG, M. W. (1941). Degeneration of the fiber tracts following experimental transection of the olfactory bulb. *Anat. Rec.* **79**, 65–66.