

A comparative survey of the mast cells of the mammalian brain

J. A. KIERNAN

*Department of Anatomy, The University of Western Ontario,
London 72, Ontario, Canada*

(Accepted 30 May 1975)

INTRODUCTION

Mast cells are abundant in the connective tissues of nerves and ganglia throughout the peripheral nervous system in man and all other vertebrates which have been studied (see Olsson, 1968, 1971, for review of normal and pathological appearances). However, mast cells do not occur in the normal human brain (Squartini & Giacanelli, 1956) or in the brains of most other mammals (Zimmerman, 1908; Nagayo, 1928), though they are found in the lesions of several diseases (Neumann, 1890). The presence of mast cells has been noted around arteries and veins in the cerebral hemispheres of various species (Kelsall & Lewis, 1964; Kelsall, 1966; Ibrahim, 1974; Krüger, 1974), in the area postrema (Cammermeyer, 1972) and in the diencephalon of an insectivore, the hedgehog (Krabbe, 1928; Campbell & Kiernan, 1966; Krüger, 1970). Electron microscopy reveals that some of the mast cells in the last-mentioned situation occur adjacent to capillaries while others are truly within the parenchyma of the brain, being surrounded entirely by the cytoplasmic processes of neurons and neuroglia (Flood & Krüger, 1970; Kiernan, 1971). Other pericapillary cells (Cammermeyer, 1966; Ibrahim, 1970; Dropp, 1972) are not now considered to be mast cells (see Discussion).

Hitherto there has been no single report of a search for mast cells, using proper criteria for their identification, in the brains of a wide variety of mammalian species. The results of such a survey will now be presented.

MATERIALS AND METHODS

The origins and numbers of animals studied, and the methods of killing and fixation and planes of sectioning are given in Table 1. With the smaller species, the whole brain was examined, while with the larger species (tree-shrew, loris, monkey, man, guinea-pig, coypu, dog, fox, cat) only the diencephalic region and the olfactory bulbs were studied. A piece of the tongue, which always contains many mast cells (see Selye, 1965), was processed alongside the central nervous tissue in every case (excepting the human specimens) in order to preclude the possibility that negative results might be due to artefacts of fixation, dehydration or staining.

Serial paraffin sections 7 μm thick were mounted on slides and alternate slides were stained with toluidine blue 0 (Heap & Kiernan, 1973) for metachromasia and

Table 1. *Details of animals used in survey*

Order, family and species	Number of individuals	Status*	Mode of death†	Fixation‡
Insectivora				
Erinaceidae				
<i>Erinaceus europaeus</i> (hedgehog)	16§	WC	E; P	Car; Form; Glut.
Soricidae				
<i>Sorex vulgaris</i> (shrew)	3	W	C	Car (Decalc)
Primates				
Tupaiaidae				
<i>Tupaia glis</i> (tree-shrew)	1	WC	P	Alc. B
Lorisidae				
<i>Nycticebus coucang</i> (slow loris)	4	WC	P	Alc. B; Car
Cercopithecidae				
<i>Macaca mulatta</i> (rhesus monkey)	4	WC	P	Alc. B; Car; Susa
Hominidae				
<i>Homo sapiens</i>	2	H	PM	Form
Rodentia				
Cricetidae				
<i>Meriones unguiculatus</i> (Mongolian gerbil)	3	C	D	Car
<i>Mesocricetus auratus</i> (Syrian hamster)	3	C	E	Alc. B
<i>Microtus agrestis</i> (vole)	2	W	C	Car
<i>Peromyscus maniculatus</i> (deer-mouse)	8	C	D	Car (Decalc)
Muridae				
<i>Mus musculus</i> (albino Swiss mouse)	2	C	E	Meth
<i>Rattus norvegicus</i> (albino Wistar rat)	8	C	E	Car; Form
Caviidae				
<i>Cavies porcellus</i> (guinea-pig)	2	G	E	Alc. B; Car
Capromyidae				
<i>Myocastor coypus</i> (coypu)	1	W	P	Car
Carnivora				
Canidae				
<i>Canis familiaris</i> (dog)	1	C	P	Form
<i>Vulpes vulpes</i> (red fox)	2	W	P	Car
Mustelidae				
<i>Mustela putorius furo</i> (ferret)	6	C	P	Car; Susa
Felidae				
<i>Felis catus</i> (domestic cat)	3	C	P	Car

* C, bred in captivity; W, wild; WC, wild animals subsequently kept in captivity; H, hospitalized patients who died from non-neurological diseases.

† C, killed by a cat and brought in warm and with head undamaged; D, cervical dislocation; E, overdosage with ether vapour; P, overdosage with intraperitoneal pentobarbitone sodium; PM, human necropsy material.

‡ Cerebral and lingual tissues fixed by immersion for 18 hours unless otherwise stated. Car, Carnoy's fluid; Form, 10% aqueous formaldehyde; Alc. B, alcoholic Bouin's fluid; Susa, Heidenhain's Susa; Meth, absolute methanol; Decalc., cranium, including brain, decalcified in formic acid-sodium formate and sectioned without removing brain; Glut, perfused with and tissues subsequently immersed in, phosphate-buffered glutaraldehyde-formaldehyde mixture.

§ This number includes some of the hedgehogs used in earlier studies (Campbell & Kiernan, 1966; Kiernan, 1971).

with Alcian blue 8GX, pH 2.5 (Pearse, 1968) (sometimes counterstained with periodic acid-Schiff and haematoxylin).

RESULTS

With both toluidine blue and Alcian blue staining methods, mast cells were detected in abundance in the connective tissue of the tongues of all the individuals of all the species studied. The methods used therefore should have detected any mast cells present in the central nervous systems of the same animals. Mast cells were considered to be those cells which contained cytoplasmic granules which exhibited γ -metachromasia (pink or red) with toluidine blue and were also stained by Alcian blue. Cells with these tinctorial properties are the only ones which accord with the generally accepted definition of mast cells (Selye, 1965).

In the shrew, deer-mouse, hamster, gerbil, rat, mouse, vole and ferret, the whole brain was examined but no mast cells were found. Only the olfactory bulb and diencephalon were examined in the guinea-pig, coypu, dog, fox, cat, monkey and man and again no mast cells were found. Colloid cysts, 10–100 μm in diameter, containing amorphous, metachromatic, alcianophilic material were occasionally seen in the central parts of the canine and human olfactory bulbs and in the human epithalamus (which was poorly fixed in the specimens available). None of these cysts resembled mast cells.

In the brain of the hedgehog, mast cells were abundant (more so than in any other species which showed them) especially in the habenular nuclei and the dorso-medial parts of the thalamus, but none were seen in the olfactory bulb. The cerebral mast cells of the hedgehog have already been thoroughly described (Campbell & Kiernan, 1966; Krüger, 1970; Flood & Krüger, 1970; Kiernan, 1971) and details will not be repeated here.

In the slow loris and tree-shrew, mast cells, stained by both toluidine blue and alcian blue, were numerous in the habenular nuclei and also, though less abundantly than in the hedgehog, in the dorsal regions of the thalamus. The cells were mostly spherical, 10–15 μm in diameter. About two-thirds of the mast cells in the thalamus and one third of those in the habenula lay adjacent to capillary blood vessels; the remainder did not appear to be related to blood vessels and were randomly scattered amongst the neurons and glial cells. The diencephalic mast cells of the tree shrew and slow loris have not been described previously and are illustrated in Figures 1–6.

No mast cells were detected in the olfactory bulbs of any species and none were found in the area postrema of those mammals in which the whole brain was sectioned. However, even in the smaller animals, the most caudal part of the medulla was usually excluded from the specimen. Mast cells were seen, though rarely, in the connective tissues of the leptomeninges and choroid plexuses of all species, being especially numerous in the choroid plexus of the slow loris. In one of the eight rats studied mast cells were occasionally present in the adventitia of small arteries and veins within the brain, being most abundant in the metathalamus.

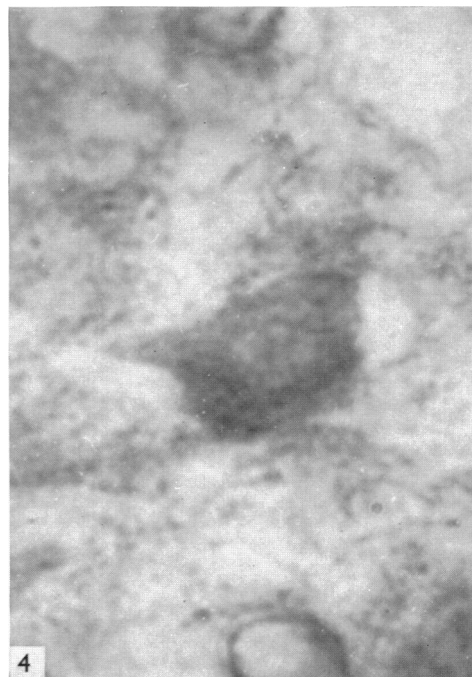
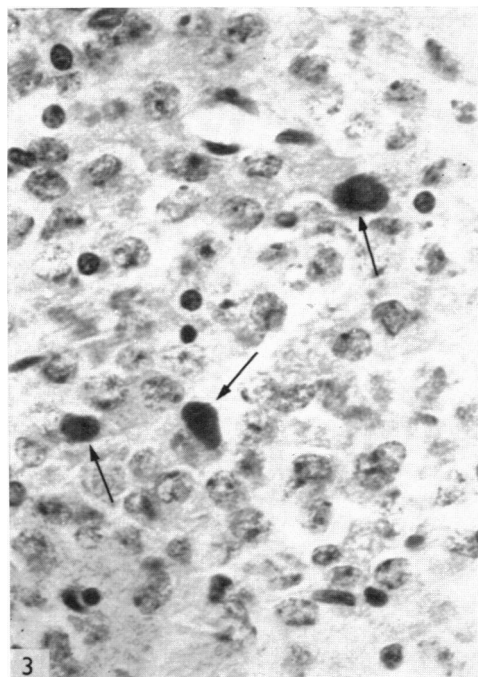
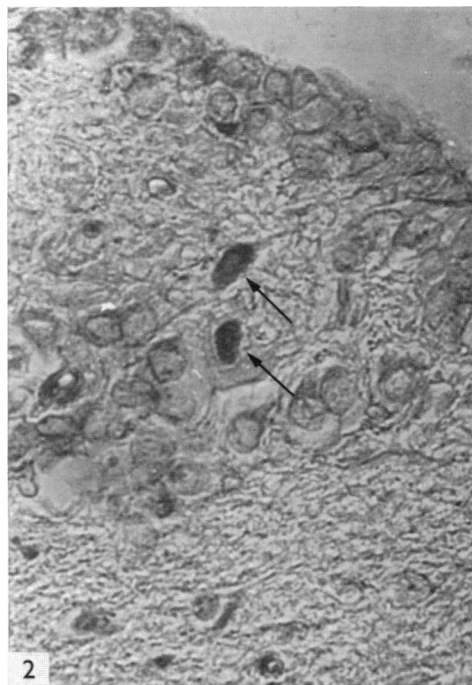
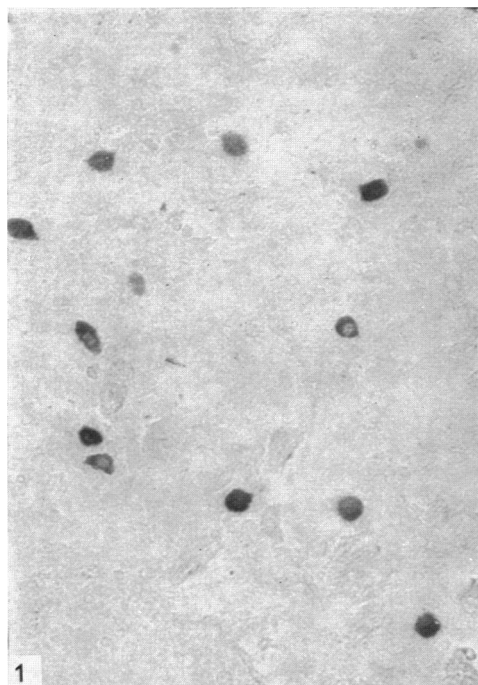


Fig. 1. Mast cells in the thalamus of a tree-shrew. Alcian blue. $\times 150$.

Fig. 2. Two mast cells (arrows) in the medial habenular nucleus of a tree-shrew. Toluidine blue. $\times 400$.

Fig. 3. Three mast cells in the thalamus of a tree-shrew. Toluidine blue. $\times 500$.

Fig. 4. Mast cell in the epithalamus of a tree-shrew. Alcian blue. $\times 1800$.

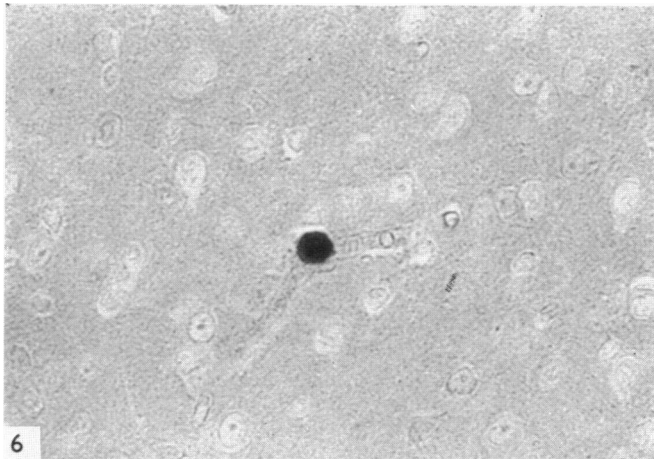
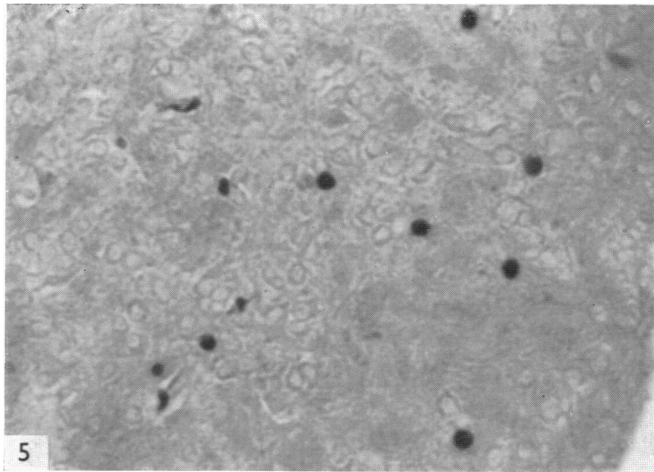


Fig. 5. Mast cells in the epithalamus of a slow loris. Alcian blue. $\times 100$.

Fig. 6. Mast cell next to a capillary in the thalamus of a slow loris. Alcian blue, counterstained with PAS. $\times 450$.

DISCUSSION

Distribution

This comparative survey has confirmed the presence of mast cells in the diencephalon of one insectivore, the hedgehog, and has revealed their presence in the epithalamus and dorsal parts of the thalamus in a lower primate, the slow loris, and in the tree-shrew, a species which has been classified both with the *Insectivora* and

with the *Primates* (see Wood Jones, 1929; Simpson, 1945; Napier & Napier, 1967 for taxonomic discussion). In the other species investigated, which included representatives of the orders *Insectivora*, *Primates*, *Rodentia* and *Carnivora*, no mast cells could be found in those parts of the central nervous system which were examined. It is appreciated that several other orders of mammals exist which have not been studied in this respect.

Other investigations

The present failure to detect mast cells in the olfactory bulb conflicts with previous reports (Cerletti, 1911; Torsegno, 1935). This discrepancy may possibly be explained by the use of different criteria for cell identification. Selye (1965) defines mast cells as elements of connective tissue which stain metachromatically under ordinary conditions. This metachromasia, most easily demonstrated with toluidine blue, is due to the presence of heparin, which is an invariable constituent of the granules of mast cells in both mammals and sub-mammalian vertebrates (Chiu & Lagunoff, 1971) and is also responsible for the staining of the cells by Alcian blue. The human tissue used in this study was not very well fixed and the amorphous metachromatic, alcianophilic cysts which it contained were presumed to be artefacts. Similar extracellular metachromatic bodies are found in some pathological states (Smith, 1949).

Mast cells are said to be present, always in relation to veins, in the telencephalon and thalamus of the hamster (Kelsall & Lewis, 1964), being most abundant in older animals (Kelsall, 1966). No mast cells could be found in the brains of the three hamsters used in the present study, though these were not aged animals. The morphological and tinctorial criteria for identification of mast cells used by Kelsall (1966) are perfectly acceptable and there is no reason to doubt the validity of her observations. Similar cells, identified both histochemically and ultrastructurally, have been demonstrated around venules and arterioles in the dorsal thalamic region in the mouse, rat, hamster and cat (Ibrahim, 1974), and in the thalamus, epithalamus and olfactory bulb of the rat (Krüger, 1974). Such perivascular mast cells were only seen in one of the rats used in the present investigation. This may indicate that the occurrence of these cells around the larger blood vessels of the brain is merely an occasional extension of their presence in connective tissue everywhere else in the body and has no special significance. The presence of mast cells in the area postrema appears to be well established (Cammermeyer, 1972). This part of the medulla, which was not sectioned in most of the brains used in the present survey, is peculiar in that it contains connective tissue and copious extracellular space (Wolfe, 1962).

In considering the mast cells of the brain the question of definition (see above) is important. Widespread pericapillary cells stainable with periodic acid-Schiff (Cammermeyer, 1966; Ibrahim, 1970), 'intensely stained' by cresyl violet and toluidine blue (Dropp, 1972), but not metachromatic or alcianophilic (Ibrahim, 1974), have been called mast cells. These cells, generally known as pericytes (see Pepler & Pearse, 1957; Duckett & Pearse, 1965) have many interesting histochemical properties (Friede, 1962; Abe, Kramer & Seligman, 1964; Kiernan, 1964) but are quite distinct from mast cells. Pericytes do not stain with Alcian blue or react metachromatically with toluidine blue, and therefore cannot contain heparin.

Furthermore, the ultrastructural features of the pericytes named 'Type II mast cells' by Ibrahim (1974) differ from those of true mast cells, both in the brain (Kiernan, 1971) and elsewhere (e.g. Fernando and Movat, 1963), in the size and texture of the cytoplasmic granules.

The rarity of mast cells in the leptomeninges is in agreement with the observations of other workers on adult animals. It is of interest, however, that Kruger (1974) found numerous mast cells in the pia surrounding the diencephalon in very young, but not in adult, rats.

Conclusions and functional considerations

It appears that, in the animals which have been studied here and elsewhere, true mast cells occur in the parenchyma of the brain only in the hedgehog, tree-shrew and slow loris. Some of these mast cells, which are confined to the epithalamus and thalamus, lie adjacent to capillaries, while others are surrounded by cells of neuroectodermal origin. In some species mast cells are found in the connective tissues surrounding small intracerebral arteries and veins and in the choroid plexuses and leptomeninges, though this is a variable occurrence even within a given species. The pericytes, which are found in all mammals in many parts of the brain, are not mast cells since there is no evidence that they contain heparin.

The functions of the parenchymal mast cells of the diencephalon are unknown. It was tentatively suggested by Campbell & Kiernan (1966) that in the hedgehog these cells might modulate the cerebral microvasculature during hibernation and Krüger (1970) noted that increased numbers of the cells were present in the brains of hibernating individuals. However, the population of mast cells *throughout the body* is increased in hibernation (Härmä & Suomalainen, 1951) and heparin from these cells may possibly be involved in associated changes in the lipid metabolism of the body (Konttinen, Rajasalmi & Sarajas, 1964). Hibernation is associated with depressed function of endocrine organs controlled by the adenohipophysis (Smit-Vis, 1962) and arousal with activation of the sympathetic nervous system (Chatfield & Lyman, 1950). The hypothalamus, which controls both these systems, is, however, always devoid of both parenchymal and perivascular mast cells. Moreover, there is no correlation between the presence of diencephalic mast cells and the habit of hibernation or with the habitats or geographical distributions of the animals studied. Rather, the presence of the cells appears to be associated with a taxonomic group including some *Insectivora* and related prosimian *Primates*.

On pharmacological grounds, Rosenblum (1973) has suggested that mast cells may be involved in vasomotor control of pial arterioles, but this seems unlikely since mast cells are rare in the leptomeninges of adult animals.

SUMMARY

A search for mast cells has been made in the brains of 18 mammalian species in 13 families in the orders *Insectivora*, *Primates*, *Rodentia* and *Carnivora*. In the larger animals, only the diencephalon and olfactory bulbs were examined. Mast cells were identified by virtue of their heparin-containing granules, which are stained by Alcian blue 8GX and, metachromatically, by toluidine blue 0.

Within the cerebral parenchyma, mast cells were confined to the dorsal diencephalon of *Erinaceus europaeus* (hedgehog), *Tupaia glis* (tree-shrew) and *Nycticebus coucang* (slow loris). Some cells were next to capillaries; others were not. Mast cells were sometimes found, though rarely, in the intracerebral perivascular connective tissue, leptomeninges and choroid plexuses of some of the other species examined.

It is concluded that pericapillary cells (pericytes), which have been called mast cells by some investigators, are not in fact mast cells since there is no evidence for the presence of heparin. The functions of mast cells in the brain are unknown.

The brains used in this survey were collected during the period 1965–74 during my tenure of appointments in the Departments of Anatomy of the Universities of Birmingham, Cambridge and Western Ontario. I am grateful to several colleagues, notably Drs T. C. Anand Kumar, D. Chivers and J. Marston for providing specimens and to Mr J. Cash, Misses C. Golding, C. Lane and J. Mallon and Mrs W. Venturin for technical assistance. Support has been received at various times from the British Medical Research Council, the Stanley Elmore Fund of Sidney Sussex College, Cambridge, the National Fund for Research into Crippling Diseases and the Medical Research Council of Canada.

REFERENCES

- ABE, M., KRAMER, S. P. & SELIGMAN, A. M. (1964). The histochemical demonstration of pancreatic-like lipase and comparison with the distribution of esterase. *Journal of Histochemistry and Cytochemistry* **12**, 364–383.
- CAMMERMEYER, J. (1966). Reaction of mast cells identified in the rabbit brain. *Journal of Neuropathology and Experimental Neurology* **25**, 130.
- CAMMERMEYER, J. (1972). Mast cells in the mammalian area postrema. *Zeitschrift für Anatomie und Entwicklungsgeschichte*, **139**, 71–92.
- CAMPBELL, D. J. & KIERNAN, J. A. (1966). Mast cells in the central nervous system. *Nature* **210**, 756–757.
- CERLETTI, U. (1911). Die Mastzellen als regelmässiger Befund im Bulbus olfactorius des normalen Hundes. *Folia neurobiologica* **5**, 718–722.
- CHATFIELD, P. O. & LYMAN, C. P. (1950). Circulatory changes during process of arousal in the hibernating hamster. *American Journal of Physiology* **163**, 566–574.
- CHIU, H. & LAGUNOFF, D. (1971). Histochemical comparison of frog and rat mast cells. *Journal of Histochemistry and Cytochemistry* **19**, 369–375.
- DROPP, J. J. (1972). Mast cells in the central nervous system of several rodents. *Anatomical Record* **174**, 227–238.
- DUCKETT, S. & PEARSE, A. G. E. (1965). A pericapillary cell in the central nervous system of the human embryo and adult. *Acta neuropathologica* **4**, 442–445.
- FERNANDO, N. V. P. & MOVAT, H. Z. (1963). The fine structure of connective tissue. III. The mast cell. *Experimental Molecular Pathology* **2**, 450–463.
- FLOOD, P. R. & KRÜGER, P. G. (1970). Fine structure of mast cells in the central nervous system of the hedgehog. *Acta anatomica* **75**, 443–452.
- FRIEDE, R. L. (1962). The cytochemistry of normal and reactive astrocytes. *Journal of Neuropathology and Experimental Neurology* **21**, 471–478.
- HÄRMÄ, R. & SUOMALAINEN, P. (1951). Heparinocytes and hibernation in the hedgehog. *Acta physiologica scandinavica* **24**, 90–95.
- HEAP, B. J. & KIERNAN, J. A. (1973). Histological, histochemical and pharmacological observations on mast cells in the stomach of the rat. *Journal of Anatomy* **115**, 315–325.
- IBRAHIM, M. Z. M. (1970). The immediate and delayed effects of compound 48/80 on the mast cells and parenchyma of rabbit brain. *Brain Research* **17**, 348–350.
- IBRAHIM, M. Z. M. (1974). The mast cells of the mammalian central nervous system. 1. Morphology, distribution and histochemistry. *Journal of Neurological Sciences* **21**, 341–478.
- KELSALL, M. A. (1966). Aging on mast cells and plasmacytes in the brain of hamsters. *Anatomical Record* **154**, 727–740.

- KELSALL, M. A. & LEWIS, P. (1964). Mast cells in the brain. *Federation Proceedings* **23**, 1107–1108.
- KIERNAN, J. A. (1964). Carboxylic esterases of the hypothalamus and neurohypophysis of the hedgehog. *Journal of the Royal Microscopical Society* **83**, 297–306.
- KIERNAN, J. A. (1971). Ultrastructure of mast cells in the diencephalon of the hedgehog. *Journal of Anatomy* **111**, 347–348.
- KONTTINEN, A., RAJASALMI, M. & SARAJAS, H. S. S. (1964). Fat metabolism in the hedgehog during the hibernating cycle. *American Journal of Physiology* **207**, 845–848.
- KRABBE, K. (1928). In discussion following paper by U. Quensel. *Acta pathologica et microbiologica scandinavica* **5**, suppl., pp. 37–38.
- KRÜGER, P. G. (1970). Mast cells in the brain of the hedgehog (*Erinaceus europaeus* Linn.). Distribution and seasonal variations. *Acta zoologica* **51**, 85–93.
- KRÜGER, P. G. (1974). Demonstration of mast cells in the albino rat brain. *Experientia* **30**, 810–811.
- NAGAYO, M. (1928). Studien über die Gewebsmastzellen. *Zentralblatt für allgemeine Pathologie und pathologische Anatomie* **43**, 289–293.
- NAPIER, J. R. & NAPIER, P. H. (1967). *A Handbook of Living Primates*. London, New York: Academic Press.
- NEUMANN, J. (1890). Ueber das Vorkommen der sogenannten 'Mastzellen' bei pathologischen Veränderungen des Gehirns. *Virchows Archiv* **122**, 378–380.
- OLSSON, Y. (1968). Mast cells in the nervous system. *International Review of Cytology* **24**, 27–70.
- OLSSON, Y. (1971). Mast cells in human peripheral nerve. *Acta neurologica scandinavica* **47**, 357–368.
- PEARSE, A. G. E. (1968). *Histochemistry, Theoretical and Applied*, 3rd ed. vol. 1. London: Churchill.
- PEPLER, W. J. & PEARSE, A. G. E. (1957). The histochemistry of the esterases of rat brain with special reference to those of the hypothalamic nuclei. *Journal of Neurochemistry* **1**, 193–202.
- ROSENBLUM, W. I. (1973). A possible role for mast cells in controlling the diameter of arterioles on the surface of the brain. *Brain Research* **49**, 75–82.
- SELYE, H. (1965). *The Mast Cells*. Washington: Butterworths.
- SIMPSON, G. G. (1945). The principles of classification and a classification of mammals. *Bulletin of the American Museum of Natural History* **85**, 1–350.
- SMITH, M. C. (1949). Metachromatic bodies in the brain. *Journal of Neurology, Neurosurgery and Psychiatry* **12**, 100–110.
- SMIT-VIS, J. H. (1962). Some aspects of hibernation in the European hedgehog, *Erinaceus europaeus* L. *Archives neerlandaises de Zoologie* **14**, 513–597.
- SQUARTINI, F. & GIACANELLI, F. (1956). Le mastzellen nel sistema nervosa centrale. *Lavori dell'Istituto de anatomia et istologia patologica della Università degli studi di Perugia* **16**, 383–387.
- TORSEGGNO, M. E. (1935). Le 'mastzellen' nel bulbo olfactorio normale. *Note e riviste di psichiatria* April 1935), **215** (cited from Selye, 1965).
- WOLFE, D. E. (1962). Fine structure of neuroglial cells in the area postrema. *Anatomical Record* (**142**), 292.
- WOOD JONES, F. (1929). *Man's Place among the Mammals*. London: E. Arnold.
- ZIMMERMAN, A. (1908). Über das Vorkommen der Mastzellen beim Meerschweinchen. *Archiv für mikroskopische Anatomie* **72**, 662–669.