

The postnatal development of the alimentary canal in the opossum

I. Oesophagus

WILLIAM J. KRAUSE, J. HARRY CUTTS AND
C. ROLAND LEESON

Department of Anatomy, University of Missouri, Columbia, Missouri 65201

(Accepted 6 October 1975)

INTRODUCTION

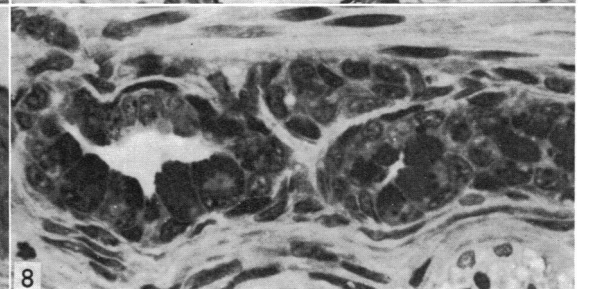
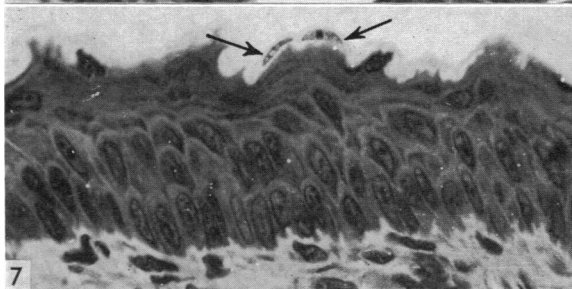
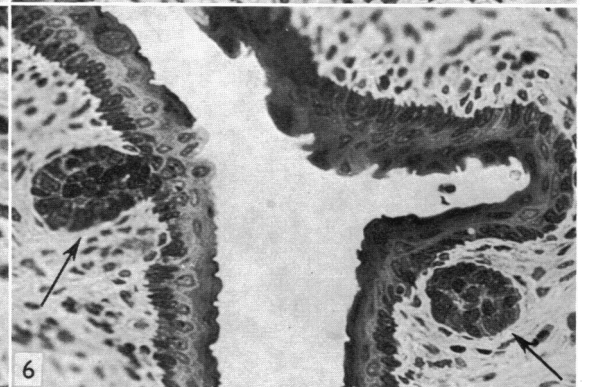
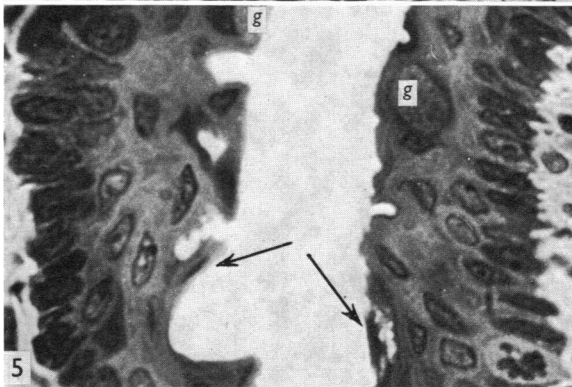
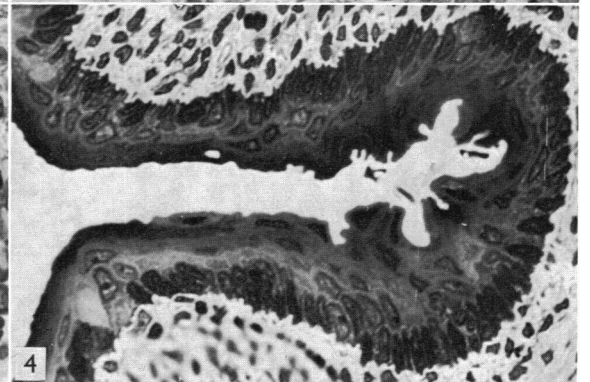
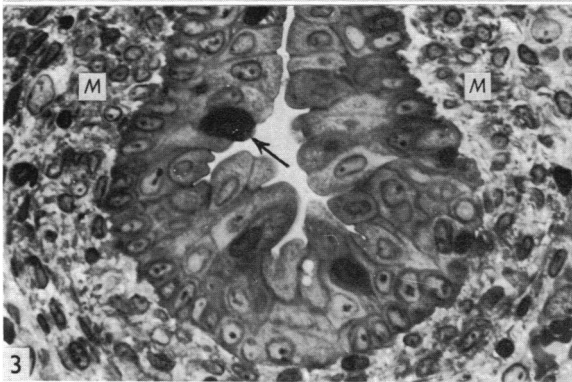
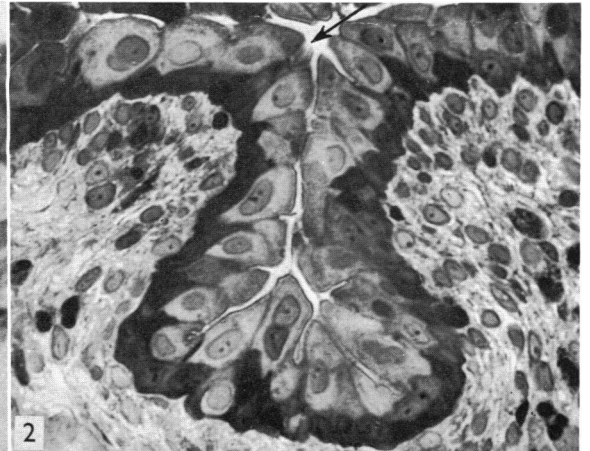
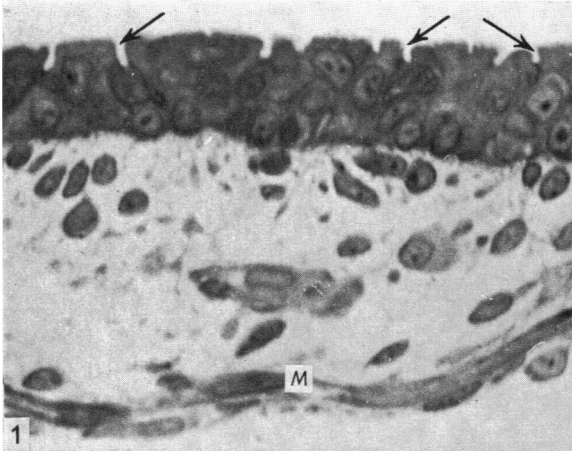
Born approximately 12·5 days after conception, the opossum (*Didelphis virginiana*) is markedly immature at birth. Further development, including both growth and differentiation, takes place in the maternal marsupium (pouch). The extensive changes that occur during the postnatal period (i.e. the period in the pouch) can be explained by the remarkably short gestation period *in utero* and the need for special mechanisms that allow for survival in the pouch.

Although Heuser (1921) reported on the very immature nature of the gastrointestinal tract of the opossum just prior to and immediately after birth, he did not comment upon the appearances of the oesophagus. Goetsch (1910) described the light microscopy of the oesophagus in the adult opossum and noted that the muscularis externa of the upper third contains skeletal muscle which gives way to smooth muscle in the upper central region. Oesophageal glands, found throughout the length of the oesophagus, were reported to be 'mixed' glands.

The present study details the sequence of changes that occurs in the oesophagus during the period of postnatal development of the opossum. Because of the peculiar nature of the distal oesophagus, as compared with its cervical and proximal thoracic parts, emphasis has been placed upon the mucosa in the latter regions.

METHODS AND MATERIALS

Ninety opossums (*Didelphis virginiana*) were used in the study. The pouch-young were divided into the following ten groups according to their snout-rump lengths (SRL): 1·5 (known to be less than 24 hours old), 2·0, 2·5 (known to be 9 days old), 3·5, 4·5, 6·5, 10·0, 13·0, 15·5, and 20·0 cm. Where postnatal ages were not known with certainty they were estimated from the data presented by Moore & Bodian (1940) and Reynolds (1942). Four adults also were used. The animals were killed by decapitation and, as quickly as possible, blocks of tissue from the cervical and thoracic regions of the oesophagus were placed in Bouin's solution or in 10% buffered neutral formalin. Segments of the abdominal oesophagus also were examined in a few of the older stages and in the adult. The tissues were processed routinely, embedded in paraffin and stained with haematoxylin and eosin, Mallory's trichrome, or



van Gieson. Histochemical methods employed specifically for visualizing mucosubstances of the oesophageal glands are outlined in Table 2. Tissues used in this portion of the study were fixed in buffered 10% neutral formalin.

Additional blocks of tissue were fixed for 4 hours at 0°C in 3.5% glutaraldehyde buffered in 0.1 M-phosphate to a pH of 7.4. The tissues were washed in buffer and post-osmicated in 1.0% osmium tetroxide at 0°C for 2 hours. The specimens were processed routinely and infiltrated with and embedded in Epon 812. Thick sections of this material, cut at 0.5–3.0 µm, were stained with toluidine blue and examined by light microscopy.

For electron microscopy thin sections of this material were mounted on uncoated grids and stained with uranyl acetate and lead citrate. The sections were examined in an RCA EMU-3F electron microscope operated at 50 kv.

Tissues for scanning electron microscopy were prepared as for transmission electron microscopy and post-osmicated in 1.0% osmium tetroxide at 0°C for 2 hours. The specimens were dehydrated in alcohol and transferred to amyl acetate prior to critical point drying. They were desiccated by liquid CO₂ substitution, during which time a bleed valve was opened and closed until amyl acetate could not be detected at the time when the valve was open, indicating complete substitution by CO₂. The dried tissues were placed on spinner stubs and coated with a gold-palladium alloy to a depth of approximately 20 nm in a vacuum evaporator. Specimens were viewed in a Cambridge Stereoscan Mark II electron microscope.

A quantitative assessment of the changes in the thickness of the mucosal epithelium and of the mitotic activity in this layer was made from the thick sections of

Fig. 1. A portion of the oesophageal wall from a newborn opossum. The epithelium appears stratified and shows numerous clefts or invaginations (arrows). The muscularis mucosae is absent and the muscularis externa is represented only by a few myoblasts (*M*) at the periphery. Epon 812-toluidine blue. × 375.

Fig. 2. The oesophageal epithelium of the 9 day old opossum (2.5 cm) exhibits two strata. The superficial layer consists of large, pale-staining cells with centrally placed rounded or oval nuclei. The cells of the basal layer stain intensely and are small and irregular in shape. A ciliated cell also is shown (arrow). Epon 812-toluidine blue. × 375.

Fig. 3. The oesophageal epithelium of the 3.5 cm opossum (ca. 17 days) is increased in thickness and continues to show goblet cells (arrow). Mesenchymal cells (*M*) in the underlying connective tissue appear orientated into a discrete layer, which later becomes the muscularis mucosae. Epon 812-toluidine blue. × 375.

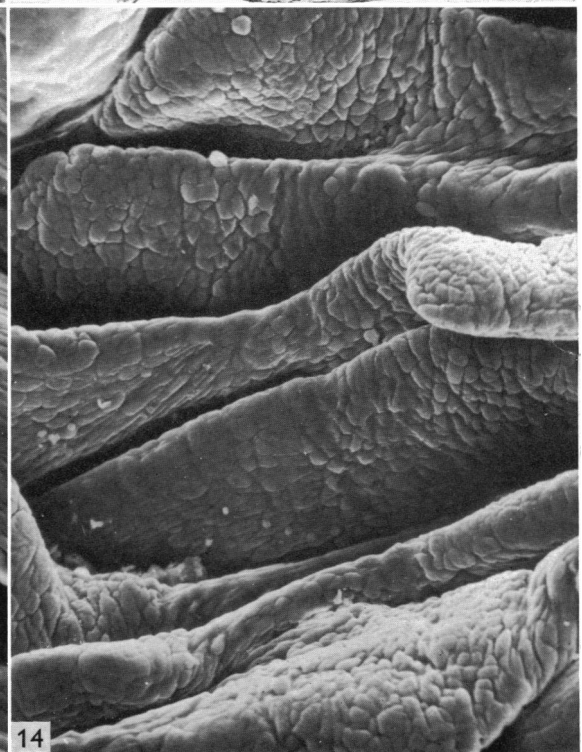
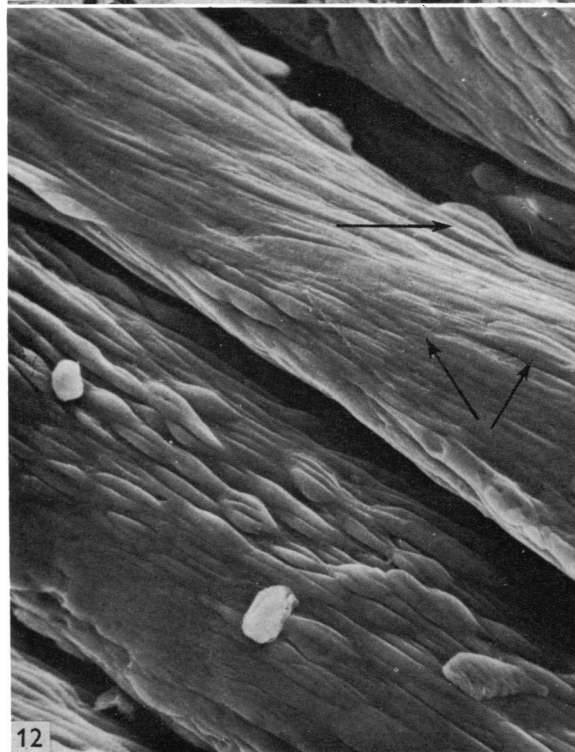
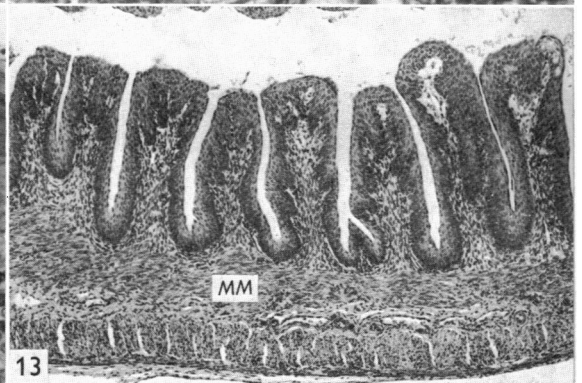
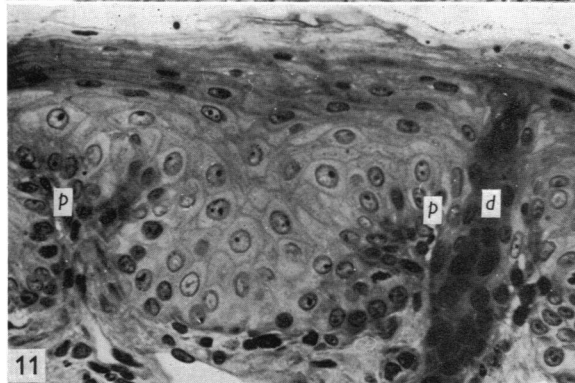
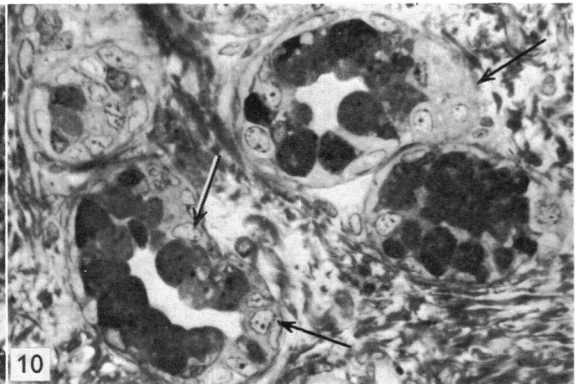
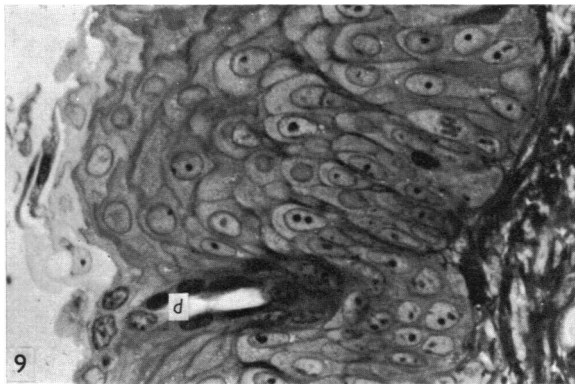
Fig. 4. The superficial stratum of oesophageal epithelium of the 4.5 cm opossum (ca. 20 days) shows flattened, squamous cells. The superficial cells retain nuclei. Epon 812-toluidine blue. × 340.

Fig. 5. Squamous surface cells appear to be sloughing into the lumen (arrows) and goblet cells (*g*) continue to be found in the surface stratum. 4.5 cm opossum (ca. 20 days). Epon 812-toluidine blue. × 580.

Fig. 6. Primordia of the oesophageal glands (arrows) extend from the epithelium into the underlying lamina propria at the 4.5 cm stage. Epon 812-toluidine blue. × 225.

Fig. 7. Three distinct strata are observed in the oesophageal epithelium of the 10 cm opossum (ca. 60 days). Cells immediately adjacent to the lumen show pale cytoplasm and retain nuclei (arrows). Epon 812-toluidine blue. × 375.

Fig. 8. Developing secretory tubules of the oesophageal glands of the 10 cm opossum are comprised primarily of mucous appearing cells which contain numerous secretory granules. Epon 812-toluidine blue. × 400.



Epon-embedded material. Three sections from each of two animals at each stage of development were examined. The epithelial thickness was determined from six random measurements on each section by means of a filar micrometer. The number of mitotic figures in the same sections was recorded and related to the area of epithelium as estimated by means of a calibrated net micrometer. The mitotic activity of the subepithelial layers was estimated similarly.

RESULTS

Light microscopy

The oesophagus of the newborn opossum (1.5 cm) consists essentially of a stratified epithelium surrounded by delicate mesenchyme (Fig. 1). The lumen is of considerable diameter and the surrounding epithelium, which is 2–3 cells in depth, shows numerous invaginations. There is no muscularis mucosae and the muscularis externa is represented only by a few, loosely knit myoblasts at the periphery of the oesophagus (Fig. 1). In the 9 day old opossum (2.5 cm), the oesophagus shows an increase in the cellularity of the connective tissue. The layers of the muscularis externa are clearly defined. The lumen does not show the degree of patency observed in the newborn and the mucosa exhibits longitudinal folding. The epithelium retains its stratified appearance and forms two distinct cell layers (Fig. 2). In the stratum immediately adjacent to the lumen, the cells appear large and irregular in shape, with lightly stained cytoplasm and centrally placed spherical or oval nuclei. The basal stratum is made up of smaller, darkly staining, irregularly shaped cells which appear to extend toward the lumen between the bases of the surface lining cells (Fig. 2). Ciliated cells and occasional goblet cells also are observed at this stage of development (Figs. 2, 3).

By 3.5 cm (*ca.* 17 days in pouch), the oesophageal epithelium has increased in depth and continues to show the two major strata observed in the 9 day old opossum (Fig. 3). The surface stratum is still comprised of large, lightly staining cells which now form a layer 2–3 cells deep. The basal stratum consists primarily of a single layer of small cells, which do not stain as intensely as in the 9 day old opossum. Goblet cells and ciliated cells continue to be a prominent feature at this stage of

Fig. 9. The oesophageal epithelium is increased in thickness and continues to show nuclei in the surface cells. The duct (*d*) of an oesophageal gland also is shown. 13.0 cm opossum (*ca.* 75 days). Epon 812–toluidine blue. $\times 375$.

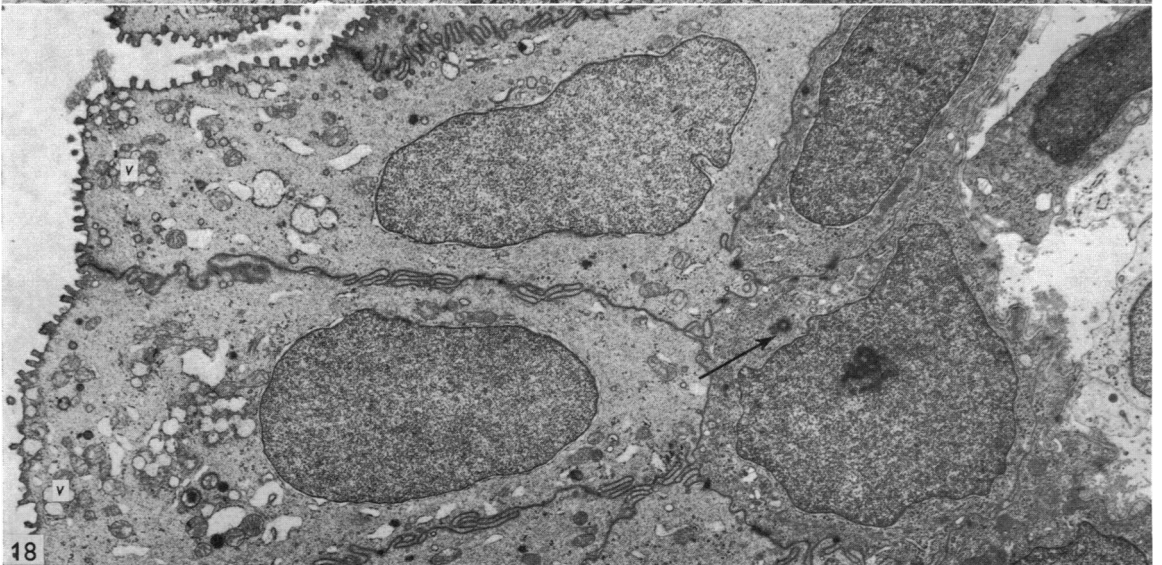
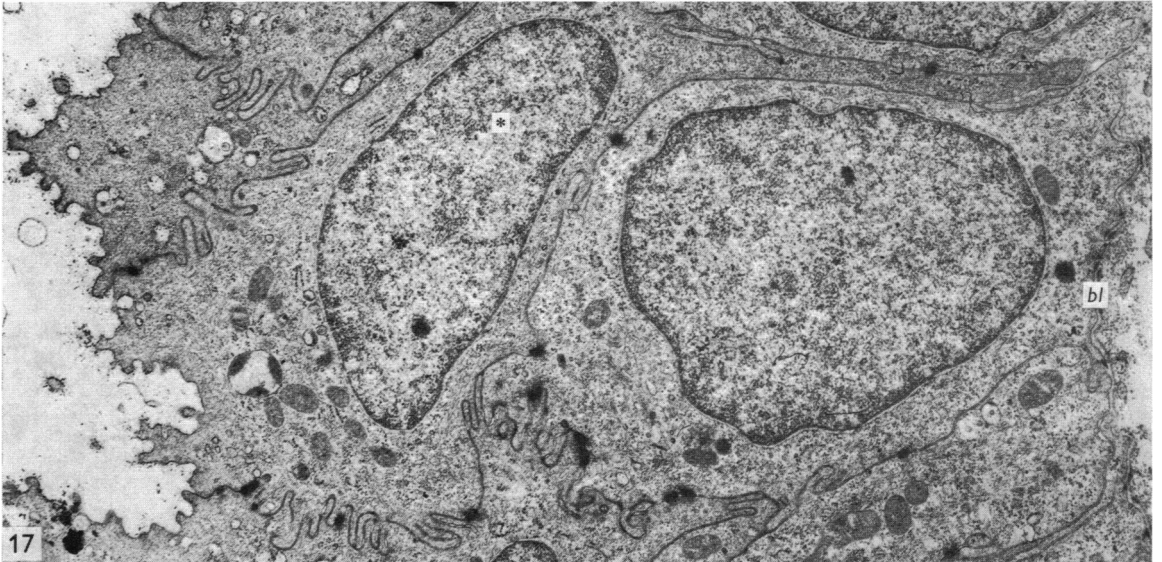
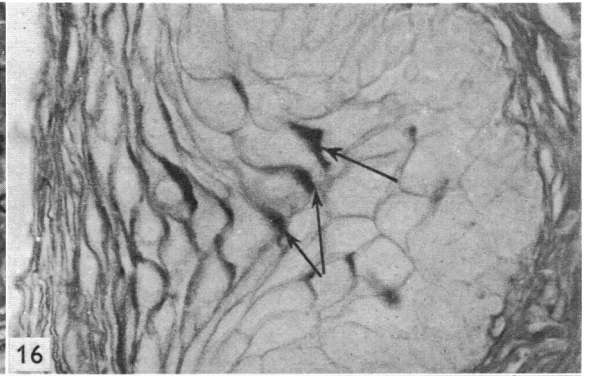
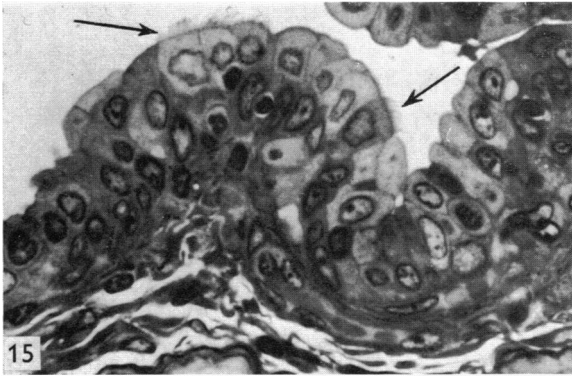
Fig. 10. Secretory tubules of the oesophageal glands of the 13 cm opossum show pale staining cells (arrows), in addition to numerous mucous cells. Epon 812–toluidine blue. $\times 400$.

Fig. 11. The oesophageal epithelium of a juvenile opossum (20 cm). Cells of the superficial stratum retain pyknotic nuclei. Numerous connective tissue papillae (*p*) project into the overlying epithelium. The duct (*d*) of an oesophageal gland also is shown. Epon 812–toluidine blue. $\times 220$.

Fig. 12. A scanning electron micrograph of the longitudinal folds of the oesophagus. What appear to be nuclear profiles (arrows) in surface cells also are shown. Juvenile. $\times 500$.

Fig. 13. A longitudinal section showing the transverse folds of the distal oesophagus. The muscularis mucosae (*MM*) is well developed in the distal oesophagus. 10 cm opossum. Haematoxylin and eosin. $\times 45$.

Fig. 14. A scanning electron micrograph of the distal transverse folds of the oesophagus. The cell apices appear round, rather than elongate as in cervical and thoracic regions. Juvenile. $\times 200$.



development. Primitive mesenchymal cells show a definite orientation in the region of the forming muscularis mucosae.

The cells at the surface of the oesophageal epithelium of the 4.5 cm opossum (*ca.* 20 days) show a marked change from the earlier stages (Fig. 4). The stratum nearest the lumen has flattened cells whose nuclei lie parallel to the luminal surface (Figs. 4, 5). Cells underlying the surface layer tend to show a similar orientation of their nuclei. Goblet cells and ciliated cells are still present between the squamous cells lining the surface of the epithelium (Fig. 5). The lumen of the oesophagus is now wider and oesophageal glands are beginning to form. The latter appear as solid outgrowths from the epithelium into the underlying connective tissue (Fig. 6). A delicate muscularis mucosae also is observed and the layers of the muscularis externa are better developed.

Three strata are clearly defined within the oesophageal epithelium at the 10 cm stage (Fig. 7): a stratum germinativum, a stratum spinosum, and a stratum corneum which remains non-keratinized. The surface squamous cells retain their nuclei and the cytoplasm of a number of them now stains lightly. The oesophageal glands show definite secretory tubules and acini (Fig. 8) and appear to be composed primarily of mucous secreting cells. The oesophageal epithelium of the 13 cm opossum (*ca.* 75 days) is thicker still and the surface cells still retain their nuclei (Fig. 9). The muscularis mucosae at this stage is of considerable thickness. The secretory portions of the oesophageal glands show continued development, with the addition of a pale staining type of cell (Fig. 10). The latter cell type is observed most often at the terminal portions of the secretory tubules or acini and shows considerable eosinophilia. The oesophageal epithelium of the juvenile and adult opossums does not appear to undergo a true keratinization and the surface cells retain their nuclei even after weaning (Fig. 11).

Fig. 15. Distal oesophagus. The epithelium within the depths of transverse folds appears immature and contains ciliated cells (arrows). The epithelium is two cell layers in thickness and the surface lining cells are large and pale-staining, similar to those observed in the 3.5 cm stage. Adult opossum. Epon 812-toluidine blue. $\times 450$.

Fig. 16. The oesophageal epithelium of the adult opossum exhibits areas of intense PAS activity within the cytoplasm of cells of the central region (arrows). The cell membranes of the surface cells also show PAS activity. $\times 425$.

Fig. 17. An electron micrograph through the oesophageal epithelium of a newborn opossum. The cells contain scattered mitochondria, Golgi membranes, rough endoplasmic reticulum and numerous free ribosomes. Numerous fine cytoplasmic filaments also are observed. The basal cell membrane shows hemidesmosomes and lies on a delicate basal lamina (*bl*). Lateral cell membranes show extensive interdigitations and scattered desmosomes. Apices of surface cells show stubby microvilli covered by a fuzzy coat. Occasional cells (*) are observed which extend from the oesophageal lumen to the basal lamina, giving some areas of the oesophageal epithelium a pseudostratified appearance. $\times 10000$.

Fig. 18. Two distinct strata are observed in the oesophageal epithelium of the 9 day old opossum (2.5 cm). The apices of columnar cells comprising the surface layer show stubby microvilli and adjacent lateral cell membranes exhibit extensive implication. The cytoplasm generally appears to be of a homogeneous nature but shows concentrations of mitochondria and vesicles (*v*) filled with a fibrillar material in the apical region. Occasional Golgi complexes and elements of rough endoplasmic reticulum also are observed. Small, irregular, electron-dense cells, which lie on a delicate basal lamina, comprise the basal stratum of the epithelium. They contain numerous free ribosomes and scattered elements of other organelles. A pair of centrioles also is shown (arrow). $\times 5100$.

Table 1. *Mitotic activity of the subepithelial layers*

Body length	No. of mitoses (per mm. ²)*			
	Lamina propria	Muscularis mucosae	Submucosa	Muscularis externa
1.5		†8.22±0.61		4.68
2.5		†13.36±1.04		26.72±3.9
3.5		9.49±0.63		16.78±1.7
4.5	1.37±0.07	9.92±0.58	2.76±0.09	11.75±2.5
6.5	6.58±0.16	5.17±0.31	4.41±0.29	7.22±1.8
10.0	7.21±0.33	4.33±0.44	9.37±0.38	6.06±1.4
13.0	5.79±0.24	2.38±0.39	4.12±1.06	3.65±2.3
20.0	0.59±0.02	1.22±0.11	0.78±0.05	1.07±0.7

* ± Standard deviation.

† Stages at which there is no well-defined muscularis mucosae. The figures given are for the total mitoses seen within the layer bounded by the epithelium and the muscularis externa.

Cell boundaries, and what appear to be nuclear profiles, are distinguishable on the surface of the longitudinal folds of the oesophagus as viewed with the scanning electron microscope (Fig. 12). Unlike the surface epithelium found on the longitudinal folds, those cells that line the transverse folds (Fig. 13) of the distal oesophagus appear rounded in nature when viewed from the surface (Fig. 14). In this small segment of the adult oesophagus, the epithelium appears very similar to that observed in the cervical and thoracic portions of the 3.5 cm opossum (Fig. 15). The epithelium is stratified in nature but retains the large, irregular, lightly staining surface cells. Such cells are thought to produce the rounded apices observed under the scanning electron microscope. The epithelium is usually 2–3 cells in depth in this region of the adult oesophagus, and ciliated cells are present within the transverse folds (Fig. 15).

Quantitative examination of the mucosal epithelium reveals the marked development that occurs in this layer (Fig. 31). Although there is a progressive increase in the depth of the epithelium throughout the entire period of postnatal development, the most marked increase in thickness occurs during the first 75 days (13 cm stage). The number of mitotic figures increases rapidly to reach a peak at 20 days (4.5 cm). Thereafter the mitotic activity of the mucosal epithelium declines and stable values are reached by the 75th day, coincident with a lessened rate of increase in epithelial depth.

Table 1 represents the mitotic activities observed in the subepithelial layers of the developing oesophagus. The lack of a well-formed muscularis mucosae up to the 3.5 cm stage precluded subdivision of the subepithelium into its constituent layers prior to the 4.5 cm stage. Hence the mitoses reported for these early stages represent the combined mitotic activity of the lamina propria, muscularis mucosae and the submucosa. Several peaks of mitosis occur. The first is seen at 2.5 cm, where there is marked mitotic activity in the combined subepithelial layers and in the muscularis externa. The lamina propria shows an increased mitotic activity for an extended period, lasting throughout the 6.5–13.0 cm stages. During this same period, there is evidence of increased activity in the submucosa, with a peak of mitosis at the 10.0 cm stage. Following the mitotic peak at 2.5 cm, the number of mitotic figures seen in

Table 2. *Histochemistry. Results of the histochemical study showing the staining of the mucin granules of the oesophageal glands*

PAS (before and after treatment with saliva)	Toluidine blue (0.1% & 1.0%) pH = 1.0	Aldehyde fuchsin	Aldehyde fuchsin & Alcian blue (0.25%) pH = 2.5	Alcian blue (0.1% & 1.0%) pH = 2.5	Alcian blue -PAS (0.1% & 1.0%) pH = 2.5	Alcian blue (0.1% & 1.0%) pH = 1.0	Alcian blue-PAS (0.1% & 1.0%) pH = 1.0
+++	+++ (metachromatic)	+++ (purple)	+++ (blue)	+++ (blue)	+++ (blue, red, blue-red)	+++ (blue)	+++ (blue, red, blue-red)
Methylation in acid methanol for 4 hours							
.	.	.	.	++ (blue)	+++ (red)*	++ blue	++ (red)*
.	+++ (blue)	.	+++ (blue)
.	+++ (blue-red)	.	+++ (blue-red)
Saponification in 1.0% KOH in 70% ethanol for 20 minutes after prior methylation at 37°C							
.	.	.	.	++ (blue)	+++ (red)*	++ (blue)	+++ (red)*
.	+++ (blue)	.	+++ (blue)
.	+++ (blue-red)	.	+++ (blue-red)
Methylation in acid methanol at 60°C for 4 hours							
.	.	.	.	-	+	-	+
Saponification in 1.0% ethanol for 20 minutes after prior methylation at 60°C							
.	.	.	.	+	++ (red)	-	++ (red)

* Majority of cells.
The intensity of the staining reaction is designated as follows: (+++), intense staining; (++) moderate staining; (+), light staining; and (-), no staining.

the muscularis externa slowly declines throughout the remaining period of postnatal development.

Histochemistry

Results of the histochemical study are summarized in Table 2. The pale cells at the terminal portions of the secretory tubules fail to stain with the histochemical procedures used in this study. The mucous cells of the oesophageal glands stain intensely with periodic acid-Schiff before and after digestion with saliva, indicating that the reactive material is not glycogen. The granules exhibit metachromasia when stained with toluidine blue and stain with aldehyde fuchsin and alcian blue at pH 2.5 as well as at pH 1.0. The staining procedure utilizing combined alcian blue-PAS reveals that acini and secretory tubules show a heterogeneous population of mucous cells staining red, blue or blue-red.

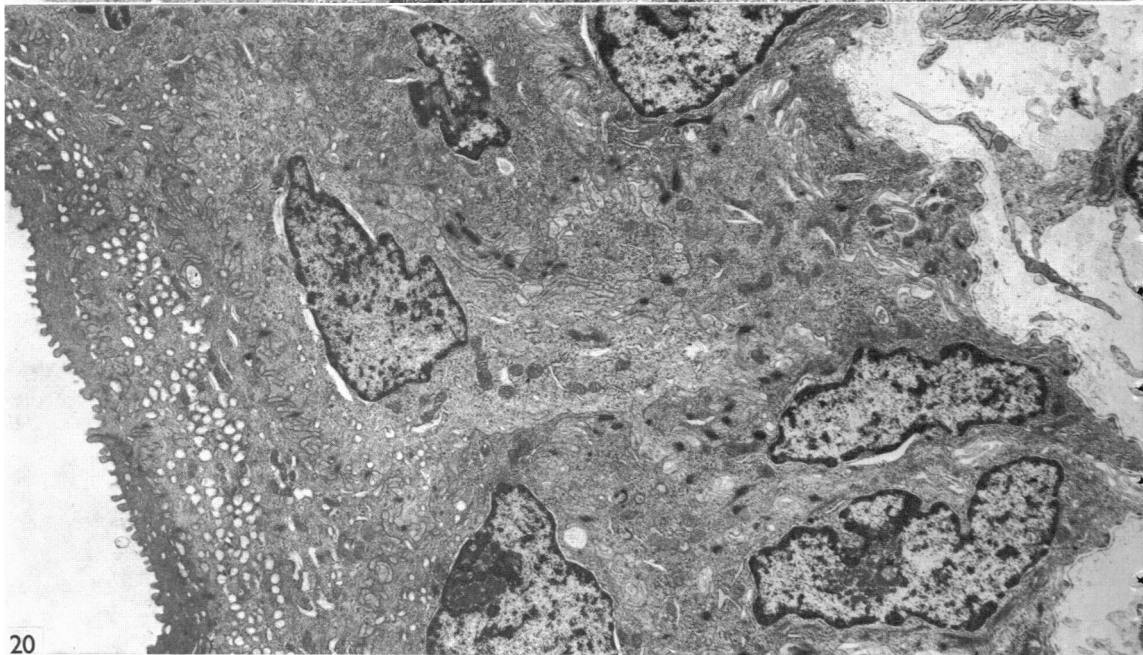
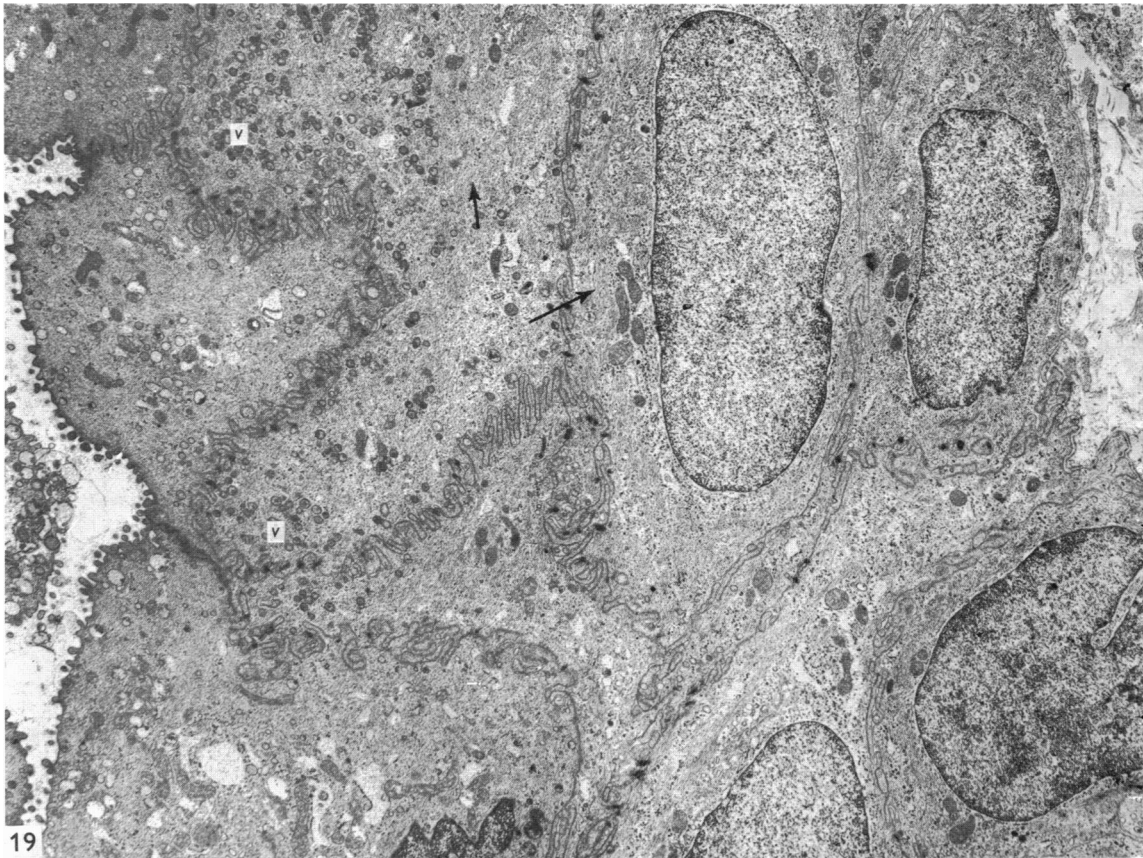

Fig. 19. Cells of the superficial stratum of the 3.5 cm opossum (ca. 17 days) show an increase in number of small vesicles (v), as well as fine cytoplasmic filaments (arrows). Surface cells continue to show stubby microvilli and adjacent cell membranes still show extensive implications. $\times 5600$.

Fig. 20. Surface cells become flattened, exhibit increased density, and contain numerous vesicles by the 4.5 cm stage (ca. 20 days). $\times 5400$.

Methylation at 37°C appeared to decrease the intensity of alcian blue staining at both pH 2.5 and pH 1.0. The combined staining procedures after methylation showed the majority of mucous cells to be PAS-positive (red) although alcinophilic cells were present in acini. Saponification after prior methylation at 37°C appeared to have little effect on the stainability of the secretory granules. Methylation at 60°C eliminated the alcinophilia of the gland and markedly reduced the PAS reactivity. Saponification after prior methylation at 60°C restored weak alcinophilia at pH 2.5 but not at pH 1.0. PAS reactivity also appeared to be moderately restored.

Metachromasia with toluidine blue, alcinophilia at pH 1.0, and positive staining with aldehyde fuchsin indicate that sulphated mucosubstances are present. Methylation at 60°C, followed by saponification, is thought to remove the formed sulphate esters on some of the acidic mucosubstances because of the loss of alcinophilia at pH 1.0. This also may account for the increase in intensity of the PAS reaction.

The secretory product of the oesophageal glands appears complex and probably contains both acidic and neutral mucosubstances. Some forms of the acidic mucosubstances are believed to be sulphated.

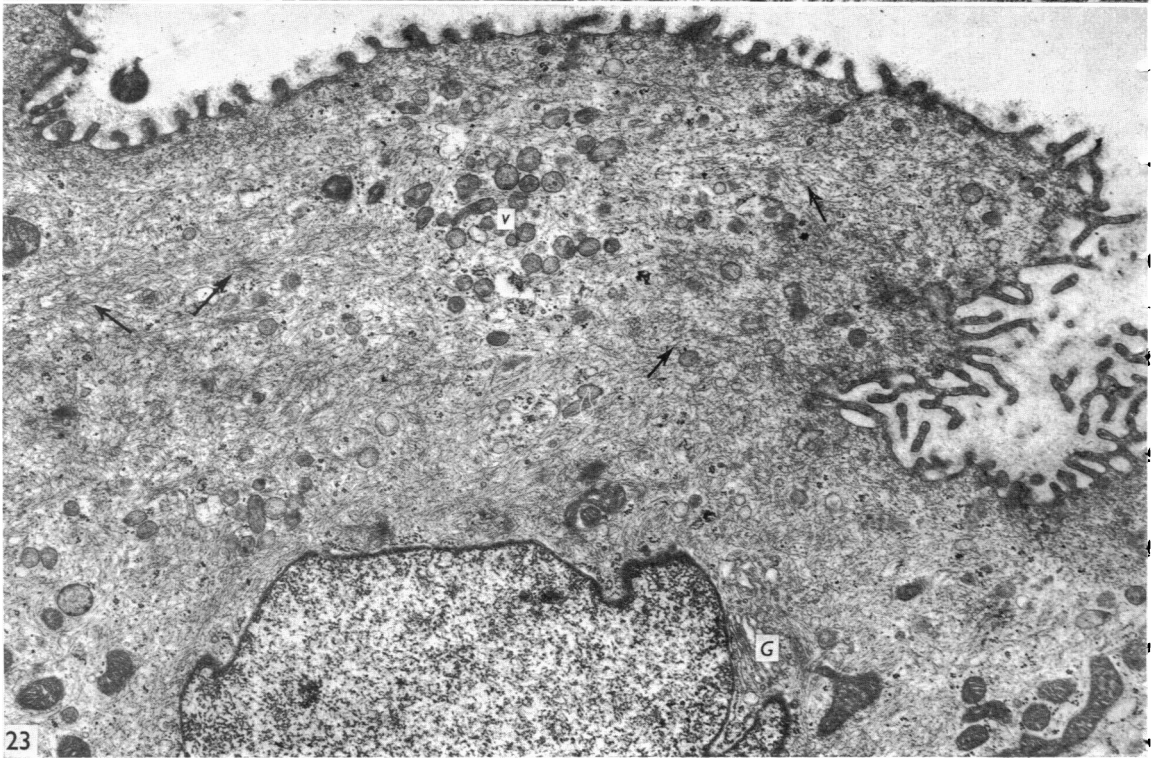
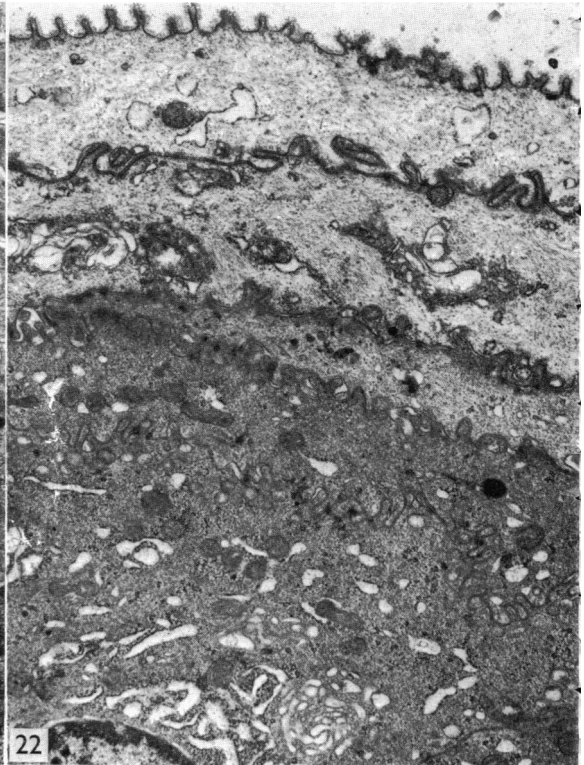
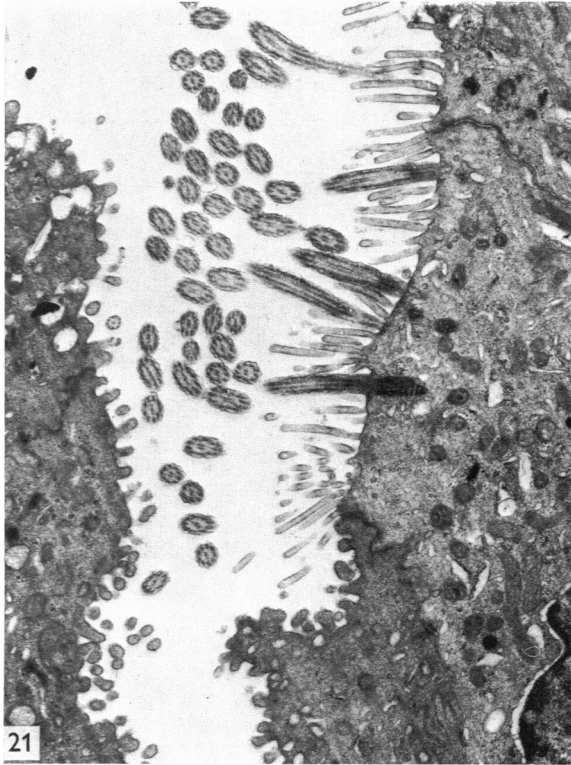
The surfaces of those cells that form the superficial layers of the stratified squamous epithelium immediately adjacent to the oesophageal lumen show light, uniform PAS reactivity. Scattered cells within the epithelium also contain aggregates of PAS-positive granules (Fig. 16). The granules appear to be concentrated in the basal regions of the cells. The granules failed to be reactive with the other stains used in this study.

Electron microscopy

The epithelium of the newborn oesophagus generally is stratified in type and shows two distinct strata. On occasion a cell spans from the basal lamina to the surface of the epithelium, giving a pseudostratified appearance in some places (Fig. 17). The surface cells exhibit numerous, stubby microvilli that are covered with a fine fibrillar material. Adjacent cell membranes show extensive implication and there are scattered desmosomes. In the basal stratum, the basal cell membrane shows hemidesmosomes and it rests on a delicate basal lamina. The cytoplasm contains scattered mitochondria, Golgi complexes, numerous free ribosomes and collections of fine filaments. Small vesicles also are found near the apex of the surface cell (Fig. 17).

The surface stratum of the oesophageal epithelium of the 2.5 cm opossum (*ca.* 9 days) contains cells that are quite different in appearance from those observed in the newborn. The surface cells are columnar in shape and the cytoplasm appears homogeneous (Fig. 18). Only scattered elements of rough endoplasmic reticulum, ribosomes and mitochondria are observed. Numerous small vesicles are seen at the apices of the surface cells, which remain in close association and exhibit an extensive interdigitation of adjacent cell membranes. Invaginations or clefts into the epithelium are also observed. The basal stratum is made up of small irregular cells which, in addition to exhibiting numerous free ribosomes, appear more electron-dense (Fig. 18). The cells of the basal stratum lie on a delicate basal lamina and show scattered hemidesmosomes.

Surface cells of the 3.5 cm opossum show an increased number of the small apical



vesicles and also an increase in the number of cytoplasmic filaments (Fig. 19). There continues to be a relative paucity of organelles in the cells of the surface stratum, but numerous free ribosomes are found in cells of the basal layer. Desmosomes and hemidesmosomes are prominent in the basal layer, and the adjacent cell membranes of the superficial layer continue to show extensive implication (Fig. 19).

By 4.5 cm (*ca.* 20 days) the superficial cells adjacent to the lumen appear flattened and often exhibit considerable electron density (Fig. 20). Cells making up the superficial stratum still show numerous cytoplasmic vesicles and the adjacent cell membranes exhibit extensive interdigitations. The cytoplasm of the basal cells continues to show numerous ribosomes. An occasional ciliated cell can be found between the flattened superficial cells which line the oesophagus (Fig. 21). In addition to cilia, the cells often show numerous, elongated microvilli. Goblet cells in the oesophageal epithelium appear very similar to those reported in the intestinal tract of numerous mammalian species, showing dense, basally placed nuclei and large amorphous granules that vary in electron density and fill the apex and supranuclear regions. Golgi membranes are associated with forming granules and granular endoplasmic reticulum is found primarily at the base in relation to the nucleus.

By 10 cm (*ca.* 60 days), the oesophageal epithelium exhibits cytological characteristics typical of later stages and of the adult. Cells of the basal and central strata are similar in appearance to those found in the 4.5 cm opossum and contain numerous free ribosomes and scattered mitochondria. Bundles of cytoplasmic filaments are also present. The superficial layers do not appear to undergo true keratinization and cells of this stratum continue to show scattered organelles and nuclei. Cells immediately adjacent to the lumen may show an electron-lucent cytoplasm in which fine filaments and vesicles, as well as scattered mitochondria and Golgi complexes, may be seen (Fig. 22). The surface still shows stubby microvilli covered by a fuzzy coat (Fig. 22).

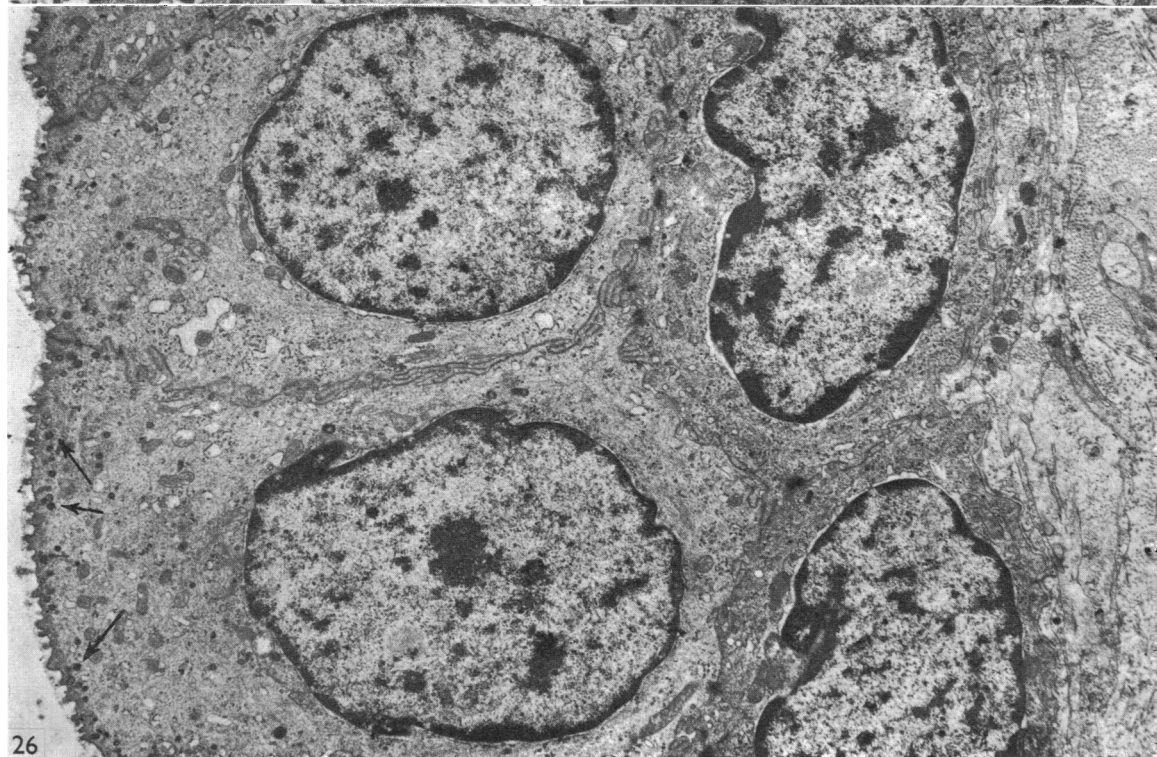
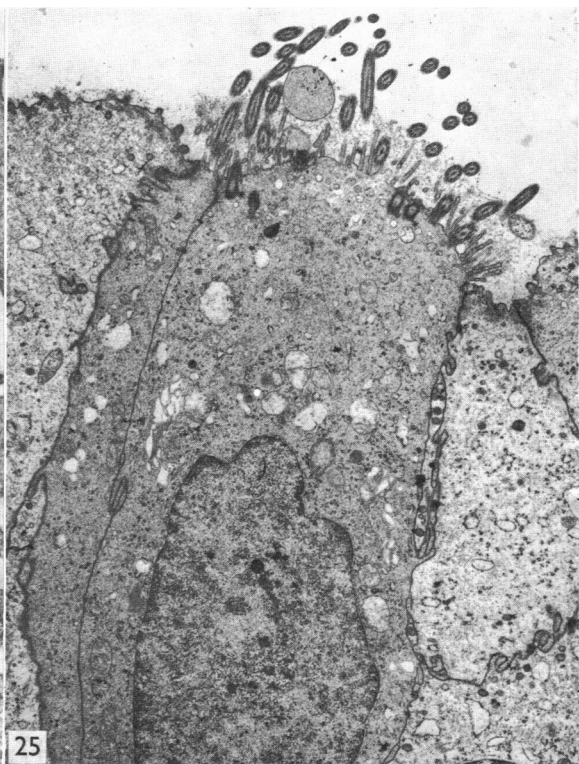
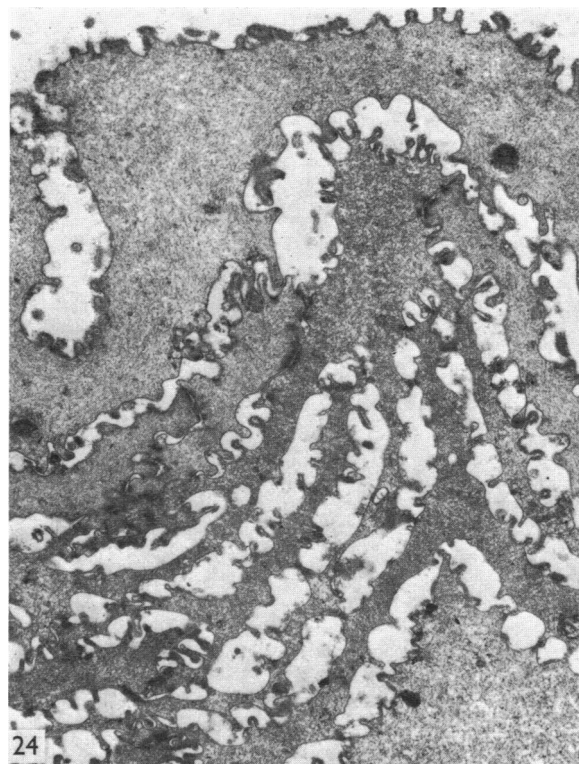
The superficial cells of the oesophageal epithelium of the 13 cm opossum retain a considerable amount of cytoplasm near the nuclei and become flattened and plate-like at the periphery. In these expanded regions a variety of organelles are observed. The cytoplasm is characterized by membrane-bound vesicles and numerous fine filaments (Fig. 23). The luminal surface continues to show stubby microvilli covered by a glycocalyx.

Cells of the superficial stratum of juvenile and adult animals appear more flattened and elongate but still show cytoplasmic filaments, scattered mitochondria, and

Fig. 21. The apex of a ciliated cell between surface squamous cells of the 4.5 cm opossum. The surface of the ciliated cell exhibits numerous, long microvilli and the cytoplasm contains numerous apical mitochondria. $\times 8000$.

Fig. 22. Cells of the superficial stratum of a 10 cm (*ca.* 60 days) opossum show varying degrees of electron density. The cells lining the oesophageal lumen show short, stubby microvilli covered by a fuzzy coat. The cytoplasm is electron-lucent, shows few organelles, but does contain numerous fine cytoplasmic filaments. Cells further from the lumen appear more electron-dense and contain a greater number of organelles. $\times 5000$.

Fig. 23. A superficial cell lining the lumen of the oesophagus from a 13 cm opossum. The cell exhibits stubby microvilli covered by a glycocalyx. Scattered vesicles (ν), mitochondria, and Golgi complexes (G) are present. The cytoplasm is filled with fine cytoplasmic filaments (arrows). $\times 8000$.



stubby microvilli covered by a fuzzy coat (Fig. 24). Occasional nuclei continue to be observed in the superficial cells of both the juvenile and adult.

The distal oesophagus of the adult opossum is peculiar not only because it exhibits numerous transverse mucosal folds, but also because it is lined by an epithelium of immature appearance in which scattered ciliated cells are found (Figs. 15, 25). The ciliated cells are similar to those described in younger specimens. In addition to cilia, the cells exhibit long microvilli covered by an abundant glycocalyx (Fig. 25). The epithelium of this region often consists of only two strata and is remarkably similar to that described in the early stages of the development of the proximal oesophagus (Fig. 26). The basal layer is composed of cuboidal cells which exhibit numerous free ribosomes and appear more electron-dense. The surface stratum consists of large columnar cells which contain small electron-dense vesicles in the apical cytoplasm (Fig. 26). The apices show stubby microvilli covered by a glycocalyx.

The oesophageal glands of the distal oesophagus are confined primarily to the lamina propria, rather than occurring in the submucosa as in the cervical and thoracic segments. The glands contain many large cells of low electron density with rounded, light, centrally positioned nuclei (Fig. 27). The remainder of the gland is comprised of mucous cells, filled with mucin granules, and exhibiting irregular 'pyknotic' nuclei confined to the base of the cell (Fig. 27). Ultrastructurally, the clear cells show low electron density, numerous mitochondria, scattered Golgi profiles, and what appear to be occasional lysosomes (Fig. 28). The adjacent cell membranes show extensive implication. Numerous secretory canaliculi also are found (Fig. 28). Mucous cells, near their base, reveal profiles of granular endoplasmic reticulum surrounding dense irregular nuclei (Fig. 29). The mucin granules show a peculiar pattern of varying electron density and are associated with scattered Golgi membranes (Fig. 29). Myoepithelial cells are found within the basal lamina of both cell types (Figs. 28, 29, 30). They appear similar to those described in numerous glandular types in a variety of species.

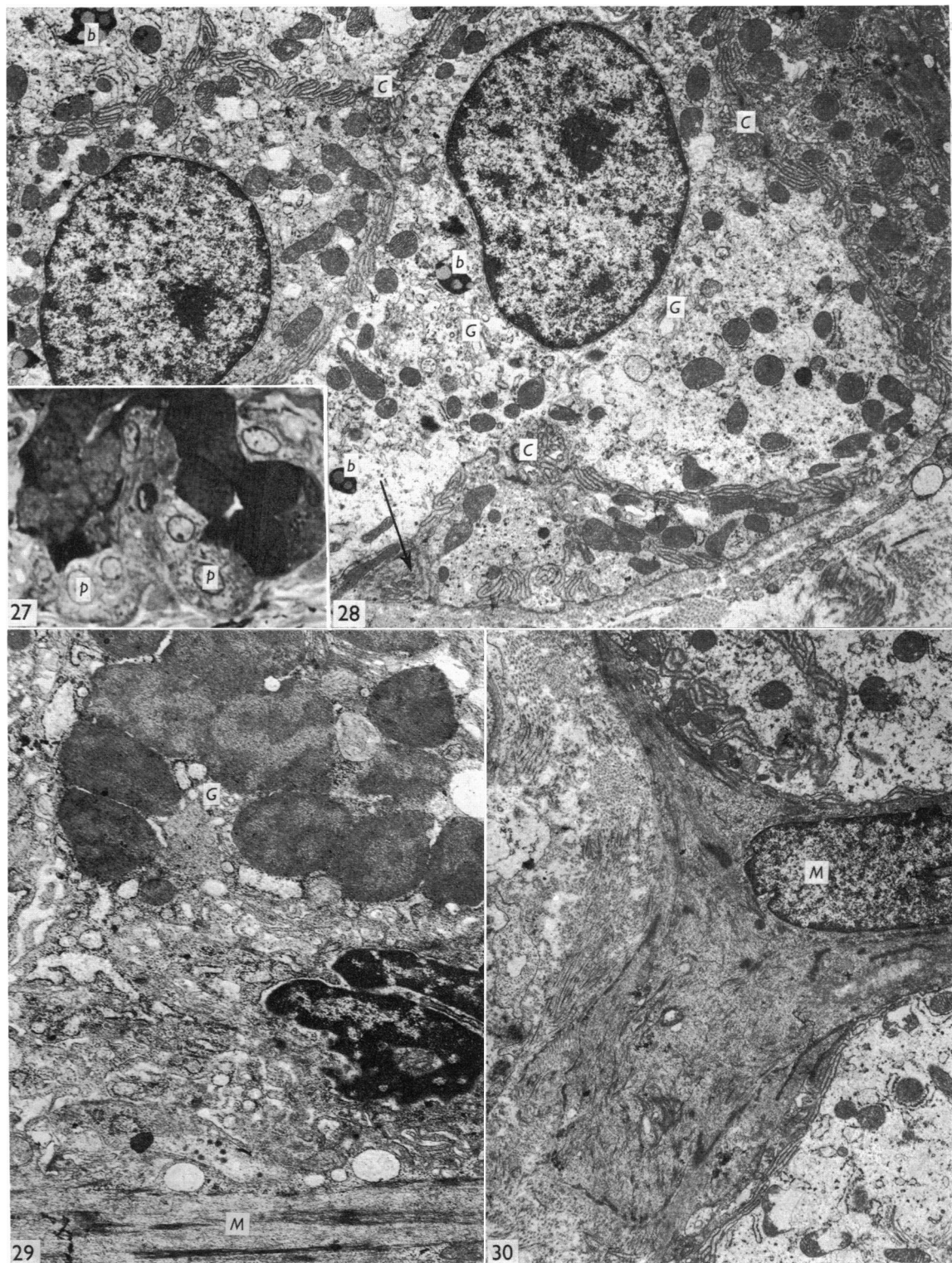
DISCUSSION

This study has detailed the extensive morphological changes that occur in the oesophagus of the opossum during postnatal development. Although it is difficult in many cases to relate these changes to varying functional activities, it must be appreciated that approximately the first 75 days of postnatal development are spent

Fig. 24. The flattened surface cells of a juvenile opossum appear to be separating and in the process of sloughing. Stubby microvilli and a glycocalyx cover all apical cell surfaces. The cytoplasm exhibits a paucity of organelles. 20 cm opossum. $\times 6000$.

Fig. 25. A ciliated cell from the distal oesophagus of an adult opossum. Note the abundance of glycocalyx at the apex around the cilia and microvilli. Surrounding cells are immature in appearance. $\times 5600$.

Fig. 26. The epithelium from within the transverse folds of the distal oesophagus is composed of two strata. Surface cells are columnar in shape and contain small electron-dense vesicles at the apex (arrows). The apical cell surface also shows stubby microvilli covered by a glycocalyx. Basal cells are cuboidal and appear more electron-dense. $\times 4200$.



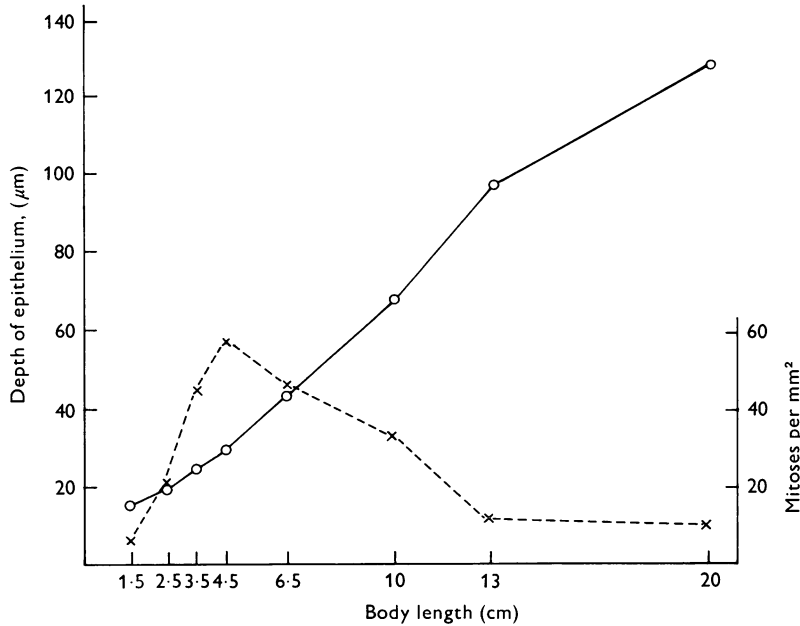


Fig. 31. Quantitative data for thickness and mitotic activity of mucosal epithelium in the oesophagus of the developing opossum. The solid line shows the thickness of the epithelial layer in microns, the interrupted line presents the number of mitotic cells per mm².

within the marsupium, and that it is not until about 90 days that the young are weaned.

The oesophageal epithelium of the newborn opossum is 2–3 cells in depth and shows numerous invaginations from its surface. By the ninth day of postnatal development, it is organized into two distinct cell layers. The basal stratum is comprised of a single layer of small irregular cells that show considerable electron density and contain numerous ribosomes. The surface stratum consists of large

Fig. 27. A light micrograph of the secretory tubules from an oesophageal gland shows its two secretory components. Cells filled with mucin droplets exhibit dense pyknotic nuclei at the base. Large pale staining cells (*p*), with centrally placed round nuclei, also are shown. These cells show occasional scattered granules. Adult opossum. Epon 812–toluidine blue. × 300.

Fig. 28. The light cells exhibit an electron-lucent cytoplasm with numerous mitochondria. Golgi complexes (*G*) and irregular dense bodies (*b*), thought to be lysosomes, also are present. The adjacent cell membranes show extensive implication and numerous secretory canaliculi (*C*) are observed. A portion of a myoepithelial cell is shown at bottom left (arrow).

Fig. 29. A segment of the mucous cell type illustrates the dense irregular nucleus and apical secretory granules. The granules show an irregular pattern of electron density. The basal portion of the cell shows profiles of granular endoplasmic reticulum and Golgi membranes (*G*) are associated with the apical secretory granules. A portion of the myoepithelial cell (*M*) is shown at the bottom. × 6000.

Fig. 30. A portion of a branching myoepithelial cell (*M*) near the base of the two adjacent light cells. × 4500.

polygonal cells that contain an electron-lucent cytoplasm and show stubby microvilli on the luminal surface. Similar large surface cells have been reported in the oesophageal epithelium of the 6 mm pig (Flint, 1907). Ciliated cells, and occasional goblet cells, are observed within the epithelium during this and in several subsequent stages of postnatal development. Frogs and other lower forms are reported to maintain a ciliated oesophageal epithelium throughout life (Kendall, 1947; Ivey & Edgar, 1952; Norris, 1959; Das, Sanyal & Sinha, 1964). Cilia also have been reported in the developing oesophagus of the chicken, turkey, guinea fowl and pigeon (Edgar, 1947; Ivey & Edgar, 1952; Hinsch, 1967), as well as in some mammals (Sevcenko, Brichova & Vacek, 1972; Sevcenko & Vacek, 1973) including man (Johnson, 1910; Johns, 1952). Unlike other mammalian forms reported to date, cilia persist in the oesophagus of the adult opossum, but are restricted to the depths of the transverse folds in the distal part of the organ. The epithelium covering these transverse folds is remarkably immature in appearance, being similar to that observed in the 3.5 cm (*ca.* 17 days) opossum. Cilia observed both in the postnatal stages and in the adult oesophagus appear similar in structure to those reported in the respiratory tract of the opossum (Krause & Leeson, 1975) and other species. Unlike those of the opossum oesophagus, cilia in the developing rat oesophageal epithelium have been reported to be atypical. They lack the characteristic basal body and instead show an osmiophilic zone of fine granulofilamentous substance (Sevcenko & Vacek, 1973). Ciliated cells of both the rat and the opossum show elongate microvilli between cilia. Microvilli on the luminal surface of the opossum oesophageal lining cells appear short and stubby and are covered by a thin glycocalyx. The glycocalyx may be of considerable depth between microvilli of ciliated oesophageal cells in the adult opossum.

Goblet cells observed within the oesophageal epithelium of many stages appear morphologically similar to those described in the intestinal epithelium of several species. They exhibit a dense 'pyknotic' nucleus toward the base and large, flocculent, membrane-bound granules in the supranuclear and apical cytoplasm.

By 4.5 cm (*ca.* 20 days), the oesophageal epithelium has changed from the immature condition found earlier to one of greater depth. The surface layer consists of flattened squamous cells which retain their nuclei. Goblet cells, scattered within the epithelium, continue to be observed. This and later stages show three basic strata: a germinal layer, a spinous layer and, adjacent to the lumen, a flattened layer of cells that retain their nuclei. The surface cells continue to show short stubby microvilli covered by a delicate glycocalyx. The epithelium throughout the suckling period, and in the adult, does not undergo complete keratinization. Similar observations have been made in the pigeon and chicken (Mottet, 1970; Kudo, 1971), pig (Flint, 1907), human (Mottet, 1970), and in newborn mice (Parakkal, 1967). Surface cells of the former species, as well as the opossum, show nuclei even in the outermost layer. The degree of cornification is thought to be correlated largely with the diet of the species (Goetsch, 1910). In animals, such as rodents and ruminants, which ingest coarse food materials, the oesophageal epithelium shows complete cornification, whereas those species consuming generally soft foods (carnivores and man) lack a thick cornified layer and the surface cells appear similar to those observed in the opossum. Cells of the stratum corneum of the chicken and pigeon oesophagus also

retain altered nuclei and organelles and fail to show the typical pattern of keratinization (Mottet, 1970; Kudo, 1971).

Superficial cells of the oesophageal epithelium of the 3.5 cm opossum (*ca.* 17 days) and of subsequent stages show numerous membrane-bound vesicles which vary considerably in electron density. Such vesicles may correspond to the membrane-coating granules reported in the mouse (Rowden, 1966), which are thought to be involved in the process of keratinization. Keratohyalin granules are not observed in the oesophageal epithelium of the opossum.

The fine cytoplasmic filaments observed in the later stages are thought to be tonofilaments and have been described previously in oesophageal epithelial cells of chicken, pigeon (Kudo, 1971), ferret, mouse (Pfeiffer, Rowden & Weibel, 1974), and rat (Toner, Carr & Wyburn, 1971).

The sloughing of surface cells in the older opossums commences in the luminal layer of epithelium when adjacent cell membranes separate and wide intercellular spaces develop. As the intercellular spaces increase in width, cells lose contact with one another and are sloughed. Similar observations have been reported in the oesophageal epithelium of the newborn mouse (Parakkal, 1967). Cell surfaces of sloughing elements in the opossum continue to show stubby microvilli and are covered by a thin glycocalyx. The glycocalyx corresponds in position to the areas of PAS activity observed at the light microscopic level on the surface of cells. Wislocki, Fawcett & Dempsey (1951) also reported PAS activity around the superficial cells of the stratified squamous epithelium of human and monkey mucous membranes and skin.

The oesophageal glands of the opossum begin as solid outgrowths from the base of the oesophageal epithelium just prior to the 4.5 cm (*ca.* 20 days) stage. The glands continue their development throughout the remainder of the postnatal period. Oesophageal glands of other mammalian species, such as the pig (Flint, 1907) and man (Johnson, 1910; Mottet, 1970), usually develop from similar outgrowths of the epithelium, but in the prenatal period. Secretory tubules and acini of the oesophageal glands of the opossum are composed of two distinct cell types. Mucous cells form the major portion of the secretory elements in the opossum. They contain numerous membrane-bound granules which show irregular patterns of varying electron density. Granular endoplasmic reticulum and Golgi membranes are restricted to the base of the cell. A light, rounded cell type, which is less numerous, often occupies the terminal portions of the secretory units or, on occasion, forms individual acini. The light cells occupy a position similar to the serous demilune cells in the submandibular salivary gland of a variety of species. Goetsch (1910) has reported, in a light microscopy study, that mammalian oesophageal glands in most species consist of two cell types: mucous and serous. The only possible exception is man, where the glands are reported to consist solely of mucous elements. Johns (1952), however, stated that both cell types are present in man.

Ultrastructurally, the light cells of the opossum lack the accumulations of granular endoplasmic reticulum and the discrete secretory granules which characterize the serous cells of many exocrine glands. Instead, they show an electron-lucent cytoplasm with few organelles, numerous secretory intercellular canaliculi and basal infolding of the plasmalemma. Structurally, the light cells appear similar to the hydrotic cell reported in bronchial glands of the opossum (Sorokin, 1965). Both the mucous and

light cells of the opossum oesophageal glands are embraced by numerous myoepithelial cells. Myoepithelial cells also have been reported surrounding both serous and mucous secretory elements of the oesophageal glands in cattle (Wakuri & Muto, 1972).

The secretory material elaborated by the mucous elements of the opossum oesophageal glands appears complex, consisting of both neutral and acid glycoproteins. Individual mucous cells may elaborate one or the other, or both, as indicated by their stainability. The oesophageal glands of man also are reported to elaborate both neutral and acidic glycoproteins (Lambert *et al.* 1973). The role of the light cell in the oesophageal glands of the opossum is unknown at present, but they may be involved in the production of a watery secretion similar to that produced by the hydrotic cell of the opossum bronchial gland (Sorokin, 1965).

The mitotic sequences noted in this study can be related to the observations made by general microscopic examination of the oesophagus. Just prior to establishment of the muscularis mucosae an increase in mitotic activity is seen within the combined subepithelial layers, and this presumably foreshadows the establishment of the muscularis mucosae. The mitotic activity persists throughout the 3.5 and 4.5 cm stages, at which time a definite but delicate muscularis mucosae can be distinguished. The decline in mitotic activity within the muscularis mucosae is relatively slow and even in the juvenile the rate of cell division is in excess of that in the lamina propria and submucosa. This would relate to the appearance of a thick, well-formed muscularis mucosae in the older animals of this species. Similarly, the establishment of a well-defined muscularis externa at the 2.5 cm stage is accompanied by an observed peak of mitosis in this layer and, like the muscularis mucosae, the muscularis externa maintains a relatively high rate of cell division throughout its subsequent development.

The number of mitotic cells within the epithelial layer is much greater than in any other stratum and this would be in keeping with a tissue in which there is both a need to build up a thickened layer and at the same time to replace cells lost from the surface. The peak of mitotic activity within the mucosal epithelium at the 4.5 cm stage coincides with an outgrowth of the epithelium to provide the initial formation of the oesophageal glands. Similarly, the peak of mitosis in the submucosa is related to the extension of the oesophageal glands and to the establishment of well defined ducts at this stage.

SUMMARY

The oesophageal epithelium of the newborn opossum generally is two to three cells in depth and in some regions appears pseudostratified. By the 9th postnatal day the epithelium shows two distinct strata. Ciliated cells and occasional goblet cells also are observed within the epithelium during this stage and in subsequent stages. Cilia persist in the oesophagus of the adult opossum, but are restricted to the depths of the transverse folds found in the distal part of the organ. The epithelium covering the transverse folds of the adult likewise has an immature appearance. By 4.5 cm (*ca.* 20 days), the epithelium has assumed a more mature appearance and is of greater depth. This and later stages show three basic strata: a germinal layer, a spinous layer and, adjacent to the lumen, a flattened layer of cells that retain their nuclei.

The epithelium throughout the postnatal period and in the adult does not undergo complete keratinization.

The oesophageal glands begin as outgrowths from the epithelium just prior to 4.5 cm (*ca.* 20 days). The glands continue their development throughout the remainder of the postnatal period. The secretory units of the oesophageal glands of the opossum are composed of two distinct cell types: a mucous form, which comprises the major portion of the secretory elements, and a light, rounded cell type which is less numerous and which occupies the terminal portions of the secretory units. Secretory material of the former appears complex, consisting of both neutral and acid glycoproteins. The secretory product of the light cell type is unknown at present. Both cell types are encompassed by myoepithelial cells.

The relationship of the mitotic sequences to the observations made by microscopic examination of the developing oesophagus is discussed.

We would like to express our sincere gratitude to Ms D. Sherman, research associate, for her excellent technical assistance and to W. Crawford, F. Sampson, H. Terrill, and C. Caldwell of the Missouri Conservation Commission for the use of materials and facilities in the present study.

This work was supported by grant 6515 Penrose Fund from the American Philosophical Society, and by University Research Council Grant NSF1074 for general research support.

REFERENCES

- DAS, P. K., SANYAL, A. K. & SINHA, P. S. (1964). Studies on ciliary movements. I. Mechanism of ciliary movement in frog's oesophagus. *Archives internationales de pharmacodynamie et de therapie* **150**, 348-355.
- EDGAR, S. A. (1947). Ciliated epithelial cells lining the oesophagus of young turkey and chick embryos. *Poultry Science* **46**, 525-534.
- FLINT, J. M. (1907). The organogenesis of the oesophagus. *Anatomischer Anzeiger* **30**, 442-451.
- GOETSCH, E. (1910). The structure of the mammalian esophagus. *American Journal of Anatomy* **10**, 1-40.
- HEUSER, C. H. (1921). The early establishment of the intestinal nutrition in the opossum - the digestive system just before and soon after birth. *American Journal of Anatomy* **28**, 341-369.
- HINSCH, G. W. (1967). Ultrastructural differentiation of the epithelium and mucous glands of the esophagus in the chick embryo. *Journal of Morphology* **123**, 121-132.
- IVEY, W. D. & EDGAR, S. A. (1952). The histogenesis of the esophagus and crop of the chicken, turkey, guinea fowl and pigeon with special reference to ciliated epithelium. *Anatomical Record* **114**, 189-211.
- JOHNS, B. A. E. (1952). Developmental changes in the oesophageal epithelium in man. *Journal of Anatomy* **86**, 431-442.
- JOHNSON, F. P. (1910). The development of the mucous membrane of the oesophagus, stomach and small intestine in the human embryo. *American Journal of Anatomy* **10**, 521-561.
- KENDALL, J. I. (1947). *The Microscopic Anatomy of Vertebrates*. 3rd ed. Philadelphia: Lea and Febiger.
- KRAUSE, W. J. & LEESON, C. R. (1975). The postnatal development of the respiratory system of the opossum. II. Electron microscopy of the epithelium and pleura. *Acta anatomica* **92**, 28-44.
- KUDO, S. (1971). Electron microscopic observations on avian esophageal epithelium. *Archivum histologicum japonicum* **33**, 1-30.
- LAMBERT, R., PANSU, D., BERARD, A., VITANI, C. & DECHELETTE, M. A. (1973). Histochemical studies on human mucous secreting glands in the soft palate, uvula and esophagus. *Digestion* **8**, 110-119.
- MOORE, C. R. & BODIAN, D. (1940). Opossum pouch young as experimental material. *Anatomical Record* **76**, 319-327.
- MOTTET, N. K. (1970). Mucin biosynthesis by chick and human oesophagus during ontogenetic metaplasia. *Journal of Anatomy* **107**, 49-66.
- NORRIS, J. L. (1959). The normal histology of the esophagus and gastric mucosae of the frog, *Rana pipiens*. *Journal of Experimental Zoology* **141**, 155-174.

- PARAKKAL, P. F. (1967). An electron microscopic study of esophageal epithelium in the newborn and adult mouse. *American Journal of Anatomy* **121**, 175-196.
- PFEIFFER, C. J., ROWDEN, G. & WEIBEL, J. (1974). *Gastrointestinal Ultrastructure. An Atlas of Scanning and Transmission Electron Micrographs*. New York: Academic Press.
- REYNOLDS, H. C. (1942). A contribution to the life history and ecology of the opossum, *Didelphis virginiana*, in Central Missouri. M.A. Thesis, University of Missouri.
- ROWDEN, G. (1966). Membrane-coating granules of mouse oesophageal and gastric epithelium. *Journal of Investigative Dermatology* **47**, 359-362.
- SEVCENKO, G., BRICHOVA, H. & VACEK, Z. (1972). Some observations on the ultrastructure of differentiation of the oesophageal epithelium in mammals. *Folia Morphologica* **20**, 79-81.
- SEVCENKO, G. & VACEK, Z. (1973). A contribution to the histogenesis of the oesophageal epithelium in mammals. *Folia morphologica* **21**, 261-264.
- SOROKIN, S. P. (1965). On the cytology and cytochemistry of the opossum's bronchial glands. *American Journal of Anatomy* **117**, 311-338.
- TONER, P. G., CARR, K. E. & WYBURN, G. M. (1971). *The Digestive System. An Ultrastructural Atlas and Review*. London: Butterworths.
- WAKURI, H. & MUTO, K. (1972). The fine structure of the cattle esophageal gland with a special reference to the myoepithelial cells. *Kitasato Archives of Experimental Medicine* **45**, 45-50.
- WISLOCKI, G. B., FAWCETT, D. W. & DEMPSEY, E. W. (1951). Staining of stratified squamous epithelium of mucous membranes and skin of man and monkey by the periodic acid-Schiff method. *Anatomical Record* **110**, 359-375.