

The intramuscular nerve endings in dystrophia myotonica—a biopsy study by vital staining and electron microscopy

D. E. ALLEN, A. G. JOHNSON* AND A. L. WOOLF†

Midland Centre for Neurosurgery and Neurology, Smethwick, Worcs

(Received 29 April 1968)

INTRODUCTION

The earliest report on the intramuscular nerve endings in dystrophia myotonica was that of Coërs (1952), who in a study of four cases demonstrated by vital staining a number of large end-plates up to three or four times the normal size.

In 1955 Coërs again referred to the pattern of intramuscular innervation in two cases of dystrophia myotonica. He emphasized the tortuous course of the terminal axons and irregularity in size of the end-plates with very large terminal arborizations sometimes forming a complicated plexus surrounding a muscle fibre for up to 150 μm of its length. He also reported an increased incidence of multiple end-plates raising the *absolute* but not the *functional terminal innervation ratio*. Cholinesterase preparations demonstrated an increase in the mean diameter of the subneural apparatuses of the end-plates and an excessive dispersal of the values. Coërs also reported subneural apparatuses with very spread-out elements corresponding to plexiform tangles surrounding the muscle fibres seen in the vitally stained preparations.

In 1959 Coërs & Woolf, summarizing the findings in six cases also studied by vital staining and histochemical demonstration of cholinesterase, emphasized not only the preservation of nerve fibres within the intramuscular nerve bundles which is characteristic of all muscular dystrophies but also the remarkable degree of sprouting of the terminal axons. Two characteristic features of the intramuscular nerve endings in dystrophia myotonica were already apparent in this early report. First, there is indeed a pronounced tendency to sprouting of the terminal axons, but in the absence of the denervated muscle fibres of a neuropathy the sprouts must inevitably form new end-plates on muscle fibres which are already innervated, leading to hyperneurotization and a rise in the *absolute terminal innervation ratio*. By hyperneurotization is implied formation of multiple end-plates on a single muscle fibre by branches of a single nerve fibre and not formation of more than one end-plate on a muscle fibre by more than one subterminal nerve fibre. In primary degeneration of the lower motor neuron denervated muscle fibres are re-innervated by sprouts from surviving axons leading to a rise in the *functional terminal innervation ratio* (number of muscle fibres innervated by one terminal axon). This rise does not occur in dystrophia myotonica. Secondly, there is in dystrophia myotonica a tendency for axonal sprouts

* Present Address: Department of Rheumatism Research, The Medical School, Birmingham.

† In receipt of grants from the National Fund for Research into Poliomyelitis and other Crippling Diseases and from the Medical Research Council.

to pursue a course parallel with the muscle fibres to which short collateral branches are given off at intervals. Each of these branches terminates on the surface of a muscle fibre in a small, often spherical, terminal expansion so that a series of miniature neuromuscular synapses are distributed on the surface of the muscle fibres along their longitudinal axes. Coërs and Woolf were able to show by means of the histochemical demonstration of cholinesterase that these synapses extended beyond the original innervation zone (Coërs & Woolf, 1959, fig. 227). In a later publication Woolf (1962) pointed out the resemblance of such a pattern of innervation to that of the normal motor innervation of the muscle fibres of the muscle spindle. Noting evidence suggesting a similarity in the contractility of the intrafusal fibres to that of 'slow' muscle fibres of frogs he suggested that there might be a correlation between the pattern of innervation in dystrophia myotonica and the myotonia and even the high-frequency low-voltage 'dive-bomber' insertion potentials observed on electromyography in this disease. However, it was necessary to point out later (Woolf, 1962, 1963) that it is possible to elicit these potentials in areas of muscle well removed from the innervation zone where it is hardly to be anticipated that axonal sprouts could extend. It is therefore improbable that the high-frequency discharges are the result of the needle electrode impinging on the sprouting nerve fibres. Furthermore, although such longitudinal series of miniature synapses are characteristic of dystrophia myotonica—they are not uniquely confined to this condition being very occasionally seen in myositis—they are not seen so invariably and in such numbers as to make them easily acceptable as a basis for so universally present and prominent a feature as the myotonia. It should also be pointed out that in myotonia congenita we have not seen the type of axonal sprouting with miniature synapse production that we have seen in dystrophia myotonica, although the end-plates are very large and elaborate in myotonia congenita. However, our material from the latter condition is small.

MacDermot (1961) in ten cases studied by vital staining saw abnormalities of the axons in all of them, both in the distal nerve fibres and in the nerve bundles. The axons showed deeply staining swellings, either globular or elongated, or great reduction in the calibre of the nerve fibres. A marked increase of nerve branching other than that which occurred pre-terminally in relation to the end-plates was present in only one case. The majority of end-plates were abnormally small, but elongated end-plates running parallel to muscle fibres were seen in all cases. The striking feature of the majority of cases was the extremely profuse terminal branching of the nerve fibres with the formation of multiple end-plates on the same muscle fibre. MacDermot concluded that there is in dystrophia myotonica, in addition to a disorder of muscle, a neuronal defect. While there is in no disease other than dystrophia myotonica so great a tendency to a distally situated branching of the subterminal fibres with resultant formation of double or even multiple end-plates on single muscle fibres, such branching is sometimes seen, though to a less extent, in myasthenia gravis and myositis. In these two conditions, however, the axonal sprouts are usually more delicate and beaded and the end-plates, though they may be expanded or elongated, lack the large terminal axonic expansions often seen in dystrophia myotonica.

METHODS AND OBSERVATIONS

It is the purpose of this paper to analyse the changes in the motor end-plates in the light of a larger series of cases (twenty-six) in which the diagnosis was confirmed by the presence of 'dive-bomber potentials' on electromyography and the characteristic appearance of the muscle in histological sections stained with haematoxylin and eosin. In all the cases vitally stained preparations of the nerve ending were available and in eight, squash preparations (for techniques see Woolf, 1962) were made,

Table 1. *Cases of dystrophia myotonica*

(In Tables 1 and 2 the measurements and counts refer to individual end-plates. Thus in the case of multiple end-plates on a single muscle fibre, each end-plate on that muscle fibre is assessed separately.)

Case	Muscle	No. of end-plates	Multiple end-plates		Mean max. diam. (μ m)	Mean no. of term. expns.
			No.	%		
Pe.	Palmaris longus	75	2	2.6	24.2	6.7
Ha.	Flexor carpi radialis	23	2	9.1	20	3.7
Wi.	Palmaris longus	34	7	20.6	24.6	6.0
Fa.	Deltoid	30	3	10.0	31.1	7.6
McC.	Palmaris longus	58	13*	22.4	27.9	8.3
Do.	Palmaris longus	277	72†	26.0	30.9	9.8
Pre.	Flexor carpi radialis	52	14‡	26.9	32.7	11.6
Ve.	Palmaris longus	120	23§	19.2	24.1	7.1

* Including two triple and one quadruple end-plate.

† Including ten triple and two quadruple end-plates.

‡ Including three triple and one quadruple end-plate.

§ Including four triple end-plates.

Table 2. '*Normal*' cases

Case	Muscle	No. of end-plates	Multiple end-plates		Mean max. diam. (μ m)	Mean no. of term. expns.
			No.	%		
Wa.	Deltoid	146	2	1.3	20.0	5.5
Kn.	Deltoid	67	3	4.3	21.4	6.8
Gr.	Palmaris longus	53	3*	5.9	21.1	11.8
Pe.	Palmaris longus	97	14*	13.8	18.3	6.7

* Including one triple end-plate

facilitating statistical assessment of the changes. It should be emphasized that the vitally stained preparations are only 'squashed' between microscope slides *after* fixation in ammonium molybdate and examination of the end-plates under the microscope before and after 'squashing' has shown that no change in the outline of the end-plate components occurs although the end-plate as a whole no doubt adjusts itself to the form of the muscle fibre, which is certainly flatter than in life. The same technique of 'squashing' is used for all our preparations so that comparisons of diameters are meaningful. In seven cases electron-microscopic preparations were made by the technique described by Cooke, Johnson & Woolf (1966). In one case two end-plates were examined, in all the others, not less than six. Here

also the pieces of muscle *after* fixation in osmic acid are viewed between glass slides in order to locate the nerve bundles, but negligible pressure is applied and it seems unlikely that the tissue is damaged.

Functional terminal innervation ratios have not been calculated in this series of cases since the loss of muscle fibres and the marked degree of sprouting of the distal extremities of the subterminal nerve fibres often rendered the pattern of innervation too complicated to make such counts feasible. Collateral re-innervation of more than one muscle fibre by a single nerve fibre was, however, very infrequent.

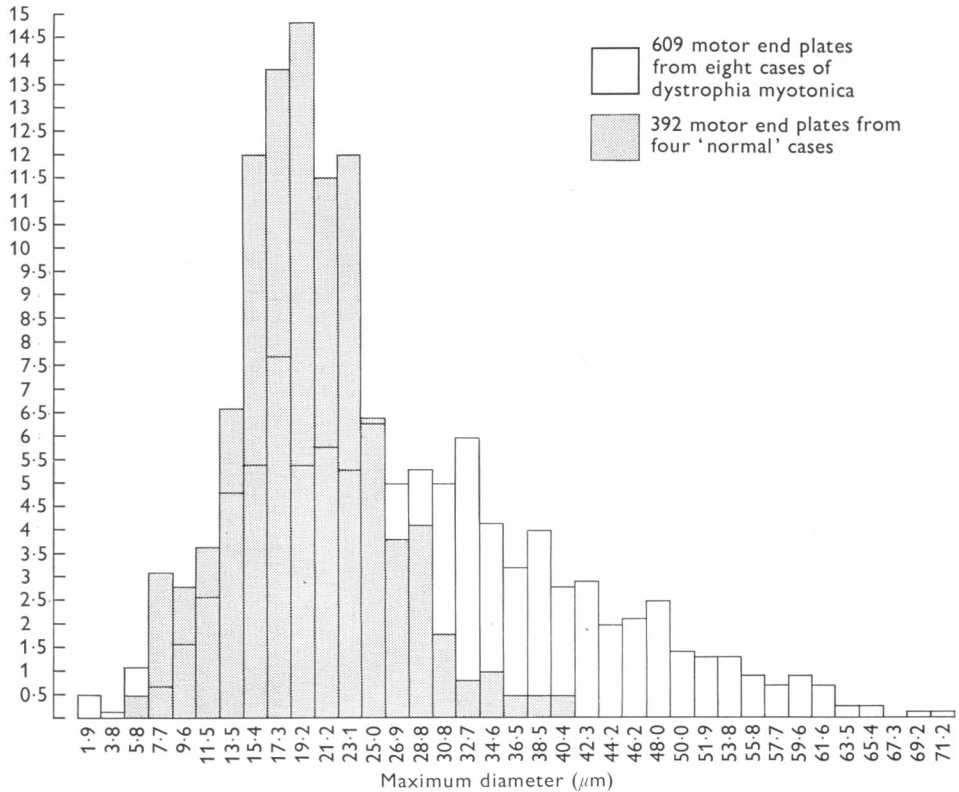


Fig. 1. Histogram indicating that the variation in maximum diameter of the motor end-plates is much greater in dystrophonia myotonica than in the 'normal' and that the tendency is towards end-plates with a larger maximum diameter.

In order to provide a statistical analysis of the degree of peripheral branching and hyperneurotization of muscle fibres we have recorded in each of our cases of dystrophonia myotonica and in four cases in which the terminal innervation pattern was thought to be normal the number of double end-plates and also the size of the end-plate (greatest cross-sectional diameter) and the number of terminal expansions (Tables 1, 2; Fig. 1). The decision as to whether an end-plate is single, double or multiple is not always easy, but in general when a group of terminal axonic expansions was separated from another group by a distance greater than that existing between the individual expansions in each group this was considered an indication that the

end-plate was double. The fact that the same observer using the same admittedly subjective criteria assessed the 'normal' and the dystrophia myotonica material renders the statistical comparison meaningful. The two 'normal' cases with biopsies from the *deltoid* were from patients suspected of having polyarteritis nodosa, but no evidence of this was present in the haematoxylin and eosin stained sections and there was no clinical evidence of involvement of these muscles. One of two cases with biopsies from the *palmaris longus* was from a case (Pe.) aged 39 suspected of having peroneal muscular atrophy but without clinical evidence of involvement of the biopsied muscle. This case was later shown to have a neurofibroma on a lumbar spinal root, so the *palmaris longus* was presumably normal. The other case (Gr.), a man aged 33, was suspected of having myositis but there was no histological evidence of this and his muscular weakness and other symptoms cleared up very quickly.

Table 3

	No. of end-plates	Mean values		
		Synaptic area (μm^2)	Total area (μm^2)	Synaptic index
Normal cases				
Pe.	21	110.5	415.5	0.27
Ku.	26	153.2	400.0	0.40
Wa.	26	128.6	359.9	0.36
Gr.	33	148.7	360.8	0.41
Dystrophia myotonica cases				
Per.	21	118.2	1082.7	0.12
Do.	26	156.4	1266.0	0.12

In this table 'end-plate' implies the entire synapse on the muscle fibre. Thus in the case of multiple end-plates on a single muscle fibre the synaptic area, total area and synaptic index values were calculated on the basis of measurements of all the end-plates on the muscle fibre.

A more graphic indication of the incidence of enlarged and multiple end-plates and their morphology is given in the illustrations (Figs. 2-5) which each show twenty-five unselected end-plates from two cases of dystrophia myotonica compared with two of the four cases in which there was no evidence of neuromuscular disease.

The tendency to enlargement of the end-plate as a whole with an increased number of mostly well-formed terminal axonic expansions is clearly shown, as is also the frequency of multiple end-plates. More detailed information on the neuromuscular synapse has also been provided in the form of synaptograms and histograms (Figs. 6, 7) and a table (Table 3) indicating the synaptic index and other parameters of the end-plate. The synaptograms were made from enlarged photomicrographs of the end-plates. The terminal axonic expansions were then inked in with indian ink and the photomicrographs re-photographed at a size suitable for measurement of the aggregate of the areas of the expansions (synaptic area) on a Quantimet apparatus (Metals Research Ltd.). The synaptic index is the ratio (synaptic area)/(total area), 'total area' being the area of the smallest rectangle which will enclose the end-plate. The synaptic index is much lower in the two cases of dystrophia myotonica than in the 'normal' cases. This is an indication of the greater dispersion of the terminal axonic

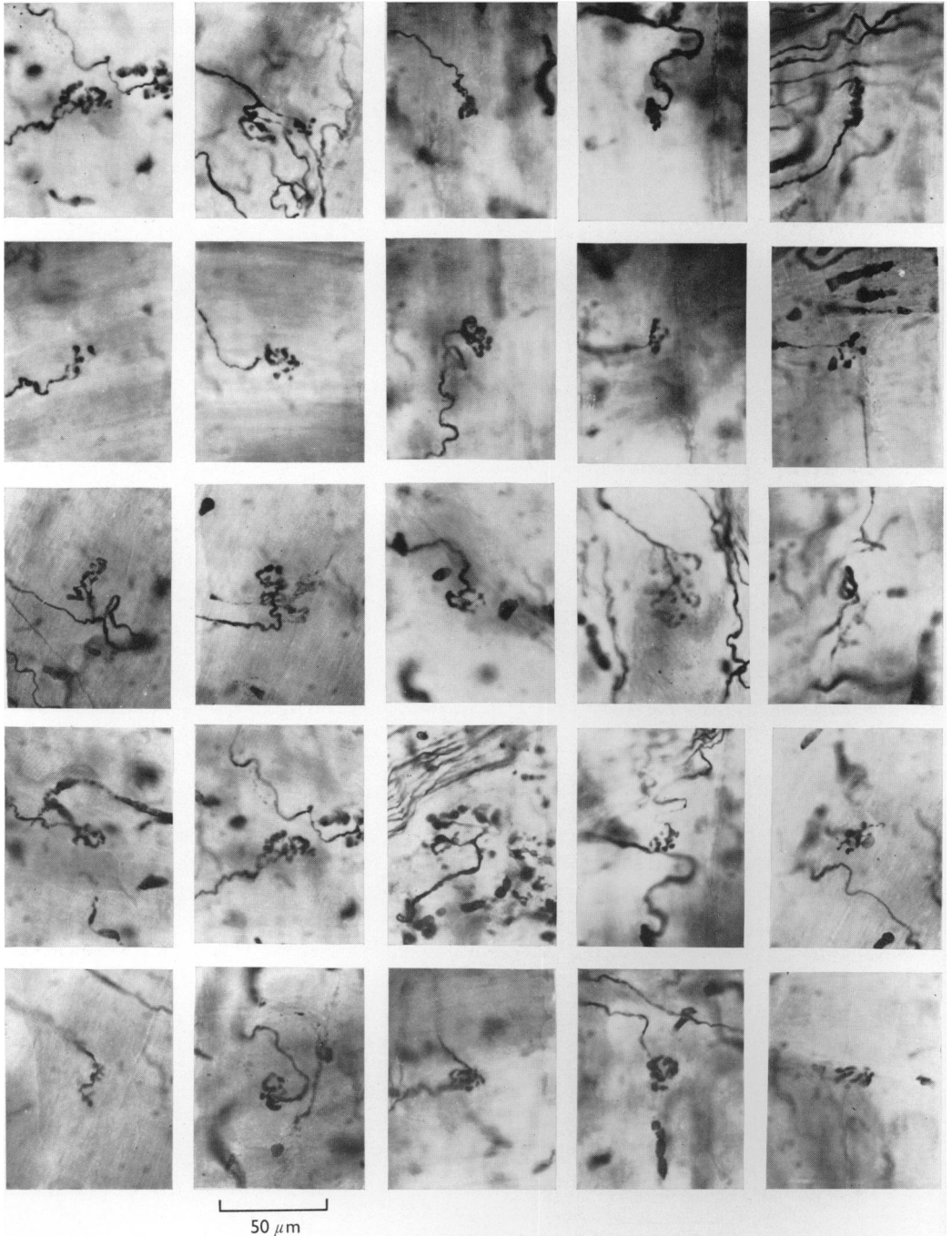


Fig. 2

Figs. 2, 3. Twenty-five unselected motor end-plates from the deltoid and palmaris longus of each of two patients (Wa., fig. 2, Gr., fig. 3), in whom the innervation of the muscle examined was thought to be normal. Vital staining with methylene blue.

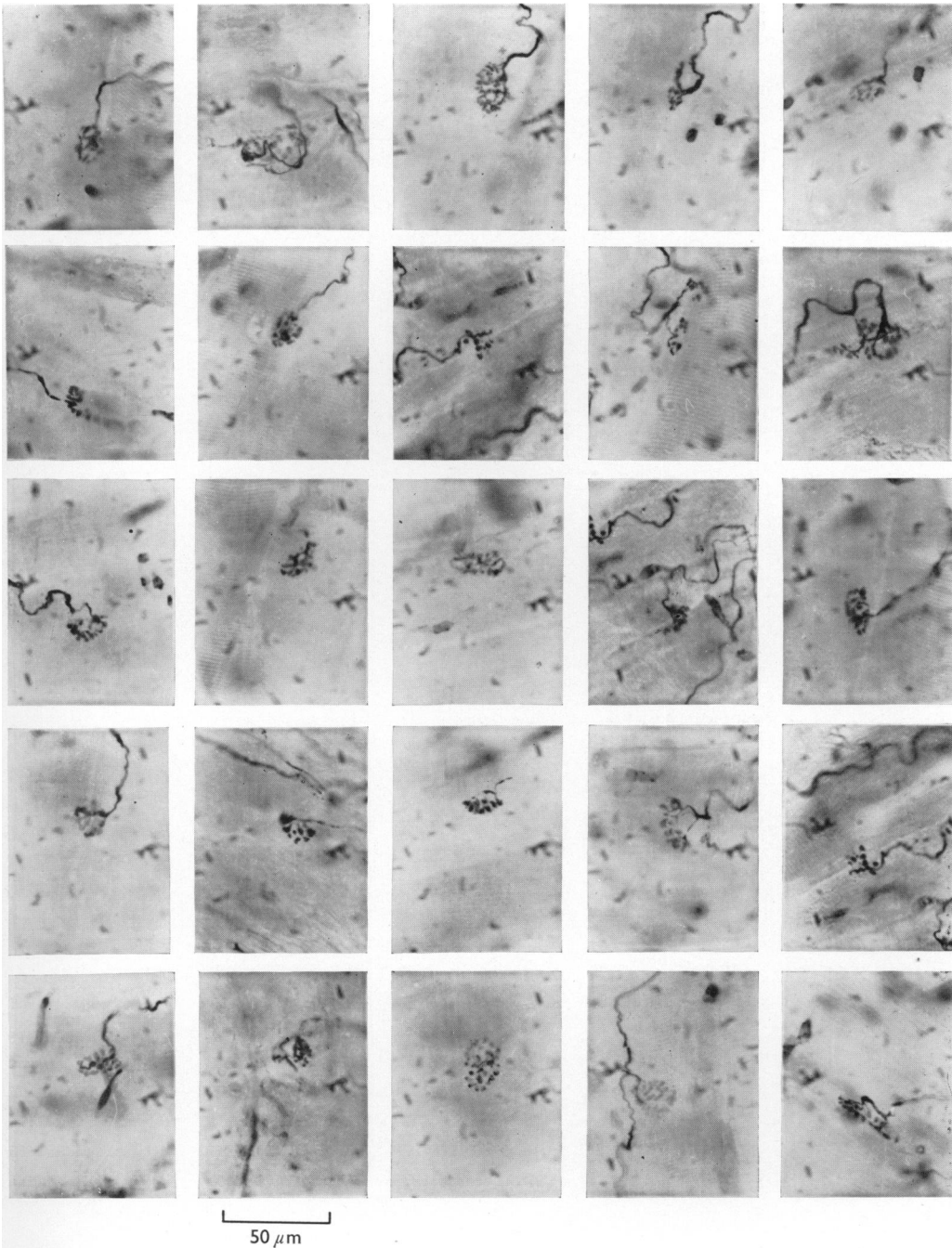


Fig. 3. For legend see fig. 2 opposite.

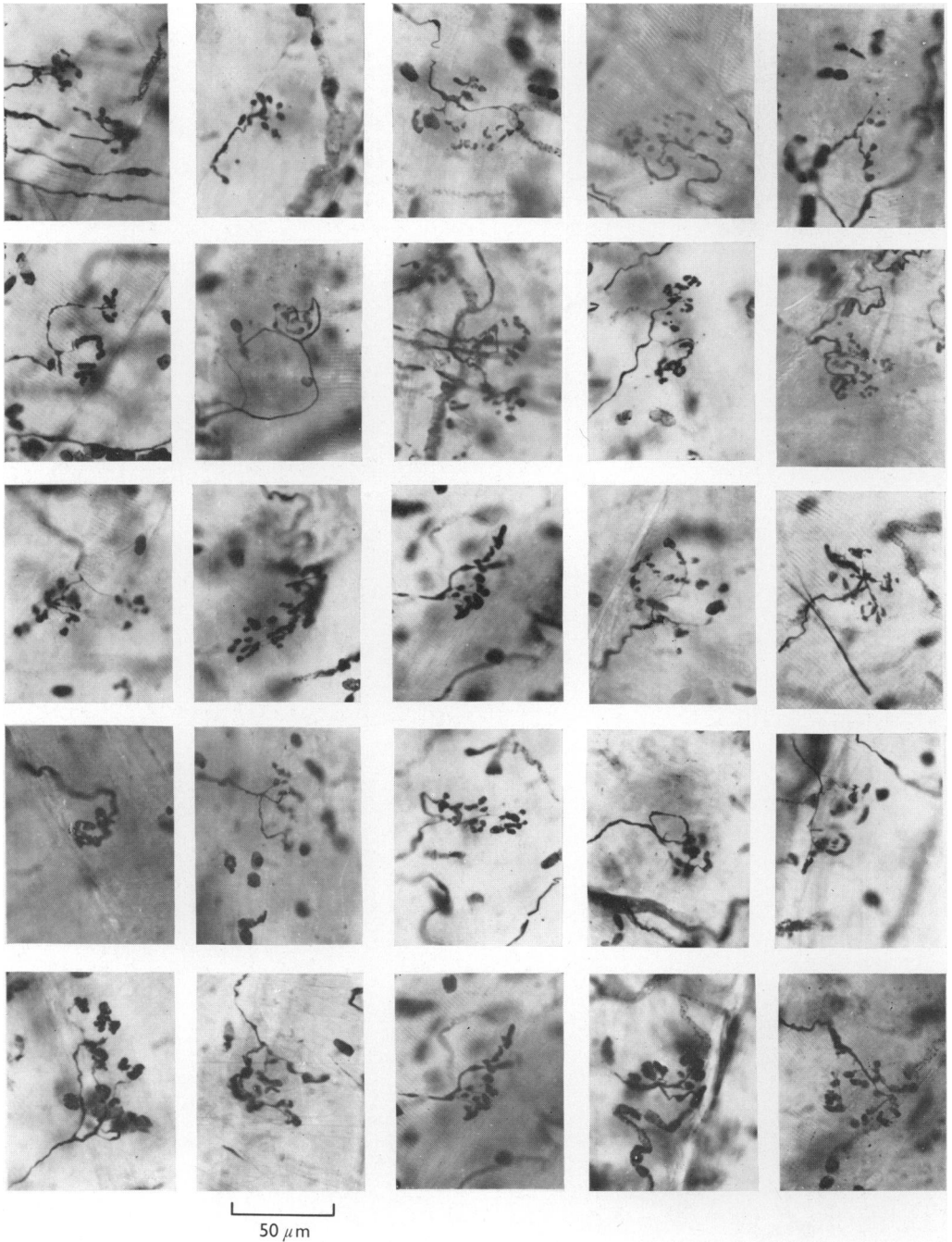


Fig. 4

Figs. 4, 5. Twenty-five motor end-plates from the palmaris longus and flexor carpi radialis respectively of each of two patients suffering from dystrophia myotonica, showing the tendency to expansion and double end-plates. Vital staining with methylene blue.

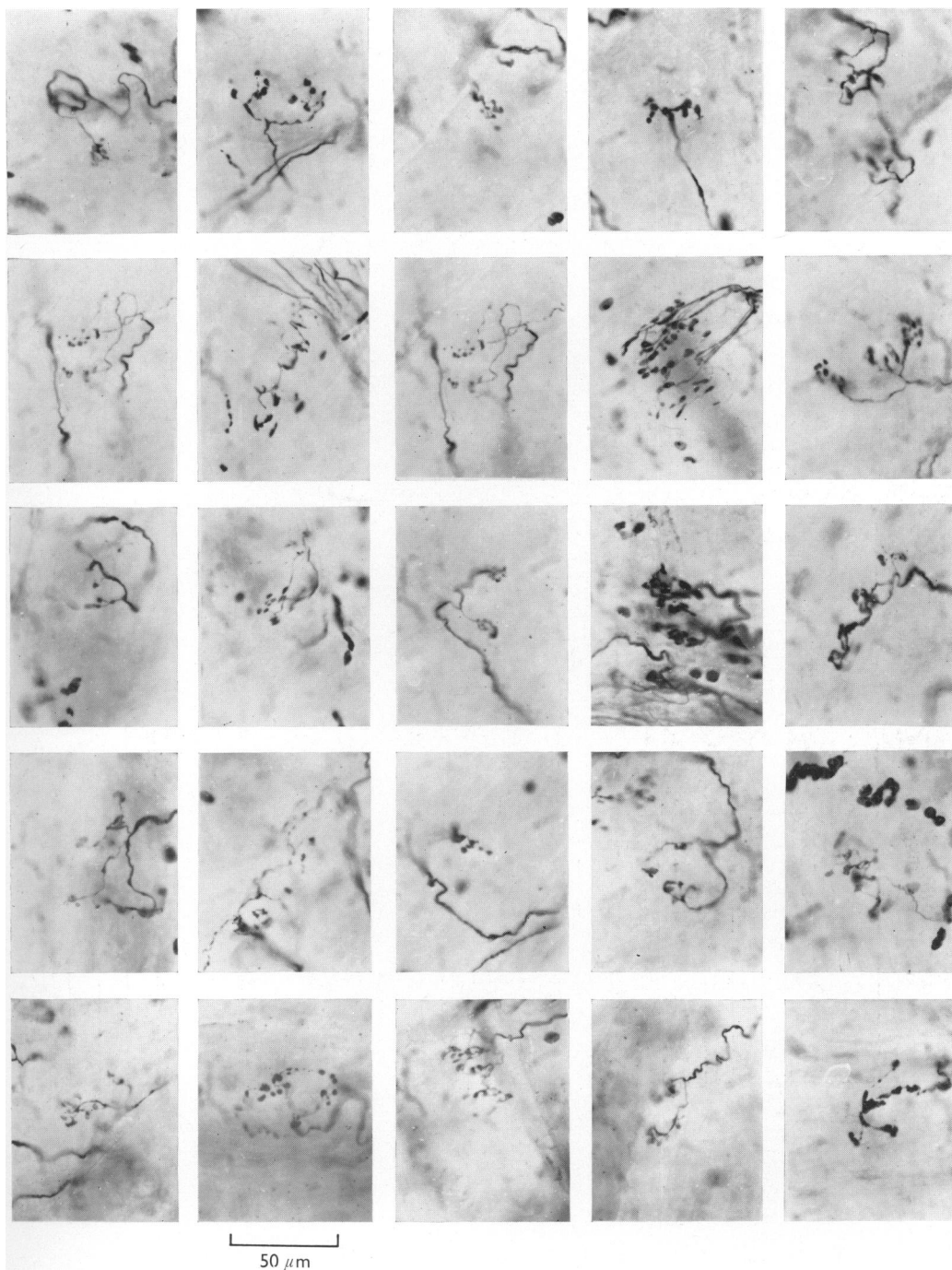


Fig. 5. For legend see fig. 4 opposite.

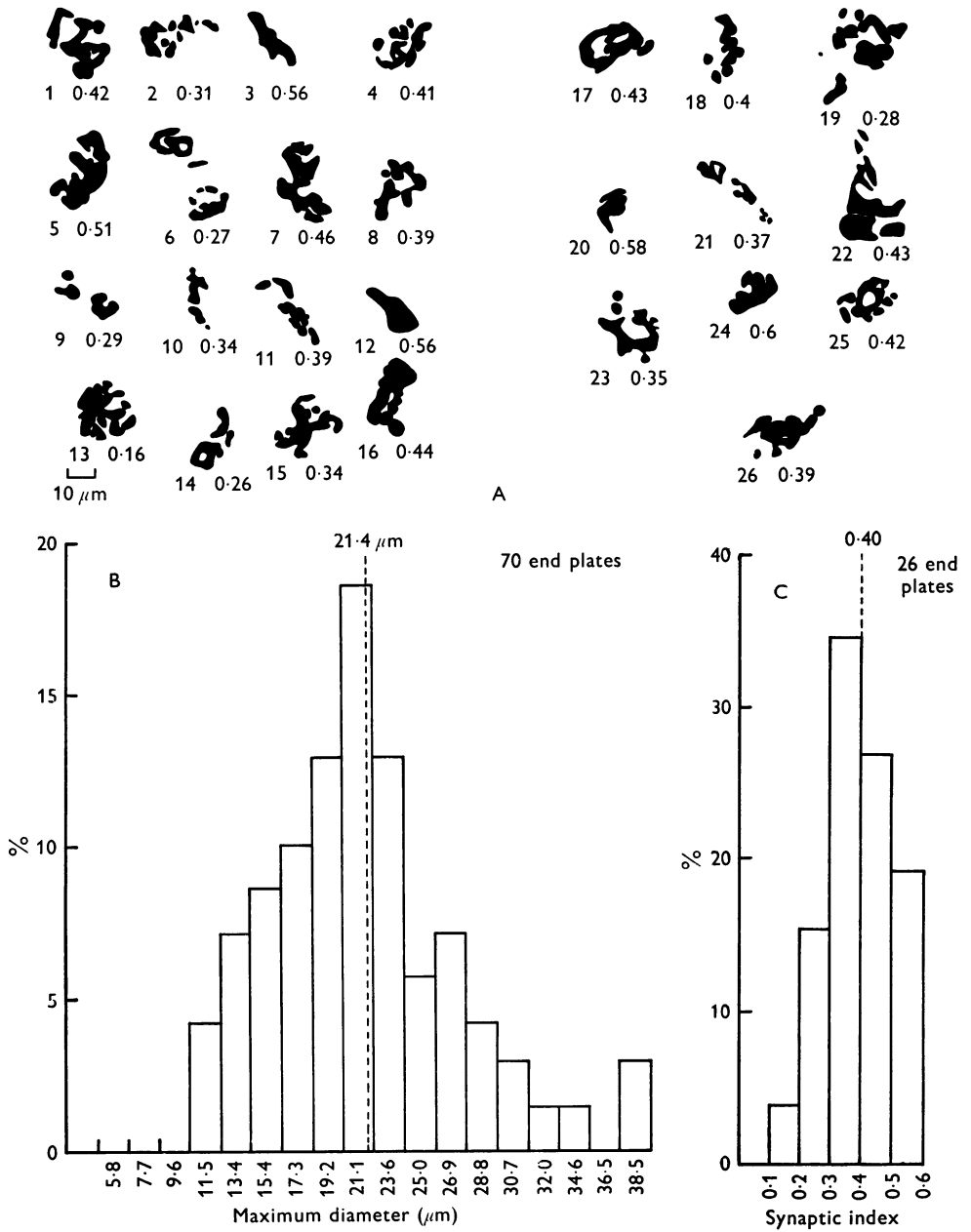


Fig. 6

Figs. 6, 7. Synaptograms and histograms showing distribution of synaptic index and maximum diameter of motor end-plates in a 'normal' case (Kn.) and a case of dystrophia myotonica (Per.). In the synaptograms the synaptic index for each end-plate is written beneath it.

expansions as compared with the more compact arrangement in the 'normal' cases. This is graphically demonstrated in the synaptograms.

Under the electron microscope the configuration of most of the end-plates was normal (Fig. 9), the terminal axonic expansions being rounded and occupying well-

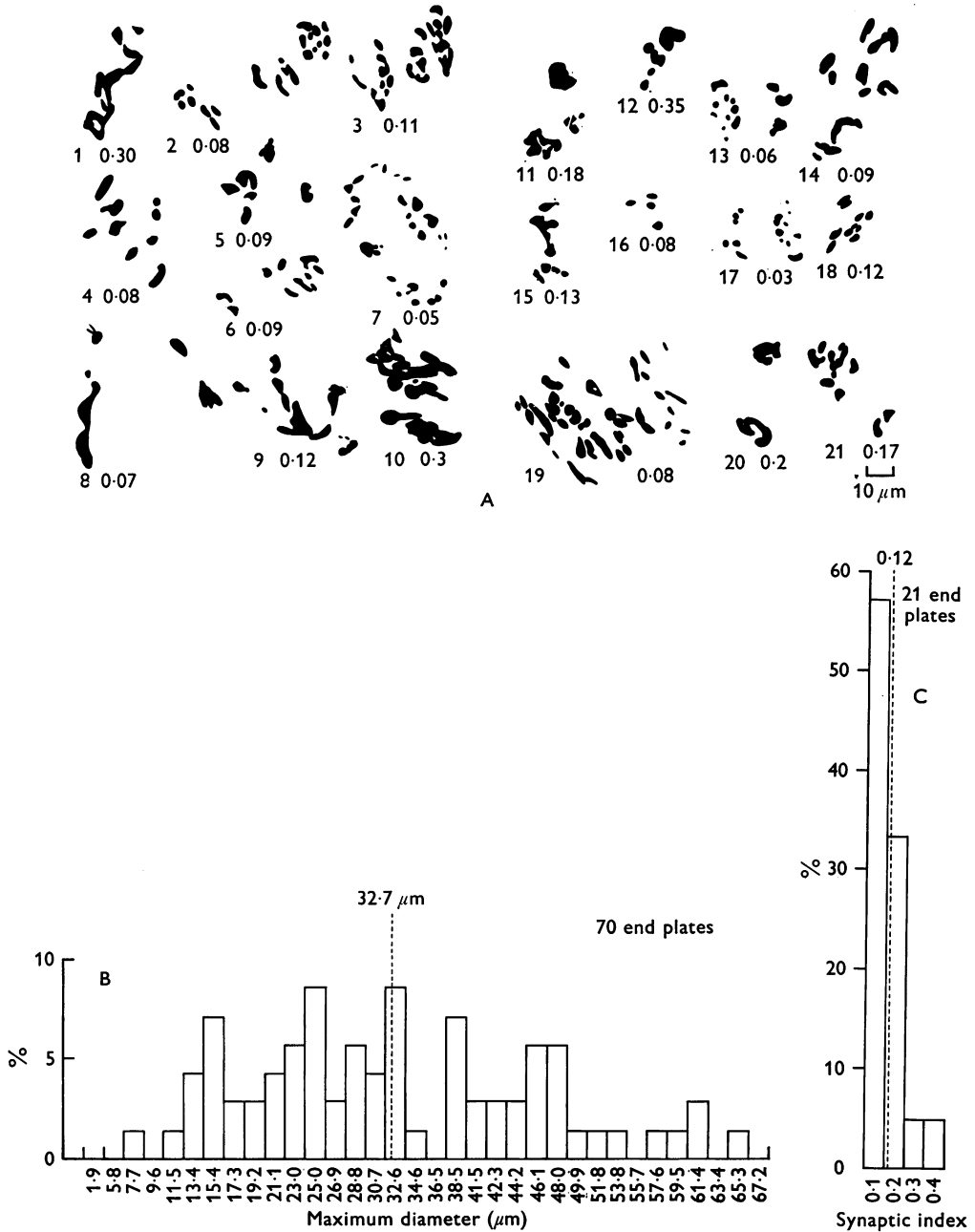
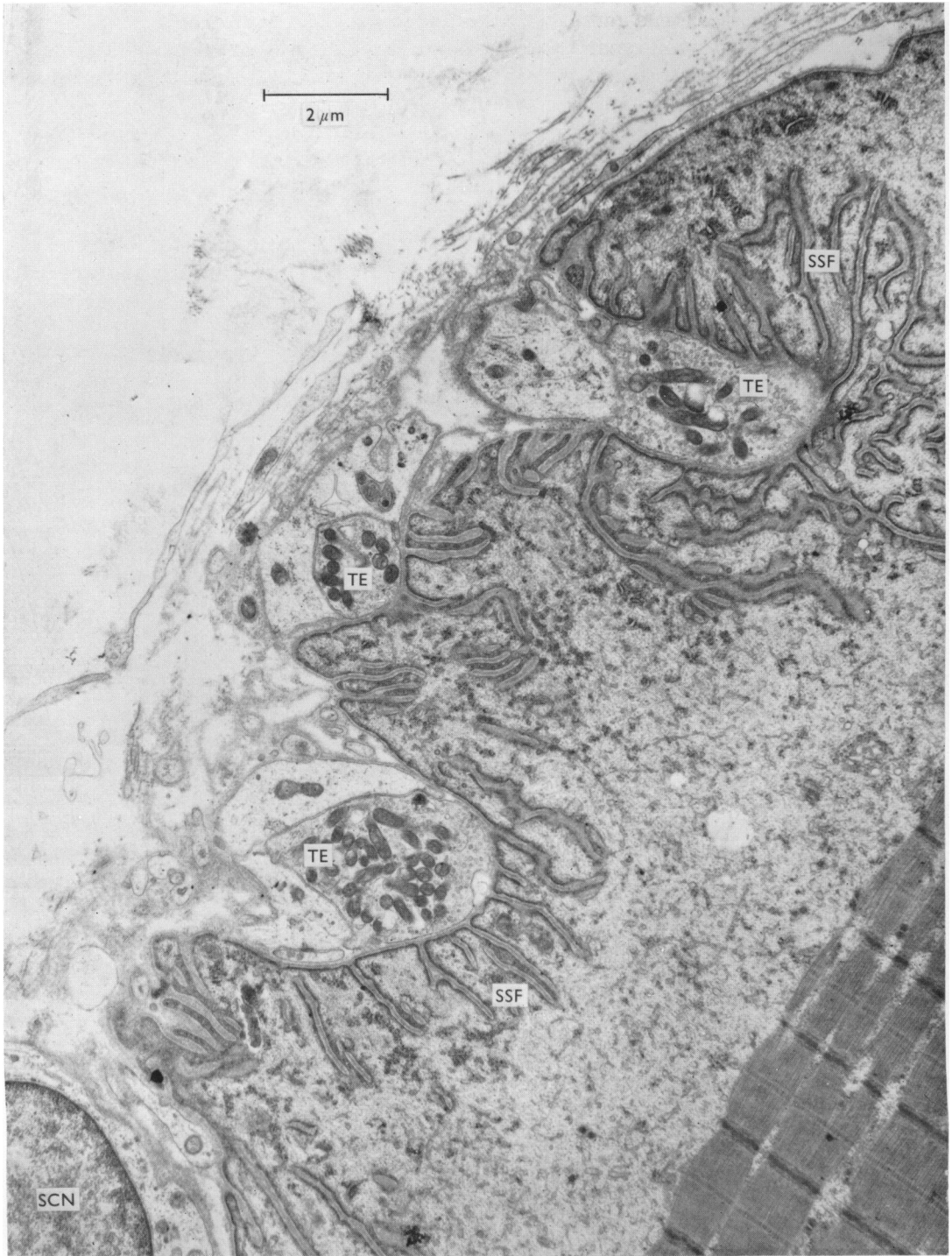


Fig. 7. For legend see fig. 6 opposite.



defined primary synaptic troughs in the sarcolemma. The secondary synaptic folds were always well developed and sometimes showed a marked hypertrophy (Fig. 10). As in the normal, the non-synaptic surface of the end-plate was usually covered by a Schwann cell or endomysial collagen. However, in this region there was sometimes a lamellated structure consisting of alternating layers of collagen fibres and a membranous material orientated at right angles to one another (Fig. 11). Occasional end-plates showed unusually large numbers of terminal axonic expansions.

In two cases the internal structure of the terminal axonic expansions was abnormal. In one of the cases there was a gradation of changes from very mild to severe. The terminal expansion illustrated in Fig. 12 contains a reduced number of synaptic vesicles. The secondary synaptic folds are short, simple and wider than normal and have an unusually dense sarcolemma. The synaptic trough is unduly flat. A few end-plates were more severely abnormal. The secondary synaptic folds in the end-plate illustrated in Fig. 13 are again reduced both in length and number. The terminal expansions are shrunken and contain very few synaptic vesicles and swollen mitochondria. The bounding membranes of these structures also appear more coarse and electron-dense than normal.

In general, synaptic vesicles were present in normal numbers and the mitochondria within the terminal axonic expansions were well preserved but were occasionally slightly swollen. Neurofilaments as normally found in axons were plentiful within the terminal expansions, sometimes appearing as long continuous threads enmeshing the mitochondria and synaptic vesicles (Fig. 14). In this illustration the mitochondria are losing their structural organization and again both mitochondrial and synaptic vesicle membranes appear thickened.

In another case large vesicles with an electron-dense central core were encountered in several otherwise normal-looking end-plates containing normal synaptic vesicles (Fig. 15).

In two cases 'end-plates' with a highly abnormal configuration were encountered. In Fig. 16 a large mass of cytoplasm, probably of Schwann-cell origin, overlies a poorly defined synaptic area on a muscle fibre. Within the Schwann-cell cytoplasm and making synaptic contact with the muscle fibre are two small processes of neural cytoplasm which contain very few synaptic vesicles. A more normal-looking Schwann cell overlies this area.

In Fig. 17 there is again a poorly defined primary synaptic trough in the surface of the muscle fibre which is occupied by three distinct and separate axonic processes

ABBREVIATIONS USED IN PLATES

AM	Axon membrane	SCN	Schwann-cell nucleus
DV	Dense vesicles	SN	Sarcolemmal nucleus
EC	Endomysial collagen	SSF	Secondary synaptic folds
GV	Granular vesicle	SV	Synaptic vesicles
M	Membrane separating Schwann cell from terminal axonic expansion	TE	Terminal expansion
MIT	Mitochondrion or mitochondria	The ruled line, except where stated, represents 1 μ m	
S	Sarcolemma		

Fig. 8. Electronmicrograph of motor end-plate from our 'normal' case Pe. Gluteraldehyde fixation, Araldite embedding.

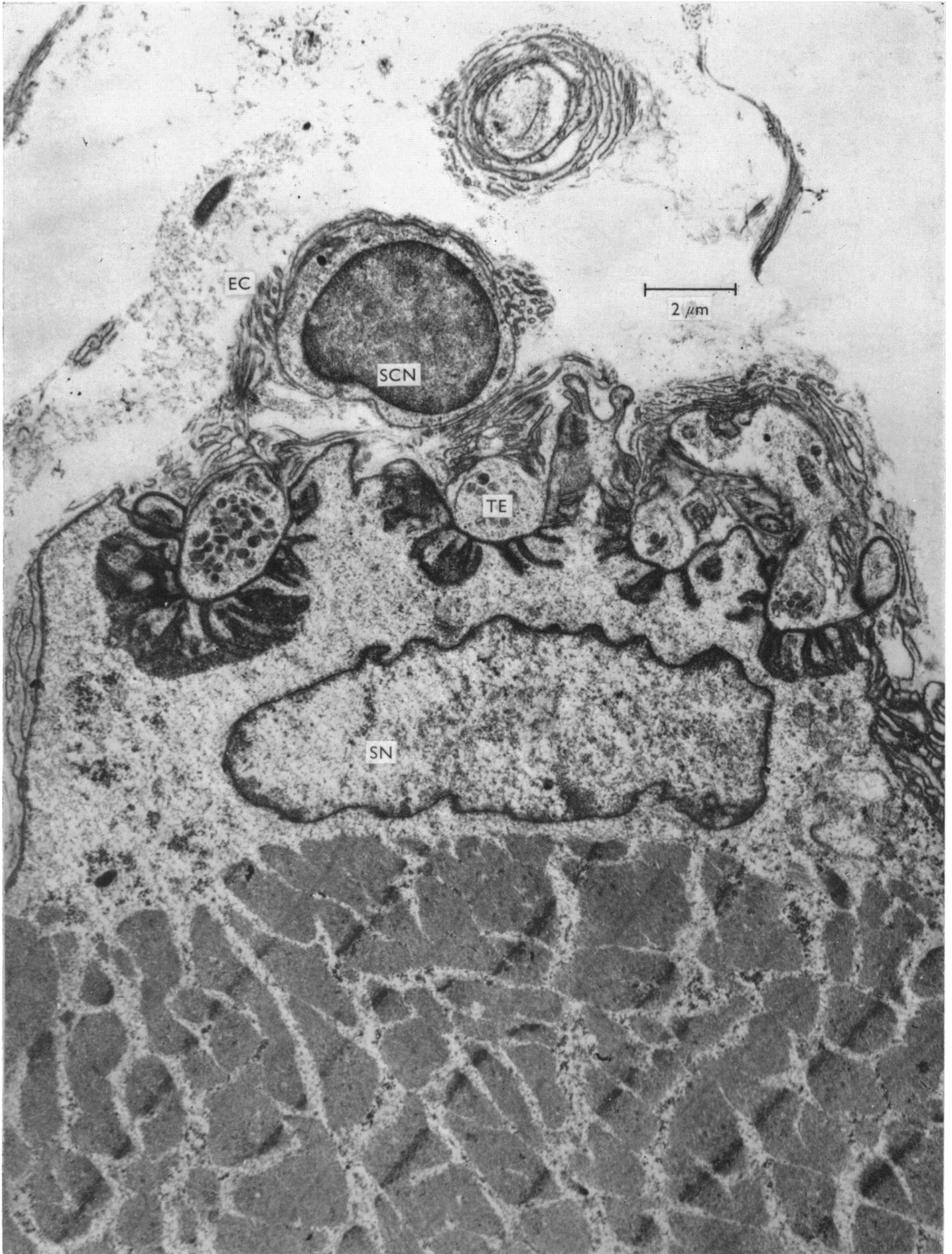


Fig. 9. End-plates from a case of dystrophia myotonica, showing normal structural organization. Small rounded terminal axonic expansions occupy well-defined primary synaptic troughs in the sarcolemma. Numerous secondary folds are also present. A Schwann cell overlies the end-plate region, the whole end-plate region being enclosed in collagen of the endomysial sheath and the membranous structures referred to in the text.

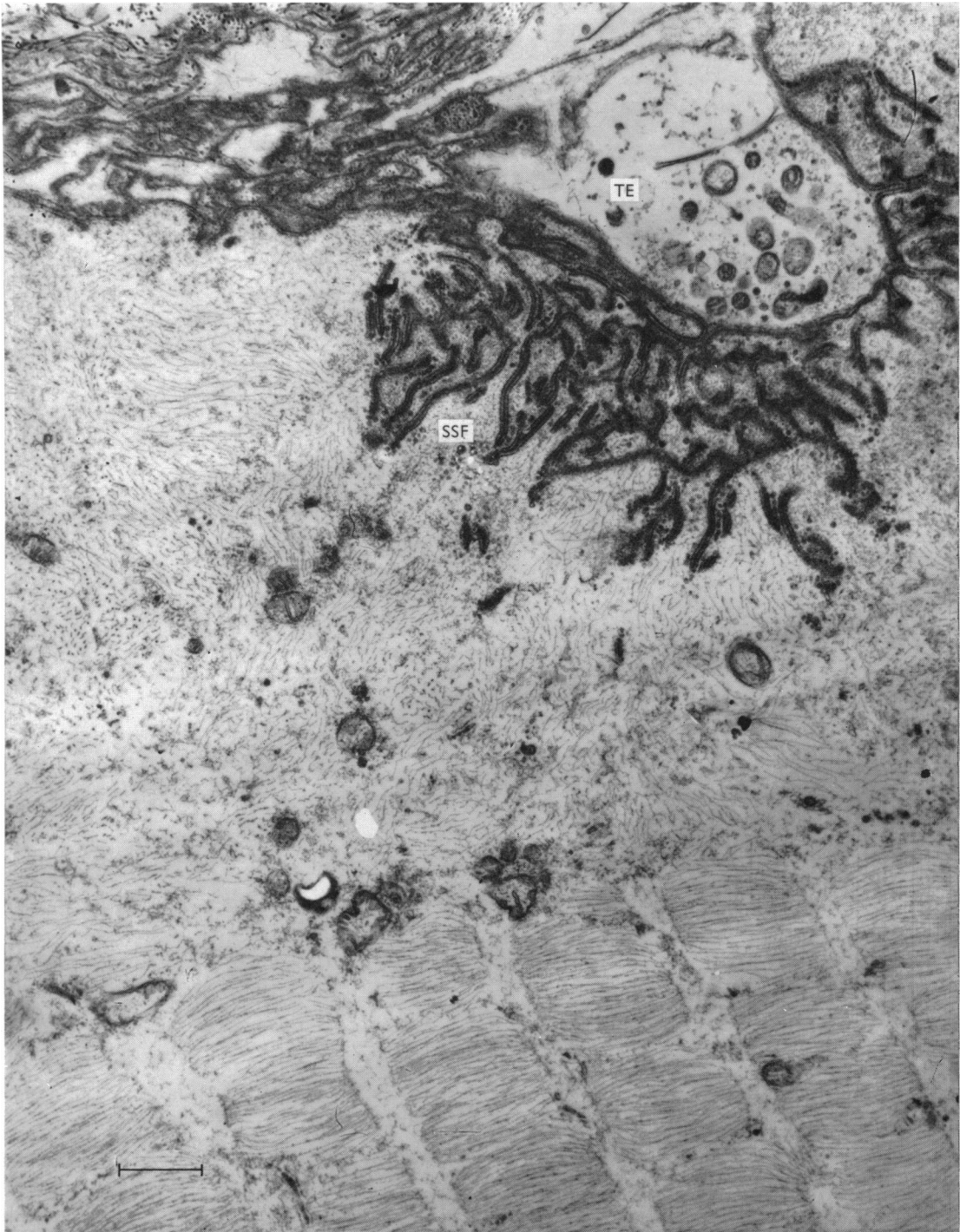

Fig. 10. Terminal axonic expansion from a case of dystrophia myotonica, showing marked hypertrophy of the secondary junctional folds. The myofibrils show total loss of I-band myofilaments and Z-line material.

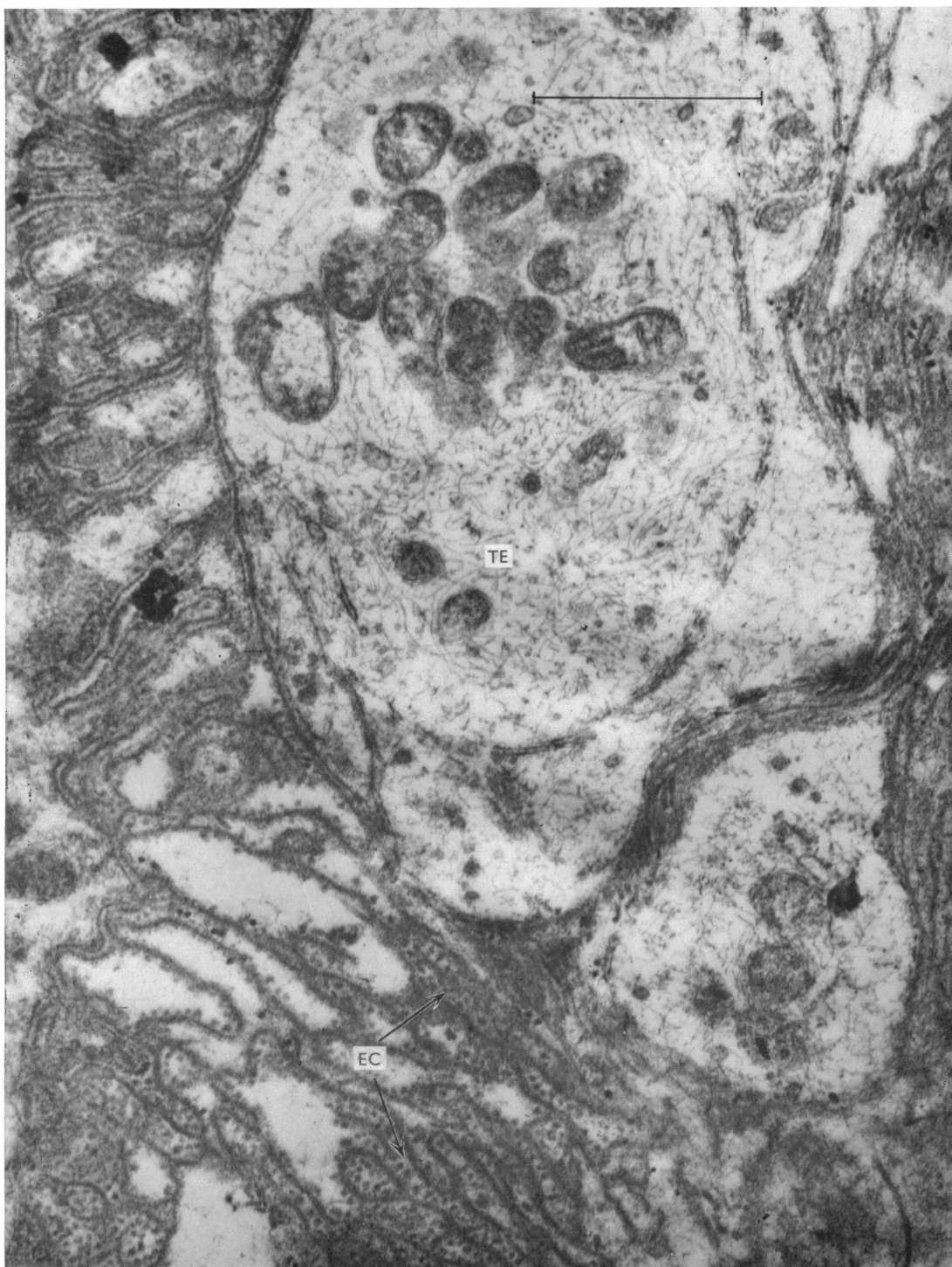


Fig. 11. Portion of motor end-plate, showing collagen of the endomysial sheath and a membranous structure orientated at right angles to the collagen.

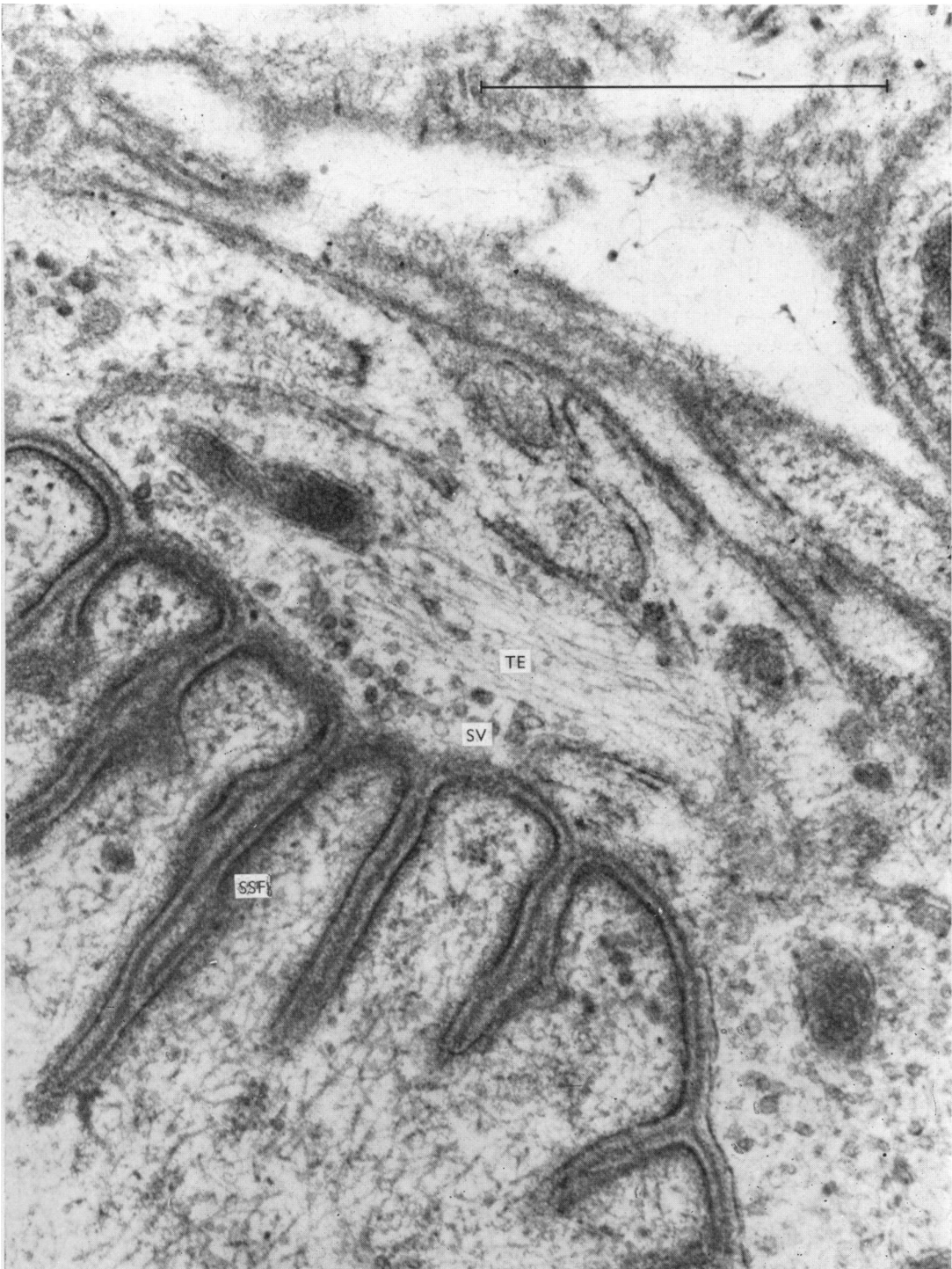


Fig. 12. Terminal axonic expansion with reduced numbers of synaptic vesicles and numerous neurofilaments. The secondary synaptic folds are reduced in length and are wider than normal.

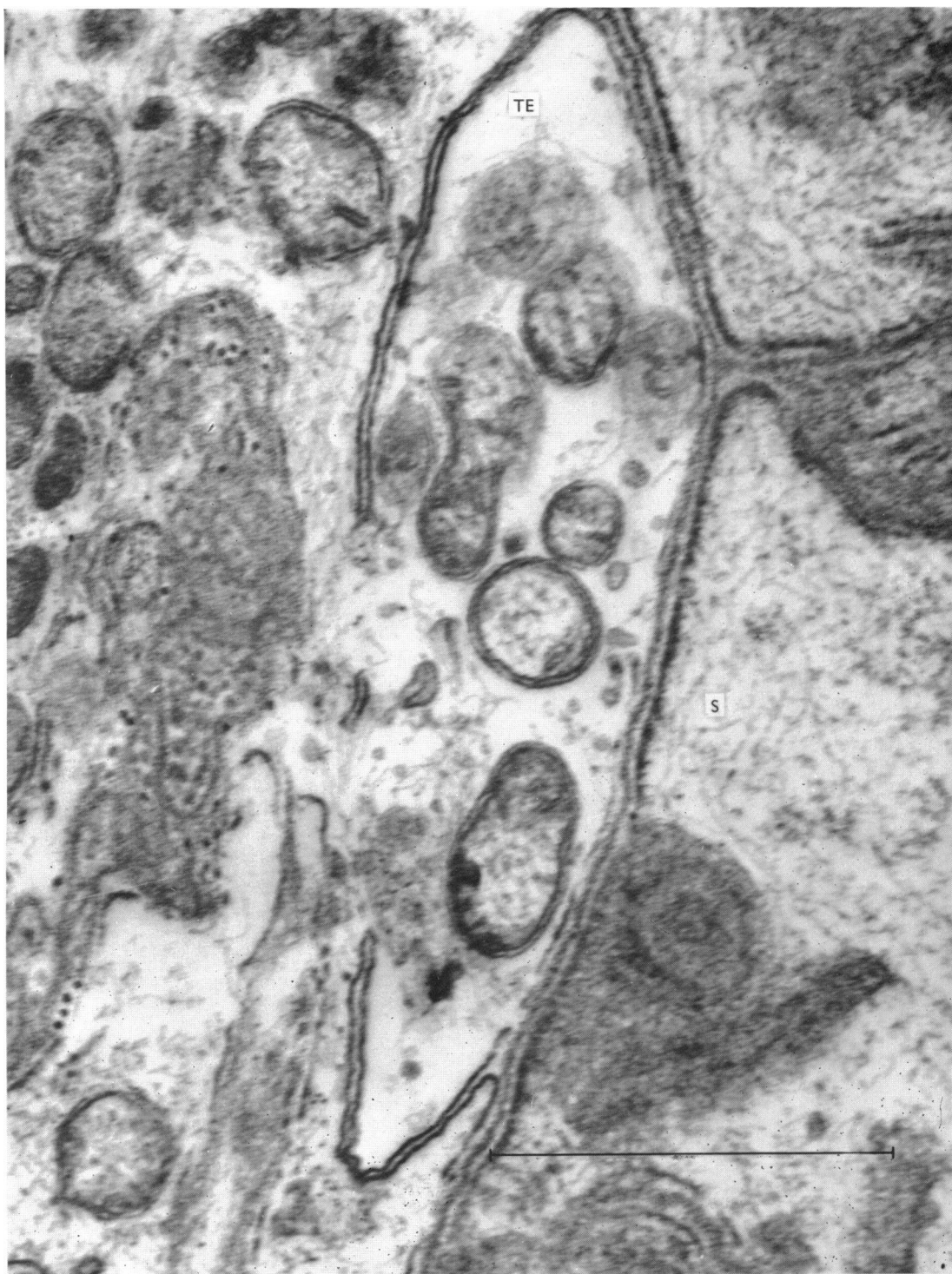


Fig. 13. Terminal expansion containing very few synaptic vesicles and swollen mitochondria. The bounding membranes of all the intracellular organelles and the terminal axonic expansion appear unusually thickened and electron-dense. The secondary synaptic folds are also shorter and wider than usual.

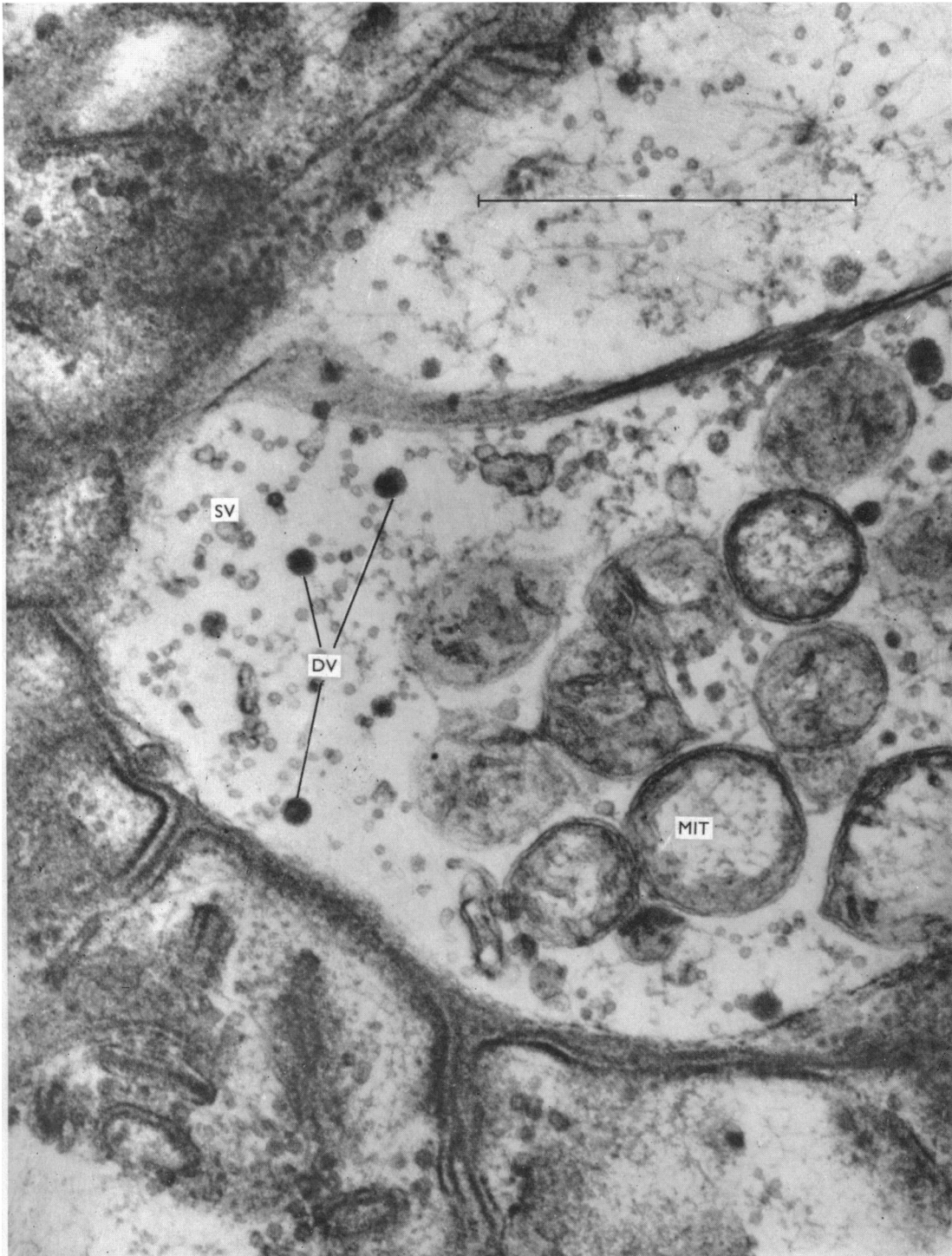


Fig. 14. Part of an abnormal terminal axonic expansion containing large electron-dense spherical particles interspersed between the synaptic vesicles. Once again the bounding membranes of all intracellular organelles appear thickened and abnormally electron-dense.

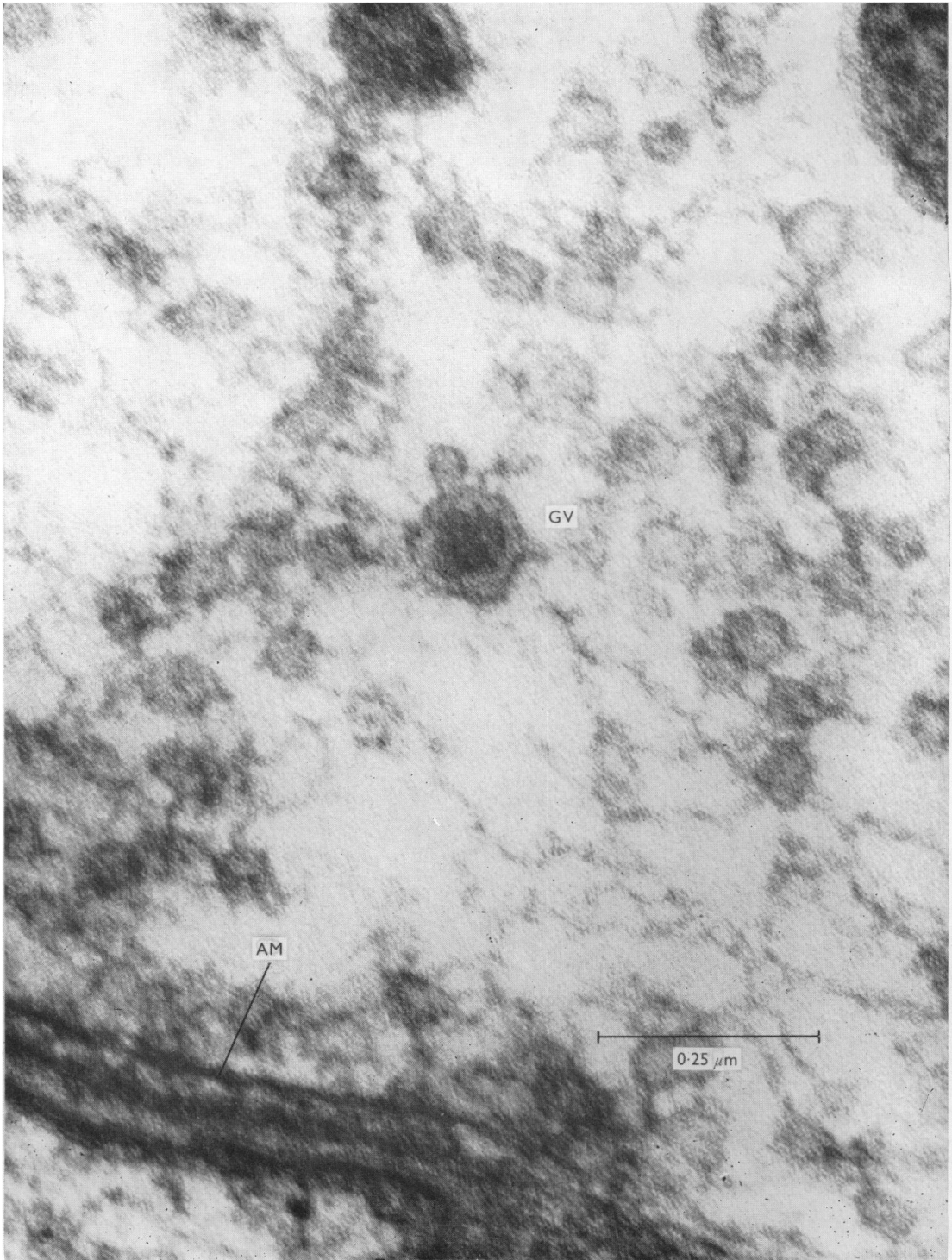


Fig. 15. Part of a terminal axonic expansion illustrating an abnormal dense-cored vesicle situated between normal-looking synaptic vesicles.

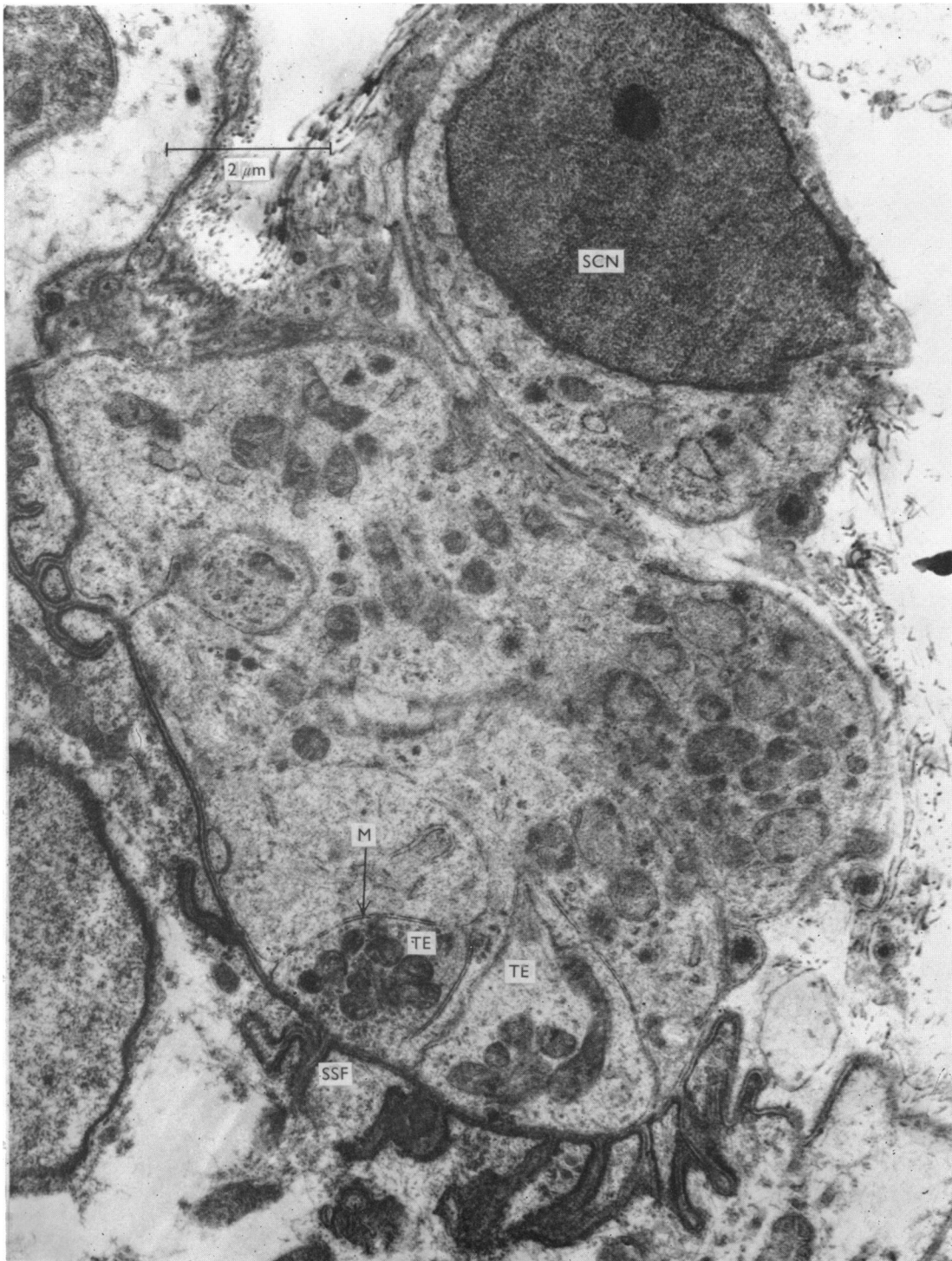


Fig. 16. Abnormal end-plate site in which a large amount of Schwann-cell cytoplasm occupies an ill-defined synaptic area on the surface of the muscle fibre. Within this Schwann-cell cytoplasm are two small axonal cytoplasmic processes which are making contact with the muscle fibre. There are very few poorly formed secondary synaptic folds located opposite these neural structures.

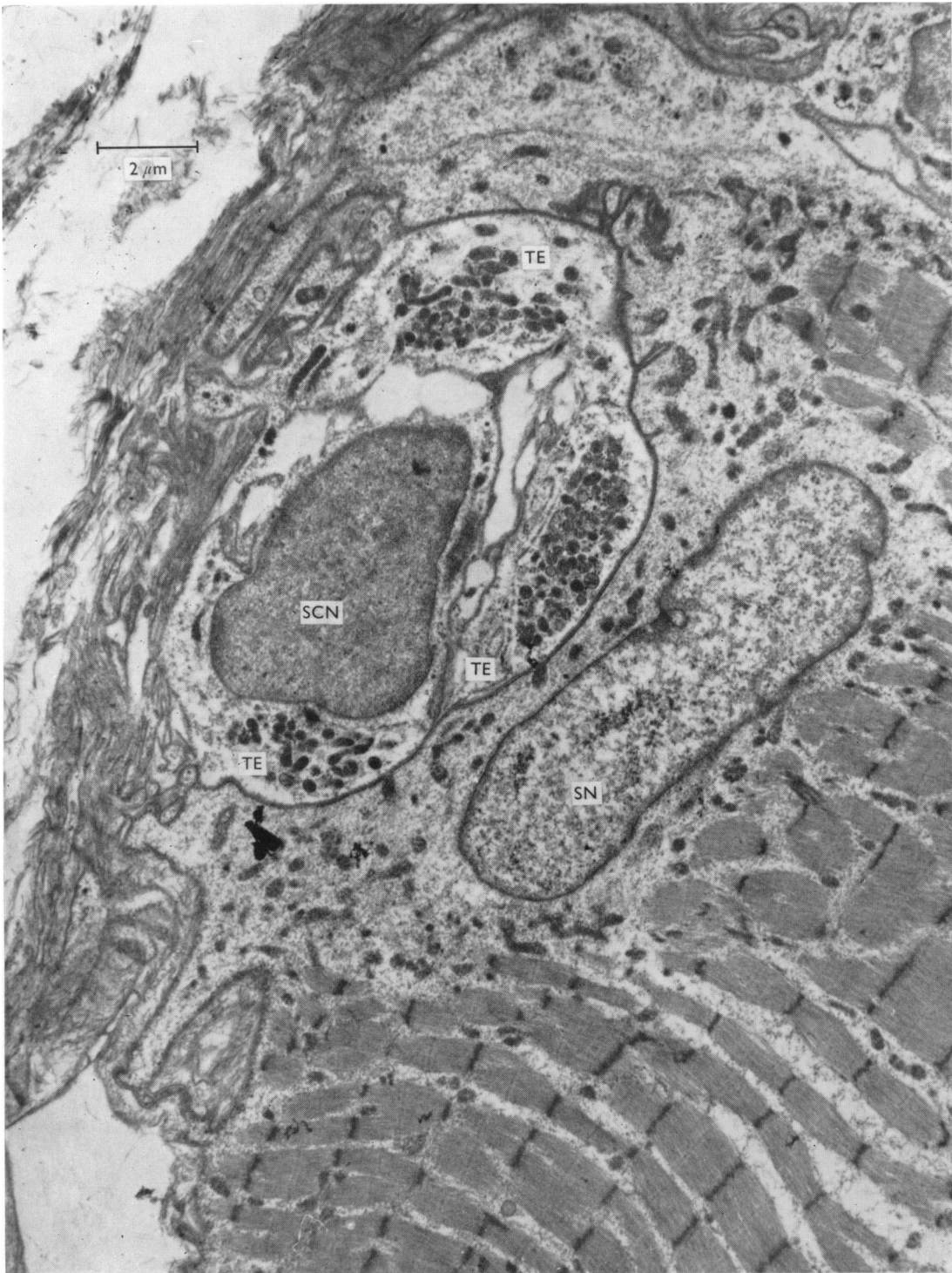


Fig. 17. Abnormal synaptic area of the surface of the muscle fibre in which three processes of neural cytoplasm are making synaptic contact with the muscle fibre. These three processes occupy different regions of the same primary synaptic trough. The centre of this synaptic zone is occupied by a Schwann cell.

which contain large numbers of small electron-dense mitochondria and synaptic vesicles. The centre of the region enclosed by the synapse is occupied by a Schwann cell. Almost all the muscle fibres in the case illustrated in Fig. 10 showed total loss of I-band myofilaments and Z-line material, although the continuity and orientation of the myofibrils was preserved.

DISCUSSION

We believe that in no disease other than dystrophia myotonica could so high a percentage of double and multiple end-plates be recorded, and certainly not in the absence of any significant rise in the *functional terminal innervation ratio*. The percentage of double and multiple end-plates is considerably in excess of that encountered in three out of four of our 'normal' cases as well as the 2.3 % reported by Coërs (1955) in a study of 721 terminal axons in various normal human muscles. Furthermore the percentage of triple and quadruple end-plates is five times as great in the dystrophia myotonica cases (34 %) as in the 'normals' (6 %). Our fourth 'normal' case did show a remarkably high percentage of multiple end-plates though even this was exceeded by six out of our eight cases of dystrophia myotonica. There was in addition in this fourth 'normal' case an elevation not only of the *absolute terminal innervation ratio* (to 1.61:1) but also of the *functional terminal innervation ratio* (to 1.25:1). The mean terminal innervation ratios for three normal deltoid muscles reported by Coërs (1955) were A.T.I.R. 1.15:1, F.T.I.R. 1.09:1, and for one flexor carpi radialis A.T.I.R. 1.19:1, F.T.I.R. 1.18:1. We have for some time suspected that there is a tendency for sprouting of the terminal axons and collateral re-innervation to take place as a result of minor constitutional disturbances or direct trauma throughout life and have pointed out that this may constitute a diagnostic hazard after the first or second decade (Woolf, 1965). This suggestion has received confirmation through the studies of Barker & Ip (1965) in the cat, rabbit and rat. It would appear that our 'normal' Pe. showed features of this latent or 'wear and tear' neuropathy, though of course he may have had another neurofibroma on the appropriate cervical spinal root, though this seems unlikely. Thus the evidence still demonstrates the consistently high incidence of multiple end-plates in dystrophia myotonica. The evidence demonstrating the large size of the end-plates in dystrophia myotonica is still more striking. It should also be noted that the mean value for the greatest diameter of the end-plates was greater in five of our cases of dystrophia myotonica than the mean of the largest diameter for 240 end-plates from the forearm muscles of twelve cases of amyotrophic lateral sclerosis, and in all but one of the dystrophia myotonica cases greater than that of 160 end-plates from nine cases of the Guillain-Barré syndrome (Woolf, Alberca-Serrano & Johnson, 1969) as well as the 392 end-plates from the four 'normal' cases reported here. Indeed, comparable figures with our three cases with the largest end-plates were only encountered in myasthenia gravis (Woolf, 1966). The figures we have given for the mean greatest diameter of vitally stained 'normal' human end-plates are the only ones available in the literature, though Coërs (1955) gave figures for the subneural apparatus. The mean number of terminal axoplasmic expansions was significantly greater in half our cases than in three out of four of our 'normals' and in all but one case greater than in the Guillain-Barré syndrome (Woolf *et al.* 1969). Thus we found the mean number of terminal

expansions in the end-plates from the cases of the Guillain-Barré syndrome was 5.54 (Woolf *et al.* 1969). The mean number of terminal axonic expansions for the end-plates from cases of amyotrophic lateral sclerosis was 7.89 (Woolf *et al.* 1969). Although this was exceeded by only three of our cases of dystrophia myotonica the number of expansions per end-plate was reduced in the latter by the tendency to form multiple end-plates. Moreover, it should be pointed out that in amyotrophic lateral sclerosis the end-plates show an increased delicacy of the filaments of the terminal arborization and shrinkage of the axoplasmic expansion which is certainly not the rule in dystrophia myotonica, in which the end-plates are often unusually well formed as though derived from a healthy and vigorous nerve cell. The high mean number of terminal axonic expansions in our fourth 'normal' case shows that caution should be exercised in evaluating this feature, but in view of the number of double end-plates in the dystrophia myotonica it would seem that the total number of axonic expansions making contact with a single muscle fibre is increased in this disease.

Coërs & Woolf (1959) suggested that the branching of subterminal nerve fibres and the end-plate changes in dystrophia myotonica were an expression of the combined effects of some substance released from the degenerating muscle fibres, together with the hypertrophy of muscle fibres which characterizes the condition. We have little to add to this observation except to suggest a chemical change in the muscle fibre surface membrane as an alternative to the release of a substance inducing axonal sprouting, since such branching is seen in any condition in which muscle fibres are denervated and it is well known that a change in the chemosensitivity of the muscle fibre surface membrane accompanies denervation.

We consider the synaptograms and estimates of the synaptic index and synaptic area particularly valuable as they give a more reliable indication of the area of synaptic contact between axon and muscle fibre as well as the area of the muscle fibre over which the end-plate is spread. Admittedly photomicrographs only give an approximate two-dimensional measurement of the areas and not all of the surface of the axonic expansion is in synaptic contact with the muscle fibre, but it is a more informative measurement than has previously been available. The findings indicate that the synaptic area is not significantly different from the normal, but because the expansions are spread over a larger 'total area' the synaptic index—which is an indication of the compactness or dispersion of the end-plate—is low. It should be pointed out that while the counts of terminal expansion and maximum diameters of end-plates relate to individual end-plates and in the case of multiple end-plates do not indicate the number of points of synaptic contact on the muscle fibre, the synaptic and total area and synaptic index estimations refer to the whole area of synaptic contact whether in the form of a single or multiple end-plate. The relatively low synaptic index in 'normal' case Pe. is again due to the large number (five) of double end-plates causing an increase in the 'total area' of the synapse, though the individual end-plates were of normal size and compactness.

While the electron-microscopic studies confirm the findings in the vitally stained preparations (elongated synaptic region and increased number of terminal axonic expansions), the principal interest centred on the interior of the expansions which we have shown in other diseases may be greatly disorganized in the absence of any

marked change in external configuration (Cooke, Johnson & Woolf, 1966). In fact the internal structure was not strikingly abnormal in the cases of dystrophia myotonica, but the large electron-dense spherical bodies (Fig. 14) and the dense-cored synaptic vesicles (Fig. 15) are of particular interest as we have not seen them in end-plates in any other condition nor in the end-plate from our 'normal' case Pe. (Fig. 8), though Coupland (1965) saw the electron-dense spherical bodies in the axonic pre-terminals of rat adrenal medulla. They may possibly be indicative of the presence of an abnormal transmitter substance. Synaptic vesicles were often reduced in number and the mitochondria were swollen. Bounding membranes, both of the terminal expansions and the synaptic vesicles, were often unduly electron-dense. It is difficult to interpret such minimal deviations from the normal but the flattening of the primary synaptic trough and shortening of the secondary synaptic troughs seen in the end-plate in Fig. 12 recall the changes described by Reger (1959), Birks, Katz & Miledi (1960) and Bauer, Blumberg & Zacks (1962) in primary neural degeneration. There is also a similarity between the terminal expansions in this end-plate and those we have encountered in cases of amyotrophic lateral sclerosis. While the changes in the myofibrils in Fig. 10 also resemble those we have reported in cases with primary neuronal degeneration (Johnson, 1968), it is probably best to interpret changes in the terminal expansions as indication of degeneration of newly formed delicate and therefore vulnerable expansions, rather than of the original expansions which have been present since or soon after birth. They certainly cannot be accepted as proof of primary neuronal degeneration, which MacDermot (1961) claimed to be present on the evidence of axonal changes in vitally stained material which we have been unable to confirm.

Although not present in every case, the tendency to the hypertrophy of secondary synaptic folds seems to be a genuine feature of dystrophia myotonica and was already noted with the light microscope in sections stained histochemically for cholinesterase by Coërs & Woolf (1959, fig. 226). Its significance is obscure.

The appearances illustrated in Figs. 16 and 17 are difficult to interpret. In Fig. 16 Schwann-cell cytoplasm occupies most of the synaptic area. The neural processes are very small and partially surrounded by the Schwann cell, from which they are separated by a well-defined membrane (M). The presynaptic cytoplasm contains numerous mitochondria. It is interesting to note that the majority of the secondary synaptic folds are formed directly opposite these neural processes. In Fig. 17 as in many pathological human end-plates the demarcation between Schwann cell and terminal axonic expansion is difficult to identify, but the structures containing the mitochondria seem to resemble terminal expansion more closely. In this figure the Schwann cell occupies a position more similar to that found in architecturally normal end-plates than that illustrated in Fig. 16.

SUMMARY

1. In eight out of twenty-six cases of dystrophia myotonica studied by vital staining of the intramuscular innervation, squash preparations were available. Statistical analysis revealed an increase in the number of double or multiple end-plates on single muscle fibres, a marked increase in the mean maximum diameter

of the end-plates and a slight increase in the number of terminal axonic expansions in comparison with biopsies from four muscles thought to be normal.

2. In two cases of dystrophia myotonica the areas of synaptic contact of axon and muscle fibre were estimated by measuring the synaptic and total areas and the synaptic indices of the end-plates. The synaptic area was not abnormal but the low synaptic indices indicated the dispersion of the axonic expansions over a larger area than normal.

3. Electron-microscopic studies on motor end-plates from seven cases of dystrophia myotonica showed the internal structure of the terminal axonic expansions to be basically normal but there were minor changes in one case, the most interesting of which was the presence of electron-dense spherical bodies of the same order of size as synaptic vesicles and dense-cored vesicles. Some terminal expansions showed changes suggesting degeneration, probably secondary to the muscle fibre changes. Hypertrophy of the secondary synaptic folds was often prominent.

Our thanks are due to Mr W. Edwards for allowing us to use the illustration of the ultrastructure of the normal motor end-plate (Fig. 8).

REFERENCES

- BARKER, D. & IP, M. C. (1965). Sprouting and degeneration of mammalian motor axons in normal and de-afferented skeletal muscle, *Proc. R. Soc. B* **163**, 538–554.
- BAUER, W. C., BLUMBERG, J. M. & ZACKS, S. I. (1962). Short and long term ultrastructure changes in denervated mouse motor end-plates. *Proc. IVth Int. Congr. Neuropath.*, Munich, 1962, pp. 16–18. Stuttgart: Georg Thieme Verlag.
- BIRKS, R. I., KATZ, B. & MILEDI, R. (1960). Physiological and structural changes at the amphibian myoneural junction in the course of nerve degeneration, *J. Physiol., Lond.* **150**, 145–168.
- COËRS, C. (1952). La dystrophie myotonique. *Acta clin. belg.* **7**, 407–444.
- COËRS, C. (1955). Les variations structurelles normales et pathologiques de la jonction neuromusculaire. *Acta neurol. belg.* **55**, 741–866.
- COËRS, C. & WOOLF, A. L. (1959). *The Innervation of Muscle*, p. 107. Oxford: Blackwell.
- COOKE, W. T., JOHNSON, A. G. & WOOLF, A. L. (1966). Vital staining and electron microscopy of the intramuscular nerve endings in the neuropathy of adult coeliac disease. *Brain* **89**, 663–682.
- COUPLAND, R. E. (1965). Electron microscopic observations on the structure of the rat adrenal medulla. II. Normal innervation, *J. Anat.* **99**, 255–272.
- GLAUERT, A. M. & GLAUERT, R. H. (1958). Araldite as an embedding medium for electron microscopy. *J. biophys. biochem. Cytol.* **4**, 191–194.
- JOHNSON, A. G. (1969). Alterations of the Z-lines and I-band myofilaments in human skeletal muscle. *Acta neuropath.* **12**, 218–226.
- MACDERMOT, D. (1961). The histology of the neuromuscular junction in dystrophia myotonica. *Brain* **84**, 75–84.
- REGER, J. F. (1959). Studies of the fine structure of normal and denervated neuromuscular junctions from mouse gastrocnemius. *J. Ultrastruct. Res.* **2**, 269–282.
- WOOLF, A. L. (1962). *Modern Trends in Neurology* (ed. D. Williams), p. 11. London: Butterworth.
- WOOLF, A. L. (1963). The theoretical basis of electromyography. *Ann. phys. Med.* **6**, 189–209 & 241–266.
- WOOLF, A. L. (1965). The pathology of the intramuscular nerve endings. *Proc. Vth Int. Congr. Neuropathology*, Zürich, September 1965, pp. 641–647.
- WOOLF, A. L. (1966). Morphology of the myasthenic neuromuscular junction. *Ann. N.Y. Acad. Sci.* **135**, 35–36.
- WOOLF, A. L., ALBERCA-SERRANO, R. & JOHNSON, A. G. (1969). The intramuscular nerve endings and muscle fibres in amyotrophic lateral sclerosis—a biopsy study. In *Motor Neuron Diseases: Research on Amyotrophic Lateral Sclerosis and Related Disorders* (Eds. F. H. Norris & L. T. Kurland). pp. 166–174. New York and London: Grune & Stratton.