

A morphological study of the development of the mouse choroid plexus

R. R. STURROCK

Department of Anatomy, The University of Dundee, Scotland

(Accepted 13 December 1978)

INTRODUCTION

In the developing brain the majority of cell divisions occur adjacent to the ventricles in the ependymal and subependymal layers (Sauer, 1935, 1936; Berry, 1974; Smart, 1973, 1976), with the nuclei of ependymal cells moving to the ventricular surface before undergoing mitosis (Sauer, 1936; Smart, 1973; Seymour & Berry, 1975). There is an extensive capillary network within the ependymal layer very early in development in the mouse brain (Sturrock, unpublished) but if, as Kappers (1958) has suggested, cerebrospinal fluid has a nutritive function in the embryo it would seem advantageous to ependymal and subependymal development for cerebrospinal fluid to be secreted at an early stage. In the adult brain, as is well known, most of the cerebrospinal fluid is produced by the choroid plexus. Development of the choroid plexus has been studied with the light microscope by Goldmann (1913), Weed (1917) and Kappers (1958), with the transmission electron microscope by Tennyson & Pappas (1968) and Davis, Lloyd & Milhorat (1973), and with the scanning electron microscope by Chamberlain (1973). The present study set out to correlate the appearances of the developing lateral ventricular choroid plexus in semithin light microscopic sections and in the transmission and scanning electron microscopes. Semithin sections were included in the study as they enable relatively large areas to be scanned rapidly while giving much better detail than conventional paraffin sections. Furthermore, as semithin sections are being increasingly used in both normal and pathological histology, it seemed that a semithin study of the development of the normal choroid plexus would be of value as a basis for future studies of pathological changes in the plexus.

The mouse was used because the choroid plexus in this species does not appear to have been studied in any detail but the timing of alterations in the patterns of cell division in the ependymal and subependymal layers are known (Smart, 1976). Autoradiographic studies of the time sequence of cortical (Smart & Smart, 1977 and unpublished) and neostriatal development (Sidman & Angevine, 1962; Angevine & McConnell, 1974; Smart & Sturrock, 1979) have also been carried out, thus allowing correlation of choroid plexus development with that of adjacent areas of the fore-brain.

MATERIALS AND METHODS

Mouse embryos aged 11, 12, 13, 14, 15, 16, 17 and 18 days postconception, newborn mice, and mice aged 5, 8, 15, 25 and 90 days postnatum were used in the present study. The embryonic mice will be identified by the prefix E (e.g. E11 = 11 days postconception), and postnatal mice will be identified by the prefix P (e.g. P0 = birth, P5 = 5 days postnatum, etc.).

Pregnant mice were anaesthetised with Nembutal and the embryos were removed by Caesarean section and killed by perfusion-fixation with a solution of 2% glutaraldehyde and 2% paraformaldehyde in a 0.05 M cacodylate buffer as described previously (Sturrock, 1978). The postnatal mice were anaesthetised with an intraperitoneal injection of Nembutal, the vascular system was flushed out with physiological saline at 37 °C, and the mice were killed by perfusion-fixation with the same mixed aldehyde solution as described above.

After perfusion was deemed to be complete the embryos were decapitated and the heads placed in fresh fixative for 4 hours at 4 °C. The brains were then removed from the skulls and placed overnight in fixative at 4 °C. At the end of this time the brains were bisected in the coronal plane at the level of the optic chiasm and the caudal segments were rinsed in 0.1 M cacodylate buffer for 1 hour, post-fixed in 1% buffered osmium tetroxide for 2 hours, rinsed in distilled water and dehydrated in graded alcohols. From absolute alcohol, half of the brains from each age were placed in epoxy propane, followed by a 50:50 solution of Spurr's resin and epoxy propane and finally flat-embedded in Spurr's resin: the other half of the brains at each age were taken through a series of mixtures of absolute alcohol and Freon 113 until finally they were in a 100% solution of Freon 113. These brains were critical point dried using Freon 13, mounted on stubs, gold coated and examined in a Cambridge S2 Stereoscan scanning electron microscope.

One μm semithin sections were prepared from the brains embedded in Spurr's resin and stained with 1% toluidine blue. When the choroid plexus was identified the blocks were trimmed and ultrathin sections, stained with uranyl acetate and lead citrate, were examined in an AEI 801 transmission electron microscope.

The postnatal brains were prepared in a similar fashion to the embryonic brains except that, instead of half brains, coronal sections 1–2 mm thick were used.

From E14 onwards it became apparent that two types of choroid plexus epithelial cells were present, viz a light and a dark type. Complete coronal semithin sections were examined, and all choroid plexus elements containing a nucleus were counted. The numbers of light and dark cells were recorded. Over 100 cells were counted at each age, and the percentage of each type was estimated. As there was no apparent difference in size between the cells, no correction factor was applied.

OBSERVATIONS

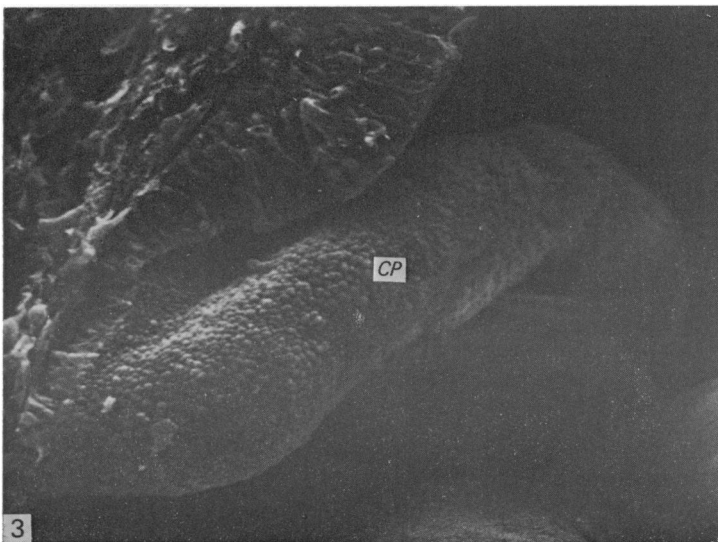
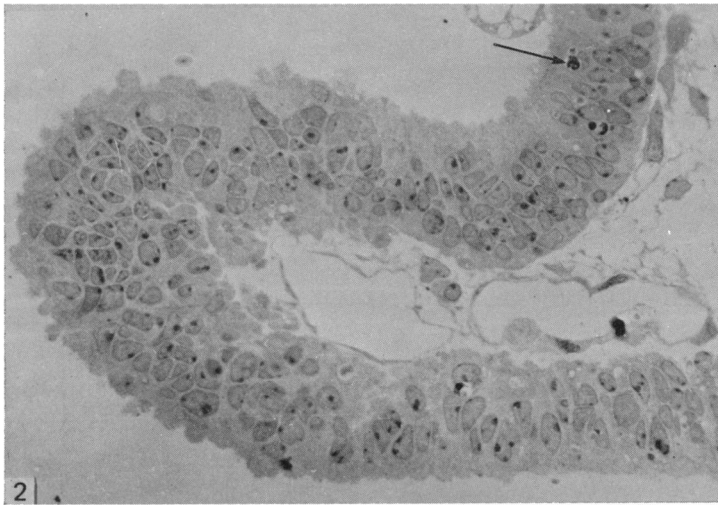
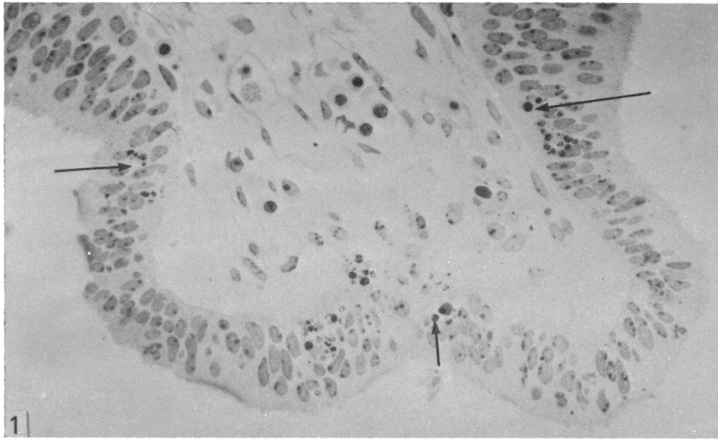
Semithin sections

The presumptive choroid plexus of the lateral ventricle can be recognised at E11 as a bilateral ridge in the roof of the interventricular foramen (Fig. 1). As noted previously (Sturrock, 1978), the sites of folding are marked by what appear to be pyknotic nuclei. A few of these pyknotic cells are still evident at E12 (Fig. 2). By E12 the choroid plexus is a well defined ridge (Figs. 2, 3). There is a rapid increase in size and folding of the ridge from E12 to E13 (Figs. 2, 4). At both E11 and E12

Fig. 1. This shows the choroid plexus anlage at E11. Note the clusters of small dark masses at the sites of folding (arrows). 1 μm , toluidine blue. $\times 300$.

Fig. 2. At E12 the choroid plexus is a well defined ridge. The epithelium remains pseudostratified columnar. The intrachoroidal space is well supplied with capillaries. Dark masses are still evident at the site of folding (arrow). 1 μm , toluidine blue. $\times 500$.

Fig. 3. This shows the appearance of the choroid plexus (CP) at E12. SEM. $\times 300$.



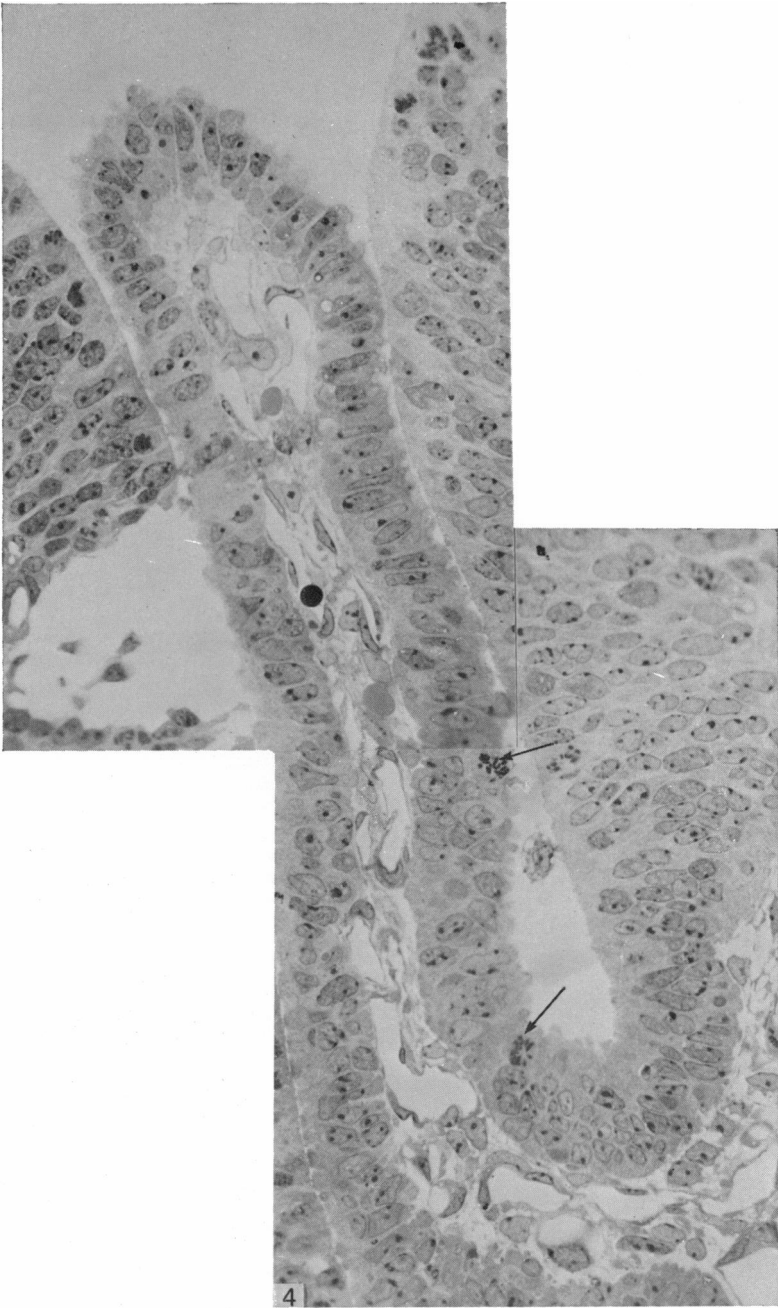


Fig. 4. This shows the choroid plexus at E13. It has increased rapidly in size since E12. Although close to the root of the plexus the epithelium remains pseudostratified, more distally it changes to simple columnar. The intrachoroidal space contains numerous capillaries. Note the mitotic figures (arrows). $1\ \mu\text{m}$, toluidine blue. $\times 500$.

(Figs. 1, 2) the choroidal epithelium is pseudostratified, but by E13 a large part of the epithelium has changed to simple columnar (Fig. 4). The part nearest the root remains pseudostratified with pale staining cells containing oval or irregular nuclei (Fig. 7), but more distally the epithelium changes to simple columnar with a brush border (Fig. 8) and the cells appear to stain slightly darker. A few cells have metachromatically staining clumps in the cytoplasm on the basal side of the nucleus (Fig. 8). A few mitotic figures are to be found, mainly near the root (Fig. 4). The vascularization of the choroid plexus appears to keep up with its rapid growth (cf. Figs. 2 and 4). At E14 and E15 the choroid plexus becomes much more extensive and tortuously folded (Figs. 5, 6).

At E14 and E15 there is a marked change in the character of the choroid epithelium. Both dark and light cells are present (Fig. 9), and a large number of cells have metachromatically staining cytoplasmic inclusions at the basal pole (Figs. 9, 10). As well as a brush border, choroidal cells with clumps of spiky cilia are present (Fig. 9). The choroidal epithelium varies from simple low columnar to cuboidal. There is a gradual change from E15 until the adult appearance is attained. In the adult (Fig. 11) the nuclear membrane is more densely stained, and the cytoplasm tends to stain darker than in younger animals. Small dark bodies can be seen scattered throughout the cytoplasm; these are probably mitochondria. The metachromatically staining inclusions seen at E14 and E15 are uncommon after birth and are absent after P5.

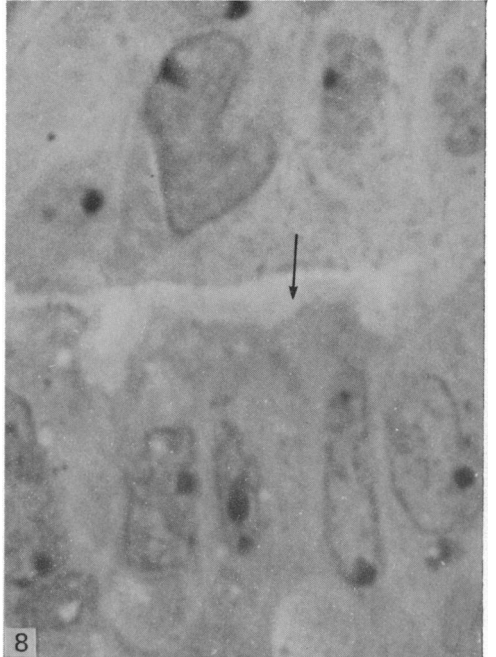
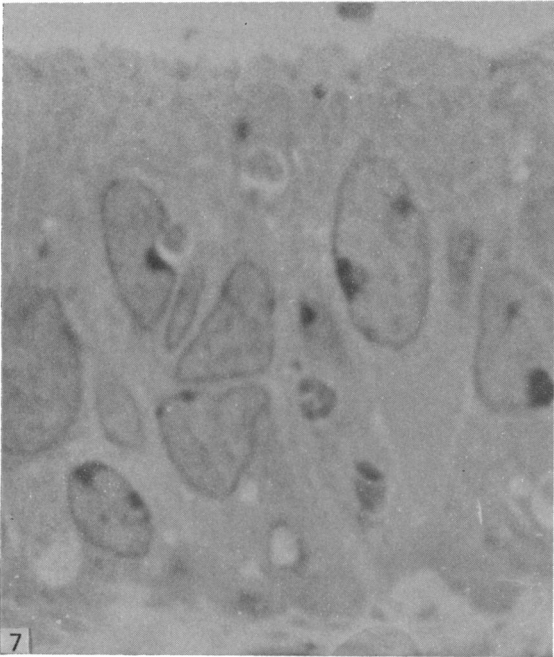
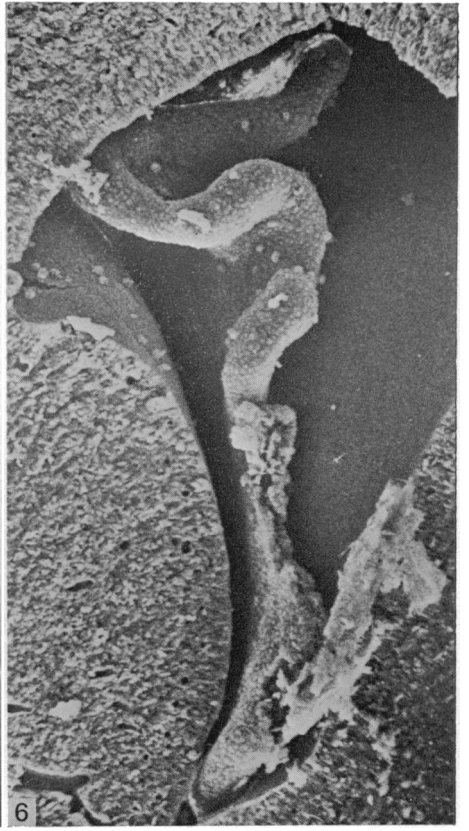
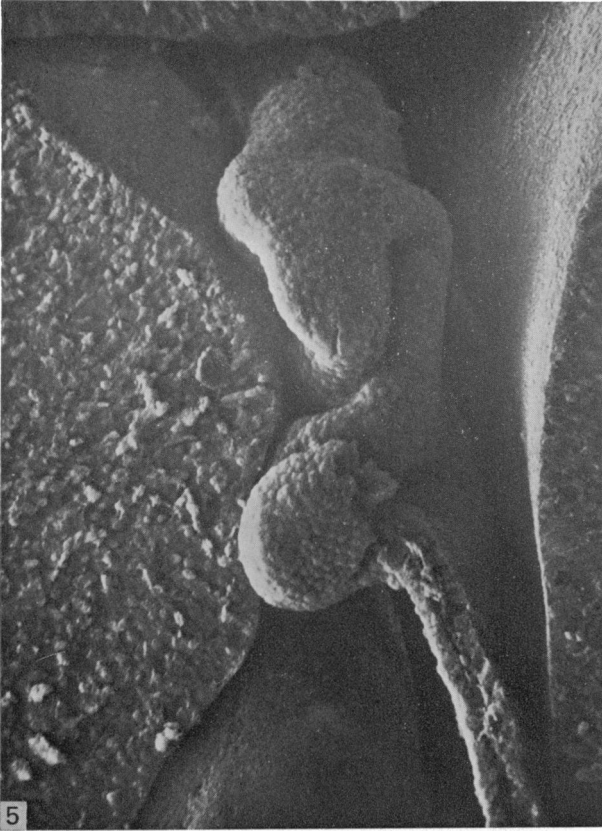
Dark cells are not seen in the developing choroid plexus from E11 to E13, and first appear at E14. The percentage of dark cells seems to be constant from the time of their appearance at E14 up to P90. The mean percentage of dark cells at all ages studied is 11.7% with a standard deviation of $\pm 1.2\%$ (Table 1).

Electron microscopy

As early as E11 microvilli can be seen on the ventricular surface of a few cells of the presumptive choroid plexus (Figs. 12, 13). Choroid plexus cells at E11 vary in cytoplasmic density and contain a Golgi complex, mitochondria and numerous short strands of rough endoplasmic reticulum (Figs. 12, 14). An occasional cilium is present (Fig. 12). The surface specialisations are more obvious in the TEM (Figs. 12, 14) than in the SEM (Fig. 13). In the TEM the dark masses resembling pyknotic nuclei (Fig. 1) can be seen to be lying within the cytoplasm of choroidal epithelial cells (Fig. 15).

By E12 (Fig. 16) the number of microvilli and cilia has increased and by E13 the microvilli appear much broader and glycogen is present in (Fig. 17) the choroid plexus cells. The number of microvilli continues to increase, but at E14 and E15 the outline of individual cells can still be seen in the SEM, although these are less obvious than at E11 (Fig. 13) and E12 (Fig. 16).

At E15 the light cells, which are in the majority, have a very pale cytoplasm with bulbous microvilli (Fig. 18). Their cytoplasm contains numerous mitochondria (Figs. 18, 19) and strands of rough endoplasmic reticulum filled with moderately darkly staining amorphous material (Figs. 18, 19). A Golgi apparatus is usually present and glycogen is scattered throughout the cytoplasm. In many cells (Fig. 19) the glycogen is aggregated also in large masses on the basal side of the nucleus: this corresponds with the location of the metachromatic masses in the semithin sections. Close to the nuclear membrane the cisternae of rough endoplasmic reticulum appear dilated and labyrinthine, separating off small circular islands of cytoplasm (Figs. 18, 19). The other unusual feature occasionally present in choroidal epithelial cells from E15



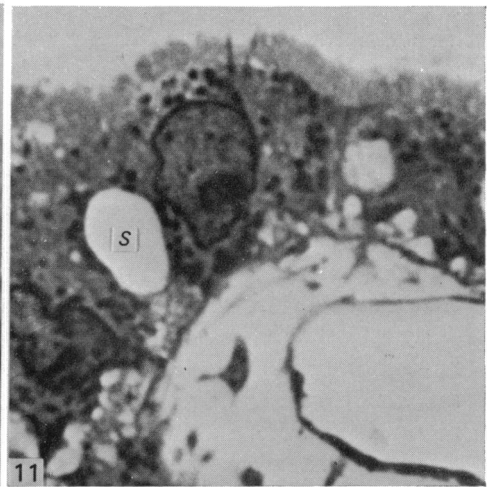
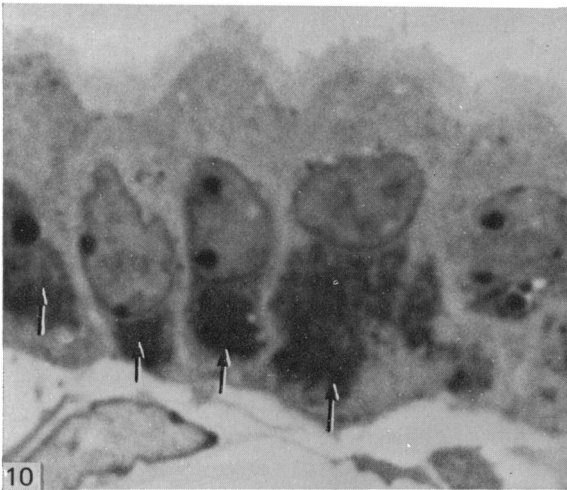
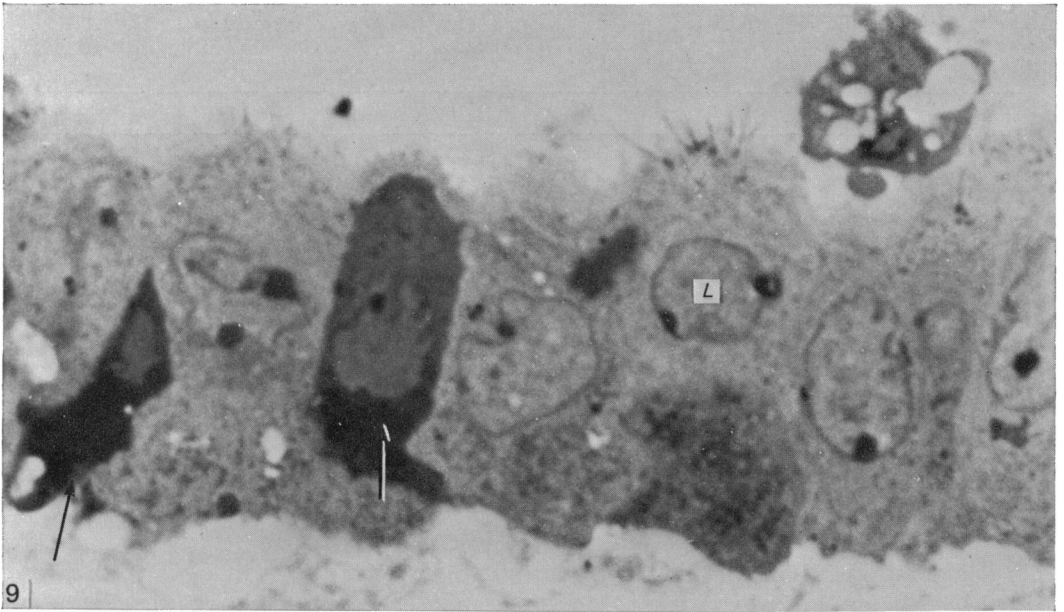


Fig. 9. This shows a variety of cell types in the E15 choroid plexus. Dark cells (arrows) are present, and one of the light cells (*L*) has a group of spiky cilia on the ventricular surface. A brush border is evident. Semithin, toluidine blue. $\times 2400$.

Fig. 10. Note the large, dark, metachromatically staining masses (arrows) on the basal side of these cells in an E15 choroid plexus. Semithin, toluidine blue. $\times 2400$.

Fig. 11. This shows the typical cuboidal choroid plexus epithelium in the adult mouse. There is a well defined brush border. The small dark intracytoplasmic bodies are mitochondria. The space between the choroid epithelial cells (*S*) is probably a fixation artefact. Semithin, toluidine blue. $\times 2400$.

Fig. 5. This demonstrates the size and complexity of the choroid plexus at E14. SEM. $\times 300$.

Fig. 6. Note the increase in size and folding in this choroid plexus from an E15 mouse compared to the E14 shown in Fig. 5. SEM. $\times 150$.

Fig. 7. This shows the choroid plexus at E13. The palely staining cells are arranged as a pseudo-stratified columnar epithelium. Semithin, toluidine blue. $\times 2400$.

Fig. 8. At E13 the choroid plexus distal to the root of the plexus changes to simple columnar. The cells stain slightly more darkly than at the root and possess a brush border (arrow). Semithin, toluidine blue. $\times 2400$.

Table 1. *The percentage of light and dark choroidal epithelial cells present at each age and the number (n) of cells counted*

Age	% light cells	% dark cells	(n)
E11	100	—	—
E12	100	—	—
E13	100	—	—
E14	88·3	11·7	(197)
E15	87·9	12·1	(239)
E16	89·7	10·3	(129)
E17	89·2	10·8	(130)
E18	88·1	11·9	(176)
P0	90·4	9·6	(178)
P5	86·0	14·0	(157)
P8	87·0	13·0	(162)
P15	87·6	12·4	(161)
P25	88·6	11·4	(132)
P90	89·0	11·0	(172)

to E17 is shown in Figures 20–22: this looks like a loose membrane-bound bag containing clumps of small granules resembling glycogen, and larger, roughly circular, tightly packed masses of similar granules. The situation of these structures varies and they may be present on the apical (Fig. 20) or basal side of the nucleus, but they are most commonly found in the basal mass of glycogen granules (Figs. 21, 22).

From E14 light and dark cells are present. The dark cells have a much darker cytoplasm (Figs. 23, 24) but the organelles are generally similar to those of the light cells except that the dark cells seem to contain more ribosomes and rough endoplasmic reticulum. The microvilli of dark cells are much thinner, and seem to be longer, than those of light cells (Figs. 23, 24). Intraventricular macrophages (Fig. 23) are more commonly seen attached to dark cells than to light cells, despite the fact that light cells are much more numerous.

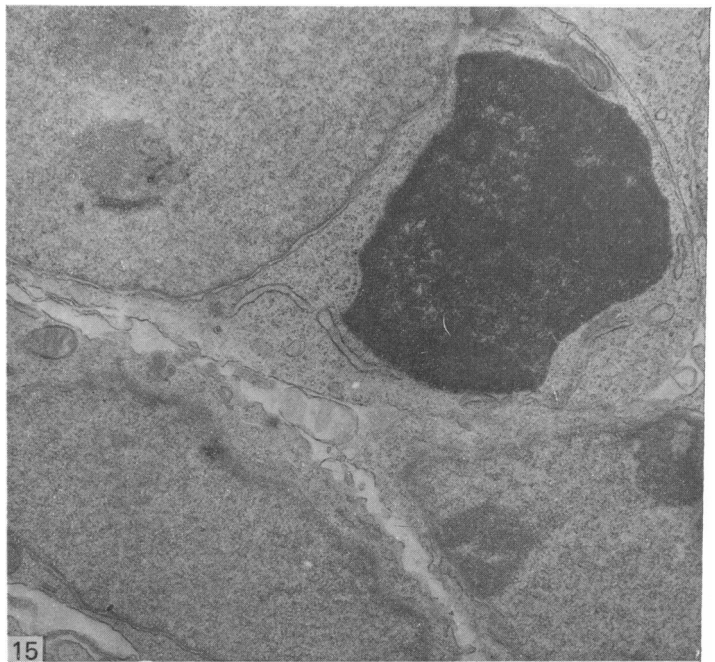
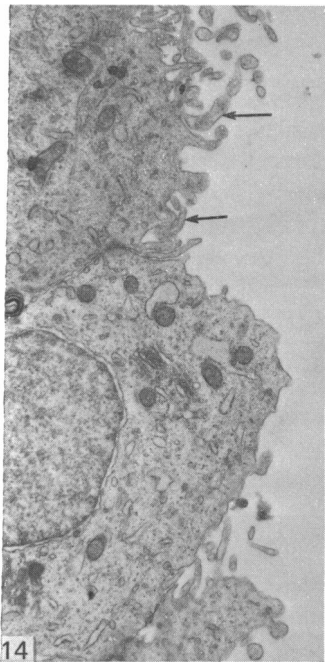
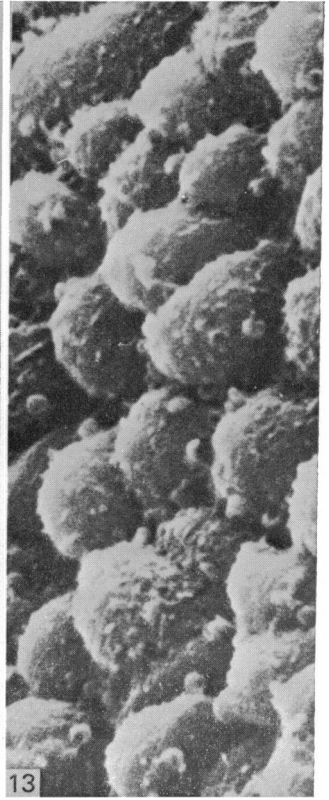
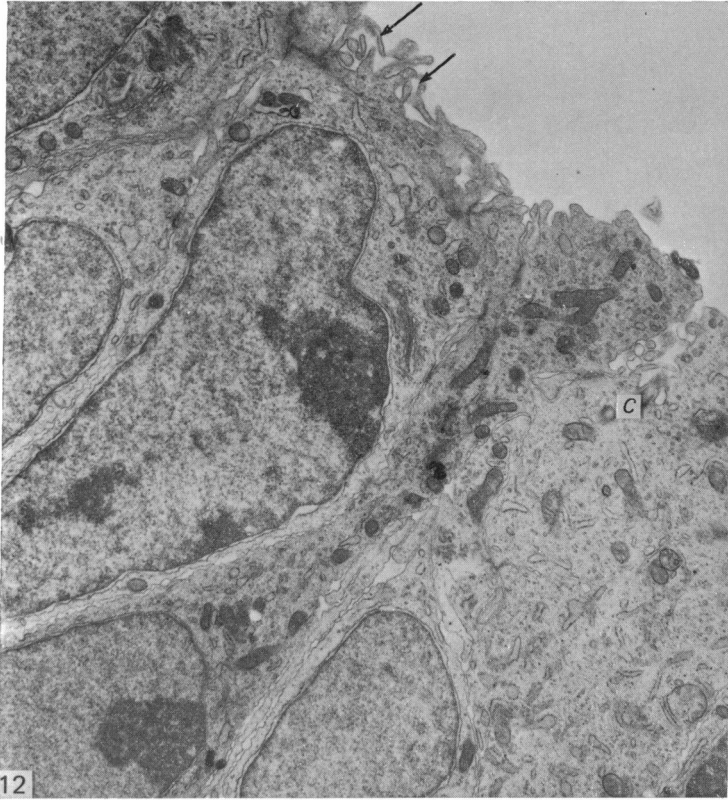
By E17 the masses of glycogen at the basal pole of the choroidal cells appear to be becoming dispersed, and at this age there is a large quantity of glycogen throughout the cytoplasm (Fig. 25). After birth the amount of glycogen in the cytoplasm is reduced (Fig. 27), and in the SEM the microvilli appear more matted (Figs. 26, 28). With increasing age the outline of individual cell boundaries can again be recognised (Fig. 28).

Fig. 12. Choroid plexus anlage at E11 showing the presence of small narrow microvilli (arrows) on the ventricular surface of the presumptive choroid plexus cells. Even in such young embryos the choroid cells are rich in organelles. Note the cilium (C). TEM. $\times 12800$.

Fig. 13. Choroid plexus anlage at E11 showing that although individual cells can be recognised there are few surface specialisations evident. SEM. $\times 2250$.

Fig. 14. Choroid anlage at E11 showing more evidence of microvilli (arrows). Cytoplasmic density appears to vary between choroid epithelial cells and the darker cells appear to be richer in microvilli than the lighter (cf. Fig. 12). TEM. $\times 12800$.

Fig. 15. This shows one of the dark masses noted in the semithin sections at E11. It is lying within the cytoplasm of a relatively undifferentiated cell. TEM. $\times 12800$.



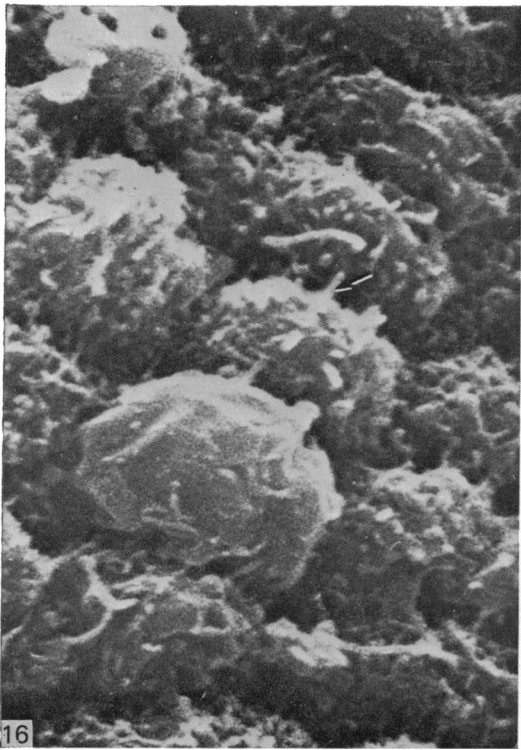


Fig. 16. At E12, cilia (arrow) and microvilli can be seen on the surface of the cells of the developing choroid plexus. SEM. $\times 5500$.

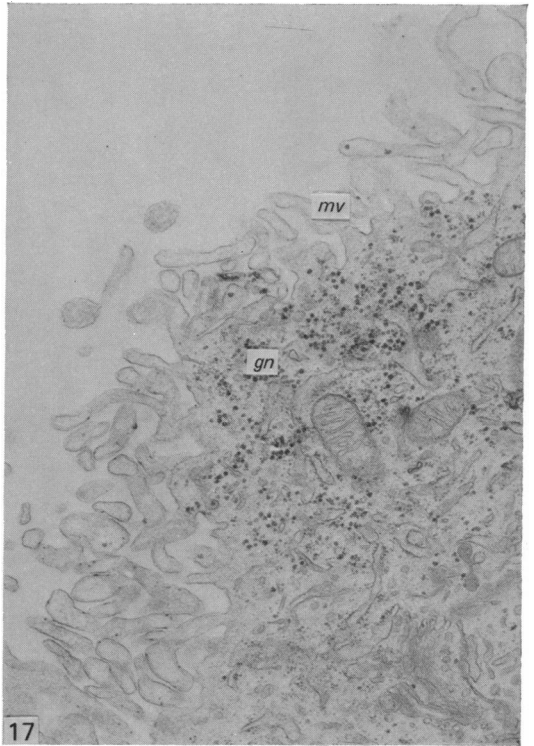


Fig. 17. By E13 choroidal epithelial cells have a well developed brush border of broad microvilli (*mv*) and are rich in glycogen (*gn*). TEM. $\times 12800$.

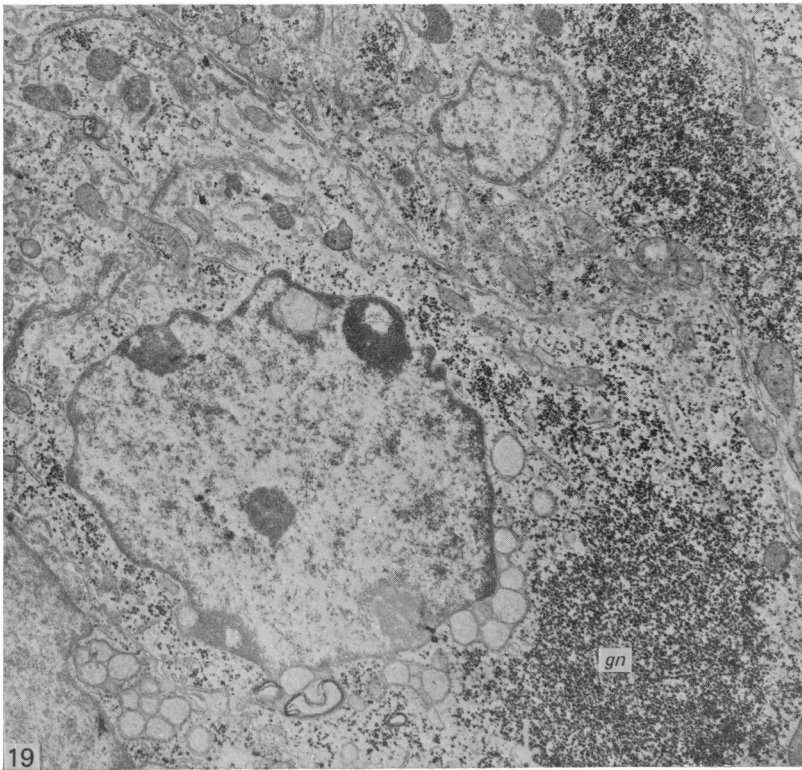
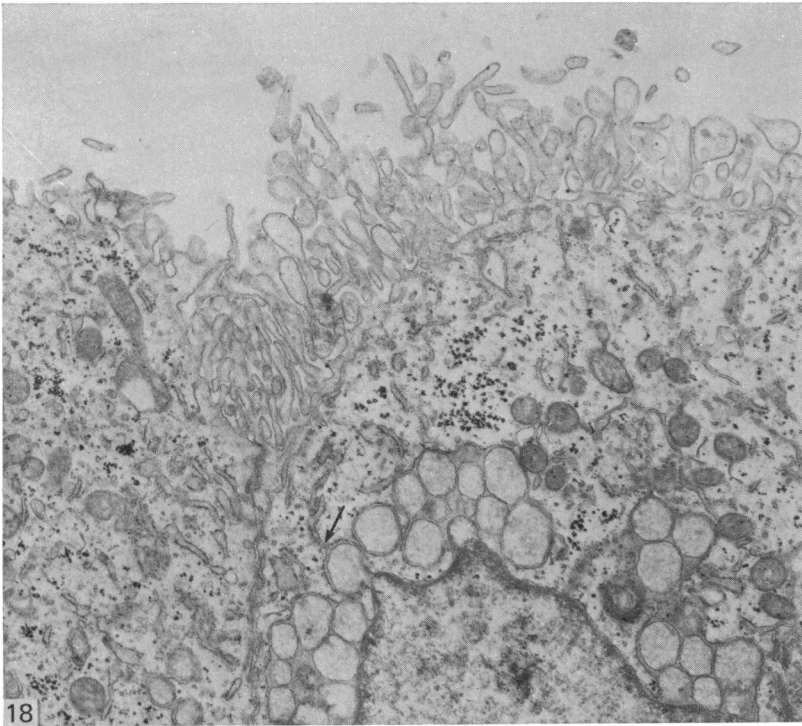
DISCUSSION

The choroid plexus of the mouse lateral ventricle increases in size and complexity extremely rapidly. From its first appearance as a pair of bilateral ridges at E11, it grows to form a fairly large structure by E14. This growth is accompanied by differentiation. As early as E11 a few narrow microvilli are present on the ventricular surface of some epithelial cells, and by E13 a well defined brush border is evident in the distal part of the developing plexus. The growth and differentiation of choroid epithelial cells is accompanied by a growth of choroidal capillaries and a change in the epithelium from pseudostratified to simple columnar at E13. By E14 two types of choroidal epithelial cells, dark and light, can be identified, and the proportion of the two cells remains constant from E14 onwards.

Light and dark choroidal epithelial cells were identified by Wislocki & Ladman (1958) in one of the earliest electron microscopic studies of the choroid plexus. They

Fig. 18. By E15 the choroid plexus epithelium is well differentiated. The rough endoplasmic reticulum contains a moderately dense amorphous substance. In some cells circular islands of cytoplasm can be seen. The spaces surrounding the islands appear to be continuous with the rough endoplasmic reticulum (arrow). TEM. $\times 12800$.

Fig. 19. This E15 choroidal epithelial cell also contains the cytoplasmic islands shown in Fig. 20, but the most obvious feature is the large mass of glycogen (*gn*) on the basal side of the nucleus. TEM. $\times 8000$.



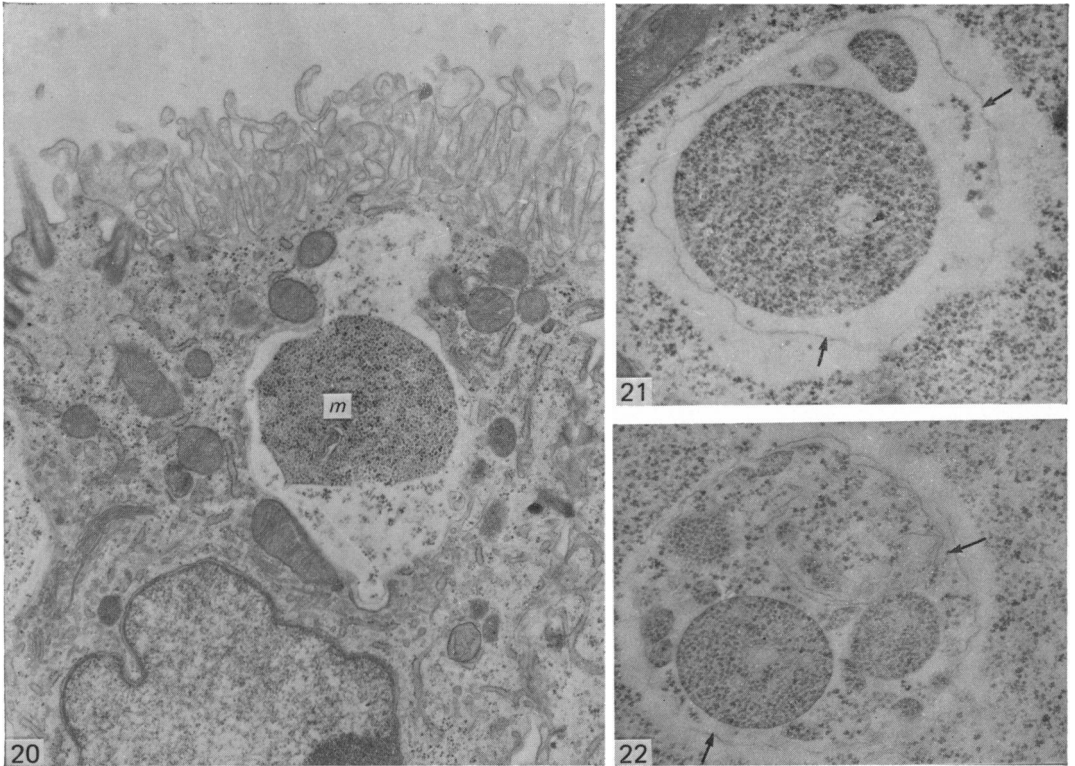


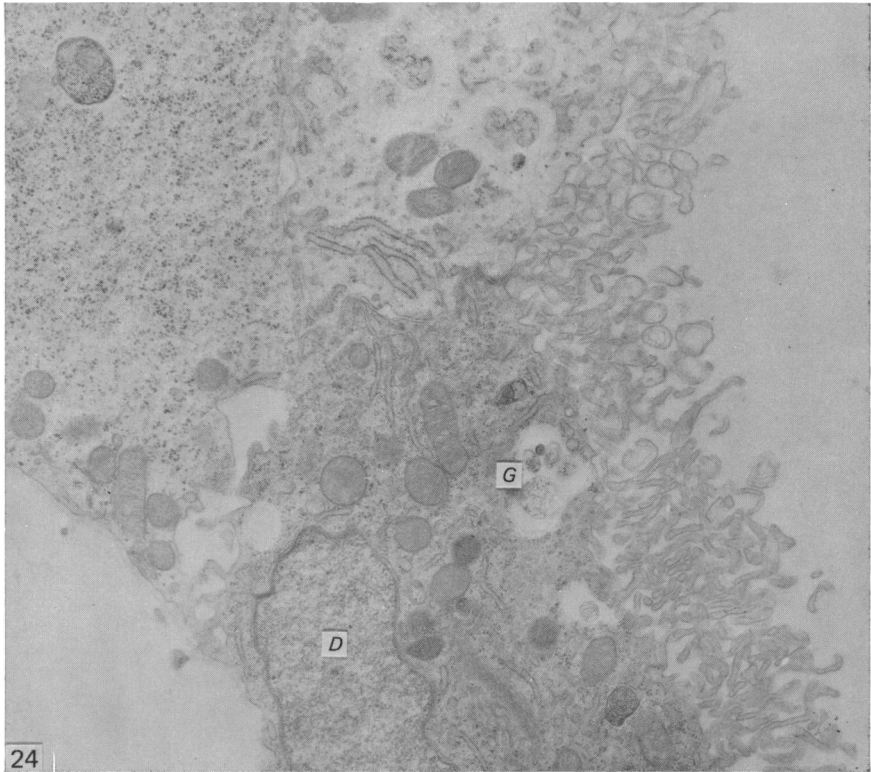
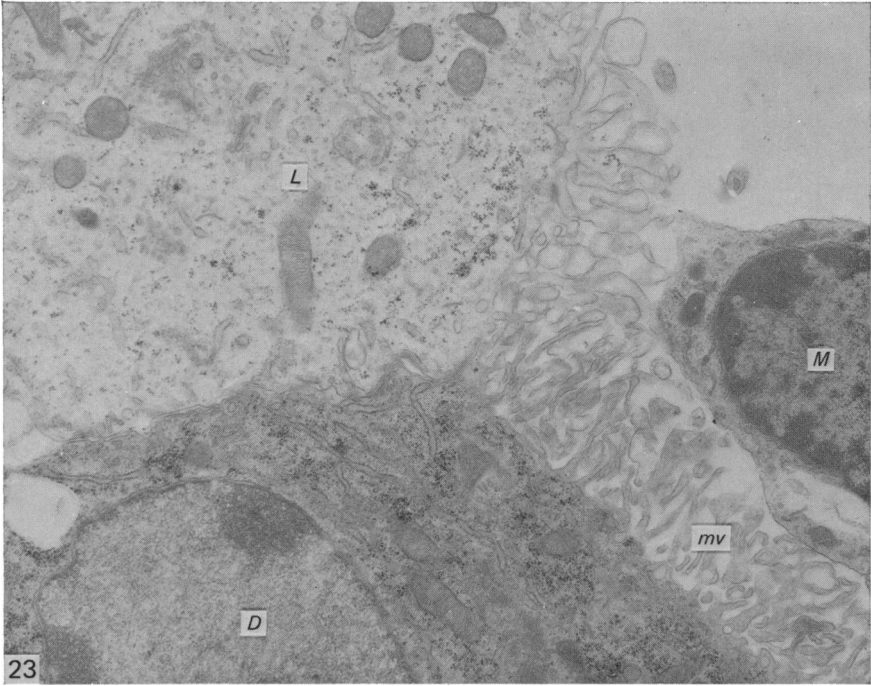
Fig. 20. This E15 choroidal epithelial cell contains an almost circular mass (*m*) of what appears to be glycogen lying within a pale area which seems to be surrounded by a membrane. The pale area contains scattered granules of glycogen. The site of this in relation to the cell surface might suggest that this is about to be secreted into the ventricle. TEM. $\times 12800$.

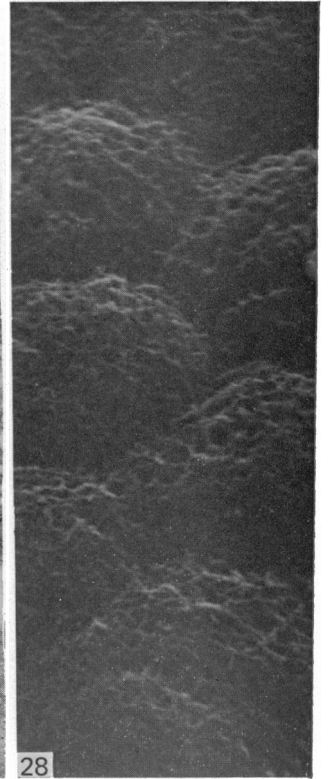
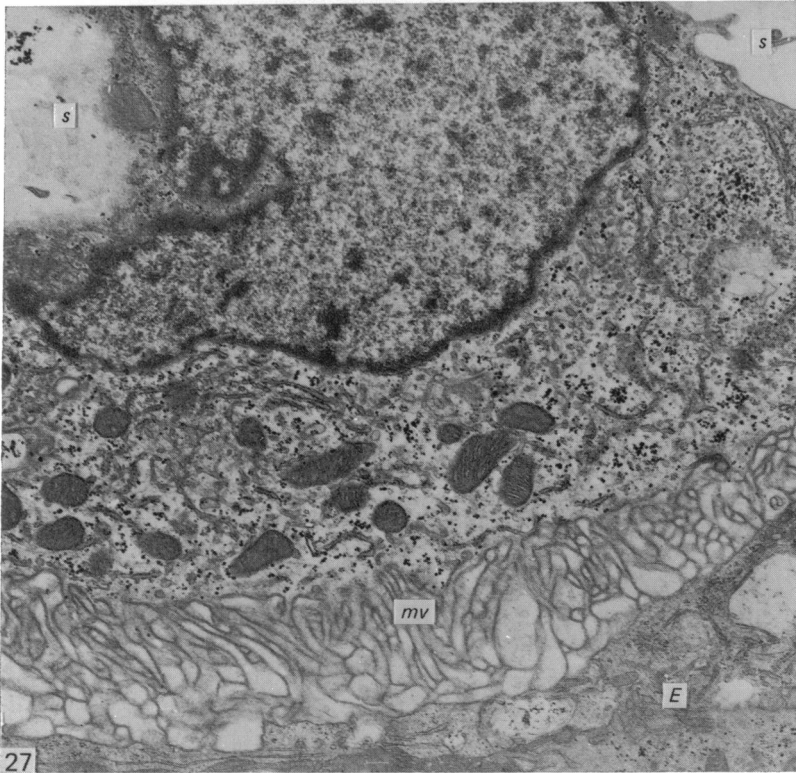
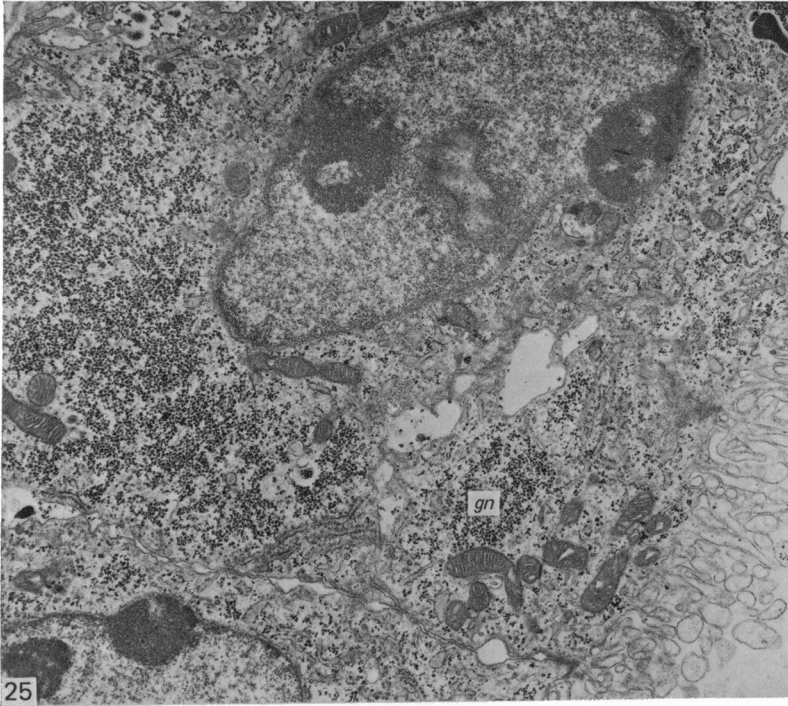
Figs. 21–22. These figures show similar masses to that shown in Fig. 22. These, however, lie within the large basal clumps of glycogen. The masses appear to be tightly packed and surrounded by a membrane. They lie in a membrane-bound space which contains scattered glycogen granules. The outer membrane (arrows) appears irregular. (E17 mouse brain.) TEM. $\times 20000$.

suggested that the difference in cell density reflected different stages in the secretory cycle of the choroidal epithelium. Differences in choroidal cell density were not mentioned by Tennyson & Pappas (1968) in their study of the developing rabbit choroid plexus. They were, however, observed by van Deurs, Møller & Amtorp (1978) in adult rat choroid plexus from brains fixed both by vascular perfusion and by intraventricular perfusion. These latter authors were of the opinion that the dark cells were not fixation artefacts and the maintenance of a constant ratio of dark to light cells from E14 on tends to support this view. It is not possible from morphological studies to interpret such a difference in density in terms of a difference in function, but if functional differentiation is involved then it is operative by E14. As

Fig. 23. In this micrograph of an E17 choroid plexus both light (*L*) and dark (*D*) cells are present. The organelles in the dark cells are more densely packed, and the microvilli (*mv*) of the dark cells are much narrower than those of the light cell. An intraventricular macrophage (*M*) is attached to the dark cell. TEM. $\times 12800$.

Fig. 24. This shows light and dark choroidal epithelial cells at E17. In this case there was no intraventricular macrophage associated with the dark cell (*D*). The dark cell contains a group of glycogen inclusions (*G*) similar to those shown in Figs. 20–22. TEM. $\times 8000$.





well as being much more electron-dense than the light cells, the microvilli of the dark cells are much finer than the rather spatulate microvilli of the light cells. This might suggest that the dark cells are relatively dehydrated and shrunken, but it is unlikely that they are degenerating cells since they form more than 10 % of the cell population of the choroidal epithelium yet pyknotic cells are not found in the choroid plexus after E13. The low incidence of mitosis in choroidal epithelium (Knudsen, 1964) suggests that there is very little cell turnover. The dark and light cells are either modulations of the same basic cell as suggested by Wislocki & Ladman (1958) or they are cells with a permanently different function. Van Deurs *et al.* (1978) found no difference between dark and light cells in the uptake of horseradish peroxidase from the CSF.

In an earlier study of intraventricular macrophages (Sturrock, 1978), very dark spherical masses resembling pyknotic nuclei were observed at the sites of folding of the presumptive choroid plexus at E11. Similar masses were present in macrophages adjacent to these foldings, and it was assumed that these were degenerating cell products undergoing phagocytosis. Under the electron microscope, however, these masses do not give the appearance of cell debris undergoing phagocytosis (Fig. 15), at least in adult animals. Sadler & Cardell (1977) found identical cell degeneration products, both by light and electron microscopy, in neuroepithelial cells of mouse embryos exposed to cytotoxic doses of hydroxyurea. Similar cell inclusions, assumed to be degenerating cells, were observed by Geelen & Langman (1977) in the parts of the folding neural tube which were about to undergo fusion. It is likely therefore that in the choroid plexus they are in fact degenerating cells, and this degeneration is purposeful, permitting rapid thinning of the epithelium at the sites of folding, and thus enabling folding to occur more quickly.

The presence of large quantities of glycogen in the developing choroid plexus is well known (Goldmann, 1913; Weed, 1917; Wislocki, 1932; Kappers, 1958; Tennyson & Pappas, 1968). Glycogen appears in choroidal epithelial cells of the mouse at E13, and already at this age it is found in large accumulations at the base of a few cells. The preferential accumulation of glycogen at the basal pole may be due either to its uptake from adjacent capillaries, or, as Kappers (1958) has suggested, to its role in the formation of the glycosaminoglycans of the basement membranes of the choroid plexus. Large quantities of glycogen are present until after birth, which might tend to favour Kappers' (1958) alternative suggestion that the glycogen has a nutritive role, particularly for ependymal cells. Oksche (1958) has shown that glycogen disappears from choroidal epithelial cells during hibernation and can be detected in ependymal cells. The timing of the accumulation and later disappearance of glycogen in the choroid epithelium coincides roughly with the mitotic activity in the ependymal and subependymal cells of the lateral ventricle (Smart, 1976).

Fig. 25. By E17 the basal masses of glycogen are becoming split up and the glycogen is dispersed throughout the cells (*gn*). TEM. $\times 12800$.

Fig. 26. At P5 the choroid plexus epithelial microvilli have a matted appearance. SEM. $\times 2050$.

Fig. 27. In the adult (P90) choroid plexus epithelial cells the glycogen is relatively sparse and evenly scattered throughout the cells. The cytoplasm is rich in organelles, especially mitochondria and rough endoplasmic reticulum. As in the semithin sections the spaces between choroidal epithelial cells (*s*) are probably artefactual. The microvilli (*mv*) are in contact with the ependyma (*E*). TEM. $\times 19000$.

Fig. 28. In the adult mouse, P90, the choroidal microvilli still appear matted, but it is now possible once again to detect individual cell boundaries. SEM. $\times 2100$.

Glycogen is also present in astrocytes in much larger quantities during development than in adult animals (Sturrock, 1974, 1976), and it has been suggested that this may also be of nutritive significance.

The dilatation of the rough endoplasmic reticulum at E15 was not found in the developing rabbit choroid plexus (Tennyson & Pappas, 1968), nor was the presence of membrane-bound masses of glycogen-like material. The situation of the 'bag' in Figure 22 raises the possibility that the products are about to be extruded into the ventricle, and it is possible that the apparent increase in rough endoplasmic reticulum activity at this time may be related to some form of secretion.

The change in character of the surface of the choroidal epithelium observed in the SEM might be due to an increase in the number of microvilli and to their becoming entangled and matted. This is supported to some extent by the TEM observations (contrast the microvilli in Fig. 20 and Fig. 27).

The mouse lateral ventricle choroid plexus epithelium, apart from the large quantities of glycogen, is well differentiated and relatively extensive by E14. At this stage few other cells of the forebrain are at all well differentiated apart from a few microglia (Smart & Sturrock, 1979). E14 seems to be a fairly important stage in mouse forebrain development, and in particular neostriatal development, with the majority of neostriatal neurons being born on this day (Angevine & McConnell, 1974). It also marks the stage when the subependymal layer is about to take over from the ependymal layer as the major site of cell production in the forebrain (Smart, 1976). The possible interdependence of the events in the choroid plexus and forebrain at this critical stage in development needs to be explored further.

SUMMARY

Development of the mouse choroid plexus was studied by semithin light microscopy, transmission electron microscopy and scanning electron microscopy. The choroid plexus is first observed as a bilateral ridge at 11 days postconception. The major morphological development appears to occur between 11 and 14 days postconception. By 14 days both dark and light choroid plexus epithelial cells are present. The percentage of dark cells appears constant from 14 days postconception up to 3 months postnatum. Metachromatically staining glycogen masses are present in the choroidal epithelium from 13 days postconception until 5 days postnatum, after which time glycogen granules are sparsely scattered throughout the cytoplasm. A few fine microvilli are present at 11 days postconception and these increase in number and become much more bulbous by 13 days. In contrast to the light choroid plexus epithelial cells, the dark cells have fine narrow microvilli. The possible significance of the two types of choroid plexus cells is discussed.

REFERENCES

- ANGEVINE, J. B. & MCCONNELL, J. A. (1974). Time of origin of striatal neurons in the mouse. *Anatomical Record* **178**, 300.
- BERRY, M. (1974). Development of the cerebral neocortex of the rat. In *Aspects of Neurogenesis. Studies on the Development of Behaviour and the Nervous System* (ed. G. Gottlieb), pp. 7-67. New York, London: Academic Press.
- CHAMBERLAIN, J. G. (1973). Analysis of developing ependymal and choroidal surfaces in rat brains using scanning electron microscopy. *Developmental Biology* **31**, 22-30.
- DAVIS, P. A., LLOYD, B. J. & MILHORAT, T. H. (1973). A comparative ultrastructural study of the choroid plexus of the immature pig. *Anatomical Record* **176**, 443-454.

- GEELAN, J. A. G. & LANGMAN, J. (1977). Closure of the neural tube in the cephalic region of the mouse embryo. *Anatomical Record* **189**, 625–640.
- GOLDMANN, E. (1913). Vitalfärbung am Zentralnervensystem (Beitrag zur Physiopathologie des Plexus choroideus und der Hirnhäute). *Abhandlungen der Preussischen Akademie der Wissenschaften* **1**, 1–60.
- KAPPERS, J. A. (1958). Structural and functional changes in the telencephalic choroid plexus during human ontogenesis. In *Ciba Foundation Symposium on Cerebrospinal Fluid* (ed. G. E. W. Wolstenholme and C. M. O'Connor), pp. 3–31. Boston: Little Brown & Co.
- KNUDSEN, P. A. (1964). Mode of growth of the choroid plexus in mouse embryos. *Acta anatomica* **57**, 172–182.
- OKSCHE, A. (1958). Histologische Untersuchungen über die Bedeutung des Ependyms, der Glia und der Plexus choroidei für den Kohlenhydratstoffwechsel des ZNS. *Zeitschrift für Zellforschung und mikroskopische Anatomie* **48**, 74–129.
- SADLER, T. W. & CARDELL, R. R. (1977). Ultrastructural alterations in neuroepithelial cells of mouse embryos exposed to cytotoxic doses of hydroxyurea. *Anatomical Record* **188**, 103–124.
- SAUER, F. C. (1935). Mitosis in the neural tube. *Journal of Comparative Neurology* **62**, 377–405.
- SAUER, F. C. (1936). The interkinetic migration of embryonic epithelial media. *Journal of Morphology* **60**, 1–11.
- SEYMOUR, R. M. & BERRY, M. (1975). Scanning and transmission electron microscopic studies of interkinetic nuclear migration in the cerebral vesicles of the rat. *Journal of Comparative Neurology* **160**, 105–126.
- SIDMAN, R. L. & ANGEVINE, J. B. (1962). Autoradiographic analysis of time of origin of nuclear versus cortical components of the mouse telencephalon. *Anatomical Record* **142**, 326–327.
- SMART, I. H. M. (1973). Proliferative characteristics of the ependymal layer during the early development of the mouse neocortex: a pilot study based on recording the number, location and plane of cleavage of mitotic figures. *Journal of Anatomy* **116**, 67–91.
- SMART, I. H. M. (1976). A pilot study of cell production by the ganglionic eminences of the developing mouse brain. *Journal of Anatomy* **121**, 71–84.
- SMART, I. H. M. & SMART, M. (1977). The location of nuclei of different labelling intensities in autoradiographs of the anterior forebrain of postnatal mice injected with 3H-thymidine on the eleventh and twelfth days post-conception. *Journal of Anatomy* **123**, 515–525.
- SMART, I. H. M. & STURROCK, R. R. (1979). Ontogeny of the neostriatum. In *The Neostriatum* (ed. I. Divac). Oxford, New York, Toronto, Paris, Sydney, Frankfurt: Plenum Press.
- STURROCK, R. R. (1974). Histogenesis of the anterior limb of the anterior commissure of the mouse brain. III. An electron microscopic study of gliogenesis. *Journal of Anatomy* **117**, 37–53.
- STURROCK, R. R. (1976). Light microscopic identification of immature glial cells in semithin sections of the developing mouse corpus callosum. *Journal of Anatomy* **122**, 521–537.
- STURROCK, R. R. (1978). A developmental study of epiplexus cells and supraependymal cells and their possible relationship to microglia. *Neuropathology and Applied Neurobiology* **4**, 307–322.
- TENNYSON, V. M. & PAPPAS, G. D. (1968). The fine structure of the choroid plexus: adult and developmental stages. In *Progress in Brain Research*, vol. 29 (ed. A. Lajtha and D. H. Ford), pp. 63–85. Amsterdam, London, New York: Elsevier.
- VAN DEURS, B., MØLLER, M. & AMTORP, O. (1978). Uptake of horseradish peroxidase from CSF into the choroid plexus of the rat with special reference to transepithelial transport. *Cell and Tissue Research* **187**, 215–234.
- WEED, L. H. (1917). The development of the cerebrospinal spaces in the pig and man. *Contributions to Embryology* **14**, no. 225.
- WISLOCKI, G. B. (1932). The cytology of the cerebrospinal pathway. In *Special Cytology*, vol. 3 (ed. E. V. Cowdry), pp. 1482–1521. New York: Harper & Row.
- WISLOCKI, G. B. & LADMAN, A. J. (1958). The fine structure of the mammalian choroid plexus. In *Ciba Foundation Symposium on Cerebrospinal Fluid* (ed. G. E. W. Wolstenholme and C. M. O'Connor), pp. 55–79. Boston: Little Brown & Co.