

Postnatal growth of Brunner's glands in the mouse

A. A. OBUOFORIBO* AND B. F. MARTIN

*Department of Human Biology and Anatomy, University of Sheffield,
and Department of Anatomy, University of Birmingham*

(Accepted 19 November 1976)

INTRODUCTION

The early studies made on the duodenal glands of Brunner were reviewed by Landboe-Christensen in 1944. The glands were first recognized by Wepfer (1679) during a post mortem study on a female subject, and he observed that they produced copious mucus when macerated in water. Later, Brunner (1688; 1715), who was Wepfer's son-in-law (Dobson, 1962), studied the glands in man and several other species and concluded that they consist of accessory pancreatic tissue. Middeldorpf (1846) suggested that they be designated the 'Glands of Brunner', although he realized that their secretion differed from that of the pancreas.

The glands have been found in all mammalian species which have been investigated (Bensley, 1903; Carleton, 1935; Elias, 1947). Usually they commence at the pyloro-duodenal junction, but their distal extent varies with the species. In Eutherian mammals they are submucosal, tubulo-alveolar, with ducts penetrating the muscularis mucosae to open into the crypts of Lieberkühn. In a series of marsupials, however, the glands have been found to open independently into the intestinal lumen (Krause & Leeson, 1969*a*; Krause, 1973), whilst in the monotremes the glands are virtually confined to the submucosa of the distal stomach (Krause, 1970; 1971).

Following the work of Florey (1955) it became fairly generally accepted that the glands secrete an alkaline, mucinous material which protects the mucosa of the proximal part of the duodenum from the acid-pepsin of the gastric secretion (Grossman, 1958). It has long been known, however, that the glands in some common laboratory species are partly or wholly serous in type. Recently, Krause (1973) reported varying proportions of serous and mucous glands in six marsupial species. Like previous investigators, however, he was unable to correlate these differences with diet.

Electron microscopy has confirmed that the glands are mucous in the guinea-pig (Cochrane, Davies, Palfrey & Stockwell, 1964), and man (Leeson & Leeson, 1968), but mixed mucous and serous in the mouse (Friend, 1965), cat (Moe, 1960) and rat (Leeson & Leeson, 1966). The glands of the rabbit are unique, in that small groups of serous cells are associated with the acini, the component cells of which show intermediate characteristics (Krause & Leeson, 1969*a*). These cells give a histochemical reaction for true lipase (Martin, 1954), which supports the view that they are elements of pancreatic tissue (Patzelt, 1936).

Although the glands of all species so far studied give a positive periodic acid-Schiff (PAS) reaction, indicating the presence of mucopolysaccharides, it is clear that there are species variations in the composition of the mucinous material and

* Present address: Department of Anatomy, University of Benin, Nigeria.

also in the range of other cellular products. It was reported by Florey & Harding (1934) that the glands do not stain with mucicarmine in all species, and more recent studies on their metachromatic reactions indicate that some species secrete neutral, others acid mucosubstances, and in some cases a mixture (Jennings & Florey, 1956; Cochrane *et al.* 1964; Krause & Leeson, 1969*a*; Krause, 1973; Obuoforibo, 1975). In a few species, histochemical techniques have demonstrated the presence of hydrolytic enzymes in the glands; for example, alkaline phosphatase is found in the cat (Moe, 1952), acid phosphatase in the guinea-pig (Cochrane *et al.* 1964) and mouse (Obuoforibo, 1972) and non-specific esterase in the mouse (Martin, 1956).

From studies on the development of the glands in man (Brand, 1877; Johnson, 1910), rabbit (Wolff, 1961), golden hamster (Mann, Sasse & Graumann, 1967) and rat and opossum (Krause & Leeson, 1967; 1969*b*), it is known that they arise as downgrowths from the duodenal mucosa, either directly or from the bases of the crypts. Although they appear after about 3 months of fetal life in man, in the other species studied they first develop at or near the time of birth. It was reported by Wolff that in the rabbit they continue to grow and develop for the first three post-natal weeks, and by Mann *et al.* that in the golden hamster they reach functional maturity about the fifteenth day. No information was given, however, about their mode and rate of growth.

In the present study, the postnatal growth of the glands has been studied in the mouse from birth to maturity. This species is particularly suitable for investigation since, as seen in a longitudinal section of the pyloro-duodenal junction (Fig. 1), the glands form a compact, comma-shaped mass about 2.5 mm long. The rounded base of the gland mass extends a short distance into the pylorus and occupies a concavity in the pyloric sphincter. In most specimens, a large, circumferentially directed vein lies close to the narrow distal extremity of the gland mass.

MATERIALS AND METHODS

All studies were made on Swiss mice bred and maintained under identical conditions. The number of young in each litter was reduced to eight at birth. Animals were killed at intervals between 1 day and 4 months after birth, but complete kinetic studies were not made on animals more than 77 days old.

After recording body weight, mice were killed by decapitation and a 1 cm length of the pyloro-duodenal junctional region was removed. The specimens were usually fixed in 80% alcohol, but some were fixed in Carnoy's fluid, 4% buffered neutral formaldehyde or formol-alcohol, and after embedding in paraffin wax they were sectioned at 6 μm .

Study of haematoxylin and eosin and periodic acid-Schiff (PAS) preparations was carried out as a routine. The surface area of the well-defined gland was determined (in sq mms) by means of an eyepiece containing a square lattice grid. The results were checked and confirmed by tracing the outline of the gland in photomicrographs with a planimeter. Estimations of cell size at different ages were also made; the technique will be considered when presenting the results.

Studies on cellular kinetics were made on animals of each age group. The mitotic index of the gland was obtained from H & E preparations, using an eyepiece graticule, whilst the total daily mitotic rate was determined from colchicine preparations. Prior to administration of this alkaloid, which blocks mitosis at metaphase, a preliminary study was undertaken on 14 adult mice from general stock. Following

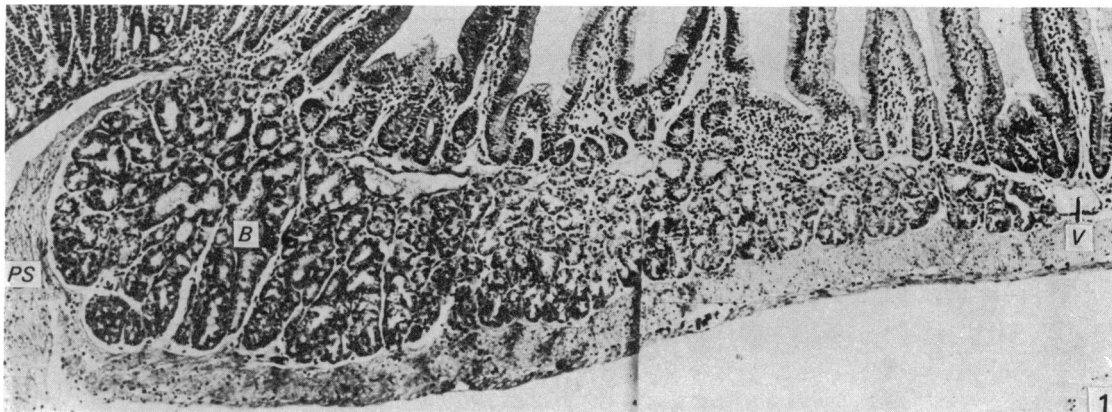


Fig. 1. Mouse; adult. Brunner's glands (*B*) form a well-defined, comma-shaped mass. The rounded base occupies a concavity in the spike-like termination of the pyloric sphincter (*PS*), whilst the narrow terminal extremity is in apposition with a large, thin-walled vein (*V*). H & E. $\times 50$.

an intraperitoneal injection of colchicine into each animal (0.2 mg per 100 gm body wt), they were killed in pairs at hourly intervals up to 7 hours later. In non-consecutive sections of the pyloro-duodenal junction, the percentage of cells within well-sectioned crypts overlying Brunner's glands which were arrested in metaphase were estimated from counts of about 1000 cells. It was found that the hourly increase in the percentage of arrested metaphases was linear up to 4 hours, but thereafter there was a decline due, at least in part, to fragmentation. A 4 hourly period was therefore used in the colchicine studies on the experimental animals.

In addition to the mitotic index and daily mitotic rate, the labelling index of the gland cells, and also certain features of their cell cycle at different ages were determined from autoradiographic studies following administration of tritiated thymidine ($^3\text{H-T}$). Following a single intraperitoneal injection ($1 \mu\text{C}$ per gm body wt), the animals were killed at intervals up to 24 hours. Sections were prepared by the stripping film method and they were 'counterstained' by the PAS reaction. From estimates of the percentage of labelled metaphases present, mitotic curves were prepared for both Brunner's glands and the crypts of Lieberkühn. To obtain the labelling index of the cells of Brunner's glands, the percentage of cells labelled 45 minutes after $^3\text{H-T}$ was determined.

RESULTS

General postnatal changes

The duodenal villi are relatively large at birth, and at the commencement of the duodenum they are broad and closely set (Fig. 2). The crypts, however, are only very shallow depressions, lined by low columnar cells which stain deeply in haematoxylin and eosin preparations. Brunner's glands consist of a few simple tubular downgrowths from the most proximal of these shallow crypts, and are easily distinguished from the latter by their lighter staining (Fig. 3). In addition, from their earliest appearance, all the glandular cells give a PAS reaction which is largely supranuclear in position, whilst in the crypts a reaction is only given by the goblet cells (Figs. 4, 5; 6 days).

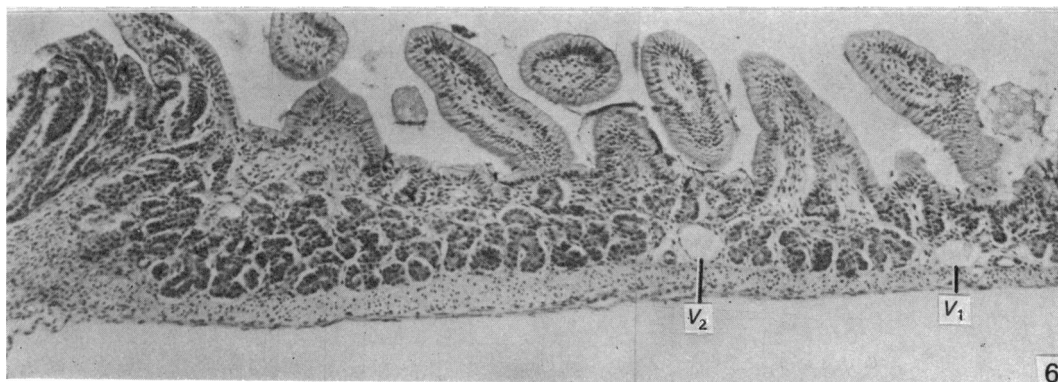
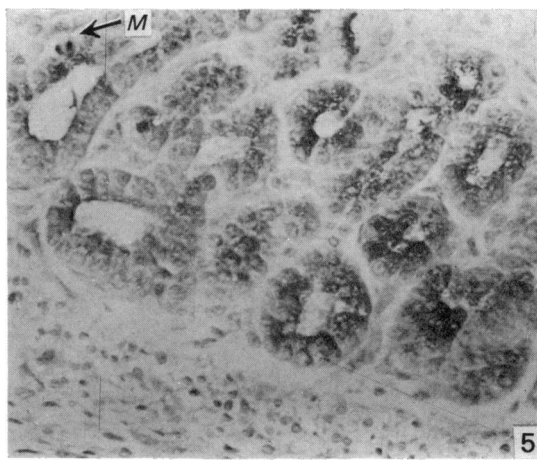
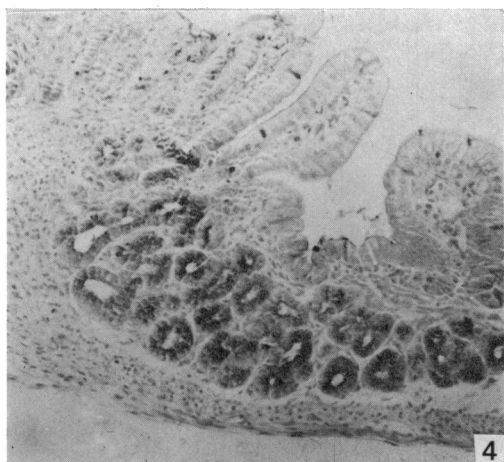
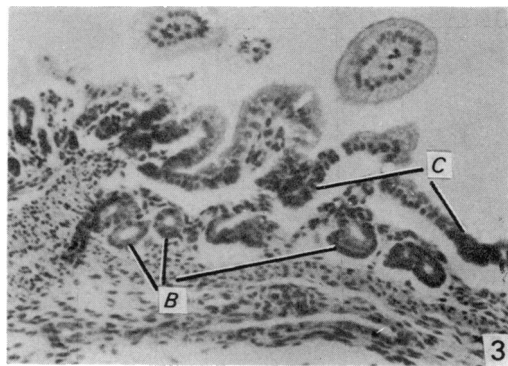
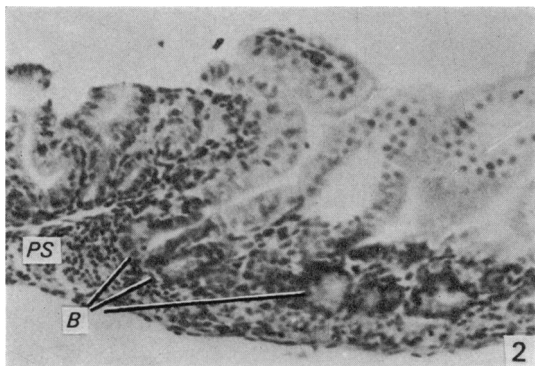


Fig. 2. Mouse; 1 day. Brunner's glands (*B*) are indicated as a few short downgrowths, just beyond the developing pyloric sphincter (*PS*). H & E. $\times 130$.

Fig. 3. Mouse; 2 days. The gland still consists of a few short tubules (*B*), which are pale-staining, whereas the very short crypts (*C*) stain deeply. H & E. $\times 130$.

Fig. 4. Mouse; 1 week. The proximal tubules have elongated and branched and the gland mass is assuming a rounded contour within the developing pyloric sphincter. The glands give a PAS reaction. $\times 130$.

Fig. 5. Higher power of preceding section shows that the PAS reaction is largely supranuclear. Note the mitotic figure (*M*). PAS. $\times 330$.

Fig. 6. Mouse; 2 weeks. The Brunner's gland mass is deepest proximally and some branched tubules are seen. At its distal extremity is a large vein (*V*₁), but (unusually) a second vein (*V*₂) lies among the distal, short tubules. H & E. $\times 90$.

Table 1. *The postnatal growth in size and in cell population of Brunner's glands*

Age (dy)	Body wt (gm)	Gland area in L.S. (sq mm)	Total cells per section	Labelling index ($^3\text{H-T}$) (%)	Mitotic index (%)	Daily mitotic rate (%)	Daily cell increment rate (%)
1	1.5	—	180	—	—	—	—
7	4.3	0.05	650	8.16	0.82	12.2	43.5
14	7.1	0.14	2340	3.41	0.61	13.2	37.1
21	9.7	0.31	3110	2.45	0.23	4.0	4.7
30	19.5	0.43	4040	1.42	0.20	3.4	3.3
55	33.8	0.56	5860	0.64	0.13	1.5	1.8
77	37.6	0.71	6800	0.52	—	—	0.7

For several days, growth of the gland consists of additions of tubular downgrowths further along the duodenum. By the end of the first week, the gland mass has not only extended distally, but shows increase in size proximally, due to elongation and branching of the tubules. The future comma-like shape of the gland mass is thereby indicated, its base already extending slightly into the pylorus where it occupies a concavity in the developing pyloric sphincter (Fig. 4).

By the end of the second week, the distal tubules have undergone some elongation and branching, but not to the same degree as the proximal tubules (Fig. 6). Further growth follows this general pattern, and by the end of the third week the gland mass has attained its adult form and relationship to the pyloric sphincter, which is now well developed (Fig. 7; compare with Fig. 1). Thereafter, growth continues at a diminishing rate, but even after the body weight has ceased to show a significant increase, the gland mass continues to increase in size, as will be shown.

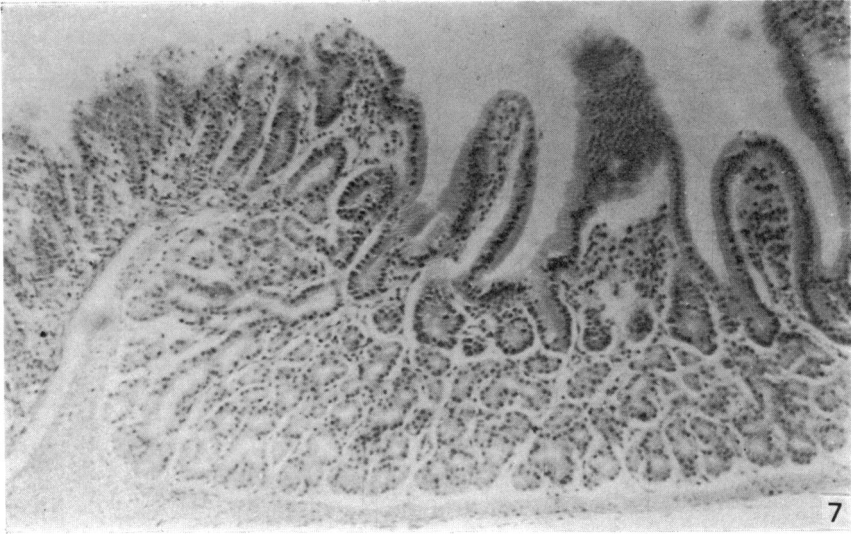
Rate of growth

In addition to measurements of the surface area of the gland mass in sections, counts of the total number of cells present, and also estimates of cell size, were made to determine to what extent increase in size of the gland mass is dependent upon increase in cell numbers.

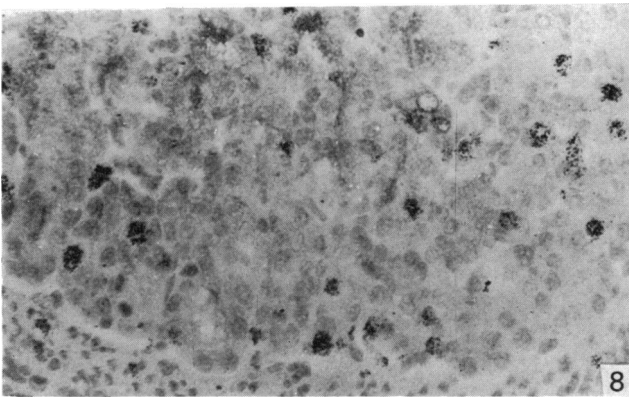
The total number of nuclei within the gland indicates the total number of cells. Estimation of cell size can be made by obtaining the average diameter from measurements of the height and width of the cells, using a microscope equipped with an eyepiece micrometer. The cell outlines are not very clear in this gland but, as far as could be judged, the average cell size did not increase with age, and furthermore the average nuclear diameter remained fairly constant. From a series of measurements at ages 1, 2, 7, and 64 days, it was found that the mean respective diameters were 6.08, 5.33, 6.05 and 7.15 μm .

The average values obtained for the kinetic features at different ages are presented in Table 1, and the relationship of the square area of the gland mass to its cell number and to the body weight are shown in Figure 10. The graph in Figure 10 was constructed by equating the values obtained at one week of age, so that their relationships at all later ages could be studied.

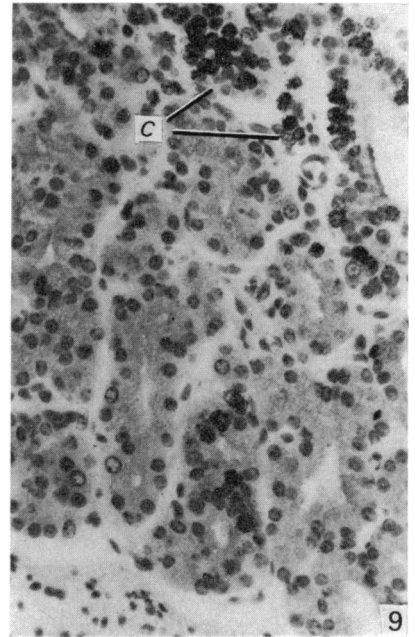
It will be seen from Figure 10 that the rise in body weight is linear for about 55 days, but thereafter there is only a small further rise, and beyond about 75 days there is virtually no further increment. The increase in glandular area is closely equated with the increase in cell population at all ages, but the increment in glandular area becomes proportionately greater than that of the body weight. Furthermore,



7



8



9

Fig. 7. Mouse; 3 weeks. The gland mass has now assumed its adult form and its rounded base lies within the well-developed 'spike' of the pyloric sphincter. Note the very long, branched tubule. H & E. $\times 130$.

Fig. 8. Mouse; 8 days. A considerable number of nuclei in Brunner's glands are labelled with $^3\text{H-T}$. Autoradiograph. $\times 330$.

Fig. 9. Mouse; 3 weeks. A much smaller number of gland cell nuclei are now labelled. The overlying crypts (C) contain many labelled cells. Autoradiograph. $\times 330$.

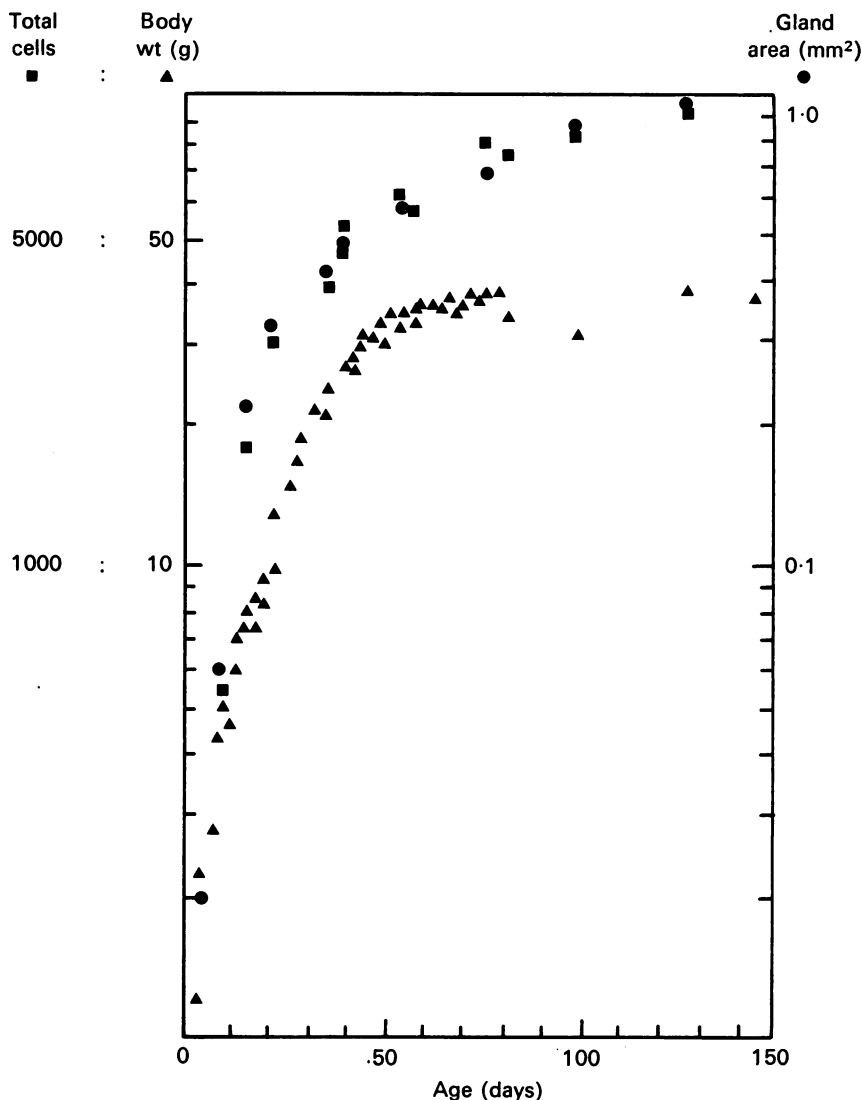


Fig. 10. Shows that the increase with age in the square area of Brunner's glands in longitudinal section is directly related to the increase in total cell population. After 20 days the increment in gland mass is relatively greater than that of the body weight, and continues after the body weight has stabilized.

the glandular tissue continues to increase at a slow but steady rate long after the body weight has become virtually static.

Kinetic features

Mitotic figures are rarely observed in the gland cells in the adult, but they appear relatively numerous during the first two postnatal weeks. It is of particular interest to note that cells undergoing mitosis show a PAS reaction in the cytoplasm, which is unchanged by pretreatment with salivary diastase, which removes glycogen (Fig. 5).

Since this result indicates that the cells are elaborating mucopolysaccharides, it may be inferred that some degree of functional differentiation has already occurred.

During the third week there is a considerable decline in mitotic activity, and by 30 days very few mitoses are to be seen, even in colchicine preparations. The labelling index shows the same pattern of decline (see Table 1, and compare Figs. 8 and 9). As in the case of cells undergoing division, cells which are preparing for division, and therefore labelled with $^3\text{H-T}$, also show a cytoplasmic PAS reaction.

Calculation of the relationship between the daily mitotic rate and the daily growth rate of the gland proved of interest. The daily mitotic rate was estimated from counts of the percentages of cells arrested in metaphase during 4 hourly periods of colchicine administration, whilst the percentage daily growth rate was estimated by the use of Brody's (1945) formula, namely,

$$\frac{N_2 - N_1}{N_1} \times \frac{100}{t_2 - t_1},$$

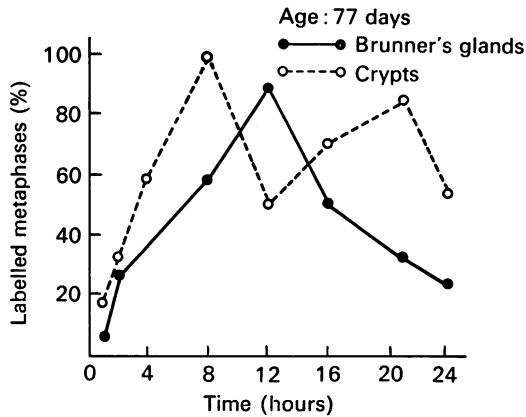
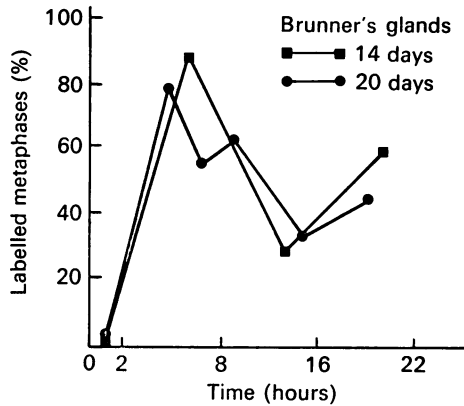
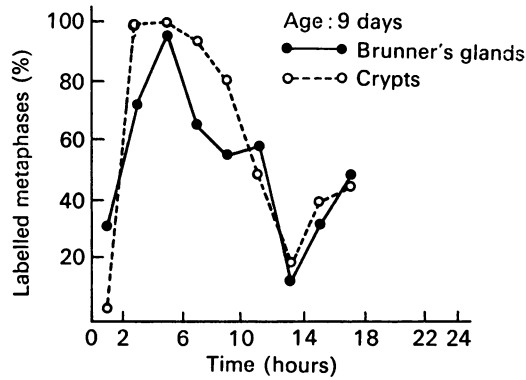
where N_1 and N_2 are the number of cells present at the times t_1 and t_2 . The result gives the number of cells added per day, expressed as a percentage of those present at the earlier stage. It will be noted in Table 1 that during the first two weeks the daily cell increment rate is at its peak (approximately 40%), and that during this period approximately three times the number of cells are added to the gland daily than can be accounted for by mitotic activity within the glandular tissue. By the end of the third week there is a marked decline in the cell addition rate, and it can now be accounted for by the mitotic activity within the gland. Beyond this time the addition rate progressively declines, but new cells are still being added after 77 days, at a rate of 0.7% per day. It would seem, therefore, that for 2-3 weeks after birth cells are being added to the gland from an external source; this point will be discussed later.

From the labelled metaphase curves shown in Figs. 11, 12 and 13, it will be seen that at 9 days of age the curve obtained from Brunner's glands is essentially the same as that for the overlying intestinal crypts (Fig. 11). The time interval between the points at which 50% of the metaphases are labelled on the ascending and descending limbs of the first mitotic wave gives a value of approximately 9 hours for the S phase, whilst the interval between 50% labelling on the ascending limbs of the first and second mitotic waves gives a value of approximately 14 hours for the cell cycle time. These values are in reasonable agreement with those of Thrasher (1966) for the crypt cells. From a larger number of animals he obtained a value of 7.8 hours for S phase and 15 hours for the cell cycle time.

At 14 and 20 days of age the phases of the cell cycle of Brunner's glands (Fig. 12) shows no change from 9 days, but by 77 days (Fig. 13) there is evidence that the cell cycle time lengthens to over 24 hours and the S phase to approximately 12 hours, whereas the crypt cells show little change in the cycle phases.

DISCUSSION

This study confirms that Brunner's glands originate as simple tubular downgrowths from the proximal crypts of the duodenum, and that a small number of these elements are present at birth. During the first postnatal week, further tubular downgrowths are added in a distal direction, leading to increase in overall length of the glandular tissue. By the end of the week the proximal tubules are undergoing elongation and branching, and this increases both the absolute and the relative size



Figs. 11–13. Labelled metaphase curves of the duodenal crypts and Brunner's glands show that the cell cycle time and its phases are similar in the two populations at 9 days (Fig. 11). The Brunner's gland cycle is unchanged at 14 and 20 days (Fig. 12), but shows lengthening by 77 days, whereas that of the crypts shows little change (Fig. 13).

of this part of the gland mass leading to the development of its typical 'comma' shape.

The most marked growth in overall size of the gland mass occurs during the first three postnatal weeks, and at the end of this time the adult form is established. During this period, the daily increment of glandular cells is much greater than can

be accounted for by the mitotic activity of the gland cells. It would therefore seem likely that the crypts, from which the original tubular downgrowths arise, continue to provide cells which move in a downward direction into the ducts of Brunner's glands, in addition to those which move upwards on to the villi. The rapid growth of the glandular tissue may well be in preparation for weaning which, in the mouse, normally occurs about 21 days after birth. It is of interest that Herbst & Sunshine (1969) found an increase in the mitotic activity and labelling index of the crypts of the rat small intestine at the time of weaning.

After the third week, cell increment to the glandular tissue can be accounted for by the mitotic activity of the gland cells. After the fourth week there is a marked fall in the daily percentage cell increment, which continues thereafter at a slowly declining rate and by 77 days is reduced to approximately 0.7%. In consequence, the glandular mass continues to increase slowly, long after the body weight has ceased to show a significant increment. Although new cells are formed in older animals, there is evidence that their cell cycle is longer than in younger animals, whereas the cycle of the crypt cells is unchanged.

Many features of the postnatal growth pattern found in the present investigation on Brunner's glands are comparable with those reported for other tissues. Both Schneyer & Hall (1969) and Redman & Sreebny (1970), in studies of the rat parotid gland, likewise found extensive proliferative activity during the first three postnatal weeks, after which mitotic activity declined markedly. Regarding the postnatal increase in cell population, estimated in longitudinal sections, Brunner's glands showed a tenfold increase between 7 and 77 days of age, a magnitude of increase which lies between that of the kidney ($\times 6.5$) and the pancreas ($\times 18.2$) (Leblond, 1964).

A special feature of postnatal development in Brunner's glands concerns cell size. In other tissues, such as cardiac muscle (Petersen & Baserga, 1965), striated muscle (Enesco & Leblond, 1962) and parotid gland (Schneyer & Hall, 1969; Redman & Sreebny, 1970), increase in cell size is a feature of postnatal growth and development: the cells of Brunner's glands in neonatal mice, however, do not differ significantly in size from those of adults.

A finding of particular interest in this investigation is that these glands continue to expand in adult life by cell replication. As pointed out by Redman & Sreebny (1970), who found in their light and electron microscope study of the developing parotid gland that cells undergoing division at all postnatal stages possess a similar degree of differentiation to that of their neighbours, there is now a growing body of evidence in support of the view of Leblond (1964) that, in expanding cell populations, *mature* cells continue to divide until the particular population reaches its definitive size.

SUMMARY

In the newborn mouse the glands of Brunner consist of a few tubular downgrowths from the proximal duodenal crypts. Within three weeks the characteristic 'comma' shape of the gland is established by later downgrowths from more distal crypts, accompanied by elongation and branching of the proximal tubular downgrowths.

The gland cells, although specialized from birth, show a high mitotic index, and a high labelling index with $^3\text{H-T}$, during the first three weeks, and particularly during the first two weeks. Nevertheless, the daily mitotic rate during this period is

insufficient to account for the daily addition of glandular cells, suggesting that there is a continuing contribution of cells from the crypts. After this time, however, the mitotic activity of the mature gland cells is sufficient to account for the continuing increase in cell population.

After the fourth postnatal week the mitotic and labelling indices decline markedly, and although mitoses are rarely seen in individual sections from older animals, cellular addition at a very slow rate is sufficient to account for the gradual expansion in size of the gland, and the process continues long after the adult body weight has been established.

We are grateful to the World Health Organization for the Research Fellowship awarded to A. A. Obuoforibo, and to the College of Medicine, University of Lagos for granting study leave to undertake this investigation, which was carried out in partial fulfilment for the degree of Doctor of Philosophy.

We should also like to express our thanks to Professor R. Barer for providing facilities in his department, to Mrs Maureen Hollingsworth and Mrs Janet Parker for their assistance with the photography, and to Mrs Ann Dyhouse for typing the manuscript.

REFERENCES

- BENSLEY, R. R. (1903). The structure of the glands of Brunner. *University of Chicago Dicennial Publication*, Series 10, 277-329.
- BRAND, E. (1877). Beitrage zur Entwicklung der Magen- und Darmwand. *Verhandlungen der Physikalisch-medizinischen Gesellschaft zur Würzburg* 9, 243-256.
- BRODY, S. (1945). *Bioenergetics and Growth*. New York: Reinhold.
- BRUNNER, J. C. (1688). De glandulis in intestino duodeno hominis detectis. (Dissertation) Heidelbergae. (Quoted by Landboe-Christensen.)
- BRUNNER, J. C. (1715). Glandulae duodeni seu pancreas secundarium in intestino duodeno hominis primum abhinc in aliis quoque animalibus detectum. Heidelbergae. (Quoted by Landboe-Christensen.)
- CARLETON, A. (1935). The distribution of Brunner's glands in the duodenum of mammals. *Proceedings of the Zoological Society of London* 1, 385-390.
- COCHRANE, W. D., DAVIES, D. V., PALFREY, A. J. & STOCKWELL, R. A. (1964). The histochemistry and electron microscopy of Brunner's glands in the guinea pig. *Journal of Anatomy* 98, 1-10.
- DOBSON, JESSIE (1962). *Anatomical Eponyms*, 2nd edn. London: E. & S. Livingstone.
- ELIAS, H. (1947). Comparison of duodenal glands in domestic animals. *American Journal of Veterinary Research* 8, 311-313.
- ENESCO, M. & LEBLOND, C. P. (1962). Increase in cell number as a factor in the growth of the organs and tissues of the young male rat. *Journal of Embryology and Experimental Morphology* 10, 530-562.
- FLOREY, H. W. & HARDING, H. E. (1934). Further observations on the secretions of Brunner's glands. *Journal of Pathology and Bacteriology* 39, 255-276.
- FLOREY, H. W. (1955). Mucin and the protection of the body. *Proceedings of the Royal Society, Series B*, 143, 147-158.
- FRIEND, D. S. (1965). The fine structure of Brunner's glands in the mouse. *Journal of Cell Biology* 25, 563-576.
- GROSSMAN, M. I. (1958). The glands of Brunner. *Physiological Reviews* 38, 675-690.
- HERBST, J. J. & SUNSHINE, P. (1969). Postnatal development of the small intestine of the rat. *Pediatric Research* 3, 27-33.
- JENNINGS, M. A. & FLOREY, H. W. (1956). Autoradiographic observations on the mucous cells of the stomach and intestine. *Quarterly Journal of Experimental Physiology* 41, 131-152.
- JOHNSON, F. P. (1910). The development of the mucous membrane of the oesophagus, stomach and small intestine in the human. *American Journal of Anatomy* 10, 521-561.
- KRAUSE, W. J. & LEESON, C. R. (1967). The origin, development and differentiation of Brunner's glands in the rat. *Journal of Anatomy* 101, 309-320.
- KRAUSE, W. J. & LEESON, C. R. (1969a). Studies of Brunner's glands in the opossum. I. Adult morphology. *American Journal of Anatomy* 126, 255-274.
- KRAUSE, W. J. & LEESON, C. R. (1969b). Studies of Brunner's glands in the opossum. II. Postnatal development. *American Journal of Anatomy* 126, 275-290.
- KRAUSE, W. J. (1970). Brunner's glands of the echidna. *Anatomical Record* 167, 473-488.

- KRAUSE, W. J. (1971). Brunner's glands of the duck-billed platypus (*Ornithorhynchus anatinus*). *American Journal of Anatomy* **132**, 147-166.
- KRAUSE, W. J. (1973). Morphological and histochemical features of the duodenal glands in six marsupial species. *Journal of Morphology* **140**, 321-342.
- LANDBOE-CRISTENSEN, E. (1944). The duodenal glands of Brunner in man, their distribution and quantity. *Acta pathologica et microbiologica scandinavica*, Suppl. **52**, 1-267.
- LEBLOND, C. P. (1964). Classification of cell populations on the basis of their proliferative behaviour. *National Cancer Institute Monographs* **14**, 119-145.
- LEESON, C. R. & LEESON, T. S. (1966). The fine structure of Brunner's glands in the rat. *Anatomical Record* **156**, 253-267.
- LEESON, T. S. & LEESON, C. R. (1968). The fine structure of Brunner's glands in man. *Journal of Anatomy* **103**, 263-276.
- MANN, V. A., SASSE, D. & GRAUMANN, W. (1967). Beitrage zur Funktionsentwicklung duodenal Drüsen beim Goldhamster. *Acta histochemica* **28**, 89-99.
- MARTIN, B. F. (1954). Serous cells in Brunner's glands of the rabbit. *Nature* **174**, 1195.
- MARTIN, B. F. (1956). The histochemical distribution of 'lipase' in the alimentary tract and associated glands of laboratory animals. *Journal of Anatomy* **90**, 440-454.
- MIDDELDORPF, A. T. (1846). *Disquisitio de glandulis Brunnianis, Vratislaviae*. (Quoted by Landboe-Christensen.)
- MOE, H. (1952). On the histochemical demonstration of alkaline glycerophosphatase and its dependence on the incubation time. *Anatomical Record* **112**, 217-236.
- MOE, H. (1960). The ultrastructure of Brunner's glands of the cat. *Journal of Ultrastructure Research* **4**, 58-72.
- OBUOFORIBO, A. A. (1972). Studies on Brunner's glands of the mouse. Ph.D. Thesis. University of Sheffield.
- OBUOFORIBO, A. A. (1975). Mucosubstances in Brunner's glands of the mouse. *Journal of Anatomy* **119**, 287-294.
- PATZELT, V. (1936). Der Darm. In von Möllendorff's *Handbuch der mikroskopischen Anatomie des Menschen* **5**, part 3, p. 172. Berlin: Springer.
- PETERSEN, R. O. & BASERGA, R. (1965). Nucleic acid and protein synthesis in cardiac muscle of growing and adult mice. *Experimental Cell Research* **40**, 340-352.
- REDMAN, R. S. & SREEBNY, L. M. (1970). Proliferative behaviour of differentiating cells in the developing rat parotid gland. *Journal of Cell Biology* **46**, 81-87.
- SCHNEYER, C. A. & HALL, H. D. (1969). Growth pattern of postnatally developing rat parotid gland. *Proceedings of the Society for Experimental Biology and Medicine* **130**, 603-607.
- THRASHER, J. D. (1966). Analysis of renewing epithelial cell populations. In *Methods in Cell Physiology* **11**, 323-357. New York: Academic Press.
- WEPFER, J. J. (1679). *Cicutae aquaticae historia et noxae*. Basileae. (Quoted by Landboe-Christensen.)
- WOLFF, H. (1961). Entwicklungsgeschichtliche, histochemische und experimentelle Untersuchungen an der Brunnerschen Drüsen des Kaninchens. *Zeitschrift für Zellforschung und mikroskopische Anatomie* **53**, 829-856.