

A study of mammalian intrafusal muscle fibres using a combined histochemical and ultrastructural technique

R. W. BANKS, D. W. HARKER AND M. J. STACEY

*Department of Zoology, University of Durham, South Road,
Durham, DH1 3LE*

(Accepted 8 June 1976)

INTRODUCTION

The presence of two types of nuclear-bag muscle fibre in mammalian muscle spindles is suggested by recent evidence from histochemical and ultrastructural studies, reviewed by Barker (1974). However, some doubt remains as to the exact properties of the nuclear-bag fibre population, since the various techniques used in these studies have not been applied to the same spindle (Barker & Laporte, 1975).

In this study we have established the histochemical profiles of intrafusal muscle fibres from various hind limb muscles of the cat, rabbit and rat and correlated these with the ultrastructure of the same fibres. The technique involved the collection of groups of serial frozen sections for histochemistry, alternating with single, much thicker sections for electron microscopy.

Preliminary observations (Banks, Barker, Harker & Stacey, 1975) have shown that two types of nuclear-bag fibre occur in the spindles of all the muscles studied, usually one of each type. These have been designated 'bag₁' and 'bag₂' on the basis of their ATPase staining reactions, following the nomenclature of Ovalle & Smith (1972). Variations in histochemical profile along the length of individual intrafusal muscle fibres were found, and the bag fibres also showed regional differences in ultrastructure.

MATERIALS AND METHODS

Material was obtained from the tenuissimus (TEN), peroneus longus (PL) and peroneus digiti quinti (PDQ) muscles of an adult cat and an adult rabbit, and from the PL, PDQ and soleus (SOL) muscles of an adult rat.

Thirty four spindles were examined, all of the spindles being incomplete to a greater or lesser extent. The sample was distributed as follows: cat, 6 spindles (2 TEN, 2 PL, 2 PDQ), mean number of intrafusal fibres 6·8 (range 6–8); rabbit, 13 spindles (2 TEN, 1 PL, 10 PDQ), mean number of intrafusal fibres 4·4 (range 4–5); rat, 15 spindles (5 SOL, 6 PL, 4 PDQ), mean number of intrafusal fibres 4·1 (range 3–6).

The muscles were removed immediately post mortem and frozen in isopentane cooled to -160°C with liquid nitrogen. Serial frozen sections were cut on a cryostat from portions of each muscle. Groups of about ten $15\ \mu\text{m}$ thick sections for the application of histochemical techniques were collected alternately with single $60\ \mu\text{m}$

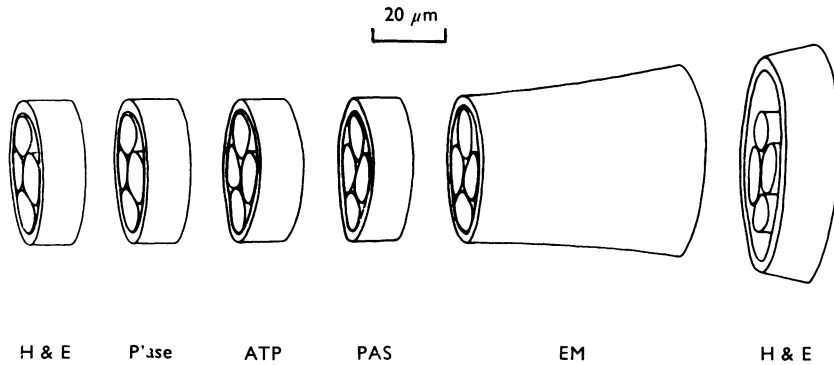


Fig. 1. Diagrammatic illustration of the sectioning technique. Groups of 15 μm thick sections were cut for histological and histochemical processing. The histological sections were stained with haematoxylin and eosin (H & E) to monitor the progress of sectioning. The histochemical sections were processed for (i) phosphorylase (P'ase), (ii) ATPase after alkaline preincubation (ATP), (iii) periodic acid-Schiff (PAS). Alternating with these sections a 60 μm thick section was cut for electron microscopy (EM).

thick sections for ultrastructural study (Pierobon Bormioli & Schiaffino, 1974) as shown in Figure 1.

Histochemistry

The histochemical profiles of the intrafusal muscle fibres were established using three staining techniques: myofibrillar ATPase following alkaline pre-incubation (Guth & Samaha, 1970); phosphorylase (Eränkö & Palkama, 1961); and glycogen as shown by the PAS technique.

In addition some sections from each group of 15 μm thick sections were stained with haematoxylin and eosin in order to follow the progress of sectioning.

Electron microscopy

Each 60 μm thick frozen section was fixed for 18 hours in 5% glutaraldehyde in 0.1 M sodium cacodylate buffered at pH 7.2. The sections were washed in the buffer solution, post-fixed for 2 hours in 1% osmium tetroxide buffered at pH 7.2 in 0.1 M sodium cacodylate, washed in buffer, dehydrated through a graded series of ethanols, immersed in propylene oxide and finally embedded in Epon.

Sections were cut on an LKB Ultratome or a Reichert OMU3, stained with uranyl acetate and lead citrate and examined with an AEI EM801 electron microscope at an accelerating voltage of 80 kV.

Reconstructions

Several spindles were reconstructed diagrammatically using data obtained from the histochemically stained sections. Cross sectional areas of intrafusal fibres were measured on calibrated micrographs using a planimeter. From each of these values the diameter of a circle having the same area was calculated and the diameters thus obtained were plotted against the positions of the corresponding sections.

Table 1. *Histochemical staining reactions in three regions of intrafusal muscle fibres classified into bag₁, bag₂ and chain types*

(Values are average numbers of points awarded on a scale 0 (absent), 1 (low), 2 (medium), 3 (high). The number of regions sampled is given in parentheses after each value.)

	A	B	C
ATPase			
Rabbit			
Bag ₁	0.7	1.0	1.4 (12)
Bag ₂	1.9 } (17)	2.9 } (19)	2.8 } (13)
Chain	2.5	3.0	2.7
Rat			
Bag ₁	1.3	1.1	1.7 (6)
Bag ₂	2.7 } (9)	2.7 } (19)	2.6 (5)
Chain	2.7	2.9	3.0 (2)
Cat			
Bag ₁	1.0	1.0	1.3
Bag ₂	1.8 } (6)	2.0 } (7)	1.7 } (3)
Chain	2.8	3.0	2.7
P'ase			
Rabbit			
Bag ₁	0.9	1.3	2.0 (13)
Bag ₂	1.6 } (16)	2.1 } (19)	2.0 } (14)
Chain	1.9	3.0	2.9
Rat			
Bag ₁	1.4	2.1	2.1 } (10)
Bag ₂	1.4 } (18)	1.8 } (17)	1.6 } (5)
Chain	1.5	3.0	2.6
Cat			
Bag ₁	1.4	1.8	1.7
Bag ₂	1.6 } (5)	1.8 } (5)	2.0 } (3)
Chain	1.8	3.0	3.0
PAS			
Rabbit			
Bag ₁	1.2	2.2	2.1 } (11)
Bag ₂	1.0 } (16)	1.4 } (17)	1.2 } (11)
Chain	1.2	2.9	2.9 (10)
Rat			
Bag ₁	1.7	1.9	2.3 } (3)
Bag ₂	1.9 } (7)	1.5 } (13)	1.7 } (3)
Chain	1.7	1.9	2.0 (1)
Cat			
Bag ₁	1.0	1.3	1.7
Bag ₂	1.7 } (3)	1.5 } (6)	1.7 } (3)
Chain	2.0	3.0	3.0

RESULTS

Histochemistry

In order to facilitate the description of regional variations the muscle spindle was considered as comprising three regions arbitrarily defined by the equatorial nucleation and by the condition of the capsule, namely A, the level from the equator to the equatorial end of the periaxial space; B, that part of the polar region enclosed by the

capsule; C, the extracapsular part of the polar region. Some results from regions A and B have been reported previously (Banks *et al.* 1975). Each section was assigned to its appropriate region and the staining intensities of the intrafusal fibres were estimated on a scale of 0 (absent), 1 (low), 2 (medium), and 3 (high). This is similar to the grading system used before (Banks *et al.* 1975) of 0, +, ++ and +++, but has the advantage that the results from a number of spindles can be easily pooled, thus taking account of any variations without making the presentation of results too cumbersome.

In every spindle examined two types of nuclear-bag fibre (one of each type) were distinguished, whereas the nuclear-chain fibres, usually more than one per spindle, formed a homogeneous group.

The histochemical profiles of muscle spindles from different muscles of the same animal did not show any consistent differences and the results for each region from all the muscles were therefore combined. The results for each of the three species are given in detail in Table 1.

Comparison of the results from different species showed that the ATPase staining reactions were the most consistent. The nuclear-bag fibres were therefore classified on the basis of this reaction as bag₁ fibres (those with relatively low ATPase activity) and bag₂ fibres (those with relatively high ATPase activity) (Ovalle & Smith, 1972).

The following general observations apply to all three species unless otherwise stated. In each type of intrafusal fibre the staining intensities produced by each histochemical method vary along the length of the fibre. Staining intensities in region A are usually lower than those of the polar regions B and C.

With the ATPase method, in rabbit and rat spindles, bag₂ fibres are indistinguishable from chains over most of their lengths (Fig. 3). In cat spindles bag fibres almost always show a lower ATPase intensity than chains (Fig. 11). In all three species the differences between the ATPase intensities of bag₁ and bag₂ are most marked in regions A and B. The greater similarity in region C is due mainly to increase in the intensities of bag₁ fibres.

With the phosphorylase reaction, differences between the three types of intrafusal fibre were most marked in rabbit spindles (Fig. 2). Bag₁ and bag₂ fibres were not clearly differentiated in rat and cat spindles with this method. Nuclear-chain fibres usually stained purple and nuclear-bag fibres brown, indicating that nuclear-bag fibres possess a branching enzyme not present in nuclear-chain fibres (Swanson, 1948).

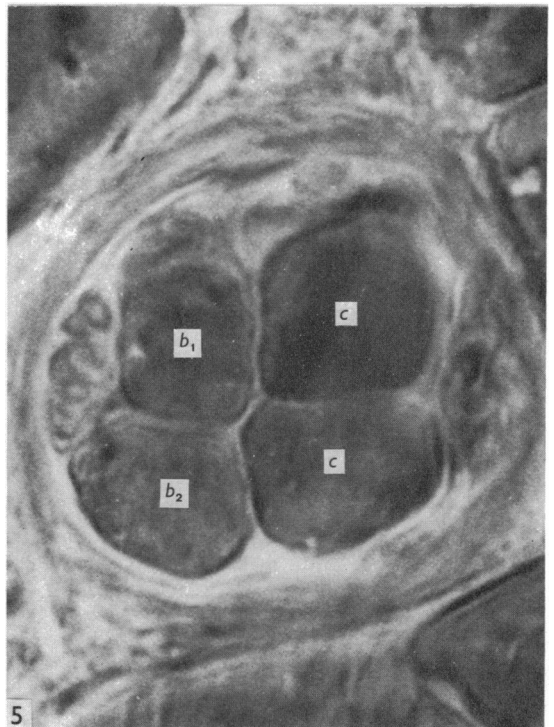
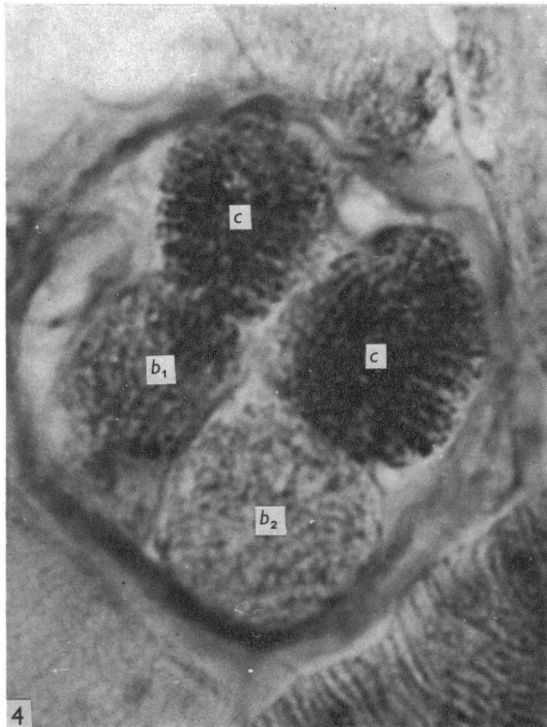
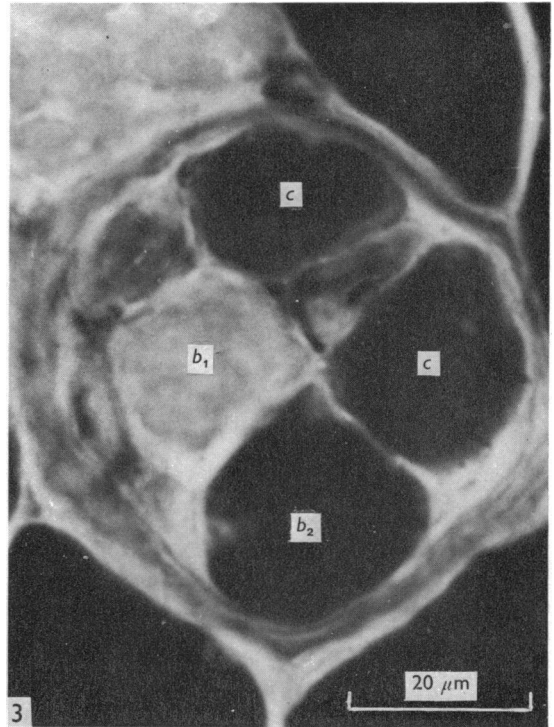
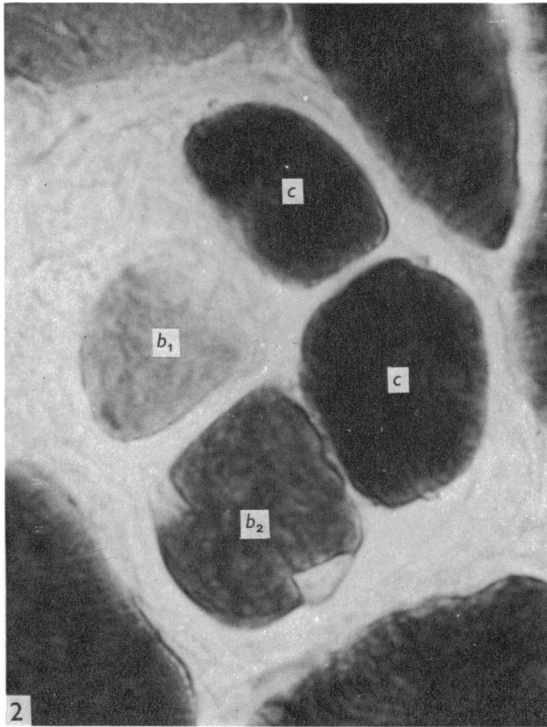
Figs. 2–5. Photomicrographs of a series of closely adjacent transverse sections through region B of a rabbit tenuissimus spindle. These should be compared with the diagrammatic illustration of the sectioning technique shown in Fig. 1. Note the relatively large diameters of the chain fibres.

Fig. 2. Phosphorylase staining intensity of the bag₁ fibre (*b*₁) is low, of the bag₂ fibre (*b*₂) is medium and of the chains (*c*) is high.

Fig. 3. Staining intensity of myofibrillar ATPase following alkaline preincubation is low in bag₁ and high in bag₂ and chains.

Fig. 4. PAS staining intensity of the bag₁ fibre is medium, of the bag₂ fibre is low and of the chains is high.

Fig. 5. A 60 μm thick section embedded in Epon showing the intrafusal fibres identified from the adjacent histochemically stained sections.



In rabbit and rat spindles bag₂ fibres usually contained less glycogen than bag₁ fibres (Fig. 4), the difference being more apparent in rabbit spindles. In rabbit and cat spindles the chain fibres contained more glycogen than either bag₁ or bag₂ fibres.

Electron microscopy

Comparison of the thick, Epon-embedded sections with the adjacent histochemically stained sections enabled each intrafusal fibre in the thick sections to be assigned with certainty to its appropriate fibre type (Fig. 5). Conditions for the preservation of fine structure were not optimal. Membrane systems, particularly sarcoplasmic reticulum, seemed the most susceptible to damage and observations were restricted to regions where these were intact. During fixation contraction could not be opposed and the sarcomeres of intrafusal and extrafusal fibres were greatly shortened. However, the sarcomeres of bag₁ fibres were consistently longer than those of bag₂ fibres, chain fibres and extrafusal fibres (Figs. 6–9; Fig. 10). In all three types of intrafusal fibre the A bands were 1.5 μm wide and the Z lines 75 nm thick, which is comparable to the thickness of the Z lines of extrafusal intermediate fibres of the rat (Schiaffino, Hanzlikova & Pierobon, 1970).

The condition of the M lines provided conspicuous differences between the intrafusal fibre types. Two major conditions were recognized. Firstly, sarcomeres possessed an M line that appeared as a prominent single structure in low power micrographs, but with higher power a substructure of five parallel faint lines was seen. This condition is designated M. The M lines of extrafusal fibres were of this type.

Secondly, sarcomeres possessed an M line consisting of two faint parallel lines. This condition has been designated dM. Sarcomeres in which no M line was visible were included in this type since they always occurred close to sarcomeres possessing faint double M lines (Fig. 8). It is probable that the faint double line is only visible in suitably orientated myofibrils with straight sarcomeres (Ovalle, 1971). Both dM and M conditions were present in different regions of some intrafusal fibres, but the nature of the transition is unknown. Bag₁ fibres (Figs. 6, 8) were of dM type throughout their lengths in rat spindles, whereas in rabbit and cat spindles they were of dM type in the equatorial region and much of the polar region, but M type in region C. Bag₂ fibres were always of dM type in the equatorial region and M type in the poles (Figs. 7, 9). The transition region corresponded approximately with the level A/B

Figs. 6–9. Electron micrographs of longitudinal sections of nuclear bag muscle fibres, showing the variation in structure in different regions, Figs. 6–8 illustrate the dM condition and Fig. 9 the M condition (see text).

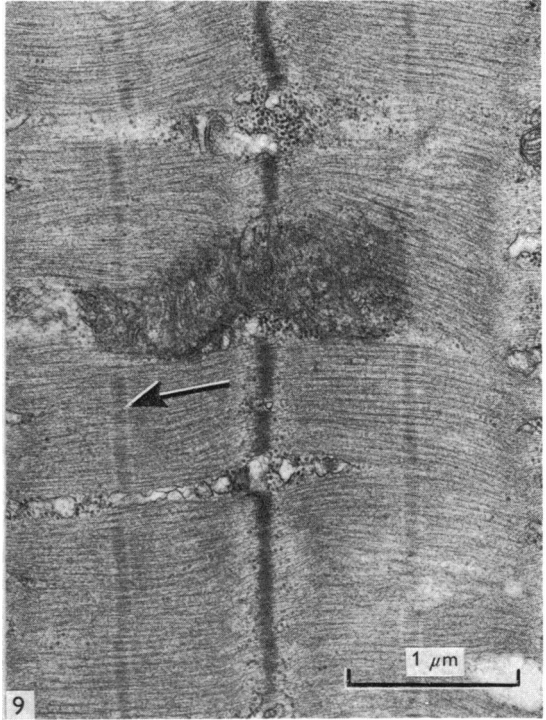
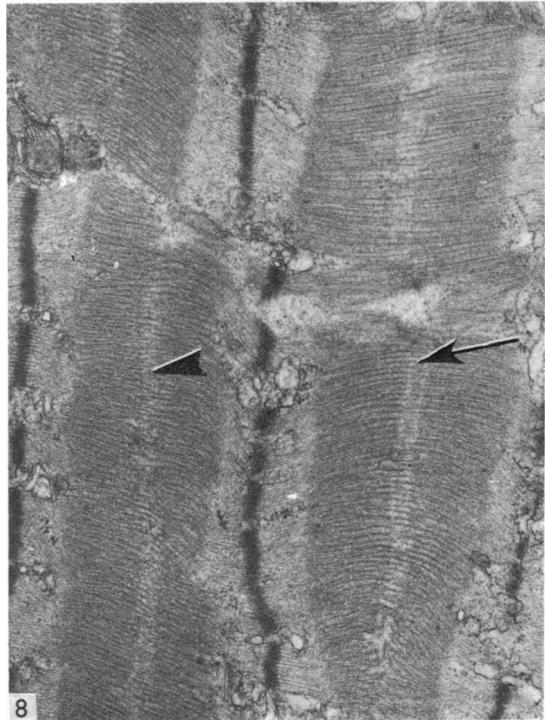
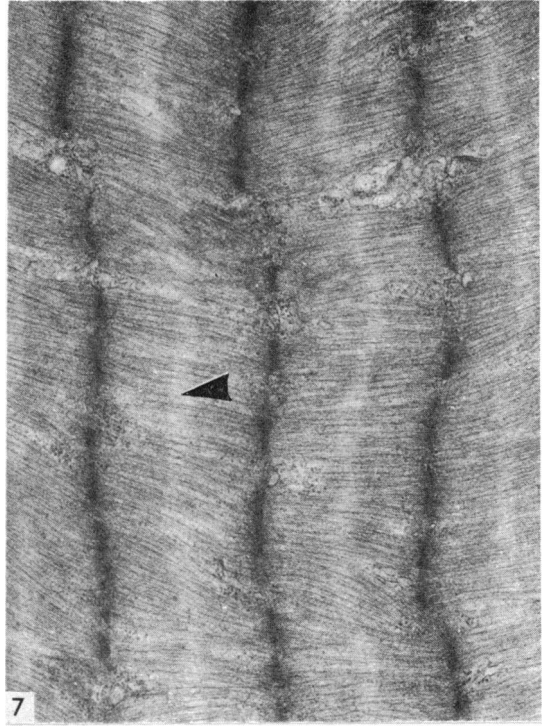
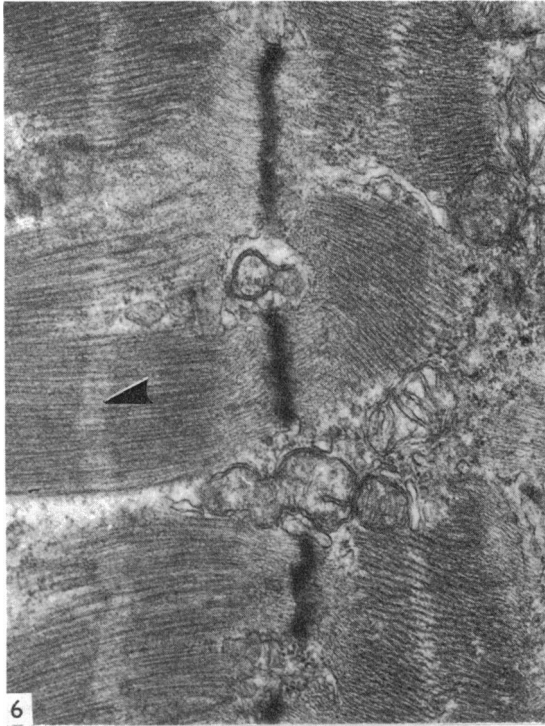
Note the varying degree of shortening of the sarcomeres produced by the fixation technique.

Fig. 6. Rat: b_1 , region A. No M line is visible in the pseudo-H zone (arrowhead).

Fig. 7. Rat: b_2 , region A. As in the b_1 fibre, no M line is present in the pseudo-H zone (arrowhead).

Fig. 8. Cat: b_1 , region B. A double M line is present in some sarcomeres (arrowed) but not in others (arrowhead).

Fig. 9. Cat: b_2 , region B. An M line is present in each sarcomere (arrowed).



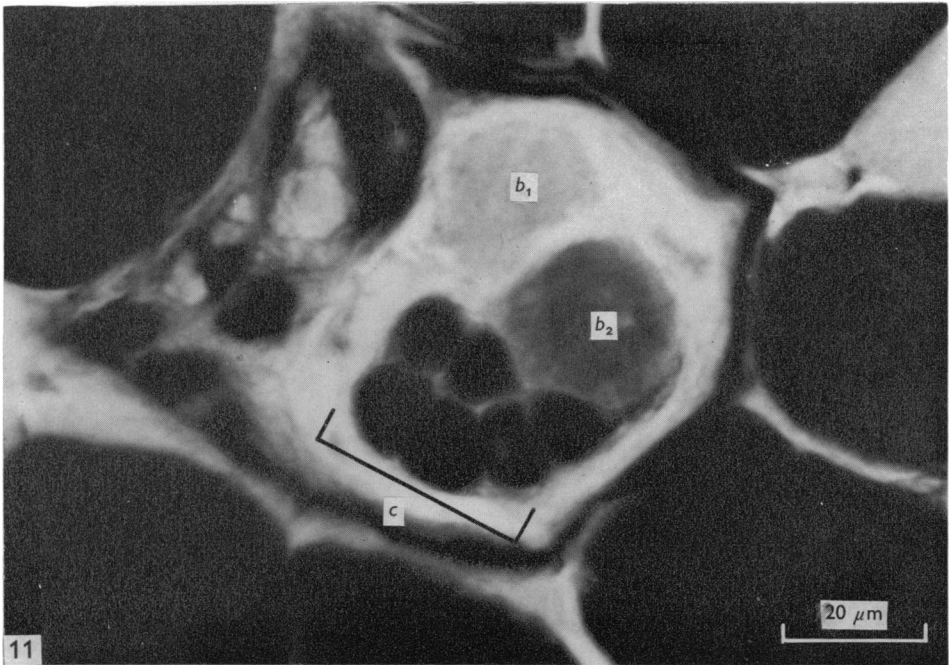
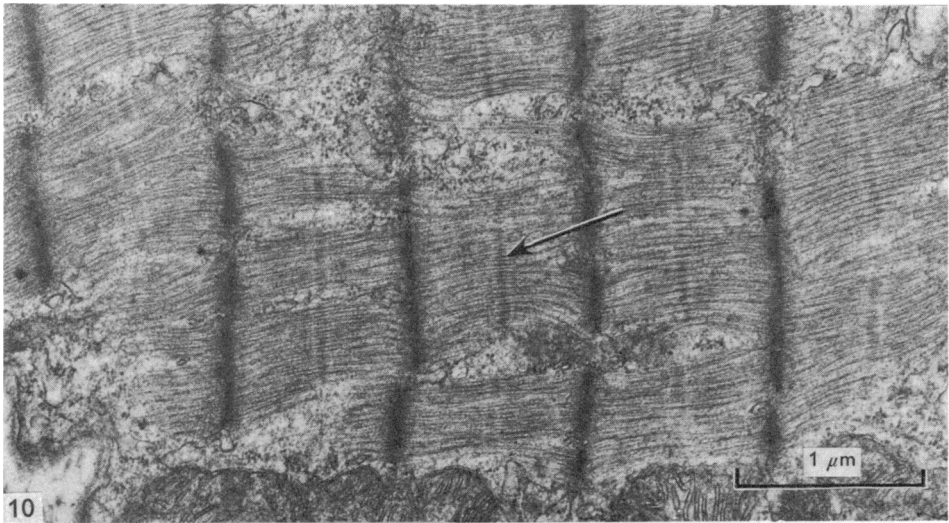


Fig. 10. Electron micrograph of longitudinal section of rat nuclear chain muscle fibre, showing the presence of an M line (arrow).

Fig. 11. Photomicrograph of a transverse section through region A of a cat tenuissimus spindle, showing myofibrillar ATPase staining intensities: b_1 is low; b_2 medium and the chains (c) high. Note that b_2 is closely associated with the chains, whereas b_1 is somewhat dissociated from the other fibres.

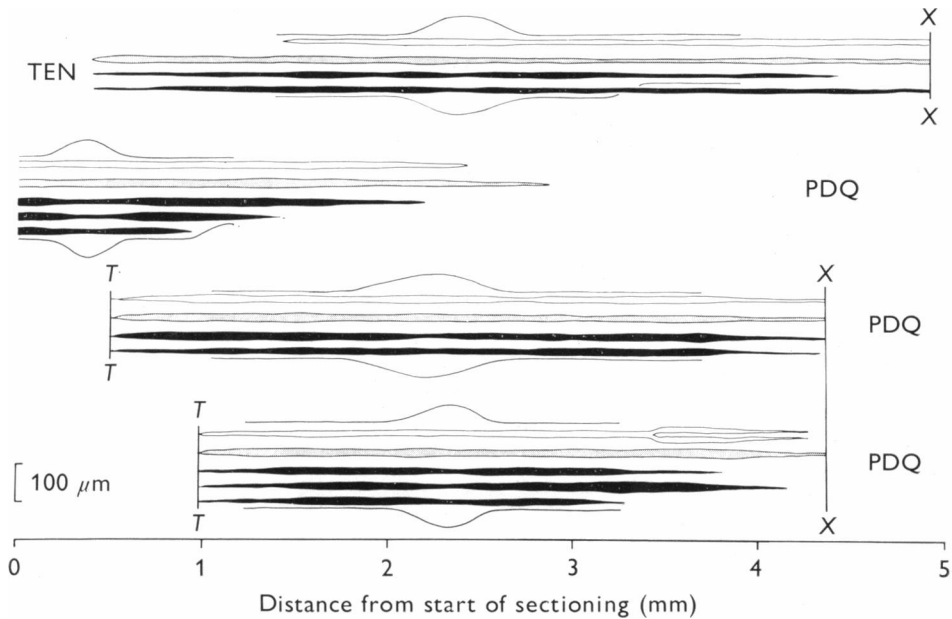


Fig. 12. Reconstructions of four rabbit spindles showing the relative dimensions of bag₁ fibres (white), bag₂ fibres (stippled) and chain fibres (black). Note that the vertical scale is twice the horizontal. PDQ, peroneus digiti quinti; TEN, tenuissimus; T, tendinous insertion of spindle; X, end of sectioning.

division. Chain fibres were of M type throughout the whole of their lengths (Fig. 10). Using this criterion they were, therefore, indistinguishable from bag₂ fibres in the spindle poles.

Reconstructions

Rabbit and rat spindles reconstructed as described above are shown in Figs. 12 and 13. The diameter measurements used to prepare the reconstructions are summarized in Table 2.

Bag₁ and bag₂ fibres are usually about the same length, but bag₂ fibres are only of significantly greater diameter than bag₁ fibres in the rat. Chain fibres are usually shorter than bag₁ or bag₂ fibres and are usually of significantly smaller diameter. In the polar regions, however, the diameters of bag₁ fibres and chain fibres are not significantly different (Figs. 2–5). Similar results have been obtained for rabbit spindle poles by Banks & James (1975). All types of intrafusal fibre taper over long distances of the polar regions before ending. This has the effect that the mean polar diameters are usually smaller than the corresponding mean equatorial diameters, despite the fact that the maximum diameters are often found in the poles. This is particularly apparent in rabbit chain fibres.

In the equatorial regions of cat spindles the chain fibres are often closely associated with the bag₂ fibres whereas bag₁ fibres are clearly separated from the two other types (Fig. 11).




Fig. 13. Reconstructions of four rat spindles. For explanation see Fig. 12. All spindles from PDQ.

DISCUSSION

The present work clearly establishes the presence of three types of intrafusal fibre in mammalian muscle spindles. However, the three types cannot always be differentiated on the basis of any single technique, whether morphological, histochemical or ultrastructural. Application of any one technique to the muscle spindle usually results in the inclusion of two of the types within a single group. It is perhaps for this reason that the view that there are only two types of intrafusal fibre has persisted for so long (Matthews, 1972). The implications of the new classification are far-reaching and earlier results may need to be re-interpreted, particularly with regard to the innervation of the muscle spindle.

Previous attempts to correlate the histochemical and ultrastructural properties of intrafusal fibres have all involved certain assumptions since the different techniques have been applied to different spindles. It is clear that in many cases the assumptions made were incorrect, so that ultrastructural and morphological properties were sometimes ascribed to the wrong histochemical type. In the present work no such assumptions have been necessary. Earlier classifications of intrafusal fibres and attempts to correlate their histochemical and ultrastructural properties are summarized in Table 3 and are compared with the present classification.

Table 2. Mean diameters (\pm standard error of the mean) of intrafusal muscle fibres from the equators and poles of rabbit and rat muscle spindles(All measurements in μm . Values of P for the null hypotheses (mean diameter fibre x) = (mean diameter fibre y) are given.)

	Equator	Pole
RABBIT		
Bag ₁	18.0 \pm 0.62	15.1 \pm 0.42
Bag ₂	18.6 \pm 0.75	16.7 \pm 0.54
Chain	14.5 \pm 0.40	14.4 \pm 0.48
Ho	P	P
Bag ₁ = bag ₂	N.S.	N.S.
Bag ₁ = chain	< 0.001	N.S.
Bag ₂ = chain	< 0.001	< 0.01
RAT		
Bag ₁	12.3 \pm 0.56	11.3 \pm 0.59
Bag ₂	18.7 \pm 2.30	14.4 \pm 0.69
Chain	9.1 \pm 0.61	9.4 \pm 0.38
Ho	P	P
Bag ₁ = bag ₂	< 0.05	< 0.01
Bag ₁ = chain	< 0.01	N.S.
Bag ₂ = chain	< 0.01	< 0.001

It is possible that those classifications which involve more than three types of fibre have arisen because of the occurrence of regional variations in intrafusal fibres. Variations in both histochemical and ultrastructural properties of intrafusal fibres are clear from the present work. Also Yellin (1974) has noted variations in ATPase activity and Banker & Girvin (1971) found that nuclear-bag fibres, which had M lines in the polar regions, lost them in the equatorial region. Other changes in the contractile apparatus reported by Banker & Girvin (1971) have not been seen in this work. Harriman, Parker & Elliott (1975) have found acid-stable ATPase activity restricted to the polar regions of nuclear-chain fibres, but present throughout one type of nuclear-bag fibre in human spindles.

In addition to those listed in Table 3, several authors have described more than two types of intrafusal fibre. The evidence was histochemical (Ogata & Mori, 1962, 1964, mouse, rat, cat and human spindles; Wirsen & Larsson, 1964, mouse spindles; James, 1971*b*, rat and guinea-pig spindles) and morphological (Cuajunco, 1927, 1940, pig and human spindles; Barker & Gidumal, 1961, cat spindles; Ogata & Mori, 1962, 1964; James, 1971*b*; Maynard & Tipton, 1971, rat spindles). Also Banks & James (1973) described three types of intrafusal fibre from guinea-pig lumbrical spindles on the basis of their diameters and ultrastructure in the equatorial region. There was a large fibre of type dM and two types of small fibre, one of type dM and one of type M. On the basis of the present work, these may be equated with bag₂, bag₁, and chain types respectively. It is interesting that the equivalent of the bag₂ and bag₁ fibre types described by Banks & James (1973) did not possess a well-developed nuclear bag.

Table 3. *Classifications of intrafusal muscle fibre types compared with the present classification*

Author, type of study and experimental animal	Original classification	Probable equivalent
Boyd (1962), morphology, cat	Nuclear bag	} Bag ₁
	Nuclear chain	{ Bag ₂ Chain
Yellin (1969), histochemistry, rat	A	Bag ₂
	B	Bag ₁
	C	Chain
	(One other type)	Bag ₁
Barker & Stacey (1970), histochemistry and morphology, rabbit	Nuclear bag	Bag ₂
	Nuclear chain	Chain
	Intermediate	Bag ₁
	EM	Bag ₁
Barker, Harker, Stacey & Smith (1972), histochemistry and EM, rabbit	Nuclear bag	Bag ₁
	Nuclear chain	Chain
	Intermediate	Bag ₂
	Morphology	Bag ₂
James (1971 <i>a</i>), histochemistry, rat; Banks (1971), histochemistry, rabbit	Nuclear bag	Chain
	Nuclear chain	Bag ₂
	Intermediate	Bag ₁
	EM	Bag ₁
Ovalle & Smith (1972), histochemistry, monkey and cat	Nuclear bag	Bag ₂
	Nuclear chain	Bag ₂
	Intermediate	Chain
Milburn (1973), histochemistry and morphology rat	Typical bag	Bag ₂
	Intermediate bag	Bag ₁
	Chain	Chain
	EM	Chain
Arendt & Asmussen (1974), histochemistry, rat, rabbit, cat, guinea-pig	Typical bag	Bag ₁
	Intermediate bag	Bag ₂
	Chain	Chain
	1 }	Bag ₁
	2 }	
	3 }	Bag ₂
4 }		
5 }	Chain	
6 }		
Banks & James (1975), histochemistry, EM and morphology, rabbit	1	Chain
	2	Bag ₂
	3	Bag ₁

The two types of ultrastructure present in intrafusal fibres have been described by a number of workers (see Barker, 1974, for review). Nuclear-bag fibres have usually been correlated with the dM type and nuclear-chain fibres with the M type. It is clear from the present work that this is only true in the equatorial region and that in the polar regions the bag fibres change from dM to M except the rat bag₁ fibre. Banks & James (1975) have shown that in the polar regions of rabbit spindles the dM type

(i.e. bag₁) contains a significantly smaller volume proportion of mitochondria than the M type. No attempt was made to subdivide the M type into bag₂ and chain fibres.

The three types of intrafusal fibre have been found to arise sequentially during development in the order bag₂, bag₁, chain (Milburn, 1973 and personal communication). Bag₁ and chain fibres each develop in association with the older bag₂ fibre and separate from this fibre after the fusion of their constituent myoblasts. In the equatorial region of adult cat spindles the chains often continue to be quite closely associated with bag₂. The development of intrafusal fibres involving three generations of myotubes is very similar to the pattern of extrafusal development (Milburn, 1973), as is strikingly suggested by comparison of the neonatal cat spindle (Scalzi & Price, 1971, Fig. 11) with developing rat extrafusal fibres (Kelly & Schotland, 1972, Fig. 3).

SUMMARY

A direct correlation of the histochemical and ultrastructural properties of intrafusal muscle fibres has been achieved by cutting frozen serial sections for histochemical applications (15 μm thick sections) and for electron microscopy (60 μm thick sections) in a repeating sequence.

Three types of intrafusal fibre were recognized, including two types of nuclear-bag fibre, designated bag₁ and bag₂. In addition to histochemical and ultrastructural differences, the three types of fibre differed in length and diameter. Regional variations of histochemical and ultrastructural properties were found.

The results are compared with previous attempts to correlate histochemical and ultrastructural properties of intrafusal muscle fibres based on indirect methods.

The authors wish to thank Professor D. Barker and Dr Alice Milburn for helpful discussions during the preparation of this paper. The work was supported by a grant from the Medical Research Council.

REFERENCES

- ARENDRT, K. W. & ASMUSSEN, G. (1974). Enzymhistochemische Untersuchungen an Muskelspindel verschiedener Species. *Anatomischer Anzeiger* **136**, 217–228.
- BANKER, B. Q. & GIRVIN, J. P. (1971). The ultrastructural features of the mammalian muscle spindle. *Journal of Neuropathology and Experimental Neurology* **30**, 155–195.
- BANKS, R. W. (1971). Histochemical studies on rabbit intrafusal fibres. *Journal of Anatomy* **108**, 613–614.
- BANKS, R. W., BARKER, D., HARKER, D. W. & STACEY, M. J. (1975). Correlation between ultrastructure and histochemistry of mammalian intrafusal muscle fibres. *Journal of Physiology* **252**, 16–17 P.
- BANKS, R. W. & JAMES, N. T. (1973). The fine structure of the guinea pig muscle spindle. *Zeitschrift für Zellforschung und mikroskopische Anatomie* **140**, 357–368.
- BANKS, R. W. & JAMES, N. T. (1975). Rabbit intrafusal muscle fibres. *Journal of Anatomy* **119**, 193.
- BARKER, D. (1974). The morphology of muscle receptors. In *Handbook of Sensory Physiology*, vol. III/2 (ed. C. C. Hunt), pp. 1–190. Berlin, Heidelberg, New York: Springer.
- BARKER, D. & GIDUMAL, J. L. (1961). The morphology of intrafusal muscle fibres in the cat. *Journal of Physiology* **157**, 513–528.
- BARKER, D., HARKER, D. W., STACEY, M. J. & SMITH, C. R. (1972). Fusimotor innervation. In *Research in Muscle Development and the Muscle Spindle* (ed. B. Q. Banker, R. J. Przybylski, J. P. Van der Meulen and M. Victor), pp. 227–250. Amsterdam: Excerpta Medica.
- BARKER, D. & LAPORTE, Y. (1975). Introduction to Symposium on Muscle Spindles. *Journal of Anatomy* **119**, 183–185.

- BARKER, D. & STACEY, M. J. (1970). Rabbit intrafusal muscle fibres. *Journal of Physiology* **210**, 70–72 P.
- BOYD, I. A. (1962). The structure and innervation of the nuclear bag muscle fibre system and the nuclear chain muscle fibre system in mammalian muscle spindles. *Philosophical Transactions of the Royal Society* **245**, 81–136.
- CUAJUNCO, F. (1927). Embryology of the neuromuscular spindle. *Publications. Carnegie Institute of Washington* **380**, 45–72.
- CUAJUNCO, F. (1940). Development of the neuromuscular spindle in human fetuses. *Publications. Carnegie Institute of Washington*, **518**, 95–128.
- ERANKO, O. & PALKAMA, A. (1961). Improved localization of phosphorylase by the use of polyvinyl pyrrolidone and high substrate concentration. *Journal of Histochemistry and Cytochemistry* **9**, 585.
- GUTH, L. & SAMAHA, F. J. (1970). Procedure for the histochemical demonstration of actomyosin ATPase. *Experimental Neurology* **28**, 365–367.
- HARRIMAN, D. G. F., PARKER, P. L. & ELLIOTT, B. J. (1975). The histochemistry of human intrafusal muscle fibres. *Journal of Anatomy* **119**, 205–206.
- JAMES, N. T. (1971 a). The histochemical demonstration of three types of intrafusal fibre in rat muscle spindles. *Histochemical Journal* **3**, 457–462.
- JAMES, N. T. (1971 b). The histochemical demonstration of myoglobin in muscle spindles. *Histochemical Journal* **3**, 333–338.
- KELLY, A. M. & SCHOTLAND, D. L. (1972). The evolution of the 'checkerboard' in a rat muscle. In *Research in Muscle Development and the Muscle Spindle* (ed. B. Q. Banker, R. J. Przybylski, J. P. van der Meulen and M. Victor, pp. 32–48. Amsterdam: Excerpta Medica.
- MATTHEWS, P. B. C. (1972). *Mammalian Muscle Receptors and Their Central Actions*. London: Arnold.
- MAYNARD, J. A. & TIPTON, C. M. (1971). The effects of exercise training and denervation on the morphology of intrafusal muscle fibres. *Internationale Zeitschrift für angewandte Physiologie einschliesslich Arbeitsphysiologie* **30**, 1–9.
- MILBURN, A. (1973). The early development of muscle spindles in the rat. *Journal of Cell Science* **12**, 175–195.
- OGATA, T. & MORI, M. (1962). Histochemical demonstration of the three types of intrafusal fibres of muscle spindles, a study on oxidative enzymes. *Acta medicae Okayama* **16**, 347–350.
- OGATA, T. & MORI, M. (1964). Histochemical study of oxidative enzymes in vertebrate muscles. *Journal of Histochemistry and Cytochemistry* **12**, 171–182.
- OVALLE, W. K. (1971). Fine structure of rat intrafusal muscle fibres. The polar region. *Journal of Cell Biology* **51**, 83–103.
- OVALLE, W. K. & SMITH, R. S. (1972). Histochemical identification of three types of intrafusal muscle fibres in the cat and monkey based on the myosin ATPase reaction. *Canadian Journal of Physiology and Pharmacology* **50**, 195–202.
- PIEROBON BORMIOLI, S. & SCHIAFFINO, S. (1974). Procedure for selecting specific structures in skeletal muscle tissue for ultrastructural study. *Journal of Submicroscopic Cytology* **6**, 129–130.
- SCALZI, H. A. & PRICE, H. H. (1971). The arrangement and sensory innervation of the intrafusal fibres in the feline muscle spindle. *Journal of Ultrastructure Research* **36**, 375–390.
- SCHIAFFINO, S., HANZLIKOVA, V. & PIEROBON, S. (1970). Relations between structure and function in rat skeletal muscle fibres. *Journal of Cell Biology* **47**, 107–119.
- SWANSON, M. A. (1948). Studies on the structure of polysaccharides. IV. Relation of the iodine colour to the structure. *Journal of Biological Chemistry* **172**, 825–837.
- WIRSEN, C. & LARSSON, K. S. (1964). Histochemical differentiation of skeletal muscle in foetal and newborn mice. *Journal of Embryology and Experimental Morphology* **12**, 759–767.
- YELLIN, H. (1969). A histochemical study of muscle spindles and their relationship to extrafusal fibre types in the rat. *American Journal of Anatomy* **125**, 31–46.
- YELLIN, H. (1974). Regional differences in the contractile apparatus of intrafusal muscle fibres. *American Journal of Anatomy* **139**, 147–152.