

Hypereosinophilic Syndrome in Cats: A Report of Three Cases

S.A. McEwen, V.E.O. Valli and T.J. Hulland*

ABSTRACT

The clinical, clinicopathological and pathological findings in three cats with hypereosinophilic syndrome are described.

The cats chosen for the study had marked eosinophilia and evidence of tissue infiltration by eosinophils. Necropsies were performed on two cats, biopsy and blood samples were provided for the third cat. At necropsy, there was diffuse reddening of femoral bone marrow with ulceration and thickening of the duodenum. The livers had an enhanced lobular pattern with multiple, white, 1-3 mm nodules throughout the parenchyma. One cat had splenomegaly and the other had several enlarged, white, firm lymph nodes. Histopathologically, there was eosinophil infiltration of intestine, lymph nodes, liver, spleen, adrenal medulla and beneath the endocardium. Ultrastructurally, the eosinophils from lymph node and bone marrow of cat II were morphologically normal.

The rigid criteria for eosinophilic leukemia were not fulfilled by these cases and the etiology of the eosinophilia in each case is not known. Possible pathogenic mechanisms are discussed.

Key words: Eosinophils, eosinophilia, hypereosinophilic syndrome, myeloproliferative disease.

infiltration tissulaire par des éosinophiles. Les auteurs effectuèrent la nécropsie de deux de ces chats, tandis qu'ils examinèrent une biopsie et des échantillons de sang du troisième. La nécropsie révéla un aspect rougeâtre diffus de la moelle osseuse fémorale, ainsi qu'un épaississement et des ulcères duodénaux. Les lobules hépatiques affichaient une individualisation plus marquée que normalement, tandis que leur parenchyme arborait plusieurs nodules blanchâtres de 1 à 3 mm de diamètre. Un des chats présentait de la splénomégalie et une autre, une hypertrophie et une plus grande fermeté de plusieurs ganglions lymphatiques. L'histopathologie révéla une infiltration de l'intestin, des ganglions lymphatiques, du foie, de la rate, de la portion médullaire des surrénales et du dessous de l'endocarde par des éosinophiles. La microscopie électronique démontra que les éosinophiles des ganglions lymphatiques et de la moelle osseuse du chat #2 présentaient une morphologie normale. Ces cas ne rencontraient pas les critères rigides de la leucémie éosinophilique, de sorte que l'étiologie de ce syndrome, dont les auteurs commentent la pathogénèse possible, demeure toujours obscure.

Mots clés: éosinophiles, éosinophilie, syndrome d'hyperéosinophilie, maladie myéloproliférative.

infiltration and with unknown etiology.

In animals and man, eosinophilia is associated with allergic diseases (5), parasitic infections (6), some neoplasms (7) and certain autoimmune diseases (5). Animals with HES have prolonged eosinophilia that is not apparently secondary to another disease process.

This study was undertaken to identify the clinical, clinicopathological and pathological findings in three cats with hypereosinophilic syndrome.

MATERIALS AND METHODS

The cats selected for this study had marked eosinophilia ($> 50.0 \times 10^9/L$) with tissue samples available for histopathology and/or electron microscopy.

Venous blood samples for hematological examination were taken in EDTA anticoagulant. The following determinations were made on each sample: white blood cell count (WBC), hemoglobin concentration (Hb), packed cell volume (PCV), white blood cell differential count (Diff.) and total solids (T.S.). Bone marrow was aspirated from the iliac crest in two cases (cats I and II) and air-dried smears were prepared immediately and stained with Wright's stain.

Biopsy and necropsy tissues for light microscopy were fixed in 10% neutral buffered formalin, embedded in paraffin, sectioned at $6 \mu m$ and stained with hematoxylin and eosin (H&E), Masson's trichrome and toluidine blue stains. Tissue for electron microscopy was fixed in 2.5% glutaraldehyde, postfixated in 1.0% osmium tetroxide, embedded in epon and sectioned on a Reichert OMV2 ultramicrotome. One μm sections were stained with a tri-

RÉSUMÉ

Cet article décrit les observations cliniques et pathologiques, relatives à trois chats atteints du syndrome d'hyperéosinophilie. Les sujets choisis pour l'étude présentaient une éosinophilie marquée et l'évidence d'une

INTRODUCTION

The hypereosinophilic syndrome (HES) is a rare condition in cats (1), dogs (2) and man (3,4). It has been defined (4) as a marked ($> 1.1 \times 10^9/L$) and prolonged (> 6 months in man) eosinophilia with evidence of tissue

*Department of Pathology, Ontario Veterinary College, University of Guelph, Guelph, Ontario N1G 2W1.

Submitted July 11, 1984.

chrome stain composed of basic fuchsin, methylene blue and azure II. Ultra thin sections were stained with uranyl-lactate and lead citrate and viewed on a Hitachi HS 9 electron microscope.

Each cat was examined clinically by its referring veterinarian and feces were examined for parasitic ova. In cases II and III, cervical lymph node biopsies were submitted to Veterinary Laboratory Services (VLS) of the Ontario Ministry of Agriculture and Food (OMAF). In case II, three and one half years after the first submission, a second biopsy of a cervical mass and a venous blood sample were submitted to the same laboratory (VLS).

Cats I and II were referred to the Small Animal Clinic, Ontario Veterinary College, for further evaluation. Venous blood samples and bone marrow aspirations were taken. Necropsies were performed on cats I and II and selected tissues were prepared for histopathology. Lymph node and bone marrow samples from cat II were taken at necropsy and prepared for electron microscopy. Cat III died six months after biopsy submission and permission for necropsy was denied. Fluorescent antibody testing (FAT) for feline leukemia virus (FeLV) was performed on peripheral blood smears from cats II and III.

RESULTS

HISTORY AND CLINICAL SIGNS

The pertinent historical and clinical data from the three cats are summarized in Table I.

CLINICAL PATHOLOGY

The hematological findings are presented in Table II. Bone marrow aspirates were taken from cats I and II. In cat I, granulocytic, erythrocytic and thrombocytic cells lines were all present and appeared to be maturing normally. The marrow contained a large increase in the number of eosinophil myelocytes, metamyelocytes, bands and especially segmented eosinophils. A bone marrow differential count was made from cat II and this is summarized in Table III. Fecal examinations for parasitic ova were negative in all three cats.

TABLE I. Historical and Clinical Data of Three Cats with HES

Cat Number:	I	II	III
Breed	DLH ^a	DLH ^a	DSH ^b
Sex	Female	Female	Male
Age at Initial Presentation	9 yrs.	10 mos.	3 yrs.
Duration of Clinical Signs	4 mos.	3.5 yrs. (Int.) ^c	1.5 yrs. (Int.)
Signs:			
anorexia/weight loss	+	+(Int.)	+
pyrexia	+	+(Int.)	-
vomiting/diarrhea	-	+(Int.)	+(Int.)
lymphadenopathy	-	+	+

^aDLH = domestic long hair

^bDSH = domestic short hair

^cInt. = intermittent

TABLE II. Hematological Findings in Three Cats with HES

Cat Number:	I	II	III
Hemoglobin Concentration (g/L)	87	124	76
Packed Cell Volume (L/L)	0.23	0.40	0.25
White Blood Cell Count (x10 ⁹ /L)	120.0	68.4	179.2
White Blood Cell Differential Count (x10 ⁹ /L) ^a			
segmented eos ^c	90.8	40.0	130.0
band eos	12.5	11.6	18.8
metamyelocyte eos	1.0	3.8	0.9
neutrophils	8.4	10.3	12.5
lymphocytes	7.2	1.7	6.3
monocytes	—	1.0	1.8
Total solids (g/L)	ND ^b	64	70
Feline leukemia virus (FAT) ^d	ND	-ve	-ve

^aDifferential based on count of 200 cells

^bND = Not done

^ceos = eosinophils

^dFAT = fluorescent antibody test

BIOPSIES

Biopsies of cervical lymph nodes were taken in cats II and III. In each case, the capsule was infiltrated by eosinophils with extension into the perinodal fat. The subcapsular sinus was empty. There was cortical hyperplasia with an enlarged paracortical region that was devoid of lymphocytes but filled with eosinophils and stromal cells. Medullary cords were small and filled with eosinophils. Toluidine blue stain revealed that low numbers of mast cells were scattered throughout the paracortex but they were especially prominent around follicles.

A second biopsy from the upper cervical region was taken in case II, three and one half years after the first. The mass was round, white, firm, 2 cm in diameter and homogeneous on cut section. Histologically, the mass consisted of a parotid salivary gland remnant and an adjacent lymph node (Fig. 2). Both structures and the connective tissue between them, were extensively infiltrated by eosinophils. Most acini

in the salivary gland were replaced by eosinophils, but some of the ducts and stroma remained. On toluidine blue stain, a few mast cells were scattered throughout the mass.

NECROPSY

Necropsies were performed on cats I and II. The liver of cat I was enlarged and weighed 3.12% of body weight. There were multiple, white, randomly distributed, irregularly shaped, 1-3 mm diameter foci scattered throughout the livers of both cats. The lobular pattern of both livers was enhanced by red and tan mottling. Both cats had a 1 cm diameter round ulcer in the proximal duodenum. Cat II had a few other 1-3 mm diameter focal ulcers in the mid duodenal region and a 1 cm diameter ulcer at the ileocolic junction. All of these ulcers were associated with localized thickening of the intestine. The spleen in cat I was enlarged and rounded. Both cats had uniform reddening of the femoral bone marrow. The lymph nodes of cat

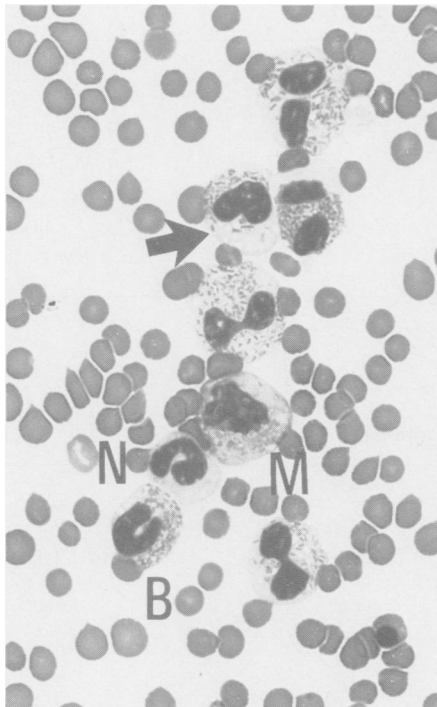


Fig. 1. Peripheral blood smear, cat II. Eosinophil myelocyte (M), band eosinophil (B), band neutrophil (N) and five segmented eosinophils, which contain vacuoles (arrow). Wright's stain. X350.

I were normal in appearance, but cat II had enlarged parotid, superficial cervical and mesenteric lymph nodes. On cut section, the nodes were uniformly white and firm. No other lesions were present at necropsy.

HISTOPATHOLOGY

Cats I and II had similar lesions histopathologically. The livers had many eosinophils in sinusoids and marked periportal infiltration of eosinophils that coalesced in some areas to form confluent aggregations. The liver lesions were generalized in cat I and regional in cat II. Beneath the focal mucosal ulceration in the duodenum, there was granulation tissue production and eosinophil infiltration of the submucosa, muscularis and serosa. Focally, throughout the duodenum, the lamina propria and submucosa were infiltrated with eosinophils and in cat I a few crypts contained cellular debris. In cat II, the mucosa of the ileocolic junction was ulcerated, with submucosal granulation tissue production, as seen in the duodenum. The adjacent ileal and colonic mucosa and submucosal lymphoid nodules were

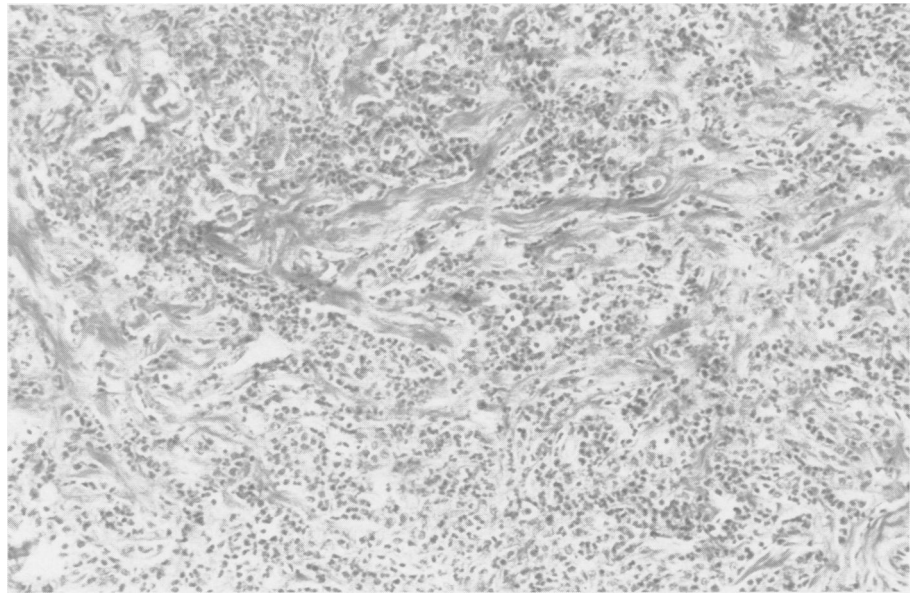


Fig. 2. Lymph node, cat II, paracortical region. Abundant fibrous connective tissue with infiltration of eosinophils. H & E. X90.

infiltrated with eosinophils. The femoral diaphyseal marrow was about 90% cellular in both cats. All cell lines were present, with a great increase in the number of eosinophils, in various stages of maturation.

The lymph nodes of both cats were involved, but to a varying degree. Some lymph nodes were normal, other nodes resembled those biopsied and described above. The rest were extensively infiltrated with eosinophils and were sclerotic, with only a few follicu-

lar remnants (Fig. 3). Perinodal infiltration was extensive and occasionally involved adjacent structures such as pancreas and salivary gland.

The spleen of cat I had rounded borders with focal capsular invasion by eosinophils. The thymic-dependent arteriolar cuffs were very wide, but the lymphocyte population was low, revealing eosinophils and dendritic reticular cells. The follicles were regularly present but small. Bilroth sinuses were filled with red cells and large

TABLE III. Bone Marrow Differential Count Cat II Expressed as Percentage of Total

Cell Type	Cat II	Normal (adapted from (8,9) ^b
Myeloblast	1.05	1.10 - 1.74
Progranulocytes	2.50	0.88 - 2.80
Myelocytes	6.60	0.30 - 1.47
Eos ^c metamyelocytes	7.45	0.20 - 1.52
Eos bands	8.10	0.00 - 0.30
Eos segs ^d	25.45	0.81 - 1.30
Neut ^e myelocytes	0.60	5.90 - 9.76
Neut metamyelocytes	1.20	7.32 - 15.0
Neut bands	3.45	14.70 - 25.80
Neut segs	5.60	9.24 - 14.0
Basophils	0.50	0.00 - 0.002
Rubriblasts	1.15	1.20 - 1.71
Prorubricytes and rubricytes	7.95	12.50 - 18.9
Metarubricytes	21.60	11.68 - 18.2
Lymphocytes	1.05	5.10 - 7.63
Monocytes	2.50	0
Disintegrated cells	3.25	0.00 - 4.60
Myeloid: Erythroid ratio	2.04:1.0	1.6:1.0 - 2.47:1.0

^aPercentages for Cat #2 based on a count of 2000 cells

^bReference values based on counts of 500 cells (9) and 1000 cells (8)

^cEos = eosinophils

^dSegs = segmented cells

^eNeut = neutrophils

numbers of eosinophils. There was eosinophil aggregation beneath the endothelium of the trabecular sinuses. The spleen of cat II had less extensive red pulp infiltration with eosinophils than the spleen of cat I. The periarterolar cuffs were small and follicles were prominent.

In both cats, there was subendocardial infiltration of eosinophils, but without fibrosis. The adrenal medullae from cat I were heavily infiltrated. No lesions were present in brain, kidney, urinary bladder, skeletal muscle or stomach.

In all tissues other than bone marrow, all eosinophils appeared to have distinctly lobated nuclei.

ELECTRON MICROSCOPY

Ultrastructurally, the eosinophils in the mandibular lymph node and bone marrow of cat II were morphologically the same as those reported from the peripheral blood of normal cats (10). In the lymph node, the eosinophils were associated with abundant collagen fibrils and some mature, well granulated mast cells (Fig. 4). In the bone marrow (Fig. 5), the eosinophils contained more abundant rough endoplasmic reticulum and mitochondria than the eosinophils in the lymph node. No degranulating cells were seen.

DISCUSSION

The hypereosinophilic syndrome (HES) is generally considered to be a group of idiopathic diseases characterized by a marked, prolonged eosinophilia with soft tissue infiltration. Morphologically, the eosinophils from the three cats in this study were normal on the basis of cytological, histopathological and, in cat II, electron microscopic evaluation.

Usually, the unexplained hyperproliferation of a single cell type raises suspicion of neoplasia. Several clinical features of the cats in this study are typical of eosinophilic leukemia, a variant of chronic myelogenous leukemia (CML) (11). These features are: a high number of well differentiated granulocytes in the peripheral blood (Fig. 1), extensive bone marrow involvement, hepatosplenic and soft tissue infiltration. Usually, however, in CML, there

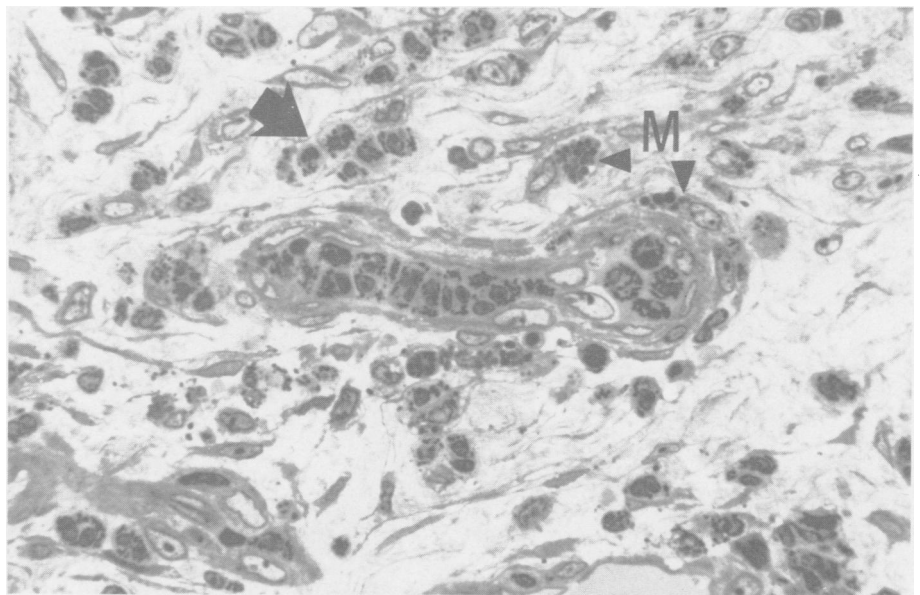


Fig. 3. Lymph node, cat II. Eosinophils are present in the lumen of a postcapillary venule and in interstitial tissue (large arrow). Mast cells (M) are scattered around the venule. 1 μ m, trichrome stain. X350.

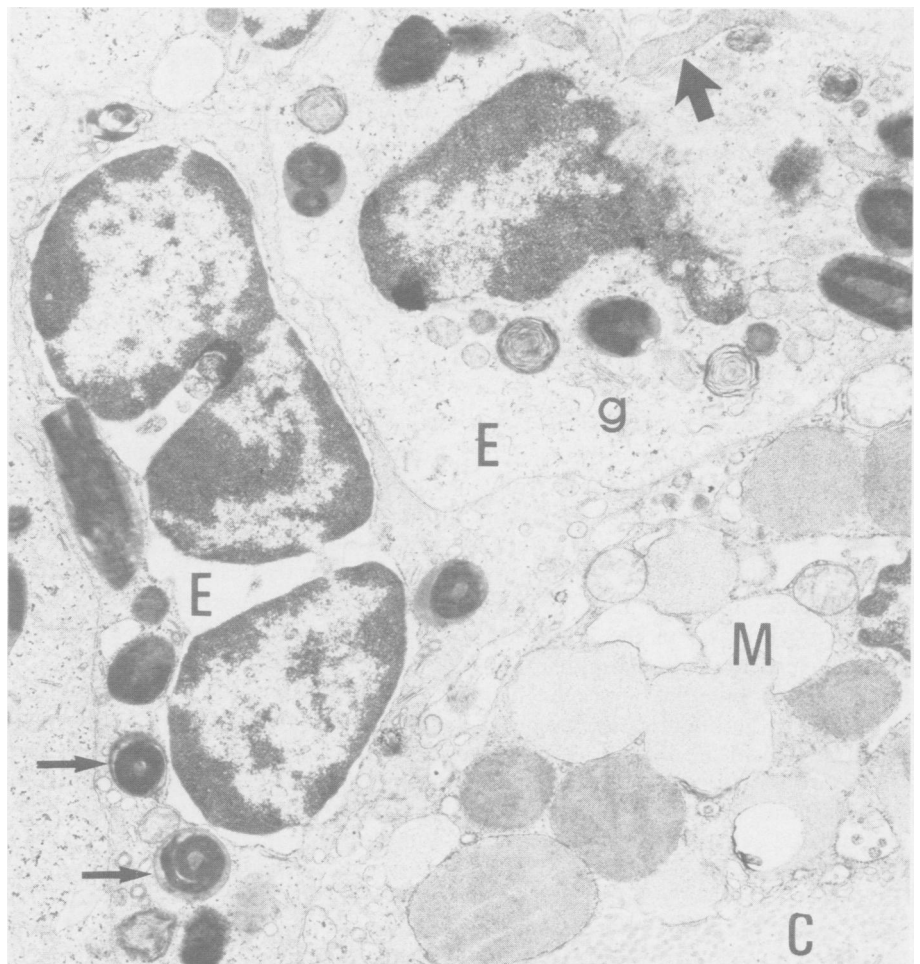


Fig. 4. Transmission electron micrograph, lymph node, cat II. Two eosinophils (E) adjacent to a mast cell (M). The eosinophils contain crystalloid granules (small arrows), mitochondria (large arrow) and golgi complex (g). The mast cell is filled with specific granules. Collagen fibrils (C) are abundant between cells. X14,000.

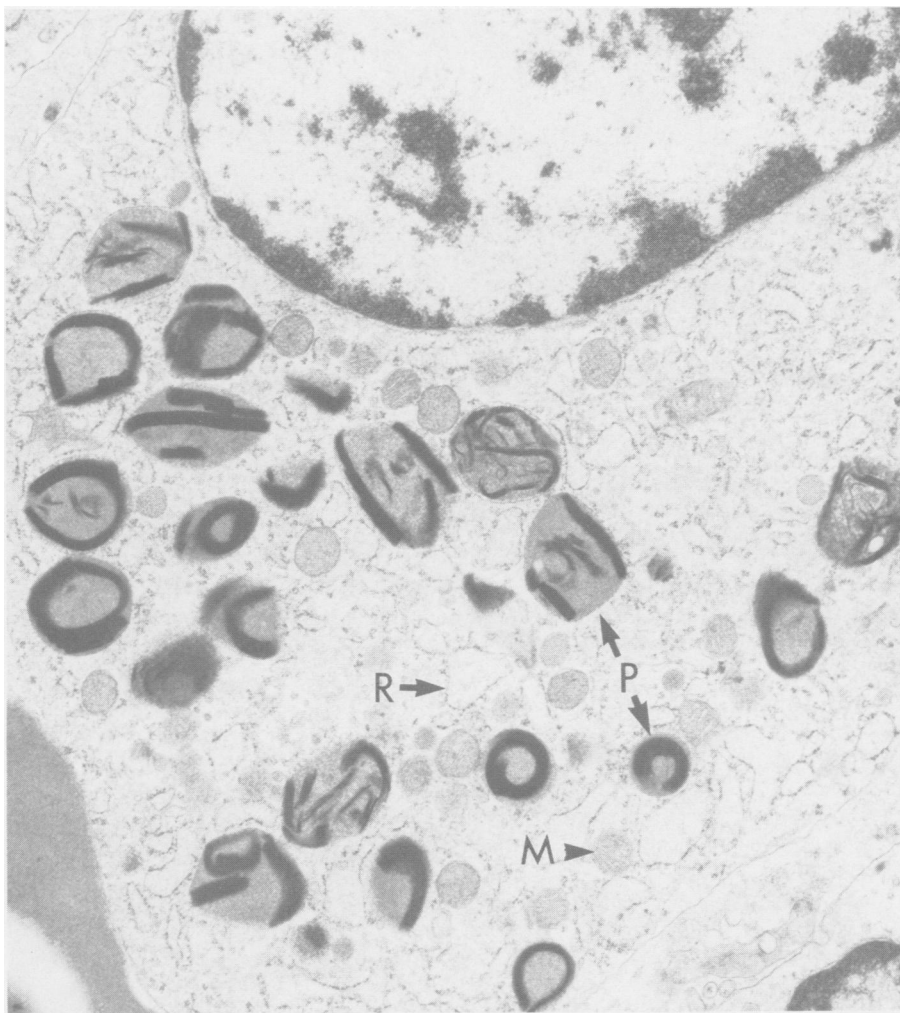


Fig. 5. Transmission electron micrograph, bone marrow, cat II. Round mitochondria (M) and dilated rough endoplasmic reticulum (R) are abundant. Crystalloid granules (P) contain typical fragmented lamellar interna. X14,000.

are at least some myeloblasts in the peripheral blood: none were present in the blood of the cats in this study. Indeed, some reported cases of eosinophilic leukemia in man have been later rejected (3). They were not considered truly leukemias because they lacked myeloblasts in the blood and lacked specific chromosomal abnormalities or biochemical markers, such as decreased leukocyte alkaline phosphatase, typical of CML in man (12). Chromosomal abnormalities have not been associated with CML in animals and normal cats and dogs appear not to have leukocyte alkaline phosphatase (13). It has been suggested that some cases of HES may be benign tumors of bone marrow (14). The long course (3.5 yrs) and slow progression of disease in cat II would be consistent with a benign tumor. The differential bone marrow count from cat II (Table

III) indicates that eosinophil maturation progressed from blast to segmented cell in synchrony. Proliferative phase eosinophils were present in bone marrow of all three cats, but were not seen in other tissues. This suggests that the eosinophils were being produced in the marrow and delivered to the tissues via the blood.

If the proliferation of eosinophils in HES is not neoplastic, then perhaps there is excessive stimulation of eosinophilopoiesis. Eosinophil production is affected by mast cells, T-lymphocytes and mediators present in serum (14). Mast cells, upon degranulation, release eosinophil chemotactic factor of anaphylaxis (ECF-A) and other substances (5) which attract eosinophils to the site of inflammation. In cats II and III, tissue sections stained with toluidine blue showed mast cells to be present in tissues infil-

trated by eosinophils, but in numbers similar to those in normal animals (15). Ultrastructurally, the mast cells associated with eosinophils in the lymph nodes of cat II showed no evidence of degranulation. The T-lymphocyte function of these three cats was not evaluated and no attempts were made to identify serum-derived eosinophilopoietic factors in them.

Eosinophilic enteritis, characterized by eosinophilia and eosinophil infiltration of the intestine has been reported in cats (1), dogs (16), and man (17). The enteric lesions seen in the cats in the present study were similar to those described in a previous report (1), where comparison to eosinophilic enteritis in man and possible pathogenetic mechanisms were discussed. Eosinophilic enteritis in dogs has been described in association with visceral larva migrans (16). No parasitic ova were seen in stool samples from the three cats in this study and no parasites were seen at necropsy or histopathologically.

The feline eosinophilic granuloma complex is a group of idiopathic diseases of the feline skin and oral cavity (18). One of the group, eosinophilic plaque, is characterized by marked focal eosinophil infiltration of the dermis, accompanied by lesser numbers of mast cells. This lesion is often associated with a peripheral eosinophilia (19). Skin and oral cavity lesions were not found in the cats presented in this study, but it is possible that HES and eosinophilic plaque share some of the pathogenetic mechanisms discussed herein. The two disease entities, in some respects, are reminiscent of the skin and systemic mastocytoma of the cat. Unlike the eosinophilic plaque, however, the feline mastocytoma is a potentially malignant neoplasm (20). Systemic mastocytoma and HES are similar in that both have peripheral blood and multiple organ involvement. The two diseases can be differentiated by examination of peripheral blood and tissue imprint smears.

Tissue damage is a consistent feature of HES in man (3,4). Sclerosis of eosinophil infiltrated lymph nodes was present in lymph nodes from the two cats (I and II) necropsied, and three of six cats with HES in a previous report

(1). The mechanisms of eosinophil-induced tissue damage in cats with HES is speculative. Eosinophils are known to have cytotoxic capabilities (20). Their peroxisomes produce hydrogen peroxide (H_2O_2) and superoxide anion (O_2^-) (14). Eosinophils from people with HES have been shown to have an increased production of O_2^- (21). It has been suggested that release of oxygen metabolites (22) and cationic proteins (20) from eosinophils are responsible for the tissue damage seen in HES. None of the eosinophils examined ultrastructurally in cat II appeared to be undergoing degranulation.

In summary, this study documents the clinical, clinicopathological and pathological findings in three cats with hypereosinophilic syndrome (HES). The etiology of hypereosinophilia in these cases is unknown.

Further studies of eosinophils may uncover an immunological basis for some cases of HES; on the other hand, establishment of the clonal proliferation of eosinophil cell lines from cases of HES may yet demonstrate that the disease is neoplastic.

ACKNOWLEDGMENTS

The authors acknowledge Drs. B. Hoff, R. Wilson and B. Binnington of Veterinary Laboratory Services, Ontario Ministry of Agriculture and Food for making cases II and III available.

REFERENCES

1. **HENDRICK M.** A spectrum of hypereosinophilic syndromes exemplified by six cats with eosinophilic enteritis. *Vet Pathol* 1981; 18: 188-200.
2. **GOTO N, KAWAMURA M, INOUE M, SATO A.** Pathology of two cases of canine disseminated hypereosinophilic disease. *J Jpn Vet Sci* 1983; 45: 305-312.
3. **HARDY WR, ANDERSON RE.** The hypereosinophilic syndromes. *Ann Intern Med* 1968; 68: 1220-1229.
4. **CHUSID MJ, DALE DC, WEST BC, WOLFF SM.** The hypereosinophilic syndrome: Analysis of fourteen cases with review of the literature. *Medicine* 1975; 54: 1-27.
5. **BEESON PB, BASS DA.** The eosinophil. *Major Probl Intern Med*, Vol XIV, 1977.
6. **KAZURA JW.** Protective role of eosinophils. In: Mahmoud AAF, Austen KF, eds. *The eosinophil in health and disease*. New York: Grune & Stratton, 1980: 231-251.
7. **SLUNGAARD A, ASCENSAO J, ZANJANI E, JACOB HS.** Pulmonary carcinoma with eosinophilia: Demonstration of a tumor-derived eosinophilopoietic factor. *N Engl J Med* 1983; 309: 778-781.
8. **PENNY RHC, CARLISLE CH, DAVIDSON HA.** The blood and marrow picture of the cat. *Br Vet J* 1970; 126: 459-463.
9. **GILMORE CE, GILMORE VH, JONES TC.** Bone marrow and peripheral blood of cats: Technique and normal values. *Pathol Vet* 1964; 1: 18-40.
10. **WARD JM, WRIGHT JF, WHARRAN GH.** Ultrastructure of granulocytes in the peripheral blood of the cat. *J Ultrastruct Res* 1972; 39: 389-396.
11. **GOLDMAN JM, MAJFELD V, TH'NG KH.** Agar culture and chromosome analysis of eosinophilic leukemia. *J Clin Pathol* 1975; 28: 956-961.
12. **WILLIAMS WJ, BEUTLER E.** *Hematology*. 3rd ed. New York: McGraw Hill, 1983.
13. **WILLSON JE, BROWN DE.** Leukemoid reaction resembling myelogenous leukemia in a dog. Failure of the leukocyte alkaline phosphatase test to aid in the differential diagnosis. *Cornell Vet* 1965; 55: 55-63.
14. **TAVASSOLI M.** Eosinophil, eosinophilia and eosinophilic disorders. *CRC Crit Rev Clin Lab Sci* 1981; 16: 35-83.
15. **SELYE H.** *The mast cells*. Washington: Butterworths, 1965.
16. **HAYDEN W, VAN KRUININGEN HF.** Eosinophilic gastroenteritis in German Shepherd dogs and its relationship to visceral larva migrans. *J Am Vet Med Assoc* 1973; 162: 379-384.
17. **SLEISENGER MH, FORDTRAN JS.** *Gastrointestinal disease*. Philadelphia: WB Saunders, 1978.
18. **SCOTT DW.** *Feline dermatology 1900-1978: a monograph*. *J Am Anim Hosp Assoc* 1980; 16: 331-332.
19. **SCOTT DW.** Observations on the eosinophilic granuloma complex in cats. *J Am Anim Hosp Assoc* 1975; 11: 261-270.
20. **MOULTON JE, ed.** *Tumors in domestic animals*. 2nd ed. Berkeley: University of California Press, 1978.
21. **GLEICH GJ, FRIGAS E, LOEGERING DA, WASSON DL, STEINMULLER D.** Cytotoxic properties of the eosinophil major basic protein. *J Immunol* 1979; 123: 2925-2927.
22. **PINCUS SH, SCHOOLEY WR, DI NAPOLI AM, BRODER S.** Metabolic heterogeneity of eosinophils from normal and hypereosinophilic patients. *Blood* 1981; 58: 1175-1181.
23. **SLUNGAARD A, VERCELLOTTI G, ZANANI JA, JACOBS HS.** Tumor-induced eosinophilia and endocardial fibrosis: Evidence for ectopic eosinophilopoietin production and toxic O_2 metabolite-mediated endothelial damage. *Trans Assoc Am Physicians* 1982; 95: 8-11.