

# Laparoscopic Injuries to the Bile Duct

## *A Cause for Concern*

A. R. MOOSSA, M.D., DAVID W. EASTER, M.D., ERIC VAN SONNENBERG, M.D., GIOVANNA CASOLA, M.D., and HORACIO D'AGOSTINO, M.D.

The authors report six patients who had injuries to their common hepatic bile duct at laparoscopic cholecystectomy over a 16-month period. Five of the six complications could be attributed to laser injuries during dissection in the region of Calot's triangle. The authors discuss the possible mechanism of these injuries, their perioperative management, and the methods of surgical reconstruction. The follow-up period ranges from 3 months to 21 months. Liver function parameters and isotope biliary excretion scans are back to normal in all six patients. The potential hazards of laparoscopic surgery demand that extraordinary care be used not only during the actual surgical procedure, but also in the preoperative decision concerning the dissection method to be employed.

**T**HE MEDICAL COMMUNITY is experiencing a dramatic change in the way calculous disease of the biliary tract is treated. The recent revolution in minimally invasive surgery, specifically laparoscopic cholecystectomy, is still in progress. The rapid acceptance of, and the increasing demand for, the procedure is phenomenal when we consider that the benefits and risks of the procedure remain to be fully evaluated. It is unknown at present if laparoscopic methods can match the safety of the "gold standard" of an open cholecystectomy, or if the main benefit will be cost savings due to shortened hospital stay and rapid return to work.

Injuries to the bile ducts during cholecystectomy are not uncommon, occurring in approximately 0.5% of those undergoing open cholecystectomy.<sup>1-3</sup> With over 500,000 cholecystectomies performed annually for calculous disease in the United States, more than 2000 injuries can be expected annually with traditional methods of cholecystectomy.<sup>4</sup> What proportion of these cases will be performed laparoscopically in the future, and what rate of

*From the Departments of Surgery and Radiology, University of California, San Diego, California*

bile duct injury will be encountered with laparoscopic methods, are unresolved questions.

We report here our experiences with biliary reconstruction in six cases referred to our institution with high bile duct injuries after laparoscopic cholecystectomy over a 16-month period. We have previously suggested that coupling laser techniques with laparoscopic surgery for the beginner in both fields may be particularly dangerous.<sup>5</sup> For the description of biliary strictures, we have employed Bismuth classification based on the level of each stricture as it relates to the confluence of the hepatic duct (Fig. 1).

### Case Reports

#### *Case Study 1*

A 57-year-old moderately obese woman underwent laparoscopic laser cholecystectomy for symptomatic gallstones. No technical problem was encountered during the procedure. Operative cholangiogram was not performed. Four days later, the patient developed abdominal pain and distention, with a mild fever and marginally elevated liver function parameters. Ultrasonography disclosed ascites with a large fluid collection in the subhepatic space. Laparotomy was performed, and a large-volume biliary ascites was evacuated. A subhepatic suction drain was placed and the patient developed a biliary fistula for about 3 weeks. The biliary drainage stopped for several days, and the drain was removed. The patient developed recurrent evidence of sepsis, and ultrasonography disclosed another subhepatic bile collection. This was drained percutaneously and, at the same time, a transhepatic catheter was placed in the biliary tree for proximal biliary diversion. The patient was managed nonoperatively for 4 further weeks and complained of multiple constitutional symptoms, including fatigue, nausea, and depression. About 11 weeks after the cholecystectomy, the patient was re-explored and reconstruction of a Bismuth type II stricture (Fig. 2) was undertaken with a hepaticojejunostomy Roux-en-Y anastomosis at the level of the hepatic duct bifurcation. All the liver function parameters returned to normal within 1 month of reconstruction. A Tc HIDA hepatobiliary scan performed 3 months later was totally normal.

Address reprint requests to A. R. Moossa, M.D., Professor and Chairman, Department of Surgery (H-810), UCSD Medical Center, 402 Dickinson St., San Diego, CA 92103.

Accepted for publication June 20, 1991.

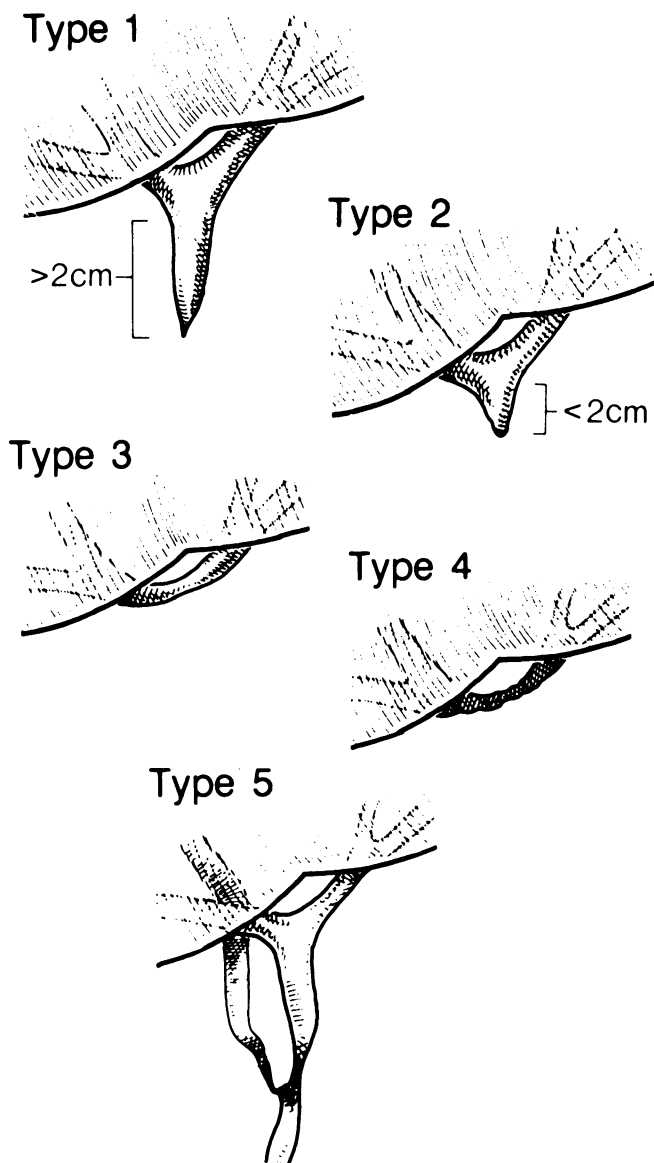


FIG. 1. Bismuth classification of benign bile duct strictures based on the location of the lesion in relation to the hepatic duct bifurcation. Reprinted with permission from Blumgart et al.<sup>18</sup>

#### Case Study 2

A 58-year-old woman underwent laparoscopic laser cholecystectomy after a previous attack of mild acute cholecystitis. A moderate amount of adhesions was divided. Operative cholangiogram was attempted but failed. The cholecystectomy proceeded uneventfully.

Two days later, the patient developed evidence of a bile leak and underwent a laparotomy. The common bile duct was explored and a T-tube was placed. The patient then developed progressive mild jaundice, and a T-tube cholangiogram showed a Bismuth type II stricture proximal to the site of insertion of the T-tube (Fig. 3). Six weeks after the laparoscopic cholecystectomy, the patient was re-explored, and the Bismuth type II stricture was repaired by hepaticojejunostomy Roux-en-Y. All the liver function parameters returned to normal within 1 week. A Tc HIDA 3 months after the repair was also normal.

#### Case Study 3

A 43-year-old obese man underwent laparoscopic laser cholecystectomy for symptomatic gallstones. He remained well for 5 months, at which time he presented with progressive obstructive jaundice. Endoscopic retrograde cholangiopancreatography showed a stricture just below the common hepatic duct bifurcation. He underwent a percutaneous placement of a stent across the stricture. He remained relatively well for another 7 months, at which point he presented with an acute obstructive cholangitis. Percutaneous transhepatic cholangiogram showed a Bismuth type III stricture (Fig. 4). He underwent percutaneous transhepatic biliary drainage followed 4 days later by abdominal re-exploration. The stent was removed and a hepaticojejunostomy Roux-en-Y repair was performed at the hepatic duct bifurcation. Liver function parameters were completely normal at 1 month, and a Tc HIDA hepatobiliary scan performed 2 months later showed normal biliary excretion.

#### Case Study 4

A 38-year-old woman underwent laparoscopic laser cholecystectomy for asymptomatic gallstones. A subhepatic drain was placed and produced copious biliary drainage within 24 hours. The patient was immediately re-explored and was found to have a near-circumferential damage of the common hepatic duct just below its bifurcation. An end-to-end anastomosis was performed over a T-tube brought out through the distal duct. A T-tube cholangiogram performed 3 months later showed good healing of the anastomosis. The T-tube was accordingly removed. The patient remained asymptomatic for 2 months, but then presented with progressive obstructive jaundice. Endoscopic retrograde cholangiopancreatography was performed with attempted passage of a guide wire for possible stent placement, but this failed. A percutaneous transhepatic cholangiogram showed a Bismuth type IV (Fig. 5) stricture. The patient was re-explored, and the right hepatic duct as well as the confluence of the middle and left hepatic duct were anastomosed to a Roux-en-Y loop of jejunum. The patient's liver function parameters returned to normal within 3 weeks, and a Tc HIDA hepatobiliary scan performed 4 months later was totally normal.

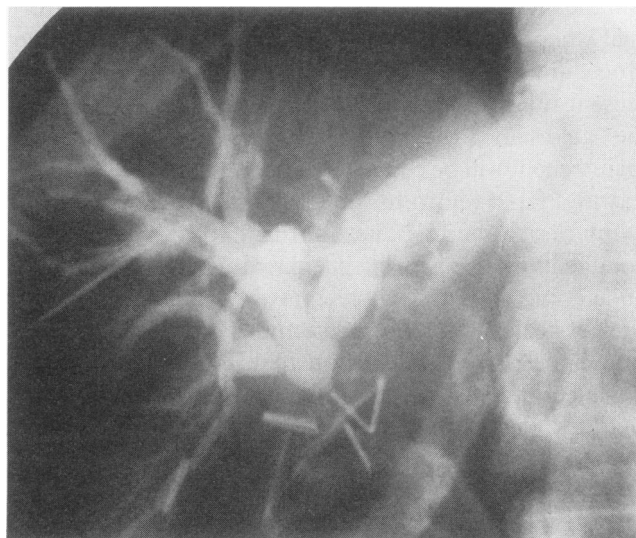

FIG. 2. Percutaneous transhepatic cholangiogram showing a Bismuth type II stricture. There is less than 2 cm of common hepatic duct below the bifurcation.

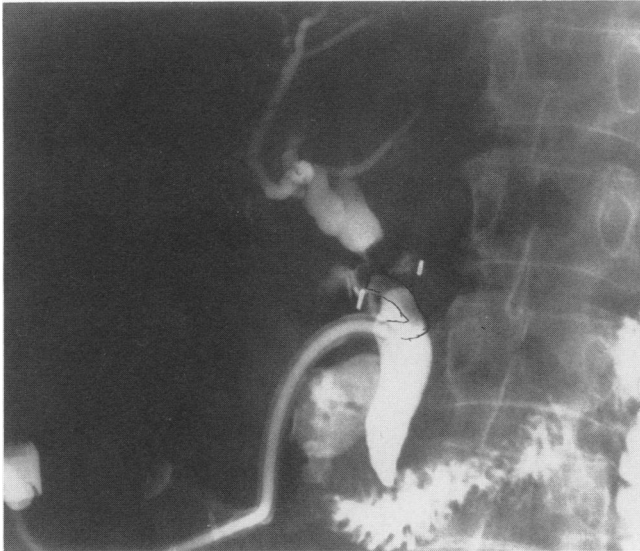

FIG. 3. T-tube cholangiogram showing a Bismuth type II stricture produced at laparoscopic cholecystectomy. Note that the T-tube was placed below the stricture at abdominal exploration.

#### Case Study 5

A 35-year-old woman underwent laparoscopic cholecystectomy for asymptomatic gallstones. Operative cholangiography was not performed. About 1 week after operation, she developed right upper quadrant pain, nausea, vomiting, and progressive jaundice. Percutaneous transhepatic cholangiogram disclosed a high duct bile duct stricture just below the level of the hepatic duct bifurcation. Two weeks later, she was re-explored, and the hepatic duct trifurcation was reanastomosed to a Roux-en-Y loop of jejunum. She made an uneventful postoperative recovery, and her liver function parameters became normal within 2 weeks. A Tc HIDA

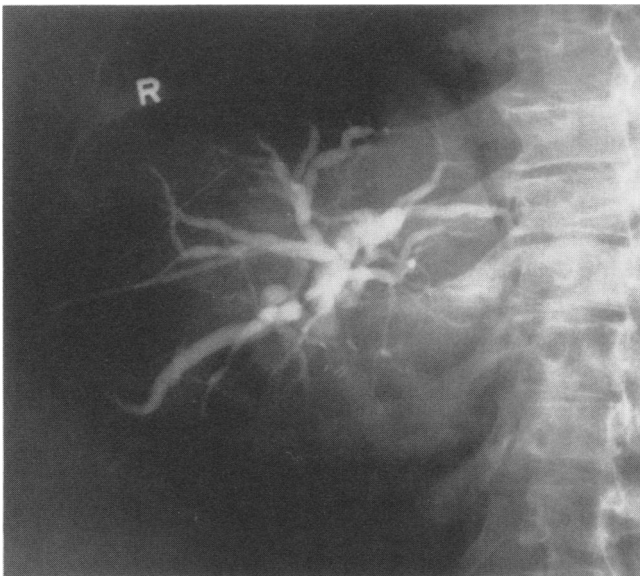


FIG. 4. Percutaneous transhepatic cholangiogram in a patient with obstructive cholangitis and a Bismuth type III stricture. Note that the metal stent that had previously been placed was totally occluded.

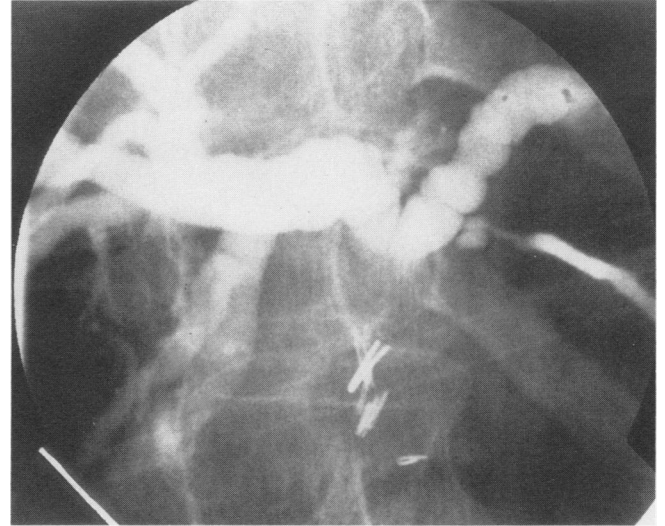


FIG. 5. Percutaneous transhepatic cholangiogram showing a Bismuth type III stricture. The hepatic duct bifurcation was intact, but there was no common hepatic duct remnant.

biliary scan performed at 3 months showed normal biliary drainage (Fig. 6).

#### Case Study 6

A 71-year-old woman underwent laparoscopic laser cholecystectomy for symptomatic gallstones. Operative cholangiogram was not performed, but the operation proceeded uneventfully. The patient remained asymptomatic for 5 months, but re-presented with recurrent right upper quadrant pain with mild fever and mild elevation of liver enzymes. Ultrasonography showed a dilated intrahepatic ductal system. Percutaneous transhepatic cholangiogram confirmed intrahepatic duct dilatation and showed a long partial stricture of the distal two thirds of the common bile duct. The patient underwent a hepaticojejunostomy Roux-en-Y repair uneventfully. Liver enzymes were back to normal within 2 weeks of the reconstruction. A Tc HIDA scan at 6 months was normal.

### Operative Details

Each exploration was notable for the presence of dense inflammatory reaction and fibrosis at the area of injury. There was a surprising finding of ductal tissue missing from the injured segment. No visible remnant of distal ductal tissue could be identified in two of the six cases, and the portal vein was easily identified as if it were an anterior structure in both instances. Healthy proximal ductal tissue was identified by dissecting inside the liver hilum and lowering the hilar plate as recommended by Bismuth. The mobilized proximal duct stump was trimmed of all scar tissue, and the biliary stoma was enlarged by incising into the left main duct. The largest possible biliary-enteric stoma was created by mucosa-to-mucosa approximation of the bile duct to a Roux-en-Y loop of jejunum in end-to-side fashion with interrupted 4-0 polyglycolic sutures. To avoid tension on the anastomosis,

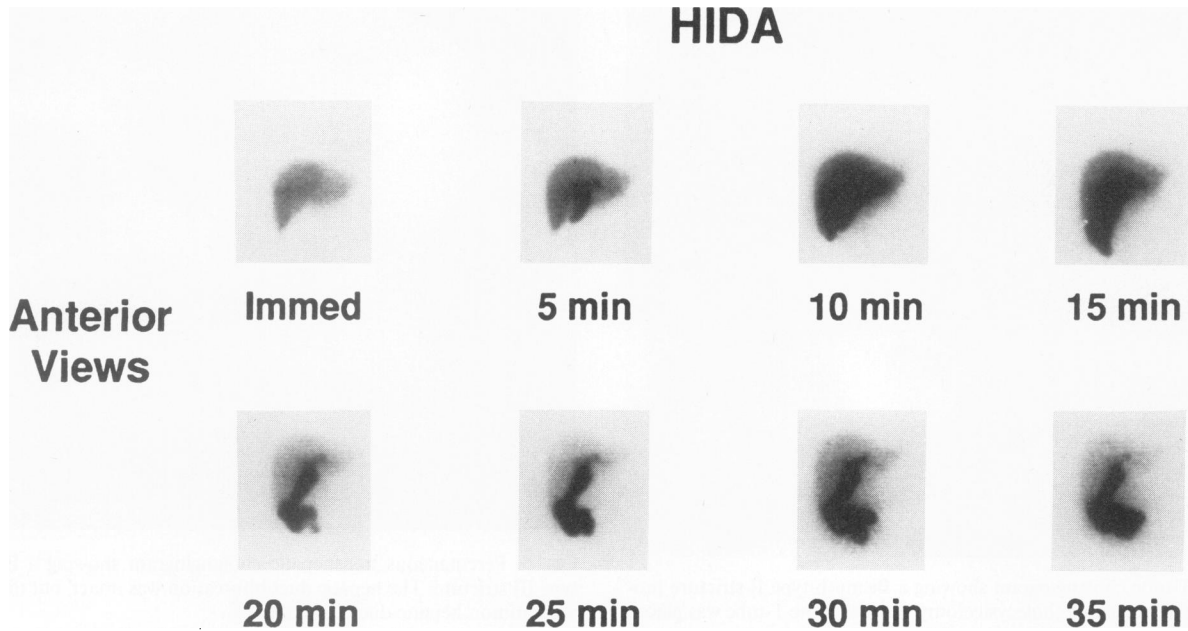


FIG. 6. Isotope biliary excretion scan with Tc-HIDA showing a widely patent and functioning hepaticojejunostomy at the level of the hepatic duct bifurcation.

the upper part of the jejunal loop was supported to the scar tissue of the gallbladder bed and the mobilized round ligament using multiple 3-0 silk sutures. Temporary (3 to 4 weeks) stenting of the anastomosis by the percutaneous transhepatic approach was employed in only two of the six individuals.

### Comments

In the treatment of symptomatic cholelithiasis, the "gold standard" against which new techniques must be compared is an open cholecystectomy with intraoperative cholangiogram. In more than 100 years of experience with open cholecystectomy, the medical community has witnessed the evolution of acceptable morbidity and mortality rates with this procedure. A new standard may be set, however, as the tidal wave of enthusiasm and early experience with laparoscopic cholecystectomy methods develops. Public demand, coupled with wide acceptance of the laparoscopic technique, may well be so great that comparisons between "open" and "closed" cholecystectomy will be available only through the use of historical controls.

A recent report of 100 consecutive elective laparoscopic cholecystectomy indicates that only four patients required conversion to the "open" method. There were one minor bile duct injury, two postoperative bile leaks, and one clinical diagnosis of a retained common bile duct stone that passed spontaneously. The authors estimate a morbidity rate of 8% and a bile duct injury rate of 1% for laparoscopic cholecystectomy.<sup>6</sup> Clearly, the most serious

worry is the issue of biliary tract injury, and our preliminary anecdotal experience suggests that the incidence may well be as high as 7% in institutions where multiple surgeons perform the "occasional" procedure without any individual obtaining a concentrated exposure. Institutions may be wise to initially limit privileges for laparoscopic surgery to a few surgeons with a genuine interest until the indications and contraindications are delineated and the safety of the procedure is well established.

It probably will be easier to scientifically evaluate the differences between various methods of laparoscopic dissection, namely, comparing laser with electrocoagulation methods. Such trials are already in progress.<sup>7,8</sup> Until the results of such comparisons become available, it will remain the domain of each individual surgeon (and patient) to choose the safest possible methodology. It is important to notice that the anatomic pattern of the laparoscopic injuries is identical to those inflicted at open cholecystectomy. The duct is damaged above the entrance of the cystic duct, presumably during dissection within Calot's triangle.

Bile duct injuries during "open" cholecystectomy occur when 1) the wrong duct is ligated or transected, 2) the lumen of the bile duct is occluded during "flush ligation" of the cystic duct, 3) the blood supply to the duct is compromised by excessive dissection, and 4) the lumen of the duct is traumatized by manipulation or forceful "dilatation."<sup>9,10</sup> To these four scenarios, we should now add a fifth possibility, namely, injury to ductal structures during inappropriate application and control of an energy source. From the practical viewpoint, the surgeon must be aware

of the avoidable damage to ductal structures through inappropriate control of the "backstop effect" of laser dissection. Injuries at laparoscopic cholecystectomy attributable to inappropriate control of electrocautery is certainly possible, but as yet we have not encountered any.

Laser dissection methods rely on the ability of light energy to excite molecules within its path sufficient to cause heating of the recipient tissue and disruption of structural proteins.<sup>11</sup> During the 20-plus years of research into and experience with the methodology of laser surgery methodology, two adaptations have been used to limit unwanted tissue damage.

The wavelength of light energy can be chosen so that certain specific tissues are targeted. Practically, this applies only to the use of laser energy to disrupt calculi and leave its adjacent epithelium free of damage. Unfortunately, that wavelength most efficient in disrupting both pigmented and cholesterol stones is also the wavelength best absorbed (and heat producing) by bile as well.<sup>11</sup> The intermittent interruption of laser energy ("pulsed dye laser") also can be used to minimize thermal damage. This translates into delivering energy sufficient to disrupt biliary and urinary calculi while limiting damage to the surrounding epithelium.<sup>12,13</sup>

Modification of wavelengths and pulse variations, however, are unlikely to impact on the inadvertent injury to bile ducts caused by laparoscopic surgeons. This is because even the "smartest" laser is unlikely to be able to discriminate between the nearly identical physical characteristics of bile duct *versus* gallbladder (or other closely related important anatomic structures).

When laser mishaps occur, tissue damage probably is mediated by ischemic injury to the recipient structures. Moreover, the tissue coagulation effects of laser energy have been used in the welding-fusion of biliary tissues.<sup>13-15</sup> It is not surprising, therefore, that a misdirected laser beam can produce substantial and complex destructive injuries to ductal structures. The blood supply of the common bile duct is extremely variable. Two of our patients (Cases 3 and 6) presented a few months after an apparently successful cholecystectomy, and the strictures may well be attributed to ischemic injury. Whether the ischemia is due to a laser effect, or to excessive stripping and devascularization of the duct, or both, is impossible to determine.

Although anatomic variants are present in up to 15% to 20% of biliary cases, there was no indication in this series of referrals that such "anomalies" contributed to the resultant injuries. Operative cholangiography was attempted in only one of these six cases, and was successful in none. Omission of this step is potentially hazardous, especially when the visual perspective of the operating surgeon has been changed (and acutely so for those who are less experienced with laparoscopic methods). This is

also particularly relevant because, laparoscopically, it is not conveniently possible to begin one's dissection at the fundus of the gallbladder, as has been described for avoiding injuries during "open" cholecystectomy.<sup>1,4</sup>

The level of experience of the operating surgeon and the technical difficulties at operation are other factors that can add to the risk of bile duct injury.<sup>9,10</sup> Each of our referred patients had relatively inexperienced surgeons (as is most of the surgical community to date). Two of the injured patients were described as obese at first operation. None, however, produced situations at operation that were perceived as dangerous enough to warrant conversion to an "open" procedure. The late Rodney Maingot, when talking about the operation of cholecystectomy, was both accurate and prophetic with the following two statements: 1) all complications are made in the operating room; and 2) the surgeon must operate by sight, not by faith.

It is interesting that, contrary to our customary patterns of referral, three of our six patients were referred for reconstructive surgical procedures by the primary surgeons.<sup>9,10</sup> The other three were referred first to interventional radiologists, and later were offered surgical repair. It may be that either surgeons are beginning to accept that benign strictures of the biliary ducts are best handled surgically<sup>16-18</sup> or that they prefer, with respect to their early experiences with laparoscopic cholecystectomy, to keep their "dirty laundry" within the surgical community.

The role of interventional radiology should not be minimized in the management of these patients. Percutaneous drainage of subhepatic bile collections is clearly preferable to a laparotomy. Percutaneous transhepatic cholangiogram is always performed ideally within 24 hours of the proposed reconstruction. It delineates the anatomy of the biliary tree proximal to the stricture and helps in the planning of a surgical strategy. The placement of a biliary catheter close to the hilum can be a useful guide in the tedious subhepatic dissection to locate a short proximal biliary stump. The catheter also can be used to temporarily stent the anastomosis if deemed desirable.

Our choice of surgical repair, a single-layer interrupted mucosa-to-mucosa anastomosis between bowel and bile duct, has in our hands and others<sup>18,19</sup> given superior results to all other techniques, including Rodney Smith's mucosal graft procedure. We recommend the method of direct mucosa-to-mucosa repair for those specialists who are challenged with these difficult situations. We no longer employ prolonged transhepatic intubation and stenting of the anastomosis as previously advocated for these high biliary strictures.<sup>20</sup>

## Conclusions

We have recently successfully reconstructed the bile ducts of six patients who had injuries sustained at lapa-

roscopic cholecystectomy. Five of these injuries were associated with laser dissection methods. Findings at operation were notable for the absence of substantial ductal length, and reconstruction at the level of the hilar liver plate was uniformly necessary.

We caution those who use laser methods of dissection during laparoscopic cholecystectomy to be particularly mindful of the "backstop effect" of laser energy, as well as the variations of ductal anatomy that can make for hazardous dissection. We believe that routine operative cholangiogram remains a major safeguard. It may be appropriate to learn laser and laparoscopic methods separately, only later to combine them if desirable, or alternatively, to await objective evaluation of the purported benefits of laser dissection techniques before subjecting patients to its potential risks.

### References

1. Hermann RE. A plea for a safer technique of cholecystectomy. *Surgery* 1976; 79:609-611.
2. Smith EB. Iatrogenic injuries to extrahepatic bile ducts and associated vessels: a 25-year analysis. *J Natl Med Assoc* 1982; 74:735-738.
3. Andren-Sandberg A, Alinder G, Bengmark S. Accidental lesions of the common bile duct at cholecystectomy. *Ann Surg* 1985; 201:328-332.
4. Henry ML, Carey LC. Complications of cholecystectomy. *Surg Clin North Am* 1983; 63:1191-1204.
5. Easter DW, Moossa AR. Laser and laparoscopic cholecystectomy: a hazardous union? *Arch Surg* 1991; 126:423.
6. Peters JH, Ellison EG, Innes JT, et al. Safety and efficacy of laparoscopic cholecystectomy. *Ann Surg* 1991; 213:3-12.
7. Berci G. (Personal communication) Preliminary data from Society of American Gastrointestinal and Endoscopic Surgeons.
8. Corbitt JB. (Personal communication) JFK Medical Center, Atlantis, FL, 1990.
9. Moossa AR, Mayer AD, Stabile B. Iatrogenic injury to the bile duct—who, how, where? *Arch Surg* 1990; 125:1028-1031.
10. Moossa AR. Iatrogenic bile duct injuries—some myths and realities. *In* Najarian JS, Delaney JP, eds. *Progress in Hepatic, Biliary, and Pancreatic Surgery*. Chicago: Year Book Medical Publishers, 1990, pp 173-218.
11. Dretler SP. Laser lithotripsy: a review of 20 years of research and clinical applications. *Lasers Surg Med* 1988; 8:341-356.
12. Murray A, Basin R, Fairclough PD, Wood RF. Gallstone lithotripsy with the pulsed dye laser: in vitro studies. *Br J Surg* 1989; 76:457-460.
13. Nishioka NS, Levins PC, Murray SC, et al. Fragmentation of biliary calculi with turnable dye lasers. *Gastroenterology* 1987; 93:250-255.
14. Oz MC, Bass LS, Popp HW, et al. In vitro comparison of thulium-holmium-chromium: YAG and argon ion lasers for welding of biliary tissue. *Lasers Surg Med* 1989; 9:248-253.
15. Popp HW, Oz MC, Bass LS, et al. Welding of gallbladder tissue with a pulsed 2.15 microns thulium-holmium-chromium: YAG laser. *Lasers Surg Med* 1989; 9:155-159.
16. Wagner HE, Barbier P. Reoperations upon the biliary duct system for benign disorders are still indicated. *Surg Gynecol Obstet* 1987; 164:56-70.
17. Browden IW, Dowling JB, Koontz K, Litwin MS. Early management of operative injuries of the extrahepatic biliary tract. *Ann Surg* 1987; 205:649-658.
18. Blumgart LH, Kelley CJ, Benjamin LS. Benign bile duct stricture following cholecystectomy: critical factors in management. *Br J Surg* 1984; 71:836-843.
19. Bismuth H, Franco D, Corlette MB, Hepp J. Long-term results of Roux-en-Y hepaticojejunostomy. *Surg Gynecol Obstet* 1978; 146:161-167.
20. Moossa AR, Block GE, Skinner DB, Hall AW. Reconstruction of high biliary tract strictures employing transhepatic intubation. *Surg Clin North Am* 1976; 56:73-81.

### Addendum

Since the submission of this article, the authors have repaired nine additional similar bile duct injuries, and one patient has died of Candida sepsis.