

An electromyographic study of the intrinsic muscles of the back in man*

BY J. M. MORRIS, GORDON BENNER AND D. B. LUCAS

*Biomechanics Laboratory, University of California, San Francisco and Berkeley,
and Department of Orthopaedic Surgery, University of California School of
Medicine, San Francisco*

The erector spinae group of muscles, as well as other muscles associated with the vertebral column, are usually considered collectively from a functional point of view. Thus, they are often thought of as 'two large' muscles, one on either side of the spinous processes. Today, little attention is paid to the exact origin, insertion, or function of the individual components of the group. Ignoring these points is understandable to a degree, for, in contrast to most muscles of the limbs, the individual back muscles are difficult or impossible to palpate, adjacent muscles generally have similar functions, and movements of the trunk are effected by a diffuse but intricate pattern of contribution from the individual muscles.

Considerable work on the electromyographic activity of the back muscles has been done (Floyd & Silver, 1951, 1955; Joseph, 1960; Joseph & McColl, 1961; Portnoy & Morin, 1956), with the erector spinae group being investigated rather extensively as a whole. However, although different areas of this group have been tested, little is reported of attempts to distinguish the action of the individual muscles. In addition, skin electrodes have usually been used.

The purpose of this study, which is part of a comprehensive investigation of the structure and mechanics of the spine being carried on at the Biomechanics Laboratory, is to consider more closely a number of the individual back muscles and to determine, by analysis of electromyographic activity, their function in movements of the trunk.

The deep or intrinsic muscles of the back may be considered, for the purposes of this study, in three groups: (1) longitudinal muscles, (2) oblique muscles, and (3) a group of small intrasegmental muscles. The first group is formed by the large sacrospinalis (erector spinae) muscle, which constitutes the bulk of the intrinsic back muscles. Of its three columns, the most lateral, the iliocostalis, consists of lumbar, dorsal (thoracic), and cervical portions; the intermediate column, the longissimus (the largest of the three), is divided into dorsal (thoracic), cervical, and capitis portions; and the most medial and smallest of the columns is the spinalis group.

The oblique muscles of the back lie deep to the longitudinal muscles and are arranged in three layers, of which the fibres pass upward and medially from the transverse processes to the spines of the vertebrae. The most superficial layer is formed by the semispinalis muscle, each group of which spans approximately five vertebral segments. Fibre groups of the medial layer, the multifidus, span three

* This investigation was supported by Veterans Administration Contract V 1005 M-2075.

segments, being most conspicuous in the lower lumbar region, where they form a thick, fleshy mass beneath the posterior layer of the thoraco-lumbar fascia. The deepest layer, the rotatores, is composed of groups spanning only one segment; these are most pronounced in the thoracic region and are in some areas represented only by small, indistinct slips.

The third group of intrinsic back muscles includes small slips of muscles that bridge the space between two vertebral processes, such as the interspinales and intertransversarii.

This study deals with the deep back muscles only in the lower thoracic and lumbar regions. In these regions, the muscles to be examined were chosen by their size, position, and, therefore, accessibility for accurate placement of electrodes within them. Dissections of cadavers confirmed the impression that electrodes could be placed within five of the muscles with reasonable accuracy. Also during dissection, the presence and location of bony and surface landmarks were carefully noted. These five muscles are the iliocostalis dorsi, longissimus dorsi, iliocostalis lumborum, multifidus, and rotatores. As will be noted, these muscles represent lateral and medial, as well as deep and superficial, portions of the intrinsic back muscles.

MATERIAL AND METHODS

The activity of the muscles was obtained by means of embedded wire electrodes consisting of fine insulated copper wire (no. 34). The wire was threaded through a no. 25 hypodermic needle, the insulation removed from the tip of the wire, and a small hook made in the end of the wire over the short side of the bevel of the needle. The needles with their contained wire electrodes were then sterilized. After suitable preparation and local anesthetization of the skin, two needles and electrodes were

Table 1. *Locations of embedded wire electrodes*

Muscle	Electrode	Location
Iliocostalis dorsi	1	Over 7th rib, $\frac{1}{4}$ distance from angle of rib to spine
	2	Over 6th rib, $\frac{1}{4}$ distance from angle of rib to spine
Longissimus dorsi	1	Over 9th rib, $\frac{1}{2}$ distance from angle of rib to spine
	2	Over 10th rib, $\frac{1}{2}$ distance from angle of rib to spine
Iliocostalis lumborum	1	Over 11th rib, $\frac{1}{4}$ distance from angle of rib to spine
	2	Over 12th rib, $\frac{1}{4}$ distance from angle of rib to spine
Multifidus	1	$\frac{3}{4}$ in. below line joining iliac crests, $\frac{1}{2}$ in. lateral to 5th lumbar spine
	2	$1\frac{1}{2}$ in. below line joining iliac crests, $\frac{1}{2}$ in. lateral to 5th lumbar spine
Rotatores	1	$\frac{1}{4}$ in. lateral to 10th thoracic spine
	2	$\frac{3}{4}$ in. below electrode 1

inserted approximately 2 cm. apart into each muscle to be studied. The needles were then withdrawn, leaving the wire electrodes with their hooks embedded within the muscles. These were easily removed subsequently by gently pulling on the wires and straightening out the hooks.

The electrode wires were connected to a junction box that was attached and grounded to the subject's chest or back. The electrical activity of the muscles was

fed into and amplified by a six-channel electromyographic instrument with a band width of 20–30,000 cyc./sec. The amplifier had a maximum sensitivity of $10\ \mu\text{V./cm.}$ deflexion of the recording pen and a peak-to-peak noise level of $5\ \mu\text{V.}$ The electrodes were bipolar in all cases, and differential-input amplifiers were used (i.e. the amplifiers measured the difference in potential between the two electrodes, and the potentials thus obtained were not referred to ground). The amplifiers provided a high inphase rejection to 60-cycle interference. The electromyographic amplifier had both integrated and direct output signals. Integration was used in all cases. The integrated output was recorded by an Offner type 506 A recorder. The integration

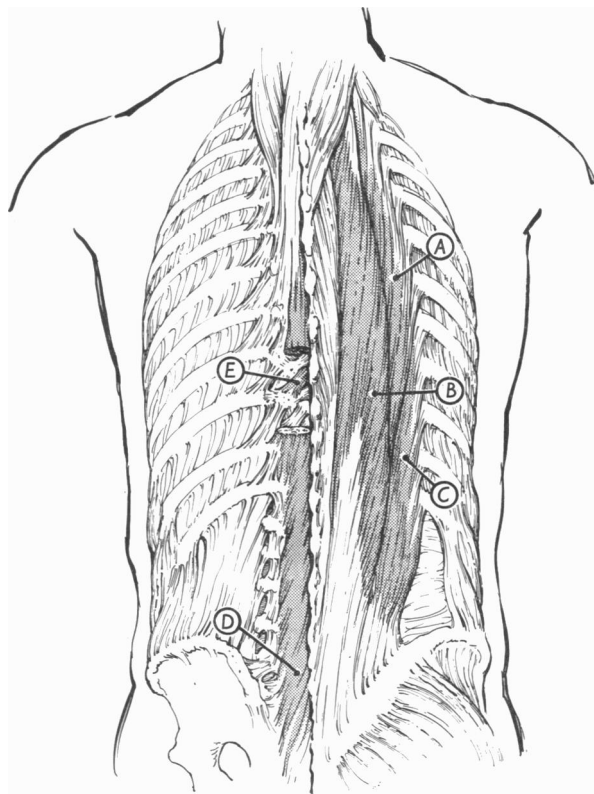


Fig. 1. Position of electrodes in muscles (all were actually placed on right side; they are shown on both sides for convenience). *A*, Iliocostalis dorsi; *B*, longissimus dorsi; *C*, iliocostalis lumborum; *D*, multifidus; *E*, rotatores.

system is similar to that described by Inman, Ralston, Saunders, Feinstein & Wright (1952). The output represents the average sum of the amplitudes of the muscle action potentials. The integrator rise time was 10 msec., and the decay time was 60 msec.

The electrodes were placed in the muscles, all on the right side, at the locations given in Table 1 and Fig. 1.

In the first three muscles listed, the needles were inserted until they impinged on

the ribs and were then withdrawn, leaving the electrodes in place. In the multifidus, the needles were inserted until they just pierced the posterior layer of the thoracolumbar fascia, which could be felt as it was entered. In the rotatores, the needles were inserted in a caudal direction until the laminae of the vertebrae were impinged.

Five healthy adult males were used as subjects for this study. Electromyographic recordings were obtained when the subjects performed the following trunk motions, following a simple set of directions:

- (1) Standing at rest.
- (2) Flexion and extension.
- (3) Relaxed and in full extension.
- (4) Rotation in the erect position.
- (5) Lateral flexion in the erect position.
- (6) Rotation in the flexed position.
- (7) Rotation in the fully extended position.
- (8) Lateral flexion in the flexed position.
- (9) Lateral flexion in the fully extended position.

Extension includes only that motion from a flexed position to the erect position, while full extension is extension beyond the erect position. Normal full extension is relaxed, while beyond that position it becomes forced.

RESULTS

In the analysis of results given below, the most important similarities and differences in the EMG records from the five subjects are described. The last four exercises are compound movements (in which the subject either flexed or fully extended the trunk, then rotated or flexed the trunk laterally, and finally returned to the erect position), and, in general, the results were predictable from those of the first five exercises. The new features that did appear will be outlined under the appropriate headings.

Standing at rest

The longissimus dorsi muscle showed continuous slight to moderate activity in all subjects; only with the back in unforced extension was this muscle, according to the recordings, inactive. The rotatores were continuously active in all except one subject, in whom the recordings showed periodic activity. A position of rest for the iliocostalis dorsi and lumborum and the multifidus was easily found, although these muscles became periodically active as the subject swayed slightly forward.

Flexion and extension (Fig. 2)

For this exercise the subject was instructed to bend forward as far as possible, rest in that position, and then extend to the erect position. During flexion, all the muscles tested were active. During rest in the fully flexed position, the multifidus and the rotatores were inactive but, in most subjects, slight activity was recorded for one or more of the erector spinae muscles. The iliocostalis dorsi, in particular, was usually active in this position. Records from all subjects showed a definite decrease in muscle activity in the fully flexed position as compared with the partially flexed

position; however, in only one subject were all the muscles inactive. With extension to the erect position, all the muscles again became more active initially. This activity rapidly fell off as the extended position was reached.

Relaxed and forced full extension (Fig. 3)

In this exercise, the subject was instructed to lean back, but not so far as to be uncomfortable, then force himself backward as far as possible, and finally to return to the erect position. The first step gave the position of relaxed full extension, and

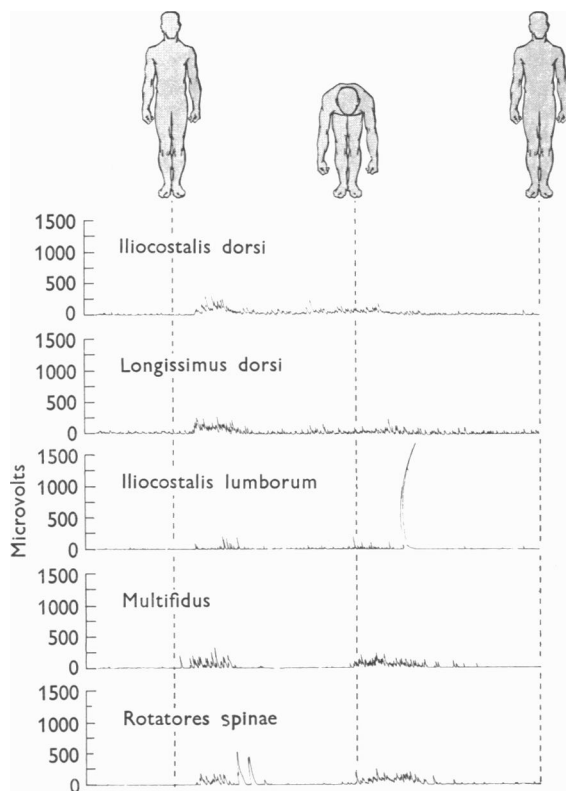


Fig. 2. Recordings of muscle activity during flexion and extension. This and the following figures show continuous recordings made during continuous movement from one position to the next.

all the muscles were found to be almost completely inactive. The next step, extreme or forced extension, was accompanied by activity in all the muscles tested except the multifidus. With resumption of the erect position, some activity was seen in most of the muscles.

Rotation in the erect position (Fig. 4)

The erector spinae muscles were generally active during ipsilateral rotation and the rotatores and multifidus during contralateral rotation. In the first type of rotation, the longissimus dorsi was particularly active—as would be expected from a

knowledge of the anatomy involved. The erector spinae muscles on one side and the rotatores and multifidus on the opposite side are therefore complementary in helping to cause rotation of the trunk. Occasionally, however, the erector spinae group showed slight activity during contralateral rotation and the rotatores and multifidus slight activity during ipsilateral rotation, with rotation resulting from an imbalance of activity. It was also noted, in records from all the subjects, that much less activity occurred during return to the original position than during rotation away from it.

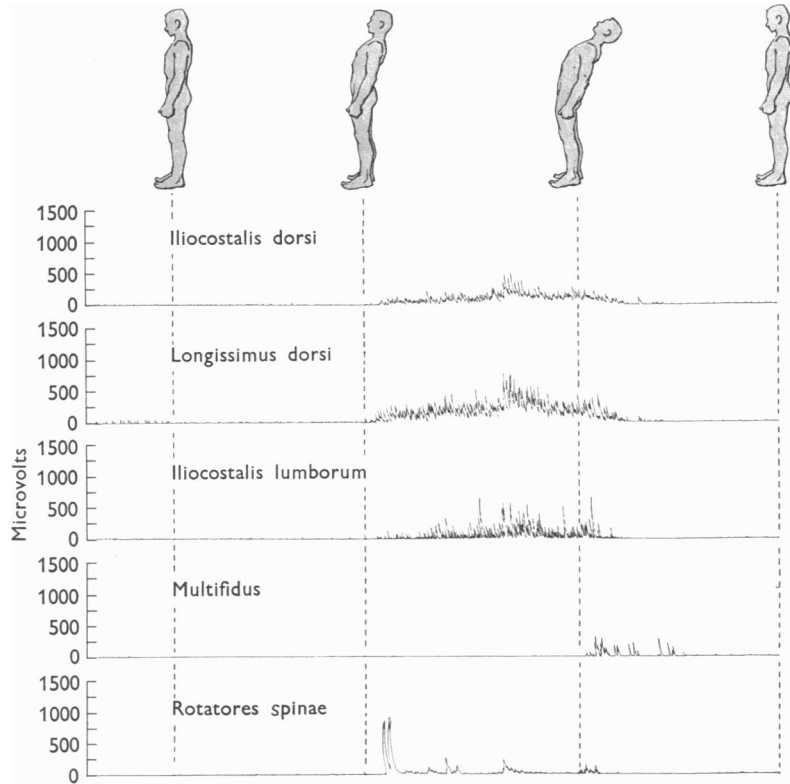


Fig. 3. Recordings of muscle activity during relaxed and forced full extension.

Lateral flexion in the erect position (Fig. 5)

In four of the five subjects, definite activity was seen in the records for the erector spinae group during ipsilateral flexion, while contralateral flexion was usually accompanied by slight activity in all the muscles. This observation would indicate that the trunk is pulled over to one side by an imbalance in the activities of the erector spinae muscles of both sides. The fact that the trunk must be pulled over by the ipsilateral muscles is in contrast to what happens in forward flexion, when the trunk is lowered in opposition to the force of gravity. However, in one of the subjects (C.C.), the reverse occurred: there was more activity in the erector spinae

muscles during contralateral flexion. This subject was tall and thin and was the most lithe of the group. In all subjects, as in the case of rotation, there was much less activity during return to the erect position than during flexion away from it.

Rotation in the flexed position (Fig. 6)

Rotation in the flexed position did not produce as much decrease of activity as was observed in the isolated flexion motion, since, in this compound movement, the subjects were not consciously trying to relax in the flexed position. Otherwise, the

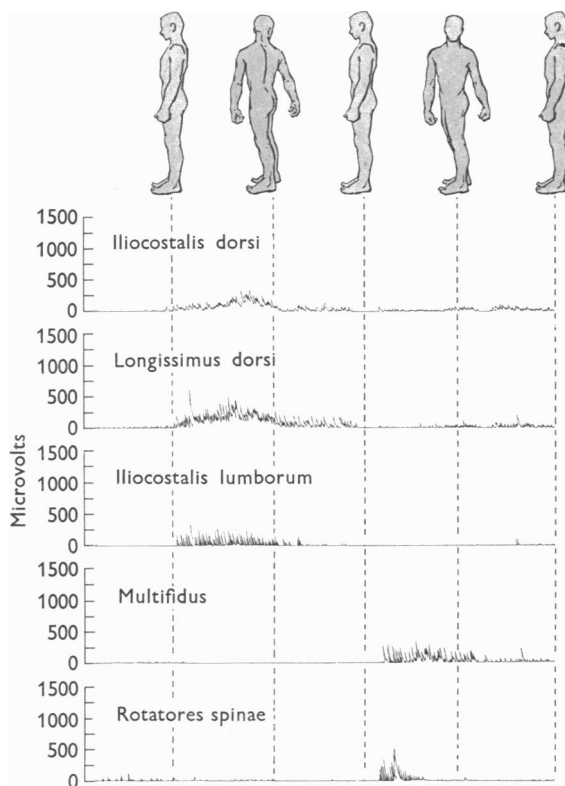


Fig. 4. Recordings of muscle activity during rotation in erect position.

activity during rotation itself was essentially the same. In most cases, the absolute levels of activity (but not the relative changes of activity) were greater than were observed during rotation in the erect position. This fact may be attributed to the awkward nature of the movement and the need for increased stability. In two subjects the multifidus and the rotatores were active throughout the exercise.

Rotation in the fully extended position (Fig. 7)

With this exercise the almost complete absence of stabilizing or background activity was noted. In all cases, the erector spinae muscles were most active in ipsilateral rotation and the rotatores in contralateral rotation. Otherwise, slight or

no activity was seen in the records for these muscles in other parts of the exercise. Thus, the two antagonist groups in rotation appear not to act together to the degree noted when the subject rotated in the erect position. In all subjects, the multifidus showed no activity during rotation in the fully extended position.

Lateral flexion in the flexed position (Fig. 8)

In contrast to the preceding exercise, this exercise gave a high level of continuous stabilizing or background activity in all muscles. There was some increase in activity in the erector spinae group during ipsilateral flexion and a smaller increase

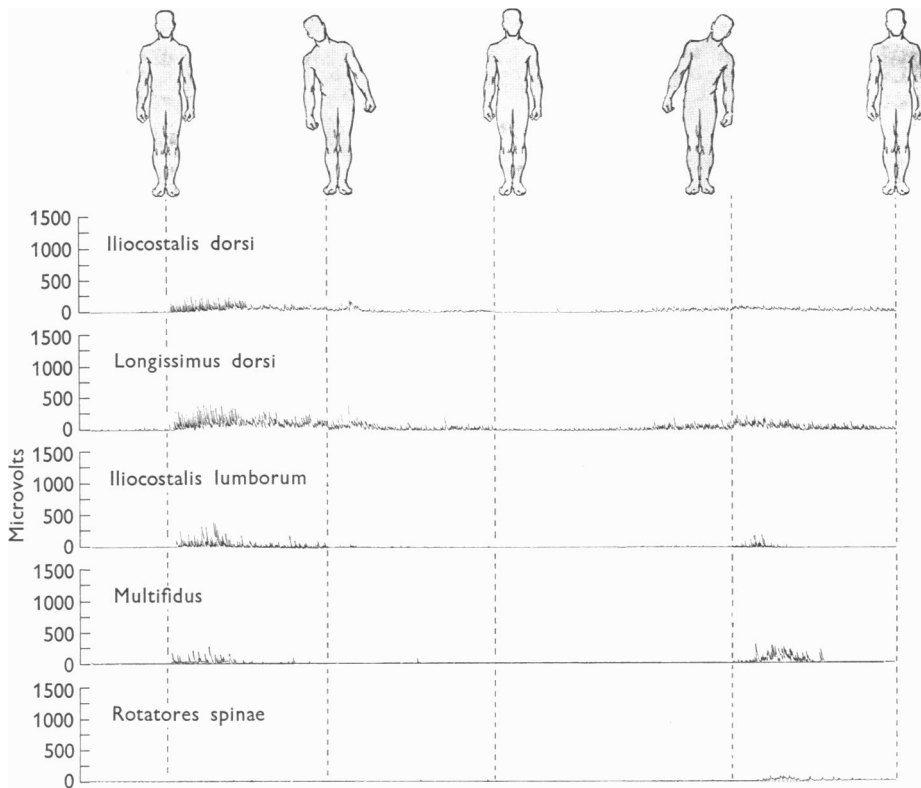


Fig. 5. Recordings of muscle activity during lateral flexion in erect position.

in activity during contralateral flexion. However, frequently the activity was so continuously high that it was difficult to detect any change associated with lateral flexion.

Lateral flexion in the fully extended position (Fig. 9)

Once the trunk was in the fully extended position, the multifidus and the rotatores showed slight or no activity with further motions. In four subjects, the erector spinae group was extremely active during ipsilateral flexion and inactive otherwise. In the more lithe subject (C.C.), the erector spinae group was most active with contralateral flexion and less active with ipsilateral flexion.

DISCUSSION

With the trunk in the erect position, the longissimus dorsi—the largest muscle studied—was continuously active, while the other back muscles were periodically active as the subject shifted his body weight slightly. With movements of the trunk in the sagittal plane, the erector spinae muscles, as well as the rotatores and the multifidus, were active in opposing the force of gravity in flexion and extension and were completely inactive in relaxed full extension.

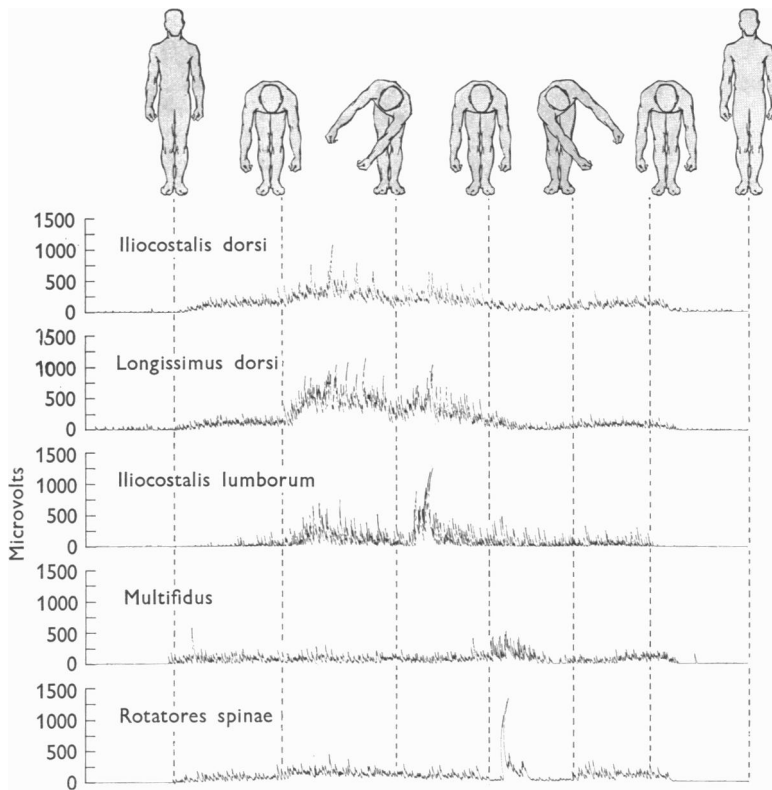


Fig. 6. Recordings of muscle activity during rotation in flexed position.

Lateral flexion in the frontal plane was accompanied by bilateral activity in the erector spinae group, with flexion resulting from an imbalance of the forces exerted by the two sides. In most of the subjects this imbalance was in favour of the ipsilateral muscles, which thus supplement the force of gravity in pulling the trunk over. In one particularly lithe person the balance was in the other direction, with the contralateral muscles lowering the trunk.

In rotation of the trunk, the rotatores and the multifidus are obviously effective in contralateral rotation and the erector spinae in ipsilateral rotation, but the latter probably act more to stabilize the trunk than to initiate rotation. For example, in right rotation the left external oblique muscle contracts and causes left lateral

flexion, as well as rotation, and the right erector spinae muscles then contract to balance the lateral flexion (Lucas, 1960; Partridge & Walters, 1959). While their activity during ipsilateral rotation is clear, their 'function' is a matter of interpretation.

In the fully flexed position, all the subjects were able to relax their back muscles a considerable amount, thus leaving the vertebral column almost 'hanging' on its ligaments. Complete relaxation, or absence of all electrically determinable activity, of all muscle occurred in only one subject. It is important to note that in compound

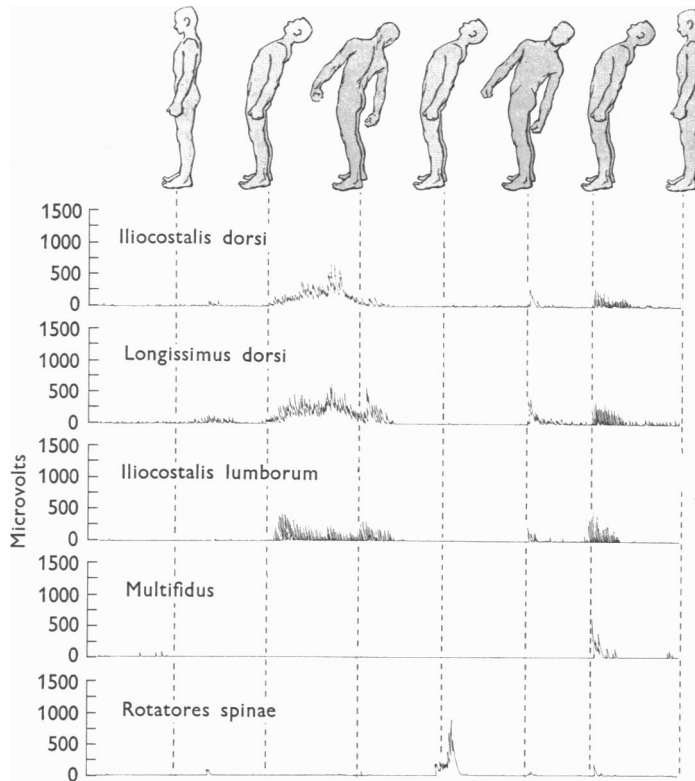


Fig. 7. Recordings of muscle activity during rotation in the fully extended position.

movements, when the subject was not trying to relax, this decrease in activity was much less marked or did not occur at all. The records of this study, then, support the view that flexion-relaxation (as described by Floyd & Silver, 1951) can occur, but we feel that in normal bending movements it occurs infrequently and only to a limited extent.

In all movements (such as lateral flexion and rotation) that involve a deviation of the trunk from the midline position, it might be expected that the muscle effecting the movement would act to return the trunk to its original position. This, however, was not indicated on our records, for little activity was seen during return of

the trunk to the midline. It might therefore be suggested that such factors as ligaments of the spine and muscle elasticity act to help return the trunk to the midline position.

The three muscles of the erector spinae group considered here (longissimus dorsi, iliocostalis dorsi, and iliocostalis lumborum) do not always show parallel activity, and one may be active while the other two are inactive (for instance, the longissimus dorsi during erect standing). In most movements, however, they may be considered together. While, in this study, the relative activities of the three muscles varied a great deal, the total activity of the group was approximately the same in all the subjects in any given motion.

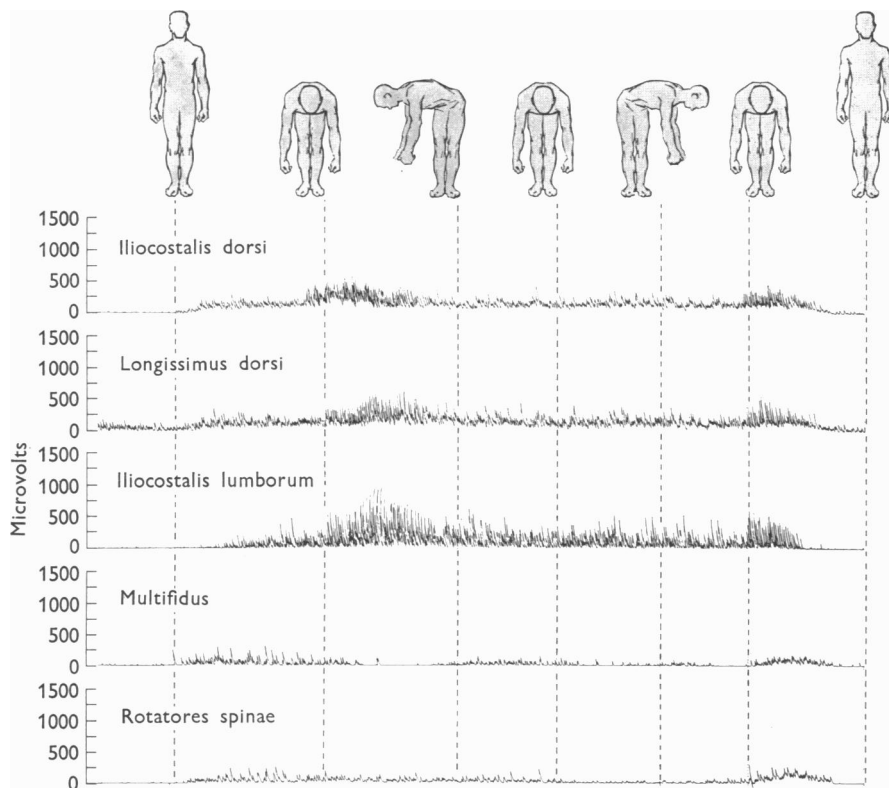


Fig. 8. Recordings of muscle activity during lateral flexion in flexed position.

SUMMARY

The erector spinae, multifidus, and rotatores muscles were studied electromyographically on five human subjects to determine their individual functions in five simple and four compound trunk motions.

It is apparent that, in the various trunk movements, a back muscle may at times initiate movement and at other times stabilize the trunk. Almost all the move-

ments of the back result from interaction of the various muscles. It has, however, been possible to record the activity of individual muscles and, in some cases, to isolate their functions by means of electromyography.

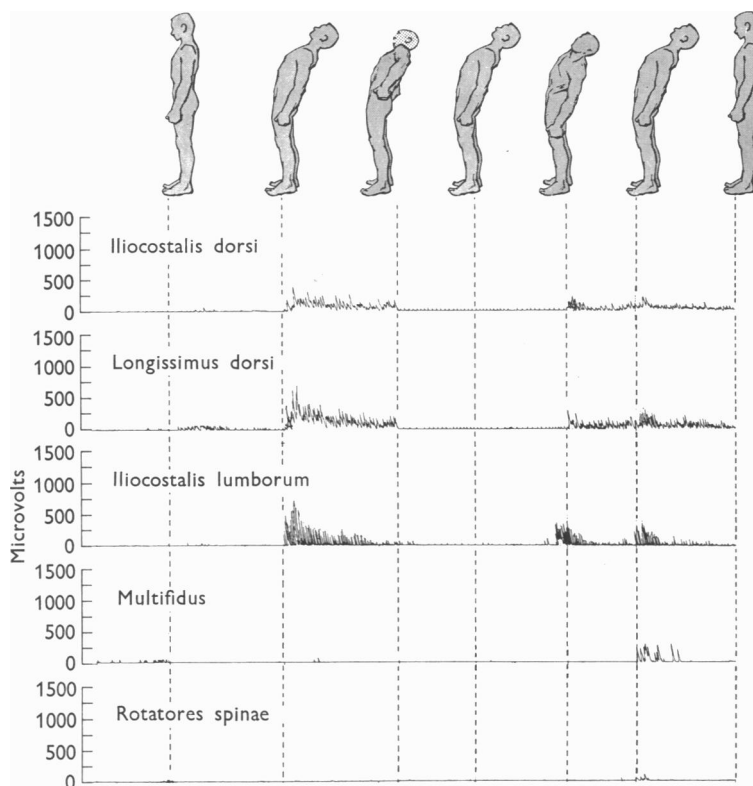


Fig. 9. Recordings of muscle activity during lateral flexion in fully extended position.

REFERENCES

- FLOYD, W. F. & SILVER, P. H. S. (1951). Function of erectors spinae in flexion of the trunk. *Lancet*, **1**, 133-134.
- FLOYD, W. F. & SILVER, P. H. S. (1955). The function of the erectors spinae muscles in certain movements and postures in man. *J. Physiol.* **129**, 184-203.
- INMAN, V. T., RALSTON, H. J., SAUNDERS, J. B. DE C. M., FEINSTEIN, B. & WRIGHT, E. W., JR. (1952). Relation of human electromyogram to muscular tension. *Electroenceph. Clin. Neurophysiol.* **4**, 187-194.
- JOSEPH, J. (1960). *Man's Posture: Electromyographic Studies*. Springfield, Ill.: Charles C. Thomas, Publisher.
- JOSEPH, J. & MCCOLL, I. (1961). Electromyography of muscles of posture: Posterior vertebral muscles in males. *J. Physiol.* **157**, 33-37.
- LUCAS, D. B. (1960). Unpublished data.
- PARTRIDGE, M. J. & WALTERS, C. E. (1959). Participation of the abdominal muscles in various movements of the trunk in man: an electromyographic study. *Phys. Ther. Rev.* **39**, 791-800.
- PORTNOY, H., & MORIN, F. (1956). Electromyographic study of postural muscles in various positions and movements. *Amer. J. Physiol.* **186**, 122-126.