

# Peritoneal Approach to Prosthetic Mesh Repair of Paraostomy Hernias

PAUL H. SUGARBAKER, M.D.

A new method for repair of large hernias at stoma sites is presented. The old abdominal incision is reopened and prosthetic mesh is sutured in place aseptically. The bowel courses above the mesh to be secured to the lateral abdominal wall creating a flap valve. Seven paraostomy hernia repairs in six patients were performed with no recurrences in a 4- to 7-year follow-up. The peritoneal approach to insertion of prosthetic mesh into the hernia defect is recommended especially for recurrent paraostomy hernias. This technique is appropriate for a hernia that possesses a large fascial defect.

THE INCIDENCE OF PARAOSTOMY HERNIA approaches 30% following abdominoperitoneal resection.<sup>1-2</sup> Following more extensive dissections, such as pelvic exenteration, the incidence is yet higher. Some authors have suggested that paracolostomy herniation may be reduced if the colon is brought to the abdominal wall through a retroperitoneal approach.<sup>3</sup> Others have found this to reduce the incidence of hernia little or not at all.<sup>2,4</sup>

The incidence of paraostomy hernia recurrence following a standard repair is difficult to determine from the surgical literature. However, success with the technique is limited and recurrence rates of 50% are not unusual.

Three different approaches to paraostomy hernia repair have been previously reported. Thorlakson advocated a direct surgical attack on the hernia; the hernia, usually occurring lateral to the stoma site, is opened, the sac is dissected away, colon is secured to the abdominal side wall and fresh fascial edges are tightened up around the intestine.<sup>5</sup> Goligher suggested an operation to resite the colonic stoma with direct repair of the abdominal wall defect.<sup>4</sup>

In large hernias present many years or recurring following repair, direct reapproximation of fascia to close the defect may not be possible. Use of a prosthetic mesh is indicated in this situation. However, its use may

*From the Surgery Branch, Division of Cancer Treatment, National Cancer Institute, National Institutes of Health, Bethesda, Maryland*

be contraindicated because of bacterial contamination of the mesh by the stoma itself which must be within the operative field. Rosin and Bonardi, Abdu, and more recently Garajobst and Sullivan advocated the use of Marlex mesh within a contaminated operative field surrounding a stoma. They reported only minor problems with sepsis in the seven patients studied.<sup>3,6,7</sup> Nevertheless, the use of foreign material in a contaminated operative field should be avoided if possible.

In the present report, prosthetic mesh is advocated for repair of the fascial defect without the problems that bacterial contamination of the operative field presents. The stomal bud is not disturbed so that return to normal intestinal function is rapid. In addition, the colon is led out through a mesh flap valve so that further herniation out around the colon is unlikely.

## Methods and Results

The intestine is prepared as for a colonic operation using mechanical and antibiotic preparation. A short course of perioperative systemic antibiotics is begun before surgery. To facilitate location of the colon intraoperatively, a large rubber catheter or colonoscope is passed approximately 20 cm into the colon. The colonic stoma is walled off from the operative field using an adhesive plastic drape.

Figure 1 shows a large paracolostomy hernia appropriate for this type of repair. Figure 2 shows the anatomic situation one encounters with small intestine alongside the exiting colon and often omentum caught up in the hernia sac. Fascial edges are attenuated and the peritoneum and skin are greatly stretched out.

The surgical approach to this procedure differs from other repairs done for hernias at the site of the colonic stoma in that the old midline or paramedian abdominal incision is reopened. After the old incision has been

Reprint requests: Paul H. Sugarbaker, M.D., Head, Colorectal Cancer Section, Surgery Branch, National Cancer Institute, Bldg. 10, Rm. 2B07, Bethesda, MD 20205.

Submitted for publication: September 19, 1984.

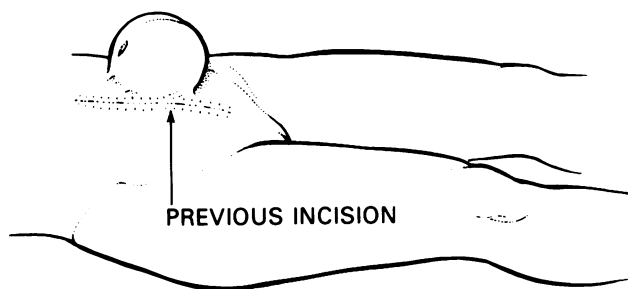


FIG. 1. In a paracolostomy or paraostomy hernia, bowel and omentum are usually found within the hernia sac.

widely opened, Kocher clamps or a self-retaining retractor are used to elevate the fascial edge of the left side of the abdominal incision. As adhesions are dissected away, the contents of the hernia sac are delivered into the abdominal cavity (Fig. 3). The portion of the colon exiting through the colonic stoma is easily located because it was earlier intubated with a large catheter or colonoscope.

It is important to identify clearly the fascial ring at the perimeter of the hernia. It is not necessary to dissect the parietal peritoneum out of the hernia sac, but this is usually accomplished without difficulty if the exposure is adequate. A ring of prosthetic mesh is cut so it will snugly fill the fascial defect. Individual sutures are placed at approximately 1-cm intervals around the fascial ring except directly laterally where the colon will enter the abdominal cavity from the subcutaneous tissue. Sutures are secured to the mesh so that each suture is under the same stress, and it is, therefore, unlikely that individual sutures will pull through. The colon is led out over the mesh to the left lateral abdominal wall and is secured there with sutures (Fig. 4). The abdominal incision is closed in a routine manner (Fig. 5).

Six recurrent and one primary paraostomy hernias have been repaired using prosthetic mesh positioned

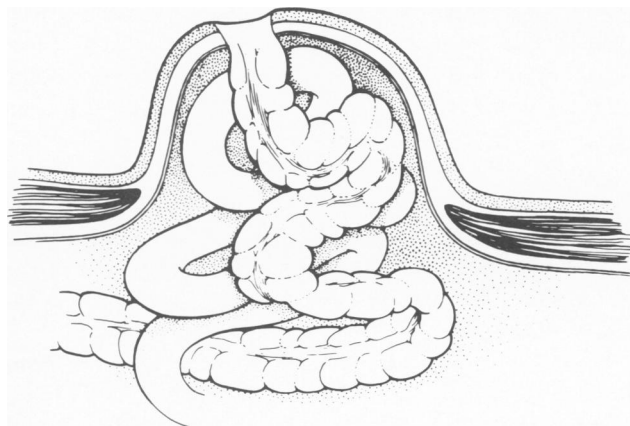


FIG. 2. Anatomic situation usually encountered in a recurrent paraostomy hernia. The fascial ring is large with attenuated edges.

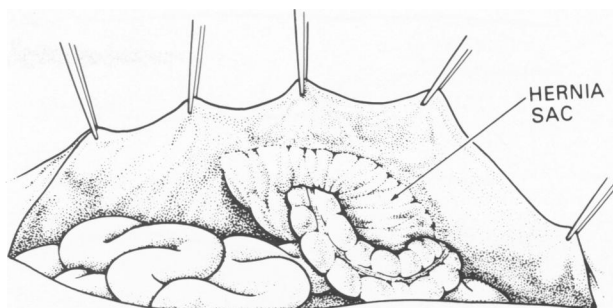


FIG. 3. A peritoneal approach is taken to expose the paraostomy hernia. Usually this means opening an old midline or paramedian incision.

through a peritoneal approach (Table 1). No recurrences have been observed with a minimum 4-year follow-up. In Patient No. 4, a hernia defect surrounding an ileal conduit had caused incarceration of small bowel within this hernia. This resulted in anuria. Prosthetic mesh repair has provided 5 years of good function. No other ostomy problems such as prolapse, fistulization, stenosis, or retraction have resulted from the repair of these seven paraostomy hernias.

### Discussion

In a small paraostomy hernia in which a small fascial defect leads to the accumulation of bowel and omentum in a subcutaneous pocket, hernia repair is often accomplished by a direct surgical attack on the problem. The hernia is opened, the fascial defect is closed with non-absorbable suture material, and the hernia defect adjacent to the bowel wall is carefully obliterated.<sup>5</sup> Although this simple surgical procedure meets with success in most patients, success is not always achieved. Patients with recurrent paraostomy hernias tend to have a large fascial defect that can only be closed under great tension. Even with the most meticulous technique, repair of these large hernias usually fails and recurrent hernia can be seen sometimes just weeks after repair. In this report we present a method of hernia repair utilizing prosthetic

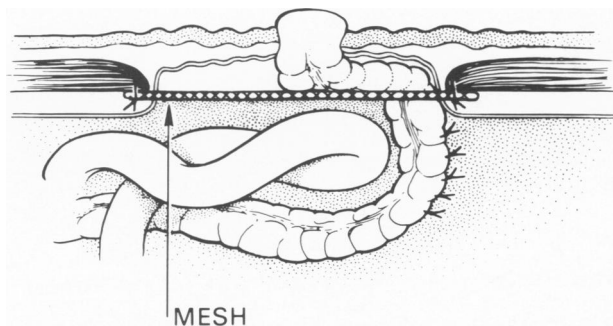


FIG. 4. Prosthetic mesh is used to close the hernia defect. The bowel loop exiting at the ostomy site is secured lateral to the mesh.

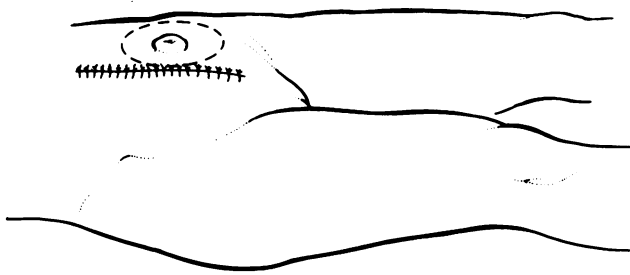


FIG. 5. The abdomen is closed with the hernia repaired.

mesh. The dangers of infection of this mesh are kept at a minimum because the operative field is completely uncontaminated. Contamination is prevented by positioning the prosthetic mesh into the hernia defect through a peritoneal approach.<sup>8</sup>

Paraostomy hernias occur almost exclusively at the lateral aspect of the bowel brought up through the abdominal wall. One wonders if the initial defect is failure of the bowel serosa to adhere to the tissues of the abdominal wall. Sutures are difficult to position lateral to the exiting segment of bowel; the difficulty of placing sutures in this area may lead to hernias occurring at this site.

Our experience with prosthetic mesh repair of seven paraostomy hernias has been excellent. In long-term

follow-up the prosthetic mesh has not become infected. The fibrous ingrowth that surrounds the mesh with time has prevented recurrence of a hernia in all seven ostomy sites. Other problems such as prolapse and stenosis have not occurred. In the urostomy patients no urine stasis within the conduit or increase in the frequency of urinary tract infections occurred. Our unusually low incidence of recurrence may be in part due to the flap-like valve that exists over the bowel as it passes from the peritoneal cavity to exit at the skin. In this situation, an increase in intra-abdominal pressure is exerted onto the mesh and then onto the bowel. The oblique course of the bowel behind the overlying prosthetic mesh prevents intra-abdominal forces from separating the bowel from the lateral portion of the ostomy. Further surgical experience with this paraostomy hernia repair is indicated; however, our favorable initial results suggest that it is indicated especially for recurrent hernias or hernias with a large fascial defect.

### References

1. Kronborg O, Kramhoft J, Backer O, Sprechler M. Late complications following operations for cancer of the rectum and anus. *Dis Colon Rectum* 1974; 17:750-753.
2. Marks CG, Ritchie JK. The complications of synchronous combined excision for adenocarcinoma of the rectum at St. Mark's Hospital. *Br J Surg* 1975; 62:901-905.
3. Harshaw DH, Gardner B, Vives A, Sundaram KN. The effect of technical factors upon complications from abdominal perineal resections. *Surg Gynecol Obstet* 1974; 139:756-758.
4. Goligher JC. *Surgery of the Anus, Rectum and Colon*, 3rd ed. London: Bailliere Tindall, 1975; 737.
5. Thorlakson RH. Technique of repair of herniations associated with colonic stomas. *Surg Gynecol Obstet* 1965; 120:347.
6. Abdu RA. Repair of paracolostomy hernias with marlix mesh. *Dis Colon Rectum* 1982; 25:529-531.
7. Garnjobst W, Sullivan ES. Repair of paraileostomy hernia with polypropylene mesh reinforcement. *Dis Colon Rectum* 1984; 27:268-269.
8. Sugarbaker PH. Prosthetic mesh repair of large hernias at the site of colonic stomas. *Surg Gynecol Obstet* 1980; 150:576-578.
9. Rosin JD, Bonardi RE. Paracolostomy hernia repair with Marlex mesh; a new technique. *Dis Colon Rectum* 1977; 20:299.

TABLE 1. Results of Prosthetic Mesh Repair of Seven Paraostomal Hernias

Patient	Initial Procedure	Site of Hernia	Previous Recurrences	Follow-up (Years)
1	Pelvic exenteration	Colostomy	2	7
2	Pelvic exenteration	Colostomy	1	6
3	Abdominoperineal resection	Colostomy	1	6
4	Pelvic exenteration	Urostomy	0	5
5	Pelvic exenteration	Colostomy	2	4
5	Pelvic exenteration	Urostomy	1	4
6	Pelvic exenteration	Colostomy	1	4