

# Sclerosing Cholangitis after Continuous Hepatic Artery Infusion of FUDR

M. MARGARET KEMENY, M.D.,\* HECTOR BATTIFORA, M.D.,† DOUGLAS W. BLAYNEY,‡ GARY CECCHI, M.D.,‡ DAVID A. GOLDBERG,‡ LUCILLE A. LEONG, M.D.,‡ KIM A. MARGOLIN, M.D.,‡ JOSE J. TERZ, M.D.\*

Eight of 46 (17.4%) patients treated in our trial of continuous hepatic artery infusion (CHAI) of fluorodeoxyuridine (FUDR) by Infusaid® pump developed biliary strictures. The lesions were clinically, radiographically, and pathologically identical to the idiopathic sclerosing cholangitis frequently seen in association with inflammatory bowel disease. Treatment included immediate cessation of intraarterial FUDR, and surgical or percutaneous drainage of the biliary tree if it was dilated. Two of the eight patients died of the complication. Three patients stabilized after biliary system drainage, and two patients improved on observation only. The pathogenesis of this complication is not understood. This report details the clinical and pathological features of this entity.

HEPATIC ARTERY INFUSION has been used for treatment of cancer metastatic to the liver with various degrees of enthusiasm in the past. Because percutaneous catheters are associated with septic complications and cannot be maintained for a long time, this method of perfusion is discouraging.<sup>1</sup> The recent introduction of a totally implantable pump (Infusaid®), which is able to deliver continuous hepatic arterial infusion (CHAI), has revived interest in this form of regional therapy. This new modality of regional infusion is seldom associated with catheter infection and therapy can be administered for months to years.<sup>2</sup> As experience is gained with the use of the Infusaid pump, new complications are being recognized: "chemical hepatitis," cholecystitis, and gastritis are the most commonly reported.<sup>2</sup> These complications usually resolve after temporary cessation of therapy. We have observed a significant number of patients receiving CHAI who have also developed permanent strictures in their biliary system, either intrahepatic, extrahepatic, or a combination of both. The clinical and radiological features of these strictures resemble idiopathic sclerosing cholangitis.<sup>3</sup> This process, which may be irreversible, has significant implications in the therapeutic management and survival of these

*From the Department of General and Oncologic Surgery,\* the Division of Anatomic Pathology,† and the Department of Medical Oncology,‡ the City of Hope National Medical Center, Duarte, California*

patients. This report reviews our experience with the newly observed complication of hepatic intraarterial fluorodeoxyuridine (FUDR).

## Procedures and Methods

In February 1982, we initiated a prospective randomized trial designed for pathologically staged patients with colorectal cancer whose only demonstrable site of metastasis was the liver. The study evaluated the effectiveness of resection of one or more hepatic metastases in combination with long-term, intermittent CHAI of FUDR with an implantable pump.<sup>4</sup> All patients without obvious extrahepatic metastases received laparotomy. The patients with solitary metastases were randomized to either surgical resection alone or to surgical resection plus CHAI of FUDR with an Infusaid pump. The patients with multiple resectable nodules were randomized to resection plus pump or to pump alone. Those patients with multiple unresectable metastases all had a pump implanted, but half were randomized to start on intravenous 5FU chemotherapy. The hepatic resections were wedge resections unless lobectomy or segmentectomy were technically simpler. Patients had the Infusaid pumps implanted in the fashion reported by other authors.<sup>4</sup> If a patient had two hepatic arteries, two pumps were used.

After surgery, patients had their pumps refilled every 2 weeks. FUDR at 0.3 mg/kg/d was placed in the pump every other visit and alternated with saline containing heparin (1000 U/cc). One cycle of therapy lasted throughout 4 weeks. Patients were followed with complete blood counts, platelet counts, and liver chemistries every 2 weeks, as well as with monthly carcinoembryonic antigen (CEA) determinations; abdominal computerized axial tomography (CAT) scans were done every 3

Reprint requests: M. Margaret Kemeny, M.D., Department of General and Oncologic Surgery, City of Hope National Medical Center, 1500 E. Duarte Road, Duarte, CA 91010.

Submitted for publication: February 6, 1985.

TABLE 1. *Patients with Biliary Stenosis*

Case No.	No. of Hepatic Metastases	Protocol Treatment	Bilirubin	AP*	SGOT/SGPT†	Radiographic Findings	Therapy	Results	Treatment Days	Total Drug Delivered (mg/kg)
1	1	Resection and pump	5.2	2082	277/576	Multiple strictures of the common duct	T-tube	Improvement in liver function, no liver metastases	117	24.8
2	4	Pump only	10.8	1386	207/222	Intrahepatic biliary narrowing, stricture extrahepatic bile duct	Observation	Death from hepatic failure	287	87.5
3	8	Pump only	9.2	750	161/330	Strictures of the intrahepatic bile ducts and common duct	T-tube	Death from hepatic failure	168	36.1
4	5	Resection and pump	7.1	600	300/122	Intrahepatic obstruction of the right and left duct	Percutaneous drainage	Improvement in liver function No liver metastases	100	17.4
5	2	Pump only	5.2	460	224/312	Narrowing in common duct right and left intrahepatic duct	T-tube	Improvement in liver function, no liver metastases	42	12.6
6	15	Pump only	5.4	1212	139/188	Multiple biliary strictures intra- and extrahepatic	Observation	Improvement in liver function, progression of liver metastases	56	15.4
7	3	Pump only	7.1	1932	80/39	Autopsy finding: 80% stenosis of right and left hepatic ducts	None	Dead from myocardial infarct	168	34
8	4	Pump only	3.5	1177	36/38	Stricture of common duct and right and left duct	Observation	Improvement in liver function, progression of liver metastases	98	18.2

\* Alkaline phosphatase.

† SGOT = serum glutamic oxaloacetic transaminase; SGPT = serum glutamic pyruvic transaminase.

months, after operation. If a patient experienced abdominal pain, severe bloating, significant diarrhea, or rising liver enzymes during the chemotherapy cycle, the FUDR was removed from the pump. When these symptoms resolved or when the liver function tests indicated that the serum glutamic oxaloacetic transaminase (SGOT) was less than three times normal, the bilirubin was less than two times normal, and the alkaline phosphatase was less than three times normal, the infusion of FUDR was restarted. However, the FUDR was resumed at a concentration of only 0.1 mg/kg/24 hr with 0.1 mg/kg/24 hr increments every treatment cycle until a dose of 0.3 mg/kg/24 hr was reached.

Between February 1982 and February 1984, 65 patients underwent laparotomy and 46 patients had pumps implanted. The complications related to the intraarterial chemotherapy included: chemical hepatitis (58.7%), cholecystitis (23%), and duodenitis, gastritis or ulcers (15%). All of these complications subsided with the discontinuation of therapy or with a cholecystectomy.

Eight patients (18.6%) developed strictures of either the intrahepatic or extrahepatic bile ducts (Table 1). The alkaline phosphatase level and the bilirubin were elevated in all of these patients. The diagnosis was made in all cases with either a percutaneous transhepatic cholangiogram (PTC) or an endoscopic retrograde cholangiopancreatogram (ERCP). Three patients had laparotomy, common bile duct exploration, and had a T-tube inserted (cases 1, 3, and 5). The liver in those patients was found to be free of cancer. One of these patients died of liver failure, and no cancer was found at postmortem examination (case 3). In the other two patients, results of the liver function tests (LFT) returned to normal. One patient (case 4) had transhepatic drainage of the bile ducts and her LFT results returned to normal. In the remaining four patients, the intraarterial therapy was terminated and their progress was monitored closely. One patient had slowly progressing deterioration of the results of his liver functions tests and died from liver failure (case 2). At autopsy, there was one small metas-

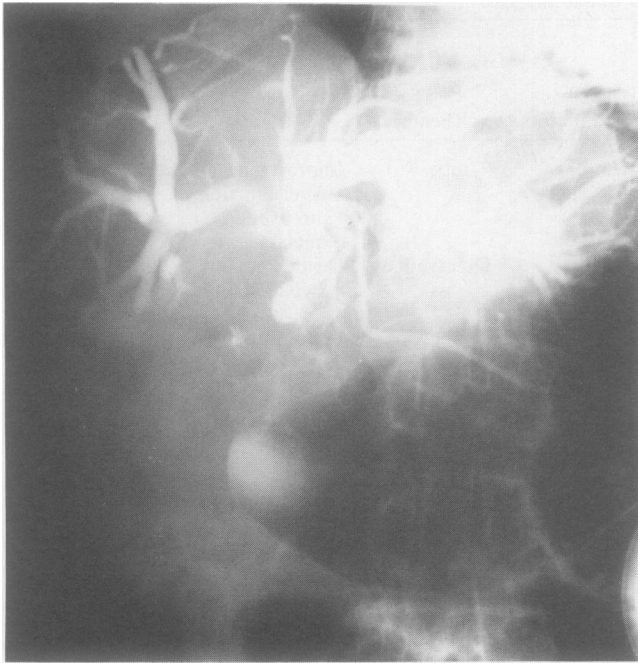

FIG. 1. Case 1: Cholangiogram (done by ERCP) which demonstrates multiple strictures in the common duct with proximal dilation.

tasis to the right lobe of the liver. One patient died from a myocardial infarction and had no carcinoma in his liver at autopsy (case 7). In two patients, results of the LFTs improved after cessation of CHAI therapy.

Once the diagnosis of sclerosing cholangitis was established, the patients received no further intraarterial chemotherapy. All of those patients had had a complete tumor response to the CHAI of FUDR with resolution of their metastases on CAT scans. Of the five surviving patients, three (cases 1, 4, and 5) seem to have a sustained response in their liver with no new metastatic disease and two have progressive metastatic liver disease (cases 6 and 8). Histopathologic findings have been the same for all of the patients studied. There was marked biliary fibrosis, with replacement of the bile duct wall by sclerotic collagenous tissue. The intrahepatic biopsies showed increased fibrous tissue in the portal spaces, predominantly around the ducts. Four representative cases will be presented, but Table 1 reviews all eight patients with this complication.

### Case Reports

**Case 1.** A 68-year-old man had a resection of Dukes' C carcinoma of the sigmoid with the finding of a synchronous solitary hepatic metastasis. At the City of Hope Hospital, 5 months later, he had a hepatic wedge resection and placement of an implantable pump for CHAI. He was administered FUDR therapy *via* the pump at 0.2 mg/kg/d 8 days after surgery. He had received three monthly cycles of FUDR at 0.3 mg/kg/d when he developed abdominal pain. Endoscopy

was negative for ulcers or gastritis. The patient was discharged when the pain subsided and restarted on chemotherapy. After receiving two further treatments at 0.2 mg/kg/d, results of his liver function tests began to rise (alkaline phosphatase, 814; bilirubin, 4.2; SGOT, 429; SGPT, 359; lactic dehydrogenase (LDH), 415). The diagnosis of chemical hepatitis was made and chemotherapy was discontinued for 4 months. Except for an elevated alkaline phosphatase (269), his liver function tests returned to normal. An ERCP done after the 4-month rest period demonstrated multiple strictures of the common bile duct (Fig. 1). Because his bilirubin was normal and the strictures were asymptomatic, he was restarted on chemotherapy at 0.2 mg/kg/d FUDR. After four courses, he redeveloped right upper quadrant pain and was taken to surgery for a cholecystectomy. At laparotomy, the gallbladder had areas of necrosis and stones. The area of the common duct was solidly fixed with fibrotic tissue, so the common duct could not be seen or palpated. After extensive dissection, the common duct was entered and a T-tube was left in place to drain the duct. The liver was palpated bimanually and no tumors were present.

The multiple biopsies of the common duct showed that the wall of the duct had been largely replaced by thick bands of collagenous tissue. No adenocarcinoma was present in the samples of liver from the previous resection site. Because of persistent high bile output, the T-tube was repositioned so that it extended through the ampulla into the duodenum. During the same procedure, the patient's Infusaid pump was removed; again, no tumor was seen. Four months later, the T-tube was pulled out accidentally and was not replaced. At eight months after his tube came out, the patient had no signs of jaundice, biliary dilatation, or cholangitis.

**Case 3.** A 47-year-old man had a Dukes' C sigmoid carcinoma removed in March 1982. Liver metastases was noted at surgery. He had an Infusaid pump implanted on August 25, 1982, and was started on CHAI of FUDR at 0.3 mg/kg/d 2 weeks later. Because of diarrhea and flu-like symptoms, his second course of chemotherapy was held for 1 month, started at 0.2 mg/kg/d, and then escalated to 0.3 mg/kg/d the following month. The abdominal pain returned in the right upper quadrant, and the chemotherapy was withheld again. In February 1983, he was admitted for a cholecystectomy for cholelithiasis. At operation, his porta hepatic area was noted to be fibrotic, and his liver biopsies revealed periportal fibrosis, but no liver metastases.

After his discharge, the patient was restarted on CHAI of FUDR and had four more courses of treatment. He then developed jaundice, with a bilirubin of 4.8. Liver function tests revealed the following: alkaline phosphatase, 344; SGOT, 81; SGPT, 123; and LDH, 143. Chemotherapy was withheld for 2 months until the jaundice disappeared. He then received FUDR at 0.1 mg/kg/d for one cycle, escalated to 0.15 mg/kg/d for two cycles, and 0.2 mg/kg/d for two more cycles. Two months after his last dose of FUDR, the patient was admitted with a bilirubin of 9.2; an alkaline phosphatase level of 760; LDH, 216; SGOT, 161; and SGPT, 330. ERCP examination revealed an obstruction at the porta hepatis. A PTC revealed strictures of intrahepatic bile ducts (Fig. 2). On January 16, 1984, a T-tube was placed during surgery. At laparotomy, his liver was free of metastatic disease but the porta hepatic area was very hard and fibrotic with total loss of normal tissue planes. The patient died 49 days after the operation from progressive liver and renal failure. At postmortem, no tumor was found in his liver. The wall of his bile duct was thickened and had been replaced by densely sclerotic collagenous tissue.

Within the parenchyma, the portal spaces showed increased bands of collagen around intrahepatic ducts.

**Case 5.** A 52-year-old woman had a positive liver scan 11 months after an anterior resection which had been done on August 10, 1982. She was sent to the City of Hope Hospital where, on July 27, 1983, an Infusaid pump was placed. After 3 months of CHAI of 0.3 mg/kg/d of FUDR, she began to develop epigastric pain. She was admitted for evaluation with a bilirubin level of 5.2; alkaline phosphatase, 460; SGOT, 224; SGPT, 312; and LDH, 185. A PTC revealed narrowing in the common bile duct and at the right and left hepatic ducts (Fig. 3). On November 11, 1983, she had placement of a T-tube (Fig. 4). No tumors were seen in the liver, and all liver biopsies revealed periportal fibrosis (Fig. 5). The T-tube remained in place for 3 months, but then came out and could not be replaced percutaneously. The patient's liver function is stable; alkaline phosphatase values are in the 200 range. She received no further intraarterial treatment after October 1983, and a CAT scan revealed no new lesions on her liver.

**Case 7.** A 68-year-old man had a low anterior resection on May 24, 1982, with synchronous bilobar liver metastases. He was referred to the City of Hope Hospital and had an Infusaid pump placed on September 22, 1982. One week later, he was started on CHAI of FUDR at 0.3 mg/kg/d. Because of some abdominal pain, his dose was reduced to 0.2 mg/kg/d. He again developed abdominal pain and was admitted for evaluation. Endoscopy at that time revealed duodenitis. His bilirubin level was 3.7 and his alkaline phosphatase level was 1078. On PTC a stricture in his common hepatic duct could be seen; a corresponding lesion was seen on CAT scan. The diagnosis was an increase of metastatic disease, and his chemotherapy was restarted at 0.2 mg/kg/d. His jaundice resolved and a follow-up CAT scan revealed that the lesion had regressed.

In April 1983, after four more courses of chemotherapy, a recurrent rectal carcinoma was diagnosed. The recurrent tumor was removed with positive margins on the pelvic wall. No

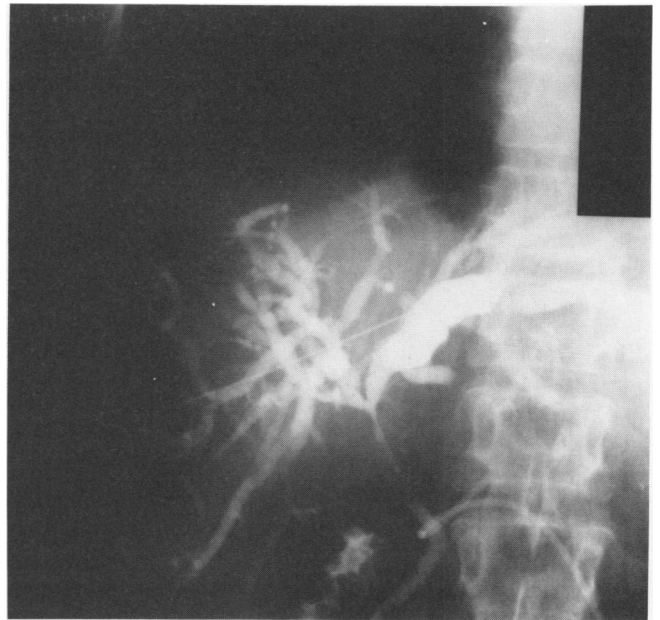


FIG. 3. Case 5: A PTC showing strictures at the bifurcation of the hepatic ducts extending into the common ducts.

liver metastases were seen at operation, but the area around the common duct was firm and fibrotic. Multiple liver biopsy specimens were negative for tumor; however, there was in-

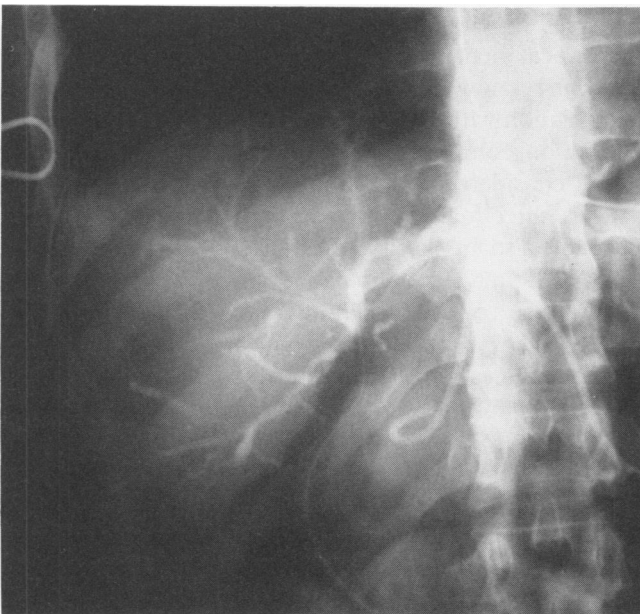


FIG. 2. Case 3: A PTC showing intrahepatic strictures of the bile ducts with obstruction at the common hepatic ducts.

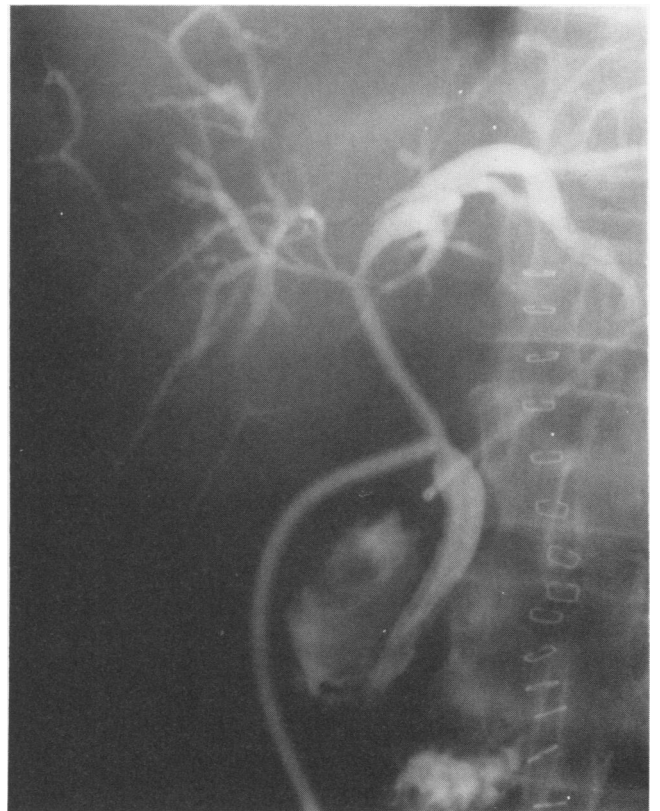

FIG. 4. Case 5: A T-tube cholangiogram showing placement of a T-tube from the bifurcation of the hepatic ducts to the duodenum.

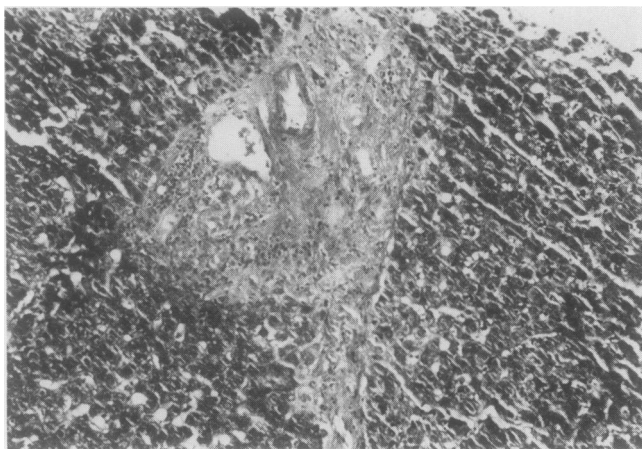


FIG. 5. Case 5: A hepatic biopsy with periportal fibrosis, especially around the biliary radicals.

creased fibrous tissue in the portal spaces, predominantly around the ducts and occasionally on adjoining portal areas.

After surgery, the patient received radiotherapy to his pelvis. One dose of 0.2 FUDR was administered in his pump after surgery, but further chemotherapy was held until completion of his radiotherapy. In August 1983, his intraarterial infusions were restarted at 0.2 mg/kg/d. After five treatments, he developed jaundice with a bilirubin of 7.1 and alkaline phosphatase, 1932. He received no further intraarterial chemotherapy. Two months later, he died from a massive myocardial infarction. An autopsy revealed that his right and left hepatic ducts were stenosed to 80% of their normal diameter. Histologically they appeared largely replaced by a dense, cellular scar-like fibrous tissue (Fig. 6). Fibrosis was also evident in the liver parenchyma around the biliary ducts (Fig. 7).

### Discussion

The concept of regional chemotherapy has attracted the interest of clinical investigators because of the expectation that organ-targeted chemotherapy will have

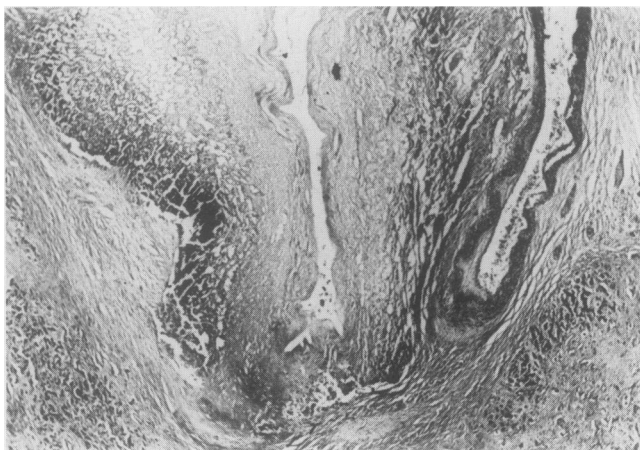


FIG. 6. Case 7: A biopsy of the bifurcation of the hepatic ducts with replacement of the duct wall by scar-like fibrous tissue.

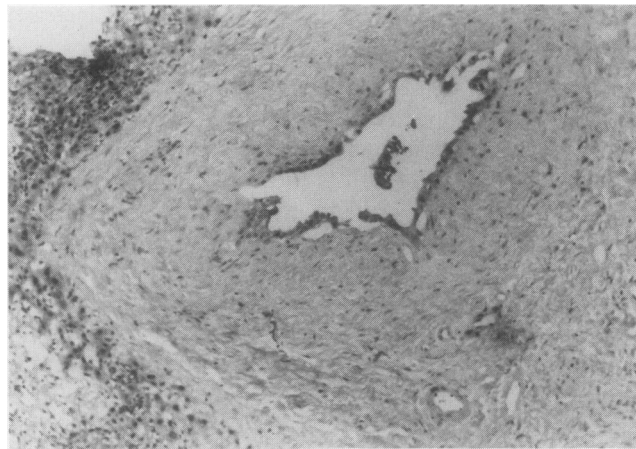


FIG. 7. Case 7: A hepatic biopsy showing fibrosis surrounding a dilated bile duct.

the pharmacological advantage of higher tumor drug concentrations, with minimal toxicity to normal peripheral tissues. A continuous infusion might overcome the short half-life of some drugs and will allow a protracted treatment through the period of remission. The significant complications seen during early trials with percutaneous catheters (*i.e.*, drug extravasation, gastric ulceration and bleeding, local and systemic sepsis, and thrombosis of visceral arteries) interfered with the design and completion of clinical trials.

The experience gained in the last 4 years with the totally implantable pump has shown that the objectives of intraarterial chemotherapy can be accomplished without the discouraging complications of the early trials. However, a new set of complications resulting from regional toxicity are recognized with increased frequency. Chemical hepatitis, cholecystitis, and duodenitis were the first known regional complications recognized in association with CHAI. Chemical hepatitis was the most common complication in our group (58.7%). Patients were considered to have chemical hepatitis when there was a three-fold rise in one of the transaminases and usually also in the alkaline phosphatase. There was a bilirubin value greater than 2 mg/100 in 90% of these cases. The cessation of intraarterial therapy resulted in the liver enzymes returning to normal in all cases. When liver enzymes were normal, therapy was resumed.

After cholecystitis developed in six of the first 19 patients (32%) and required cholecystectomy, we modified our procedure so that all patients underwent cholecystectomies at the time of the pump implantation procedure. This complication has been eliminated. Two of the six patients with cholecystectomies went on to develop sclerosing cholangitis.

Sclerosing cholangitis has not been previously described as a complication of FUDR infusion. Our patients



had clinical, radiographic, and pathological findings similar to the idiopathic sclerosing cholangitis frequently seen in association with inflammatory bowel disease.<sup>3</sup> The clinical picture was one of painless jaundice with elevated alkaline phosphatase levels. In those patients receiving CHAI of FUDR who developed chemical hepatitis, the levels of alkaline phosphatase were either minimally or greatly elevated; the significant elevation was the SGOT and SGPT levels—greater than three times normal. The same steep increase of the transaminases was not seen as frequently with the sclerosing cholangitis. The differential diagnosis was made by radiographic means, either through a PTC or an ERCP. Strictures of the extrahepatic or intrahepatic bile ducts, or both, were seen. As in the case with idiopathic sclerosing cholangitis, the bifurcation of the hepatic ducts was most commonly involved. Pathologically, there was diffuse fibrosis and scarring replacing the walls of the extrahepatic bile ducts. The liver parenchyma usually developed periportal fibrosis with increased bands of collagen around the intrahepatic ducts. The clinical, radiological, and pathological triad were identical to idiopathic sclerosing cholangitis.

The pathogenesis of this process in the setting of hepatic intraarterial FUDR remains obscure, but possible causes can be postulated. All of these patients have in common a careful dissection of the artery supply to the liver with special emphasis on the ligation of all collaterals off the hepatic artery. This may lead to ischemia of the extrahepatic bile duct, but it does not explain the intrahepatic component of this process. The reverse also could be possible. If all the collaterals were not ligated, the porta hepatis would be exposed to the infused chemotherapy, possibly resulting in a fibrous reaction of the area. We have seen this fibrous reaction in patients with this complication. This process does not seem to be related to drug dosage or duration of infusion as it has developed between 42 to 287 days with total doses of FUDR ranging from 17 mg/kg to 87.5 mg/kg. Since this complication is seen in only 18% of the patients getting identical treatments, there may be more than one factor involved in this pathological process.

With these new complications clearly established as part of CHAI chemotherapy, the diagnostic work-up in patients with jaundice during the CHAI can be approached in a rational manner. Progression of disease or metastases to the porta hepatis should be considered together with the possibilities of chemical hepatitis and sclerosing cholangitis. CAT scan of the abdomen and LFTs will provide the initial information in the differ-

ential diagnoses. If the two first diagnoses cannot be clearly established or are ruled out as the cause of jaundice, the PTC or ERCP must be performed. The local treatment must be tailored to the radiological findings. If the strictures are in the extrahepatic and the larger intrahepatic biliary tree, then a percutaneous transhepatic drainage system should be inserted if possible. If the strictures are mainly in the extrahepatic bile ducts, a surgical drainage procedure can be attempted. Exploration of the common duct with insertion of a T-tube may be possible. However, it is a cumbersome procedure, in our experience, because of the marked fibrosis that surrounds the porta hepatis and because of the small size of the bile duct. A biliary enteric bypass would be technically very difficult in the setting of the intense fibrosis, and it would not resolve the intrahepatic component of the sclerosis. The timely discontinuation of the chemotherapy is very pertinent to the eventual outcome of these patients, since this process may be halted with the cessation of therapy. Three of the eight patients resolved their jaundice while off therapy without an indwelling bypass device. Unfortunately, two of these patients have also had a recurrence of their hepatic metastases.

The introduction of CHAI with the Infusaid pump has increased the enthusiasm for regional therapy in the management of cancer metastatic to the liver; however, the development of the apparently irreversible damage to the biliary tract system sends a word of caution to the management of these patients. Early diagnosis of these complications may prevent further deterioration of the biliary system and a reassessment of the drug schedule. Lower starting dosage may prevent some cases from developing, but clinical trials are needed to assure that anti-tumor efficacy is not compromised.

## References

1. Ansfield FJ, Ramirez G, Skibba J, et al. Intrahepatic arterial infusion with 5-fluorouracil. *Cancer* 1971; 28:1147.
2. Balch CM, Urist MM, Soong S, McGregor M. A prospective phase II clinical trial of continuous FUDR regional chemotherapy for colorectal metastases to the liver using a totally implantable drug infusion pump. *Ann Surg* 1983; 198:567.
3. Cameron JL, Gayler RW, Sanfey H, et al. Sclerosing cholangitis. *Ann Surg* 1984; 200:54.
4. Kemeny M, Goldberg DA, Browning S, et al. Experience with continuous regional chemotherapy and hepatic resection as treatment of hepatic metastases from colorectal primaries: a prospective randomized study. *Cancer* 1985; 55:1265.
5. Balch CM, Urist MM, McGregor ML. Continuous regional chemotherapy for metastatic colorectal cancer using a totally implantable infusion pump. *Am J Surg* 1983; 145:285.