
Resection of Scarred Papillary Muscles Improves Outcome after Surgery for Ventricular Tachycardia

IRVING L. KRON, M.D.

JOHN P. DIMARCO, M.D.*
BRUCE B. LERMAN, M.D.*

STANTON P. NOLAN, M.D.

Papillary muscle scarring is encountered frequently during operations for sustained ventricular tachycardia (VT). Indications for excision of the papillary muscle scar and mitral valve replacement (MVR) are controversial. The findings in 46 consecutive patients undergoing operative electrophysiologic map-directed endocardial resections for VT were reviewed. There was papillary muscle scarring in 15 patients (average age: 59 years; sex: 11 male, 4 female; average ejection fraction: $31 \pm 14\%$). Eleven patients had a VT with the site of origin on a scarred papillary muscle; four had another VT site of origin. Six patients underwent papillary muscle scar resection (5 with MVR); six underwent papillary muscle cryotherapy ($-60\text{ C} \times 2\text{ min}$); and three had neither papillary muscle resection nor MVR. All six patients with papillary muscle resection \pm MVR are alive and free of arrhythmia after 14.3 ± 7.6 months of follow-up. Five of six patients treated by papillary muscle cryotherapy alone manifested spontaneous (4 patients) or inducible (1 patient) VT during early postoperative evaluation. Two of the three patients with untreated papillary muscle scarring developed late complications requiring reoperation. One patient developed mitral regurgitation requiring MVR 5 months later. The other developed a previously undocumented VT 2 years after operation. Significant papillary muscle scarring visualized at the time of operation for arrhythmia is an indication for resection of the scar and the papillary muscle, even if this necessitates MVR. In this series, attempts to preserve the papillary muscle, by incomplete resection of the scar or by cryotherapy, resulted in a high failure rate owing to recurrent VT or mitral regurgitation.

SURGICAL THERAPY has become an accepted and effective approach to the control of ventricular tachycardia (VT) since Harken, Josephson, and Horowitz described the technique of intraoperative mapping and endocardial resection in 1979.¹ This approach is based on the concept that sustained VT in patients with coronary artery disease is due to re-entry originating in

Presented at the 97th Annual Meeting of the Southern Surgical Association, Hot Springs, Virginia, December 1-4, 1985.

Reprint requests: Irving L. Kron, M.D., Box 181, Department of Surgery, University of Virginia Medical Center, Charlottesville, VA 22908.

Submitted for publication: December 23, 1985.

From the Departments of Surgery and Internal Medicine (Cardiology Division), University of Virginia Medical Center, Charlottesville, Virginia*

the border zone between myocardial scar and normal myocardium.² Excision of endocardial scar from most parts of the heart is simple and well tolerated, but the optimal approach when scarring of the papillary muscles, a common finding, is present remains controversial. Two of the three early failures reported by Horowitz and colleagues were in patients whose arrhythmia was localized to the base of a papillary muscle, which was only partially resected at the time of operation.³ Moran and coworkers suggested that in patients with scarring of one or both papillary muscles, extended endocardial resection of all visible scar with mitral valve replacement (MVR) should be performed.⁴ Others have suggested that the use of either cryosurgery or an encircling endocardial ventriculotomy around the base of the papillary muscle might be successful, thus obviating the need for MVR.⁵ In this report, we review our operative results in patients with papillary muscle scarring who underwent left ventricular aneurysmectomy and subendocardial resection for recurrent VT.

Materials and Methods

Patient Characteristics

Forty-six consecutive patients with coronary artery disease and prior myocardial infarctions underwent electrophysiologic map-directed left ventricular aneurysmectomy and endocardial resection between 1983 and 1985 for recurrent sustained ventricular tachyarrhythmias. Among these 46 patients, 15 had extensive scarring of one or both papillary muscles and form the study group for this report. There were 11 men and four women, with a mean age of 59 years (range: 45-76). The left ventricular ejection frac-

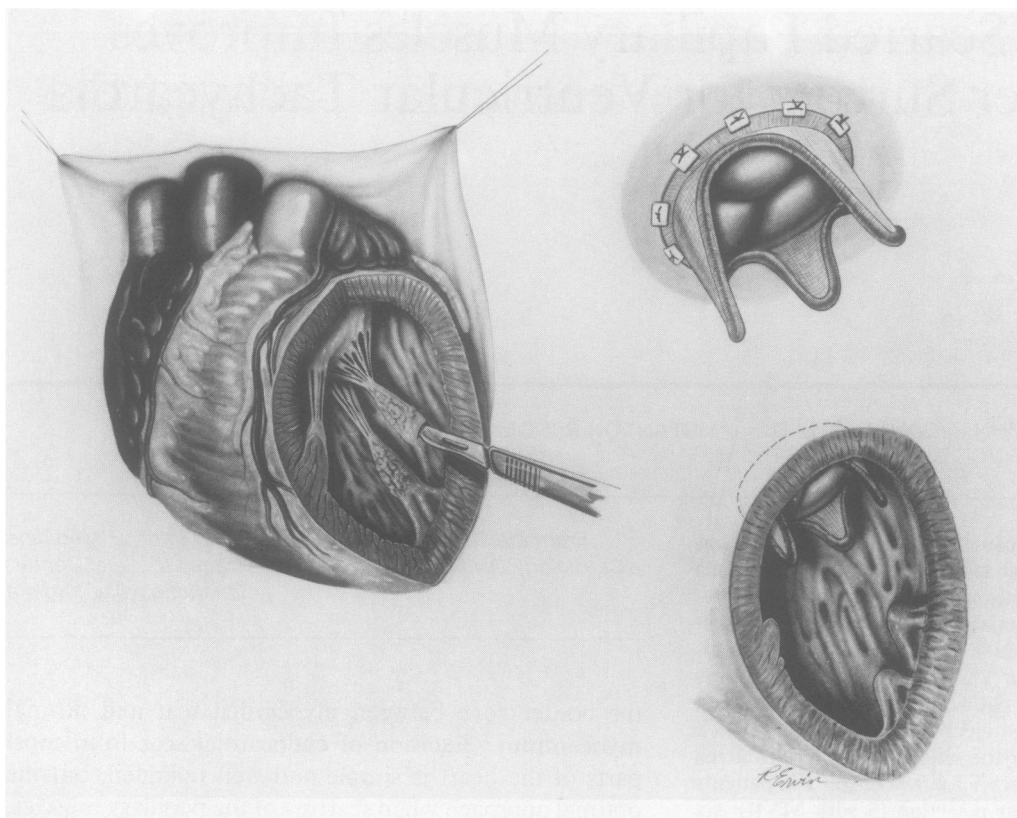


FIG. 1. Resection of papillary muscles in mitral valve replacement through a left ventricular aneurysmectomy.

tion was $31 \pm 14\%$ (mean \pm SD). All patients had sustained monomorphic VT, with the diagnosis confirmed at preoperative electrophysiologic study in 14 of the patients. Preoperative electrophysiologic study was not performed in one patient, owing to unstable angina. The techniques of electrophysiologic study used in our laboratory have been described previously.⁶ Electrophysiologic studies were performed after discontinuation of antiarrhythmic drugs. Eight patients who had relatively well-tolerated arrhythmias underwent preoperative endocardial catheter mapping to localize the site of origin of the arrhythmia.

Twelve patients had failed two or more antiarrhythmic drug trials, and medically refractory VT was the primary indication for operation. In the remaining three patients, persistent angina and heart failure necessitated operative intervention, and multiple drug trials were not undertaken.

Intraoperative Technique

All patients were anesthetized with narcotics and nitrous oxide and placed on normothermic (38–40 C) cardiopulmonary bypass prior to induction of VT. Three pairs of reference electrodes were sutured to the right and left ventricular epicardial surfaces to permit recording of local electrograms and programmed stimulation. After induc-

tion of VT, endocardial mapping was performed with a finger-held electrode (Elecath, Rahway, NJ). Resection of the site of earliest activation and surrounding areas of visible scar was performed, and the effects of the resection were assessed by the inability to reinduce VT.

The treatment of scarred papillary muscles varied. If the VT was not localized to the papillary muscles, they were left intact. If the site was mapped to the papillary muscles, we either resected the papillary muscle and replaced the mitral valve or applied a cryoprobe to the papillary muscle (Ron Wallach, Inc., Fairfield, CT). Cryoablation was performed by two or three 2-minute applications of a 1.5-cm² probe at -60 C to the involved papillary muscle. This was repeated after aortic cross-clamping and administration of cardioplegia in order to increase the size of the cryolesion.⁷ In one patient, the base of the posterior papillary muscle was resected and the remaining muscle reimplanted in the ventricle.

After the endocardial resection was completed, moderate hypothermia was induced, the aorta was cross-clamped, crystalloid cardioplegia was instilled, and aortocoronary bypass and/or MVR was performed. All valve replacements were performed through a left ventriculotomy with a porcine bioprosthesis (Fig. 1).

Postoperative electrophysiologic study was performed 7–14 days after the operation, using a single electrode

catheter placed in the right ventricle through a peripheral vein. If the follow-up study revealed sustained VT, long-term antiarrhythmic drug therapy guided by repeat electrophysiologic testing was prescribed.

Results

Electrophysiologic Findings

Eleven of 15 patients with VT and papillary muscle scarring manifested VT that originated in the region of one or both papillary muscles at the time of intraoperative mapping. Five of these 11 had multiple morphologies, with the additional site or sites of origin identified on the interventricular septum. The septum was the only site of VT origin identified in the four remaining patients (Table 1; Fig. 2).

Papillary Muscle Resection with Endocardial Resection

Six patients underwent papillary muscle resection: five had MVR and one had reimplantation of the posterior papillary muscle. All had at least one site of origin of VT localized to a papillary muscle. Two of these six patients had severe mitral regurgitation after operation. All patients who underwent papillary muscle resection survived the operation. All had negative postoperative electrophysiologic study and were discharged without antiarrhythmic drugs. They remain alive and free of recurrent VT after an average follow-up of 14 months (range: 3 months–3 years).

Papillary Muscle Cryotherapy with Endocardial Resection

Six patients were treated with cryotherapy of either the posterior (5 patients) or anterior (1 patient) papillary muscle. In five of these patients, endocardial mapping had localized the site of origin of VT to a papillary muscle. One other patient had obvious scarring of the posterior papillary muscle, but the site of VT was located on the septum. Repeat intraoperative programmed stimulation after placement of the cryolesions failed to initiate VT. These six patients were all successfully weaned from cardiopulmonary bypass, but four of the six developed spontaneous episodes of sustained VT during the early postoperative period. The VT experienced by two of these patients was finally controlled by the administration of amiodarone; in another, it was controlled by procainamide. Despite control of the arrhythmias, two of the four patients required prolonged ventilatory support and died of sepsis and complications of their arrhythmias 3 months after operation. A third patient was discharged on procainamide with the arrhythmia controlled. The final patient who developed postoperative VT had repeated episodes that were uncontrolled despite multiple drug trials. At reoperation 1 week after his initial operation, he un-

derwent papillary muscle resection and MVR, but he could not be weaned from cardiopulmonary bypass.

Two patients who underwent simple papillary muscle cryoablation had no further clinical VT. One was discharged without antiarrhythmic drugs after undergoing a negative electrophysiologic study. The other patient manifested VT in response to ventricular stimulation during his postoperative electrophysiologic study. This arrhythmia was suppressed with procainamide and has remained asymptomatic.

Untreated Papillary Muscles

Three patients had scarring of one or both papillary muscles at the time of operation; however, the VT originated only from the septum and could not be induced after resection of the septal endocardium. The papillary muscles were therefore left intact. These three patients initially did well and were discharged on no antiarrhythmic drugs. One patient continues to do well 18 months after operation. The other two, however, eventually required reoperation for complications related to the scarred papillary muscles. One patient developed mitral regurgitation and required MVR and repair of a small ventricular septal defect 6 months after the initial operation. He has done well during the subsequent 18 months. The other patient had no cardiac symptoms for 2 years after his initial operation but then developed a VT that did not respond to antiarrhythmic therapy. Endocardial catheter mapping localized the site of VT origin to the posterior papillary muscle. The patient underwent reoperation, which confirmed the site of origin of the arrhythmia to be the posterior papillary muscle. After MVR and despite initially satisfactory cardiovascular hemodynamics, he could not be weaned from bypass because of fulminant noncardiac pulmonary edema.

Discussion

The appropriate treatment of scarred papillary muscles found during operations for VT remains controversial. Moran and colleagues⁸ reported that 15 of 67 patients (22%) undergoing surgical therapy for VT had papillary muscle scarring, and they compared results in the nine (of these 15) patients who had papillary muscle resection and MVR with results in the six who did not. Among the nine patients with MVR, there was one perioperative death; two patients continued to have VT. However, all six patients whose scarred papillary muscles were not resected had recurrent VT after operation, either spontaneously or at electrophysiologic study.

Ivey and coworkers described their results in 11 patients with recurrent VT and prior inferior myocardial infarctions. Two patients with a site of origin on a papillary muscle underwent resection and did well. Five others with

TABLE 1. Patient Characteristics

Patient No.	Age (Years)	Sex	Preoperative Mitral Regurgitation	Location of Myocardial Infarction	Intraoperative VT Site of Origin	Treatment of Papillary Muscles	Adjuvantive Operative Procedures	Postoperative Arrhythmias	Postoperative EPS	Postoperative antiarrhythmic Medications	Results
1	59	M	4+	Posterior	Posterior PM	Resection	CABG2 MVR	None	Negative	None	Alive and well, 18 months
2	62	M	0	Anterior and posterior	Septum	Cryoablation	LVA/CABG2	Recurrent VT/VF	—	Lidocaine, procainamide, amiodarone	Died at reoperation
3	74	M	0	Posterior	Posterior PM	Cryoablation	CABG3	Spontaneous VT	Sustained VT	Amiodarone	Alive and well, 28 months
4	56	M	1+	Anterior	Septum	None	LVA/CABG3	None	Negative	None	Recurrent VT at 2 years; died at reoperation
5	67	M	0	Posterior	Posterior PM	Cryoablation	CABG3	Spontaneous VT	Sustained VT	Procainamide	Died of sepsis 3 months after operation
6	50	M	2+	Anterior	Septum	None	LVA	None	Negative	None	MVR 6 months after operation; alive and well, 20 months
7	62	M	4+	Anterior	Anterior PM	Resection	LVA/CABG3 MVR	None	Negative	None	Alive and well, 22 months
8	64	M	1+	Posterior	Posterior PM	Resection	LVA/MVR	None	Negative	None	Alive and well, 12 months
9	60	M	0	Anterior	Septum	None	LVA	None	Negative	None	Alive and well, 20 months
10	65	F	0	Posterior	Posterior PM	Cryoablation	CABG3	Spontaneous VT	Not done	Amiodarone	Died after 3 months of respiratory failure
11	55	M	0	Anterior & Posterior	Posterior PM and septum	Resection	LVA/CABG2 MVR	None	Negative	None	Alive and well, 14 months
12	48	M	0	Anterior	Anterior PM and septum	Cryoablation	LVA	None	Sustained VT	Procainamide	Alive and well, 16 months
13	73	F	0	Anterior	Posterior PM and septum	Cryoablation	LVA	None	Negative	None	Alive and well, 10 months
14	61	F	0	Posterior	Posterior PM and septum	Resection Base Post. PM	LVA/CABG2	None	Negative	None	Alive and well, 6 months
15	47	M	1+	Anterior	Anterior/Posterior PM and septum	Resection	LVA/CABG1 MVR	None	Negative	None	Alive and well, 3 months

VT = ventricular tachycardia; EPS = electrophysiologic study; PM = papillary muscle; CABG = coronary artery bypass graft; LVA = left ventricular aneurysm; VF = ventricular fibrillation.

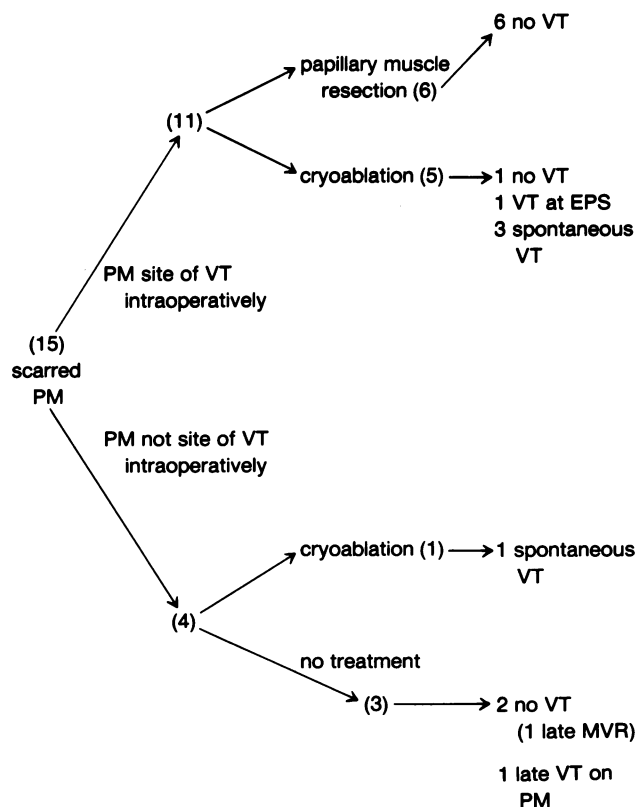


FIG. 2. A summary of electrophysiologic results and the outcome of operation.

papillary muscle scarring did not have resections, and two of these patients developed VT after operation.

Other techniques for managing papillary muscle scarring in patients with recurrent VT have been proposed.¹⁰ Encircling endocardial incisions interrupt the blood supply and produce an ischemic area that may be electrically inactive. No report on their use only for papillary muscle scarring is available, but their use in other regions appears to be associated with increased mortality in comparison to that from endocardial resection.¹¹⁻¹⁴

Cryosurgery also has been used to treat arrhythmias originating from scarred papillary muscles. A cryolesion at -60°C can experimentally ablate the electrical activity of myocardial tissue and produce an inert lesion that is different from normal myocardium.^{15,16} However, our results with cryosurgery of scarred papillary muscle have been poor. There are several possible explanations. Mapping of VT is not precise, but the cryolesion is specific for a small area. Cryoablation of larger areas would take multiple applications, and it is still not certain that the source of the arrhythmia would be rendered electrically inert. Our technique of sequential mapping and resection is not an effective guide to cryoablation. Initially, a larger area is made electrically inert, and the arrhythmia cannot be

reinduced in the operating room. Despite this, when thawing occurs and myocardial edema regresses, the arrhythmia has recurred 1 to 2 days after operation.

Our results indicate that the safest short-term treatment of severely scarred papillary muscles shown to be the site of VT is resection and MVR. Severe scarring of both papillary muscles, if left untreated, has led to late mitral regurgitation or VT requiring reoperation with high morbidity and mortality. At present, the issue of MVR in patients with scarred papillary muscles and the arrhythmia clearly localized to another site remains unsettled.

References

- Harken AH, Josephson ME, Horowitz LN. Surgical endocardial resection for the treatment of malignant ventricular tachycardia. *Ann Surg* 1979; 190:456.
- Cox JL. Anatomic electrophysiologic basis for the surgical treatment of refractory ischemic ventricular tachycardia. *Ann Surg* 1983; 198:119.
- Horowitz LN, Harken AH, Kastor JA, Josephson ME. Ventricular resection guided by epicardial and endocardial mapping for treatment of recurrent ventricular tachycardia. *N Engl J Med* 1980; 302:589.
- Moran JM, Kehoe RF, Loeb JM, et al. Extended endocardial resection for the treatment of ventricular tachycardia and ventricular fibrillation. *Ann Thorac Surg* 1982; 34:538.
- Cox JL. Discussion. *Ann Thorac Surg* 1982; 34:550.
- DiMarco JP, Lerman BB, Kron IL, Sellers TD. Sustained ventricular tachyarrhythmias within 2 months of acute myocardial infarction: results of medical and surgical therapy in patients resuscitated from the initial episode. *J Am Coll Cardiol* 1985; 6:759-768.
- Holman WL, Ikeshita M, Douglas JM, et al. Cardiac cryosurgery: effects of myocardial temperature on cryolesion size. *Surgery* 1983; 93:268.
- Moran JM, Kehoe RF, Loeb JM, et al. The role of papillary muscle resection and mitral valve replacement in the control of refractory ventricular arrhythmia. *Circulation* 1983; 68 (Suppl II):154-160.
- Ivey TD, Brady GH, Misbach GA, Greene HL. Surgical management of refractory ventricular arrhythmias in patients with prior inferior myocardial infarction. *J Thorac Cardiovasc Surg* 1985; 89:369.
- Guiraudon G, Fontaine G, Frank R, et al. Encircling endocardial ventriculotomy: a new surgical treatment for life-threatening ventricular tachycardias resistant to medical treatment following myocardial infarction. *Ann Thorac Surg* 1978; 26:438.
- Ungerleider RM, Holman WL, Stanley TE, et al. Encircling endocardial ventriculotomy for refractory ischemic ventricular tachycardia. I. Electrophysiological effects. *J Thorac Cardiovasc Surg* 1982; 83:840.
- Ungerleider RM, Holman WL, Stanley TE, et al. Encircling endocardial ventriculotomy for refractory ischemic ventricular tachycardia. II. Effects on regional myocardial blood flow. *J Thorac Cardiovasc Surg* 1982; 83:850.
- Ungerleider RM, Holman WL, Calcagno D, et al. Encircling endocardial ventriculotomy for refractory ischemic ventricular tachycardia. III. Effects on regional left ventricular function. *J Thorac Cardiovasc Surg* 1982; 83:857.
- Cox JL, Gallagher JJ, Ungerleider RM. Encircling endocardial ventriculotomy for refractory ischemic ventricular tachycardia. IV. Clinical indications, surgical technique, mechanism of action, and results. *J Thorac Cardiovasc Surg* 1982; 83:865.
- Klein GJ, Harrison L, Ideker RF, et al. Reaction of the myocardium to cryosurgery: electrophysiology and arrhythmogenic potential. *Circulation* 1979; 59:364.
- Holman WL, Ikeshita M, Ungerleider RM, et al. Cryosurgery for cardiac arrhythmias: acute and chronic effects on coronary arteries. *Am J Cardiol* 1983; 51:149.