

---

# Impact of Emergency Angiography in Massive Lower Gastrointestinal Bleeding

---

WILLIAM BROWDER, M.D.    ELMO J. CERISE, M.D.    MARTIN S. LITWIN, M.D.

---

Fifty patients with massive lower gastrointestinal bleeding were initially managed with emergency angiography. The average age was 67.2; mean hematocrit, 23.7; and average transfusion, 7.6 units. Thirty-six patients (72%) had bleeding site located; bleeding sites were distributed throughout the colon. Etiologies of bleeding included diverticular disease (19 patients) and arteriovenous malformations (15 patients). Twenty of 22 (91%) patients receiving selective intra-arterial vasopressin stopped bleeding; however, 50% rebled on cessation of vasopressin. Thirty-five of 50 (70%) patients underwent surgery, with 57% operated on electively after vasopressin therapy. Seventeen patients had segmental colectomy, with no rebleeding. Nine of the 17 patients had diverticular disease in the remaining colon. Operative morbidity in these 35 patients was significantly improved when compared to previously reported patients undergoing emergency subtotal colectomy without angiography (8.6% vs. 37%) ( $p < 0.02$ ). Emergency angiography successfully locates the bleeding site, allowing for segmental colectomy. Vasopressin infusion transiently halts bleeding, permitting elective surgery in many instances.

**W**HILE THE MAJORITY of patients with complaints of lower gastrointestinal bleeding spontaneously cease hemorrhaging, continuing massive rectal bleeding poses both diagnostic and therapeutic problems. When the source of such bleeding is obscure and exploratory laparotomy is performed, intraoperative efforts to locate and resect the source of bleeding are often unsuccessful. Because the results of this approach have been so discouraging, some have advocated routine emergency subtotal colectomy in those with massive rectal bleeding.<sup>1</sup>

Selective arterial catheterization to identify bleeding sites in the gastrointestinal tract was first described in the 1960s.<sup>2</sup> Since that time, numerous studies have documented the diagnostic and therapeutic benefit of angiography and vasopressin infusion in the lower gastrointes-

*From the Department of Surgery, Tulane University School of Medicine, New Orleans, Louisiana*

---

tinal bleeder.<sup>3-9</sup> Widespread use of angiography in such patients has led to the realization that the arteriovenous (AV) malformation, heretofore an unknown source of bleeding, is an important clinical entity. The characteristics of this gastrointestinal lesion have now been well documented.<sup>6,9-12</sup>

The use of recently developed colonoscopic instruments and nuclear scanning techniques has created confusion about the role of angiography in the management of these patients. This present study was designed to assess the contribution of emergency angiography and vasopressin infusion in the management of patients with massive lower gastrointestinal bleeding.

## Methods and Materials

Fifty patients admitted since 1980 to the Tulane Surgical Service with massive lower gastrointestinal bleeding, as defined by one of the following two criteria, were studied: (1) requirement of 4 units of blood transfusion during the initial 2 hours in the hospital, (2) systolic blood pressure below 100 mmHg while actively bleeding. Following the institution of intravenous fluids and blood sampling for routine chemistries, screening for etiology of the bleeding was accomplished using the diagnostic scheme described by Boley et al.<sup>13</sup>

This protocol included insertion of a nasogastric tube and examination of the aspirate to rule out upper gastrointestinal bleeding. Proctoscopy was performed to rule out anorectal pathology as a source of the bleeding. A coagulation profile including prothrombin time, partial thromboplastin time, and platelet count was used to detect any coagulopathy.

After completion of these initial studies, selective angiography was performed in all 50 patients. Both the su-

---

Reprint requests: William Browder, M.D., Tulane Medical School, Department of Surgery, 1430 Tulane Avenue, New Orleans, LA 70112.  
Submitted for publication: February 26, 1986.

perior and inferior mesenteric arteries were catheterized in an effort to locate the bleeding site in the colon. If no bleeding site was identified and active bleeding continued, an emergency subtotal colectomy was performed. If no site was identified but active bleeding stopped, barium enema and colonoscopy were accomplished and elective colon resection performed, if indicated. If a source of active bleeding was localized by the emergency angiography, selective vasopressin infusion was performed when possible (Fig. 1).

Vasopressin infusion was performed as described by Baum et al.<sup>3,14</sup> Following localization of the bleeding site and proper placement of the catheter, infusion of vasopressin was begun at 0.2 units/min, increasing to 0.4 units/min, if needed. A follow-up arteriogram was done 20–30 minutes later to demonstrate vasospasm and cessation of bleeding. If successful, vasopressin infusion was tapered over the ensuing 24–48 hours. All patients who stopped bleeding as a result of the vasopressin infusion were followed closely for recurrent bleeding. Those who had a second bleeding episode in the hospital were immediately operated on. The remainder underwent further diagnostic work-up, and an elective operative procedure was performed when indicated. All patients were monitored following discharge for recurrent bleeding. Follow-up periods ranged from 10 months to 4 years.

In those patients who were operated on, morbidity and mortality statistics were collected and tabulated. These results were then compared to those in a previous report from our institution by Drapanas et al. in 1973, in which massive lower gastrointestinal bleeders underwent emergency subtotal colectomy without the benefit of prior angiography.<sup>1</sup> Statistical analysis of difference between the two groups of patients was based on Yates correction of  $\chi^2$  with one degree of freedom. A  $\chi^2$  value representing a 95% confidence level was considered significant.

### Results

Average age of these 50 patients was 67.2 years (range: between 39 and 93 years). There were 29 women and 21 men. Thirty-one patients were hypertensive, and 21 patients had congestive heart failure and/or ischemic heart disease. Diabetes mellitus was noted in ten patients. Average systolic blood pressure for the 50 patients was 111 mmHg (range: 60–180 mmHg). Mean pulse rate was 99 (60–130). Average hematocrit for these patients was 23.7% (range: 7–34%). Average amount of blood transfused was 7.6 units (range: 2–40 units).

### Emergency Angiography

All 50 patients who underwent emergency angiography were actively bleeding. In 36 patients (72%), extravasation of contrast material was noted, and a bleeding site located.

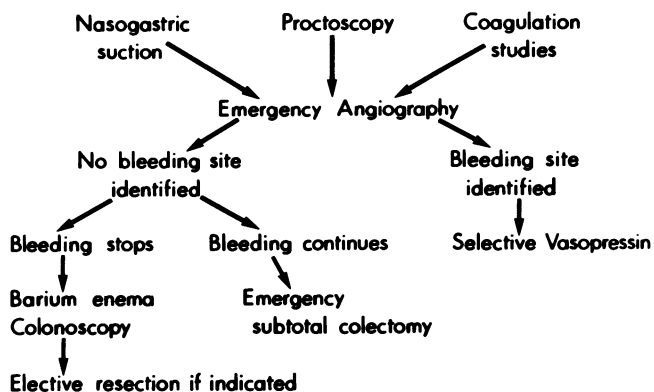


FIG. 1. Diagnostic protocol utilized in 50 patients with massive lower gastrointestinal bleeding.

Negative angiographic findings in 14 patients (28%) appeared to be related to delay in performing the angiography. In this latter group of patients, the delay ranged from 2 to 18 hours (average: 6 hours). Sites of active bleeding were located primarily in the right colon (Fig. 2). Nineteen patients bled from diverticular disease; in 15 patients AV malformations were demonstrated as the source of bleeding, and one patient bled from a left colon ulcer.

### Selective Vasopressin Infusion

Twenty-two of the 36 patients with identifiable bleeding sites underwent selective vasopressin infusion. Failure to utilize vasopressin in 14 patients was related to inability to maintain selective catheterization of the vessel, presence of severe ischemic heart disease, or cessation of bleeding

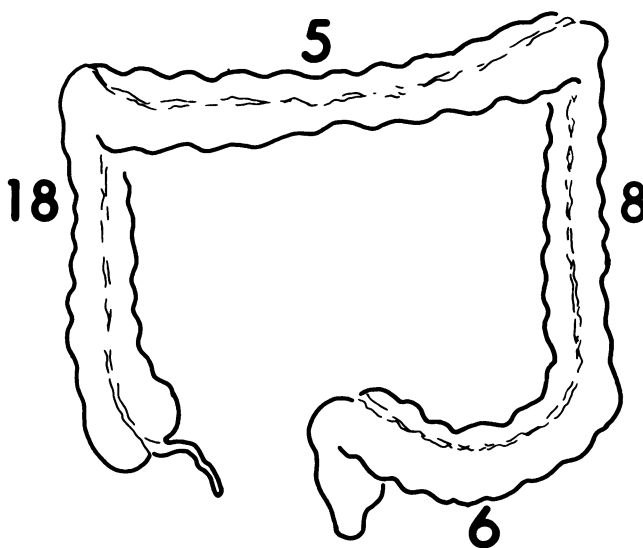


FIG. 2. Site of bleeding in the 36 patients who had contrast extravasation at angiography. One patient had active bleeding from two AV malformations located in the left and right colon.

TABLE 1. Operative Procedures in Massive Colon Bleeding

	N
Subtotal colectomy	18
Right colectomy	11
Left colectomy	4
Transverse colectomy	1
Sigmoid colectomy	1

during the angiography. Vasopressin infusion stopped the bleeding in 20 of the 22 patients (91%); however, ten of these 20 patients (50%) rebled after the vasopressin was discontinued. Five of the patients who rebled did so within the first 6 hours following cessation of vasopressin infusion. The remainder rebled within 3 days after the drug was discontinued.

#### Gastrointestinal Work-up

Forty-four of the 50 patients underwent proctoscopy on admission to the hospital. In 40 of these patients, proctoscopy revealed active bleeding from beyond the extent of the proctoscope. In four patients, proctoscopy revealed no active bleeding in the area of the rectosigmoid. In those patients who stopped bleeding either spontaneously or following vasopressin administration, elective diagnostic work-up of the colon was accomplished. Thirty-five patients underwent barium enema. Diverticular disease was noted to be confined to the left colon in 14 patients and was diffuse in 12 patients. Nine patients had a normal barium enema. Because of the short time that elapsed before angiography, colonoscopy was performed in only 15 patients. In 11 of the 15 patients who were colonoscoped, blood was noted throughout the entire colon. No obvious site of active bleeding was located during any of the colonoscopic examinations.

#### Surgical Intervention

Thirty-five of the 50 patients (70%) underwent colon resections. Twenty of these patients (57%) had an elective operation. Of these 20 elective resections, ten patients had rebled while in the hospital after vasopressin infusion had been discontinued. Fifteen of the 35 patients (43%) had

TABLE 2. Etiology of Massive Lower Gastrointestinal Bleeding

	AV Malformation	Diverticulum
Age	67.6	68.6
Admitting systolic pressure	124*	99*
Admission hematocrit	23	23.9
Amount transfused (units)	7.3	6.4
Success with vasopressin	9/9 (100%)	12/13 (92%)
Rebleeding with vasopressin	3/9 (33%)	7/12 (58%)

\*  $p < 0.02$ .

emergency surgery. Seven of these 15 patients had had negative angiography, but, because active bleeding continued, emergency surgery was necessary. The remaining eight patients did not have vasopressin infusion attempted and either continued bleeding or rebled shortly after angiography; in these latter patients, emergency surgery was also necessary.

The 15 patients who did not have an operation either refused surgery or were such poor operative risks that operation was contraindicated. Eight of these patients have been followed for over 1 year with no episode of rebleeding.

Various operative procedures were performed in the 35 patients (Table 1). Subtotal colectomy was performed when there was diverticular disease throughout the colon (10 patients). Four patients underwent subtotal colectomy for continued bleeding from an unknown site. An additional four patients had subtotal colectomy for multiple bleeding sites or other associated colon pathology, such as carcinoma.

Three of the 35 patients undergoing surgery developed complications after operation. Two patients developed subphrenic abscesses, and one developed a superficial wound infection. Overall operative morbidity of 8.6% was significantly lower than the 37% morbidity reported by Drapanas et al. in a series of patients who underwent emergency subtotal colectomy for lower gastrointestinal bleeding at our institution<sup>1</sup> ( $p < 0.02$ ). One of the 50 patients undergoing angiography developed femoral artery thrombosis following completion of the study. This patient underwent arterial thrombectomy at the time of colectomy and recovered with no sequelae.

Operative mortality in this current group of patients was 11.4%. Causes of death included myocardial infarction, abdominal bleeding secondary to myelofibrosis, renal failure, and subphrenic abscess. This mortality rate was essentially the same as the 11% following emergency subtotal colectomy as reported by Drapanas et al. in 1973.<sup>1</sup>

Seventeen of the 35 operations (48.6%) consisted of segmental resection of the bleeding site. Nine of the 17 patients undergoing segmental colectomy had diverticular disease present in the remaining colon that was not resected. Mean follow-up of 18 months has revealed no rebleeding in any of the 17 patients. The only episode of rebleeding following surgery has been in a patient who underwent subtotal colectomy for multiple colonic AV malformations and 7 months later developed lower gastrointestinal bleeding from an AV malformation in the jejunum. Further work-up revealed multiple AV malformations throughout the small bowel.

#### AV Malformation Versus Diverticular Disease

Since AV malformations and diverticular disease were the most common etiologies in this group of patients,

these two entities were analyzed separately and then compared for any major differences in clinical presentation (Table 2). Mean systolic blood pressure was significantly lower in the patients who were bleeding from diverticular disease; however, average admission hematocrit and amount of blood transfused were not significantly different between the two groups. While both groups responded equally to vasopressin infusion, diverticular bleeding was somewhat more likely to recur. In 12 of the 15 patients with AV malformations, the bleeding site was located in the right colon. However, in those patients with diverticular disease, the bleeding sites were equally distributed throughout the colon.

### Discussion

This series of patients with massive lower gastrointestinal bleeding, as defined by continued rectal bleeding with hypotension or transfusion of more than 4 units of blood, was composed primarily of elderly patients (mean age: 67). Drapanas et al., reporting on patients with massive rectal bleeding between 1968 and 1972, also noted a preponderance of the aged (mean age: 65).<sup>1</sup> Others have also documented that this disease remains one of the elderly population.<sup>8</sup> This group of patients also required large amounts of blood transfusion to stabilize the hematocrit (average: 7.6 units). Boley et al. likewise noted that, when the elderly patients with lower gastrointestinal bleeding were bleeding rapidly enough to result in positive angiography, they also required extensive transfusion (7.6 units).<sup>6</sup> Those with negative angiography who presumably had stopped bleeding required less transfusion (4 units).<sup>6</sup>

Widespread use of angiography has identified AV malformation as a frequent cause of gastrointestinal bleeding. In the present series, 15 of the 36 patients who were identified by angiography to be actively bleeding had AV malformations. Based on characteristic radiographic findings and their high frequency of occurrence in the elderly, Boley et al. have hypothesized that they are degenerative lesions associated with repeated partial and intermittent low grade obstruction of the submucosal veins of the right colon.<sup>6,15,16</sup> Since bleeding from these AV malformations is venous in origin, one could reasonably expect them to be self-limiting and frequently to stop hemorrhaging spontaneously. Several reports have confirmed this observation.<sup>4,10</sup> In one series, 30 of 32 AV malformations stopped bleeding spontaneously.<sup>10</sup> Not surprisingly, angiography under such "elective situations" often results in failure to demonstrate extravasation of the contrast material. Several reports of large numbers of patients managed in this fashion have described only a 10–20% incidence of extravasation at angiography.<sup>4,6,9,13</sup> For this reason, AV malformation has not been emphasized as an etiology of massive lower gastrointestinal bleeding. In this experience, all patients were excluded who spontaneously

stopped bleeding or were bleeding at slow rates; only those with severe, active rectal bleeding were studied. Fifteen of these patients had AV malformations confirmed as their source of bleeding by pathologic examination and/or radiographic findings at the time of angiography. All 15 of these patients demonstrated extravasation of contrast material at the time of angiography. Based on this experience, it is apparent that a patient with an AV malformation may have bleeding as severe as that from diverticular disease.

Because bleeding from diverticular disease is usually arterial in nature, it has long been reported that massive bleeding from diverticular disease is more severe than that seen from AV malformations. The present study includes 19 patients with massive lower gastrointestinal bleeding from diverticular disease. However, when those patients were compared to the 15 patients with AV malformations, there was very little difference between the two groups. While the mean admitting systolic blood pressure was significantly lower in the patients bleeding from diverticular disease, both the mean hematocrit and average amount of blood transfused were no different in the two groups of patients. Both groups of patients also responded similarly to vasopressin infusion during angiography.

Several reports have noted almost exclusive location of the AV malformation in the right colon.<sup>5,6</sup> However, there have been reports of AV malformations bleeding significantly from the left and transverse colons.<sup>9</sup> In this report, 12 of the 15 AV malformations were located in the right colon, and only three were in the left colon. Because of the occasional left-sided location of AV malformations and the frequent coexistence of AV malformations and diverticular disease, prompt angiography is of paramount importance in obtaining an accurate etiology and location of the gastrointestinal bleeding.

Seventy-two per cent of our patients had a bleeding site demonstrated by extravasation of contrast material at angiography. This result compares favorably with results reported in other series of patients with lower gastrointestinal bleeding studied by angiography (Table 3). The collected series totaled 247 patients, with angiography being successful in demonstrating the bleeding site in 69% of the cases. In many of these collected reports, the degree of bleeding at the time of angiography and the timing of angiography following detection of the rectal bleeding were not specified. These two factors have great bearing on the success rate of angiography. In our experience with this group of actively bleeding patients, average time to angiography in the unsuccessful cases was 6 hours. This further emphasizes the importance of avoiding delay in the initial work-up.

Since it detects rates of bleeding as low as 0.1 ml/min, some have advocated routine use of the technitium scan prior to angiography so as to insure that bleeding is suf-

TABLE 3. Detection of Bleeding Site by Angiography

	No.	No. Detected	Per Cent
Present series	50	36	72
Welch, 1978 <sup>4</sup>	26*	20	77
Britt, 1983 <sup>9</sup>	40	23	58
Nath, 1981 <sup>5</sup>	14	12	86
Wright, 1979 <sup>8</sup>	14	12	86
Boley, 1979 <sup>6</sup>	43	28	65
Casarella, 1974 <sup>7</sup>	60	40	67
Total	247	171	69

\* Diverticular disease only.

ficiently active to warrant angiography.<sup>13</sup> Our approach in this group of actively bleeding patients was immediately to perform emergency angiography and to forego the delay that would occur with attempts at nuclear scanning. Others have also advocated immediate angiography in patients who are unstable and actively bleeding.<sup>17</sup>

Baum et al. were the first to popularize intra-arterial vasopressin as a means of halting gastrointestinal bleeding.<sup>14,18</sup> In our experience, 91% of those who underwent intra-arterial vasopressin had cessation of bleeding. However, 50% of these patients rebled at varying time intervals after the termination of vasopressin infusion. A review of 83 collected cases of colon hemorrhage treated by vasopressin reveals similar results (Table 4). Eighty-two per cent of these patients had success with the vasopressin. However, subsequently 41% of the initial successes had recurrent bleeding following discontinuation of the vasopressin. Athanasoulis et al. have detailed some of the clinical problems that arise with the use of vasopressin in colon bleeding.<sup>19</sup> They reported 17 patients who stopped bleeding with vasopressin and did not undergo elective colectomy. Of the 17, eight subsequently rebled. It is quite apparent that frequently vasopressin infusion is only a temporizing measure in the active lower gastrointestinal bleeder.

A critical question regarding vasopressin infusion is whether its use allows stabilization of critically ill patients so that later elective colon resection can be performed.

TABLE 4. Control of Hemorrhage by Vasopressin Infusion

	No.	Successful (%)	Rebleeding (%)
Present series	22	20 (91)	10 (50)
Welch, 1978 <sup>4</sup>	22	18 (82)	4 (22)
Wright, 1980 <sup>8</sup>	20	14 (70)	10 (71)
Britt, 1983 <sup>9</sup>	7	6 (86)	4 (67)
Clark, 1981 <sup>20</sup>	12	10 (83)	—
Total	83	68 (82)	28 (41)

TABLE 5. Segmental Colectomy for Lower Gastrointestinal Bleeding

	No. Resected	Rebled
Present series	17	0
Nath, 1981 <sup>5</sup>	16	0
Britt, 1983 <sup>9</sup>	14	1
Casarella, 1974 <sup>7</sup>	30	0
Boley, 1979 <sup>10</sup>	27	4
Welch, 1978 <sup>4</sup>	42	4
Wright, 1980 <sup>8</sup>	21	1
Total	167	10 (6%)

Avoidance of emergency subtotal colectomy should then result in improved operative morbidity and mortality. In an effort to clarify this issue, comparison was made between this recent experience and the emergency subtotal colectomy patients reported by Drapanas et al.<sup>1</sup> This latter group of 30 patients had massive colon bleeding and underwent emergency subtotal colectomy. Because angiography was not readily available at that time, none of them had preoperative angiography. Using this emergency approach, operative morbidity was 37%.<sup>1</sup> In contrast, in our series, management with angiography and vasopressin infusion allowed 57% of our patients to undergo elective operations; this resulted in a significant improvement in operative morbidity (8.6%).

Operative mortality in our patients managed with angiography was similar to that in the emergency subtotal colectomy group. However, close analysis of the mortality in patients undergoing angiography reveals that all four deaths occurred after emergency subtotal colectomy for continued bleeding when vasopressin therapy was not used or failed. There was no operative mortality in patients who had successful vasopressin therapy and subsequent elective colectomy. These results indicate that emergency angiography and vasopressin therapy can have a beneficial impact on the management of these very difficult patients.

In the present experience, both subtotal colectomy and segmental resection were utilized. Subtotal colectomy was used most frequently in patients who had diffuse diverticular disease, an unknown bleeding site in the colon, or other colonic pathology in addition to the primary bleeding site. The success of angiography in identifying a discrete bleeding site in the colon has prompted some to advocate segmental resection in the management of these patients.<sup>5,13,19</sup> In our series, 17 patients underwent segmental colectomy (8 for AV malformation, 9 for diverticular disease). In all of these patients, the bleeding sites were located by extravasation of contrast, and none were rebled following surgery. In a collective review of 167 patients undergoing segmental resection for lower gastrointestinal bleeding, the overall rebleeding incidence was 6% (Table 5).

Several authors have looked specifically at segmental colectomy for AV malformations. Welch et al. reported 31 right colectomies for AV malformations and four instances of rebleeding.<sup>4</sup> Similarly, Boley et al. reported 27 right colectomies for AV malformations with rebleeding in three patients.<sup>10</sup> However, both of these studies included patients who did not have the bleeding site identified by extravasation of contrast material. Rather, the AV malformation was identified by angiographic characteristics following cessation of the active colon bleeding.

A difficult decision must be made when segmental colectomy is performed for bleeding from a site identified by angiography and the remaining colon contains diverticular disease. In our series, nine patients had segmental colectomy and no rebleeding from the remaining colon that contained diverticular disease. Boley et al. reported 11 patients with segmental colectomy for bleeding AV malformation and diverticular disease in the remaining colon segment. Of these, only one rebled after surgery.<sup>6</sup> In the 27 right colectomies for AV malformations reported by Boley et al., the three patients who rebled did so from diverticular disease in the remaining left colon.<sup>10</sup> Based on our experience and that summarized above, it can be concluded that segmental colectomy can be performed with a low incidence of rebleeding, provided the bleeding site is clearly identified by angiography.

Controversy still exists concerning the advantage of segmental colectomy.<sup>13,21</sup> The obvious advantage of subtotal colectomy over segmental colectomy is that any possible area of future bleeding in the remaining colon will be removed. However, our data support the concept that, with prompt identification of a bleeding site by the judicious use of angiography, segmental colectomy can be performed with rates of rebleeding comparable to that of subtotal colectomy.

The role of subtotal colectomy in the management of colon bleeding also remains controversial. Welch et al. recommended subtotal colectomy for patients with diffuse disease and for those with both right-sided AV malformations and left-sided diverticular disease.<sup>4</sup> In contrast, Boley et al. recommended subtotal colectomy in such patients only as a last resort. Rather, segmental colectomy should be performed when any bleeding site is identified by angiography. Additionally, when an angiogram demonstrates an AV malformation, even when there is no extravasation of contrast material, right hemicolectomy should be performed even when there is diverticular disease in the remaining colon. Subtotal colectomy should be performed only when the angiogram is normal and the patient continues to bleed actively.<sup>13</sup> We support the more aggressive use of segmental colectomy. However, we must again stress the importance of early angiography to document by extravasation of contrast the exact bleed-

ing point in these patients. In the absence of demonstrated extravasation by angiography, we would not recommend segmental resection of an AV malformation if diverticular disease is present in the remaining colon. The incidence of rebleeding in such patients is significant.

### Summary and Conclusions

In this experience with 50 patients with massive lower gastrointestinal bleeding, early angiography in the actively bleeding patient resulted in localization of the bleeding site in 72% of the patients. The bleeding sites occurred more often in the right colon, but 36% of the patients had bleeding from the left colon or sigmoid colon. AV malformation was the etiology of the massive bleeding in approximately one half of the patients diagnosed. Treatment by vasopressin infusion was successful in 91% of the patients so treated, but in half of these patients there was only transient hemostasis with rebleeding following cessation of vasopressin. Of the 35 patients who underwent surgery, 57% had initial stabilization with vasopressin therapy and underwent subsequent elective colectomy. Based on this experience, we feel that early angiography on an emergent basis is essential if one is to identify a bleeding point in the colon. Additionally, vasopressin infusion can temporarily halt active colon bleeding so that the patient may be stabilized and later undergo elective surgery. Improved operative morbidity and mortality will then result.

In this group of patients, operative approach included subtotal colectomy and segmental resection. Operative morbidity was improved when compared to a previous report of patients from this institution who had emergency subtotal colectomy without angiography. While operative mortality was unchanged between the two groups, all deaths in the angiography group followed subtotal colectomy for continued bleeding. That there has been no incidence of rebleeding following segmental resection clearly illustrates the value of angiographically demonstrating the bleeding site in the preoperative work-up. Emergency angiography and vasopressin infusion have thus contributed to improvements in the management of the patient with massive lower gastrointestinal bleeding by not only allowing for the avoidance of emergency surgery but also by permitting segmental colectomy of the bleeding site.

### References

1. Drapanas T, Pennington G, Kappelman M, Lindsey E. Emergency subtotal colectomy: preferred approach to management of massively bleeding diverticular disease. *Ann Surg* 1973; 177:519-526.
2. Nusbaum M, Baum S. Radiographic demonstration of unknown sites of gastrointestinal bleeding. *Surgical Forum* 1963; 14:374.
3. Baum S, Rosch J, Dotter C, et al. Selective mesenteric arterial in-

- fusions in the management of massive diverticular hemorrhage. *N Engl J Med* 1973; 288:1269-1272.
4. Welch C, Athanasoulis C, Galdabini J. Hemorrhage from the large bowel with special reference to angiodysplasia and diverticular disease. *World J Surg* 1978; 2:73-83.
  5. Nath R, Sequeira J, Weitzman F, et al. Lower gastrointestinal bleeding: diagnostic approach and management conclusions. *Am J Surg* 1981; 141:478-481.
  6. Boley S, DiBiase A, Brandt L, Sammartano R. Lower intestinal bleeding in the elderly. *Am J Surg* 1979; 137:57-64.
  7. Casarella W, Galloway S, Taxin R, et al. Lower gastrointestinal tract hemorrhage: new concepts based on arteriography. *American Journal of Roentgenology* 1974; 121:357-368.
  8. Wright H, Pellicia O, Higgins E, et al. Controlled semi-elective segmental resection for massive colonic hemorrhage. *Am J Surg* 1980; 139:535-538.
  9. Britt L, Warren L, Moore O. Selective management of lower gastrointestinal bleeding. *Am Surg* 1983; 49:121-125.
  10. Boley S, Sammartano R, Brandt L, Sprayregen S. Vascular ectasias of the colon. *Surg Gynecol Obstet* 1979; 149:352-359.
  11. Shbeeb I, Prager E, Love J. The aortic valve-colonic axis. *Dis Colon Rectum* 1984; 27:38-41.
  12. Baum S, Athanasoulis C, Waltman A, et al. Angiodysplasia of the right colon: a cause of gastrointestinal bleeding. *American Journal of Roentgenology* 1977; 129:789-794.
  13. Boley S, Brandt L, Frank M. Severe lower intestinal bleeding: diagnosis and treatment. *Clin Gastroenterol* 1981; 10:65-91.
  14. Baum S, Nussbaum M. The control of gastrointestinal hemorrhage by selective mesenteric arterial infusion of vasopressin. *Radiology* 1974; 98:497-505.
  15. Boley S, Sprayregen S, Sammartano R, et al. The pathophysiological basis for angiographic signs of vascular ectasias of the colon. *Radiology* 1977; 125:615-621.
  16. Boley S, Sammartano R, Adams A, et al. On the nature and etiology of vascular ectasias of the colon: degenerative lesions of aging. *Gastroenterology* 1977; 72:650-660.
  17. Eckstein M, Athanasoulis C. Gastrointestinal bleeding: an angiographic perspective. *Surg Clin North Am* 1984; 64:37-51.
  18. Nussbaum M, Baum S, Blakemore W, et al. Clinical experience with selected intra-arterial infusion of vasopressin in the control of gastrointestinal bleeding from arterial sources. *Am J Surg* 1972; 123:165-172.
  19. Athanasoulis C, Baum S, Rosch J, et al. Mesenteric arterial infusions of vasopressin for hemorrhage from colonic diverticulosis. *Am J Surg* 1975; 129:212-216.
  20. Clark R, Colley D. Pharmacangiography. *Seminars in Roentgenology* 1981; 16:42-51.
  21. Welch J, Donaldson G. Recent experience in the management of cancer of the colon and rectum. *Am J Surg* 1974; 127:258-266.