

THE CONNEXIONS OF THE INFERIOR COLLICULUS AND OF THE DORSAL NUCLEUS OF THE LATERAL LEMNISCUS

BY THE LATE H. H. WOOLLARD AND J. A. HARPMAN

From the Department of Anatomy, University College, London

THE midbrain auditory centres have been the subject of repeated anatomical and physiological investigations. Controversy has ranged around the problems of their fibre connexions and functions. The present paper deals with anatomical observations made with a view to establishing the afferent and efferent connexions of the inferior colliculus and of the dorsal nucleus of the lateral lemniscus. The physiological significance of the anatomical findings is discussed.

MATERIAL AND METHODS

Four guinea-pigs and four cats were used. Lesions were placed in various parts of the medulla or midbrain, by means of a fine knife in the guinea-pigs, and electrolytically by the Clarke-Horsley stereotaxic instrument in the cats. Ether anaesthesia was used, and aseptic precautions were observed. The animals were killed 12 days after the operations. The brains were fixed by perfusion through the blood vessels and prepared by the method of Marchi after fixation in either Müller's fluid or formalin, or according to the chlorate-osmic-formalin technique of Swank & Davenport (1935). The latter method gives preparations in which the incidence of pseudo-Marchi reaction is reduced to a minimum, and allows of counterstaining by cresyl violet.

EXPERIMENTS AND OBSERVATIONS

EXPERIMENT 1

In a guinea-pig a lesion was made with the intention of destroying the cochlear nuclei. During recovery the animal exhibited symptoms of interference with the vestibular apparatus.

Histological examination

Lesion. The ventral cochlear nucleus has been cut away and the dorsal cochlear nucleus has been destroyed (Pl. I, fig. 1). The vestibular nerve has been considerably injured. The dorsal spino-cerebellar tract and restiform body have been slightly damaged where they enter the cerebellum. The cranio-ventral portion of the flocculus has also been affected.

Fibre degeneration. Degenerate fibres from the vestibular nerve run medially and dorsally and are distributed to the lateral, medial, and superior vestibular

nuclei (Pl. I, fig. 1). There is some degeneration in the ramus descendens of the vestibular nerve.

From the region of the lesion degenerate fibres pass into the cerebellum and end in the flocculus, uvula, roof nuclei, and in the lobus medius, ansiformis, and paramedianus. The degeneration in the cerebellum is restricted to the operated side except in the region of the roof nuclei and central part of the lobus medius. A set of degenerate fibres runs with the tractus uncinatus of Russell, ending in the homolateral medial vestibular and globose nuclei.

There is massive degeneration in the trapezoid body. The majority of these fibres run along the lateral and ventral aspects of the medulla and lie ventral to the superior olivary nuclear complex of the injured side (Pl. I, fig. 1). A few fibres (fibres of Held) run dorsal to the restiform body and the spinal nucleus and tract of the trigeminal nerve, then turn ventro-laterally, traverse the spinal nucleus of the fifth cranial nerve and join the trapezoid body. One such fibre is shown in Pl. I, fig. 1.

On the side of the lesion some fibres of the trapezoid body end directly in the lateral region of the superior olive. Many collaterals arising from the trapezoid body run dorsalwards and terminate in the superior and accessory olivary and medial praeolivary nuclei. Other fibres and collaterals end in the trapezoid nuclei. The trapezoid body acquires a more dorsal position on crossing over to the opposite side, where similar connexions obtain. The fibre relationships in question have been confirmed in rat brains prepared by a Cajal reduced silver method and Bodian's protargol technique. The synaptic terminations of fibres and collaterals are verifiable in such material.

Degeneration occurs in the acoustic stria. These fibres, from the region of the lesion, pass dorsal to the restiform body and lateral vestibular nucleus, and thence through the ventral region of the superior vestibular nucleus and medial vestibular nucleus to reach a position immediately lateral to the genu of the facial nerve (Pl. I, fig. 1). Here the acoustic stria divides into two parts. Homolateral fibres run ventralwards, medial to the outgoing fibres of the facial nerve, to reach the area of Monakow and end in the ipsilateral superior olivary nuclear complex. A contralateral set of fibres runs diagonally across the medulla to reach the area of Monakow and the superior and accessory olivary nuclei of the opposite side. Some fibres of the acoustic stria may end in the formatio reticularis on either side of the raphe. Possibly a few fibres of the stria acoustica contribute to the lateral fillet. A group of fibres crosses in the dorsal half of the medulla and ends in the formatio reticularis lateralis, between the spinal root of the trigeminal and the outgoing fibres of the facial nerve. The origin of these fibres is uncertain.

A small number of degenerate fibres runs in the lateral fillet of the operated side; a few end in the corresponding nuclei of the lateral fillet, the remainder ending in the inferior colliculus. The lateral fillet of the opposite side contains many degenerate fibres (Pl. II, fig. 1). Some fibres end in the ventral and dorsal nuclei of the lateral fillet, and a few collaterals form part of the dorsal com-

missure of the lateral lemniscus. The majority enter the inferior colliculus, to the central nucleus of which they are distributed (Pl. II, fig. 1).

It is possible that from their position in the central nucleus of the inferior colliculus some of the degenerate fibres turn horizontally cranialwards to end in the three deeper layers of the superior colliculus. A small number of lateral fillet fibres courses in the inferior brachium and ends in the medial geniculate body.

EXPERIMENT 2

In a guinea-pig a lesion was made in the caudal and dorso-lateral region of the midbrain, a small amount of superficial tissue being removed. The animal made a good recovery.

Histological examination

Lesion. The anterior two-thirds of the right inferior colliculus have been injured (Pl. II, fig. 2). The lesion extends to the medial border of the colliculus, and cranially involves the caudal part of the superior colliculus. On the lateral aspect of the midbrain the lesion extends ventrally, affecting the lateral region of the dorsal nucleus of the lateral fillet and nucleus parabigemini.

Fibre degeneration. There is much degeneration in the right inferior brachium, the fibres of which terminate in the caudo-ventral nucleus of the medial geniculate body. Possibly a few fibres end in the other nuclei of the medial geniculate body.

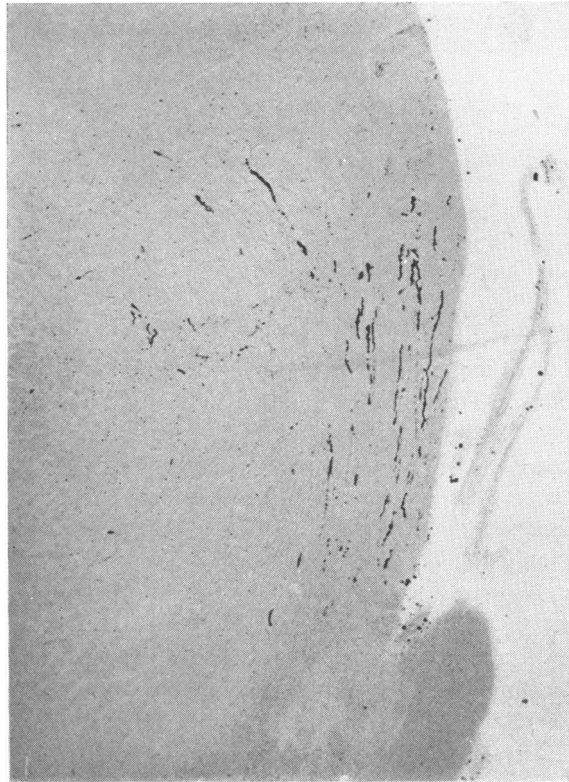
The inferior intercollicular commissure contains many degenerate fibres, which end in the dorsal half of the inferior colliculus of the opposite side.

A bundle of thick fibres arises from the ventro-lateral aspect of the inferior colliculus and courses medialwards between its ventral border and the dorsal nucleus of the brachium conjunctivum (Pl. II, fig. 2). Some of the fibres enter the central grey matter of the aqueduct of Sylvius. Others extend no further than the mesencephalic nucleus of the trigeminal nerve, and possibly terminate in it. The terminations of these fibres could not be established by the examination of reduced silver preparations.

Tecto-pontine fibres arise from the region affected by the cranial part of the lesion. The fibres are thick, and arise either from the cranial pole of the inferior colliculus, the caudal part of the superior colliculus, the nucleus parabigemini, or several of these structures. The most cranial region only of the inferior colliculus possibly contributes to this fibre pathway. The fibres are distributed among those of the lateral fillet (Text-fig. 1), and terminate in the lateral pontine nucleus of the same side.

It is probable that a few fibres extend from the inferior into the three deeper layers of the superior colliculus. The injury to the dorsal nucleus of the lateral lemniscus has led to degeneration in the dorsal commissure of the lateral fillet or commissure of Probst (Pl. II, fig. 2). This degeneration is more than that occurring in this commissure in Exp. 1. The course and terminations

of the commissure show the same features in Exp. 4, and are described under that heading.



Text-fig. 1. Exp. 2. Photomicrograph of a transverse section showing degenerate tecto-pontine fibres among the fibres of the lateral fillet. Chlorate-osmic-formalin. $\times 60$.

EXPERIMENT 3

In a guinea-pig a lesion was placed in the right inferior colliculus. The post-operative course was uneventful.

Histological examination

Lesion. A wedge-shaped portion of tissue has been cut out of the dorso-lateral aspect of the caudal two-thirds of the right inferior colliculus. Caudally the lesion affects the dorso-lateral two-thirds of the colliculus, while cranially it is confined to the surface.

Fibre degeneration. There is much degeneration in the right inferior brachium, the fibres ending in the caudo-ventral nucleus of the medial geniculate body. The inferior intercollicular commissure contains many degenerate fibres, which end in the dorsal half of the uninjured inferior colliculus.

EXPERIMENT 4

In a guinea-pig a lesion was made in the ventral region of the right inferior colliculus. The animal made an uneventful recovery.

Histological examination

Lesion. The lesion affects the ventral region of the caudal two-thirds of the right inferior colliculus, the dorsal nucleus of the lateral lemniscus, and the lateral part of the brachium conjunctivum and dorsal nucleus of the brachium conjunctivum. The caudal part of the right inferior brachium has been cut across.

Fibre degeneration. There are many degenerate fibres in the right inferior brachium, ending in the caudo-ventral nucleus of the medial geniculate body. Many degenerate fibres course in the inferior intercollicular commissure, and end in the dorsal half of the inferior colliculus of the opposite side.

No statement can be made as to whether fibres from the region of the lesion reach the homolateral mesencephalic nucleus or central grey matter, because of pseudo-Marchi reaction in the proximity of the injury.

The dorsal nucleus of the lateral fillet—and possibly also the ventro-lateral region of the inferior colliculus—gives rise to fibres of the commissure of Probst, which shows more degeneration than in Exp. 1. The fibres of the commissure course medialwards, lying ventral to the dorsal nucleus of the brachium conjunctivum, and then through the ventral region of the central grey matter and the homolateral nucleus of the trochlear nerve (Pl. I, fig. 2). It is improbable that any of the fibres end in the latter nucleus. The fibres turn ventralwards and pass through the ipsilateral fasciculi confines and medial longitudinal bundle, to which they do not contribute. At the midline the fibres lie immediately ventral to the medial longitudinal bundles (Pl. I, fig. 2). The fibres continue towards the opposite side, lying ventral to the heterolateral medial longitudinal bundle and fasciculi confines. Some end in the contralateral dorsal nucleus of the brachium conjunctivum and dorsal nucleus of the lateral lemniscus. Others turn dorsalwards and, running with fibres of the lateral fillet, end in the anterior part of the central nucleus of the heterolateral inferior colliculus. The commissural fibres are disposed somewhat obliquely, occupying a slightly more cranial plane at their terminations than at their origin.

Many lateral and ventral fibres of the right brachium conjunctivum have degenerated. They reach the contralateral red nucleus, in which many end. Others, on reaching this position, turn dorsalwards, and penetrating among the fibres of the medial longitudinal bundle and medial fasciculi confines, terminate in the oculomotor nucleus on the side opposite to that upon which the lesion was inflicted. A few degenerate fibres of the brachium conjunctivum continue cranially beyond the red nucleus, and turn dorsally or dorso-laterally to end in the thalamus. They are too few to determine the nucleus in which they end.

EXPERIMENTS 5 AND 6

In two cats in which electrolytic lesions were placed in the cranio-ventral region of the midbrain, the needle electrode passed through the dorsal nucleus of the lateral fillet, which was thus incidentally injured. The post-operative symptoms were referable to the main lesions, and do not call for comment in the present text.

Histological examination

Lesions. In each case the medial half of the left dorsal nucleus of the lateral lemniscus and adjoining lateral fillet fibres have been destroyed. The main lesions and the fibre degeneration ensuing from them are not discussed.

Fibre degeneration. In both cases degenerate fibres, from the lesion, run dorsalwards with the lateral fillet. Most of them end in the homolateral inferior colliculus, mainly in the central nucleus. A few course along the medial aspect of the inferior colliculus and cross in the inferior intercollicular commissure, ending in the contralateral inferior colliculus.

There is much degeneration in the commissure of Probst. In the cat the fibres of this system are disposed in a strictly transverse plane; otherwise they have a similar course and termination as in the guinea-pig.

EXPERIMENT 7

In a cat an electrolytic lesion was placed in the left inferior colliculus. The animal made an uninterrupted recovery.

Histological examination

Lesion. The dorsal third of the caudal third of the left inferior colliculus has been destroyed. More anteriorly the lesion is limited to the dorso-medial fourth of the inferior colliculus. At the level of the cranial third of the inferior colliculus the lesion also extends into the dorso-lateral region of the central grey matter, almost reaching the ependyma of the aqueduct. Cranially the lesion involves the dorso-medial surface of the caudal region of the superior colliculus.

Fibre degeneration. Degenerate fibres course from the lesion across the uninjured part of the inferior colliculus, and reach the homolateral inferior brachium, to the lateral region of which they are confined. There are many degenerate fibres in the inferior intercollicular commissure. Some of them end in the dorsal half of the inferior colliculus of the opposite side, while others enter the heterolateral inferior brachium. In this they attain a lateral position. The degenerate fibres in the inferior brachia terminate in the caudo-ventral nuclei of the corresponding medial geniculate bodies.

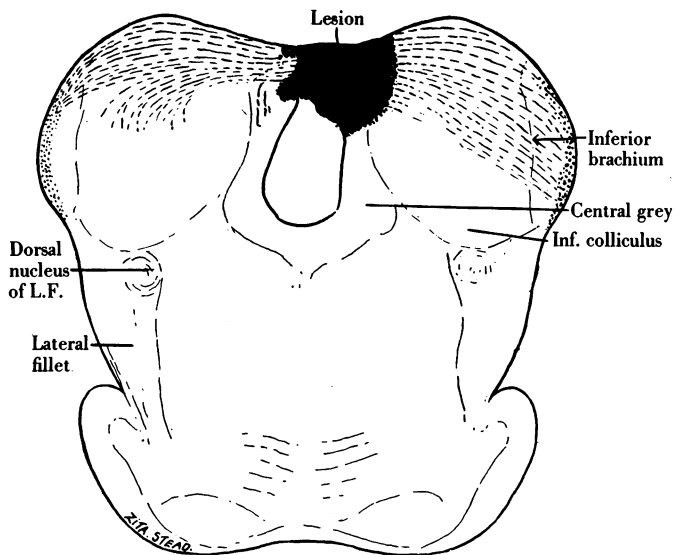
Degenerate fibres occur in the crossed and uncrossed tecto-spinal tracts. They arise from the injured portion of the superior colliculus. From this region tecto-pontine fibres also arise. They form a bundle external to the lateral fillet, ending in the lateral pontine nucleus of the same side.

EXPERIMENT 8

In a cat an electrolytic lesion was made in an inferior colliculus. The animal recovered uneventfully.

Histological examination

Lesion. The lesion affects the dorso-medial region of the caudal two-thirds of the inferior colliculus. Caudally, the dorso-medial sixth of the colliculus has been destroyed. Cranially the lesion is smaller, and involves the junction of the inferior colliculus with the inferior intercollicular commissure. The cranial half of the lesion includes the dorsal region of the central grey matter, and extends into the aqueduct (Text-fig. 2).



Text-fig. 2. Exp. 8. Drawing of a transverse section at the level of the middle of the inferior colliculi, showing the lesion and degenerate fibres.

Fibre degeneration (Text-fig. 2). From the site of the lesion many degenerate fibres course across the uninjured part of the inferior colliculus and enter the ipsilateral inferior brachium. They are confined to the lateral half of the brachium, and end in the caudo-ventral nucleus of the medial geniculate body.

There are many degenerate fibres in the inferior intercollicular commissure. Some of them end in the dorsal half of the contralateral inferior colliculus. The majority enter the heterolateral inferior brachium—in which they occupy the lateral region—and end in the caudo-ventral nucleus of the medial geniculate body.

There are some degenerate, irregularly disposed, short fibres in the central grey matter.

DISCUSSION OF RESULTS

The distribution of the lateral fillet. The course and distribution in the medulla oblongata of the fibres arising from the ventral and dorsal cochlear nuclei and the vestibular nerve as established in Exp. 1 are in agreement with the observations of Held (1891, 1892, 1893), Tschermak (1899), Cajal (1909-11), Lewy (1909), Yoshida (1924, 1925) and others on Weigert, Golgi and Marchi preparations of various mammals. There is some discrepancy regarding the terminations of the lateral fillet in the midbrain, medial geniculate body and possibly cerebral cortex. Held, from Weigert and Golgi preparations of brains of the cat, rabbit, chimpanzee and human foetus, concludes that fibres from the lateral fillet end in the homolateral dorsal nucleus of the lateral fillet, homolateral and contralateral inferior and superior colliculi, and cerebral cortex. Fibres from the cochlear nerve and the secondary auditory relay nuclei are supposed to reach the cortex. Most of the fibres to the cortex are stated to course in the superior brachium. The medial geniculate body is not mentioned. The auditory radiation is considered to consist of lateral fillet fibres and a smaller contribution from the inferior colliculus. Van Gehuchten (1906 *a, b*), from Marchi studies on the guinea-pig, concludes that all the fibres of the cochlear nerve end in the dorsal and ventral cochlear nuclei. Kölliker (1896), from Golgi preparations of the cat and Weigert material of the human brain, describes the lateral fillet as ending in the dorsal nucleus of the lateral fillet and the inferior and superior colliculi. Tschermak, from Marchi preparations of the brain of a cat in which the trapezoid body had been sectioned, concludes that fibres from the lateral fillet end in the inferior and superior colliculi. The homolateral fibres of the lateral fillet arise mainly from the superior and accessory olivary, medial praeolivary and trapezoid nuclei. This is in agreement with the findings of Held and Cajal, who also, however, include in the ipsilateral lateral fillet fibres from the cochlear nuclei. The occurrence of a few degenerate fibres in the lateral fillet of the operated side in Exp. 1 is in agreement with the interpretations of Held, Tschermak and Cajal. Cajal (1902), from Golgi preparations of the brain of the mouse, describes the majority of the fibres of the lateral fillet as entering the inferior brachium and ending in the medial geniculate body. Many of the fibres send collaterals into the inferior and superior colliculi, in which also terminate a few direct fibres. Some fibres of the lateral fillet cross in the inferior intercollicular commissure to end in the inferior colliculus of the opposite side. Valeton (1907), from myelogenesis studies on human material, concludes that fibres of the lateral fillet end in the inferior and superior colliculi. Valeton (1908) also states, from observations on Weigert preparations of a large series of mammalian brains, that some fibres of the lateral fillet cross in the anterior medullary velum to end in the inferior colliculus of the opposite side. No degenerate fibres have been observed in the anterior medullary velum in any of the present experiments involving the lateral fillet (Exps. 1, 5 and 6), dorsal nucleus of the lateral fillet (Exps. 2, 4, 5 and 6) and inferior colliculus (Exps. 2, 3, 4, 7 and 8). Lewy, from Marchi studies on the cat and rabbit,

describes the lateral fillet as ending in the inferior colliculus. Castaldi (1926), from investigation of the brains of embryonic and neonatal guinea-pigs prepared by the methods of Cajal and Weigert, concludes that the superior colliculus receives a small number of lateral fillet fibres.

Exp. 1 shows that in the guinea-pig the majority of the lateral fillet fibres arising from the dorsal and ventral cochlear nuclei end in the contralateral inferior colliculus. A small number of fibres ends in the contralateral ventral and dorsal nuclei of the lateral lemniscus. A few fibres end in the medial geniculate body, while the termination of lateral fillet fibres in the superior colliculus is doubtful; if any are present they are few in number. In Exp. 1 the possibility of fibres from the superior olivary nuclear complex or the trapezoid nuclei reaching the superior colliculus is not excluded. It is unlikely, however, that any appreciable proportion of lateral fillet fibres end in the superior colliculus, since in Exps. 4, 5 and 6 no fibres were seen to extend from the region of the lesion into this structure, whilst in Exp. 2 only a few fibres possibly course from the injured area into the superior colliculus. In each of these cases the lesion should have interrupted some of the lateral fillet fibres that may go to the superior colliculus.

A small group of fibres arising from the dorsal and ventral cochlear nuclei terminates in the homolateral nuclei of the lateral fillet and inferior colliculus.

The inferior brachium. The contribution of the lateral fillet to the inferior brachium has been discussed in the preceding section. The majority of the fibres in the inferior brachium are derived from the inferior colliculus of the same side. Valeton (1908) and Obersteiner (1912), the latter from Weigert preparations of the human brain, claim that fibres from the inferior intercollicular commissure enter the inferior brachium. Jeléńska-Macieszyna (1911), from Marchi material of the rabbit, denies the existence of such fibres. Similar fibres have been observed in Exps. 7 and 8 on cats. In these cases the lesions involve the dorso-medial region of the inferior colliculus. No fibres from the inferior intercollicular commissure have been observed to enter the inferior brachium in Exps. 2, 3 and 4 on guinea-pigs, in which the lesions in the inferior colliculus have not affected the dorso-medial region of this structure.

Jeléńska-Macieszyna states that, while possibly a few fibres of the inferior brachium end in the "dorsal" nucleus of the medial geniculate body, the majority end in the "ventral" nucleus. In the present experiments the ascending fibres of the inferior brachium were found to end in the caudo-ventral nucleus of the medial geniculate body.

In Exps. 7 and 8 the degenerate fibres in the homolateral and contralateral inferior brachia are confined to the lateral region of these structures. In these cases the lesions are limited to a small portion of the inferior colliculus, and do not interrupt fibres arising from its uninjured parts. The findings suggest a spatial arrangement of the fibres in the inferior brachium. It is possible that there is a point-to-point relationship between the components of the inferior colliculus and the medial geniculate body. A localization in the medial genicu-

late body with regard to various parts of the audito-sensory cortical area has been shown by Clark (1936*a*) and Walker (1937) in the macaque, from observations on retrograde cell degenerations in the diencephalon after ablation of various portions of the temporal lobe. Poliak (1932) and Woollard & Harpman (1939), from Marchi studies on the macaque and cat respectively, have described a regular arrangement of the geniculo-cortical fibres, so that, for instance, in the cat the fibres from the lateral part of the medial geniculate body reach the caudal, those from the medial part the cranial, those from the dorsal portion the dorsal and those from the ventral part the ventral region of the audito-sensory cortex. Ades *et al.* (1939), by the method of conditioned reflexes, have shown that in the cat there is a precise spatial localization of different sound frequencies in the medial geniculate body. Poliak (1927), Lorente de Nó (1933) and Lewy & Kobrak (1936) have demonstrated a regular pattern in the projection of the organ of Corti on the cochlear nuclei. Culler (1935), Stevens *et al.* (1935) and Culler *et al.* (1937) have shown that the several segments of the cochlea respond differentially to acoustic stimuli of different frequencies. There is thus a precise localization of function in the auditory system. A point-to-point projection extending from the organ of Corti to the cerebral cortex is the requisite of the Helmholtz theory of hearing or its modifications. Such a relationship has been shown to exist between the medial geniculate body and the cortex, and the organ of Corti and the cochlear nuclei; the observations of Exps. 7 and 8 suggest that it may also occur between the inferior colliculus and the medial geniculate body. The observations of Lewy indicate at least an orderly disposition of the fibre connexions of the medullary auditory nuclei.

Winkler (1921) states that fibres from the inferior colliculus reach the cortex via the inferior brachium. In the present experiments no ascending fibres in the posterior brachium have been observed to reach any structure other than the caudo-ventral nucleus of the medial geniculate body.

Descending fibres from the inferior colliculus. There is much controversy on the contribution that the inferior colliculi may make to descending tectal connexions. Held describes fibres from the inferior colliculus and dorsal nucleus of the lateral lemniscus coursing among the fibres of the lateral fillet and ending in the homolateral superior olivary and trapezoid nuclei. Fibres from the inferior colliculus to the dorsal nucleus of the lateral fillet are also described. Kölliker denies the existence of any of these fibres. Cajal describes crossed and uncrossed descending pathways arising from the anterior region of the inferior colliculus; the crossed fibres form part of the tecto-spinal tract. Each pathway consists of fibres from both inferior colliculi, those derived from the contralateral inferior colliculus crossing in the inferior intercollicular commissure. The destination of these tracts is unknown. Winkler (1920) mentions fibres from the inferior colliculus to the dorsal nucleus of the lateral fillet. Castaldi (1926) describes homolateral tecto-pontine fibres arising from cells along the lateral aspect of the inferior colliculus, and "recurrent tecto-cochlear fibres of the lateral fillet" which, arising from the "principal" nucleus

of the inferior colliculus, descend in the lateral fillet. The terminations of these tracts are not specified. Tsai (1925), from Weigert preparations of the brain of the opossum, describes various fibre systems from the superior and inferior colliculi to the lateral nucleus of the pons and the substantia nigra. The tracts described are stated to arise principally from the inferior colliculi. Rioch (1929), from similar material of carnivores, describes tecto-nigral and nigro-tectal tracts associated mainly with the inferior collicular portion of the mesencephalic tectum.

Observations using the Marchi technique have also led to conflicting results. Tricomi-Allegra (1907), in the rabbit, placed lesions in the anterior part of the inferior colliculus. Degenerate fibres are stated to enter the decussations of Meynert and Forel to reach the heterolateral formatio reticularis and red nucleus. Tecto-pontine fibres arise from the lateral region of the lesions. They lie external to the lateral fillet and end in the pontine nuclei. Jelenska-Macieszyna (1911), in the rabbit, placed lesions in the dorsal half of the inferior colliculus. Descending fibres are described coursing from the caudal region of the central nucleus of the inferior colliculus to the dorsal nucleus of the lateral lemniscus, and possibly also to homolateral vestibular nuclei. Busacca (1921), in the dog, describes an uncrossed set of fibres that, arising from the inferior colliculus, runs at first with the lateral fillet, then lies ventro-lateral to the superior olive, and can be traced as far caudalwards as the second cervical segment of the spinal cord.

The tecto-pontine tract was discovered by Münzer (1898) and Münzer & Wiener (1898, 1902), who named it the superficial tecto-bulbar tract. It was demonstrated by the Marchi method in the pigeon after lesions of the corpus bigeminum, and in the rabbit after lesions of the superior colliculus. In the rabbit the tract arises from the caudal part of the superior colliculus and lies external to the lateral fillet. The majority of the fibres end in the homolateral pontine nuclei. A few fibres reach a somewhat more medial position and end in the neighbourhood of the medial fillet; the figures suggest that they terminate in the trapezoid nuclei. Pawlow (1900) describes the tecto-pontine tract in a rabbit in which a lesion is stated to have been placed in the superior colliculus. Examination of the author's illustrations reveals that the lesion also affected the ventral part of the cranial pole of the inferior colliculus. The fibres were traced in Marchi preparations; they lie external to the lateral fillet and terminate in the homolateral nuclei of the pons. Van Gehuchten (1906*a, b*) states that, while from his earlier experiments he believed that Münzer's fibres arise from the inferior colliculus, further work and the examination of Pawlow's specimen have led him to the conclusion that the tecto-pontine tract arises from the superior colliculus. De Lange (1910), in the rabbit, studied descending tectal fibres by the methods of Weigert, Nissl and Marchi. The lesions were made by undercutting the tectum. Crossed and uncrossed tecto-bulbar and tecto-spinal fibres arise from the superior colliculus. Fibres—mostly uncrossed but a few crossed—arise from the caudal part of the superior colliculus and end in

the region of the trapezoid body and pontine nuclei. The cranial extremity of the inferior colliculus may contribute to some or all of the fibre systems described. Jelenska-Macieszyna (1911, 1913), from Marchi studies on the rabbit, concludes that the tecto-pontine tract arises from the caudal region of the superior colliculus. Rasmussen (1936), from Marchi material of the cat, establishes that the tecto-spinal tract arises only from the superior colliculus.

In the present material tecto-pontine fibres were observed in Exps. 2 and 7, in which the lesion includes the caudal extremity of the superior colliculus. In Exp. 2, on a guinea-pig, it is not possible to determine whether the fibres arise from the cranial pole of the inferior colliculus, the caudal part of the superior colliculus, the nucleus parabigeminus, or several of these centres. In Exp. 7, on a cat, degenerate tecto-pontine and crossed and uncrossed tecto-spinal fibres arise from the injured region of the superior colliculus. In the guinea-pig, the more primitive form, the tecto-pontine fibres are scattered among the fibres of the lateral fillet. In the cat they form a compact bundle external to the lateral fillet. The same topographic relation obtains in the rabbit (Münzer & Wiener, Pawlow, Tricomi-Allegra). The tecto-pontine fibres are uncrossed and terminate in the lateral nucleus of the pons. No other descending fibres were observed in the present experiments.

Fibres from the inferior colliculus to the central grey matter. Scattered short fibres from the inferior colliculus to the central grey matter have been described by Cajal and Castaldi. There is no mention in previous literature of the bundle of fibres observed in Exp. 2, arising from the ventro-lateral region of the inferior colliculus and going to the central grey matter and possibly the homolateral mesencephalic nucleus of the fifth nerve.

Fibres from the inferior to the superior colliculus. Whilst Held and Cajal state that cells in the cranial region of the inferior colliculus give rise to fibres ending in the superior colliculus, no mention of such a connexion is made by authors who have applied experimental methods. The results of Exp. 2 indicate that such fibres probably exist, but that they are very few in number. The fibres described by Held from the dorsal nucleus of the lateral fillet to the superior colliculus have not been observed in the present material.

Negative results. Cajal describes fibres from the inferior colliculus contributing to the commissure of Gudden. Castaldi traced this commissure in two guinea-pigs in which the optic tracts were atrophied by excising the eyes. The commissure could be traced no further caudalwards than the medial geniculate bodies. Weaver (1937), from experimental studies on the cat, emphasizes that the commissures of Meynert and Gudden are one complex, the inferior hypothalamic decussation. While Gudden (1879) believed it to connect the medial geniculate bodies, there is as yet no satisfactory evidence of its origin, which would appear to be several diencephalic nuclei. In the present experiments no degenerate fibres were observed in the inferior hypothalamic decussation.

No fibres from the inferior colliculus were found to join the tecto-cerebellar

tract or to reach the cerebellum by any other way. This observation is in accord with the results of previous workers.

Fibres from the dorsal nucleus of the lateral lemniscus. Kölliker describes fibres coursing from the dorsal nucleus of the lateral fillet into the homolateral inferior colliculus, and remarks that possibly fibres from the dorsal nucleus of the lateral fillet enter the inferior intercollicular commissure. A few degenerate fibres reaching the inferior colliculus of the opposite side through the inferior intercollicular commissure from lesions involving the dorsal nucleus of the lateral fillet and adjoining lateral fillet fibres were observed in Exps. 5 and 6 on cats, but not in Exps. 2 and 4 on guinea-pigs. Degenerate fibres enter the homolateral inferior colliculus in Exps. 5 and 6, but it is not certain whether they are derived from the dorsal nucleus of the lateral lemniscus or whether they are lateral fillet fibres.

The fibres of the commissure of Probst (dorsal commissure or transverse fibres of the lateral fillet) are considered to be derived from four sources: collaterals of fibres of the lateral fillet (Held, Cajal, Castaldi), the dorsal nucleus of the lateral lemniscus (Held, Castaldi), the inferior colliculus (Held, Kölliker) and the nucleus of Kölliker-Fuse (Castaldi). The first two sources are confirmed by Exps. 1, 2, 4, 5 and 6 of the present series. No fibres have been traced into the commissure in Exps. 3, 7 and 8, in which the lesions are confined to the dorsal part of the inferior colliculus. Whether fibres from the ventral part of the inferior colliculus or from the nucleus of Kölliker-Fuse take part in the commissure has not been determined in the present experiments. The course of these fibres in the guinea-pig, described in the record of Exp. 4, agrees with the observations of Castaldi on the same animal. The following are some of the terminations of the fibres of the commissure of Probst that have been inferred from the study of normal material: the contralateral inferior colliculus (Held), the homolateral nucleus of the trochlear nerve (Ziehen, 1903*a, b*), the contralateral reticular nuclei and the mesencephalic nucleus (Bechterew & Lagursky, 1897), the contralateral dorsal nucleus of the lateral fillet (Lewandowsky) and the medial longitudinal bundle (Winkler, 1920). It may form a contralateral descending tract (Castaldi). The present observations show that the fibres of this system end in the contralateral dorsal nucleus of the lateral fillet, dorsal nucleus of the brachium conjunctivum and central nucleus of the inferior colliculus. The dorsal nucleus of the brachium conjunctivum is the dorso-lateral of two cell masses depicted by Winkler & Potter (1911, 1914) lying in relation to the superior peduncle, and especially well developed at the level of the inferior colliculus.

Cajal and Huber & Crosby (1929) describe fibres from the dorsal nucleus of the lateral fillet to the medial geniculate body of the same side. Such fibres have not been observed in Exps. 5 and 6, in which the lesions were limited to the dorsal nucleus of the lateral fillet and adjacent lateral fillet fibres.

Incidental findings. The distribution of degenerate fibres in the cerebellum observed in Exp. 1 is in agreement with the generally accepted cerebellar

terminations of the vestibular nerve, restiform body and dorsal spino-cerebellar tract.

In Exp. 1 fibres were found arising from the region of the lesion and terminating in the homolateral medial vestibular and globose nuclei. They follow a course similar to, but in the reverse direction of, the fasciculus uncinatus of Russell. They are possibly those described by Lewy as the radix verticalis, connecting the ganglion of Scarpa with the superior and medial vestibular nuclei. The radix verticalis runs like the fasciculus uncinatus, lying dorsal to the restiform body after passing through the ventral cochlear nucleus.

The termination of fibres of the brachium conjunctivum in the contralateral oculomotor nucleus observed in Exp. 4 has been described by Wallenberg (1898), Klimoff (1901), Saito (1922, 1923), Riese (1925) and Clark (1936*b*).

CORRELATION OF THE ANATOMICAL FINDINGS WITH PHYSIOLOGICAL WORK

Electrical stimulation of the inferior colliculus has given discrepant results. Ferrier (1876), Prus (1899) and Bechterew (1909), working on the monkey, dog, cat, rabbit, guinea-pig, rat and sheep, obtained a variety of responses, including clonic and tonic extensor spasms, walking movements, deviation of the head, body and eyes to the opposite side, and of the head and body to the same side when stronger stimuli were employed, rotation, erection and abduction of the ears (especially that of the opposite side), dilatation of the pupil, slowing of respiration and pulse rates, and rise in blood-pressure. Prus obtained in the dog the same motor reactions of the head, body and eyes on painting the inferior colliculi with cocaine. Recent workers, on electric stimulation of the inferior colliculus in the cat, record no effect on the pupil (Ingram *et al.* 1931), blood pressure (Kabat *et al.* 1935), muscle tone of the bladder (Kabat, 1936) or respiration (Kabat *et al.* 1936). These investigators employed currents of moderate intensity and accurately localized the point of stimulation by the Clarke-Horsley stereotaxic instrument. Some of the fibre pathways concerned in the control of blood pressure, muscle tone of the bladder and rate and amplitude of respiration lie close to the medial border of the inferior colliculus. It is probable that at least some of the reactions obtained by earlier investigators were due to spread of the electric current to neighbouring fibres or nuclei.

Ferrier, Marckwald, Lewandowsky (1896), Prus and Bechterew, from ablation and electric stimulation experiments, conclude that the inferior colliculus influences respiration and phonation. Similar experiments by Klemperer, Grabower (1897, 1911), Spiegel & Enghoff (1925), Spiegel & Ullmann (1926) and Kabat *et al.* (1936) offer no support to the conception that the inferior colliculus is related to the mechanism of respiration or phonation.

Unilateral removal of an inferior colliculus in the rat, rabbit, and guinea-pig leads, according to Bechterew (1895, 1909), to transient absence or diminution of reflex movements of the contralateral external ear to auditory stimuli. Spiegel & Kakeshita (1926), working on the cat and guinea-pig, found that

removal of the mesencephalic tectum or section of the brain stem caudal to the inferior colliculi does not abolish reflex movements of the auricular muscles, closing of the eyelids or contraction of the body musculature to auditory stimuli, provided these are sufficiently loud. Forbes & Sherrington (1914), after section of the brain stem cranial to the inferior colliculi, obtained similar motor reactions employing auditory stimuli of moderate intensity. Spiegel & Kakeshita conclude that the inferior colliculi may be reflex centres for "certain kinds" of auditory stimuli. Motor responses to sounds may be subserved by collaterals from the trapezoid body to the facial nucleus and reticular nuclei of the hindbrain (Held, 1893), and by fibres from the superior olive to the medial longitudinal bundle and the nucleus of the abducens nerve (Yoshida, 1925).

The present observations disclose three possible fibre pathways for reflex activities of the midbrain auditory centres. They are: the fibres from the ventrolateral region of the inferior colliculus to the central grey matter and possibly the mesencephalic nucleus of the fifth nerve, the fibres of the commissure of Probst terminating in the dorsal nucleus of the brachium conjunctivum, and the probably existing fibres from the inferior to the superior colliculus. The significance of the first fibre connexion is doubtful. Kappers *et al.* (1936) state that the nuclei of the brachium conjunctivum contribute fibres to the superior peduncle and probably receive fibres from the ventral spino-cerebellar tract. They are, therefore, probably motor centres. Gerver has shown that a much stronger electric current is required to obtain movements of the eyes by electric stimulation of the inferior than of the superior colliculus. Stimulation of the inferior colliculi does not produce movements of the eyes when they have been separated from the superior colliculi by a cover-slip. The paucity of the possible reflex pathways from the inferior colliculus indicates that the majority of the motor reactions obtained by electric stimulation of this structure are due to diffusion of the current.

Marchi studies by the present writers have shown that in the cat and guinea-pig fibres arising from the temporal region of the cerebral cortex end in the homolateral medial geniculate body and inferior colliculus. In the cat the fibres to the medial geniculate body arise from the audito-sensory area. These fibres are also described by Mettler (1932), from similar material. The exact origin of the cortical fibres to the inferior colliculus in the cat remains to be determined. In the macaque the medial geniculate body receives fibres from the superior temporal gyrus, and the inferior colliculus is supplied with fibres from most of the temporal region (Mettler, 1935). Woollard & Harpman have shown that the medial geniculate body gives rise to no fibre tracts other than the auditory radiation and possibly Gudden's commissure. It is, therefore, a purely sensory centre. The observations recorded in the present paper show that the inferior colliculus is almost wholly a sensory nucleus. It is, therefore, postulated that the fibres from the temporal region of the cortex to the medial geniculate body and inferior colliculus exert a controlling effect upon the sensory impulses received by these centres. Brouwer (1928) has similarly

suggested that the fibres extending from the visual cortical area to the lateral geniculate body transmit inhibitory impulses.

SUMMARY

1. The connexions of the inferior colliculus and of the dorsal nucleus of the lateral lemniscus have been studied in four guinea-pigs and four cats by the method of Marchi and its modification by Swank and Davenport.

2. The majority of the lateral fillet fibres arising from the cochlear nuclei end in the contralateral nuclei of the lateral fillet and central nucleus of the inferior colliculus.

3. Some fibres from the cochlear nuclei end in the homolateral nuclei of the lateral fillet and inferior colliculus.

4. A few lateral fillet fibres end in the medial geniculate body.

5. The termination of lateral fillet fibres in the superior colliculus is problematical.

6. In the guinea-pig, the inferior brachium contains fibres derived from the homolateral inferior colliculus and a few lateral fillet fibres; in the cat it also receives fibres from the contralateral inferior colliculus through the inferior intercollicular commissure.

7. The ascending fibres in the inferior brachium end in the caudo-ventral nucleus of the medial geniculate body.

8. In two cats the findings suggest a spatial arrangement of the fibres in the inferior brachium.

9. Tecto-pontine fibres arise, in the guinea-pig, from either the cranial pole of the inferior colliculus, the caudal part of the superior colliculus, the nucleus parabigemini, or several of these centres. They course among the fibres of the lateral fillet, and end in the ipsilateral lateral pontine nucleus.

10. Tecto-pontine fibres arise, in the cat, from the caudal region of the superior colliculus. They form a bundle external to the lateral fillet, and terminate as in the guinea-pig.

11. Fibres arise from the ventro-lateral region of the inferior colliculus, course medialwards, and end in the central grey matter and possibly in the homolateral mesencephalic nucleus.

12. A few fibres probably run from the inferior to the superior colliculus.

13. The commissure of Probst, or dorsal commissure of the lateral fillet, receives fibres from the dorsal nucleus of the lateral lemniscus and collaterals from lateral fillet fibres. The fibres of the commissure end in the contralateral dorsal nucleus of the lateral lemniscus, dorsal nucleus of the brachium conjunctivum, and central nucleus of the inferior colliculus.

14. Other fibres stated in the literature to arise from the inferior colliculus and dorsal nucleus of the lateral fillet have not been found.

15. The anatomical findings are correlated with physiological work. It is concluded that the midbrain auditory nuclei subservise very few reflex activities, being almost wholly sensory centres.

16. It is suggested that the fibres from the temporal region of the cortex to the medial geniculate body and inferior colliculus control the sensory impulses received by these centres.

Our thanks are due to Mr F. J. F. Barrington for performing the operations in Exps. 7 and 8.

REFERENCES

- ADES, H. W., METTLER, F. A. & CULLER, E. A. (1939). *Amer. J. Physiol.* **125**, 17.
- BECHTEREW, W. v. (1895). *Neurol. Zbl.* p. 706.
- (1909). *Die Funktionen der Nervenzentra*, 2, 1065. Jena.
- BECHTEREW, W. v. & LAGURSKY (1897). Quoted by Castaldi, L. (1926).
- BROUWER, B. (1928). *Dtsch. Z. Nervenheilk.* **105**, 9.
- BUSACCA, A. (1921). *Folia neuro-biol., Lpz.*, **12**, 165.
- CAJAL, S. R. Y (1902). *Trab. Lab. invest. Biol. Univ. Madrid*, **1**, 207.
- (1909–11). *Histologie du système nerveux de l'homme et des vertébrés*. 2 vols. Paris.
- CASTALDI, L. (1926). *Arch. Anat.* **23**, 481.
- CLARK, W. E. LE GROS (1936a). *J. Anat., Lond.*, **70**, 447.
- (1936b). *J. Anat., Lond.*, **71**, 7.
- CULLER, E. A. (1935). *Ann. Otol., etc., St Louis*, **44**.
- CULLER, E. A., WILLMAN, J. & METTLER, F. A. (1937). *Amer. J. Physiol.* **119**, 292.
- FERRIER, D. (1876). *The Functions of the Brain*. London.
- FORBES, A. & SHERRINGTON, C. S. (1914). *Amer. J. Physiol.* **35**, 367.
- GEUCHTEN, A. VAN (1906a). *Le névraxe*, **8**, 39.
- (1906b). *Anatomie du système nerveux de l'homme*. Louvain.
- GERVER. Quoted by von Bechterew, W. (1909).
- GRABOWER (1897, 1911). Quoted by Spiegel, E. A. (1927).
- GUDDEN, B. v. (1879). *Arch. Ophthal.* **25**, **1**, 237.
- HELD, H. (1891). *Arch. Anat. Physiol., Anat. Abt.*, p. 27.
- (1892). *Arch. Anat. Physiol., Anat. Abt.*, p. 33.
- (1893). *Arch. Anat. Physiol., Anat. Abt.*, p. 201.
- HUBER, G. C. & CROSBY, E. C. (1929). *J. comp. Neurol.* **48**, 1.
- INGRAM, W. R., RANSON, S. W. & HANNETT, F. I. (1931). *Amer. J. Physiol.* **98**, 687.
- JELÉNSKA-MACIESZYNA, S. (1911). *Neurol. Zbl.* p. 473.
- (1913). *Folia neuro-biol., Lpz.*, **6**, 23.
- KABAT, H. (1936). *J. comp. Neurol.* **64**, 187.
- KABAT, H., MAGOUN, H. W. & RANSON, S. W. (1935). *Arch. Neurol. Psychiat., Chicago.*, **34**, 931.
- — — (1936). *J. comp. Neurol.* **63**, 211.
- KAPPERS, C. U. A., HUBER, G. C. & CROSBY, E. C. (1936). *The Comparative Anatomy of the Nervous System*, **1**, 813. New York.
- KLEMPERER. Quoted by Spiegel, E. A. (1927).
- KLIMOFF, J. (1901). *Arch. mikr. Anat.*
- KÖLLIKER, A. v. (1896). *Lehrbuch der Gewebelehre*, **2**, 391. Leipzig.
- LANGE, S. J. DE (1910). *Folia neuro-biol., Lpz.*, **3**, 633.
- LEWANDOWSKY, M. (1896). Quoted by Spiegel, E. A. (1927).
- Quoted by Castaldi, L. (1926).
- LEWY, F. H. (1909). *Folia Neuro-biol., Lpz.*, **2**, 471.
- LEWY, F. H. & KOBRAK, H. (1936). *Arch. Neurol. Psychiat., Chicago.*, **35**, 839.
- MARCKWALD. Quoted by Spiegel, E. A. (1927).
- METTLER, F. A. (1932). *J. comp. Neurol.* **55**, 139.
- (1935). *J. comp. Neurol.* **63**, 25.
- MÜNZER, E. (1898). *Prag. med. Wschr.*
- MÜNZER, E. & WIENER, H. (1898). *M Schr. Psychiat. Neurol.* **3–4**.
- — — (1902). *M Schr. Psychiat. Neurol.* **12**, 241.
- NÓ, R. LORENTE DE (1933). *Laryngoscope*, **43**, 327.

- OBERSTEINER, H. (1912). *Anleitung beim Studium des Baues der nervösen Zentralorgane*, 5th ed. p. 410.
- PAWLOW, M. (1900). *Le névraxe*, **1**, 129.
- POLIAK, S. (1927). *Z. ges. Anat. I. Z. Anat. EntwGesch.* **84**.
- (1932). *The Main Afferent Fibre Systems of the Cerebral Cortex in Primates*. Univ. California Press, Berkeley.
- PRUS, J. (1899). *Wien. klin. Wschr.* pp. 112, 1311.
- RASMUSSEN, A. T. (1936). *J. comp. Neurol.* **63**, 501.
- RIESE, W. (1925). *Z. ges. Neurol. Psychiat.* **94**, 629.
- RIOCH, D. McK. (1929). *J. comp. Neurol.* **49**, 121.
- SAITO, M. (1922, 1923). *Arb. neurol. Inst. (Inst. Anat. Physiol. ZentNerv.) Univ. Wien*, **23**, 74 and **24**, 77.
- SPIEGEL, E. A. (1927). "Die Region der Vierhügel. Corpus quadrigeminum posterius." In Bethe's *Handb. norm. pathol. Physiol.* **10**, 200.
- SPIEGEL, E. A. & ENGHOFF (1925). Quoted by Spiegel, E. A. (1927).
- SPIEGEL, E. A. & ULLMANN (1926). Quoted by Spiegel, E. A. (1927).
- SPIEGEL, E. A. & KAKESHITA (1926). *Pflüg. Arch. ges. Physiol.* **212**, 769.
- STEVENS, S. S., DAVIS, H. & LURIE, M. H. (1935). *J. gen. Psychol.* **13**, 297.
- SWANK, R. L. & DAVENPORT, H. A. (1935). *Stain Tech.* **10**, 87.
- TRICOMI-ALLEGRA, G. (1907). *Anat. Anz.* **31**, 335.
- TSAI, C. (1925). *J. comp. Neurol.* **39**, 217.
- TSCHERMAK, A. (1899). *Neurol. Zbl.* **18**, 674, 731.
- VALETON, M. T. (1907). *De mergscheede ontwikkeling van den nervus octavus*. Amsterdam.
- (1908). *Arb. neurol. Inst. (Inst. Anat. Physiol. ZentNerv.) Univ. Wien*, **14**, 29.
- WALLENBERG, A. (1898). *Anat. Anz.* **14**, 353.
- WALKER, A. E. (1937). *J. Anat., Lond.*, **71**, 319.
- WEAVER, T. A. (1937). *J. comp. Neurol.* **66**, 333.
- WINKLER, C. (1920). *Opera Omnia*, no. 7.
- (1921). *Manuel de Neurol., Haarlem*, **1**, 324.
- WINKLER, C. & POTTER, A. (1911). *An Anatomical Guide to Experimental Researches on the Rabbit's Brain*. Amsterdam.
- (1914). *An Anatomical Guide to Experimental Researches on the Cat's Brain*. Amsterdam.
- WOOLLARD, H. H. & HARPMAN, J. A. (1939). *J. Neurol. Psychiat., Lond.*, **2**, N.S., no. 1, p. 35.
- YOSHIDA, I. (1924). *Folia anat. japon.* **2**, 289.
- (1925). *Folia anat. japon.* **3**, 111.
- ZIEHEN, T. (1903a). *Mschr. Psychiat. Neurol.* **14**, 54.
- (1903b). *Mschr. Psychiat. Neurol.* **14**, 289.

EXPLANATION OF PLATES I AND II

PLATE I

- Fig. 1. Exp. 1. Photomicrograph of a transverse section at the level of the cochlear nuclei, showing the lesion and the degeneration in the fibres of the vestibular nerve, trapezoid body and acoustic stria. Marchi. $\times 20$.
- Fig. 2. Exp. 4. Photomicrograph of a transverse section at the level of the junction of the caudal with the middle third of the inferior colliculi. The figure shows the relation of the degenerate fibres of the commissure of Probst to the fasciculi confines, medial longitudinal bundles and homolateral nucleus of the trochlear nerve. Marchi. $\times 60$.

PLATE II

- Fig. 1. Exp. 1. Photomicrograph of a transverse section at the level of the middle of the inferior colliculi, showing the termination of degenerate fibres of the lateral fillet in the dorsal nucleus of the lateral fillet and central nucleus of the inferior colliculus. Marchi. $\times 50$.
- Fig. 2. Exp. 2. Photomicrograph of a transverse section at the level of the middle of the inferior colliculi. The figure shows the lesion, a bundle of fibres arising from the ventro-lateral region of the colliculus and ending in the central grey matter and possibly the homolateral mesencephalic nucleus, and degeneration in the commissure of Probst. Chlorateosmic-formalin. $\times 27$.

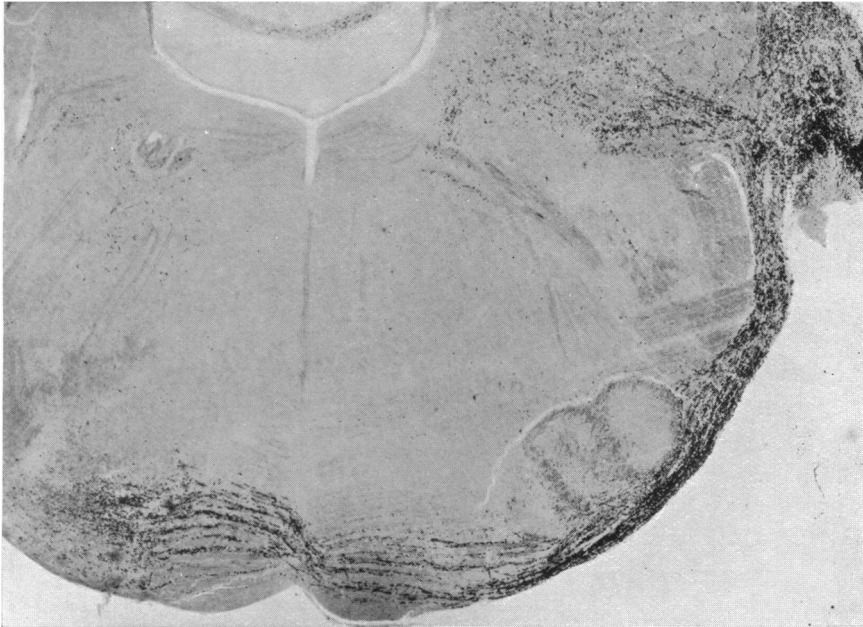

Fig. 1.

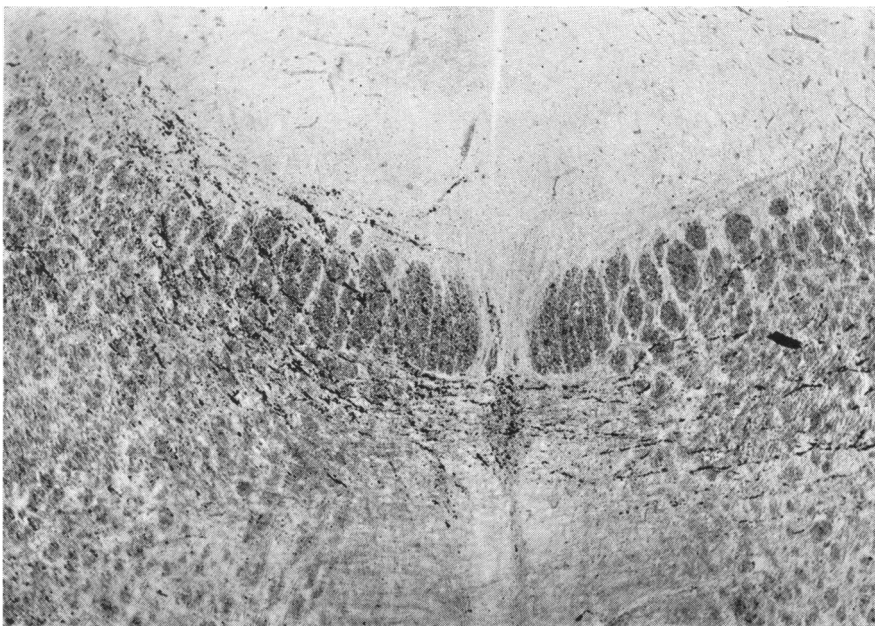


Fig. 2.

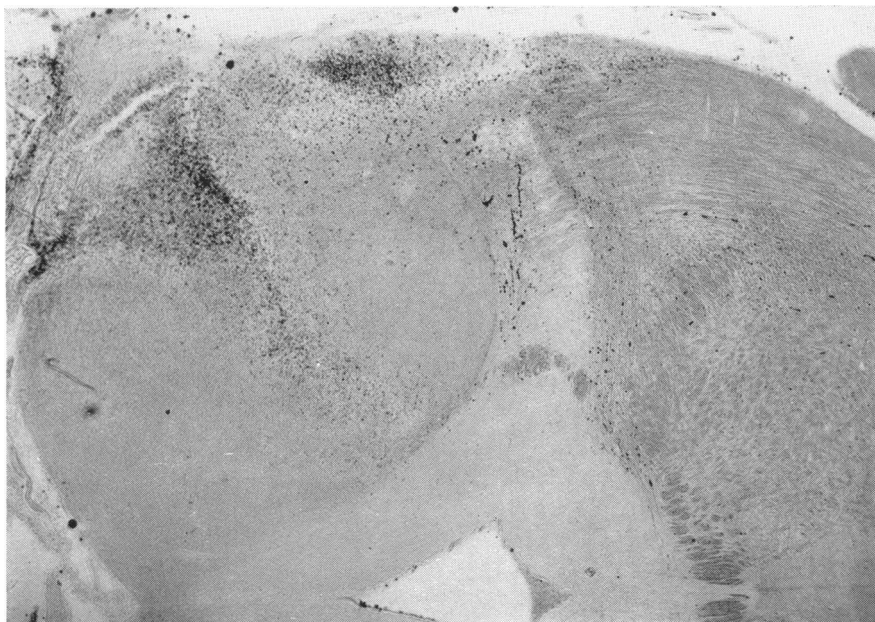


Fig. 2.

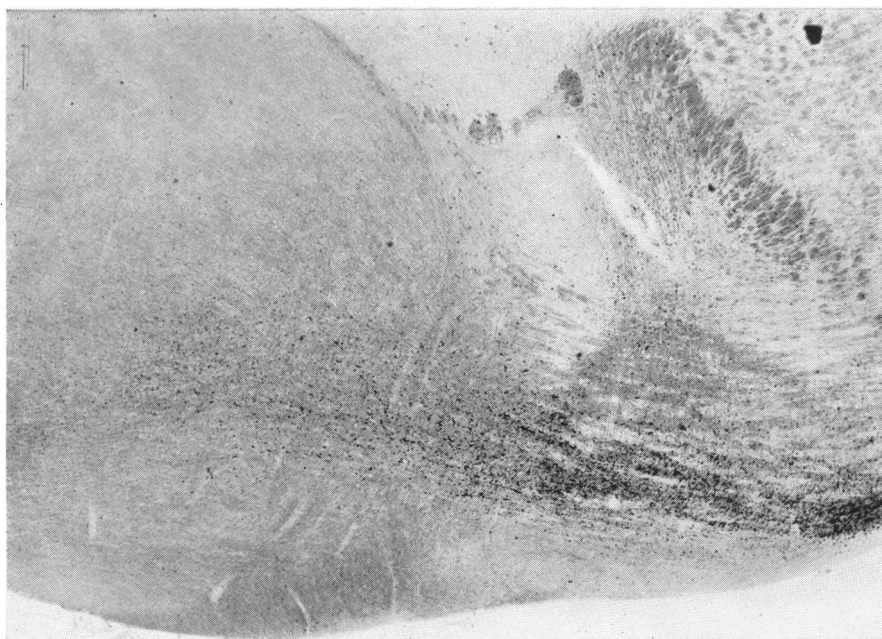

Fig. 1.