

Gross and Histopathological Findings in Unusual Lesions caused by *Streptococcus suis* in Pigs

II. Central Nervous System Lesions

S. Ernest Sanford*

ABSTRACT

Subacute meningoencephalitis or meningoencephalomyelitis caused by *Streptococcus suis* was diagnosed in 53 pigs over a four-year period. Affected pigs averaging 11 weeks of age with a range from five days to 26 weeks, had been treated with antibiotics and had partially recovered. Hyperemia of meningeal vessels and modest increase in cerebrospinal fluid were the most common gross central nervous system lesions. Histologically, fibrin, edema and a mixture of inflammatory cells were present in meninges and choroid plexus. Linear and perivascular infiltrates of neutrophils and mononuclear inflammatory cells invaded the brain and spinal cord and similar infiltrates were in lumina of ventricles and the spinal canal. Inflammatory cells also invaded the superficial layers of the brain directly from the overlying meninges. Bilateral subacute optic perineuritis and Gasserian ganglioneuritis also occurred. Segmental cortical necrosis of cerebellar folia characterized by degeneration, necrosis, neuronophagia and drop out of groups of Purkinje cells was a distinct lesion seen in 27 of the 53 pigs. Mild spongiosis of white matter in the cerebellum and brain stem accompanied these changes.

Key words: Pigs, *Streptococcus suis*, meningoencephalomyelitis, optic perineuritis, Gasserian ganglioneuritis, cerebellar cortical necrosis, neuronophagia.

RÉSUMÉ

Au cours d'une période de quatre ans, l'auteur a diagnostiqué une méningo-encéphalite ou une méningo-encéphalomyélite subaiguës, attribuables à *Streptococcus suis*, chez 53 porcs. Leur âge moyen était de 11 semaines, mais il variait de cinq jours à 26 semaines; on leur avait administré des antibiotiques et ils avaient partiellement guéri. Les lésions macroscopiques les plus fréquentes du système nerveux central se traduisaient par une hyperémie des vaisseaux des méninges et une légère augmentation du liquide céphalo-rachidien. L'histopathologie révéla la présence de fibrine, d'oedème et d'un exsudat cellulaire mixte, dans les méninges et les plexus choroïdes. Des infiltrats linéaires et périvasculaires de neutrophiles et de mononucléaires envahissaient le cerveau et la moelle épinière; les mêmes cellules se retrouvaient dans la lumière des ventricules et du canal épendymaire. Elles envahissaient aussi le cortex cérébral, directement de la pie-mère. Une périnévrte optique subaiguë et bilatérale, ainsi qu'une inflammation subaiguë du ganglion de Gasser, se produisirent aussi. Une nécrose segmentaire du cortex cérébelleux qui se caractérisait par de la dégénérescence, de la neuronophagie et la disparition de groupes de cellules de Purkinje, constituait une lésion distincte, chez 27 des 53 porcs. Une légère spongiose de la substance blanche du cervelet et du bulbe rachidien, accompagnait ces changements.

Mots clés: porcs, *Streptococcus suis*, méningo-encéphalomyélite, périnévrte optique, inflammation du ganglion de Gasser, nécrose du cortex cérébelleux, neuronophagie.

INTRODUCTION

Purulent meningitis in pigs and humans caused by *Streptococcus suis* type 2 has been reported from Europe for over two decades (1-6). Similar reports from North America (7-9), Hong Kong (10) and elsewhere (11,12) have been more recent and less frequent. Some 17 serotypes of *S. suis* now have been identified (12, Henrichsen J, personal communication), but *S. suis* type 2 still is the serotype most commonly isolated from pigs with meningitis.

This report describes several, previously unreported lesions seen in the central nervous system (CNS) of pigs submitted to the Huron Park Veterinary Diagnostic Laboratory (HPVDL) with CNS diseases caused by *S. suis* over the four-year period 1982-1985. Lesions associated with the heart are reported in an accompanying paper (14).

MATERIALS AND METHODS

Case records of all pigs from which *S. suis* was isolated from the CNS at the HPVDL between January 1982 and December 1985 were reviewed. Pertinent clinical data and necropsy findings were noted and formalinized tissues embedded in paraffin blocks were sectioned at 6 μ m, stained with hematoxylin and eosin and reexamined by light microscopy. Methods used at the HPVDL for identification of *S. suis* type 2 previously have been reported (7). In 1984 and 1985 slide coagglutination with serogroup 2 anti-serum linked to staphylococcal protein A was used to identify *S. suis* type 2. Serotypes other than type 2 were identified as *S. suis* and not typed further.

*Veterinary Laboratory Services, Ontario Ministry of Agriculture and Food, Huron Park, Ontario N0M 1Y0.

Submitted November 19, 1986.

RESULTS

Subacute meningoencephalitis or meningoencephalomyelitis was diagnosed in 53 pigs. The average age of affected animals was 11 weeks (range five days to 26 weeks). Affected pigs almost invariably had been treated with penicillin or a broad-spectrum antibiotic and had partially recovered from the initial acute disease, but continued to exhibit nervous dysfunction. On being touched or moved, older finishing pigs (18-24 weeks old) frequently emitted a piercing, shrill cry resembling the scream of a child. The *S. suis* cultured from 45 of the 53 brains was type 2.

Gross lesions were not distinctive. Hyperemia of meningeal vessels and modest increase in cerebrospinal fluid were the most common findings, and even these were inconsistent. Wisps of fibrin on the meninges and small amounts of fibrinopurulent exudate especially on the dorsal surface of the cerebellum, ventral medulla and pons, or on the floor of the cranial vault were found occasionally.

Histological lesions were subacute and chronic leptomeningitis, encephalomyelitis, and multifocal and segmental cortical necrosis of cerebellar folia. Leptomeningitis was diffuse but most marked over the cerebellum and was characterized by a fibrinous exudate and infiltrations of a mixture of inflammatory cells. In some pigs the infiltrate was primarily of neutrophils while in others the infiltrate contained mostly mononuclear cells (Fig. 1). Similar infiltrates were seen in the choroid plexus and spinal meninges. Ependymitis and ependymal perforation with influx of inflammatory cells into the ventricles and spinal canal also occurred.

Encephalitis was characterized by linear infiltrates of neutrophils and/or mononuclear inflammatory cells, usually intra- and perivascularly, as extension into the cortex from the overlying meninges (Fig. 2). Infiltrates most commonly were located in the cerebral hemispheres and especially the cerebellum. Necrosis of vessel walls was associated with these cellular aggregates. Vessel endothelia were swollen and sometimes lumina were occluded (Fig. 2). Mild gliosis and occasionally microabscesses were seen in the adjacent neuropil. Inflammatory cells also

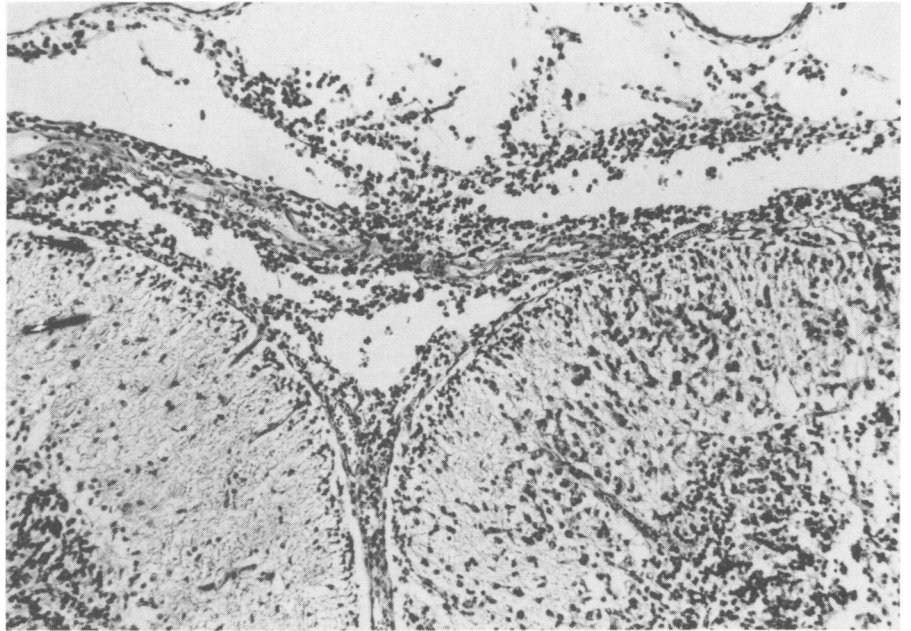


Fig. 1. Fibrinocellular leptomeningitis caused by *S. suis* in the cerebellum of a pig. In the right folium the inflammatory cells appear to have invaded directly and are destroying the molecular layer. H & E. X100.

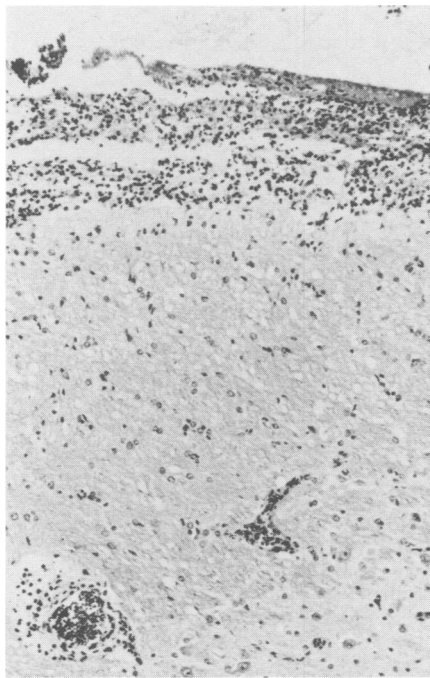


Fig. 2. Intra- and perivascular inflammatory cell infiltrates in cerebral cortex of a pig with *S. suis* subacute meningoencephalomyelitis. Vessel lumina are occluded. H & E. X100.

invaded the superficial layers of the brain directly from the overlying meninges (Figs. 1 and 3). This, again, was more common in cerebellar folia than in the cerebral cortex. Similar changes were in white and grey matters of spinal cord sections examined. Inflammatory cell exudates into the

spinal canal occasionally occurred. Bilateral subacute purulent optic perineuritis was present in the eyes of six of 14 pigs checked. Gasserian ganglion neuritis characterized by a mixture of inflammatory cells crowding the periphery of the ganglion and infiltrating among the ganglionic neurons was present in 17 of 45 pigs checked.

Multifocal and segmental necrosis of cerebellar folia was a distinct lesion that accompanied influxes of neutrophils and mononuclear cells into the molecular and granular layers, and was seen in 27 of 53 pigs with encephalitis. Granular cells were sometimes reduced in number. Purkinje cells were distorted and shrunken, nuclei were pyknotic and perikarya eosinophilic. Neuronophagia of Purkinje neurons was evident (Figs. 3 and 4). Groups of Purkinje cells frequently were absent and replaced by large vacuoles in the Purkinje cell layer of segments of, or an entire folium of the cerebellum (Fig. 4). Perineuronal vacuolation of degenerating Purkinje cells was common (Figs. 3 and 4). Adjacent, unaffected Purkinje cells were unaltered (Fig. 3). Mild spongiosis in cerebellar and medullary white matter accompanied the cerebellar cortical changes.

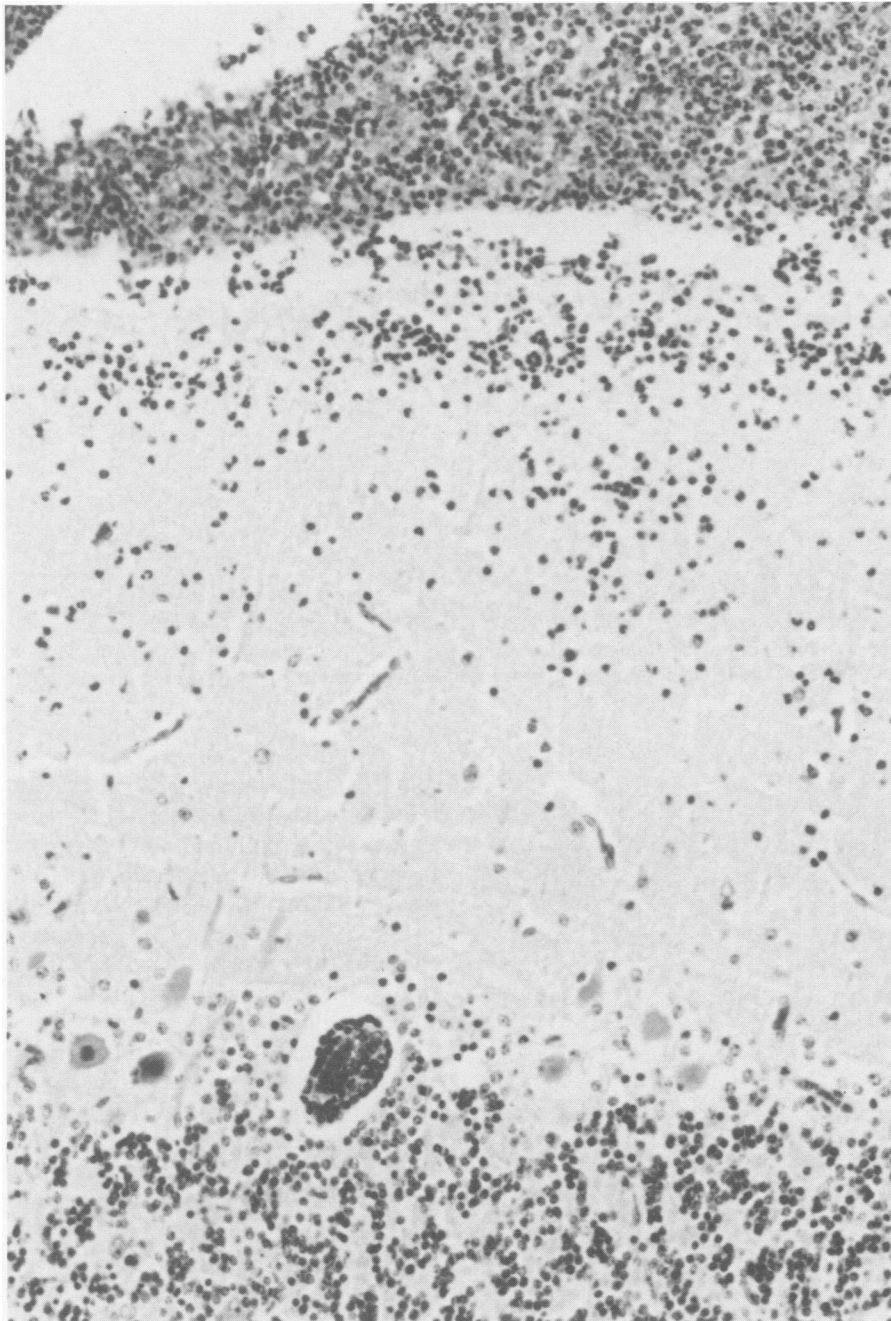


Fig. 3. Degenerate Purkinje neuron surrounded by large vacuole and undergoing neuronophagia in cerebellum. Adjacent Purkinje cells appear normal. Note the invasion of the molecular layer by a mixture of inflammatory cells from the overlying meninges. H & E. X200.

DISCUSSION

Subacute meningoencephalitis and meningoencephalomyelitis seem to have been almost totally ignored in previous reports on *S. suis* disease. The only reference to encephalitis in the literature seems to be that made by Schoon (15) who identified a mild CNS gliosis as an adjunct to fibrinopurulent leptomeningitis, the first of three types of leptomeningitis described by him. Pathogenetically, the enceph-

alomyelitis seems to be an extension from the meninges (i) via the blood vessels and, more dramatically, (ii) by direct invasion of inflammatory cells into the brain. The latter mechanism was most severe in cerebellar folia and led to necrosis of large segments of folia. A third mechanism, invasion of the CNS by breaching the ependymal lining in the ventricles and spinal canal also occurred, but less frequently.

Though not previously reported, bilateral Gasserian ganglioneuritis and

optic perineuritis were not unexpected. Gravitational flow would allow the exudate from the meninges to extend to and encompass the Gasserian ganglia located on the floor of the calvarium next to the brain. On the other hand, the optic perineuritis was a direct extension of the leptomeningitis along the meningeal covering of the optic nerve as it leaves the brain.

Segmental cortical necrosis of cerebellar folia has been recognized in the pig as a sequel to meningoencephalitis of various etiologies (16,17). Furthermore, Done previously has described similar cerebellar changes in a ten-week-old pig with chronic suppurative choroiditis, ependymitis and meningitis caused by a Lancefield group C streptococcus (17). However, cerebellar cortical necrosis, degeneration and dropout of Purkinje cells caused specifically by *S. suis* infection has not previously been reported. Occlusion of arteries supplying affected portions of cerebellar folia could produce regional hypoxia leading to hypoxic or ischemic degeneration of Purkinje cells and the associated cerebellar cortical changes. Build up of intracranial pressure resulting from suppurative meningeal exudates may be instrumental in producing stenosis or occlusion of arteries running close to the edge of the tentorium, such as the anterior cerebellar artery of the pig (17). Terminal branches of the arteries which supply the depths of the sulci are then especially vulnerable (17,18).

Increasing numbers of antibiotic treated pigs are submitted annually to the HPVDL with CNS signs and histopathological lesions identical to those described above for *S. suis* meningoencephalitis but from which no bacteria are isolated. Although viral cultures have all been negative it is nevertheless increasingly disconcerting since the histological lesions in these more chronic *S. suis* cases often are almost indistinguishable from those of viral encephalitis. Although Canada is free from many of the most feared of the viral encephalitis (e.g. pseudorabies, hog cholera, African swine fever), considerable effort is expended to rule out viruses when these lesions are seen. Serological titers are also negative in blood taken, before sacrifice, from pigs with these CNS lesions and titrated against the above-

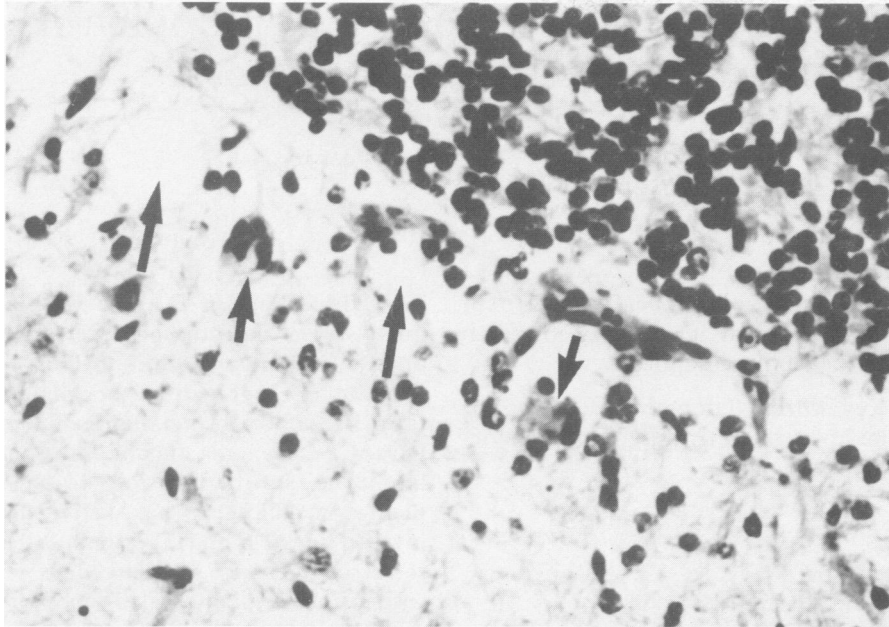


Fig. 4. Purkinje cells are absent and replaced by empty vacuoles (arrows) in Purkinje cell layer of cerebellum. Two degenerate Purkinje cells (arrowheads) are undergoing neuronophagia. H & E. X250.

mentioned exotic CNS viral encephalitic agents. Fortunately, most of these pigs are from previously identified *S. suis* endemic herds. Furthermore, the *S. suis* organism sometimes is isolated from the CNS of similarly affected litter- or penmates submitted at the same time. This, combined with the negative virus cultures clearly suggests that a much larger number of pigs examined at the HPVDL had the CNS lesions caused by *S. suis* than the 53 recorded in this study. Similar findings are likely at other diagnostic laboratories around the world. In places where the above-mentioned viral encephalitides are endemic the diagnostic dilemma would be greatly increased.

Antibiotic treatment may have been instrumental in promoting the more chronic encephalitic lesion described in this report. It is possible however that these encephalitic changes were chronic lesion in untreated pigs which survived the early septicemic phase of the disease. Some of the lesions (e.g. necrotizing vasculitis) are even suggestive of immune complex mediated inflammation. These more chronic CNS lesions caused by *S. suis* need to be investigated further.

ACKNOWLEDGMENTS

I gratefully acknowledge the assistance of S. Hoffman, B. Kierstead and S. Reid with data compilation, the technical and professional staff at the HPVDL for their contributions, and Dr. I. Wilkie with photomicrography.

REFERENCES

1. DE MOOR CE. Septicaemic infections in pigs, caused by haemolytic streptococci of new Lancefield groups designated R, S and T. *Antonie van Leeuwenhoek* 1963; 29:272-280.
2. WINDSOR RS. Meningitis in pigs caused by *Streptococcus suis* type II. *Vet Rec* 1977; 101:378-379.
3. WINDSOR RS, ELLIOTT SD. Streptococcal infection in young pigs. IV. An outbreak of streptococcal meningitis in weaned pigs. *J Hyg (Lond)* 1975; 75:69-78.
4. KUNTER E, WITTIG W. R- und S-streptokokken-infektionen beim schwein. *Arch Exp Veterinaarmed* 1976; 30:211-216.
5. PEDERSEN KB, SLOT P, SCHOU J. Udbrud af streptokokmeningitis i en dansk svinebesaetning. *Dansk Vet Tidsskr* 1977; 60: 812-813.
6. CLIFTON-HADLEY FA. *Streptococcus suis* type 2 infections. *Br Vet J* 1983; 139:1-5.
7. SANFORD SE, TILKER AME. *Streptococcus suis* type II — associated disease in swine: Observations of a one-year-study. *J Am Vet Med Assoc* 1982; 181:673-676.

8. ST JOHN VS, WILCOCK B, KIERSTEAD M. *Streptococcus suis* type 2 infection in swine in Ontario: A review of clinical and pathological presentations. *Can Vet J* 1982; 23:95-97.
9. ERICKSON ED, DOSTER AR, POKORNY TS. Isolation of *Streptococcus suis* from swine in Nebraska. *J Am Vet Med Assoc* 1984; 185:666-668.
10. CHAUPY, HUANG CY, KAYR. *Streptococcus suis* meningitis. An important underdiagnosed disease in Hong Kong. *Med J Aust* 1983; 1:414-417.
11. BUDDLE JR, JONES JET, PASS DA, ROBERTSON J. The isolation of *Streptococcus suis* type II from a pig with meningitis. *Aust Vet J* 1981; 57:437-438.
12. ROBERTSON ID. The isolation of *Streptococcus suis* type 1 and 2 from pigs in New Zealand. *NZ Vet J* 1985; 33: 148.
13. PERCH B, PEDERSEN KB, HENRICHSEN J. Serology of capsulated streptococci pathogenic for pigs. Six new serotypes of *Streptococcus suis*. *J Clin Microbiol* 1983; 17:993-996.
14. SANFORD SE. Clinical, gross and histopathological findings in unusual lesions caused by *Streptococcus suis* in pigs I. Cardiac lesions. *Can J Vet Res* 1987; 51:481-485.
15. SCHOONH-A. Clinical and pathomorphological aspects of streptococcal leptomeningitis in pigs. Commission of European Communities Report EUR8515 En 1983; 12-17.
16. JUBB KVF, KENNEDY PC, PALMER N. Pathology of domestic animals. 3rd ed. Vol 1. Toronto: Academic Press Inc., 1985.
17. DONEJT. Some cases of cerebellar cortical sclerosis in pigs. *Acta Neuropathol (Suppl 1)* 1962; 1:33-38.
18. LINDENBERG R. Compression of brain arteries as pathogenetic factor for tissue necrosis and their areas of predilection. *J Neuropathol Exp Neurol* 1955; 14:223-243.