

JOURNAL OF ANATOMY

THE DEVELOPMENT OF THE HYPOPHYSIS CEREBRI, PRE-ORAL GUT, AND RELATED STRUCTURES IN THE MARSUPIALIA.

By KATHARINE M. PARKER, B.Sc. (Lond.), *Assistant in the Department of Zoology, University of London, University College.*¹

INTRODUCTION.

THE following investigation of the development of the hypophysis cerebri in Marsupials was undertaken at the suggestion of Professor J. P. Hill, and I wish to express my gratitude to him for help and advice without which the work would have been impossible.

The literature of the pituitary is already vast, and for close on a century its origin has been the subject of much scientific discussion, but relatively little work has been done on the later stages of its development. The rich supply of embryological material in Professor Hill's collection makes it possible to add some facts to those already recorded by other authors, whilst the interesting conditions revealed in some of the Marsupials afford a further reason for adding this contribution to the existing literature.

The pre-oral gut (Seessel's pocket) in some Marsupials actually becomes part of the so-called anterior lobe of the pituitary, hence it becomes necessary to include as full an account as possible of that structure. Furthermore, the relations of the anterior end of the notochord to Seessel's pocket are, in some species, so close as to merit description in the same connection; whilst in intimate relation to the anterior end of the chorda there is, in some Marsupials, a mass of cells giving rise to a pair of head cavities. In fact, study of the region of the head shows that the notochord, head cavities, pre-oral gut, and the hypophysis are so closely related that to omit any one of these structures is to render the description inadequate. It is doubtless impossible at present to arrive at a correct estimation of the phylogenetic importance of the facts, and further study on the subject, more especially in the

¹ Thesis approved for the Degree of Doctor of Science in the University of London.

lower Vertebrates, is very desirable. The difficulty of the problem is evident from the number of different structures of unknown significance which are said to be derived from either the roof of the fore-gut or the head of the notochord—*e.g.* the “præchordal Platte” described by Oppel (40) in *Anguis fragilis*; the “Gaumentasche” of Selenka (55) in *Didelphys*; the pharyngeal bursa, first described by Mayer (31) in 1840, whose possible identity with Seessel’s pocket has since been discussed. From an investigation based on one sub-class of the Vertebrates it is obviously impossible to deduce theories of general applicability, but, at the least, some facts may be added which will in the future help in the solution of the interesting problem of the phylogeny of the Vertebrate head.

The descriptive portion of the paper is divided into two sections: the first dealing with early stages in which the relations of the notochord, fore-gut, oral plate, and hypophysis can be studied; the second, with the process of conversion of the simple evagination of the oral ectoderm into the glandular portion of the adult hypophysis. I have referred only briefly to some phases through which the infundibular process passes, and have deliberately omitted any description of the development of the portion of the diencephalic floor lying in proximity to the pituitary body. During preservation the brain is very apt to become abnormally folded, and the infundibular process is undoubtedly distorted in several of the embryos which have come under my observation. On the other hand, it is difficult to give a satisfactory description of this region of the brain from study of transverse series without making reconstructions. As I hope in the future to work out the development of the fore-brain in Marsupials, which will involve making models of several stages, I propose to deal with the diencephalic floor in a later paper, and it is probable that some further facts may then be added to the present description of the development of the infundibular process itself.

I wish to thank Mr F. C. Pittock, of University College, for much help, both in the making of a model and in various other ways.

DESCRIPTION OF STAGES.

SECTION I.—*Early Development of the Chorda, Fore-gut, Premandibular Somites, and Hypophysis.*

Before passing on to stages immediately prior to the formation of the hypophysis, it will be well to briefly review the relations of chorda and fore-gut which are brought about on formation of the head-fold.

From the very complete series of early stages of *Perameles* in Professor Hill’s collection, it is possible to work out the early history of the fore-gut

and chorda in considerable detail. It is not within the scope of the present paper to deal with this subject except in so far as it sheds light on the early relations of the oral plate, gut, and notochord. *Perameles* possesses a very well-marked protochordal plate (*cf.* figs. 69 and 71 in Wilson and Hill's "Observations on the Development of *Ornithorhynchus*" (63)), which, like the chorda itself in early stages, is continuous laterally with the entoderm of the gut. When the head-fold forms, this protochordal plate is involved therein and forms the wall of the anterior extremity of the fore-gut. During this period the entoderm closes in below the notochord, which accordingly becomes detached as a solid rod of cells. The protochordal plate, on the other hand, retains its original relations to the entoderm on either side of it, and continues to form the actual wall of the anterior angle of the fore-gut. Its originally anterior portion, which on formation of the head-fold becomes ventral, constitutes the entodermal layer of the oral plate.

STAGE I. *Perameles nasuta* (2 P.).—Fig. 1 represents a median longitudinal section through an embryo of *Perameles nasuta* (2 P.), the drawing being made by reconstruction from several sections near the middle line. The brain, which is as yet open except in the region posterior to the auditory neuromere, is flexed at two points, representing the diemesen (D.-M.) and the mesen-metencephalic (M.-Mt.) limits. Posterior to the projecting anterior border of the medullary plate is a rounded depression, the primitive infundibular recess (I.).

The gut has attained a considerable size in the dorsi-ventral direction. Its anterior wall is in intimate contact with the brain, while the anterior portion of its ventral wall forms, with the ectoderm, the oral plate (O.P.). These two portions of the gut wall, which are derived from the protochordal plate, consist of cells which are rich in protoplasm and contain a number of darkly staining granules (Pt.P.). This appearance is characteristic of the protochordal plate of earlier stages. The dorsal wall of the fore-gut consists of cubical or columnar cells with little protoplasm. Posterior to the region shown in the figure, the gut wall consists of much-flattened entoderm cells.

The notochord in the trunk region is small and typical, but becomes slightly thickened in the region of the myelencephalon (Ch.), whilst immediately posterior to the second point of flexure of the brain it passes into a dense mass of cells (P.P.) extending forwards and tapering in front of the anterior flexure to a fine point. This tapering extremity is so intimately connected with the wall of the fore-gut that the two structures are here indistinguishable, and their point of fusion represents in this stage the posterior limit of the protochordal plate.

In transverse section (fig. 2) it is seen that this mass of cells (P.P.) is narrow from side to side, while from its anterior extremity there arise a small pair of solid outgrowths (Pm.S.). (*N.B.*—Only one of these is shown completely in the figure, as the sectional plane is slightly oblique.)

In a prior stage of *Perameles*, represented by a flat embryo, the slender notochord is directly continuous at its anterior end with the protochordal

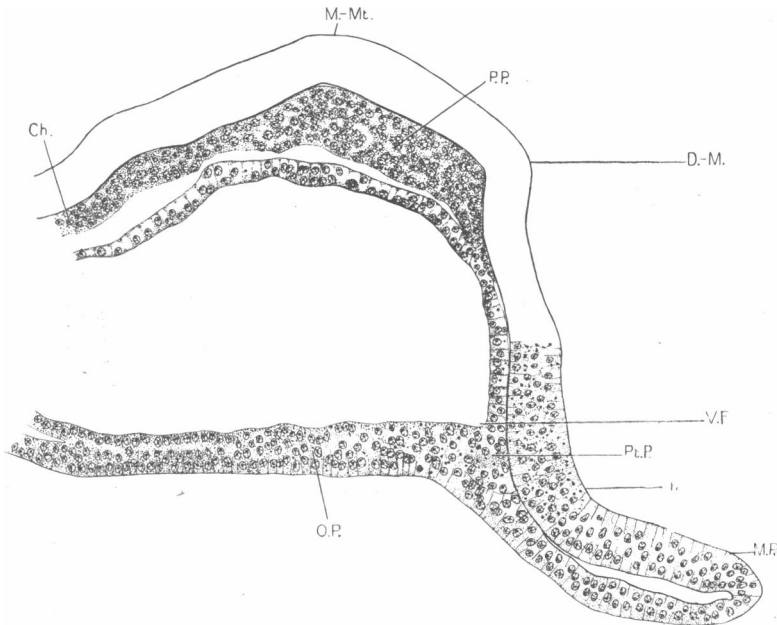


FIG. 1.—Stage I. *Perameles nasuta* (2 P.). Median longitudinal section (reconstructed).

Ch., chorda; D.-M., dien-mesencephalic limit; I., primitive infundibular recess; M.-Mt., mesen-metencephalic limit; M.P., medullary plate; O.P., oral plate; P.P., prechordal plate; Pt.P., protochordal plate; V.F., ventral angle of fore-gut.

plate, and no such mass of cells is present. From its position and relations it is clear that it represents that mass of tissue connecting the gut and notochord which has been described by Oppel (40), Platt (43), and others, in lower Vertebrates; and this lends support to the view that the small outgrowths represent the first trace of the premandibular somites. As we shall see, these structures are clearly present in embryos of *Bettongia gaimardi* and *Macropus ruficollis* of a slightly later stage. Moreover, though it is impossible to trace their history continuously, we find undoubted premandibular head-cavities in the next stage of *Perameles*, the

subsequent history of which has already been described by Elizabeth A. Fraser (12) in Professor Hill's material.

We may therefore conclude that the mass of cells at the anterior end of the chorda represents the "præchordal Platte" of Oppel, and that its lateral outgrowths are the rudiments of premandibular head cavities. I shall accordingly refer to the cell mass in question as the prechordal plate.

There is no differentiation of hypophysial epithelium at this stage.

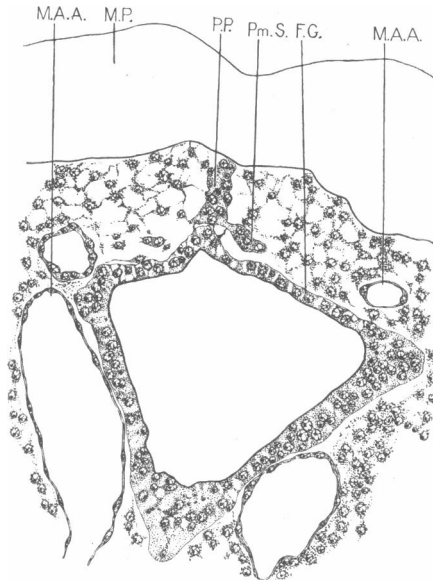


FIG. 2.—Stage I. *Perameles nasuta* (2 P.). Transverse section through prechordal plate and rudimentary premandibular somites. Sl. 1-3-4.

F.G., fore-gut; M.A.A., 1st (mandibular) aortic arch; M.P., medullary plate; P.P., prechordal plate; Pm.S., premandibular somite.

STAGE II. *Bettongia gaimardi*.—This embryo is at a slightly later stage than that of *Perameles nasuta* (2 P.), Stage I., described above, but in the relations of the brain, gut and notochord there is very close agreement between the two embryos.

The brain is flexed at two points, the hind-brain is closed, while the mid- and fore-brains are still widely open.

The anterior wall of the fore-gut lies against the floor of the fore-brain and forms a well-marked angle with the roof. It is somewhat thickened, and is presumably derived from a protochordal plate as in *Perameles*.

At the anterior end of the notochord is a thickened mass of cells which is bent over so that its anterior extremity lies between the floor of the fore-

brain and the anterior wall of the fore-gut, while the apex of the bend lies above the antero-dorsal angle of the gut. This mass of cells represents the prechordal plate of *Perameles*, but is less well-marked, and, although its anterior extremity is in close contact with the wall of the fore-gut, there does not appear to be actual continuity between the two structures at this stage.

On each side of the embryo, lying posterior to the well-developed optic

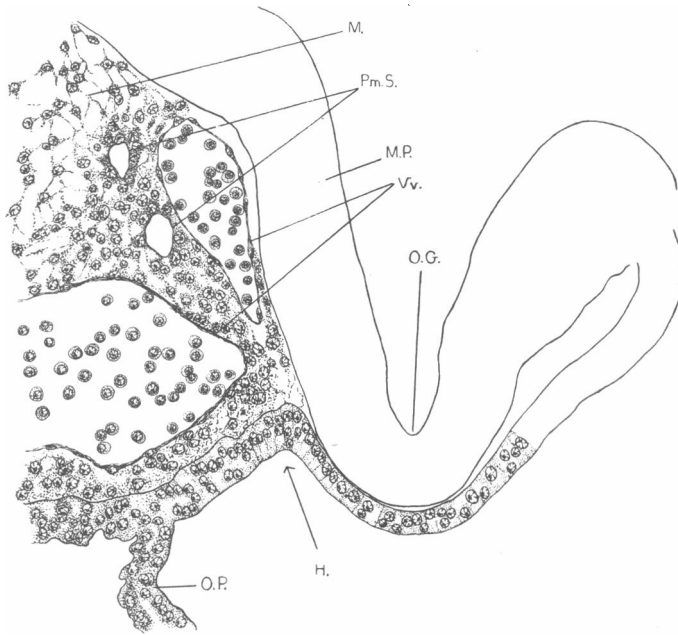


FIG. 3.—Stage II. *Bettongia gaimardi*. Longitudinal section passing through the optic groove and premandibular somites. Sl. 2-2-2.

H., hypophysial angle; M., mesenchyme; M.P., medullary plate; O.G., optic groove; O.P., oral plate; Pm.S., premandibular somite; Vv., blood-vessels.

groove (fig. 3, O.G.), there is a mesodermal mass which can readily be distinguished by its relative density from the loose mesenchyme of the head (fig. 3, Pm.S.). Furthermore, each of these mesodermal masses contains several small but perfectly distinct cavities, two of which are shown in fig. 3, round which the cells are arranged in a radiating manner, forming an irregular epithelial wall. These cavities are not symmetrical on the two sides of the embryo. Owing to the fact that the head of the embryo is cut longitudinally, it is very difficult to determine the exact lateral and median limits of these structures, but after careful study of the series, I

have been able to make out that a fine strand of cells connects each mass with the anterior end of the prechordal plate. From the position and relations of these structures it is evident that they represent premandibular somites. The fact that more than one cavity is present in each mesodermal mass does not appear to indicate the presence of more than one pair of somites, for the cavities are irregularly arranged and are not symmetrical on the two sides of the embryo.

The hypophysial angle (H.) is recognisable, but there is no differentiation of the ectoderm in this region.

STAGE III. *Macropus ruficollis*.—This embryo shows a distinct advance on the *Bettongia* embryo described above. The brain is sharply flexed at the mesen-metencephalic junction, the hind-brain is closed, the mid-brain widely open, whilst in the fore-brain the medullary folds are closely opposed but not yet fused.

The fore-gut, in correlation with the flexure of the brain, has a well-marked antero-dorsal angle. Its anterior wall is not thickened as is the case in *Perameles* and *Bettongia*. The notochord is discontinuous in the region of the hind-brain. At its anterior end, which still persists, there is a slight enlargement, bent at an acute angle and lying between the antero-dorsal angle of the fore-gut and the floor of the mesencephalon at the point of flexure. This structure, the reduced remnant of a prechordal plate, is not in actual continuity with the wall of the fore-gut.

On each side of the fore-brain, postero-lateral to the optic vesicles, there is a group of mesoderm cells,¹ similar to those described in the same situation in *Bettongia gaimardi* (fig. 4, Pm.S.).

Each cell group is distinguishable from the surrounding mesenchyme by its relative density, and contains several small cavities around which the cells are arranged in the form of a fairly definite epithelium (Ep.H.C.). The two masses are connected across in the middle line by a transverse "bridge" (B.) consisting of a fine, solid strand of cells which runs across immediately anterior to the tip of the notochord.

The sectional plane of this series is transverse to the notochord, and the existence of the bridge is accordingly perfectly clear. On the other hand, it is very difficult to determine whether or no the tip of the prechordal plate is in contact with the bridge connecting the somitic masses. As, however, the section showing the connecting piece is next to that in which the tip of the notochord is seen, it is clear that they are at least in very close proximity to each other.

The mesodermal masses of this embryo bear to the notochord and gut

¹ My attention was first drawn to the presence of these structures in this embryo by Professor Hill.

the relations which characterise premandibular head cavities, which we may accordingly assume them to be.

The ectoderm of the head is unmodified at the base of the oral plate, *i.e.* there is as yet no differentiation of the hypophysial epithelium.

Trichosurus vulpecula.—This stage is represented in the *Trichosurus* series by two embryos, one cut longitudinally, the other transversely. These embryos show a very close resemblance to that of *Perameles nasuta* (2 P.), Stage I., in the relations of gut, brain, and notochord, but in several respects they belong more properly to the same stage as the *Macropus* embryo described above. As they show nothing new, it is not necessary to give a separate description of them, but it may be noted that structures

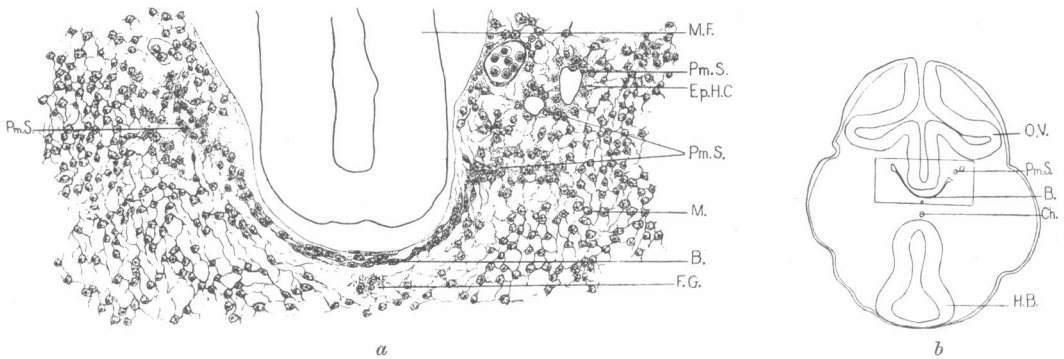


FIG. 4.—Stage III. *Macropus ruficollis*. (a) Transverse section through premandibular somites; (b) outline diagram of whole section of which (a) is a part. Sl. 1-4-5.

B., bridge connecting premandibular somites; Ch., chorda; Ep.H.C., epithelium of head cavity; F.G., wall of fore-gut; H.B., hind-brain; M., mesenchyme; M.F., medullary fold; Pm.S., premandibular somite; O.V., optic vesicle.

similar to the undoubted head cavities of *Macropus ruficollis* are present in one of the embryos of *Trichosurus* at this stage of development.

STAGE IV. *Perameles nasuta* (13, VII. 05).—This embryo shows a distinct advance on the preceding, the brain being completely closed and Rathke's pouch already differentiated. It is cut in horizontal sections, and, as the relations of the parts are particularly interesting, a wax plate-reconstruction was made of the fore-brain, hypophysis, chorda, etc. (see fig. 5). Detailed observations are, moreover, made possible by the remarkably perfect preservation of the embryo.

The floor of the diencephalon shows a rounded depression, the primitive infundibular recess (I.), anterior to which is a slight ridge, indicating the future position of the optic chiasma. The hypophysial primordium—Rathke's pouch (R.P.)—is now present as a thickened stretch of ectoderm,

closely applied to the infundibular depression. The pouch is very shallow anteriorly and deepens somewhat behind, where its lateral angles are fairly well marked. Its posterior wall forms the anterior wall of the fore-gut, and constitutes the ectoderm of the dorsal portion of the oral plate (O.P.), which is still complete. In its dorsal portion, the oral plate is bent at a fairly sharp angle, the apex of this angle forming in section a "plug" (P.) which

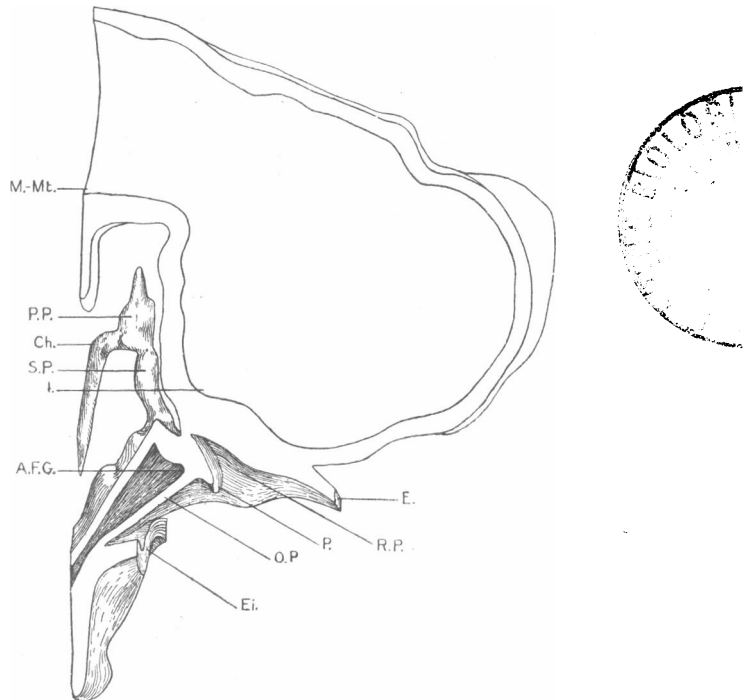


FIG. 5.—Stage IV. *Perameles nasuta* (13, VII. 05). Longitudinal section through model of fore-brain, hypophysis, Seessel's pocket, and notochord, slightly to the right side of the middle line.

A.F.G., anterior angle of fore-gut; Ch., chorda; E., ectoderm of head; Ei., ectoderm of mandibular arch; I., infundibular recess; M.-Mt., Mesen-metencephalic limit; O.P., oral plate; P., "plug" formed by projection of oral plate into Rathke's pouch; P.P., prechordal plate; R.P., Rathke's pouch; S.P., Seessel's pocket.

projects into Rathke's pouch, and will be seen in similar stages in other species (*cf.* fig. 31, O.P.), whilst the rest of the oral plate is thin.

The dorsal wall of the fore-gut is thickened immediately behind Rathke's pouch, and from it there arises a small median outgrowth (S.P.), slightly dilated at its extremity and running backwards parallel with the di-cephalic floor to meet the somewhat irregular prechordal plate (P.P.). This latter preserves its original form, being narrow from side to side and

of relatively considerable dorso-ventral extent. The prechordal plate is continuous at its caudal extremity with the notochord (Ch.), which is here small and typical, and, following the flexure of the brain, is bent at approximately a right angle at the mesen-metencephalic junction (M.-Mt.).

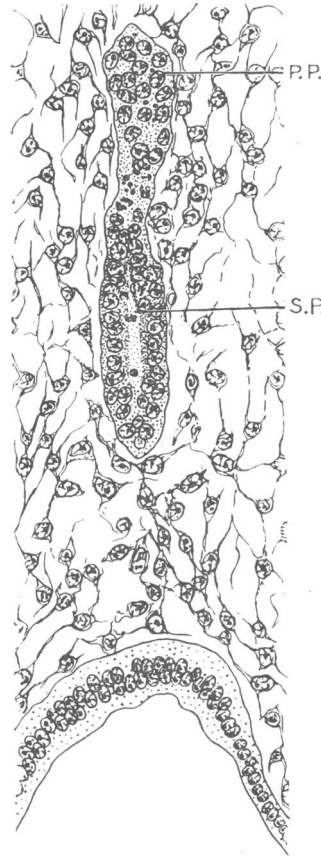


FIG. 6.—Stage IV. *Perameles nasuta* (13, VII. 05).
Section through prechordal plate and Seessel's
pocket. Sl. 3-3-11.

P.P., prechordal plate; S.P., Seessel's pocket.

The small outgrowth (S.P.), arising as it does immediately behind the oral plate, represents the remnant of the pre-oral gut usually known as Seessel's pocket. It will be noticed that its distal extremity is continuous with the prechordal plate, and we may therefore conclude that it has arisen from that part of the fore-gut of the early stage of *Perameles* which

is situated at the junction of the prechordal plate with the entoderm of the gut wall.

The minute structure of the organs in this region is also worthy of note. The thickened wall of the fore-gut immediately behind Rathke's pouch shows all the features characteristic of the protochordal plate of earlier stages, the granulation of the cells being recognisable here, and to a less extent in the portion of oral plate adjacent to it. We may therefore conclude that here, as in the previous stage, the antero-ventral wall of the fore-gut is formed by the protochordal plate. Seessel's pocket, arising from the dorsal side of this portion of the gut (fig. 6, S.P.), has no actual lumen

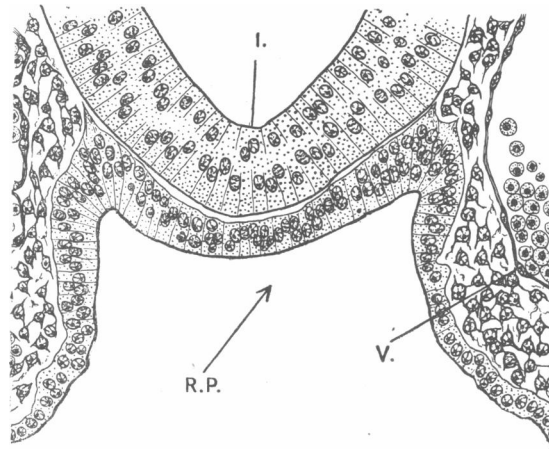


FIG. 7.—Stage IV. *Perameles nasuta* (13, VII. 05). Transverse section through primitive infundibular recess and Rathke's pouch.

I., primitive infundibular recess; R.P., Rathke's pouch; V., blood-vessel.

but is obviously tubular in structure, its walls consisting of a very regular epithelium. It is impossible to define exactly the limit between the wall of Seessel's pocket and the prechordal plate (P.P.), which consists of a rather irregular mass of cells, containing darkly staining granules. From its margin, cells here and there project, giving it an irregular outline, in which respect it contrasts with the notochord proper, whose outline is perfectly definite. Some of these cells appear to represent traces of the former connection between the prechordal plate and the premandibular somites, which have now acquired a considerable size and possess a distinct cavity. In this stage they have already been described and figured by Fraser (12).

The walls of Rathke's pouch (fig. 7, R.P.) consist of a regular columnar epithelium which is thin in the middle line and thickens somewhat at the

lateral angles, where the cells are closely packed and show evidence of rapid growth. Thus there is a tendency for the cells in these two regions to project on the outer side of the wall, giving almost an appearance of proliferation (fig. 7), a condition which is doubtless due to the rapid multiplication of the cells.

Dasyurus viverrinus.—As *Dasyurus* differs in some important respects from the types described above, and as, moreover, a complete series of stages showing the early development of Rathke's pouch is available, it will be best to describe the stages of *Dasyurus* consecutively as a series, distinct from *Perameles*, *Bettongia*, and *Macropus*.

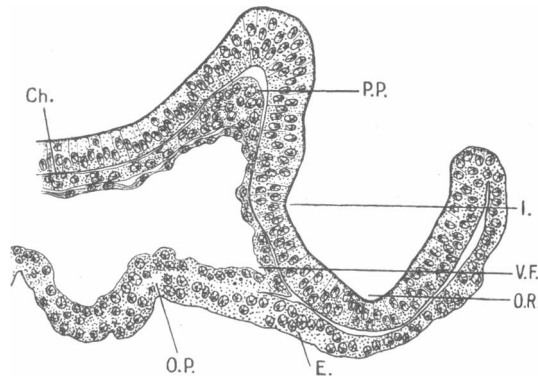


FIG. 8.—Stage I. *Dasyurus viverrinus* (I., A. 02). Median longitudinal section through the anterior end of the brain, chorda, and fore-gut (reconstructed). Sl. IV. 1-14 to 2-1.

Ch., chorda; E., ectoderm; I., primitive infundibular recess; O.P., oral plate; O.R., optic recess; P.P., prechordal plate; V.F., ventral angle of fore-gut.

STAGE I. (I., A. 02).—This stage corresponds approximately with Stage I. of *Perameles*.

The relations of brain, gut, chorda, and oral plate are best seen in median longitudinal section (fig. 8). The brain is flexed at one point, while the hind-brain only is closed. The anterior end of the medullary plate curves upwards, and two depressions in the floor of the fore-brain can be identified. Of these, the anterior is the optic (O.R.), the posterior the infundibular recess (I.). The chorda (Ch.) extends to shortly behind the point of flexure of the brain. Throughout the greater part of its length it consists of a thin strand of cells, but at its anterior end, which lies in the angle formed by the cranial flexure, there is a marked thickening, the prechordal plate (P.P.) bent at an acute angle and reaching its greatest thickness opposite the flexure of the brain floor. The tapering extremity of the prechordal plate, as in *Perameles*, is directly continuous

with the gut-wall. The antero-dorsal angle of the gut is thin-walled while its antero-ventral angle has relatively thick walls, consisting of somewhat irregular, elongated cells. Here again the whole of the anterior wall of the fore-gut as well as the anterior part of the entoderm of the oral plate is to be regarded as derived, as in *Perameles*, from a protochordal plate. The latter, however, is not nearly so clearly differentiated in *Dasyurus* as it is in *Perameles*.

No traces of premandibular somites are recognisable.

The ectoderm of the hypophysial angle (E.) consists of columnar epithelium, and as yet shows no sign of differentiation.

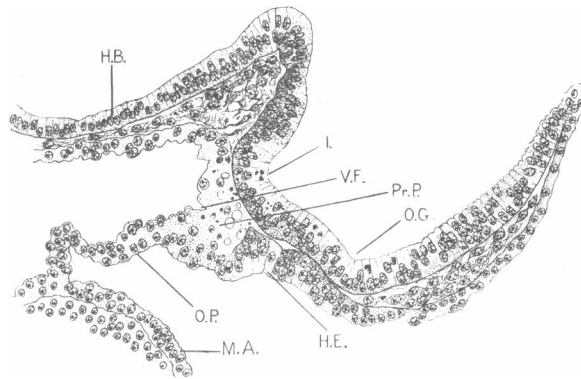


FIG. 9.—Stage II. *Dasyurus viverrinus* (1, 01). Median longitudinal section through anterior end of brain and fore-gut. Sl. 3-3-2.

H.B., hind-brain; H.E., hypophysial epithelium; I., primitive infundibular recess; M.A., mandibular arch; O.G., optic groove; O.P., oral plate; Pr.P., protochordal plate; V.F., ventral angle of fore-gut.

STAGE II. *Dasyurus viverrinus* (1, 01).—In general features this stage resembles the preceding so closely that no detailed description will be necessary.

The brain in median longitudinal section (fig. 9) presents much the same features as in Stage I., but the infundibular depression (I.) and the optic recess (O.G.) are both more clearly defined. The prechordal plate is no longer recognisable as a distinct structure. The wall of the antero-ventral angle of the fore-gut (protochordal plate, fig. 9, Pr.P.) is now distinctly thickened and has a very characteristic appearance. The cells are regularly arranged, contain a number of darkly staining granules, and are vacuolated.

The first trace of the primordium of the hypophysis is now recognisable. Immediately anterior to the oral plate, the ectoderm consists of distinctly elongated epithelial cells (H.E.) The thickening extends forwards as far

as the optic recess, and is most marked at the point of contact of the ectoderm with the entoderm of the pre-oral gut. Posterior to this point the modified ectoderm of the hypophysis thins out slightly and is directly continuous with the oral plate (O.P.), in which the ectoderm and entoderm are now indistinguishable.

In transverse section we can see the primordium of the hypophysis as a thickened and slightly invaginated stretch of ectoderm, in intimate contact with the floor of the brain.

STAGE III. *Dasyurus viverrinus* (II., a, 01): Embryos a, b, and c.—

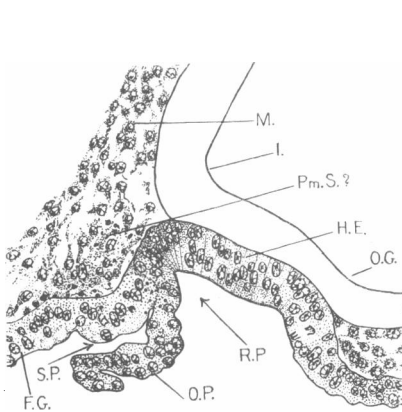


FIG. 10.—Stage III. *Dasyurus viverrinus* (II., a, 01). Embryo a. Median longitudinal section through the hypophysis and Seessel's pocket. Sl. 2-3-7.

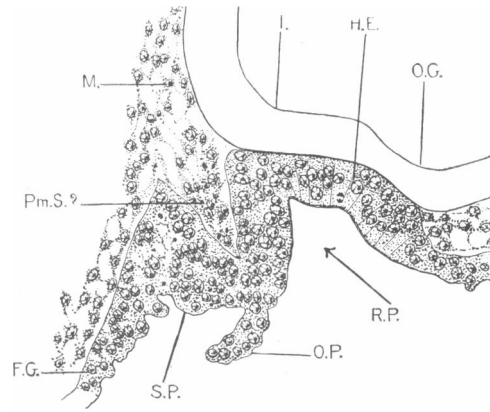


FIG. 11.—Stage III. *Dasyurus viverrinus* (II., a, 01). Embryo c. Median longitudinal section through the hypophysis and Seessel's pocket. Sl. 2-1-11.

F.G., fore-gut; H.E., hypophysial epithelium; I., primitive infundibular recess; M., mesenchyme; O.G., optic groove; O.P., oral plate; Pm.S.(?), possible trace of premandibular somite; R.P., Rathke's pouch; S.P., Seessel's pocket.

The embryos of this stage are only slightly more advanced than those of the preceding. The optic groove (fig. 10, O.G.) and the infundibular recess (I.) are slightly more clearly marked. The hypophysis has distinctly deepened and the oral plate has ruptured. The relations to the pre-oral gut in individual embryos of the stage vary slightly (*cf.* figs. 10 and 11).

In two embryos (*a* and *b*, fig. 10), which are cut longitudinally, the hypophysis is separated from the anterior angle of the gut simply by the thickness of the oral plate, which is ruptured ventrally (O.P.). The wall of the hypophysis consists of columnar epithelial cells, very regularly arranged. The pouch (R.P.) shows an obtuse anterior angle and an acute posterior angle, and the latter has progressed back so as to lie beneath the deepest part of the infundibular recess. The regular columnar

epithelium extends over the apex of the posterior angle of the pouch and passes into continuity with the thickened wall of the anterior angle of the fore-gut, as well as with the persisting upper part of the oral plate. Seessel's pocket is represented simply by the thick-walled anterior angle of the fore-gut, and is separated from Rathke's pouch merely by the persisting upper part of the oral plate.

In a third embryo (*c*, fig. 11), cut longitudinally, Rathke's pouch is somewhat larger. Moreover, instead of the posterior wall of the hypophysis being in direct contact with the anterior wall of the fore-gut, a certain amount of mesenchyme is present immediately behind Rathke's pouch. Seessel's pocket accordingly forms a small conical diverticulum whose wall is separated from that of Rathke's pouch by mesoderm. The remnant of oral plate (O.P.) is attached to the ventral border of the fold between Seessel's pocket and the hypophysis.

This condition resembles the typical arrangement in many Eutheria and birds, in both of which groups the pre-oral gut forms a short diverticulum separated from the hypophysis by a solid fold containing a mesodermal core.

In all the embryos of this stage there is on either side of the middle line, immediately posterior to the hypophysis, a group of cells lying dorsal to the gut-wall. In the first of the types described above, these cells lie posterior to the apex of the anterior angle of the fore-gut (fig. 10, Pm.S. ?); in the second, they lie between the hypophysis and Seessel's pocket (fig. 11, Pm.S. ?). This cell mass can be distinguished from the surrounding mesoderm by its density and by the presence of a number of darkly staining granules. It seems possible that it represents a pair of somites, presumably premandibular, but apart from it no trace of head cavities has been found in *Dasyurus*.

STAGE IV. *Dasyurus viverrinus* (β).—In this stage the floor of the infundibulum is marked by a distinct angle, but no definite infundibular process has appeared.

The hypophysis now forms a distinct pouch, with a small remnant of the oral plate attached to its posterior wall in some embryos. In one embryo only of this stage is there still a considerable remnant of Seessel's pocket; in the others, a very slight diverticulum (fig. 12, S.P.) marks the position of the pre-oral gut; but in every case the posterior wall of the hypophysis, though continuous with, is perfectly distinct from, the anterior wall of Seessel's pocket.

It is evident from the foregoing that in *Dasyurus*, Seessel's pocket is a variable and transient structure, for it is hardly recognisable in some embryos, and in no case does it play any part in later development.

It has not been possible to recognise in this stage the group of cells described in the preceding stage and interpreted as possibly somitic.

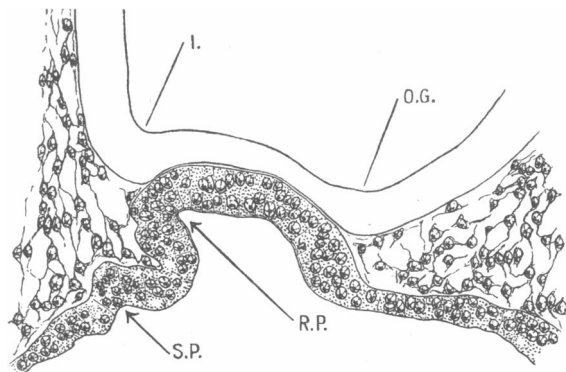


FIG. 12.—Stage IV. *Dasyurus viverrinus* (β). Median longitudinal section through hypophysis. Sl. 2-6-11.

I., primitive infundibular recess; O.G., optic groove; R.P., Rathke's pouch; S.P., Seessel's pocket.

SECTION II.—*The Later Development of the Hypophysis cerebri and the Pre-oral Gut.*

This section deals with the development of the hypophysis subsequent to the establishment of Rathke's pouch, *i.e.* with the origin and development of the infundibular process and the conversion of the simple buccal invagination into the so-called anterior lobe and pars intermedia of the adult.

With regard to the nomenclature of the parts of the adult hypophysis, it has already been pointed out by Tilney (58) and others that the terms "anterior" and "posterior lobes" and "pars intermedia" are open to serious criticism. They are applicable to the human subject, but not to all Vertebrates, inasmuch as the infundibular process is frequently dorsal to the rest of the pituitary and in some species is actually anterior thereto. Moreover, these terms are based exclusively on topography, and indicate neither the function nor the origin of the parts, for the "pars intermedia" is only intermediate in position and not in any other sense. Furthermore, there is good reason to suppose that the tissue of the non-nervous portion of the hypophysis which is in contact with the nervous portion consists of two parts. As these two regions have been clearly recognised, as far as I am aware, only by Tilney (59), the simplest method is to adopt the

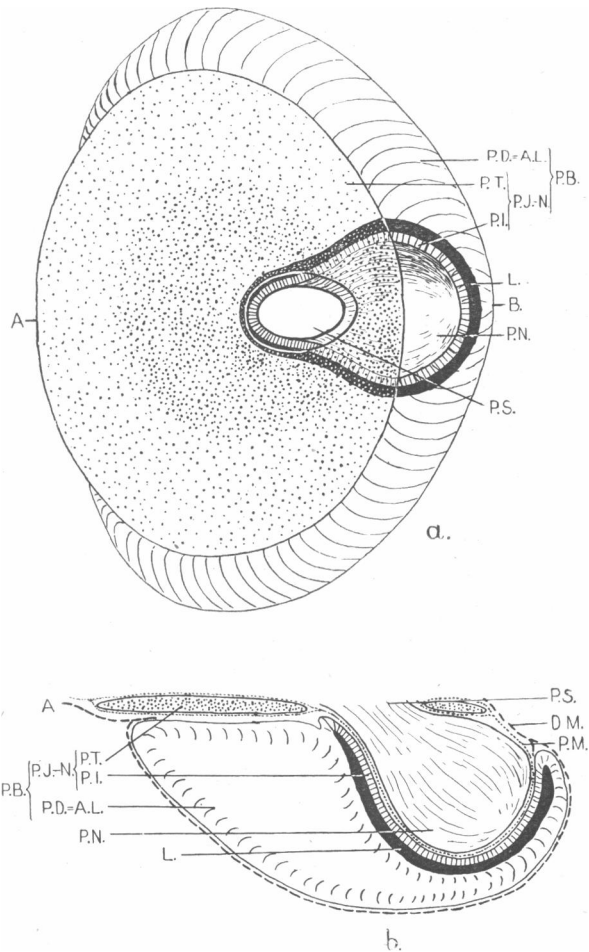


FIG. 13.—(a) Diagrammatic ground plan of hypophysis to show the relations of the various parts. The hypophysis is represented as removed from the brain and viewed from the dorsal surface in optical section. (b) Diagrammatic median longitudinal section through adult hypophysis. (Sectional plane indicated by line A B in fig. a.) (N.B.—The relations and approximate proportions of the parts in these figures were obtained by measurement with an ocular micrometer of the hypophysis in *Trichosurus vulpecula*, Stage XI. (see p. 212), H.L. 20 mm., G.L. 4 cm.)

D.M., dura mater; L., lumen; P.M., pia mater; P.S., pituitary stalk;
 P.B., pars buccalis; { P.J.-N., pars juxta-neuralis; { P.T., pars tuberalis;
 { P.D., pars distalis = A.L., anterior lobe;
 P.N., pars neuralis. { P.I., pars infundibularis;

nomenclature used by him, some of the terms being originally suggested by Gentes (15).

We can accordingly recognise in the hypophysis a *pars neuralis* (fig. 13, P.N.) (=posterior lobe, infundibular process, "Hirnteil," neurohypophysis) and a *pars buccalis* (P.B.) (=anterior lobe, epithelial or glandular portion, "Hauptlappen," together with the *pars intermedia*). The *pars buccalis* is subdivided into a *pars juxta-neuralis* (P.J.-N.), in contact with the brain, and a *pars distalis* (P.D.) (=anterior lobe proper). The *pars juxta-neuralis* consists of a *pars tuberalis* (P.T.) (Tilney (59)), lying in contact with the tuber cinereum, and a *pars infundibularis* (P.I.) (=pars intermedia), *i.e.* the epithelial layer between the residual lumen and the infundibular process. The difference in origin and appearance of these two portions of the *pars juxta-neuralis* which Tilney (59) describes in the fowl, cat, rabbit, rat, and sheep, is also recognisable in Marsupials.

In early stages the use of topographical terms is necessary, and I accordingly describe the parts of Rathke's pouch as dorsal, *i.e.* on the side next the diencephalic floor; ventral, *i.e.* on the side next the pharyngeal roof; cranial, towards the telencephalon; and caudal, towards the mesencephalon.

Trichosurus vulpecula.

STAGE I. *Embryos* γ 99, 1.01, and δ 97.—The hypophysis of these embryos shows only a slight advance on that of Stage IV., *Perameles nasuta* (13, VII. 05).

The oral plate is ruptured (fig. 14, O.P.), but its ventral point of attachment is still visible, whilst dorsally a considerable remnant of it persists. Behind the oral plate is a small conical diverticulum with thickened walls. This is the only trace of pre-oral gut which occurs in *Trichosurus* (fig. 14, S.P.).

On the cephalic side of the oral plate the ectoderm of the head is thickened for a short distance, forming with the ectoderm of the upper margin of the oral plate the primordium of Rathke's pouch (R.P.). Transverse sections show that in its cephalic portion the pouch is widely open on its ventral side, while its dorsal wall is closely applied to the diencephalic floor. The pouch is, however, closed in its posterior portion and is bifid at its caudal extremity. The small pre-oral gut fits into the bifurcation of the pouch so that in the middle line its entoderm is in contact with the floor of the diencephalon, whilst on either side it is separated therefrom by the lateral branches of Rathke's pouch. The wall of the pouch consists of several layers of columnar cells.

The floor of the diencephalon is depressed to form the primitive infundibular recess, whose dorsal limit is indicated by a slight horizontal ridge on the inside of the diencephalon. No infundibular process is yet indicated.

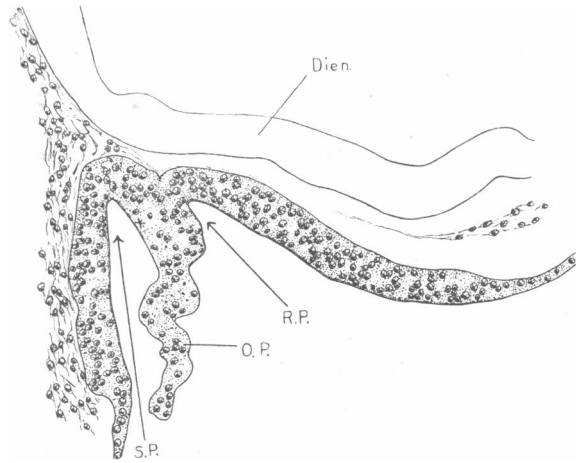


FIG. 14.—Stage I. *Trichosurus vulpecula* (1, a, 01). Median longitudinal section through the hypophysis and Seessel's pocket. Sl. 2-4-4.

Dien., diencephalic floor; O.P., oral plate; R.P., Rathke's pouch; S.P., Seessel's pocket.

STAGE II. *G.L.* 7 mm. (*Embryo* a' 97).—In this stage the limits of Rathke's pouch are clearly indicated by lateral grooves. The pouch is still widely open anteriorly, but its opening has narrowed considerably. Its roof is thick, its posterior closed portion is quadrilateral in transverse section, and its caudal extremity is slightly bifid.

The infundibular depression is relatively wide anteriorly, but becomes narrower posteriorly, indicating the form and position of the infundibular process.

A small rounded diverticulum situated caudal to the opening of Rathke's pouch represents the degenerating remnant of Seessel's pocket.

STAGE III. *G.L.* 7.5 mm. (*Embryo* XIX. 04).—The opening of Rathke's pouch has narrowed so as to form a short, wide duct, while the pouch itself is subdivided, in the portion behind the duct, by a pair of horizontal constrictions. The two lobes thus formed may be distinguished as proximal (*i.e.* nearest to the opening of the pouch, fig. 15, P.L.) and distal (*i.e.* nearest to the diencephalic floor, D.L.). The constriction disappears at the point where the hypophysial duct opens, so that the anterior, open section of the pouch is undivided. We shall see that the proximal lobe is destined to

form the pars tuberalis of the adult hypophysis, the remainder of the pouch forming the pars distalis and the pars infundibularis.

Both proximal and distal lobes in this stage are slightly bifid at their caudal extremity, the distal more markedly so than the proximal.

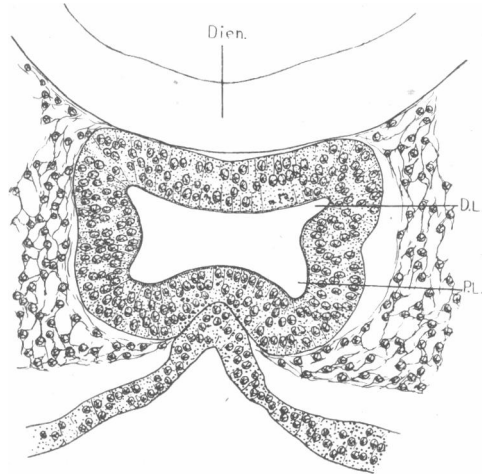


FIG. 15.—Stage III. *Trichosurus vulpecula* (XIX. 04). Transverse section through Rathke's pouch. Sl. 2-4-7.

D.L., distal lobe; Dien., diencephalic floor; P.L., proximal lobe.

STAGE IV. *G.L.* 7.25 mm. (XII. 02 and XII. A. 02).—The duct is here still further reduced, and anterior to it the pouch is relatively small and simple. The distal lobe is now considerably larger than the proximal, and extends further in the caudal direction (figs. 16 and 17). It is relatively extensive in the dorso-ventral direction immediately caudal to the duct, and its walls are thick, consisting of a many-layered epithelium. Posterior to this it widens from side to side and becomes shallower, its dorsal wall becomes thin, while its lateral walls are thick and rather irregular. It is bifid posteriorly, the walls of the two halves being thin and forming a regular epithelium.

The proximal lobe (P.L.) is compressed dorso-ventrally, is wide from side to side, and is undivided posteriorly. The ventral wall is thin (fig. 16), its dorsal wall thicker.

A short conical infundibular process is present, fitting in between the two halves of the bifid caudal extremity of the distal lobe. Its walls, like those of the brain generally, consist simply of undifferentiated cells, uniformly distributed through its thickness. (*N.B.*—The infundibular process

is not shown in the longitudinal section figured, owing to the obliquity of the sectional plane.)

A small remnant of oral plate (fig. 17, O.P.) is present, arising from the postero-ventral wall of the proximal lobe. The narrowing of Rathke's pouch has occurred in such a way as to carry this remnant of oral plate within the opening of the pouch so that a remnant of Seessel's pocket (S.P.)

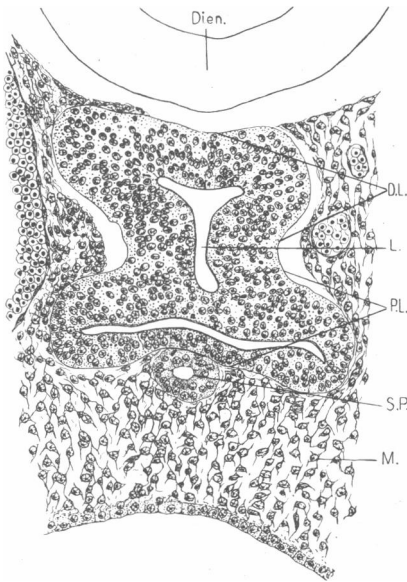


FIG. 16.—Stage IV. *Trichosurus vulpecula* (XII. 02). Transverse section through hypophysis. Sl. 5-2-8.

D.L., distal lobe; Dien., diencephalic floor; L., lumen; M., mesenchyme; P.L., proximal lobe; S.P., Seessel's pocket.

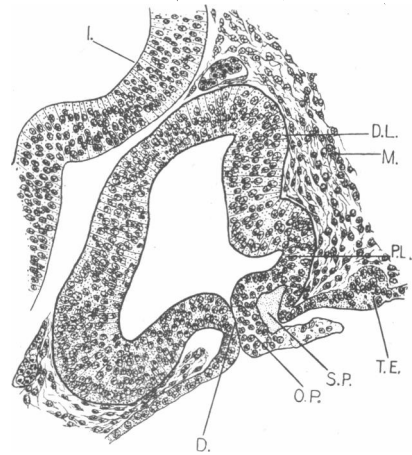


FIG. 17.—Stage IV. *Trichosurus vulpecula* (XII. A. 02). Longitudinal section through hypophysis. Sl. 8-3-2.

D., duct of Rathke's pouch; D.L., distal lobe; I., infundibular recess; M., mesenchyme; O.P., oral plate; T.E., transitory entodermal thickening; P.L., proximal lobe; S.P., Seessel's pocket.

is carried inwards and forms a small diverticulum on the posterior wall of the short duct. Thus it happens that portions of oral plate and of the entodermal wall of Seessel's pocket come to be included in the hypophysis at this stage.

STAGE V. *G.L.* 8.5 mm. (*Embryos* IV. 01 and 5' 97).—The distal lobe (fig. 18, D.L.) has enlarged considerably, while the proximal lobe (P.L.) is much smaller relative to the whole buccal pouch. The duct is now reduced to a fine strand of cells. Seessel's pocket and the remnant of the oral plate have disappeared completely.

The proximal lobe, which lies entirely posterior to the remnant of the

duct, is wide from side to side, but very shallow dorso-ventrally, with a small, cleft-like cavity. Its walls are thin and its lateral margins are slightly enlarged (L.P.L.). The lumen communicates with that of the main, distal lobe by a wide opening.

The distal lobe now constitutes the main bulk of the pouch, and its walls are distinctly thickened, except the portions which lie in actual contact with the infundibular process, these being thin (fig. 18, *c* and *d*). The

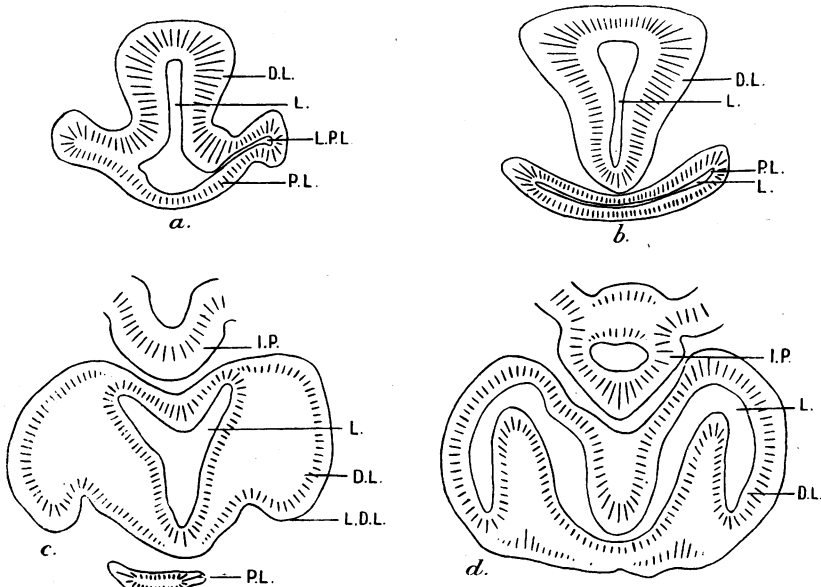


FIG. 18.—Stage V. *Trichosurus vulpecula* (IV. 01). Series of transverse sections through hypophysis, *a* being the most anterior, *d* the most posterior.

D.L., distal lobe; I.P., infundibular process; L., lumen; L.D.L., lateral expansion of distal lobe; L.P.L., lateral expansion of proximal lobe; P.L., proximal lobe.

lobe is rounded anteriorly, then becomes enlarged in the dorso-ventral direction (fig. 18, *a*). Posterior to the remnant of the duct, it has two large dorso-lateral hollow appendages (fig. 18 *c*, L.D.L.), whose cavities open into the main lumen. The distal lobe is still bifid caudally, and the infundibular process, which is a short, conical structure, fits in between the two halves. Its walls show no change since the preceding stage.

Up to this stage the most intimate relations between the diencephalic floor and the buccal pouch have been maintained, but in the longitudinal series of this stage there is a certain amount of mesenchymal tissue between the hypophysis and the brain floor in the region anterior to the

infundibular process. This latter is, however, in direct contact with the epithelial wall of the buccal pouch.

STAGE VI. *G.L.* 11 mm. (*Embryos XXII. 01 and XXI. 04*); *G.L.* 11.5 mm. (*Embryo VII. 01*).—The walls of the main distal lobe (D.L.)

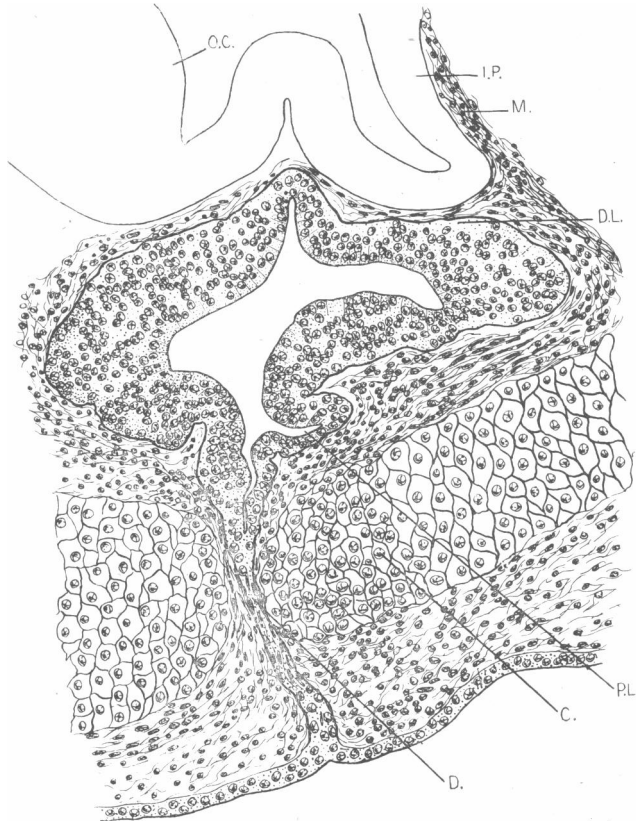


FIG. 19.—Stage VI. *Trichosurus vulpecula* (XXII. 01). Median longitudinal section through hypophysis. Sl. 11-2-1.

C., cartilage of skull; D., duct of Rathke's pouch; D.L., distal lobe; I.P., infundibular process; M., mesenchyme; O.C., optic chiasma; P.L., proximal lobe.

have now thickened considerably, so that in the region anterior to the duct only a small remnant of the lumen is present (figs. 19 and 20, L.).

The lumen enlarges in dorso-ventral extent in the middle portion of the hypophysis, and narrows again posteriorly. The dorso-lateral, wing-like expansions of the previous stage are still present, but their cavity is reduced to a small cleft, in open communication with the main lumen.

The walls consist of closely packed cells, showing no trace of differentiation or grouping.

The proximal lobe (fig. 20, P.L.) is crescentic in transverse section, with thin walls consisting of a regular epithelium. Its median portion contains a small, cleft-like cavity (L.), while its lateral wings (L.P.L.) are markedly enlarged and are produced backwards along the sides of the distal lobe.

In the posterior portion of the pouch, the dorsal wall is somewhat thin, and the bluntly conical infundibular process (fig. 19, I.P.), whose walls are still undifferentiated, fits into a depression in this wall. A thin layer of connective tissue has penetrated between the neural and buccal portions of the hypophysis in this stage.

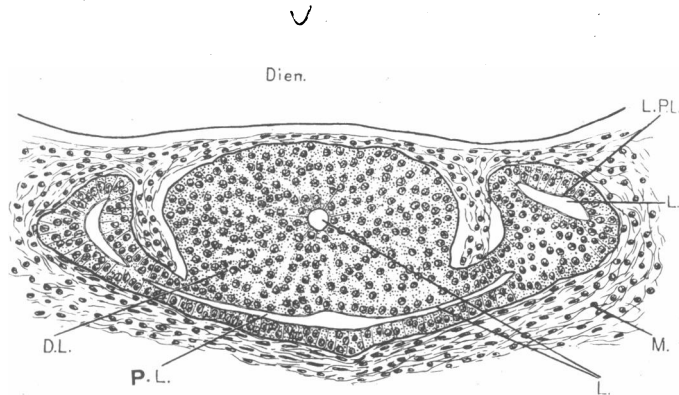


FIG. 20.—Stage VI. *Trichosurus vulpecula* (VII. 01). Transverse section through hypophysis. Sl. 4-1-9.

D.L., distal lobe; Dien., diencephalic floor; L., lumen; L.P.L., lateral expansion of proximal lobe; M., mesenchyme; P.L., proximal lobe.

No trace of Seessel's pocket is present.

STAGE VII. *G.L.* 13 mm. (*Embryos IX. 01 and VIII. 01*).—In general shape the hypophysis closely resembles that of the preceding stage, but it has increased considerably in size.

The walls of the anterior half of the distal lobe have increased in thickness, so that the lumen is reduced to a small, circular cavity (fig. 21, L.), while the extreme anterior end is solid. In the mid-portion of the hypophysis the lumen of the distal lobe increases in vertical extent, and still opens into the cavity of the proximal lobe. Posterior to this it expands into a triangular cavity (fig. 22, L.) with a thin roof (P.I.) and very thick sides; whilst in the hindermost portion the lateral walls also become thinner, the cavity spacious (fig. 23, L.), and the roof indented by the infundibular process (fig. 23, I.P.).

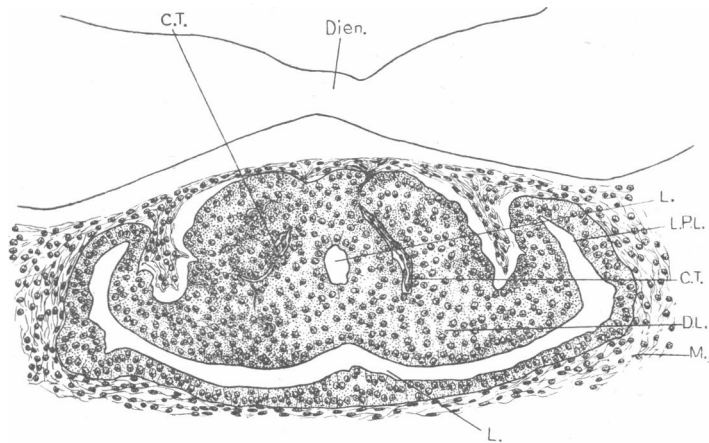


FIG. 21.—Stage VII. *Trichosurus vulpecula* (IX. 01). Transverse section through proximal and distal lobes of hypophysis. Sl. 4-5-10.

C.T., connective tissue; D.L., distal lobe; Dien., diencephalic floor; L., lumen; L.P.L., lateral expansion of proximal lobe; M., mesenchyme.

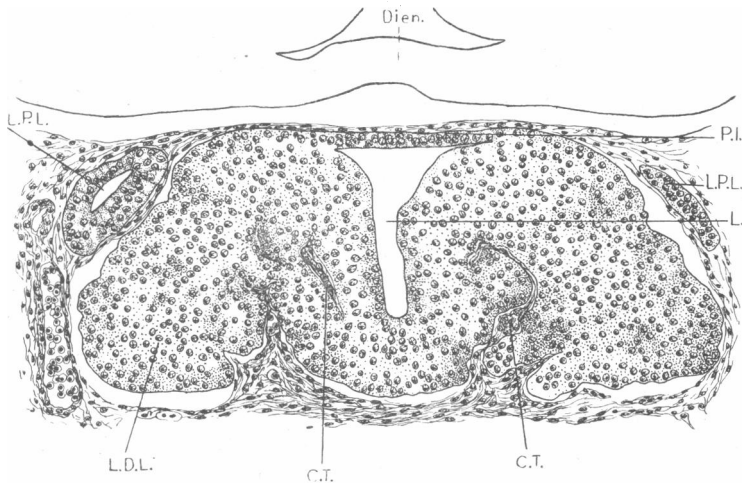


FIG. 22.—Stage VII. *Trichosurus vulpecula* (IX. 01). Transverse section through distal lobe in region of its lateral expansion. Sl. 5-1-6.

C.T., connective tissue; Dien., diencephalic floor; L., lumen; L.D.L., lateral expansion of distal lobe; L.P.L., lateral expansion of proximal lobe; P.I., portion of wall of pouch destined to form the pars infundibularis.

The proximal lobe is relatively and actually larger than in the preceding stage (fig. 21, P.L.). It is crescentic in transverse section, and has a

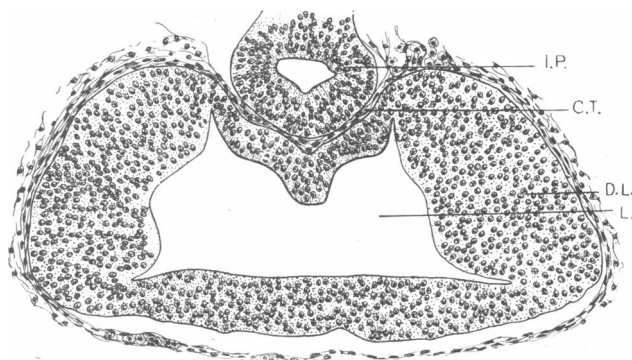


FIG. 23.—Stage VII. *Trichosurus vulpecula* (IX. 01). Transverse section through hypophysis in region of the infundibular process. Sl. 5-2-2.

C.T., connective tissue; D.L., distal lobe; I.P., infundibular process; L., lumen.

well-marked lumen. Its walls consist of a thin and regular epithelium, its dorsal wall has fused to a large extent with the distal lobe, while its lateral

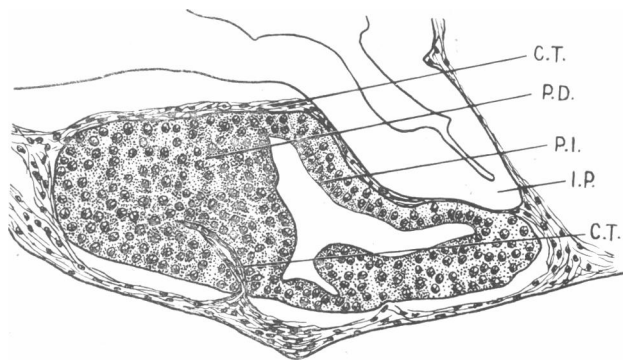


FIG. 24.—Stage VII. *Trichosurus vulpecula* (XXIV.). Medial longitudinal section (reconstructed) through hypophysis. Sl. 7-1-2-4.

C.T., connective tissue; I.P., infundibular process; P.D., pars distalis; P.I., pars infundibularis.

margins (L.P.L.) have grown upwards towards the brain and are prolonged for some way posterior to its median portion (fig. 22, L.P.L.).

In this stage we can see the commencement of processes which convert the uniform walls of Rathke's pouch into the glandular "anterior lobe" of the typical adult hypophysis. In the more solid anterior portion of the

main lobe, thin strands of connective tissue (C.T.) are penetrating into the substance of the walls, sometimes carrying small blood-vessels with them. These strands grow in more or less symmetrically on either side of the middle line, so as to split the solid walls into lobules (figs. 21 and 22); and the cells also show a tendency to group themselves into cords or lobules, but with no indication of lumina. This lobulation only affects the anterior portion of the main lobe, the posterior portion thereof and the whole of the proximal lobe having thin uniform epithelial walls.

The infundibular process is fairly long, with a bluntly pointed apex (figs. 23 and 24, I.P.), and is separated from the buccal portion of the hypophysis by connective tissue (C.T.).

The duct is still present in one embryo of this stage, but is lost in the others, its site being marked by the perforation of the cartilage of the basis cranii.

In this stage the several portions of the adult hypophysis can now be identified. The pars neuralis (fig. 24, I.P.) is pressed against the dorsal wall of the pars buccalis, which itself consists of a juxta-neural portion (P.I.), represented by the thin wall in contact with the pars neuralis and the solid pars distalis (P.D.), already in process of conversion into a gland. The primordium of the pars tuberalis is represented by the lateral enlargements (fig. 21, L.P.L.) of the proximal lobe, the median portion of which subsequently becomes incorporated in the pars distalis. Thus the pars tuberalis is the only part which has not attained approximately its adult situation.

STAGE VIII. *G.L.* 15 mm., *new-born (pouch foetus 5' 97)*. — This stage shows a further advance in the process of breaking up of the solid walls of the hypophysis into lobules. In its main features the hypophysis closely resembles that of the preceding stage. The proximal lobe is much less distinct, its median portion being only represented by horizontal clefts (L., fig. 26) with a thin epithelial floor. Its lateral extensions (fig. 25, L.P.L.) are, however, considerably enlarged, and extend both anteriorly and posteriorly beyond their point of attachment, as hollow structures lying dorso-laterally to the main lobe (fig. 25, L.P.L.).

Ingrowths of connective tissue have broken up the walls of the anterior half of the distal lobe into rounded lobules (fig. 25), making the whole of the pars distalis appear less compact and less uniform than in preceding stages.

The infundibular process is rounded or slightly triangular in transverse section. It narrows to a definite stalk, connecting it with the diencephalic floor. There is a small amount of connective tissue between the infundibular process and the pars buccalis.

A remnant of the duct persists, and a thinning of the cartilage below the hypophysis marks the site of its perforation by the duct.

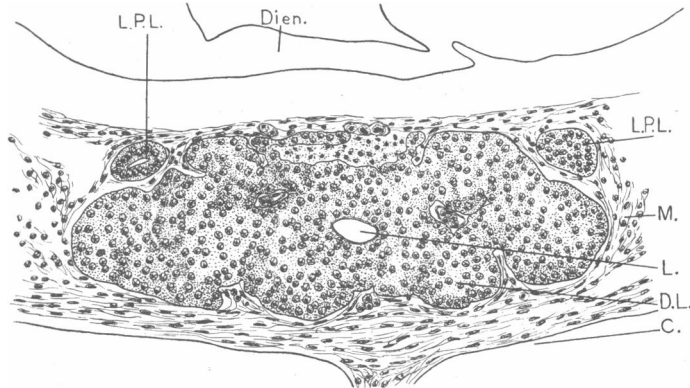


FIG. 25.—Stage VIII. *Trichosurus vulpecula* (5' 97). Transverse section through anterior portion of distal lobe. SL. 3-5-2.

C., cartilage; D.L., distal lobe; Dien., diencephalic floor; L., lumen; L.P.L., later expansions of proximal lobe; M., mesenchyme.

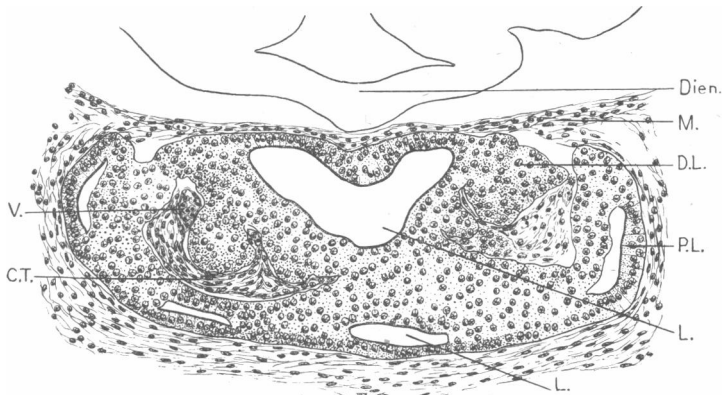


FIG. 26.—Stage VIII. *Trichosurus vulpecula* (5' 97). Transverse section through proximal and distal lobes. SL. 3-5-7.

C.T., connective tissue; D.L., distal lobe; Dien., diencephalic floor; L., lumen; M., mesenchyme; P.L., proximal lobe; V., blood-vessel.

STAGE IX. *Pouch foetus G.L.* 17 mm., and *pouch foetus G.L.* 17.5 mm.—The pars buccalis is now converted into a relatively compact structure, *i.e.* there is little indication externally of subdivision into lobes. The proximal lobe is, however, still represented in the middle line by a small, horizontal cleft, while the lateral wings are still further enlarged.

There is a considerable main lumen, which is restricted to the posterior half of the pars buccalis. The walls of the pars distalis consist of masses of cells more or less completely split up into lobules, separated by connective tissue carrying blood-vessels. The pars juxta-neuralis (infundibularis) consists of a thin epithelial layer, lying close to the infundibular process, but separated therefrom by connective tissue.

The infundibular process closely resembles that of the preceding stage, and still contains a well-marked lumen.

Remnants of the duct are present, and the point of perforation of the cartilage is still clear in one embryo.

STAGE X. *Pouch fetus, H.L. 11 mm., and pouch fetus H.L. 12.5 mm.*—The hypophysis has now attained its adult condition in regard to the general arrangement of the parts. Its subsequent development consists chiefly in histological differentiation in the various regions.

The pars buccalis (fig. 27) is clearly differentiated into pars distalis and pars juxta-neuralis, including infundibular (P.I.) and tuberal (P.T.) portions. The latter has now assumed its definitive position lying between the pars distalis and the diencephalic floor (T.C.), but is as yet restricted to the region anterior and lateral to the hypophysial stalk (figs. 27 and 28, P.T.).

The bulk of the organ is constituted by a compact pars distalis derived from the ventral, antero-, and postero-ventral walls of the pars buccalis of earlier stages. This is continuous on its dorsal side with the thin layer of epithelium constituting the infundibular portion of the pars juxta-neuralis (P.I.) and forming the roof of the residual lumen (L.) which forms a cup-shaped cleft surrounding the infundibular process. (Compare figs. 27 and 28, L.) There is a relatively small portion of the pars tuberalis (P.T.) in the median line, but on either side of the hypophysial stalk it has attained considerable dimensions (fig. 28, P.T.).

The pars distalis consists of a compact mass of solid cords of cells, many of which are outlined and separated from each other by strands of connective tissue which can be traced inwards from the sheath surrounding the pars buccalis. The nuclei of the cells of the pars distalis are spherical and deeply stained. The cytoplasm of the majority of the cells is stained faintly blue, but there are also a number of cells whose cytoplasm is stained a distinct reddish colour. These red cells appear to correspond with the chromophilic cells described in the hypophysis by histologists. They appear in this stage for the first time in *Trichosurus*, and, as will be seen from fig. 27, are most numerous in the posterior portion of the pars distalis. They appear in greater numbers and show their peculiar staining capacity in a more marked degree in the later stages of *Dasyurus* and *Phascolarctos*.

The infundibular portion of the pars juxta-neuralis (P.I.) consists of a

thin layer of epithelium closely investing the pars neuralis on its anterior, ventral, and lateral surfaces, but leaving its postero-dorsal face exposed. In transverse sections this layer forms about three-fourths of a circle, surrounding the infundibular process, and also forms both walls of the dorso-lateral horns of the crescentic residual lumen (fig. 28). It is slightly thickened in the region where it joins the lateral masses of the pars distalis.

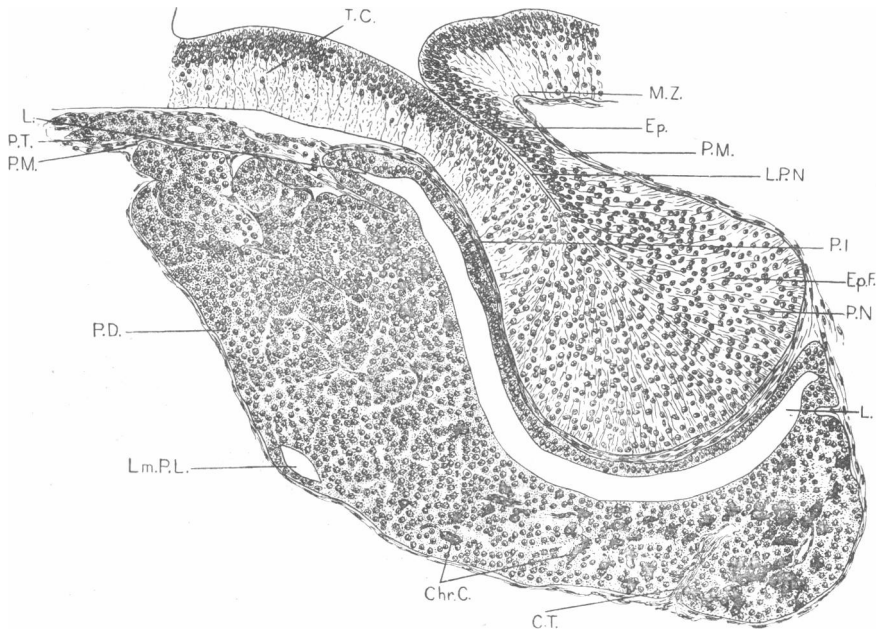


FIG. 27.—Stage X. *Trichosurus vulpecula* (H.L. 12.5 mm.). Median longitudinal section through hypophysis. Sl. 11-1-5.

C.T., connective tissue; Chr.C., chromophilic cells; Ep., ependyma; Ep.F., ependymal fibres; L., lumen; L.P.N., lumen of pars neuralis; Lm.P.L., remnant of lumen of proximal lobe; M.Z., marginal zone; P.D., pars distalis; P.I., pars infundibularis; P.M., pia mater; P.N., pars neuralis; P.T., pars tuberalis; T.C., tuber cinereum.

At its anterior extremity, the pars infundibularis is prolonged into a pocket-like diverticulum, projecting towards the pars tuberalis and lying between the tuber cinereum and the pars distalis (fig. 27, L.). The epithelium of the pars juxta-neuralis consists of two or three layers of cells with very darkly staining nuclei.

The pars tuberalis is the direct derivative of the enlarged lateral portions of the proximal lobe of earlier stages. The proximal lobe is no longer complete, but portions of it remain. A small cleft on the ventral side of the pars distalis (fig. 27, Lm.P.L.) represents the remnant of its median

cavity, whilst the tubules of the pars tuberalis are connected on one side at least with the pars distalis by a solid cord of cells which runs round the side of the pars distalis and joins it ventro-laterally. This is clearly the remnant of the hollow, crescent-shaped portion of the proximal lobe. Its dorso-lateral wings have enlarged markedly, grown up towards the brain and branched, so that they now form a series of thin-walled tubules which have penetrated between the pars distalis and the tuber cinereum. Anterior to the pocket-like diverticulum of the pars infundibularis, they actually reach the middle line; in the region of the diverticulum, they lie on either

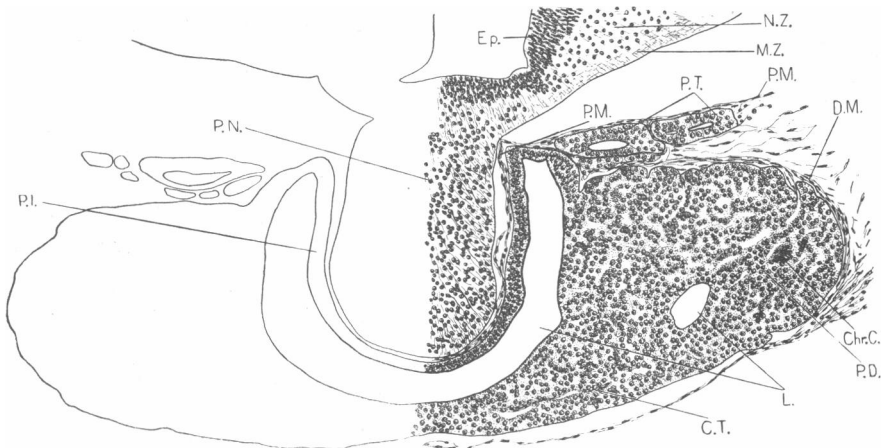


FIG. 28.—Stage X. *Trichosurus vulpecula* (H.L. 11 mm.). Transverse section through hypophysis. Sl. 10-1-2.

C.T., connective tissue; Chr.C., chromophilic cells; D.M., dura mater; Ep., ependyma; L., lumen; M.Z., marginal zone; N.Z., nuclear zone; P.D., pars distalis; P.I., pars infundibularis; P.M., pia mater; P.N., pars neuralis; P.T., pars tuberalis.

side of it; posterior to it, they lie lateral to the stalk of the pars neuralis (see fig. 28, P.T., etc.). The walls of the tubules consist of two or three layers of epithelial cells whose nuclei are deeply stained, while their cytoplasm in its staining capacity resembles the lightly stained cells of the pars distalis.

The infundibular process is connected with the floor of the diencephalon by a relatively stout stalk. It is enlarged distally (fig. 27, P.N.), and contains a small lumen in the 12.5 mm. (H.L.) embryo (fig. 27, L.P.N.), but is solid in the 11 mm. (H.L.) embryo. The ependymal layer of the diencephalic floor is continuous with that of the infundibular stalk, and extends a short way into the substance of the pars neuralis, the bulk of which is made up of fibres and scattered cells closely resembling those of the nuclear (mantle) zone of the diencephalic wall (fig. 28, N.Z.).

The connective tissue separating the nervous and non-nervous portions of the hypophysis exhibits a tendency to penetrate into the tissues of the pars neuralis, but has not as yet done so to any marked extent, nor is there any sign of blood-vessels entering the nervous lobe at this stage.

STAGE XI. *Pouch foetus G.L. 4 cm., H.L. 20 mm.*—The hypophysis in this foetus closely resembles that of the preceding stage in form and general relations of the parts. It has increased considerably in size, both pars buccalis and pars neuralis being much larger than in the

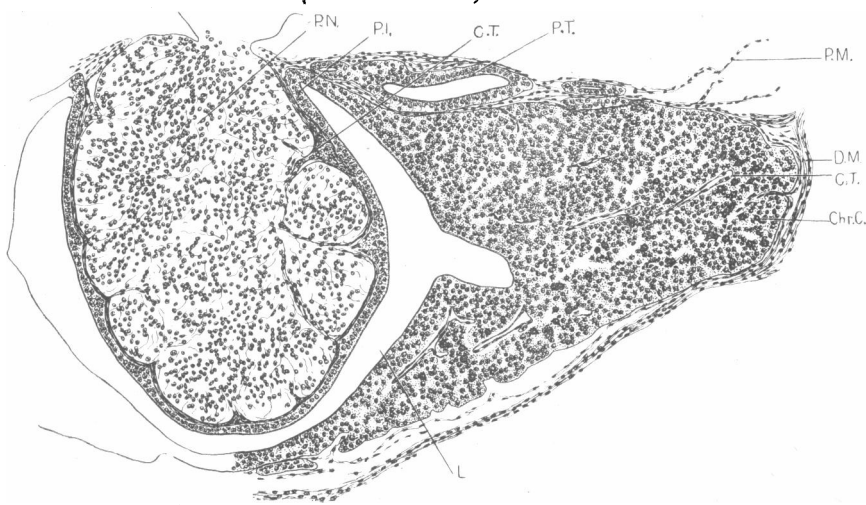


FIG. 29.—Stage XI. *Trichosurus vulpecula* (H.L. 20 mm.). Transverse section through hypophysis. Sl. 23-3-5.

C.T., connective tissue; Chr.C., chromophilic cells; D.M., dura mater; L., lumen; P.I., pars infundibularis; P.M., pia mater; P.N., pars neuralis; P.T., pars tuberalis.

preceding stage, whilst the process of histological differentiation has made considerable progress.

The number of chromophilic cells (fig. 29, Chr.C.) in the pars distalis has increased considerably, especially in the posterior portion of that part. Moreover, these cells are now more clearly differentiated from the chromophobic cells, their cytoplasm staining a bright red, while that of the chromophobic cells is stained faint blue.

The pars tuberalis (P.T.) has increased to such an extent that it has spread into the narrow space between the pars buccalis and the diencephalic floor so as to completely encircle the hypophysial stalk (*cf.* fig. 13). Thus it comes to have the form described by Tilney (59), viz. that of a diaphragm lying between the pars distalis and the diencephalon, with the stalk of the pars neuralis passing through its aperture.

It is in the pars neuralis (fig. 29, P.N.) and the pars infundibularis (P.I.) that we find the most marked advance on the preceding stage. The distal portion of the pars neuralis has expanded considerably, while its attachment to the diencephalic floor is relatively slender. The connective tissue between these two portions has grown actively and penetrated into the tissues of the pars neuralis, breaking it up more or less completely into lobules (fig. 29, P.N.). Furthermore, it tends to carry in with it some of the cells of the pars infundibularis, so that whilst the outer side of that layer, *i.e.* that bordering the residual lumen, is still perfectly regular, the inner margin is irregular, the cells here and there penetrating a short way into the tissues of the pars neuralis. Over the greater part of its extent, however, the pars infundibularis simply consists of a single layer of epithelium.

The pars neuralis still contains a large number of cells, but its fibrous constituents have become much more conspicuous.

Capillaries do not appear as yet to have penetrated into the pars neuralis; indeed, the pars buccalis is not yet richly vascularised.

The relations of the meninges are as follows (figs. 13 and 29, D.M., P.M.):—The dura mater (D.M.) forms a connective tissue capsule for the whole of the pituitary body. The main portion passes straight round on the ventral surface of the whole structure, thus enclosing it within the same membrane with the brain. At the anterior and posterior ends of the pituitary a considerable thickness of the dura mater is reflected over the dorsal surface of the pars buccalis, but this layer extends in towards the hypophysial stalk through only a few sections. In the remainder of the pars distalis a few fibres pass round on to the dorsal surface of the lobe, and even penetrate inwards to the middle line, except in the region of the hypophysial stalk. The pia mater (P.M.) constitutes a very thin layer covering the brain and passing continuously over the surface of the pars neuralis, lying between it and the pars juxta-neuralis and penetrating into the substance of the nervous lobe in the manner already described. The pia mater also completely invests the tubules of the pars tuberalis and penetrates between them.

Phascolarctos cinereus.—In many respects the development of the hypophysis of *Phascolarctos* closely resembles that of *Trichosurus*. It shows, however, one or two points of interest, notably the persistence of Seessel's pocket. I have accordingly described such stages in development as serve to illustrate these points.

STAGE I. *G.L.* 4 *mm.*—The hypophysis is already developed as a wide pouch, fairly deep posteriorly where it is closed, but shallow and widely open in its anterior portion. It is very noticeably bilobed (*cf.* fig. 30),

the lateral angles being thick-walled, while in the middle line the epithelium is much thinner.

There is a small remnant of the oral plate, posterior to which lies Seessel's pocket, in the form of a short, rounded diverticulum of the fore-gut, whose tip lies between the floor of the hypophysis and the wall of the gut.

No infundibular process is present, and from the fact that the di-encephalon is still unclosed it is evident that the hypophysis appears at an earlier stage in *Phascolarctos* than it does in *Trichosurus*.

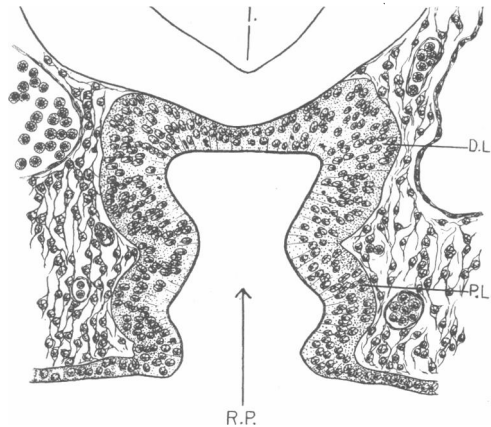


FIG. 30.—Stage II. *Phascolarctos cinereus*. Transverse section through Rathke's pouch. Sl. 5-11-2. Note the markedly thickened lateral angles of Rathke's pouch.

D.L., distal lobe ; I., infundibular recess ; P.L., proximal lobe ;
R.P., Rathke's pouch.

STAGE II. *G.L.* 7.5 mm.—In this stage we find a remarkable development of the pre-oral gut.

The hypophysis forms a deep pouch, which is differentiated anteriorly into proximal and distal lobes by a well-marked equatorial constriction.

The oral plate is ruptured ventrally, but a considerable portion of it persists dorsally, being inserted at the apex of Rathke's pouch and separating this from the pre-oral gut. The oral plate is slightly convex on its posterior face, so that in the sections immediately behind that which passes through its full expanse, the convex projection of the oral plate is cut and appears in section as a sort of plug (cf. *Perameles nasuta*, (13 VII. 05), fig. 5). The section represented in fig. 31 passes through almost the complete expanse of oral plate dorsally, and shows the ventral portion of the oral plate projecting into Seessel's pocket.

Seessel's pocket forms a vesicle of considerable dimensions (figs. 31 and 32, S.P.) opening by a small duct immediately posterior to the oral plate. It is of the same depth as the hypophysis, and its distal wall is in actual contact with the diencephalic floor (fig. 32, Dien.), whilst it also, like Rathke's pouch, shows an indication of an equatorial constriction.

Its walls are thick, and are composed of a regular, columnar epithelium.

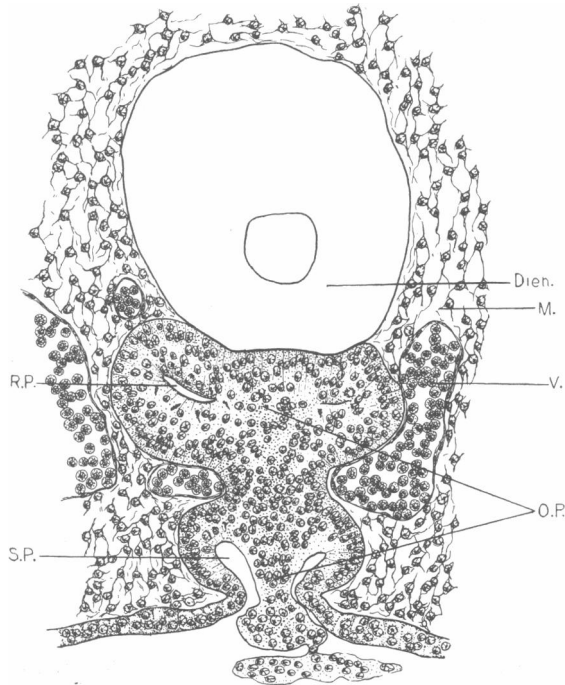


FIG. 31.—Stage II. *Phascolarctos cinereus*. Transverse section through hypophysis, Seessel's pocket, and the oral plate. Sl. 5-1-5.

Dien., diencephalic floor; M., mesenchyme; O.P., oral plate; R.P., Rathke's pouch; S.P., Seessel's pocket; V., blood-vessel.

Histologically it is, in fact, indistinguishable from the hypophysis. The anterior extremity is pressed against the posterior wall of Rathke's pouch, which is thereby indented slightly in the middle line.

A rounded depression in the diencephalic floor represents the primitive infundibular recess, but no infundibular process is yet differentiated.

The notochord in this embryo reaches actually to the level of the posterior wall of Seessel's pocket, but is not in actual contact therewith.

STAGE III. *G.L.* 9 mm.—The hypophysis has increased considerably

in size, but is still widely open anteriorly and consists of proximal and distal lobes.

A definite infundibular process is present in the form of a short conical outgrowth of the diencephalic floor (fig. 34, I.P.). This is in intimate contact with both Rathke's pouch and the pre-oral gut (*vide infra*).

Remnants of the oral plate are present in the form of a solid, knob-like mass of tissue lying outside the pouch and a small portion lying free in the lumen of Rathke's pouch.

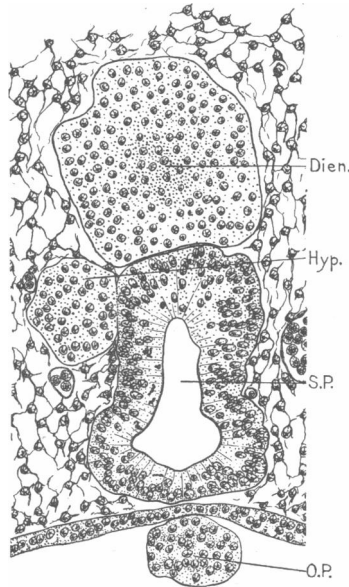


FIG. 32.—Stage II. *Phascolarectos cinereus*. Transverse section through Seessel's pocket. Sl. 5-1-2.

Dien., diencephalic floor; Hyp., posterior wall of one of lateral caudal lobes of the hypophysis; O.P., oral plate; S.P., Seessel's pocket.

Seessel's pouch has lost its opening into the gut and simply forms a closed, hollow vesicle, in intimate contact with Rathke's pouch, but having no communication with it. It is elongated in the antero-posterior direction, and is divided as before into two lobes, whose cavities are now completely separate from each other. Its walls consist, as before, of regular columnar epithelial cells, and resemble those of the hypophysis so closely that in the posterior region, where Rathke's pouch is bifid and Seessel's pocket lies between the two halves, there appear to be three precisely similar lobes of the hypophysis (fig. 34).

Anterior to the point of bifurcation of Rathke's pouch, the pre-oral gut is excluded from contact with the brain floor. It is constricted in this region and has no lumen, but widens again anteriorly and has a small, cleft-like cavity (fig. 33, S.P.). At one point (fig. 33) it is partially separated from Rathke's pouch by a small blood-vessel, but elsewhere the walls of the two structures are in close contact.

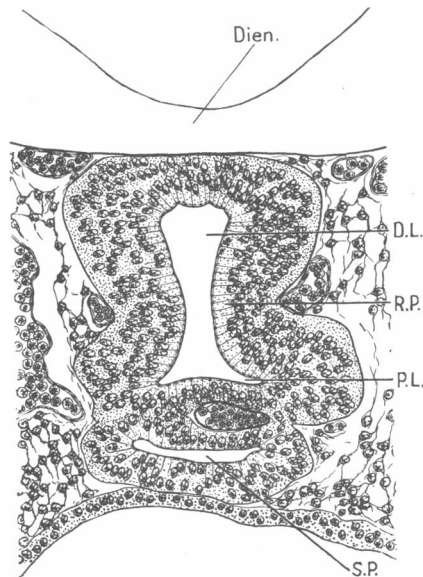


FIG. 33.—Stage III. *Phascolarctos cinereus*. Transverse section through Rathke's pouch and Seessel's pocket. Sl. 4-4-3.

D.L., distal lobe; Dien., diencephalic floor; P.L., proximal lobe; R.P., Rathke's pouch; S.P., Seessel's pocket.

STAGE IV. *G.L.* 11 *mm.*—This stage shows the beginning of the process of formation of tubules. Unfortunately, the series is broken in the region of the hypophysis, so that it is impossible to give a full description.

The walls of the distal lobe in *Phascolarctos*, instead of undergoing subdivision by ingrowths of connective tissue, as occurs in *Trichosurus*, proliferate actively and give off numerous outgrowths which penetrate into the connective tissue surrounding the hypophysis (fig. 35). The proximal lobe is much curved (fig. 35, P.L.), so that its lateral margins, which are enlarged and prolonged both anteriorly and posteriorly, lie dorso-lateral to the main lobe (L.P.L.).

Seessel's pocket is still present, and forms a closed vesicle with a small,

cleft-like lumen. It is much flattened, and is applied to the ventral surface of the hypophysis (S.P.).

STAGE V. *G.L.* 12·25 *mm.*—In this stage the process of conversion of the simple buccal pouch into the compact glandular lobe of the adult is proceeding.

The posterior portion of the pars buccalis has fairly uniform thick walls and a large lumen. Its dorsal wall is indented by the infundibular process. The walls of the anterior portion of the main lobe are produced into numerous outgrowths, some of which now possess a small lumen.

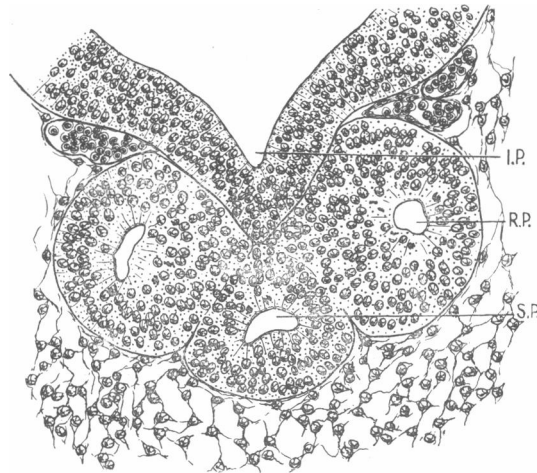


FIG. 34.—Stage III. *Phascolarctos cinereus* (9 mm.). Transverse section through posterior portion of Rathke's pouch and Seessel's pocket. Sl. 4-2-7.

I.P., infundibular process ; R.P., Rathke's pouch ; S.P., Seessel's pocket.

The spaces between these processes are filled with connective tissue in which as yet there are few blood-vessels. The proximal lobe shows the same relations as in the preceding stage. Its walls are produced into a few short solid processes.

The infundibular process is short and conical, and a certain amount of connective tissue has penetrated between it and the pars buccalis, but has not yet reached the middle line.

Seessel's pocket forms a closed vesicle in the same position as in the preceding stage. At its posterior end it increases in dorso-ventral extent, forming a rounded vesicle with thick walls and a small lumen. Anteriorly it becomes flattened and widens out so as to form a thin plate with a cleft-like lumen, while its dorsal wall is confluent with the substance of the

rest of the pars distalis. Its lumen, however, does not communicate with that of the hypophysis.

The pre-oral gut therefore now forms an apparent part of the hypophysis, from which it can only be distinguished by a slight difference in staining capacity and by the fact that its lumen, unlike any portion of the main lumen of the pars buccalis, is completely isolated.

A small remnant of the hypophysial duct is present in this stage, lying

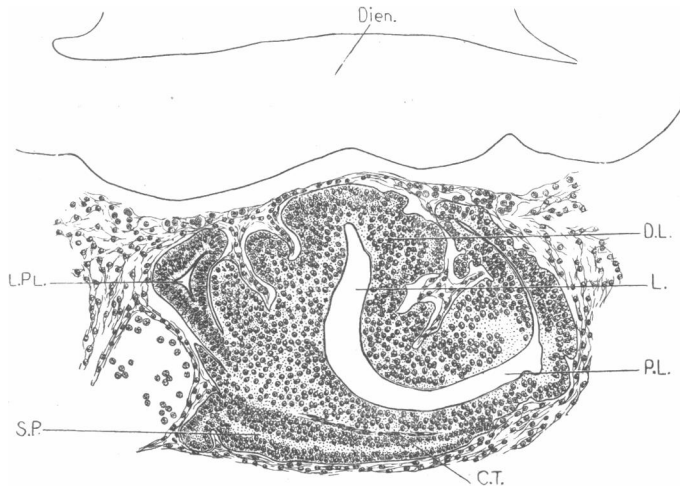


FIG. 35.—Stage IV. *Phascolarctos cinereus* (11 mm.). Transverse section through proximal and distal lobes of hypophysis. Sl. 6-1-10.

C.T., connective tissue; D.L., distal lobe; Dien., diencephalic floor; L., lumen; L.P.L., lateral enlargement of proximal lobe; P.L., proximal lobe; S.P., Seessel's pocket.

outside the cartilage of the skull, but there is no trace of it within the skull, nor any indication of perforation of the cartilage.

STAGE VI. *GL.* 13.5 mm.: *longitudinal and transverse series.*—In general form the hypophysis in this stage closely resembles that of the preceding, but the process of tubule-formation has increased so far as to convert the distal portion of the pars buccalis into a compact mass of tubules separated from each other by connective tissue (fig. 36).

The minute structure of the pars buccalis differs considerably in this stage from that of any stage of *Trichosurus*. Fig. 36, which represents a longitudinal section about 6-8 sections (15μ) from the middle line, shows this structure. In place of the solid, irregular, and ill-defined lobules of *Trichosurus*, the cells are arranged in a series of relatively definite tubules (T.), some of which possess a lumen (L.i.), while the outline of these tubules, instead of being indicated simply by a cleft, is marked by a definite though

fine line, representing a basement membrane of the cells constituting the walls of the tubules.

The infundibular process is narrow and pointed, and is separated from the pars buccalis by connective tissue, which has penetrated to the middle line in some places.

Seessel's pocket can be readily identified, and has undergone no change since the preceding stage.

STAGE VII. *G.L.* 16.5 mm.: *new-born.*—This stage shows little advance on the preceding. The pars distalis has become more compact,

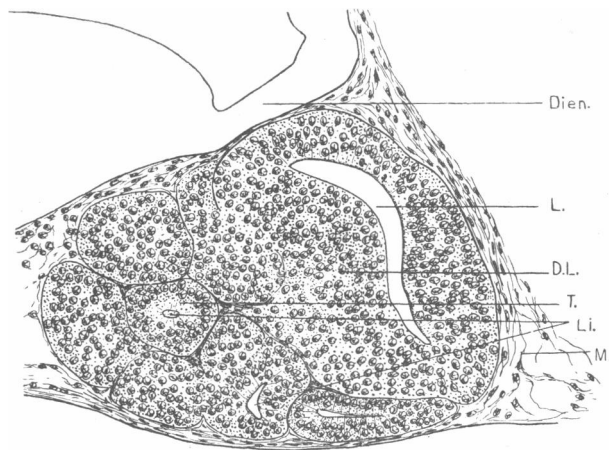


FIG. 36.—Stage VI. *Phascolarctus cinereus* (13.5 mm.). Longitudinal section through hypophysis. Sl. 12-2-7.
D.L., distal lobe; Dien., diencephalic floor; L., lumen of pars distalis; L.i., lumina of tubules; M., mesenchyme; T., tubule of pars distalis.

its tubules having increased in size and number and become pressed more closely together.

The lateral portions of the proximal lobe have grown round the main body of the pars buccalis, and now lie almost entirely dorsal thereto.

Seessel's pocket is clearly recognisable. As before, it is dorso-ventrally compressed and wide anteriorly, while posteriorly it forms a vesicle triangular in section and having a small lumen.

STAGE VIII. *Pouch fetus G.L.* 17 mm.—A noticeable feature of this stage is the very rich supply of capillaries to the pars distalis. They occupy the spaces between the tubules, and have also penetrated between the infundibular process and the pars buccalis. A pair of small vessels, symmetrically disposed, enter the pars distalis on its ventral surface. The distal lobe in this, as in other similar stages of *Phascolarctos* and in *Trichos-*

urus (*cf.* fig. 22), is produced into two large wing-like processes, and the blood-vessels enter on the under side of these and penetrate deeply into the tissue of the lobe. Another vessel enters in the middle of the posterior wall of the pars buccalis.

The lateral prolongations of the proximal lobe are now branched (fig. 37), and form a collection of tubules lying dorsal and dorso-lateral to the rest of the pars buccalis. These constitute the primordium of the pars tuberalis (P.T.).

It is not possible in this embryo to identify Seessel's pocket with certainty.

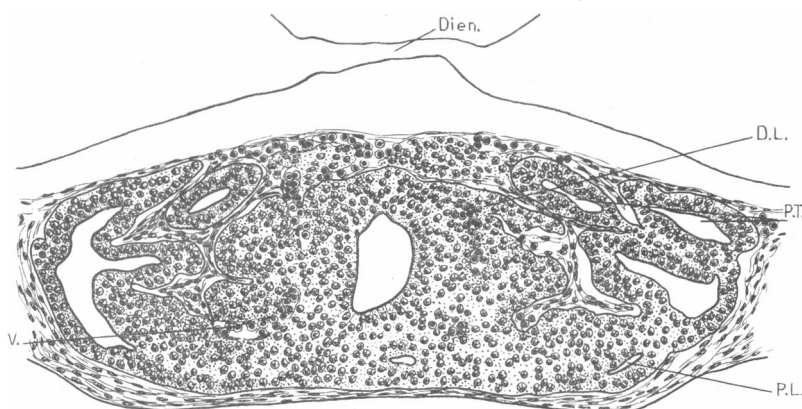


FIG. 37.—Stage VIII. *Phascolarctos cinereus* (17 mm. G.L.). Transverse section through proximal and distal lobes of hypophysis, to show the branched lateral expansions of the former (primordium of pars tuberalis). Sl. 3-2-8.

D.L., distal lobe; Dien., diencephalic floor; P.L., proximal lobe; P.T., primordium of pars tuberalis; V., blood-vessel.

STAGE IX. *Pouch fœtus G.L.* 18 mm.—The series is broken in the region of the hypophysis, but it is worth noting that Seessel's pocket is clearly recognisable and has exactly the same form and relations as in Stage VII.

STAGE X. *Pouch fœtus G.L.* 18.5 mm., *H.L.* 9.5 mm.—This stage shows in general little advance on the preceding. The pars buccalis is somewhat more compact, its tubules being closely pressed together. In this stage for the first time chromophilic cells can be identified in the pars distalis. They are very brightly stained, and are most numerous in the posterior region.

The lateral wings of the proximal lobe are slightly less branched than in the preceding stage.

The infundibular process is small relatively to the size and advanced

condition of the pars buccalis. It forms a simple, thin-walled diverticulum with a somewhat constricted neck.

It is not possible to identify Seessel's pocket with absolute certainty in this stage. A small, flattened structure, closely resembling Seessel's pocket in other embryos, is present, but is in such close relation to the proximal lobe that it is impossible to draw an absolute distinction between the two structures.

STAGE XI. *Pouch fetus* G.L. 24 mm., H.L. 11.5 mm.—The hypophysis has increased markedly in size. The tissue of the pars distalis has un-

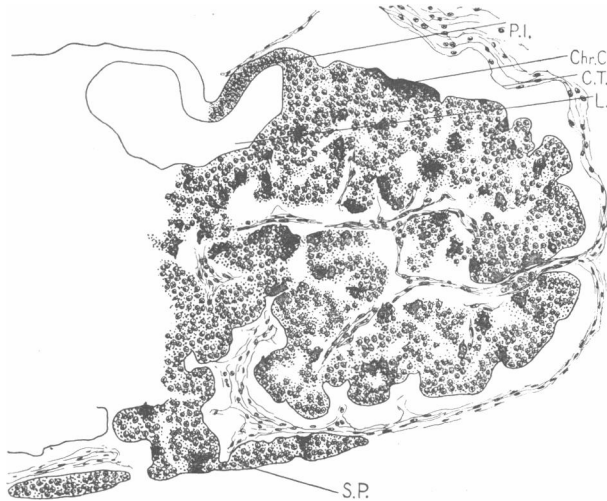

FIG. 88.—Stage X. *Phascolarctos cinereus* (H.L. 11.5 mm.). Transverse section through pars distalis. Sl. 10-1-3.

C.T., connective tissue; Chr.C., chromophilic cells; L., lumen; P.I., pars infundibularis; S.P., Seessel's pocket.

fortunately shrunk away somewhat from the connective tissue, which now forms an interlacing network penetrating throughout the substance of the pars distalis. The appearance of compactness is accordingly destroyed.

The pars distalis consists of numerous rounded lobules, all of which have now lost their lumina. The cells are very clearly differentiated into chromophilic (Chr.C.) and chromophobic types, the former showing up as clear bright-red patches in the tissue (represented black in figures).

The pars tuberalis forms a collection of branched tubules lying between the body of the pars distalis and the diencephalic floor anterior to the infundibular process. It is still connected by a cell cord with the ventral side of the pars buccalis.

The infundibular process has increased somewhat in size, but is still relatively small, and is hollow. Its walls have increased in thickness to a slight extent.

Seessel's pocket can be clearly identified in the posterior portion of the hypophysis. Its caudal portion is free, and is separated from the substance of the pars buccalis by a definite connective tissue sheath. Its caudal extremity retains its original form and relations, lying partly

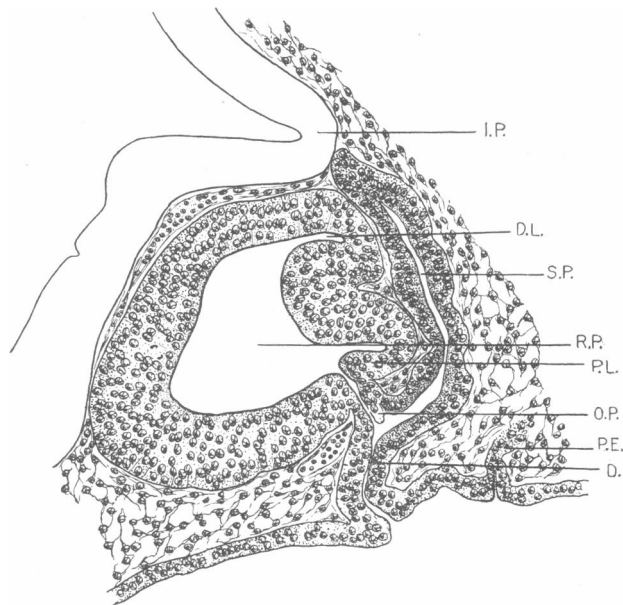


FIG. 39.—Stage I. *Phascolomys mitchelli* (G.L. 8.5 mm.). Longitudinal section through hypophysis and Seessel's pocket. Sl. 8-2-8.

D., duct; D.L., distal lobe; I.P., infundibular process; O.P., remnant of oral plate; P.E., proliferation of entoderm; P.L., proximal lobe; R.P., Rathke's pouch; S.P., Seessel's pocket.

ventral to and between the two halves of the posterior extremity of the pars buccalis. The anterior portion of Seessel's pocket fuses with the ventral side of the pars distalis and becomes absolutely indistinguishable from it (fig. 38, S.P.).

Phascolomys mitchelli.—In *Phascolomys* also Seessel's pocket persists and forms part of the hypophysis, but certain points of difference may be noted between the development in this form and in *Phascolarctos*.

STAGE I. (a) G.L. 9 mm.—Rathke's pouch is already established, and closely resembles that of *Phascolarctos*, Stage II., having well-marked

proximal and distal lobes. It is widely open in its mid-region, but is closed at both anterior and posterior ends.

No definite infundibular process is present.

The distal lobe of Rathke's pouch is bifid at its caudal extremity, and lying between the two halves is a well-developed Seessel's pocket, which in this instance differs considerably from Rathke's pouch in its staining capacity. It is a hollow, conical structure, its walls being composed of a regular epithelium, the cells staining more darkly than those of the hypophysis. It runs forwards, ventral to the hypophysis and in the middle line, for a short distance, and then twists to one side. In correlation with this asymmetry, the remnant of oral plate is displaced from its normal plane and lies obliquely, forming, as usual, the partition wall between Seessel's pocket and the hypophysis.

(b) *G.L.* 8.5 mm.—The hypophysis of this embryo differs from that described above mainly in the fact that the opening of Rathke's pouch is reduced to a narrow duct (fig. 39, D.).

Seessel's pocket (S.P.) has retained its original relations, but the elongation of the duct has taken place ventral to the opening of the pre-oral gut, *i.e.* between the base of that structure and the pharyngeal roof, so that there is a relatively long and narrow duct (D.) which is common to both Seessel's pocket and the hypophysis. A small remnant of oral plate (O.P.) can still be recognised attached to the posterior wall of Rathke's pouch, at its point of junction with Seessel's pocket.

It may be noted that in both the 8.5 mm. and the 9 mm. embryos there is a small entodermal outgrowth (fig. 39, P.E.) posterior to Seessel's pocket.

This structure is a thin tubular diverticulum, and closely resembles the hypophysial duct. It has a minute lumen opening into the pharynx, is very short, and tapers to a blind extremity. I have not observed the occurrence of this structure in other species, unless it corresponds with the entodermal proliferation shown in fig. 17 of *Trichosurus*, Stage IV.

In a later stage of *Phascolomys* (15.5 mm. *G.L.*) there is possibly a trace of it still indicated by the fact that the cartilage is perforated at two points. Through the anterior of these perforations the hypophysial duct passes, whilst on the pharyngeal side of the second there is a small diverticulum, possibly representing a remnant of the structure described above.

In its subsequent stages the hypophysis of *Phascolomys* very closely resembles that of *Phascolarctos*. The walls of the pouch grow out as solid processes which become pressed together to form the compact *pars distalis*. The origin of the *pars tuberalis* is exactly the same as in *Phascolarctos*.

Seessel's pocket is still recognisable in an embryo of 17.5 mm. G.L., but no later stages are available.

In *Phascolomys* the extremely rich vascular supply to the pars distalis in stages of 15.5 mm. G.L. and 17.5 mm. G.L. is noteworthy, and is even more marked than in *Phascolarctos* at similar stages.

Dasyurus viverrinus.—A series of *Dasyurus* stages, from the establishment of Rathke's pouch to a stage in which the infundibular process has become solid, is available, and from study thereof it is evident that the development of the hypophysis in *Dasyurus* closely resembles that process in *Trichosurus*. With regard to the process of conversion of the simple pouch into the glandular lobe of the adult, *Dasyurus* seems to be in some respects intermediate between *Trichosurus* and *Phascolarctos*, for both outgrowth of solid processes and ingrowth of connective tissue play a part in the elaboration of the gland. After the establishment of Rathke's pouch and its subdivision into proximal and distal lobes, its walls become considerably thickened and produced into short rounded processes. At the same time the walls are subdivided by ingrowths of connective tissue so that the two processes occur contemporaneously.

A definite infundibular process appears relatively early in *Dasyurus*, viz. in a stage corresponding approximately to *Trichosurus*, Stage IV., where it forms a relatively long, conical diverticulum.

There is no trace of Seessel's pocket in *Dasyurus* subsequent to the last stage described in Section I. of this paper.

From the more complete series of late stages in *Dasyurus* it is possible to make out some points, more particularly with regard to the infundibular process, which are not shown in the *Trichosurus* series. I propose, therefore, to give a brief description of the three oldest stages of *Dasyurus viverrinus*.

STAGE H. *Pouch fetus*, G.L. 13.5 mm., H.L. 8 mm.—In the general arrangement of the parts, this stage closely resembles *Trichosurus*, Stage X.

From the longitudinal section (fig. 40) it will be seen that the pars buccalis extends further round on to the posterior side of the infundibular process than it does in *Trichosurus*, so that only a small portion of the neck of the latter is exposed. The residual lumen is narrow and cup-shaped, following the outline of the pars neuralis, from which it is separated by a thin epithelial layer, the pars infundibularis (P.I.), which in most places is only one cell thick. A thin layer of connective tissue lies between the pars infundibularis and the pars neuralis.

In the transverse section of this stage the differentiation of two types of cells in the pars distalis is very well marked, the cytoplasm of the chromophilic cells, which are still few in number, staining a bright, clear

red. In the longitudinal section figured, however, there are few chromophilic cells, and these are not markedly differentiated.

The pars tuberalis forms a thin sheet of much-flattened tubules (P.T.), lying between the diencephalic floor and the pars distalis (P.D.), and invested by a thin layer of connective tissue. A small amount of this section of the pars buccalis has penetrated to the middle line anterior to the hypophysial stalk, but the greater part of it lies laterally thereto. The cellular con-

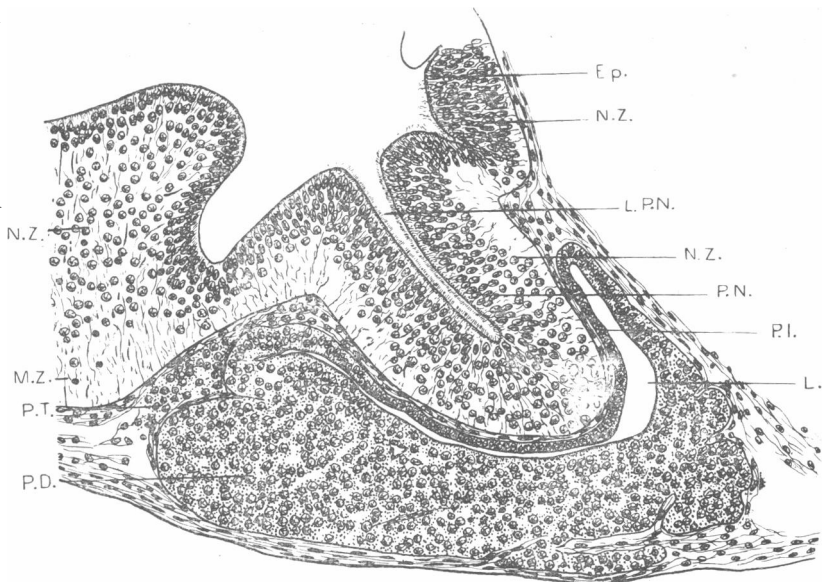


FIG. 40.—Stage H. *Dasyurus viverrinus*. Median longitudinal section through hypophysis. Sl. 3-1-12.

Ep., ependyma; L., lumen; L.P.N., lumen of pars neuralis; M.Z., marginal zone; N.Z., nuclear zone; P.D., pars distalis; P.I., pars infundibularis; P.N., pars neuralis; P.T., pars tuberalis.

nection of the pars tuberalis with the ventral side of the pars distalis is lost, but its origin from the proximal lobe is clear from earlier stages of *Dasyurus*.

The infundibular process is thick and bluntly pointed, and contains a well-defined, narrow cavity (L.P.N.). The walls of the process contain a large number of cells. In the region of the neck these are restricted to the inner half of the wall, *i.e.* that bordering the lumen, whilst the outer part is exclusively composed of fibres. The cells of the innermost layer constituting the ependyma are apparently ciliated, and are continuous with the ependymal cells lining the brain vesicles. They are not histologically

different from the remaining cells which constitute the nuclear or mantle zone (N.Z.). In the distal half of the infundibular process the nuclei of the mantle zone extend out to the periphery, leaving no distinct marginal zone, though they are less closely packed in this region.

STAGE I. *Pouch fetus*, G.L. 17 mm., H.L. 10 mm.—The only change which has occurred in the pars buccalis consists in the increase in the number of the chromophilic cells, which are particularly numerous in the posterior portion of the pars distalis.

The infundibular process has thickened, but its cavity still persists. The ependyma cells can be more readily distinguished from the cells of the nuclear zone, and form a layer, several cells in thickness, lining the lumen.

Fibres can be traced from the internal limiting membrane, passing outwards amongst numerous nuclei scattered through the thickness of the wall. In this stage, as in the last, it is only in the neck of the pars neuralis that a definite marginal zone, consisting of fibres only, can be recognised. In this stage, however, the number of cells is less in comparison with the thickness of the wall than in the preceding, and the fibres are correspondingly more conspicuous.

In the transverse series of this stage the lumen of the infundibular process is already obliterated, but in other respects it shows no difference from the longitudinal series.

STAGE J. *Pouch fetus*, G.L. 20 mm., H.L. 12.5 mm.—The pars buccalis shows no advance on the preceding stage.

The infundibular process (fig. 41), on the other hand, has undergone considerable changes. The whole structure is considerably enlarged, and now has a round, expanded distal portion and a slightly constricted neck. The cavity is obliterated, but its site is indicated by an axial mass of ependymal cells (Ep.). The number of cells in the infundibular process as a whole is relatively, at least, much smaller, so that the pars neuralis now appears to consist of an interlacing mass of fibres with nuclei scattered amongst them. These cells are not restricted to any one portion of the structure, but, apart from the concentration of ependymal cells at the line of closure of the lumen, they are uniformly distributed, so that even in the region of the neck a marginal zone is no longer recognisable. On the other hand, in the region of the tuber cinereum, immediately anterior to the neck of the infundibular process, typical mantle and marginal layers are differentiated.

It thus appears that the infundibular process arises as a diverticulum of the diencephalic floor, whose walls undergo differentiation into ependymal, mantle (nuclear), and marginal zones similar to those of the brain wall.

Subsequently, however, the walls of the pars neuralis undergo modification, becoming more fibrous than those of the brain. As already seen in *Trichosurus* (Stage XI.), it later undergoes further changes due to the ingrowth of connective tissue and cells of the pars infundibularis.

Perameles nasuta.—Apart from details of no apparent importance, such as the differences in the shape of the hypophysis in some stages, the

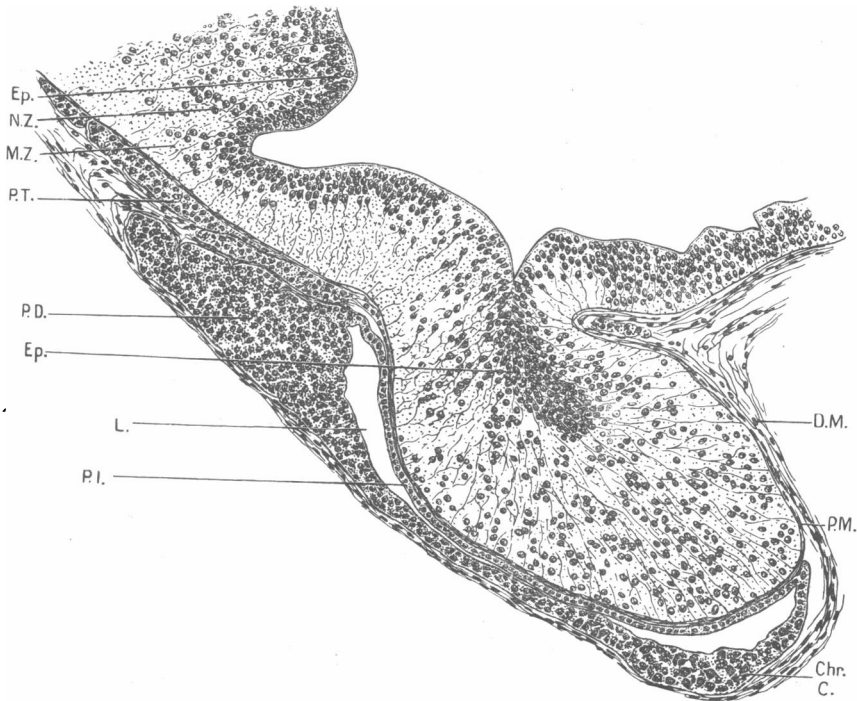


FIG. 41.—Stage J. *Dasyurus viverrinus*. Median longitudinal section through hypophysis. Sl. 1-2-7.

Chr.C., chromophilic cells; D.M., dura mater; Ep., ependyma; L., lumen; M.Z., marginal zone; N.Z., nuclear zone; P.D., pars distalis; P.I., pars infundibularis; P.M., pia mater; P.T., pars tuberalis.

development of the pituitary body in *Perameles* closely resembles that of *Trichosurus*. The differentiation of proximal and distal lobes and the process of formation of glandular tissue follows the same course as in *Trichosurus*.

It is interesting to note that, in spite of the marked development of Seessel's pocket in *Perameles nasuta* (13, VII. 05), Stage IV., described in Section I. of this paper, there is no trace of this structure in any subsequent stage.

The relations of the meninges to the various parts of the hypophysis in a *Perameles* pouch young of 35 mm. G.L., 18.5 mm. H.L., are precisely the same as in *Trichosurus*, Stage XI. (p. 212).

SUMMARY AND DISCUSSION.

I. *The Premandibular Somites, Prechordal Plate, and the Anterior End of the Notochord.*

It is not within the scope of the present paper to deal in any detail with the literature relating to the premandibular head cavities, which is discussed at greater length in relation to the development of the eye muscles in Marsupials by Elizabeth A. Fraser (12).

That the relatively small and irregular structures described in Section I. of this paper are in reality the precursors of the definitive premandibular head cavities described in later stages by E. A. Fraser (12) is evident from comparison with lower Vertebrates, more especially Selachians and Reptiles. In Selachians (Platt, 42, 43), the premandibular head cavities are structures of considerable size, and are connected with each other by a transverse canal (see fig. 42, Pm.B.). Both the premandibular head cavities and the connecting bridge are derived, according to Platt (42, 43), from an entodermal outgrowth from the fore-gut.

Oppel (40) describes the occurrence of premandibular head cavities and a connecting bridge in *Anguis fragilis*. These originate from a mass of entoderm cells to which he has given the name "præchordal Platte," situated between the wall of the fore-gut and the head of the chorda.

C. E. Johnson (25) describes the premandibular somites in an early stage of *Chelydra* (3.5 mm.) as consisting of a small group of cells arranged in a radiating manner around a central lumen (*cf.* figs. 3 and 4). These are connected by a bridge, the median portion of which forms part of a mass of cells arising from the anterior wall of the fore-gut. A similar mass of cells has been described as the point of origin of head cavities by Hoffmann (23).

Filatoff (10), Corning (7), Salvi (48), and Dorello (9), on the other hand, describe the origin of the premandibular cavities from the wall of the fore-gut itself.

The embryos of *Perameles* (Stage I., Section I.), *Bettongia* (Stage II., Section I.), and *Macropus* (Stage III., Section I.), described above, form a series of stages in which we can trace the origin of a pair of outgrowths clearly corresponding with the premandibular somites of Selachians and Reptiles, arising, as in lower Vertebrates, from a prechordal plate, and connected in *Macropus* by a transverse bridge.

This prechordal plate is not yet developed in a stage of *Perameles* preceding the first described in the present paper, but there is present in early stages of *Perameles* the massive protochordal plate described by Wilson and Hill (63). The protochordal plate from the first shows evidence of active growth power, and gives rise to the pre-oral gut (Seessel's pocket), and to the upper portion of the oral plate. It seems evident that it also gives rise to the prechordal plate in *Perameles*, for continuity is retained between that structure and the wall of the fore-gut derived from protochordal plate in Stage I. (fig. 1), and again between the prechordal plate and Seessel's pocket in Stage IV. (fig. 6).

The history of the protochordal plate has been fully described in the dog by Bonnet (6), who points out that here it gives rise not only to a portion of oral plate, but also to the "pre-oral entodermal pouch" and to mesoderm. He homologises the "interepithelial cell-mass" of Rex (47) with the protochordal plate, and points out that the difference in the various accounts of the development of the premandibular head cavities refer only to their mode of origin from the "interepithelial cell-mass."

The above account of *Perameles* agrees closely with that given by Bonnet (6). The pre-oral entodermal pouch of Bonnet (6) and Dorello (9), the interepithelial mass of Rex (47), the præchordal Platte of Oppel (40), the Zwischenplatte of Filatoff (10), as well as the unnamed mass of cells described by Platt (42, 43) and others as the point of origin of premandibular somites, all alike represent derivatives of the protochordal plate. Moreover, as the wall of the anterior angle of the fore-gut is also a derivative of the protochordal plate, the origin of premandibular somites directly from the fore-gut, as described by Corning (7) and Salvi (48), may readily be interpreted on the same lines, for in either case the ultimate source of the premandibular somites and their connecting bridge is the protochordal plate.

Attention may here be drawn to a possible interpretation of the structure described and figured by Selenka in *Didelphys* (55) under the name of "Gaumentasche." This structure he regards as the branched and hollow anterior end of the chorda. In a later paper (56) he states that he has observed a similar structure in the chick and the duck, as well as other Vertebrates. I have found no trace of such a branched gland as he describes in an embryo of *Didelphys virginiana* (8.5 mm. G.L.) in Prof. Hill's collection which I have examined. Selenka's fig. 16, plate xxx. (55), shows so close a resemblance to the condition described and figured in *Perameles nasuta* (Stages I. and IV., Section I., figs. 1 and 5) as to suggest that the "Gaumentasche" which he observed is nothing more than a prechordal plate in continuity with a well-developed Seessel's pocket.

With regard to the relations of the anterior end of the chorda to the fore-gut and Rathke's pouch, a number of observers have described the apex of the notochord as being in continuity with the hypophysis in birds (Mihalkovics, 33), and in Eutheria (Bonnet, 6; Woerderman, 64; and Miller, 35). This condition is purely secondary, and my own observations lend not the slightest support to the view of Miller that the notochord makes a considerable contribution to the developing hypophysis.

The primitive relation of the anterior end of the chorda is one of continuity with the protochordal plate. The subsequent history can be

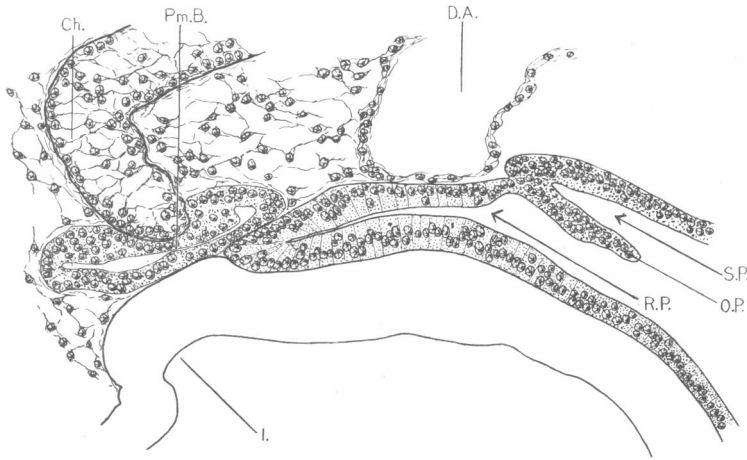


FIG. 42.—*Squalus acanthias* (14 mm. embryo). Median longitudinal section (reconstructed) through the hypophysis and chorda. Sl. 1-4-2-9.

Ch., chorda; D.A., dorsal aorta; I., primitive infundibular recess; O.P., oral plate; Pm.B., bridge connecting premandibular head cavities; R.P., Rathke's pouch; S.P., Seessel's pocket.

clearly followed in stages of *Perameles*, for, as the various derivatives of the protochordal plate become established, the chorda retains its continuity therewith until we get the condition shown in figs. 5 and 6 in which the notochord is continuous with the prechordal plate and this again with Seessel's pocket. In forms in which a transverse premandibular canal is developed, the continuity between chorda and pre-oral gut is of necessity interrupted, so that the primitive condition is transient. Moreover, the hypophysis at this period grows rapidly backwards, while Seessel's pocket, at the same time, in most Vertebrates degenerates. It will be readily seen that this would produce, in a stage immediately succeeding *Perameles*, Stage IV. (fig. 5), a condition of contact of Rathke's pouch with the prechordal plate or with a "bridge" connecting the premandibular somites.

This latter condition occurs in Selachians (fig. 42), and is described by van Wijhe (62). In Eutheria, in which neither a definite prechordal plate nor a bridge connecting premandibular somites has been described, the notochord naturally comes into contact with Rathke's pouch, and in some cases—pig, Miller (35), Woerderman (64); dog, Bonnet (6)—there is temporarily established a continuity between the two structures.

II. *Seessel's Pocket (Pre-oral Gut).*

In 1877, Seessel (54) first described in the chick a small diverticulum of the gut wall, lying posterior to the hypophysis and in such close contact therewith that its lower concave surface lies exactly on the upper convex surface of the hypophysis. He states that it has a narrow funnel-shaped cavity and a wall of radially placed cylindrical cells, of the same thickness as the hypophysis wall. The reduced remnant of this structure he observed at a later stage as a short diverticulum attached to the duct of the hypophysis.

Seessel's pocket has been described by Nusbaum (39) in the dog as occurring immediately behind a fold which separates it from the hypophysis. In 80 per cent. of the dog embryos examined by Nusbaum, Seessel's pocket comes into close relation with the hypophysis. The lower portion is connected with the pharyngeal epithelium, and contains a small lumen. The distal half breaks up into several cell-groups, one of which passes, in part at least, into the wall of the hypophysis, while the rest of Seessel's pocket disappears completely. Nusbaum regards these facts as evidence that Seessel's pocket and the hypophysis are both parts of one and the same structure, viz. an ancestral communication between the pharynx and the exterior, similar to the unpaired naso-hypophysial duct of Myxinoids.

A portion of pre-oral gut has also been recognised by Bonnet (6) in the dog, and by numbers of other workers in various Vertebrates. Salvi (50), in a detailed study of the pre-oral gut of birds, describes the formation of a succession of "intestinal vertices" of which the tertiary one represents Seessel's pocket. The obliteration of this gives rise to the final "quaternary intestinal vertex." He also describes (48) intimate relations between the pre-oral gut, premandibular somites, and the hypophysis, but does not find any contribution from the entoderm of Seessel's pocket to the hypophysis.

This participation of the entoderm of Seessel's pocket in the formation of Rathke's pouch has also been described by von Kupffer (30) and Saint-Remy (52).

In the Marsupials which I have examined, Seessel's pocket is of common occurrence. In *Dasyurus* it is very small and variable in its relations,

(cf. Stage III. of *Dasyurus viverrinus*, Section I. of this paper), but in this species, as the hypophysis deepens and closes, Seessel's pocket disappears, leaving no trace.

In *Trichosurus*, Seessel's pocket bears relations to the hypophysis similar to those described by Seessel for the chick. It forms a small conical diverticulum, separated from Rathke's pouch by a remnant of oral plate; and, as the posterior end of the hypophysis is slightly bilobed, Seessel's pocket lies between the lobes. (*Trichosurus*, Stage I.) In the process of narrowing of the mouth of Rathke's pouch, the posterior point of constriction is situated behind the opening of Seessel's pocket (fig. 17), so that that structure becomes included in the hypophysial duct and forms for a time a small pocket-like diverticulum on the posterior side of the duct. This subsequently disappears, and it cannot definitely be said that it contributes actively to the formation of the hypophysis, for it is merely continuous with the duct, which is itself destined to disappear. It is perfectly clear, however, that the insertion of the oral plate, which marks the point of junction of ectoderm and entoderm, comes to be situated within the tissues of the hypophysis, which accordingly cannot be regarded as of exclusively ectodermal origin.

In *Perameles* a well-developed Seessel's pocket is present in one stage (*P. nasuta*, Stage IV. of Section I.). It arises undoubtedly from the region of the fore-gut derived from the protochordal plate, and is directly continuous with the remnant of the prechordal plate. In subsequent stages, however, all trace of Seessel's pocket has disappeared.

In *Phascolarctos* and *Phascolomys* we find the most remarkable development of Seessel's pocket. In *Phascolarctos*, Stage III., it appears at first sight to form a third median lobe of the bilobed caudal portion of the hypophysis, and its identity is only clear from the fact that it arises posterior to the oral plate. The constriction of Rathke's pouch then occurs in such a manner that Seessel's pocket is included in the hypophysis, and, instead of degenerating as it does in other cases, it persists as a portion of the pars buccalis. Up to a relatively late stage it is recognisable as a flattened vesicle lying on the ventral surface of the hypophysis, and in several embryos its original relations to the caudal bifid extremity of Rathke's pouch are retained, so that sections through the hinder end of the hypophysis in the last stage of *Phascolarctos* described above bear a very close resemblance to those of the third stage (fig. 34). In some cases Seessel's pocket has the appearance of being an integral part of the hypophysis (fig. 38), whereas in other cases its walls are completely separated by connective tissue from the rest of the pars buccalis and it retains to some extent its own identity. In later stages, however, it

appears simply as a slightly differentiated tubule or lobe of the hypophysis.

In *Phascolomys*, again, we find a well-developed Seessel's pocket which, like that of *Phascolarctos*, becomes included in the buccal portion of the hypophysis. In early stages of *Phascolomys* (fig. 39) Seessel's pocket forms a long, conical diverticulum, opening on to the posterior face of the hypophysial duct. The walls are slightly less regular than those of Rathke's pouch, and its cells are distinguishable from those of the hypophysis by reason of their greater staining capacity.

We have thus undoubted evidence that Seessel's pocket in at least two Marsupials (*Phascolarctos cinereus* and *Phascolomys mitchelli*) actually enters into the composition of the pars buccalis of the pituitary body, whilst in *Trichosurus* a doubtful amount of entoderm is included in the hypophysis.

Professor Hill has drawn my attention to the fact that in an *Echidna* embryo in his collection there is a well-developed Seessel's pocket. From Professor Hill's graphic reconstruction of this embryo it is clear that Rathke's pouch has just formed; the oral plate is ruptured, and behind it is a conical diverticulum, slightly longer than the hypophysis. Whether this structure subsequently degenerates in *Echidna* or forms part of the hypophysis is unknown. The condition in the above-mentioned embryo closely resembles that in *Phascolarctos*, Stage II., 7.5 mm., in which, however, the hypophysis is further advanced and is accordingly slightly longer than Seessel's pocket.

The occurrence of such a well-developed Seessel's pocket in Monotremes and Marsupials and its inclusion in the hypophysis in *Phascolarctos* and *Phascolomys* is remarkable, and its significance is uncertain. It must be admitted as a possibility that the inclusion of the pre-oral gut in the pars buccalis indicates nothing more than a slight variation from the normal Vertebrate method of closure of the hypophysial pouch. Further observations are necessary to prove how frequently the phenomenon occurs in other groups of Vertebrates.

In connection with the discussion as to the fate of Seessel's pocket, it may be well to make a brief reference to the pharyngeal bursa, a structure of doubtful significance, which has been identified with Seessel's pocket by some workers (Meyer). This structure was first described by A. J. C. Mayer (31) in 1840, and has since been discussed by Killian (28), Grünwald (17), Meyer (32), Huber (24), and others. Huber, in a full discussion on the subject, decides against Meyer's theory that the pharyngeal bursa is merely a persistent Seessel's pocket, on the ground that the two structures are separated by almost the whole length of the future pharyngeal vault;

and the same objection applies to the suggestion that the pharyngeal bursa is a persistent hypophysial duct.

I have not been able to find any trace of a pharyngeal bursa in any Marsupial embryo which I have studied; but if such a bursa is present at any stage in Marsupials, it cannot be derived from Seessel's pocket, as that structure either degenerates completely or becomes part of the hypophysis; neither can it represent a persistent hypophysial duct, as that retains for some time its relations to the hypophysis and then disappears completely.

III. *The Formation of Rathke's Pouch.*

An excellent historical note on the pituitary body is given by Herring (22) in a recent paper, and it is unnecessary to recapitulate here the many different views that have been held as to the ontogenetic and phylogenetic origin of the hypophysis. Rathke (46), in 1838, was the first to describe the origin of the anterior lobe of the pituitary from a pouch-like ingrowth. Subsequent work has established the ectodermal origin of this structure beyond question.

In early stages of *Dasyurus* described above, we see the exact relations of Rathke's pouch to the fore-gut and oral plate. In Stages I. and II. the oral plate (figs. 8 and 9, O.P.) is still complete, and in the former there is as yet no indication of the formation of the hypophysis. In Stage II. no definite invagination has taken place, but the hypophysial epithelium is differentiated, and this differentiation affects a small portion of the ectoderm of the oral plate. In the next stage the oral plate is ruptured (fig. 10), but a considerable remnant of it persists. Instead of lying, as it does in the preceding stage (fig. 9), in approximately the same line with the ectoderm of the head, it has become bent forwards so as to form an acute angle therewith. The wall of the fore-gut, which in Stage II. lies in contact with the brain floor, has ceased to do so in Stage III., and a mass of cells, possibly representing a head somite, lies above it (figs. 10 and 11). The modified stretch of epithelium now forms a shallow pouch with its dorsal wall pressed closely against the brain floor. It is evident that the apex of the pouch has grown actively backwards, for in Stage II. (fig. 9) it lies anterior to the infundibular depression, whilst in Stage III. it lies immediately below it. The posterior limitation of the pouch is brought about partly by the backward growth of this apex, and partly, as stated by Mihalkovics (33) and Kraushaar (29), by the forward bending of the oral plate. This movement of the oral plate does not, however, appear to be a purely mechanical result of its rupture, for in *Perameles nasuta* (Stage IV.), in which the oral plate is still complete, there is a

distinct forward projection thereof, close to its dorsal insertion (fig. 5, P.), and this projection forms the posterior wall of Rathke's pouch. The anterior and lateral folds limiting the pouch are simply the result of the active growth of the epithelium of the pouch. Lying as it does with one wall in close contact with the brain, the natural result of active growth and division of the cells is firstly to increase the area in contact with the brain, and secondly to produce round this area folds, or lips, thus converting the structure into a shallow pouch. Stage III. of *Dasyurus* (fig. 12) shows a further result of this growth in the deepening of the pouch posteriorly.

That the chorda does not in Marsupials play a mechanical role in drawing Rathke's pouch inwards is self-evident from the fact that it stops some way behind the hypophysis in most cases, and is never in actual contact therewith.

As Herring (22) remarks, the close contact between the hypophysial epithelium and the infundibular depression in these early stages is doubtless of importance in bringing about the development of a definite pouch. In most of the early stages there is evidence of very active growth at the lateral angles of the pouch (fig. 7), and it is clear that rapid growth at these points will tend of itself to bring about a deepening of the pouch.

The narrowing of the mouth of the pouch requires a different explanation. Müller (36) put forward the theory that this was due to the pressure of the internal carotid arteries. Mihalkovics (33) and Kraushaar (29) both regard it as due to the development of the primordium of the skull. In Marsupials there are no blood-vessels in a position to cause the narrowing of the mouth of the pouch, and, as far as it seems possible to give any explanation of this phase of development, that given by Mihalkovics and Kraushaar is probably correct, for the narrowing of the opening of the pouch and its final reduction to a slender duct occur contemporaneously with the condensation of the mesenchyme which ushers in the formation of the cartilage of the skull.

The appearances of transverse sections through Rathke's pouch in early stages, such as are shown in figs. 7 and 30, are exceedingly suggestive of a bilobed origin of the hypophysis; whilst in Stage I. of *Phascolarctos* the condition is even more marked, the epithelium in the middle line being remarkably thin. The activity of the cells of the lateral angles of the pouch is indicated, in most of the early stages which I have examined, by such appearances as are shown in fig. 7. Moreover, these lateral angles tend to be prolonged backwards beyond the median portion of the pouch, thus giving rise to a distinctly bilobed caudal extremity. In *Trichosurus*, and more especially in *Phascolarctos*, this branching of the pouch may be

due to the presence of a median Seessel's pocket, indenting the posterior wall of Rathke's pouch. In *Trichosurus* the caudal bifurcation persists and even becomes more marked after Seessel's pocket has become a mere remnant attached to the duct, and the conical infundibular process, which is just appearing, lies between the two halves.

It is impossible to say at present whether this bilobed condition indicates the origin of Rathke's pouch from a structure consisting of two symmetrical portions. On the whole, it seems more probable that it is merely due to three independent factors, viz. active growth and multiplication of the cells at the angles of the pouch, the pressure of Seessel's pocket on the middle line of the posterior wall of the pouch, and the subsequent protrusion of the infundibular process into the same position.

It may be noted that Gaupp (13) and Salvi (48) have described a three-fold origin of the hypophysis in Reptiles, but the lateral lobes in this case probably represent nothing more than an early establishment of the primordia of the *pars tuberalis*.

IV. *The Later Development of the Hypophysis cerebri.*

The development of the hypophysis subsequent to the establishment of Rathke's pouch consists in the outgrowth and differentiation of the infundibular process, and in the conversion of the simple thin-walled buccal pouch into the various regions characteristic of the *pars buccalis* of the adult, viz. the solid glandular *pars distalis*, the *pars infundibularis*, and the *pars tuberalis*.

(a) *The Development of the Pars buccalis.*

1. *Development of the Pars juxta-neuralis.*—The separation of the primordium of the *pars tuberalis* occurs in Marsupials at a very early stage, and this fact gives confirmation to the view of Tilney (59) that the *pars tuberalis* and *pars infundibularis* constitute two distinct morphological elements in the *pars juxta-neuralis*.

According to Tilney (59), the *pars tuberalis* in the adult cat, dog, rabbit, rat, sheep, and fowl "is moulded to the base of the brain in such a manner that the saccular eminence of the tuber cinereum rests in it as one saucer in another" (Tilney, 59, p. 263), whilst a median aperture in the *pars tuberalis* admits of the passage of the infundibular process. With regard to its ontogeny, he describes in a 14-mm. cat embryo the appearance of a pair of processes from the lateral borders of the dorsal surface of the buccal pouch in the region where the neck of the pouch joins the body. These are destined to form the *pars tuberalis*, and he accordingly calls them tuberal

processes. They grow up towards the brain, and also extend both posteriorly and anteriorly, to fuse eventually and form a continuous structure lying between the tuber cinereum and the pars distalis. In the chick of 5 days, 20 hours he describes the origin of tuberal processes "near the cephalic pole of the body of the pituitary anlage."

Although Tilney alone has clearly recognised both the origin and fate of this portion of the hypophysis, it seems probable that certain structures described by other authors may prove to be identical with it. Thus Mihalkovics (33) and Kraushaar (29) have described the development of a solid process arising from the lower end of the hypophysial sac and growing forwards towards the optic chiasma. Salzer (51) has given special attention to the subject, and finds that in the pig there is an epithelial thickening which corresponds to the process described by Mihalkovics (33) in the rabbit, and by Kraushaar (29) in the mouse. This sends forwards "towards the chiasma" a process consisting of glandular substance. Salzer states also that he finds a similar anterior process in the guinea-pig.

Herring (21 and 22) describes "a tongue-like process of the pars intermedia" in the cat and monkey, and from his figures it seems probable that this structure is the anterior portion of the pars tuberalis. (Compare figs. 2 and 5 of Herring (21) with Tilney's (59) longitudinal sections, figs. 1, 2, 5, 7, 9, etc.) With regard to the development of this portion, Herring (22) states that the neck of the hypophysial sac retains a tubular character for some time and becomes somewhat convoluted. "One of these convolutions applies itself to the under surface of the brain and gives rise to the tongue-like process which extends forwards from the anterior lobe towards the optic chiasma": Herring (22, p. 171).

Baumgartner (4), in a description of the development of the hypophysis in turtles, describes the presence in an early stage (5-mm. embryo) of a main pouch and two lateral buds. The free ends of these lateral buds grow forwards and dorsalwards, and later their distal portions become wing-like and extend forwards beneath the brain floor, whilst their proximal parts lateral to the anterior lobe are crescentic in transverse section. In the newborn animals the lateral lobes have fused across the median line, whilst their crescentic, proximal portions are united by outgrowths of their free edges both dorsally and ventrally around the "anterior lobe," so that this latter is enveloped by the layer so formed. This description probably refers to a pars tuberalis such as is described by Tilney (59), and having an origin similar to that described for Marsupials.

It may further be noted that Baumgartner's description affords an explanation of the threefold origin of the hypophysis described by Gaupp

(13) and Salvi (48) in Reptiles. Baumgartner finds a median pouch developed first, followed by two lateral buds. Gaupp (13) similarly describes three invaginations, the two lateral ones forming elongated slit-like depressions separated from the median one by fairly considerable folds in which lie a pair of veins (*cf.* fig. 33). In later development, the three invaginations deepen and become simultaneously nipped off from the mucous membrane. The lateral lobes separate from the median and may degenerate, but Gaupp finds in almost adult lizards two groups of cells, apparently derived therefrom, actually embedded in the walls of the diencephalon. These groups of cells may represent a displaced *pars tuberalis*.

Salvi (48) describes similar lateral primordia in Reptiles, but does not trace their subsequent history. On the ground of a connexion between these structures and the premandibular somites, he regards the lateral pits as equivalent to the ectodermal invaginations of a pair of gill slits. The development of the premandibular somites in Marsupials lends no support to the theory that they represent gill pouches, nor is there any evidence in this group in support of Salvi's interpretation of the significance of the lateral pits of Gaupp.

Comparing Gaupp's (13) and Salvi's (48) accounts with that of Baumgartner (4), and with the mode of development of the *pars tuberalis* in Marsupials, it seems probable that the threefold origin described by Gaupp and Salvi may prove to represent an early differentiation of the primordium of the *pars tuberalis*.

The development of the *pars tuberalis* in Marsupials is perfectly clear. In quite early stages the portion of Rathke's pouch lying posterior to the duct becomes subdivided into two lobes, which are respectively distal and proximal in relation to the hypophysial duct, and are separated from each other by a horizontal constriction. While the distal lobe thickens and forms the glandular tissue of the *pars buccalis* as well as the *pars infundibularis*, the proximal lobe remains thin-walled. It becomes drawn out laterally, and early becomes crescentic in transverse sections. (Compare figs. 18, 20, 21, and 26.) Its lateral borders enlarge and curve up towards the dorsal side of the *pars buccalis* (figs. 26, 37). These wing-like structures are prolonged anteriorly considerably beyond the main body of the proximal lobe. In subsequent stages the median portion of this lobe becomes greatly reduced, loses its lumen, and fuses with the ventral surface of the distal lobe, whilst the enlarged lateral portions grow up towards the brain floor. Finally they branch and form a collection of flattened tubules which, increasing greatly in number, extend first anteriorly and meet and fuse in the middle line in front of the infundibular process,

whilst later they penetrate to the caudal side of that structure and thus come to form a complete ring around it.

Up to the latest stage which I have studied (*Trichosurus*, Stage XI., fig. 29), the *pars tuberalis* consists of hollow, flattened tubules with thin walls for the most part only one cell in thickness, and consisting of cubical epithelial cells. No variation in staining capacity is evident in these cells.

From the above summary it becomes clear that the *pars tuberalis* takes its origin at a very early stage from Rathke's pouch. In Reptiles, if my interpretation of Baumgartner's and Gaupp's descriptions is correct, it arises from a pair of hollow outgrowths which are at first separate from the main median hypophysial invagination. The three primordia become simultaneously nipped off from the buccal ectoderm, thus acquiring a common duct. In the Marsupials, the narrowing of the mouth of the pouch takes place before the differentiation of the tuberal primordium, but this is still a hollow outgrowth whose subsequent history clearly shows its homology with the lateral invaginations described by Baumgartner (4). In the Eutheria, according to Tilney (59), the *pars tuberalis* is derived from a pair of solid processes arising from the point of junction of the neck and body of the hypophysis, this being also the position of the proximal (tuberal) lobe in Marsupials.

The development of the *pars infundibularis* shows no point of special interest. The postero-dorsal wall of Rathke's pouch represents the primordium of this portion. Unlike the rest of the distal lobe, it never thickens markedly, but on the contrary, as development proceeds, becomes reduced to a thin and very regular layer of epithelium. The infundibular process as it grows downwards indents it from above, and during the growth of the hypophysis as a whole the *pars infundibularis* spreads round in all directions, so that it eventually comes to cover the infundibular process on its anterior and lateral sides, and to a certain and variable extent on its posterior face. It is noticeable that in the Marsupials the thin epithelium of the *pars infundibularis* forms not only the layer in contact with the *pars neuralis*, but also extends beyond this, forming the ventral wall of the anterior and posterior angles of the residual lumen (*cf.* fig. 27), and the dorsal wall of its lateral horns (fig. 28).

With regard to the time of penetration of connective tissue between the buccal and neural portions of the hypophysis, various statements have been made. As noted by Herring (22) and Salzer (51), in the initial stages these two parts are in intimate contact. In a *Trichosurus* embryo of 8.5 mm. G.L. (Stage V.), connective tissue has penetrated between the primordia of the *pars neuralis* and the *pars buccalis*. This connective

tissue is derived from the pia mater, and not, as would be supposed from Stendell's (57) description and figure (fig. 17), from the dura mater.

In the final stages of development (Trichosurus, Stage XI.) some of the cells of the pars infundibularis become carried by growth and penetration of the connective tissue into the substance of the pars neuralis, while the remainder form a thin epithelial layer surrounding that structure.

2. *Development of the Pars distalis.*—In the Marsupials which I have studied, two methods of conversion of the walls of Rathke's pouch into the glandular pars distalis may be observed. Of these methods, that observed in Phascolarctos is probably the more primitive, and will accordingly be dealt with first, that of Trichosurus being more specialised. In both cases the cells of the walls of the distal lobe of Rathke's pouch multiply freely except in the region of contact with the developing infundibular process. In both cases also there is produced from the posterior half of the pars buccalis a pair of large, dorso-lateral outgrowths into which a narrow cleft-like lumen extends. (*Cf.* fig. 22, in which, however, the actual section figured passes not through the lumen but through the solid wall.) In Phascolarctos capillaries supplying the pars distalis enter by the ventral cleft between this lateral wing-like process and the median lobe. I have not been able to ascertain with certainty whether this is the case in Trichosurus or not, though a large amount of connective tissue undoubtedly penetrates at these points. It therefore seems possible that the separation of these lobes by a pair of ventral clefts merely serves to afford a point of entry for connective tissue and blood-vessels.

In Phascolarctos, the rapid multiplication of the cells of the walls of Rathke's pouch results in the outgrowth of numerous processes from the outer surfaces of the walls. These are at first short and rounded, but soon become longer; their extremities enlarge and in some cases acquire a lumen (*cf.* fig. 36). They increase rapidly in number, so that the pars distalis comes to consist of a mass of tubules and cell cords, separated from one another by connective tissue which, from the nature of the process of development, inevitably becomes included in the walls.

Although in Phascolarctos, Stage VIII. and in the following stages, as well as in Phascolomys, the very rich vascularity of the pars buccalis is noticeable, there is no indication of sinusoidal development such as Herring (22) describes in the pig. In earlier stages there are blood-vessels lying in close proximity to Rathke's pouch, but these do not penetrate until Stage V., and at no stage is there any indication of the processes from the walls of Rathke's pouch growing into the blood-vessels and pushing the endothelial walls before them as described by Herring (22). On the contrary, several definite points of penetration of the capillaries into the substance of

the pars distalis can be recognised, viz. the ventro-lateral clefts as already mentioned and the posterior wall of the pars distalis.

It seems, therefore, that in *Phascolarctos* there occurs, contemporaneously with the outgrowth of processes from the walls, a certain amount of ingrowth of connective tissue, and more especially of blood-vessels.

Salzer (51) describes a similar condition in the pig, and draws attention to the fact, which is true also of *Phascolarctos*, that the lumina of the tubules arise entirely independently of the main lumen. Mihalkovics (33) in the chick, and Kraushaar (29) in the mouse, both describe the formation of tubules simply by outgrowth from the wall of the buccal pouch.

In *Trichosurus*, on the other hand, the walls of Rathke's pouch thicken considerably, so that the lumen is much reduced; but up to Stage VII. the walls retain their original compact form, with a regular, unbroken outline. The process of "tubule" formation then begins, and is ushered in by the ingrowth of connective tissue strands at a number of points. The cells of the wall then gradually become grouped so as to form lobules and cell-cords, but in no stage in *Trichosurus* do these acquire a lumen. By further ingrowth of connective tissue, and by a process of grouping and rearranging of the cells, the pars distalis of *Trichosurus* acquires a glandular structure. As might be expected from the difference in the mode of development, the pars distalis in *Trichosurus* is throughout its history a very much more compact structure than that of *Phascolarctos*.

A similar process of gland formation by ingrowth of connective tissue was described by J. Müller (36) for the pig; but, according to Salzer's (51) very full and careful description, outgrowths of processes from the wall also play a large part in the development of the hypophysis of this Mammal.

It would be natural to assume that the primitive mode of elaboration of a glandular structure such as the pars distalis is that of the formation of outgrowths, probably hollow, from the walls of a simple pouch. The tubules thus formed would, as they increase in number, become pressed together until they constitute a relatively compact gland. In the adult hypophysis in Mammals the tubular structure is almost entirely lost (*cf.* Herring, 22), and there seems to be a tendency to omit in development the stage of formation of hollow outgrowths.

In the Mammalia both the process of outgrowth and that of penetration of connective tissue occur contemporaneously, and the Marsupials which I have studied form a well-graduated series in this respect. In *Phascolarctos* and *Phascolomys* the process of formation of outgrowths from the walls of Rathke's pouch undoubtedly plays a markedly preponderating part in development, while ingrowth of connective tissue occurs to a relatively slight extent. In early stages in *Dasyurus*, outgrowths form on the walls,

but they are neither so numerous nor so long as those in *Phascolarctos* and *Phascolomys*. In *Trichosurus* and *Perameles* outgrowths of the walls play but a very small part, the adult condition of compactness being attained by a far less circuitous method by direct increase in thickness and by contemporaneous rearrangement of the constituent cells of the walls as cell-cords or lobules.

In this connection it may be noted that whilst in Stage V. of *Phascolarctos* the bulk of the *pars distalis* consists of definite tubules, the lumina of these is lost for the most part, if not entirely, in later stages.

Embryological evidence thus agrees with the facts of comparative anatomy, for the anterior lobe in lower Vertebrates consists simply of a greater or less number of branching tubules (Stendell, 57, figs. 63, 65, 66), and we may conclude that the *pars buccalis* of the Mammals also arose as a branched tubular gland which in the course of evolution became more and more compact until it has in some cases lost, even in ontogeny, all trace of the process by which it has developed.

3. *Histological Differentiation of the Pars distalis.*—The final stage in the development of the *pars distalis* is the process of histological differentiation. In embryological material not stained for special histology, it is naturally impossible to follow this process in great detail, and it was not my original attention to deal with this subject at all. It may, however, be noted that in later stages in all the types examined the cells of the *pars distalis* exhibit a very conspicuous differential staining capacity (see figs. 27, 28, 29, 40, and 41). The bulk of the *pars distalis* in these stages consists of cells with oval or spherical nuclei and cytoplasm which stains a typical hæmatoxylin blue. Amongst these occur a few cells with spherical nuclei and cytoplasm which stains bright red. These two types of cells appear to represent respectively the "chromophobic" and "chromophilic" cells described by Flesch (11) and referred to by Herring (21). Herring (*loc. cit.*) himself describes three types of cells: one small and non-granular, the second larger, with granulated cytoplasm, and thirdly, the deeply staining type. I have not observed any cells which correspond with this second granular type, and merely record the occurrence of the chromophilic cells for the purpose of indicating the stage at which they first appear, viz. in *Trichosurus*, Stage X. (11 mm. H.L.); *Phascolarctos*, Stage IX. (9.5 mm. H.L.); *Dasyurus*, Stage H. (13.5 mm. G.L.). It may also be noted that in all the cases in which these chromophilic cells can be observed they are most numerous in the posterior portion of the *pars distalis*.

Neither the time of appearance of these cells nor their mode of origin, scattered as they are in the substance of the hypophysis, nor any other facts in development in Marsupials, lend any support to the view of Miller

(35) that the existence of two histologically distinct types of cells in the "anterior lobe" is due to the origin of the one group from ectoderm and the other from entoderm (head of the notochord).

The Fate of the Lumen.—With increase of thickness of the walls of the buccal pouch, the lumen naturally becomes reduced, and in the course of reduction it passes through a variety of forms which do not seem of sufficient importance to justify a detailed description. Two distinct portions of the lumen persist up to Stage X. of *Trichosurus*: one forming the cup-shaped residual lumen surrounding the *pars neuralis*; the second, a small isolated cleft on the ventral side of the *pars distalis* (fig. 27, Lm.P.L.), representing the last trace of the median lumen of the proximal (tuberal) lobe of earlier stages. This small cleft subsequently disappears, whilst the main cavity persists in a pouch foetus of 4 cm. G.L. (Stage XI.) as a cup-shaped residual lumen.

(b) *Development of the Pars neuralis.*

In early stages of development of the brain, prior to closure, a rounded depression of the floor of the diencephalon occurs. This represents the primitive infundibular depression, and it is from the posterior angle of this that the infundibular process grows out. As already stated, I am unable at present to describe the process of development of the diencephalic floor or to identify with certainty the post-chiasmatic and post-infundibular recesses and eminences described by Tilney (60), and the development of the infundibular process is so closely related to that of the diencephalic floor that it is impossible to discuss the former satisfactorily in the absence of definite knowledge of the latter. A few points may, however, be noted.

The infundibular process itself arises as a short, conical or rounded hollow outgrowth from the diencephalic floor, and its walls for a considerable time retain the primitive character of the brain-wall in early stages of its development. Subsequently its cavity becomes reduced and the walls show some indication of differentiation into the three zones, ependymal, mantle (or nuclear), and marginal, characteristic of the developing brain-wall. Complete differentiation is, however, restricted to the neck of the *pars neuralis*, while in the distal portion cells are scattered throughout the substance of the wall, leaving no specialised marginal zone. The substance of the wall in this stage is traversed by fine fibres, probably both ependymal and neuroglial. In later stages the infundibular process enlarges considerably and its lumen becomes obliterated. The walls undergo several changes, the cells become fewer, the fibres much more conspicuous; and in the last stage which I have observed,

the connective tissue has penetrated to a considerable extent into the substance of the pars neuralis, carrying with it a few of the cells of the pars infundibularis.

V. *Note on the Relation of the Meninges to the Parts of the Hypophysis cerebri.*

In both *Trichosurus* and *Perameles* it is possible in late stages to observe the relations of the meninges to the parts of the hypophysis, and in both these types the pia mater completely invests the pars neuralis and also the pars tuberalis (fig. 13, P.M.). This statement differs from the account and diagram (fig. 17) of Stendell (57), according to which the pia mater is perforated by the pars neuralis, while the dura mater passes between the pars neuralis and the pars infundibularis. In the forms which I have examined, the dura mater constitutes a connective tissue capsule, the greater part of it passing ventral to the whole of the pituitary, while a thinner layer passes over the dorsal surface of the pars buccalis but thins out considerably as it approaches the hypophysial stalk, and is not continued between the pars neuralis and the pars infundibularis (see fig. 13). In Marsupials the pia mater does not end, as described by Stendell (57) for Vertebrates generally, at the point of origin of the infundibular process, but penetrates between this latter and the pars infundibularis.

FINAL SUMMARY.

1. In *Bettongia*, *Macropus*, *Perameles*, and *Trichosurus* there is present a pair of head cavities whose early relations and subsequent history (see Elizabeth A. Fraser (12)) show them to be premandibular somites. The origin of these structures has been traced only in *Perameles*, in which they arise from a prechordal plate which represents a derivative of the antero-dorsal wall of the fore-gut, which is formed from the protochordal plate.

2. A well-developed Seessel's pocket (pre-oral gut) occurs in some Marsupials, and in *Phascolarctos cinereus* and *Phascolumys mitchelli* forms a constituent part of the hypophysis.

3. The primitive relation of the tip of the notochord is one of continuity with the protochordal plate, and in *Perameles* continuity is retained between the chorda and the derivatives of the protochordal plate (prechordal plate and Seessel's pocket). As a secondary condition, continuity may be established between the chorda and the hypophysis.

4. The development of Rathke's pouch is due to rapid growth of the

differentiated epithelium of the hypophysial angle, and not to any mechanical power exercised by the chorda or any other structures.

5. From Rathke's pouch in Marsupials there arises a proximal lobe, at the point of junction of the duct with the body of the pouch. This forms the pars tuberalis of the adult pituitary body.

6. The glandular structure of the pars distalis (anterior lobe) of the adult is produced either by outgrowth of processes from the walls of Rathke's pouch or by ingrowth of connective tissue into the thickened walls of that structure.

7. Two types of cells, "chromophilic" and "chromophobic," are differentiated *in situ* in the pars buccalis before the adult condition is fully reached.

8. The pars neuralis arises as a hollow conical outgrowth of the diencephalic floor. It is gradually transformed into a solid, swollen lobe, and is then penetrated by connective tissue.

ADDENDUM.

Since the completion of the above, a paper has appeared on the development of the hypophysis in Reptiles by Baumgartner (*Journal of Morphology*, vol. xxviii., No. 1, Dec. 1916), who describes the origin of the pars tuberalis in a considerable number of Reptiles from lateral buds such as are described by Gaupp (13), and by Baumgartner (4) in an earlier paper. This is in agreement with the interpretation given above, according to which the lateral buds described in Reptiles are homologous with the proximal lobe found in early stages in Marsupials.

BIBLIOGRAPHY.

- (1) ANDRIEZEN, W. LLOYD, "The Morphology, Origin, and Evolution of Function of the Pituitary Body, and its Relation to the Central Nervous System," *Brit. Med. Journ.*, vol. i., 1894.
- (2) AYERS, "Vertebrate Cephalogenesis," *Journ. of Morph.*, vol. iv., 1890.
- (3) BAUMGARTNER, E. A., "The Development of the Hypophysis in *Squalus acanthias*," *Journ. of Morph.*, Sept. 1915.
- (4) BAUMGARTNER, E. A., "The Development of the Hypophysis in Turtles," *Anat. Record*, vol. x., No. 3, 1916.
- (5) BEARD, J., "The Old Mouth and the New," *Anat. Anz.*, vol. iii., 1888.
- (6) BONNET, R., "Beiträge zur Embryologie des Hundes: Erste Fortsetzung," *Anat. Heft*, Bd. xvi, Heft ii.
- (7) CORNING, H. K., "Über die Entwicklung der Kopf- und Extremitätenmuskulatur bei Reptilien," *Morph. Jahrb.*, Bd. xxviii., 1900.

- (8) CHIARUGI, G., "Di un organo epiteliale situato al dinanzi della ipofisi," *Monitore Zoologico Italiano*, anno ix., n. 2, 1898.
- (9) DORELLO, P., "Studi embriologici sui Rettili," *Ricerche fatte nel Lab. di Anat. Norm. della R. Università di Roma ed in altri Lab. biol.*, vol. vii., fasc. 3 e 4, 1900.
- (10) FILATOFF, D., "Die Metamerie des Kopfes von *Emys lutaria*," *Morph. Jahrb.*, Bd. xxxvii., 1907.
- (11) FLESCHE, *Tageblatt der 57. Versammlung deutscher Naturforscher und Aerzte zu Magdeburg, 1884*. Quoted from HERRING (21).
- (12) FRASER, E. A., "The Head Cavities and Development of the Eye Muscles in *Trichosurus vulpecula*; with Notes on some other Marsupials," *Proc. Zool. Soc. Lond.*, 1915.
- (13) GAUPP, E., "Über die Anlage der Hypophyse bei Sauriern," *Archiv für mikr. Anat.*, Bd. xlii., 1893.
- (14) GEMELLI, A., "Sur la structure de la région infundibulaire des poissons," *Journ. de l'Anat.*, vol. xlii., 1906.
- (15) GENTES, "Structure du feuillet juxta-nerveux de la portion glandulaire de l'hypophyse," *Réun. Biol. de Bordeaux*, 1903, No. 10. Quoted from TILNEY (58).
- (16) GÖPPERT, E., "Die Entwicklung des Mundes, der Mundhöhle und ihrer Organe," *Hertwig's Handbuch der vergl. u. exper. Entwicklungslehre*, Bd. ii. 1.
- (17) GRÜNWARD, L., "Eine Cyste der Chordascheide," *Anat. Anz.*, vol. xxxvii., 1910.
- (18) HALLER, B., "Untersuchungen über die Hypophyse und die Infundibularorgane," *Morph. Jahrb.*, Bd. xxv., 1898.
- (19) HALLER, B., "Über die Hypophyse niederer Placentalier und den Saccus vasculosus der urodelen Amphibien," *Arch. f. mikr. Anat.*, Bd. lxxiv., 1909.
- (20) HALLER, B., "Über die Ontogenese des Saccus vasculosus und der Hypophyse der Säugetiere," *Anat. Anz.*, Bd. xxxvii., 1910.
- (21) HERRING, P. T., "The Histological Appearances of the Mammalian Pituitary Body," *Quart. Journ. of Exp. Phys.*, vol. i., 1908.
- (22) HERRING, P. T., "The Development of the Mammalian Pituitary Body," *Quart. Journ. of Exp. Phys.*, vol. i., 1908.
- (23) HOFFMANN, C. K., "Weitere Untersuchungen zur Entwicklungsgeschichte der Reptilien," *Morph. Jahrb.*, Bd. xi., 1886.
- (24) HUBER, G. C., "On the Relation of the Chorda dorsalis to the Anlage of the Pharyngeal Bursa or Median Pharyngeal Recess," *Anat. Record*, vol. vi., 1912.
- (25) JOHNSON, C. E., "Head Somites and Eye Muscles in *Chelydra*," *Amer. Journ. of Anat.*, vol. xiv., 1913.
- (26) JOHNSTON, J. B., "The Fore-brain Vesicle in Vertebrates," *Journ. of Comp. Neur. and Psych.*, vol. xix., 1909.
- (27) KEIBEL, F., "Zur Entwicklungsgeschichte der Chorda bei Säugern (Meerschweinchen und Kaninchen)," *Arch. für Anat. u. Phys.*, *Anat. Abt.*, 1889.
- (28) KILLIAN, G., "Über die Bursa und Tonsilla pharyngea," *Morph. Jahrb.*, Bd. xiv., 1888.
- (29) KRAUSHAAR, R., "Entwicklung der Hypophyse und Epiphyse bei Nagethieren," *Zeits. für wissen. Zool.*, vol. xli., 1885.
- (30) VON KUPFFER, "Die Deutung des Hirnanhanges," *Sitzber. der Gesellschaft f. Morphol. u. Physiol. in München*, 1894.
- (31) MAYER, A. J. C., "Bursa seu cystis tubæ Eustachianæ bei einigen Säugethieren," *Neue Notizen aus dem Gebeite der Natur- und Heilkunde von Froriep*, Bd. xiv., 1840. Quoted from HUBER (24).

(32) MEYER, R., "Über die Bildung des Recessus pharyngeus medius s. Bursa pharyngea in Zusammenhang mit der Chorda bei menschlichen Embryonen," *Anat. Anz.*, Bd. xxxvii, 1910.

(33) MIHALKOVICS, "Wirbelsaite und Hirnanhang," *Arch. für mikr. Anat.*, Bd. xi., 1875.

(34) MIHALKOVICS, *Entwicklung des Gehirns*, 1877.

(35) MILLER, M. M., "The Hypophysis of the Pig," *Anat. Record*, vol. x., No 3, 1916.

(36) MÜLLER, J., "Über Entwicklung und Bau der Hypophysis und der Processus infundibuli cerebri," *Jena. Zeitschr.*, vol. vi., 1871.

(37) NEAL, H. V., "The Problem of the Vertebrate Head," *Journ. Comp. Neur.*, vol. viii., 1898.

(38) NEAL, H. V., "Segmentation of the Nervous System in *Squalus acanthias*," *Bull. of Mus. of Comp. Zool. at Harvard College*, vol. xxxi., No. 7, 1898.

(39) NUSBAUM, J., "Einige neue Thatsachen zur Entwicklungsgeschichte des Hypophysis cerebri bei Säugethieren," *Anat. Anz.*, Bd. xii., 1896.

(40) OPPEL, A., "Ueber Vorderkopfsomiten und die Kopfhöhle von *Anguis fragilis*," *Arch. für mikr. Anat.*, Bd. xxxvi., 1890.

(41) PAULISCH, O., "Das vordere Ende der Chorda dorsalis und der Frank'sche Nasenkamm," *Arch. für Anat. und Phys.*, *Anat. Abt.*, 1887.

(42) PLATT, JULIA B., "The Morphology of the Vertebrate Head," *Journ. of Morph.*, vol. v., 1891.

(43) PLATT, JULIA B., "Further Contribution to the Morphology of the Vertebrate Head," *Anat. Anz.*, vol. vi., 1891.

(44) RABL-RUCKHARD, H., "Das gegenseitige Verhältnis der Chorda, Hypophysis und des mittleren Schädelbalkens bei Haifischenembryonen, nebst Bemerkungen über die Deutung der einzelnen Theile des Fischgehirns," *Morph. Jahrb.*, vol. vi., 1880.

(45) RABL-RUCKHARD, H., "Das Grosshirn der Knochenfische und seine Anhangsgebilde," *Arch. für Anat. und Phys.*, *Anat. Abt.*, 1883.

(46) RATHKE, "Ueber die Entstehung der Glandula pituitaria," *Arch. für Anat. Phys. und wiss. Med.*, Bd. v., 1838.

(47) REX, H., "Ueber das Mesoderm des Vorderkopfes der Lachmöwe," *Morph. Jahrb.*, vol. xxxiii., 1905.

(48) SALVI, G., "L'origine ed il significato delle fossette laterali dell' ipofisi e della cavita premandibulari negli embrioni di alcuni Sauri," *Archivio Ital. di Anatomia e di Embriologia*, vol. i., 1902.

(49) SALVI, G., "Lo sviluppo ed il valore della cosi detta tasca di Seessel," *Arch. Ital. di Anat. e di Embriol.*, vol. ii., fasc. 1, 1903.

(50) SALVI, G., "L'intestino preorale degli Uccelli": Part I., *Mem. Soc. Tosc. Sc. Nat.*, vol. xix., 1903; Part II., *Mem. Soc. Tosc. Sc. Nat.*, vol. xxi., 1905.

(51) SALZER, H., "Zur Entwicklung der Hypophyse bei Säugern," *Arch. für mikr. Anat.*, Bd. li., 1898.

(52) SAINT-REMY, "Sur la signification morphologique de la poche pharyngienne de Seessel," *Compt. Rend. de la Soc. de Biologie*, 1895. Quoted from HERRING (22).

(53) SEDGWICK, A., "Notes on Elasmobranch Development," *Quar. Jour. Micr. Sc.*, vol. xxxiii., 1892.

(54) SEESSEL, A., "Zur Entwicklungsgeschichte des Vorderdarms," *Arch. für Anat. u. Phys.*, *Anat. Abt.*, 1877.

- (55) SELENKA, E., *Studien über Entwicklungsgeschichte der Thiere*, Heft iv., Zweite Hälfte, 1887.
- (56) SELENKA, E., "Die Gaumentasche der Wirbelthiere," *Biol. Centralblatt* Bd. vii., 1888.
- (57) STENDELL, W., "Die Hypophysis cerebri" in Oppel's *Lehrbuch der vergleichenden mikroskopischen Anatomie der Wirbelthiere*, Teil viii., 1914.
- (58) TILNEY, F., "Contribution to the Study of the Hypophysis cerebri, with especial reference to its Comparative Histology," *Mem. of Wistar Inst. of Anat. and Biol.*, No. 2, 1911.
- (59) TILNEY, F., "An Analysis of the Juxta-neural Epithelial Portion of the Hypophysis cerebri; with an Embryological and Histological Account of a hitherto Undescribed Part of the Organ," *Internat. Monats. für Anat. und Phys.*, Bd. xxx., 1913.
- (60) TILNEY, F., "The Morphology of the Diencephalic Floor," *Journ. of Comp. Neur. and Phys.*, vol. xxv., 1915.
- (61) TRAUTMANN, A., "Hypophysis cerebri einiger Säuger," *Arch. für mikr. Anat.*, Bd. lxxiv., 1909.
- (62) VAN WIJHE, J. W., "Ueber Somiten und Nerven im Kopfe von Vögel- und Reptilien-embryonen," *Zool. Anz.*, vol. ix., 1886.
- (63) WILSON, J. T., and HILL, J. P., "Observations on the Development of Ornithorhynchus," *Phil. Trans. of Roy. Soc. Lond.*, Series B, vol. 199, 1907.
- (64) WOERDERMAN, M. W., "Über einen Zusammenhang der Chorda dorsalis mit der Hypophysenanlage," *Anat. Anz.*, vol. xliii., 1913.
- (65) ZEIGLER, H. E., "Die phylogenetische Entstehung des Kopfes der Wirbelthiere," *Jena. Zeits. für Naturwissens.*, vol. xliii., 1907.