

Naturally Acquired *Pasteurella multocida* Infection in Rabbits: Clinicopathological Aspects

Ronald F. DiGiacomo, Yi-Min Xu, Vivien Allen, Michael H. Hinton and Geoffrey R. Pearson

ABSTRACT

A cohort of 41 New Zealand White rabbits, 35 to 60 days old, from twelve litters were followed for twelve weeks for development of pasteurellosis. Eleven of 19 rabbits in five litters acquired *Pasteurella multocida* infection. The incubation period was difficult to determine as *P. multocida* infection was detected both before and after the onset of rhinitis. The response of rabbits to infection varied from subclinical infection to death from systemic pasteurellosis. Atrophy of the maxilloturbinates of the nares was detected in rabbits with chronic rhinitis associated with *P. multocida* infection.

RÉSUMÉ

Quarante-et-un lapins New Zealand White âgés de 35 à 60 jours provenant de douze portées différentes ont été suivis pendant douze semaines afin de détecter l'apparition de pasteurellose. Onze des 19 lapins provenant de cinq portées ont développé une infection à *Pasteurella multocida*. La période d'incubation de la maladie a été difficile à déterminer puisque l'isolement de *P. multocida* a été réalisé avant et après l'apparition des signes de rhinite. Les signes cliniques de la maladie ont varié de l'infection sous-clinique jusqu'à la mort des individus. De son côté, la rhinite chronique causée par *P. multocida* s'est caractérisée par une atrophie des turbinés maxillaires des cavités nasales. (Traduit par D^r Pascal Dubreuil)

INTRODUCTION

There have been few reported studies of the natural history of *Pasteurella multocida* infection in rabbits. Aside from the classical studies of Webster (1-5), reported about 60 years previously, there are few contemporary studies (6-8). An understanding of the natural history of infection is essential to control of this disease, one of the major disease syndromes in rabbits. Hence, a prospective study was undertaken in a closed university breeding colony of New Zealand White rabbits, in which pasteurellosis was endemic (9).

MATERIALS AND METHODS

ANIMALS

For several years, the Department of Animal Husbandry, School of Veterinary Science, University of Bristol, has

had a closed breeding colony of New Zealand White rabbits (*Oryctolagus cuniculus*). The breeding colony consisted of 45 does and eight bucks. Litters were weaned at 30 days of age. Subsequently, each litter was reared together as a group. Rabbits were maintained in suspended wire cages in one building. Commercially prepared rabbit feed and water were available *ad libitum*. Twelve litters of rabbits, aged 35 to 60 days old, comprising 41 rabbits were sampled weekly for 10 to 12 weeks. At each sampling, rabbits were observed for signs of rhinitis and a deep nasal swab of the nares was obtained. Rhinitis was defined as the appearance of a mucopurulent discharge at the external nares. These litters had no evidence of *P. multocida* infection on the initial nasal swab. Procedures conformed to the Guidelines on the Care of Laboratory Animals and Their Use for Scientific

TABLE I. The development of *P. multocida* infection and rhinitis in New Zealand White rabbits followed longitudinally

Litter ID	Age at entry (days)	No. in litter	Outcome	
			<i>P. multocida</i> infection	Rhinitis
898	42	1	1	1
773	37	2	0	0
903	47	2	1	0
889	57	2	0	1
737	37	3	0	3
828	37	3	0	3
604	47	3	0	2
728	47	3	0	2
897	42	5	3	5
899	52	5	4	5
846	42	6	0	4
894	52	6	2	6
Total		41	11	32

Department of Comparative Medicine, School of Medicine, University of Washington, Seattle, Washington 98195 (DiGiacomo), Department of Pathology (Xu, Pearson) and Department of Veterinary Medicine (Allen, Hinton), School of Veterinary Science, University of Bristol, Langford, Avon, England BS18 7DU. Present address of Dr. Xu: Department of Veterinary Medicine, Jiangsu Agricultural College, Yangzhou, Jiangsu, Peoples Republic of China.

This study was supported by grants RR01203 and RR01326 from the National Center for Research Resources, National Institutes of Health, Bethesda, Maryland.

Submitted August 29, 1990.

TABLE II. Onset and duration of *P. multocida* infection and rhinitis in weanling New Zealand White rabbits

Rabbit ID	<i>P. multocida</i> infection		Rhinitis		Comments ^a
	Age at onset (days)	Duration (wk)	Age at onset (days)	Duration (wk)	
897-1	50	4 + ^b	50	4 + ^b	Died of systemic pasteurellosis
897-4	57	8 +	57	8 +	
897-2	71	6 +	57	7	Remission of rhinitis one week previously
903-2	53	7	— ^c	—	Cleared infection two weeks previously
898-1	65	6	93	2	Remission of rhinitis and cleared infection two weeks previously
894-3	79	2	72	4	Remission of rhinitis and cleared infection one week previously
894-6	128	1 +	121	2 +	
899-5	108	3 +	94	5 +	
899-2	115	3 +	87	7 +	
899-3	122	2 +	101	2	Remission of rhinitis three weeks previously
899-4	122	2 +	129	1 +	

^aInfection and rhinitis in relation to necropsy

^bPlus indicates infection or rhinitis was present at necropsy

^cRhinitis not detected

Purposes as promulgated by the Royal Society and Universities Federation for Animal Welfare.

BACTERIAL ISOLATION

The nares of rabbits were cultured weekly by inserting a swab deeply into both nasal cavities. Swabs were inoculated directly onto nutrient agar plates containing 5% defibrinated sheep blood with and without 2 µg/mL clindamycin (10). Plates were incubated aerobically at 37°C, and examined after 24 and 48 h. Isolates of *P. multocida* were identified by standard criteria, including colonial morphology and biochemical reactions (11). Characteristics of these isolates have been reported previously (12).

HISTOPATHOLOGICAL EVALUATION

All rabbits that acquired *P. multocida* infection, two other rabbits with rhinitis and four noninfected rabbits were killed by an intravenous injection of pentobarbitol sodium and necropsied. Bacterial cultures were obtained from the paranasal sinuses, after removal of the nasal bones, the middle ears and representative sections of the lungs. The upper respiratory tract was removed anterior to the orbits and fixed in 10% formic acid for decalcification. Sections of the lungs were fixed in 10% neutral buffered phosphate formalin. Following demineralization, the nares were sectioned between the incisors and pre-

molars. Sections were embedded in paraffin, cut at 5 µm and stained with hematoxylin and eosin.

RESULTS

MICROBIOLOGICAL AND CLINICAL FINDINGS

Eleven of the 41 (27%) rabbits in five of the 12 litters followed longitudinally acquired *P. multocida* infection (Table I). Two of eight litters with three or fewer littermates developed infection whereas three of four litters with more than three littermates developed infection. All litters with *P. multocida* infection, except one, exhibited rhinitis, however, all litters without *P. multocida* infection, except one, also demonstrated rhinitis. Infection was detected between 50 to 128 days of age in 11 rabbits (Table II). Ten rab-

bits exhibited rhinitis. Four rabbits developed rhinitis 0 to 28 days after the detection of *P. multocida* in the nares whereas six rabbits developed rhinitis 7 to 28 days prior to the detection of *P. multocida*. The rabbit with infection unaccompanied by rhinitis cleared infection prior to necropsy. Two additional rabbits with rhinitis had a remission of signs in conjunction with clearance of infection prior to necropsy. Except for two rabbits that had remission of signs, all other rabbits had both *P. multocida* infection and rhinitis at necropsy.

NECROPSY FINDINGS

Of the 11 rabbits that acquired *P. multocida* infection, three rabbits had no detectable nasal infection at necropsy whereas eight still had nasal *P. multocida* infection (Table III). Of

TABLE III. Infection with *P. multocida* and disease of the upper and lower respiratory tract in New Zealand White rabbits at necropsy

Nasal <i>P. multocida</i> infection	N	Nares		Paranasal sinuses		Middle ears		Lungs	
		Infect	Exudate	Infect	Exudate	Infect	Exudate	Infect	Consol
Never infected	4	0	0	0	0	0	0	0	0
Past infection	3	0	0	0	0	1	1	0	0
Current infection	8	8	6 ^a	7	5 ^b	2	2 ^c	2	2 ^c
<i>S. aureus</i> infection	2	0 ^d	2	0 ^d	2	0	0	0	1

^aFive bilateral, one unilateral

^bOne bilateral, four unilateral

^cBoth bilateral

^d*S. aureus* recovered from the nares and paranasal sinuses of both rabbits

Infect = Infection

Consol = Consolidation

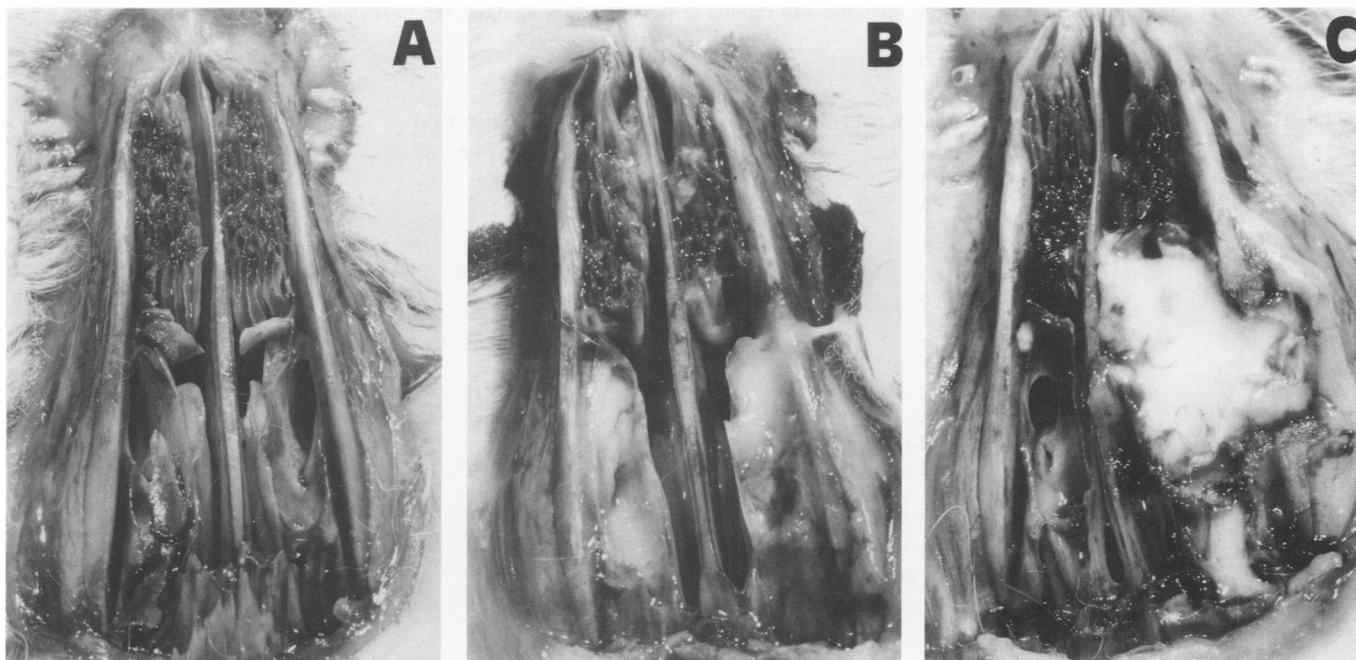


Fig. 1. Frontal section of the upper respiratory tract after removal of the nasal bones in New Zealand White rabbits at necropsy. **A.** Normal (rabbit without *P. multocida* or *S. aureus* infection); **B.** Rabbit with *P. multocida* infection (mucopurulent exudate in nares and paranasal sinuses with atrophy of maxilloturbinates); **C.** Rabbit with *S. aureus* infection (purulent exudate in nares and paranasal sinuses with atrophy of maxilloturbinates and unilateral erosion of the nasal bone).

TABLE IV. Histopathological findings in the upper respiratory tract of New Zealand White rabbits in relation of *P. multocida* and *S. aureus* infection

Nasal <i>P. multocida</i> infection	N	Histological findings in the upper respiratory tract ^a										
		Luminal exudate		Epithelial hyperplasia		Mucosal inflammation		Turbinate atrophy		Periosteal fibroplasia		
		No.	Score	No.	Score	No.	Score	No.	Score	No.	Score	
Never infected	4	0	0	0	0	0	0	0	0	0	0	0
Past infection	2 ^b	0	0	1	1	0	0	0	0	0	0	0
Current infection	7 ^b	5	1-3	4	2-3	4	1-2	4	1	3	1-2	
<i>S. aureus</i> infection	2	2	2-3	2	2-3	2	1-3	2	1	1	2	

^aNumber with findings (No.) and range of severity (Score). Score: 0 = absent, 1 = mild, 2 = moderate, 3 = severe

^bHistopathology on one rabbit each not performed

the three rabbits with past infection, one had unilateral otitis media due to *P. multocida*. Of the eight rabbits with current infection, most had mucopurulent rhinitis, accompanied by mucopurulent sinusitis due to *P. multocida* infection (Fig. 1). Fewer rabbits had otitis media and pulmonary consolidation due to *P. multocida*. Four rabbits from four litters (litter ID 728, 737, 773, 889) that never developed detectable *P. multocida* infection were necropsied. No evidence of *P. multocida* infection or disease of the respiratory tract was detected at necropsy. Two rabbits from two litters (litter ID 604, 828) which never developed *P. multocida* infection were necropsied because of severe rhinitis of three

and six weeks duration (Fig. 1). *Staphylococcus aureus* was recovered from the exudate in the nares and paranasal sinuses of both rabbits (Table III).

MICROSCOPIC FINDINGS

In the never infected group the nasal mucosa and turbinates were normal (Table IV). The epithelium varied from simple cuboidal to pseudostratified columnar epithelium at the tip of the turbinates with only a few scattered mucus secreting cells (Fig. 2). It was supported on a delicate vascular lamina propria with occasional lymphoid cells. The edges of the turbinate bones were smooth with a flattened periosteum. The histological findings

were similar in rabbits with previous *P. multocida* infection (Table IV). In rabbits with current *P. multocida* infection there was a bilateral luminal exudate in the nasal cavity of most rabbits consisting of viable and degenerated heterophils, fibrin and mucus (Table IV, Fig. 3). The epithelium was hyperplastic, composed of columnar cells with loss of cilia and an increased number of goblet cells. In many areas epithelial cells were necrotic and heterophils infiltrated the epithelium. The lamina propria was increased in depth with edema and inflammatory cells. The turbinate bones had irregular outlines in four rabbits with proliferation of fibroblasts in the periosteum. The histolo-

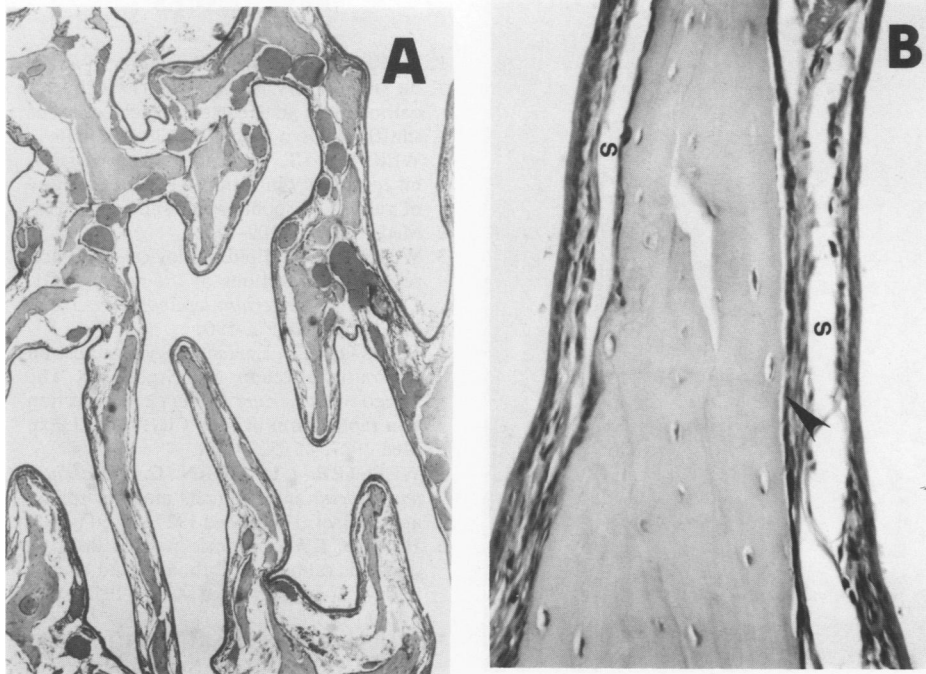


Fig. 2. Normal nasal mucosa and turbinates of a rabbit without *P. multocida* or *S. aureus* infection. A. The epithelium is thin, there are few cells in the lamina propria and surface of the bone is smooth; B. The ciliated epithelium is simple cuboidal, there are few cells in the lamina propria and the surface of the bone is covered by flattened periosteal cells (arrow). S, artefactual separation. (H & E. A X48, B X300).

gical findings in rabbits with *S. aureus* infection were similar (Table IV, Fig. 4).

DISCUSSION

Pasteurellosis was endemic in the breeding colony. A postmortem survey of rabbits dying within the first six months of life revealed that 81 of 417 (19%) rabbits examined had respiratory disease (9). Bronchopneumonia was the most common condition diagnosed and *P. multocida* was the most common isolate. Other bacteria isolated included *S. aureus* and *Bordetella bronchiseptica*. A survey of breeding does prior to our study revealed that 13 of 45 (29%) carried *P. multocida* in their nares. Typing of isolates revealed at least two capsular types (A and nontypeable) and three somatic antigen types (3,4 and 5), that occurred either singly or in some combination (12).

It was difficult to determine the incubation period since six of the ten rabbits with infection accompanied by rhinitis developed rhinitis prior to detection of *P. multocida* infection. Either we failed to detect nasal infection or some other agent was respon-

sible for the rhinitis. However, in most of the 11 rabbits, antibodies to *P. multocida* were detected two to three weeks after the last negative nasal culture (13). In a previous study (7)

that examined the development of rhinitis in relation to the acquisition of *P. multocida* infection, three of 13 (23%) rabbits developed rhinitis prior to detection of infection. Webster (2,5) reported that *P. multocida* was present in the nares prior to onset of rhinitis. In one report (2), most rabbits developed rhinitis ≤ 21 days after onset of infection whereas in another study (5) most rabbits developed rhinitis ≤ 60 days after infection.

Eleven of 19 (58%) rabbits in five litters acquired *P. multocida* infection. These 11 rabbits exhibited a wide spectrum of host responses. One infected rabbit failed to develop rhinitis and cleared its nasal infection. Of the ten rabbits with rhinitis, four had spontaneous remissions and two of these also cleared their nasal infections. One rabbit died of systemic pasteurellosis with fibrinopurulent pericarditis and pleuritis. This variability was evident even within litters. The spectrum of response in rabbits to *P. multocida* infection has been noted previously by Webster (3-5).

Pathologically, in rabbits with rhinitis and *P. multocida* infection, the lumen of the nasal cavities contained large amounts of degenerated heterophils with inflammatory exudates. There was hyperplasia, degeneration

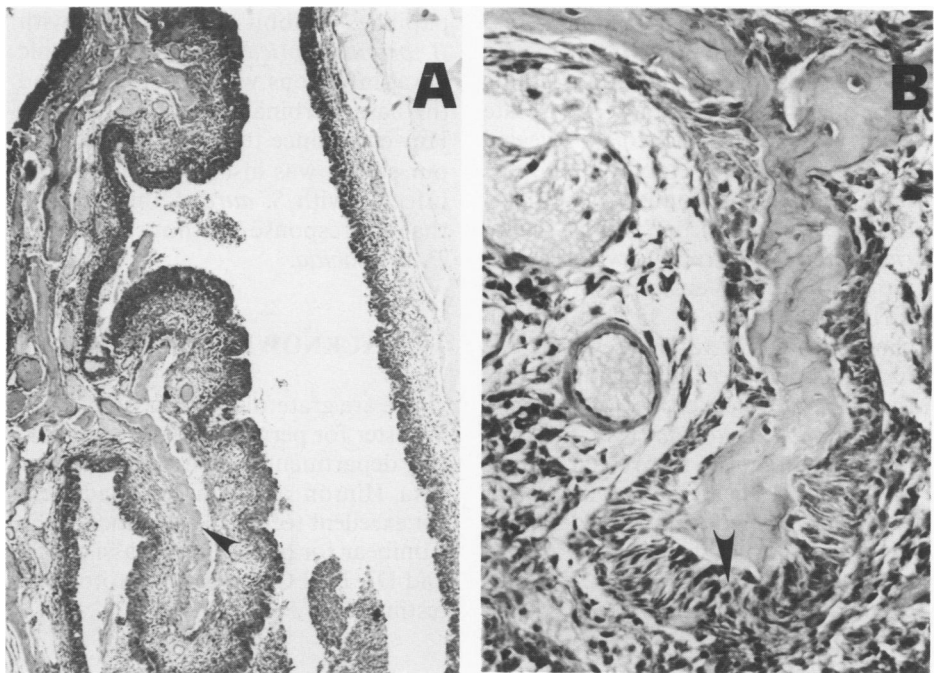


Fig. 3. Nasal mucosa and turbinates of a rabbit infected with *P. multocida*. A. The epithelium and lamina propria are thickened with inflammatory cells and the turbinate bones are irregular (arrow); B. Atrophy of turbinates with periosteal fibroplasia (arrow). (H & E. A X120, B X300).

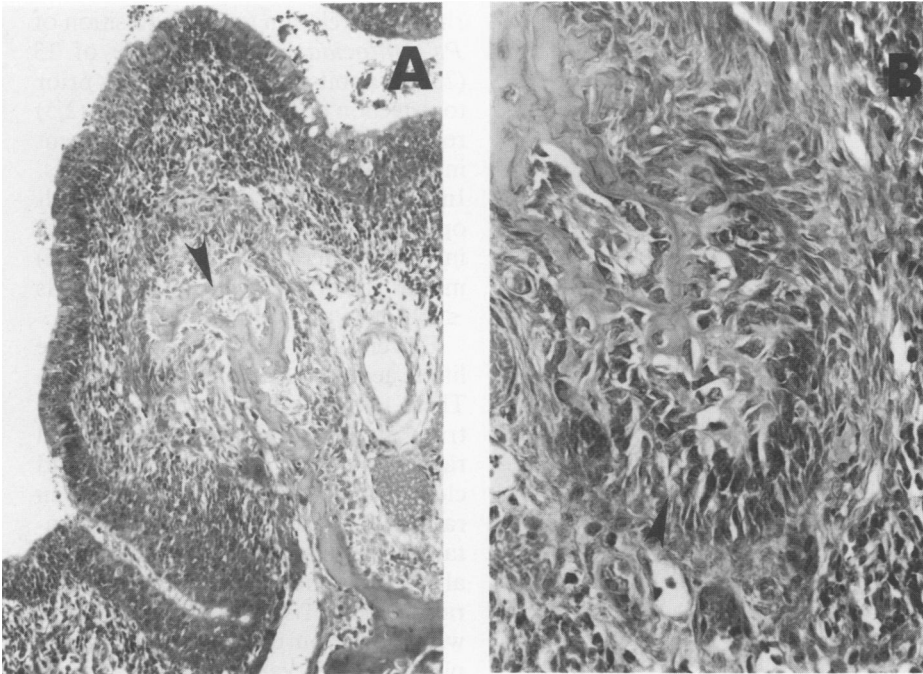


Fig. 4. Nasal mucosa and turbinates of a rabbit infected with *S. aureus*. A. The epithelium and lamina propria are infiltrated by inflammatory cells, the turbinate bone is irregular (arrow) and the periosteum is thickened; B. Atrophy of turbinates with proliferation of periosteal fibroblasts (arrow). (H & E. A X300, B X480).

and inflammation of the epithelium. The lamina propria showed severe inflammation. Both the epithelium and lamina propria were greatly thickened. There was hyperplasia of periosteal fibroblasts with atrophy of turbinates. Assay of isolates from four rabbits with turbinate atrophy and one isolate from a rabbit without atrophy revealed no cytotoxicity for embryonic bovine lung cells (14). Atrophy of the nasal turbinates in conjunction with *P. multocida* infection in rabbits was recently reported (15). Webster (1) reported turbinate atrophy in 35 rabbits with clinical rhinitis of varying severity. The nasal passages were filled with pus and the turbinates were eroded or atrophic. *Pasteurella multocida* was the predominant organism recovered from the nasal passages in all rabbits. In another study, Webster (3) inoculated rabbits intranasally with strains of *P. multocida* and *B. bronchiseptica*. Rabbits inoculated with *P. multocida* devel-

oped chronic mucopurulent rhinitis and histopathological examination revealed erosion of the cartilage and reduction in the number of turbinate papillae. Rabbits inoculated with *B. bronchiseptica* developed chronic nasal infections without rhinitis, and the nasal turbinates were unaffected. However, since turbinate atrophy, in our study, was also found in rabbits infected with *S. aureus*, this suggests that the response was not specific for *P. multocida*.

ACKNOWLEDGMENTS

We are grateful to Professor A.J.F. Webster for permitting these studies in the department rabbitry. We thank Rita Hinton and Margot Maddocks for excellent technical assistance, John Conibear for photographic assistance, and Dr. Neil Chanter for cytotoxicity testing.

REFERENCES

1. WEBSTER LT. The epidemiology of a rabbit respiratory infection. II. Clinical, pathological, and bacteriological study of snuffles. *J Exp Med* 1924; 39: 843-856.
2. WEBSTER LT. The epidemiology of a rabbit respiratory infection. IV. Susceptibility of rabbits to spontaneous snuffles. *J Exp Med* 1924; 40: 109-116.
3. WEBSTER LT. Epidemiological studies on respiratory infections of the rabbit. VIII. Carriers of *Bacterium leprosepticum*. *J Exp Med* 1926; 43: 573-590.
4. WEBSTER LT. Epidemiological studies on respiratory infections of the rabbit. IX. The spread of *Bacterium leprosepticum* infection at a rabbit farm in New City, N.Y. *J Exp Med* 1927; 45: 529-551.
5. WEBSTER LT, BURN C. *Bacterium leprosepticum* infection. Its mode of spread and control. *J Exp Med* 1927; 45: 911-935.
6. HAGEN KW. Enzootic pasteurellosis in domestic rabbits. I. Pathology and bacteriology. *J Am Vet Med Assoc* 1958; 133: 77-80.
7. DIGIACOMO RF, GARLINGHOUSE LE, VAN HOOSIER GL. Natural history of infection with *Pasteurella multocida* in rabbits. *J Am Vet Med Assoc* 1983; 183: 1172-1175.
8. NAKAGAWA M, NAKAYAMA K, SAITO M, TAKAYAMA S, WATARAI S. Bacteriological and serological studies on *Pasteurella multocida* infection in rabbits. *Exp Anim* 1986; 35: 463-469.
9. HINTON M. Post mortem survey of diseases in young rabbits. *Vet Rec* 1979; 104: 53-54.
10. GARLINGHOUSE LE, DIGIACOMO RF, VAN HOOSIER GL, CONDON J. Selective media for *Pasteurella multocida* and *Bordetella bronchiseptica*. *Lab Anim Sci* 1981; 31: 39-42.
11. LENNETTE EH, SPAULDING EH, TRUANT JP. *Manual of Clinical Microbiology*, 4th ed. Washington, DC: American Society for Microbiology, 1985: 321-325.
12. DIGIACOMO RF, ALLEN V, HINTON MH. Naturally acquired *Pasteurella multocida* subsp. *multocida* infection in a closed colony of rabbits: Characteristics of isolates. *Lab Anim* 1991; 25: 236-241.
13. DIGIACOMO RF, TAYLOR FG, ALLEN V, HINTON MH. Naturally acquired *Pasteurella multocida* infection in rabbits: Immunological aspects. *Lab Anim Sci* 1990; 40: 289-292.
14. CHANTER N, RUTTER JM, LUTHER PD. Rapid detection of toxigenic *Pasteurella multocida* by an agar overlay method. *Vet Rec* 1986; 119: 629-630.
15. DIGIACOMO RF, DEEB BJ, GIDDENS WE, BERNARD BL, CHENGAPPA MM. Atrophic rhinitis in New Zealand White rabbits infected with *Pasteurella multocida*. *Am J Vet Res* 1989; 50: 1460-1465.