

# Mitral Valve Prolapse in 3-year-old Healthy Cavalier King Charles Spaniels. An Echocardiographic Study

Henrik D. Pedersen, Bent Ø. Kristensen, Kasper A. Lorentzen, Jørgen Koch, Asger L. Jensen, and Annette Flagstad

## ABSTRACT

Clinical studies have shown that Cavalier King Charles Spaniels (CKCS) have a high prevalence of mitral valvular insufficiency (MVI). Echocardiography has the potential to disclose early valvular changes, and the present prospective study was designed to investigate the occurrence of mitral valve prolapse (MVP) in young CKCS without heart murmurs, and to correlate the degree of MVP with the clinical status of the dogs by including CKCS with MVI as well. The study was based on blinded evaluations of echocardiographic recordings of mitral valves from 34 CKCS and 30 control dogs. Thirteen (87%) of 15 three-year-old CKCS without heart murmurs had MVP (2 total and 11 partial), as compared with 1 (7%) of 15 three-year-old normal Beagle dogs ( $P < 0.0001$ ), and none of 15 three-year-old normal Medium Size Poodles ( $P < 0.0001$ ). Of 19 CKCS with MVI, MVP was found in 84% of the entire group and in 100% of dogs with pulmonary congestion or edema. The occurrence of total MVP tended to be higher in the group with MVI (47%, 9/19), when compared with the younger CKCS without heart murmurs (13%, 2/15,  $P = 0.06$ ). MVP was positively associated with excessive heart rate variability ( $P = 0.003$ ). The radius of curvature of the anterior mitral valve leaflet in systole was significantly reduced in dogs with MVP when compared with those without ( $P < 0.0001$ ). In conclusion, this study shows that CKCS at an early age have a high occurrence of MVP. This

suggests: 1) A genetic predisposition of CKCS to MVP; and 2) That MVP is a pathogenetic factor in the development of mitral valvular insufficiency. Follow up studies may add further support to these proposals, and clarify whether echocardiography may be an aid in selecting CKCS for future breeding.

## RÉSUMÉ

Des études cliniques ont démontré une prévalence élevée d'insuffisance mitrale (IM) chez des épagneuls Cavalier King Charles (ECKC). Puisque l'échocardiographie permet de détecter des changements valvulaires précoces, une étude prospective fut conçue afin de déterminer s'il est possible d'identifier le prolapsus de la valve mitrale (PVM) chez les jeunes chiens de cette race en l'absence d'un souffle cardiaque. En outre, l'étude visait aussi à établir une corrélation possible entre le degré de PVM et la sévérité des signes cliniques chez le ECKC en incluant dans l'étude des ECKC avec IM. Des évaluations d'enregistrements échocardiographiques de la valve mitrale fait à l'aveugle ont été réalisés sur 34 ECKC et 30 chiens témoins. Treize ECKC sur 15 (87 %) âgés de trois ans et ne présentant pas de souffle d'IM avaient un PVM (2 complets et 11 partiels) alors qu'il n'a été noté que chez 1 des 15 chiens de race Beagle ( $P < 0,0001$ ) et aucun des 15 caniches de taille moyenne ( $P < 0,0001$ ) du même âge. Sur 19 ECKC avec IM, la présence de PVM a été observées chez 84 % des animaux et chez 100 % des

chiens présentant de la congestion ou de l'œdème pulmonaire. La présence de PVM total était plus élevée ( $P = 0,06$ ) chez les chiens ECKC avec IM (9/19, 47 %) que chez les jeunes ECKC sans IM (2/15, 13 %). Une association positive a été établie entre le PVM et une variabilité excessive de la fréquence cardiaque ( $P = 0,003$ ). Le rayon de courbure du feston antérieur de la valve mitrale en systole chez les chiens avec PVM était réduit de façon significative ( $P < 0,0001$ ) comparativement aux chiens témoins. L'étude a permis de démontrer que chez les jeunes chiens ECKC la présence de PVM est fréquente. Ces observations suggèrent: 1) une prédisposition génétique des ECKC au PVM; et 2) le PVM est un facteur pathogénétique impliqué dans le développement de l'IM. Des études additionnelles sont nécessaires pour appuyer ces hypothèses, et pour déterminer si l'échocardiographie serait utile dans la sélection des chiens ECKC au fin de reproduction.

(Traduit par Docteur Rocky Difruscia)

## INTRODUCTION

Chronic valvular disease (CVD), especially involving the mitral valve, is the most common heart disease in dogs (1-3). The Cavalier King Charles Spaniel (CKCS) breed seems to have a genetic predisposition to CVD, since previous clinical studies have shown that a high proportion of dogs of this breed develops mitral valvular insufficiency (MVI) at a young age (4-7). Solid evidence of a high heredity of CVD was given in a

Small Animal Hospital, Department of Clinical Studies, The Royal Veterinary and Agricultural University, 13 Bülowsvej, DK-1870 Frederiksberg C, Denmark (Pedersen, Koch, Jensen, Flagstad); Department of Cardiology, Århus University Hospitals, Skejby, 100 Skejbygårdsvej, DK-8200 Århus N, Denmark (Kristensen, Lorentzen).

This study was supported by the Danish Agricultural and Veterinary Research Council project no 13-4661-1.

Correspondence and reprint requests: Henrik D. Pedersen, Department of Anatomy and Physiology, Section for Veterinary Physiology and Biochemistry, The Royal Veterinary and Agricultural University, 13 Bülowsvej, DK-1870 Frederiksberg C, Denmark.

Submitted September 8, 1994.

recently completed prospective clinical study, in which it was found that the parental CVD status had a marked influence on the probability of heart murmur and murmur intensity of the offspring (8). Therefore, if dogs with increased risk of MVI later in life could be identified, a reduced prevalence of MVI and subsequent heart failure could be obtained by excluding such dogs from the breeding population.

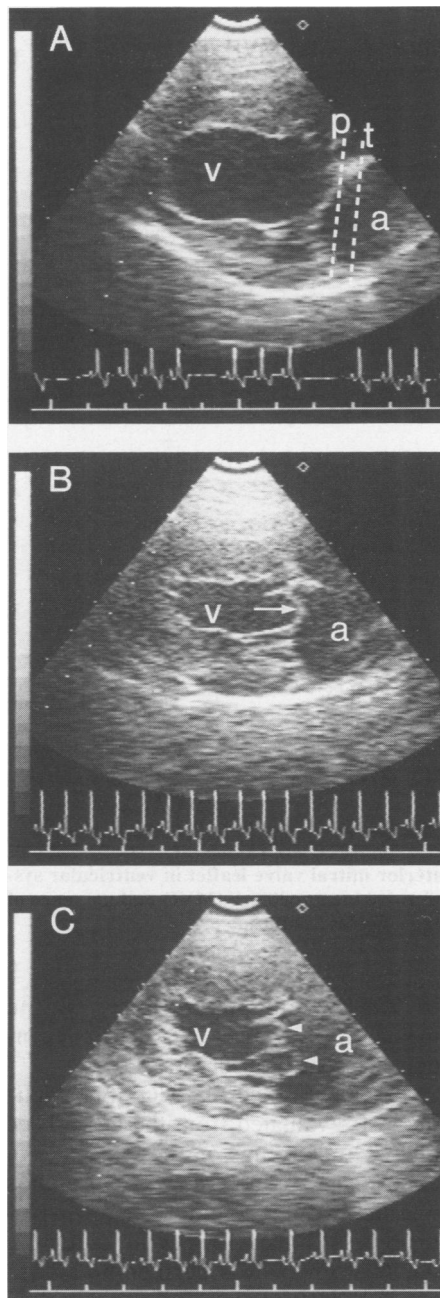
The mucoid degeneration of the mitral valves in dogs has been reported grossly and histologically to be comparable to the changes found in primary mitral valve prolapse (MVP) in humans (9–11). Mitral valve prolapse can be diagnosed with echocardiography as systolic displacement of the mitral leaflets to the atrial side of the plane of the mitral annulus (12, 13). In accordance with this, it was reported from a single, small retrospective echocardiographic study that 5 of 8 CKCS with MVI had MVP (7). However, MVP does not always precede the development of MVI, and MVI can occur without MVP.

In the present prospective echocardiographic study, we aimed to establish: 1) The prevalence of MVP in a consecutive series of young CKCS without heart murmurs; and 2) The correlation between degree of MVP and the clinical status of the dogs. The study takes into account the subjectivity of echocardiography by evaluating the echocardiograms from CKCS and age- and sex-matched control dogs in a blinded fashion. In addition, attempts have been made to evaluate whether measurements of the radius of curvature of the anterior mitral leaflet in systole would be of any aid in judging the degree of MVP, and whether there is an association between MVP and ECG abnormalities as is known from human studies (14,15).

## MATERIALS AND METHODS

### DOGS

By invitation, 48 3-year-old clinically healthy CKCS, Beagles and medium size Poodles (height at shoulder between 35 and 45 cm) were examined in our small animal hospital during a 3 mo period. One Beagle and 2 CKCS dogs had systolic murmurs and were excluded from the study. The 2 CKCS were included in the group of



**Fig. 1.** Two dimensional right parasternal long axis 4-chamber echocardiograms illustrating the mitral valve in systole. Echocardiogram A illustrates a normal mitral valve without prolapse from a 3-year-old female Beagle dog. The dashed line p is the borderline between no prolapse and partial prolapse and the line t is the borderline between partial and total prolapse. In echocardiogram B, taken from a 3-year-old male Cavalier King Charles Spaniel without heart murmur, a partial mitral valve prolapse is seen (arrow). Echocardiogram C is from a 6-year-old Cavalier King Charles Spaniel with mitral valve incompetence showing total mitral valve prolapse (arrowheads). The left ventricle is denoted 'v' and the left atrium 'a'.

CKCS with MVI described below. The group of 3-year-old healthy dogs without heart murmurs thus consisted

of 15 CKCS (7 males and 8 females), 15 Beagles (7 males and 8 females), and 15 medium size Poodles (6 males and 9 females). In the same study period, 19 CKCS with MVI (5 males and 14 females aged 2 to 9 y; mean 6.7 y) were examined. The dogs were classified according to the New York Heart Association system (NYHA; 16). Eight were in functional class I, 6 were in class II and the remaining 5 were in class III. Dogs in class I had no symptoms of heart failure and no enlargement of the left atrium on the echocardiogram. Dogs in class II had a mild to moderate enlargement of the left atrium and/or showed minor clinical symptoms such as coughing, slight dyspnea, or fatigue. If thoracic radiographs showed signs of pulmonary congestion or edema, dogs were allocated to class III. All examinations were carried out by the same veterinary cardiologist (HDP).

### ECHOCARDIOGRAPHIC EXAMINATION

An Aloka Echocardiograph SSD 725 with a 5 MHz mechanical sector transducer was used. The dogs were positioned in right lateral recumbency and scanned from below through a cut out hole in the table using the right parasternal approach. None of the dogs were sedated. All the echocardiographic examinations were performed by the above-mentioned investigator. During the initial part of the examination, lasting approximately 15 min, standard M-mode and 2-D measurements were obtained. Subsequently, the mitral valve was evaluated in the right parasternal long axis 4-chamber view. Once a good image of the mitral valve was obtained, approximately 2 min were recorded on an S-VHS tape. During the recording, the transducer was angulated in order to obtain good images of all parts of the mitral leaflets.

### EVALUATION OF THE MITRAL VALVE RECORDINGS

The 2 min mitral valve recordings from the 64 dogs were all coded by a video technician and analyzed independently by 3 observers who were blinded to the identity of the dogs and to the diagnoses made by the other observers. From each recording, a still-frame showing the maximum protrusion of the leaflets in ventricular systole was chosen and, from this,

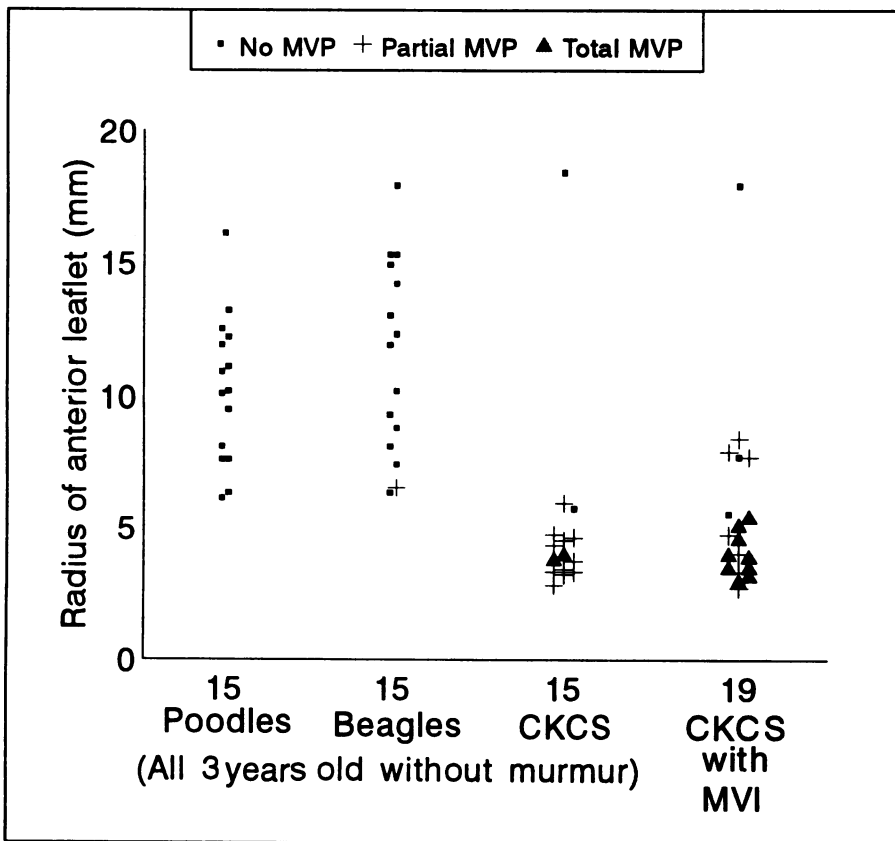


Fig. 2. Individual radii of the curvature of the anterior mitral valve leaflet in ventricular systole in 64 dogs grouped according to breed, mitral valve incompetence (MVI) and presence of mitral valve prolapse. CKCS denotes Cavalier King Charles Spaniels.

it was determined if the valve was normal or had partial or total MVP. Total MVP was defined as protrusion of a leaflet to the atrial side of a line drawn from the middle of the often elliptical echodense area at the lower part of the atrial septum to the atrioventricular junction (Fig. 1A and 1C). Partial prolapse was defined as a protrusion of a leaflet past a line drawn from the point where the anterior leaflet inserts to the point where the posterior leaflet inserts (Fig. 1A and 1B). In case of disagreement among the observers, a consensus was reached by the 3 observers after reviewing the tape together.

The radius of the curvature of the anterior mitral valve leaflet was measured on the monitor screen using a transparency with a series of semi-circles (5 to 50 mm radius and 1 mm increments) printed on it. The radius of the semi-circle that fitted the curvature of the most curving part of the leaflet in ventricular systole was chosen. The radius was later converted to the actual size using the scale on the echocardiogram. The radius measurements given

in the present paper represent the means of the values obtained independently by the 3 observers.

The occurrence of ECG abnormalities was evaluated from the last 60 sec of ECG recordings on the monitor. An abnormal R-R interval was defined as one being twice or more than that of a preceding or following interval. An A-V block was defined as a non-conducted P-wave. The abnormality was graded, so that mild abnormality was defined if 1 or 2 abnormal R-R intervals occurred on these 60 sec recordings, and severe if more than 2 abnormal R-R intervals and/or A-V block occurred. The ECG measurement was missing in 5 dogs and, in another 5 with severe heart failure (NYHA III) and high sympathetic tone, the data were excluded from analyses.

The intra-observer variation of the MVP diagnoses was calculated by examining 16 mitral valve recordings twice in a random order on the videotape (8 three-year-old CKCS and 8 three-year-old Beagles). Taken together, the 3 observers read 81% of the identical recordings correctly. The

TABLE I. Mitral valve prolapse in 45 healthy three-year-old dogs without heart murmurs. The figures represent consensus results from a blinded echocardiographic evaluation of 15 Beagles, 15 medium-sized Poodles and 15 Cavalier King Charles spaniels (CKCS)

Breed	Normal valve	Partial prolapse	Total prolapse
Beagles <sup>a</sup>	14 (93%)	1 (7%)	0 (0%)
Poodles <sup>b</sup>	15 (100%)	0 (0%)	0 (0%)
CKCS <sup>c</sup>	2 (13%)	11 (74%)	2 (13%)

<sup>a</sup> vs <sup>c</sup> and <sup>b</sup> vs <sup>c</sup>:  $P < 0.0001$ ; <sup>a</sup> vs <sup>b</sup>:  $P = 1.0$

inter-observer variation was assessed by comparing the diagnoses made by each observer with the consensus results. In this way, 80% of the individual diagnoses were found to be identical with the consensus results.

#### STATISTICAL METHODS

Fisher's exact test was used to evaluate the associations between MVP status and different groups of dogs and between MVP status and presence of ECG abnormalities. The radii found in different groups were compared using Student's *t*-test for unpaired observations. All comparisons were two-tailed and a *P*-value of 0.05 was chosen as the level of significance.

#### RESULTS

The echocardiographic findings in the 45 three-year-old dogs without heart murmurs are shown in Table I. As can be seen, 13 (87%) of the 15 CKCS had either partial or total MVP as compared with 1 out of 15 (7%) Beagles ( $P < 0.0001$ ) and no Poodles ( $P < 0.0001$ ). A billowing of the anterior mitral valve leaflet was the cause of the prolapse in all cases.

The results in the 19 CKCS with MVI are shown in Table II. Of these dogs, 16 (84%) had MVP. The number of dogs with total prolapse tended to be higher in this group (9 of 19 dogs) when compared with 3-year-old CKCS without murmurs (2 of 15 dogs;  $P = 0.06$ ). All the dogs in NYHA functional class III had MVP. The numbers of dogs with partial and total MVP in classes I and II were almost equal. There was a tendency towards a higher proportion of dogs with total prolapse in NYHA functional class III when compared with dogs in functional classes I and II ( $P = 0.14$ ).

The relationship between the radius of the anterior mitral leaflet and MVP

**TABLE II. Mitral valve prolapse in 19 Cavalier King Charles Spaniels (CKCS) with a left apical systolic murmur and various degrees of heart failure. The figures represent consensus results from a blinded echocardiographic evaluation. The dogs are grouped according to the New York Heart Association classification (NYHA)**

CKCS with heart murmurs	Normal valve	Partial prolapse	Total prolapse
Total (n = 19)	3 (16%)	7 (37%)	9 (47%)
NYHA I (n = 8) <sup>a</sup>	2 (25%)	3 (38%)	3 (38%) <sup>d</sup>
NYHA II (n = 6) <sup>b</sup>	1 (17%)	3 (50%)	2 (33%) <sup>e</sup>
NYHAIII (n = 5) <sup>c</sup>	0 (0%)	1 (20%)	4 (80%) <sup>f</sup>

<sup>a</sup> vs <sup>b</sup>:  $P = 1.0$ ; <sup>a</sup> + <sup>b</sup> vs <sup>c</sup>:  $P = 0.31$ ; <sup>d</sup> + <sup>e</sup> vs <sup>f</sup>:  $P = 0.14$

appears in Fig. 2. The mean radius ( $\pm$ SEM) of the 15 three-year-old CKCS ( $5.0 \pm 1.0$  mm) was smaller than that of Beagles ( $11.4 \pm 0.9$  mm;  $P < 0.0001$ ) and Poodles ( $10.2 \pm 0.7$  mm;  $P = 0.0002$ ). The mean radii found in the 2 control breeds were not significantly different ( $P = 0.32$ ). The mean radius ( $\pm$ SEM) found in the 34 dogs without MVP ( $10.99 \pm 0.64$ ) was significantly higher than that found in the 19 dogs with partial MVP ( $4.68 \pm 0.41$ ;  $P < 0.0001$ ). The mean radius found in dogs with total MVP ( $4.00 \pm 0.23$ ) was not significantly different from that found in dogs with partial MVP ( $P = 0.24$ ).

The results from the evaluation of the ECGs are shown in Table III. The degree of ECG abnormality was positively associated with MVP ( $P = 0.003$ ). One dog had 2nd-degree AV block and 1 had atrial premature complexes as their sole ECG abnormalities.

## DISCUSSION

This study has shown that echocardiographic MVP occurs in more than 80% of both young and older CKCS with a tendency to an association between the degree of MVP and the clinical status of the dogs. An association between MVP and increased heart rate variability was also documented. A high prevalence of MVP in CKCS with MVI has previously been reported (7), and our results in the group with MVI may be regarded as a confirmation of these findings. The findings of an equally high occurrence of MVP in young CKCS without heart murmurs have not been reported previously.

In the present study, the right parasternal long axis 4-chamber view was used to evaluate the mitral valves. This is a widely used image plane in veterinary echocardiography

that consistently gives good images of the left side of the heart (17). In humans, the atrioventricular plane is defined by a line extending from the base of the aortic valve to the atrioventricular junction (13). Such an image plane, which consistently gives good images of both the mitral valve and the aortic valve, is difficult to obtain in dogs (17). This implies that the defining line used in humans can not be used in dogs, and we therefore defined a set of criteria (Fig. 1). This potentially could overdiagnose MVP, but since we found only one case of partial prolapse among 30 control dogs, we believe that the criteria can be applied with a minimum risk of false positive diagnoses. Moreover, since the echocardiograms were evaluated blindly, with a high degree of reproducibility, we believe that our findings of MVP in the young CKCS dogs without heart murmurs represent true new observations.

Since MVP was almost not found in control dogs of similar age, the observations in the young CKCS suggest a genetic predisposition to suffer from MVP. In humans, MVP is known to be an autosomal dominantly-inherited condition with age- and sex-dependant expression (18). A similar mode of transmission in dogs remains to be proven, and such studies are ongoing in our laboratory. At present, it is unclear what reduction is to be expected in the incidence of MVI by reducing the incidence of MVP in a given population.

The prognostic value of diagnosing MVP in a young otherwise healthy dog must await longitudinal studies, in which the dogs are followed regularly. A billowing leaflet in a young human individual is often considered to have a benign course, although the follow-up studies that have been undertaken on this issue have been too short (19). However, the situation

**TABLE III. Occurrence of ECG abnormalities in 54 dogs grouped according to presence of echocardiographic mitral valve prolapse (MVP). An abnormal R-R interval was defined as one being twice or more than that of a pre- or postceding interval**

Prolapse	Number of abnormal R-R intervals in 60 sec		
	None (%)	$\leq 2$ (%)	$> 2$ (%)
No MVP (n = 34) <sup>a</sup>	26 (76)	5 (15)	3* (9)
MVP (n = 20) <sup>b</sup>	8 (40)	2 (10)	10† (50)

<sup>a</sup> vs <sup>b</sup>:  $P = 0.003$

\*One dog in this group also had 2nd degree A-V block

† One dog in this group was included because of atrial premature complexes, and one because of 2nd degree A-V block. Two of the remaining 8 dogs also had 2nd degree A-V block

in dogs may be different since, in general, they are much more prone to degenerative valvular lesions and also to progression of these lesions (10).

The results from measurements of the radius of the anterior mitral leaflet in systole as an adjunct in graduating the degree of MVP showed that there is some overlap between normal and partial MVP, and a great overlap between partial and total MVP. At present, measurements of this radius seem not to be a valuable tool in graduating MVP in dogs. However, the findings of a reduced radius in dogs with MVP seem to correlate nicely with pathology. During the development of CVD, the chordae and leaflets are progressively weakened by the degeneration of collagen bundles, which causes a ballooning deformity of the valve (9).

We found a high degree of heart rate variability in dogs with MVP. The exact cause of the increased heart rate variability is not known, but the observations appear to be similar to those encountered in human studies (14,15). Many human patients with MVP have symptoms despite having no, or only mild, MVI. These symptoms are related to neuroendocrine or autonomic dysfunction most often of either a hypervagal or a mixed hypervagal/hyperadrenergic type (15). In the present study, the dogs were recumbent for approximately 15 to 20 min before the mitral valve sequences were recorded, and most of the dogs were very relaxed at this time. Any hyperadrenergic component of a dysautonomia would, therefore, be low, thus allowing the hypervagal component to dominate

the ECG. A study specifically designed to investigate ECG abnormalities in dogs with MVP is required to clarify whether dysautonomia also exists in dogs with MVP as found in humans. Our preliminary results appear to agree with this hypothesis.

Since pathological studies have shown the degenerative changes in the mitral valves to be related to age, and since human studies have shown MVP to be inherited, it might well be that the high incidence of MVI found in CKCS is due to a genetic predisposition to MVP. If so, echocardiographic studies of this breed at an early age might prove to be a valuable aid in selecting dogs for future breeding. To prove the proposed pathogenesis, however, requires longitudinal studies, and a large number of dogs will be followed at our small animal hospital at regular intervals in the coming years in order to elucidate the matter further.

#### ACKNOWLEDGMENTS

The authors wish to thank Ms. K. Faber and Mr. K. Norby, Small Animal Hospital, Dept. of Clinical Studies for their excellent technical assistance.

#### REFERENCES

1. **BUCHANAN JW.** Chronic valvular disease (endocardiosis) in dogs. *Adv Vet Sci Comp Med* 1977; 21: 75-106.
2. **DETWEILER DK, PATTERSON DF.** The prevalence and types of cardiovascular disease in dogs. *Ann N Y Acad Sci* 1965; 127: 481-516.
3. **WHITNEY JC.** Observations on the effect of age on the severity of heart valve lesions in the dog. *J Small Anim Pract* 1974; 15: 511-522.
4. **THRUSFIELD MV, AITKEN CGG, DARKE PGG.** Observations on breed and sex in relation to canine heart valve incompetence. *J Small Anim Pract* 1985; 26: 709-717.
5. **DARKE PGG.** Valvular incompetence in Cavalier King Charles Spaniels. *Vet Rec* 1987; 120: 365-366.
6. **HÄGGSTRÖM J, HANSSON K, KVART C, SWENSON L.** Chronic valvular disease in the Cavalier King Charles Spaniel in Sweden. *Vet Rec* 1992; 131: 549-553.
7. **BEARDOW AW, BUCHANAN JW.** Chronic mitral valve disease in Cavalier King Charles Spaniels: 95 cases (1987-1991). *J Am Vet Med Assoc* 1993; 203: 1023-1029.
8. **SWENSON L, HÄGGSTRÖM J, KVART C, JUNEJA RK.** Effects of parental cardiac status on prevalence and severity of chronic valvular disease (CVD) in Cavalier King Charles Spaniels. *J Am Vet Med Assoc.* (In press).
9. **KOGURE K.** Pathology of chronic mitral valvular disease in the dog. *Jpn J Vet Sci* 1980; 42: 323-335.
10. **POMERANCE A, WHITNEY JC.** Heart valve changes common to man and dog: a comparative study. *Cardiovasc Res* 1970; 4: 61-66.
11. **GUARDA F, AMEDEO S, SCOTTI C, BUSSADORI C, VERCELLI E.** Über die pathologie des prolaps der mitralklappe des hundes. *Dtsch tierärztl Wschr* 1989; 96: 172-174.
12. **DEVEREUX RB, KRAMER-FOX R, SHEAR MK, KLIGFIELD P, PINI R, SAVAGE DD.** Diagnosis and classification of severity of mitral valve prolapse: Methodologic, biologic, and prognostic considerations. *Am Heart J* 1987; 113: 1265-1280.
13. **FEIGENBAUM H.** Echocardiography. 5th ed. Philadelphia: Lea & Febiger, 1994: 262-269.
14. **BOUDOULAS H, KOLIBASH AJ, BAKER P, KING BD, WOOLEY CF.** Mitral valve prolapse and the mitral valve prolapse syndrome: A diagnostic classification and pathogenesis of symptoms. *Am Heart J* 1989; 118: 796-818.
15. **COGHLAN HC.** Autonomic dysfunction in the mitral valve prolapse syndrome: The brain-heart connection and interaction. In: Boudoulas H, Wooley CF, eds. *Mitral valve prolapse and the mitral valve prolapse syndrome.* Mount Kisco, NY: Futura Publishing Company, Inc, 1988: 389-426.
16. **CRITERIA COMMITTEE, NEW YORK HEART ASSOCIATION, Inc.** Diseases of the heart and blood vessels. Nomenclature and criteria for diagnosis. 6th ed. Boston: Little Brown & Co, 1964; 110-114.
17. **THOMAS WP.** Two-dimensional, real-time echocardiography in the dog. Technique and anatomic validation. *Vet Radiol* 1984; 25: 50-64.
18. **DEVEREUX RB, BROWN WT, KRAMER-FOX R, SACHS I.** Inheritance of mitral valve prolapse: effect of age and sex on gene expression. *Ann Intern Med* 1982; 97: 826-832.
19. **BARLOW JB.** Mitral valve billowing and prolapse — an overview. *Aust NZ J Med* 1992; 22: 541-549.