

The development of the human hippocampal fissure

TRYPHENA HUMPHREY

*Department of Anatomy, University of Alabama Medical Center,
Birmingham, Alabama, U.S.A.*

INTRODUCTION

No fissure of the human brain has aroused so much controversy concerning its development as the hippocampal fissure. Nevertheless, it has received little attention in human foetuses after the hippocampal formation takes on its characteristic adult appearance. Indeed, the early discussions (1890–1938) centred on whether the shallow groove in the medial wall of the hemisphere during early development (beginning at 16 mm; Hines, 1922) becomes the adult hippocampal fissure, is a transient fissure, or is merely an artifact (Mall, 1903) related to poor and/or late fixation (see Elliot Smith, 1903; Hines, 1922). Little attention was given to stages over 40 mm by Hines (1922), His (1904), Hochstetter (1919) and Retzius (1901), although the definitive hippocampal fissure was identified for a 46.5 mm foetus by Hochstetter in 1894. This fissure was figured at 55.0 mm by Beck (1949), identified by Humphrey (1966*a, b*) at 56.0 mm and possibly 48.6 mm, and illustrated by Macchi (1951, figs. 32–33) at later ages.

Some authors of current text-books of embryology (Hamilton, Boyd & Mossman, 1962) follow the account of Hines. Others report the development of the fissure during the fourth embryonic month (Arey, 1965) but quote no authority for the statement. Streeter (1912) illustrated the hippocampal fissure for a foetus 'about 4 months old' and stated that it appears 'about the third month' (95 mm long, Streeter, 1912, fig. 67 and p. 100). Cunningham (1890) identified the hippocampal fissure at the end of the fourth month, or 'a little later.' Although Elliot Smith (1923, p. 624) considered the adult human hippocampal fissure to result from artificially separating the surfaces, most recent text-books of gross anatomy and neuroanatomy class this fissure as a total fissure (Gray, 1954; Peele, 1961; Crosby, Humphrey & Lauer, 1962; Strong & Elwyn, 1964).

A few investigators indicate that the hippocampal fissure has been partially obliterated (Blackstad, 1956, p. 420; also 1958, fig. 1, and 1963, figs. 1 and 12C). Frequently, in drawings, its partial obliteration is implied by the line used to separate the molecular layers of the cornu ammonis and the gyrus dentatus (e.g. Lorente de Nó, 1934; Angevine, 1965). For this fissure, Green stated that it 'may be considered that the pia has become rolled into the cleft' but added that 'very little connective tissue can be found' in the fissure (Green, 1964, p. 570). In the 1930 edition of Piersol's *Human Anatomy*, mention is made of 'the remains of the hippocampal sulcus' (p. 1166). Concerning its development, Piersol stated (p. 1190): 'At first open on the mesial surface, the fissure subsequently becomes almost entirely filled by the dentate gyrus and in the fully developed brain is scarcely seen.'

In the author's previous investigations (Humphrey, 1964, 1966*a, b*), changes noted in the region of the hippocampal fissure revealed facts relevant to its development

and to its status in the adult brain that have not been reported heretofore. Consequently the present study was undertaken to: (1) determine the age level at which the hippocampal fissure becomes identifiable; (2) follow its course of development; and (3) ascertain whether it becomes partly obliterated and, if so, the remnants present in the adult human brain.

MATERIALS AND METHODS

Serial sections from over sixty human embryos and foetuses from 9.0 mm long to 261.0 mm in c.r. length (see Humphrey, 1966*a, b* for additional data on staining, etc.) were studied. The account that follows is based on 25 of these series, prepared by Nissl and protargol silver methods. Relevant data for the ten foetuses used for the illustrations of the hippocampal fissure are given in Table 1. All foetuses listed in Table 1, and all others 16 mm and over, were freshly fixed.

Table 1. *Data on the foetuses used in the illustrations**

No. in collection	c.r. length (mm)	Menstrual age (weeks)†	Technique used	Thickness of sections (μ m)
34‡	37.0	10	Protargol§	10
85‡	44.0	10.5	Toluidin blue and erythrosin	10
119‡	48.6	11	Thionin and erythrosin	10
39	61.5	12	Protargol§ and erythrosin	10
118	79.0	13.5	Thionin	10
47	112.0	15.5	Toluidin blue and erythrosin	15
91	143.0	18.5	Protargol-S	15
98 M	144.0	18.5	Thionin and eosin	20
82	168.0	20.5	Protargol§	15
78	261.0	30	Thionin and erythrosin	20

* These foetuses and premature infants (nos. 82 and 78) are from the series for which Dr Davenport Hooker studied and recorded reflex activity (Hooker, 1952, 1958 and elsewhere). Except for nos. 85, 91 and 98 M, records were made of reflex activity, but no movements were elicited from these three.

† Menstrual age was estimated from the tables of Streeter (1920) by Dr Davenport Hooker in his studies of human foetal activity. Using the tables of Mall (1918), the ages are about half a week less except for the last four, the estimated age of which is essentially the same.

‡ Serially sectioned *in toto*. For the others, the brain was removed and sectioned separately. See Materials and Methods for the planes of sectioning.

§ The protargol method of Bodian (1937).

The foetuses under 12 weeks of menstrual age (Table 1) were sectioned transversely *in toto* (Figs. 4–7) so that the hippocampal formation is cut in the plane illustrated in Fig. 1. The brains of all foetuses of 12 weeks and older were sectioned in the coronal plane as illustrated in Figs. 2 and 3. Reference to Figs. 1–3 is made in the text and in the figure descriptions to orient the reader as accurately as possible to the plane of sectioning.

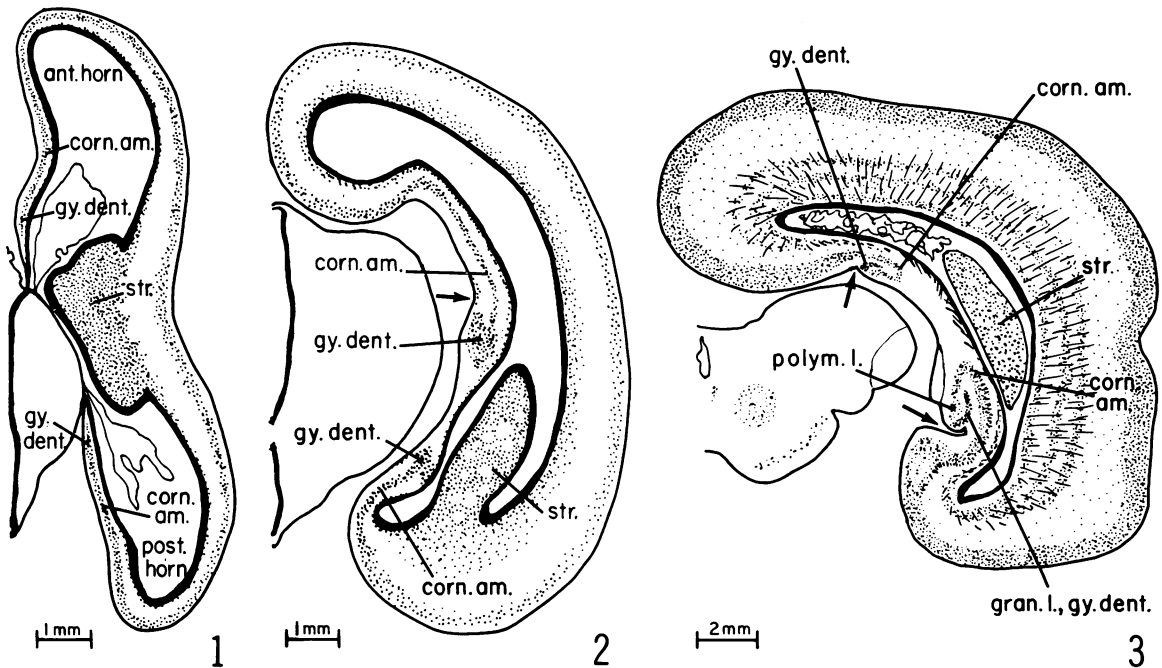
OBSERVATIONS

The appearance and early developmental stages of the hippocampal fissure

Although sometimes a broad, shallow groove may be seen along the hippocampal formation of foetuses 20.0–32.0 mm, c.r. length (Humphrey, 1966*a*, fig. 6 and 1966*b*, fig. 3), its position varies and, in freshly fixed material, it is more often absent

than present. A shallow groove is found more frequently where the mesenchyme is torn or blood vessels run for a long distance parallel with the surface (Fig. 4). Where the tissue is intact, these superficial grooves are probably transitory structures related to temporary differences in the thickness of the telencephalic wall. Whether such grooves are comparable to the hippocampal fissure of later development and in the adult brain is questionable.

By 37.0 mm C.R., a shallow groove is consistently identifiable where the hippocampal formation is located along the postero-lateral aspect of the diencephalon



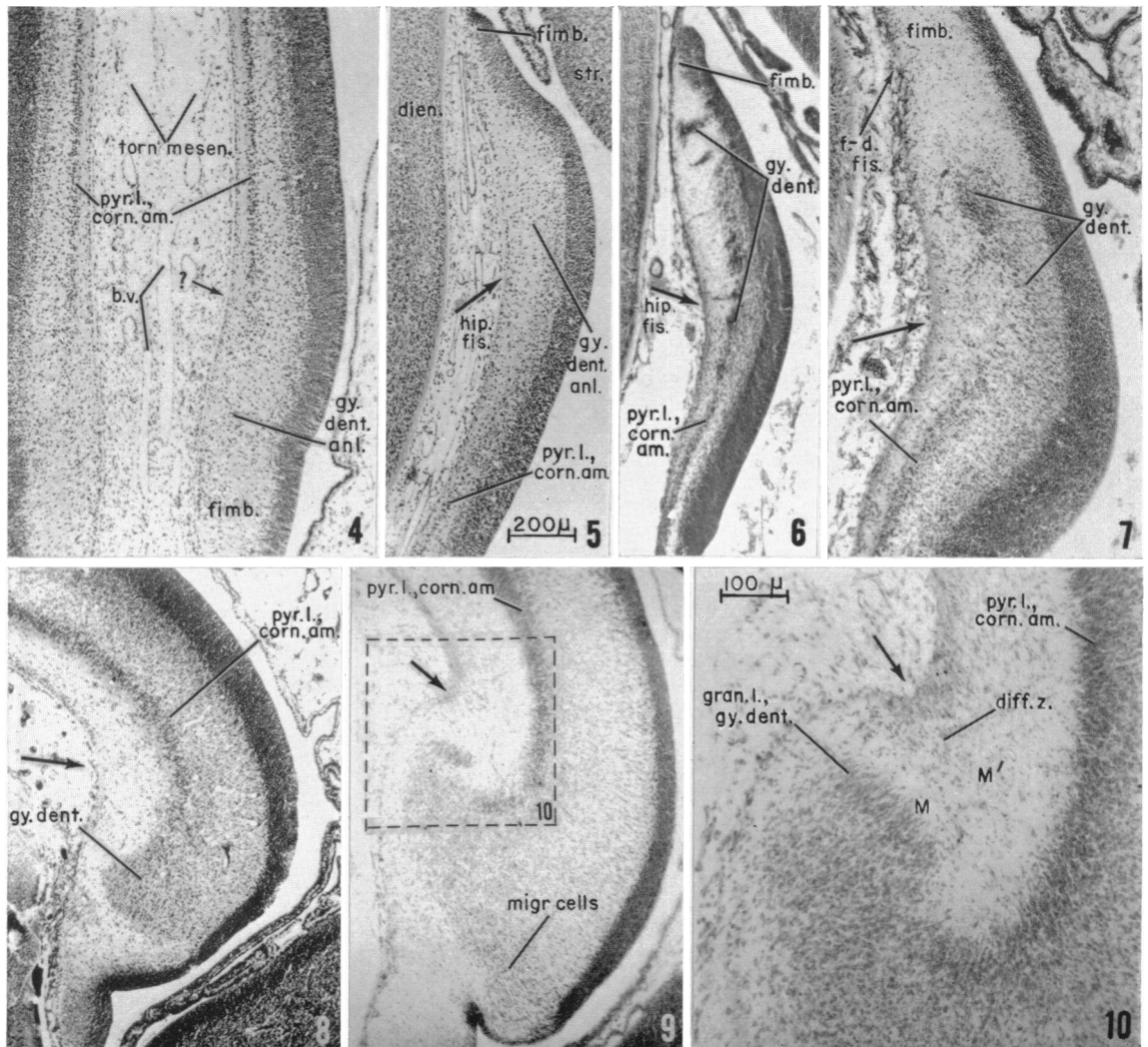
Figs. 1-3. Drawings of sections through one side of the brain of each of three human foetuses to illustrate the planes of the sections photographed and the location of the hippocampal formation. The unlabelled arrows point to the hippocampal fissure. Fig. 1. 48.6 mm C.R. length, 11 weeks of menstrual age. Fig. 2. 79.0 mm C.R. length, 13.5 weeks of menstrual age. Fig. 3. 143.0 mm C.R. length, 18.5 weeks of menstrual age.

ant. horn, anterior horn of lateral ventricle; *corn. am.*, cornu ammonis; *gran.l., gy.denti.*, granular layer of gyrus dentatus; *gy.denti.*, gyrus dentatus; *polym.l.*, polymorphic layer of gyrus dentatus; *post. horn*, posterior horn of lateral ventricle; *str.*, striatal region.

(the postero-medial wall of the lateral ventricle, Figs 1, 5), although not found either more anteriorly (Fig. 4) or more posteriorly. This fissure lies opposite the primordial gyrus dentatus (Fig. 5), rather than opposite the concavity of the pyramidal layer of the cornu ammonis as it does later in development (e.g. Figs 9-14). By 44.0 mm, the fissure is deeper and has shifted toward the junction of the cornu ammonis with the gyrus dentatus (Fig. 6). This change in location coincides with the development of a cell layer in the primordial gyrus dentatus (44.0 mm foetus, Fig. 6), and so with the appearance of the definitive dentate gyrus (Humphrey, 1966*a, b*). As this cell layer develops, the gyrus dentatus increases markedly in thickness,

whereas the telencephalic wall of the cornu ammonis remains thin (Figs. 5–6). At anterior levels of the hippocampal formation, however, there is no marked difference between the thickness of the cornu ammonis and the gyrus dentatus at both 37.0 mm (Fig. 4; see also Humphrey, 1966*a*, fig. 6C, and 1966*b*, fig. 3D) and 44.0 mm (Humphrey, 1966*a*, fig. 7A–B). The greater thickness of the gyrus dentatus gives rise to the shallow groove along this gyrus that constitutes the hippocampal fissure (Figs. 5, 6). For a 46.5 mm foetus, Hochstetter (1919, fig. 82, and p. 97) also identified the hippocampal sulcus in the temporal part of the hippocampal formation.

For an extremely limited region of the hippocampal formation of the 48.6 mm foetus, just posterior to the thin area over the postero-dorsal aspect of the dien-cephalon, the cell layer of the gyrus dentatus is thicker than elsewhere (Fig. 7).



Although all sections through this area are cut obliquely, it is obvious that the gyrus dentatus is consistently wider from the external surface to the ependymal layer than is the cornu ammonis. At anterior levels, where the gyrus dentatus is less well developed, a comparable fissure is lacking, both for this foetus and at 44.0 mm. Likewise, only a short distance farther postero-inferiorly the difference in the thickness of the telencephalic wall in the two regions becomes slight and the fissure, although identifiable, is extremely shallow (Humphrey, 1966*a*, fig. 7C; 1966*b*, fig. 3G).

In foetuses of 12 and 13.5 weeks (Figs. 8, 9), the hippocampal fissure is uniformly present for an increasingly greater part of the hippocampal formation and becomes progressively deeper. By 13.5 weeks, when the definitive granular layer of the gyrus dentatus is appearing (Figs. 9, 10) the even greater thickness of the dentate gyrus has rotated this gyrus toward the cornu ammonis. Consequently, the hippocampal fissure is deeper and more sharply defined.

Figs. 4–10. Photomicrographs of the hippocampal formations of five different human foetuses (37.0–79.0 mm in c.r. length, 10–13.5 weeks of menstrual age) to illustrate the early development of the hippocampal fissure. Figures 4–9 are at the same magnification (see scale on Fig. 5). The plane of sectioning for Figs. 4–7 is shown by Fig. 1 and that for Figs. 8–10 by Fig. 2. The unlabelled large arrows as well as the smaller arrows labelled *hip.fis.* point to the hippocampal fissure.

Fig. 4. The hippocampal formation from the antero-medial wall of the lateral ventricles of a 37.0 mm foetus (10 weeks; see Fig. 1 for location). On the left side of the figure there is no indication of a hippocampal fissure. The shallow groove on the right side (see *small arrow* with interrogation point) resembles a hippocampal fissure but may be an artifact either produced by the torn mesenchyme or related to the blood vessels running parallel to the surface. Protargol preparation, section 31–2–5.

Fig. 5. The hippocampal formation from the postero-medial wall of the lateral ventricle of the same foetus (10 weeks; see Fig. 1 for location). The small arrow labelled *hip.fis.* points to a shallow furrow that is situated along the primordial gyrus dentatus. Section 29–1–1.

Fig. 6. The hippocampal formation of a foetus of 44.0 mm c.r. length (10.5 weeks) from the same region as the area shown in Fig. 5. The deepest part of the shallow groove constituting the hippocampal fissure (*hip.fis.*) has shifted nearer to the junction of the gyrus dentatus and cornu ammonis, i.e. nearer to the location of the hippocampal fissure later in development. Toluidin blue and erythrosin stain, section 32–1–3.

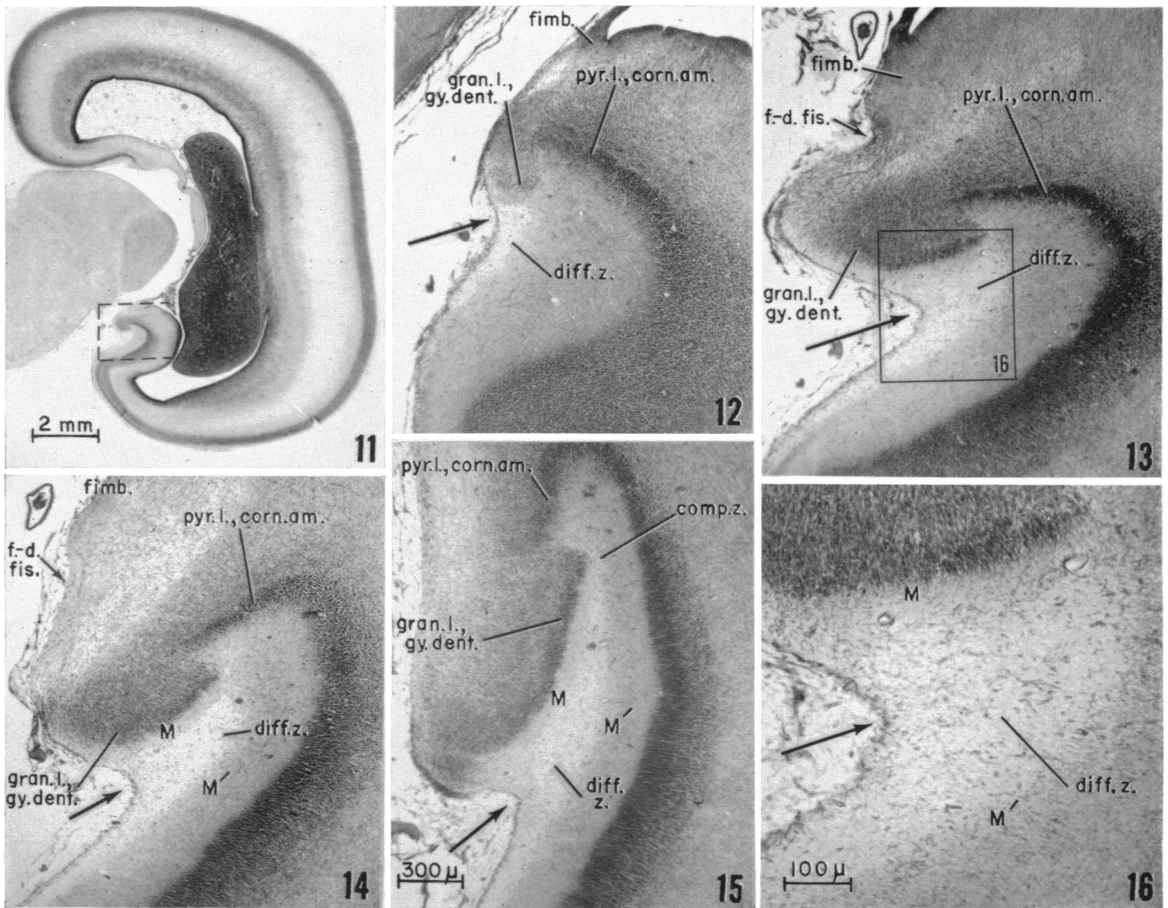
Fig. 7. The hippocampal fissure of a foetus of 48.6 mm c.r. length (11 weeks) from the same portion of the hippocampal formation as is illustrated in Figs. 5 and 6. The deepest part of the shallow fissure (unlabelled large arrow), where best represented, is located between the gyrus dentatus and the cornu ammonis. Thionin and erythrosin stain, section 42–1–1.

Fig. 8. The hippocampal fissure of a foetus of 61.5 mm c.r. length (12 weeks) from the region of the dorsally located hippocampal formation from a coronal section of the brain such as is shown in Fig. 2. Although still shallow, the fissure is oriented toward the cornu ammonis. Protargol preparation, section 76–1–2.

Fig. 9. The deeper and more sharply defined hippocampal fissure of a foetus of 79.0 mm c.r. length (13.5 weeks) from the same general region as that shown in Fig. 8. The orientation of the fissure is distinctly toward the cornu ammonis. Thionin stain, section 111–1–2.

Fig. 10. The region of the hippocampal fissure from a section (113–2–1) near that shown in Fig. 9, enlarged to show the cellular character of the triangular diffuse zone, the adjacent molecular laminae, and the granular layer of the gyrus dentatus.

b.v., blood vessels; *dien.*, diencephalon; *diff.z.*, diffuse zone; *f.-d.fis.*, fimbriodentate fissure; *fimb.*, fimbria; *gran.l.*, *gy.dent.*, granular layer of gyrus dentatus; *gy.dent.*, gyrus dentatus; *gy.dent.anl.*, anlage of gyrus dentatus; *hip.fis.*, hippocampal fissure; *M* and *M'*, molecular layer, gyrus dentatus and cornu ammonis respectively; *migr. cells*, migrating cells; *pyr.l.*, *corn.am.*, pyramidal layer of cornu ammonis; *str.*, striatum; *torn mesen.*, torn mesenchyme.



Figs. 11–16. Photomicrographs of sections of the telencephalon of a human foetus of 112.0 mm c.r. length (15.5 weeks), to show representative steps in the development of the hippocampal fissure as seen in passing from the temporal end of the developing hippocampal formation toward the retrosplenial region. The magnification scale for Figs. 12–15 is on Fig. 15. The unlabelled arrows indicate the hippocampal fissure. Toluidin blue and erythrosin stain.

Fig. 11. Low-power photograph to show the location of the hippocampal formation illustrated in Figs. 12–15. The broken lines indicate the region in question. Section 233–2.

Fig. 12. The shallow hippocampal fissure and small diffuse zone near the temporal end of the hippocampal formation. Section 172–1.

Fig. 13. The deeper hippocampal fissure and larger diffuse zone 750 μm distant from the area in Fig. 12. Section 188–3.

Fig. 14. The hippocampal fissure 375 μm posterior to the section illustrated in Fig. 13. Section 197–1.

Fig. 15. The hippocampal fissure, the diffuse zone and the compression zone near the retrosplenial region. Section 210–1.

Fig. 16. The diffuse zone from the region enclosed by solid lines in Fig. 13, enlarged to show the nature of this area.

comp.z., compression zone; *diff.z.*, diffuse zone; *f.-d.fis.*, fimbriodentate fissure; *fimb.*, fimbria; *gran.l., gy.dent.*, granular layer of gyrus dentatus; *M* and *M'*, molecular layer, gyrus dentatus and cornu ammonis respectively; *pyr.l., corn.am.*, pyramidal layer of cornu ammonis.

When the dentate gyrus approaches the cornu ammonis, a zone containing many scattered cells, including some of the marginal cells of Brown (1966) and Humphrey (1966*b*), appears deep to the fissure (Fig. 10). In the hippocampal formation of insectivorous bat embryos, this region was designated the diffuse zone by Brown (1966). For human fetuses, this diffuse zone, which begins at 12 weeks, has a well-defined triangular shape by 13.5 weeks (Figs. 9, 10). It lies between the definitive molecular layer (*M*) of the gyrus dentatus on one side and the stratum moleculare (*M'*) of the cornu ammonis on the other (Fig. 10).

The hippocampal fissure at 15.5 weeks, 112 mm crown rump

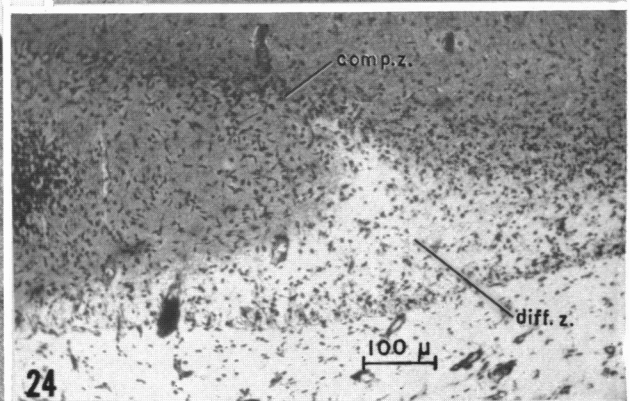
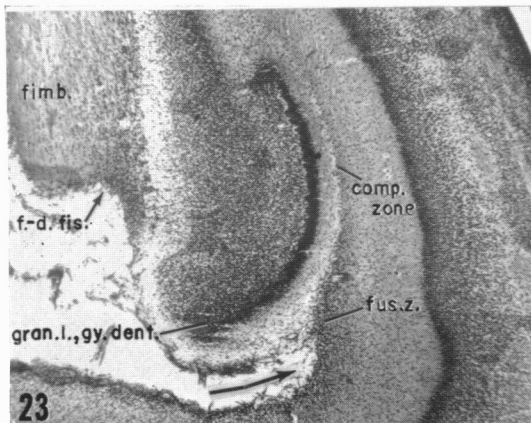
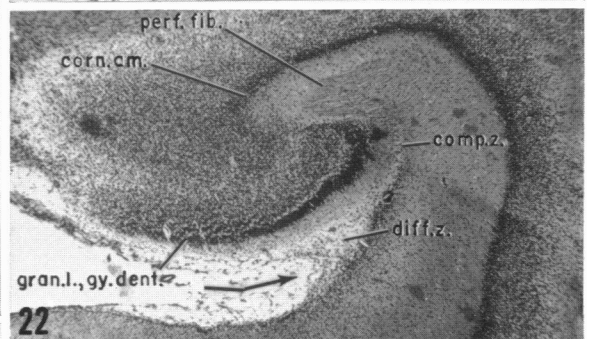
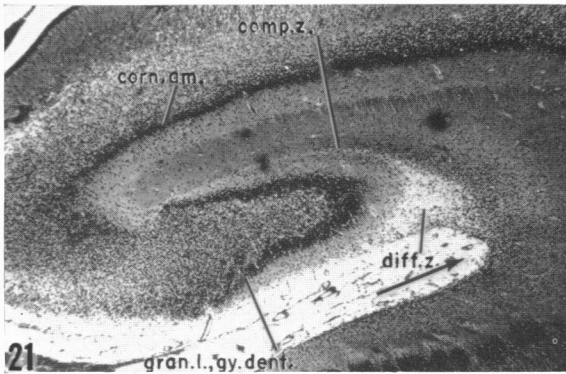
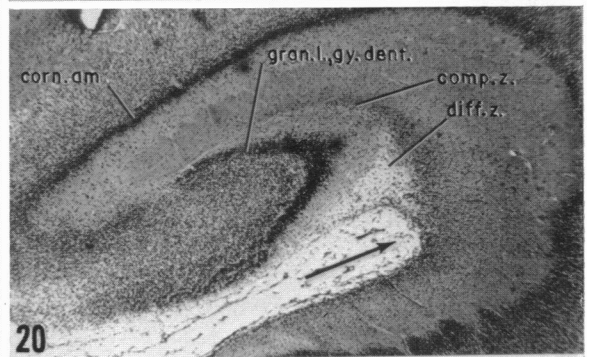
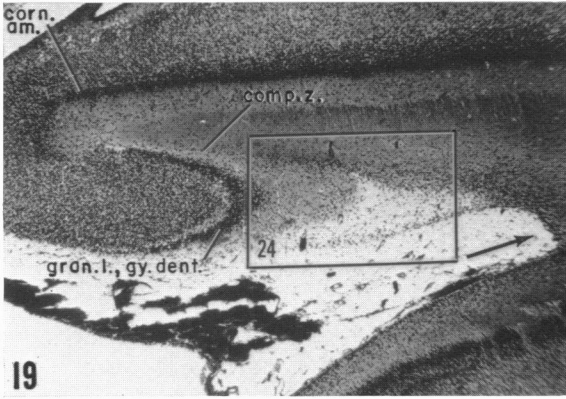
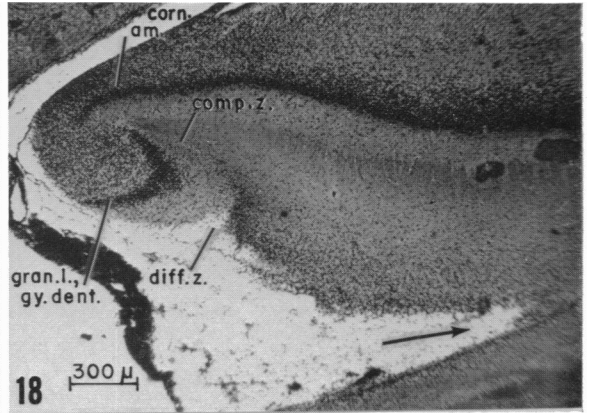
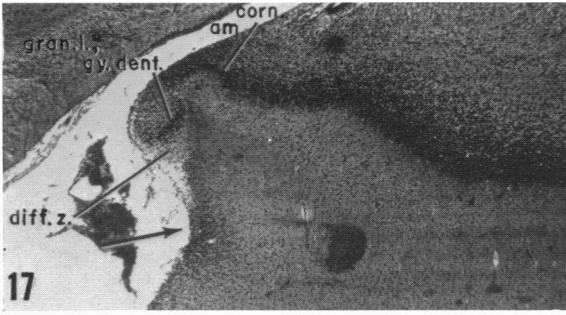
By 15.5 weeks, the hippocampal fissure is best developed in the temporal portion of the hippocampal formation (Figs. 11–15; ventral region of Macchi, 1951). Figures 2 and 11 illustrate the plane of sectioning; the area enclosed by broken lines in Fig. 11 indicates the location of Figs. 12–16. At this age (Figs. 12–15) and later (Figs. 17–23, 26–32, 35–37 and 40, 41), the developmental history of the hippocampal fissure can be traced, up to the age level under consideration, by following the hippocampal formation from its anterior tip in the temporal region toward the retrosplenial portion.

Anteriorly, the gyrus dentatus is small and the hippocampal fissure is shallow, with a diffuse zone of semilunar shape (Fig. 12). As the gyrus dentatus enlarges more posteriorly (Fig. 13), the hippocampal fissure deepens and the diffuse zone becomes triangular in outline with the shorter arm parallel to the gyrus dentatus. Due to growth without cell proliferation, the cell density of the diffuse zone is less than at 13.5 weeks (compare Figs. 10 and 16). Still farther posteriorly the triangular diffuse zone narrows, the gyrus dentatus enlarges and the hippocampal fissure deepens still more (Figs. 14, 15). With the increased size, inward growth and additional development of the granular and polymorphic layers of the dentate gyrus, the fissure is directed dorsally as well as laterally (Figs. 12–15). Where the gyrus dentatus is the largest and has rotated inward the farthest (Fig. 15), the deepest portion of the diffuse zone is taking on a linear character due to pressure from both the gyrus dentatus and the cornu ammonis. Consequently this part of the diffuse zone is being converted into a compression zone (Fig. 15, *comp.z.*).

The hippocampal fissure at 18.5 weeks, 143 and 144 mm crown rump

Between 15.5 and 18.5 weeks, both the hippocampal formation and the associated fissure have changed markedly. In addition to a greater antero-posterior extent and a marked increase in size, there is greater differentiation both in the cornu ammonis and in the gyrus dentatus. Because of the variability in development and the fact that some changes are better demonstrated by protargol silver preparations (Figs. 17–24) and others by Nissl material (Figs. 25–34), photographs from two 18.5-week fetuses are included. The coronal plane of sectioning and the orientation and general location of the regions illustrated are shown in Figs. 3 and 25.

Near the tip of the temporal pole, the shallow hippocampal fissure and small hippocampal formation are accompanied by a diffuse zone, but no compression zone (Fig. 17). The compression zone appears farther posteriorly as the dentate gyrus enlarges and rotates inward (Fig. 26). The fissure both deepens and widens as the



gyrus dentatus increases in size (Figs. 18–20, 27) then narrows (Figs. 21–23, 28, 29) to bring the two sides in contact (Figs. 29–32). The gradual narrowing and fusion of the hippocampal fissure are shown best in the Nissl material (Figs. 26–32); the contact of its two walls is less well demonstrated in the protargol-S series (Figs. 22, 23).

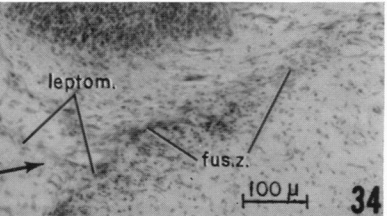
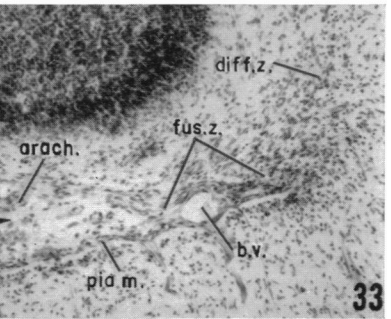
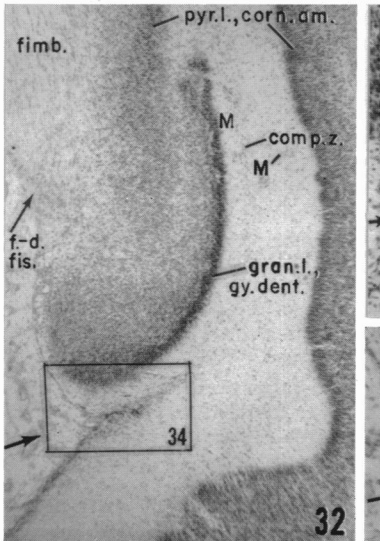
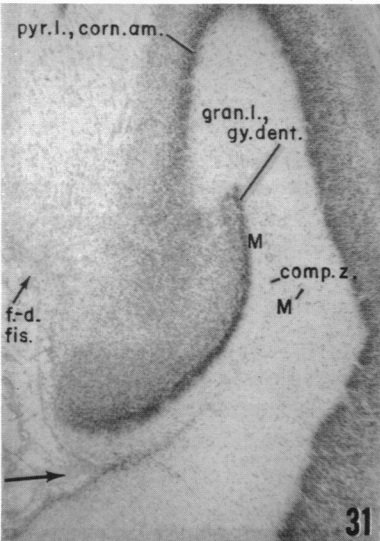
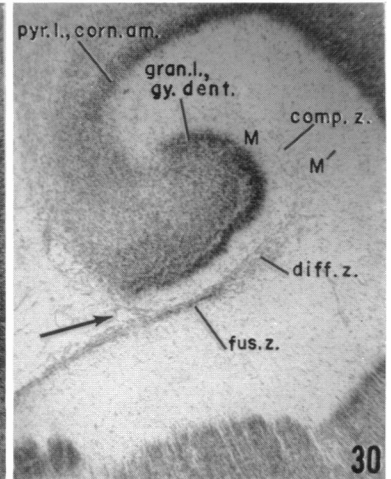
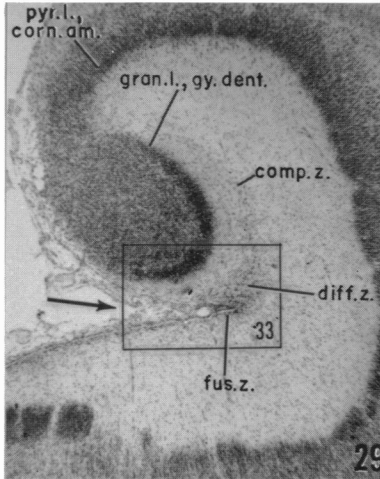
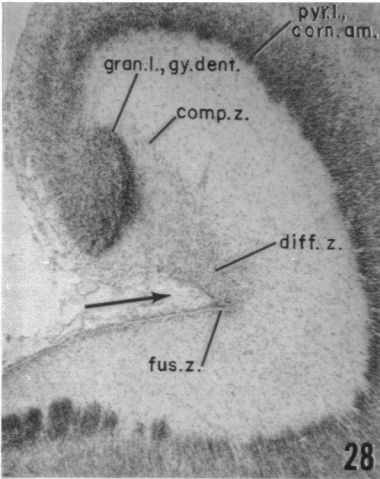
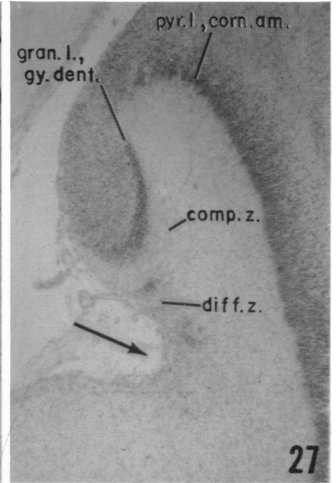
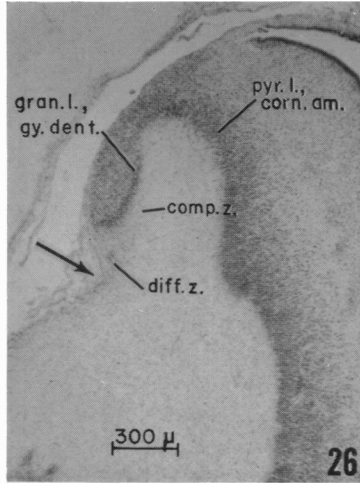
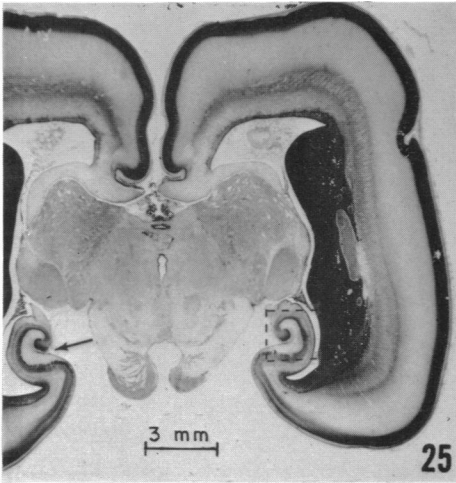
The nature of the cells in the diffuse and compression zones (i.e. whether neurons or neuroglia) could not be determined from the routinely stained Nissl and protargol material available. From the early age at which these cells appear, however, it is suggested that they are the undifferentiated marginal cells of Hines (1922). From their almost complete disappearance at later ages, it is believed that most of them degenerate and disappear, probably due in large part to the compression, although some of them may begin differentiation.

At the tip of the temporal pole, the diffuse zone does not lie at the depths of the hippocampal fissure but along the surface adjacent to the gyrus dentatus, both at this age (Figs. 17–19, 26–28) and later (Figs. 35, 36). With the greater inward growth (or rotation) of the gyrus dentatus and the more dorso-lateral orientation of the hippocampal fissure posteriorly, the diffuse zone gradually becomes aligned with the hippocampal fissure (Figs. 20–22, 28–30). As these changes take place, the diffuse zone becomes increasingly more compressed, from its deepest to its most superficial part, and is transformed gradually into the compression zone. Due to the compression, the diffuse zone increases in cellularity, as does also the adjacent part of the compression zone. In the deeper portions of the compression zone the cells progressively degenerate and disappear, as the compression increases, to leave a linear zone that becomes less and less cellular. This almost cell free indistinct band constitutes the final phase in the development of the compression zone. Because these changes constitute a continuous process, from anterior to posterior levels of the hippocampal formation and from the superficial to the deep portions of the diffuse and compression zones, the cell density in these zones varies. The usual variations in differentiation at a given age level probably account for the differences in cell density of the diffuse zone between the 18·5-week protargol preparation and the 18·5-week Nissl material at comparable levels, although differences in fixation (no. II of Bodian, 1937, and Carnoy's fluid respectively) may be a factor as well.

Figs. 17–24. Photomicrographs illustrating the representative steps in the development of the hippocampal fissure of a human foetus of 143·0 mm c.r. length (18·5 weeks, no. 91) as seen in passing from the temporal end of the hippocampal formation toward its retrosplenial portion. The unlabelled arrows point to the deepest part of the hippocampal fissure. The magnification scale for Figs. 17–23 is on Fig. 18. Protargol-S preparation.

The shallow hippocampal fissure and minute diffuse zone of the small hippocampal formation anteriorly in the temporal region in Fig. 17 (section 28–1) is replaced farther posteriorly by a deep, acutely angular hippocampal fissure, a larger diffuse zone along the wall of the fissure and a definite compression zone (Fig. 18, section 32–4). On passing toward the retrosplenial area, the diffuse zone approaches the depths of the hippocampal fissure and narrows as the compression zone increases in extent and the gyrus dentatus becomes larger (Figs. 19–21; sections 39–2, 54–1 and 49–1 respectively). Still closer to the retrosplenial region, the diffuse zone is in alignment with the hippocampal fissure (Fig. 22, section 64–1), the lips of which are beginning to fuse (Fig. 23, section 81–2). The cellular content of the diffuse zone and of the adjacent part of the compression zone, as seen in this protargol silver preparation, is shown in Fig. 24.

comp.z., compression zone; *corn.am.*, cornu ammonis; *diff.z.*, diffuse zone; *f.-d.fis.*, fimbriodentate fissure; *fimb.*, fimbria; *fus.z.*, fusion zone; *gran.l.*, *gy.dent.*, granular layer of gyrus dentatus; *perf.fib.*, perforant fibres.



After the walls of the fissure touch each other, fusion begins. This merging of the two surfaces is clearer in the Nissl material (Figs. 28–34). Even before the diffuse zone is in alignment with the hippocampal fissure, fusion has begun (Fig. 28) and becomes more extensive farther posteriorly (Fig. 29) as the diffuse zone is transformed into the compression zone (Figs. 29–32). In the fusion area (Fig. 29), the pia mater may be present both superficial and deep to blood vessels that become enclosed within the walls of the fissure (Fig. 33). As the diffuse zone narrows progressively (Figs. 29–30) it comes completely in line both with the fusion zone and the fissure superficially and with the compression zone, deeply (Figs. 30–32). At the same time, the compression zone increases in extent, primarily because the gyrus dentatus is larger, although the greater obliquity of the sections adds to the apparent length. Since the compression zone is co-extensive with the sulco-distal limb of the granular layer of the gyrus dentatus (McLardy, 1963) and lies between the molecular layers of the dentate gyrus (*M*) and the cornu ammonis (*M'*), this zone increases in extent as the granular layer develops. The compression zone also becomes progressively more indistinct as the degenerating cells in it disappear (Figs. 29–32). It is only rarely that any signs of fusion are found and all indications of merging of the walls of the fissure could be missed easily unless all sections of a series were examined (compare Fig. 31 with Figs. 30 and 32).

After the walls of the fissure fuse, the leptomeninges disappear. Where fusion is less advanced (Fig. 33), the pia mater may be identified both deep and superficial to a blood vessel, whereas where fusion is greater (Fig. 34), the pia cannot be seen. The fusion zone also contains an increased number of small cells (not identifiable without special stains) which may be microglia and play a part in the disappearance of the pia mater when the walls of the fissure fuse completely. The fusion is less extensive antero-posteriorly in the protargol series than in the thionin material and inclusion of the pia mater is not demonstrable (compare Fig. 23 with Figs. 28–34). However, in the silver material many perforant fibres (Lorente de Nó, 1934) pass across the compression zone, a region where no fissure ever existed (Fig. 22).

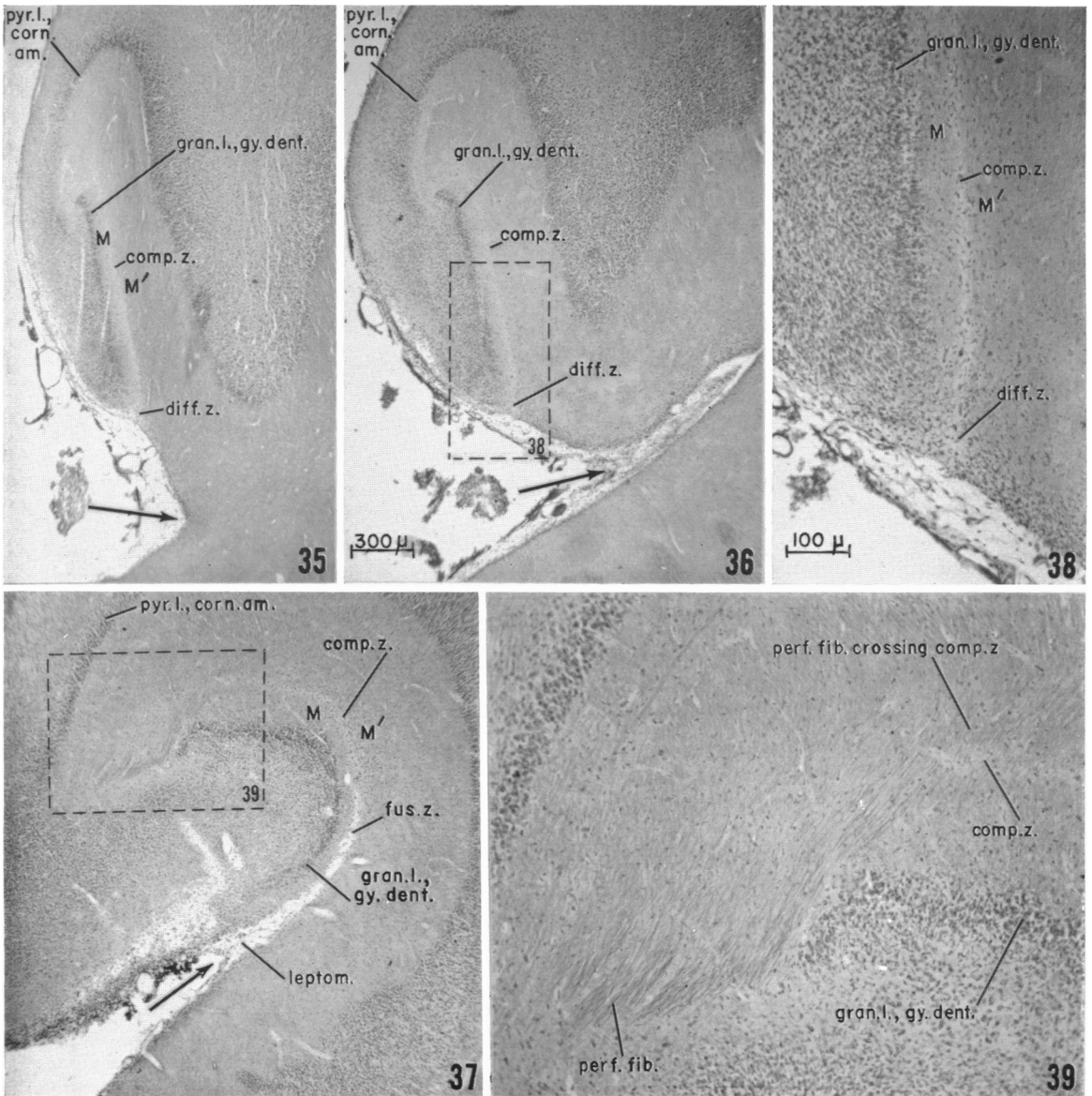
Figs. 25–34. Photomicrographs illustrating the hippocampal fissure (Figs. 25–32) of a 144.0 mm human foetus (C.R. length, no. 98 M, 18.5 weeks) and the region of fusion of its walls (Figs. 33–34) in more detail. Thionin and eosin stain. Fig. 3 also shows the coronal plane in which this brain is sectioned.

Fig. 25 demonstrates the location of the hippocampal formation illustrated in Figs. 26–32 (area designated by broken lines). The shallow hippocampal fissure and small diffuse zone near the temporal pole (Fig. 26, section 75–1) soon become a deeper and wider hippocampal fissure and a larger diffuse zone on passing toward the retrosplenial region (Fig. 27, section 84–1). Still farther posteriorly the fissure deepens and narrows even more (Fig. 28, section 105–2) as the gyrus dentatus increases further in size. When the walls come in contact, fusion begins (Fig. 28) and increases progressively (Figs. 29–32, sections 110–2, 129–1, 161–2 and 174–1 respectively) toward the retrosplenial region, as the diffuse zone is increasingly compressed (Figs. 29, 30) and frequently may not even be identifiable (Figs. 31–32). Figs. 33 and 34 are higher magnifications (scale on Fig. 34) of the region of fusion of the hippocampal fissure from the area enclosed by solid lines in Figs. 29 and 32 respectively. The magnification scale for Figs. 26–32 is on Fig. 26.

arach., arachnoid; *b.v.*, blood vessel; *comp.z.*, compression zone; *diff.z.*, diffuse zone; *f.-d.fis.*, fimbriodentate fissure; *fimb.*, fimbria; *fus.z.*, fusion zone; *gran.l.*, *gy.dent.*, granular layer of gyrus dentatus; *leptom.*, leptomeninges; *M* and *M'*, molecular layer, gyrus dentatus and cornu ammonis respectively; *pia m.*, pia mater; *pyr.l.*, *corn.am.*, pyramidal layer of cornu ammonis.

The hippocampal fissure at 20.5 weeks, 168 mm crown rump

The most striking change in the hippocampal fissure region is the reduction in the diffuse zone (Figs. 35, 36, 38) near the temporal pole and its complete disappearance farther posteriorly (Figs. 37, 40, 41). This squeezing of the diffuse zone into the compression zone, brought about by the greater size and added inward growth of the gyrus dentatus, also increased the extent of the compression zone between the molecular layers (*M* and *M'*, Figs. 37, 38, 40–42). Indeed, near the deep end of the



granular layer (Figs. 40, 41), the pressure has made the compression zone almost indistinguishable. Many more perforant fibres cross the deep part of the compression zone (Figs. 37, 39) than at 18.5 weeks (Fig. 22). In areas of fusion like that illustrated in Fig. 43 at *x*, a few scattered fibres also cross the obliterated fissure, but they cannot be distinguished at this magnification.

Inclusion of leptomeningeal tissue in the fusion zone of the hippocampal fissure is clear (Figs. 37, 40, 41, 43). On enlargement of this zone (Fig. 43) a blood vessel and its accompanying pia mater are demonstrable.

By 20.5 weeks, the relations of the hippocampal fissure of the adult brain are becoming plain. Thus where the hippocampal formation is best developed, the fissure is reduced to a surface indentation between the dentate gyrus and the junction of the entorhinal cortex with the subicular region (Figs. 40, 41). Anteriorly, a deep fissure is still present (Fig. 36). As the gyrus dentatus is folded inward to a greater degree, however, and the deep part of the open fissure (such as that seen in Fig. 36) closes, as seen at more caudal levels (Figs. 37, 40, 41), and its walls fuse, the remaining shallow surface indentation is located between the gyrus dentatus and the presubiculum, as in Fig. 37, or still later (Fig. 41) between the gyrus dentatus and the adjacent entorhinal cortex as in the newborn infant (Conel, 1939, fig. 183) and in the adult human brain (Crosby *et al.* 1962, fig. 295).

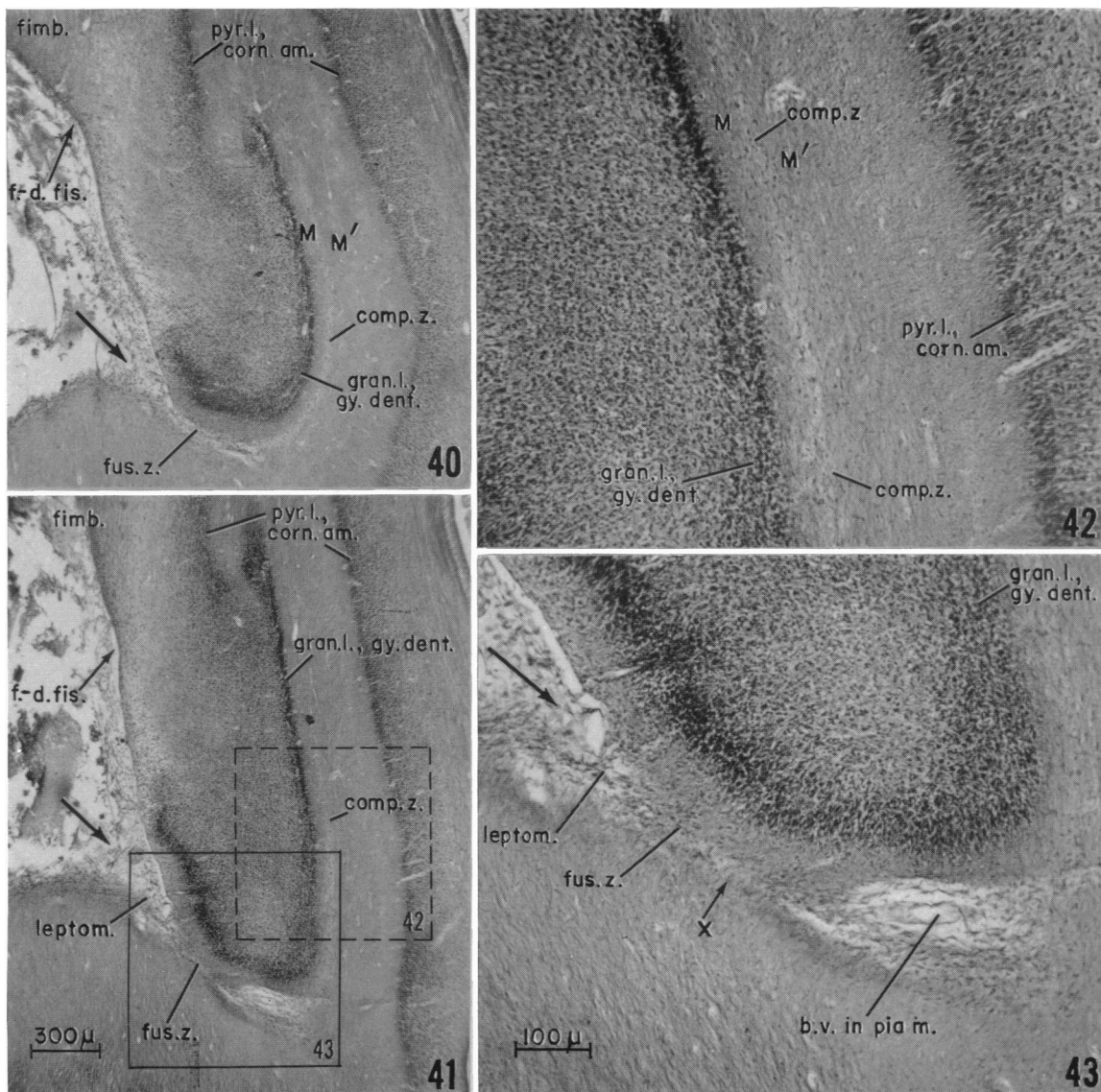
The hippocampal fissure at 30 weeks, 261.0 mm crown rump

By 30 weeks, the well-developed hippocampal formation has acquired most of the characteristics observed in the adult human brain (Figs. 44, 45). The hippocampal fissure appears only as a shallow surface indentation with almost no indication of the earlier fusion of its walls (Fig. 44). In some regions, however, remnants of the leptomeninges may be identified deep to the groove, particularly in association with blood vessels (Figs. 45, 46). In such areas, many small cells remain, although fusion is sufficiently advanced that there are no remnants of the pia mater (Fig. 47). The compression zone is more extensive, but the line that it forms between the molecular layer of the dentate gyrus (*M*) and that of the cornu ammonis (*M'*) is often almost impossible to detect (Figs. 44, 45, 48). This zone is most completely obliterated at the

Figs. 35–39. A series of photomicrographs showing the hippocampal fissure of a 168.0 mm foetus c.r. length, (20.5 weeks) near the temporal pole of the telencephalon. The region illustrated is from the ventral hippocampal area from coronal sections such as that labelled in Fig. 3. The arrows point into the hippocampal fissure. Protargol preparation.

The compression zone is extensive even near the temporal pole at this age and the diffuse zone small and along one side of the relatively shallow hippocampal fissure (Fig. 35, section 618–1). Farther posteriorly (Fig. 36, section 625–2) the fissure is deeper than at other levels and the diffuse zone still lies along the side of the fissure. As the diffuse zone comes into alignment with the hippocampal fissure, its walls come together (Fig. 37, section 655–1). The compression and diffuse zones shown within the broken lines on Fig. 36 are enlarged in Fig. 38. The numerous perforant fibres illustrated within the broken lines on Fig. 37 cross the compression zone (Fig. 39) where no hippocampal fissure ever existed rather than an obliterated hippocampal fissure.

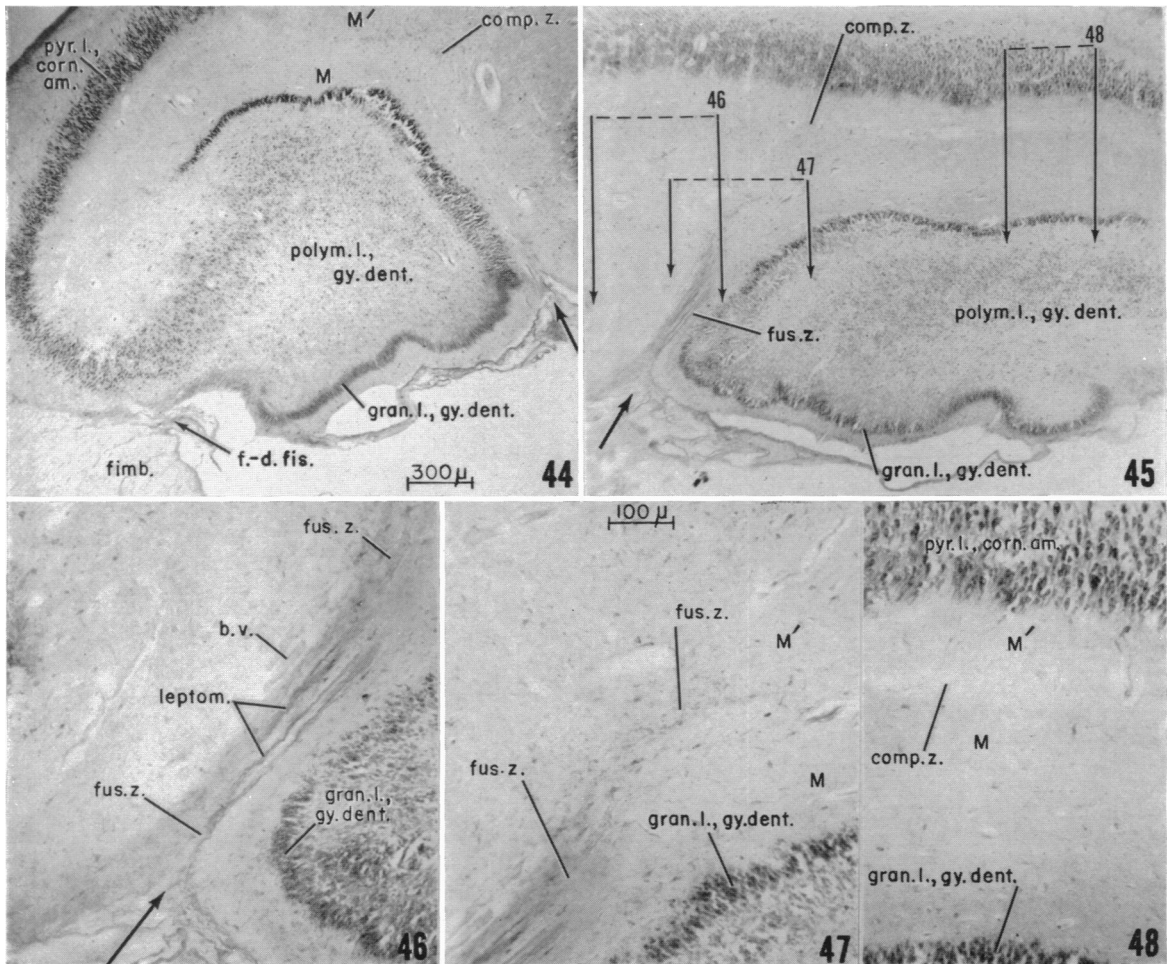
comp.z., compression zone; *diff.z.*, diffuse zone; *fus.z.*, fusion zone; *gran.l.*, *gy.dent.*, granular layer of gyrus dentatus; *leptom.*, leptomeninges; *M* and *M'*, molecular layer of gyrus dentatus and cornu ammonis respectively; *perf.fib.*, perforant fibres; *perf.fib. crossing comp.z.*, perforant fibres crossing compression zone; *pyr.l.*, *corn.am.*, pyramidal layer of cornu ammonis.



Figs. 40-43. Photomicrographs of two levels of the hippocampal formation from the region approaching the splenium of the corpus callosum of the 168.0 mm foetus illustrated in Figs. 35-39. In Figs. 40-41 (sections 688-1 and 701-1 respectively), a long compression zone lies parallel to the sulco-distal limb of the granular layer of the gyrus dentatus and a shorter fusion zone lies along the sulco-proximal limb. The arrows indicate the hippocampal fissure. The magnification scale for Figs. 40 and 41 is shown on Fig. 41. The higher power photographs of the compression zone (Fig. 42, magnification scale on Fig. 43) and of the fusion zone (Fig. 43) are the areas enclosed in broken lines (Fig. 42) and solid lines (Fig. 43) on Fig. 41. They show the decrease in the density of the compression zone (Fig. 42) and the inclusion of the leptomeninges and blood vessels when the lips of the fissure fuse (Fig. 43).

b.v. in pia m., blood vessel in pia mater; *comp.z.*, compression zone; *f-d. fis.*, fimbriodentate fissure; *fimb.*, fimbria; *fus.z.*, fusion zone; *leptom.*, leptomeninges; *gran.l., gy. dent.*, granular layer of gyrus dentatus; *M* and *M'*, molecular layer of gyrus dentatus and cornu ammonis respectively; *pyr.l., corn. am.*, pyramidal layer of cornu ammonis; *x*, area where a few perforant fibres cross into the dentate gyrus (see text).

end of the suprapyramidal (Angevine, 1965) or sulco-distal (McLardy, 1963) limb of the granular layer of the dentate gyrus (Figs. 44, 45, 48), i.e. in the portion that appears earliest in development (Humphrey, 1966a).



Figs. 44–48. Photomicrographs of the hippocampal formation of both sides of the brain from coronal sections through the subsplenial region of a foetus of 261.0 mm C.R. length (Figs. 44, 45). For orientation see the dorsally situated hippocampal formation in Fig. 3. Thionin and erythrosin stain. The unlabelled arrows point to the hippocampal fissure. The molecular layer of the gyrus dentatus (*M*) is separated from that of the cornu ammonis (*M'*) by the compression zone. The shallow hippocampal fissure, the short zone of fusion, and the compression zone are shown in the high-power photographs (Figs. 46–48), the locations of which are indicated by the areas delimited by the appropriately numbered arrows in Fig. 45. The magnification scale for Figs. 44 and 45 is on Fig. 44; that for Figs. 46–48 is on Fig. 47.

b.v., blood vessel; *comp.z.*, compression zone; *f.-d.fis.*, fimbriodentate fissure; *fimb.*, fimbria; *fus.z.*, fusion zone; *gran.l., gy.dent.*, granular layer of gyrus dentatus; *leptom.*, leptomeninges; *M* and *M'*, molecular layer, gyrus dentatus and cornu ammonis respectively; *polym.l., gy.dent.*, polymorphic layer of gyrus dentatus; *pyr.l., corn.am.*, pyramidal layer of cornu ammonis.

DISCUSSION

Since no fissure could be demonstrated in the hippocampal formation of human foetuses prior to 10 weeks of menstrual age (37 mm foetus) in freshly fixed material without artifacts from sectioning or other causes, it is concluded that the sulci identified earlier in development by many previous investigators (see introduction) are artifacts. The definitive hippocampal fissure first appears when differences in the growth rate of the gyrus dentatus and the cornu ammonis result in a thicker telencephalic wall in the dentate gyrus. The shallow, but variable, groove that is sometimes seen somewhat earlier in development in well fixed and prepared material is probably a transitory fissure or perhaps a precursor of the hippocampal fissure, as was suggested by Cunningham (1890) and others. Like the definitive hippocampal fissure, however, no doubt a transitory fissure is due to differences in the growth rates of adjacent areas, except that such disparities are not maintained.

The most extensive studies of the development of the mammalian hippocampal formation that include the hippocampal fissure are those of Tilney (1938, opossum), Godina & Barasa (1964, sheep), Brown (1966, insectivorous bats) and Humphrey (1964, 1966*a, b*, man). For rabbit embryos, Rose (1926, tables 10–11) illustrated what is probably the diffuse zone being transformed into the compression zone of the present account, but these stages do not show any fusion.

The diffuse zone deep to the fissure (mentioned by Brown, 1966, for bat embryos) is well represented in a 79 mm human foetus (13.5 weeks). Marginal cells appear in this diffuse zone by 12 weeks (Humphrey, 1966*b*) and increase in number later in development. Brown also noted and illustrated the compression of the diffuse zone, although he applied no name to the narrow band so produced. At no time throughout the developmental period that Brown identified the hippocampal fissure, is it deep enough for the walls to even approach each other. Therefore, no fusion would be possible for such insectivorous bats.

In the developing hippocampal formation of the opossum, Tilney (1938, pp. 8 and 10) recognized a 'hippocampal groove' early in development (16 mm) which 'marks the subsequent position of the hippocampal fissure'. In photographs at later stages (35, 45, 60 mm) there is a relatively deep hippocampal fissure with its walls in contact (Tilney, 1938). One of Tilney's illustrations (fig. 11, p. 24; 45 mm opossum) shows fusion of the walls of the hippocampal fissure superficially as well as a band of scattered cells more deeply situated, i.e. the deeper region of fusion and early compression of the diffuse zone. Likewise, Tilney (1938, pp. 26 and 32) mentioned a 'lamina interposita' deep to the hippocampal fissure both for 35 mm embryos (Tilney's figs. 5–6) and for the adult opossum but did not explain its formation. From his figures, however, Tilney's lamina interposita consists of the fusion zone and the adjacent part of the compression zone before the latter region becomes acellular. For a primitive macrosomatic mammal like the opossum, with a large gyrus dentatus in which the granular layer is well represented and a large ventricular eminence is formed by the cornu ammonis as early as 35 mm, the walls of the hippocampal fissure touch each other early in development and their fusion appears almost inevitable.

In their study on sheep foetuses, Godina & Barasa identified the hippocampal fissure by 67 mm. However, their photomicrographs show a broad, shallow groove

at 54 mm, when the gyrus dentatus region has thickened (Godina & Barasa, 1964, fig. 2). With the enlargement of the dentate gyrus, the photographs show a prominent diffuse zone which is rapidly compressed into a band of cells (Godina & Barasa, 1964, figs. 4-5, 67 and 80 mm), as in the bat (Brown, 1966). In sheep foetuses, however, the photomicrographs of Godina and Barasa (1964, figs. 8-10 and p. 337) reveal a deeper hippocampal fissure with its walls in contact ('negli intervalli tra i vasi, le due pareti affrontate della scissura collabiscono') as in human foetuses. Evidently the hippocampal fissure in the adult sheep is partially obliterated as it is in man. For the sheep brain, like the human brain, both fusion and compression zones appear and the diffuse zone apparently is completely transformed into a compression zone.

Although the evidence from embryonic bat, opossum, sheep and rabbit brains is not extensive, probably a diffuse zone is a transitory feature in the development of the hippocampal fissure for all mammals having a characteristic dentate gyrus, and a compression zone occurs in such adult brains also. Whether or not any fusion and obliteration of the walls of the fissure occur, no doubt depends on the factors that increase the depth of the hippocampal fissure, including not only the degree of development of the gyrus dentatus and cornu ammonis, but also the development of the other cortical regions that limit the surface areas available for the expansion of the hippocampal formation.

The perforant paths of Lorente de Nó (1934; direct temporo-ammonic path of Cajal, 1911) pass through both the molecular layer of the cornu ammonis and the molecular layer of the gyrus dentatus to reach the granular layer. According to Lorente de Nó (1934, p. 143) the 'ventricular blade' of the gyrus dentatus (sulco-proximal limb of McLardy, 1963; infrapyramidal limb of Angevine, 1965) receives fewer perforant fibres. From their position, it is the fibres to this limb that would be most likely to cross the obliterated area of the hippocampal fissure. Some authors state that the perforant fibres 'cross the fused hippocampal fissure' (Blackstad, 1956, p. 497) or cross the 'cleft between the hippocampus proper and the dentate' gyrus (Green, 1964, p. 570) *en route* to the granular layer. Figures illustrating the crossing fibres are common (Cajal, 1911, fig. 434, man; Lorente de Nó, 1934, figs. 3, 18, 19, mouse; Vaz Ferreira, 1951, figs. 42, 43, 46, rat; Blackstad, 1956, fig. 7 and 1958, fig. 4). In the protargol series of the 18.5-week and 20.5-week foetuses (Figs. 22, 37, 39), these perforant fibres may be seen crossing the compression zone, the region where a fissure was never present, rather than the area where it has been obliterated. At 20.5 weeks, a few fine fibres cross the region of fusion also. They are demonstrable at the area labelled *x* in Fig. 43, but the tiny fascicles and single fibres can be seen only at higher magnifications. It seems probable that more perforant fibres do cross the compression zone than the fusion zone in adult human brains also. For mammals like insectivorous bats (Brown, 1966), which have no region of fusion of the walls of the fissure, all the perforant fibres must pass across the compression zone. Whether or not perforant fibres cross an area of fusion of the walls of the hippocampal fissure can be determined only on the basis of developmental studies.

For the most part, the figures of the adult mammalian hippocampal formation provide no clue concerning a partial obliteration of the hippocampal fissure during development. However, figs. 20 and 21 of McLardy (1963) of the macaque brain illustrate pia mater along the sulco-proximal limb of the dentate gyrus with a

definite area of separation in the region where the two limbs join. Such an arrangement is indicative either of close contact of the walls of the fissure or of their incomplete fusion. No doubt demonstrating the hippocampal fissure in the adult human brain frequently leads to separation along the line of fusion, if not even deeper. This is probably the basis for Elliot Smith's statement in 1923 (p. 624) that '*there is no fissura hippocampi in the human brain*', but only an artificially made cleft.

Fusion of the external surfaces of the diencephalon and telencephalon in the region crossed by the internal capsule has been widely accepted in the past by embryologists (Streeter, 1912; Patten, 1946; Hamilton *et al.*, 1962). However, Sharp (1959) questioned this concept and explained the increase in the area of fibre passage by widening of the posterior wall of the interventricular foramen as the internal capsule increases in size. The evidence of fusion of the deep portions of the walls of the hippocampal fissure reported in this paper quite definitely indicates that external surfaces may grow together, or fuse, in the course of the development of the brain of some mammals.

SUMMARY

Approximately 60 embryonic human brains, serially sectioned, from embryos 9 mm long to fetuses 261.0 mm in C.R. length (5.5–30 weeks of menstrual age), were examined for the development of the hippocampal fissure.

A broad shallow hippocampal fissure was first identified at 37 mm C.R. (about 10 weeks) in the best differentiated portion of the hippocampal formation only. This shallow hippocampal fissure appears when the telencephalic wall of the primordial dentate gyrus becomes thicker than that of the cornu ammonis. The hippocampal fissure identified at this age and later is not homologous with the fissure of that name identified for birds by Craigie (1930) or for reptiles by Hines (1923), Shanklin (1930) and others, but not by Crosby (1917).

When first identified, the wide shallow hippocampal fissure lies along the surface of the primordial dentate gyrus; it shifts toward the cornu ammonis when a cell layer develops in the gyrus dentatus. After a cell mass develops in the fimbrial end of the dentate gyrus, the shallow hippocampal fissure lies between the dentate gyrus and the cornu ammonis. The fissure deepens, becomes more sharply defined and is oriented toward the cornu ammonis after the dentate gyrus begins to develop its granular layer (Figs. 9, 10, 75–80 mm C.R. or about 13.5 weeks of menstrual age). As the surface groove continues to deepen, it becomes oriented progressively more toward the junction of the cornu ammonis with the subicular region (Figs. 13–15). Still later in development the groove is farther along the subicular region toward the presubiculum (Figs. 19–21 and 28–32). In the foetus of 30 weeks and in the adult human brain (Crosby *et al.* 1962, fig. 295), the superficial groove that constitutes the hippocampal fissure is oriented toward the junction of the presubiculum and the entorhinal cortex.

Like the orientation of the hippocampal fissure, its location between the parts of the limbic system shifts during development, beginning when the definitive layers of the gyrus dentatus first appear (Figs. 9, 10). At this time, the hippocampal fissure lies between the granular layer of the gyrus dentatus and the pyramidal layer of the cornu

ammonis. By 15·5 weeks, it is essentially between the granular layer and the junction of the cornu ammonis with the subicular region (Figs. 14, 15). By 18·5 and 20·5 weeks, the fissure lies between the granular layer and the subiculum, or even between the granular layer and the junction of the subiculum with the entorhinal cortex (Figs. 19–21, 28–30, 37 and 41). In the 30-week foetus, in the newborn infant (Conel, 1939, Fig. 183) and in the adult human brain (Crosby *et al.*, 1962, fig. 295), in typical sections the hippocampal fissure is situated between the entorhinal cortex and the granular layer of the sulcoproximal limb of the gyrus dentatus. Thus the relation of the fissure to the granular layer of the gyrus dentatus is the constant feature whereas the position with reference to the other parts of the limbic system changes as development progresses just as it does to a lesser degree in phylogeny (compare fig. 2 of Lorente de N6, 1934, for the mouse, with fig. 295 of Crosby *et al.*, 1962, for man).

For the 18·5-week (Figs. 17–23 and 26–32) and the 20·5-week foetuses particularly (Figs. 35–37) the figures show that the fissure lies between the different parts of the limbic system at successive antero-posterior levels of the hippocampal formation, just as it does during progressive stages in development. This difference is well demonstrated by Fig. 36, illustrating the developing uncus region and Fig. 37, a level posterior to it. However, if the fissure in Fig. 36 is considered to be closed as far toward the surface as the granular layer of the gyrus dentatus (as it is later in development), the surface indentation then lies between the entorhinal cortex and the granular layer, a stage that it is approaching in Fig. 37. It should be noted also, that because of the hook formed in the uncus region, the usual coronal plane of sectioning may demonstrate folds of the subicular region (Fig. 36) or even of the cornu ammonis (Rose, 1927, table 75) that distort the relationships.

As the gyrus dentatus increases in size it grows toward the cornu ammonis, partly at least because of the direction of cell migration into it from the ependymal (or germinal or matrix) layer (Humphrey, 1966*a*). This growth, added to that of the cornu ammonis, causes the medial wall of the hemisphere to bulge into the lateral ventricle. Because this ventricular prominence is aligned with the hippocampal fissure, it has been classed as a total fissure.

When the hippocampal fissure deepens and becomes sharply defined (13·5 weeks), a triangular zone of scattered cells appears between the molecular layer of the dentate gyrus and that of the cornu ammonis. It constitutes the diffuse zone (Brown, 1966, bat embryos). The growth of the dentate gyrus toward the cornu ammonis compresses this diffuse zone into a narrow band that constitutes a compression zone, first in the deep part of the diffuse zone, then progressively toward the surface.

When compression of the diffuse zone brings the walls of the hippocampal fissure into contact they begin to fuse from the depths of the fissure outward. Fusion is apparently rapid, for no signs of it were found at 15·5 weeks (112·0 mm C.R.), and definite manifestations occur at 18·5 weeks (144·0 mm C.R.) and later. Both pia mater and blood vessels may be included between the walls of the hippocampal fissure as they fuse. The leptomeninges are resorbed, for traces of them are rare at 30 weeks (261·0 mm C.R.). A shallow but distinct superficial fissure then remains on the surface.

After the compression zone forms and fusion of the walls of the hippocampal fissure begins, the fusion zone, the diffuse zone and the compression zone all appear

as continuations of the surface fissure (see Fig. 29, for example). If the fusion and compression zones remaining in later development are considered as inward extensions of the hippocampal fissure, this fissure continues to be oriented toward the concavity of the cornu ammonis from 13·5 weeks throughout the foetal age period studied (30 weeks). This orientation is also present in a typical section through the hippocampal formation of the adult human brain. Superficially, however, the indentation made by the fissure may be situated between the dentate gyrus and the entorhinal cortex as early as 20·5 weeks.

For the foetal brain at 30 weeks, the hippocampal fissure consists of a clearly defined but shallow surface indentation, a linear fusion zone deep to it where the embryonic fissure has been obliterated and, in continuity with the deep end of this fusion zone, a linear compression zone. In the postnatal human brain there is also a superficial, but true, hippocampal fissure, a region of fusion of the walls of the embryonic fissure with its obliteration, and a compression zone where the brain tissue has been pressed together to leave only a narrow line continuous with and indistinguishable from the obliterated fissure.

The author wishes to thank all those who have assisted in the conduct of this research. The suggestions and criticisms of Dr Elizabeth C. Crosby have been particularly valuable. The assistance of Mrs Edith N. Vaughn in preparing additional microscopic material and in the photography, and the technical aid of Mrs Catherine P. Glazner in preparing the manuscript are greatly appreciated.

The co-operation of the Department of Obstetrics and Gynecology, University of Pittsburgh, and the Elizabeth Steel Magee Hospital in carrying on the functional studies through which the anatomic material was secured from 1932 to 1962 is acknowledged with gratitude.

This investigation was supported by a U.S. Public Health Service research career programme award, NB-K6-16716, from the National Institute of Neurological Diseases and Blindness. The author was also aided by Grant HD-00230, National Institute of Child Health and Human Development, National Institutes of Health. The present paper is publication no. 46 in a series of physiological and morphological studies on human prenatal development begun under the direction of Dr Davenport Hooker in 1932. Much of the embryologic material used for this research was prepared under the support of previous grants from the Penrose Fund of the American Philosophical Society, the Carnegie Corporation of New York, The University of Pittsburgh, the Sarah Mellon Scaife Foundation of Pittsburgh, and Grant B-394 from the National Institute of Neurological Diseases and Blindness, National Institutes of Health.

REFERENCES

- ANGEVINE, J. B. JR. (1965). Time of neuron origin in the hippocampal region. An autoradiographic study in the mouse. *Expl Neurol.* **13**, (Suppl. no. 2), 1-70.
- AREY, L. B. (1965). *Developmental Anatomy*, 7th ed. Philadelphia: Saunders.
- BECK, E. (1949). Neues zur Morphogenie des Cornu Ammonis. *Allg. Z. Psychiat.* **124**, 69-86.
- BLACKSTAD, T. W. (1956). Commissural connections of the hippocampal region in the rat, with special reference to their mode of termination. *J. comp. Neurol.* **105**, 417-537.
- BLACKSTAD, T. W. (1958). On the termination of some afferents to the hippocampus and fascia dentata. An experimental study in the rat. *Acta anat.* **35**, 202-214.
- BLACKSTAD, T. W. (1963). Ultrastructural studies on the hippocampal region. *Prog. Brain Res.* **3**, 122-148.
- BODIAN, D. (1937). The staining of paraffin sections of nervous tissues with activated protargol. The role of fixatives. *Anat. Rec.* **69**, 153-162.
- BROWN, J. W. (1966). The development of the hippocampal formation in some insectivorous bats. Int. Symp. on *Phylogensis and Ontogenesis of the Forebrain*, pp. 92-103. Stuttgart: Georg. Thieme.
- CAJAL, S. RAMÓN Y, (1911). *Histologie du Système Nerveux de l'Homme et des Vertébrés*, vol. II. Paris: Maloine.
- CONEL, J.L. (1939). *The Postnatal Development of the Human Cerebral Cortex*. I. *The Cortex of the Newborn*. Cambridge, Massachusetts: Harvard University Press.
- CRAIGIE, E. H. (1930). Studies on the brain of the kiwi (*Apteryx australis*). *J. comp. Neurol.* **49**, 223-357.
- CROSBY, E. C. (1917). The forebrain of *Alligator mississippiensis*. *J. comp. Neurol.* **27**, 325-402.
- CROSBY, E. C., HUMPHREY, T. & LAUER, E. W. (1962). *Correlative Anatomy of the Nervous System*. New York: Macmillan.
- CUNNINGHAM, D. J. (1890). The complete fissures of the human cerebrum, and their significance in connection with the growth of the hemisphere and the appearance of the occipital lobe. *J. Anat. Physiol., Lond.* **24**, 309-345.
- ELLIOT SMITH, G. (1903). Note on the so-called 'Transitory Fissures' of the human brain, with special reference to Bischoff's 'Fissura perpendicularis externa'. *Anat. Anz.* **24**, 216-220.
- ELLIOT SMITH, G. (1923). I. The central nervous system. Subsection on *The Nervous System*, in 5th ed. *D. J. Cunningham's Text-book of Anatomy*. Ed. A. Robinson. London: Oxford University Press.
- GODINA, G. & BARASA, A. (1964). Morfogenesi ed istogenesi della formazione ammonica. *Z. Zellforsch. mikrosk. Anat.* **63**, 327-355.
- GRAY, H. (1954). *Anatomy of the Human Body*, 26th ed. Ed. C. M. Goss. Philadelphia: Lea and Febiger.
- GREEN, J. D. (1964). The hippocampus. *Physiol. Rev.* **44**, 561-608.
- HAMILTON, W. J., BOYD, J. D. & MOSSMAN, H. W. (1962). *Human Embryology*, 3rd ed. Baltimore, Maryland: Williams and Wilkins.
- HINES, M. (1922). Studies in the growth and differentiation of the telencephalon in man. The fissura hippocampi. *J. comp. Neurol.* **34**, 73-171.
- HINES, M. (1923). The development of the telencephalon in *Sphenodon punctatum*. *J. comp. Neurol.* **35**, 483-537.
- HIS, W. (1904). *Die Entwicklung des menschlichen Gehirns während der ersten Monate*. Leipzig: S. Hirzel.
- HOCHSTETTER, F. (1894). Beiträge zur Entwicklungsgeschichte des Gehirns. *Bibliothca med.* (Quoted from Hochstetter, 1919).
- HOCHSTETTER, F. (1919). *Beiträge zur Entwicklungsgeschichte des menschlichen Gehirns*. I. Wien und Leipzig: Deuticke.
- HOOKE, D. (1952). *The Prenatal Origin of Behavior*. 18th Porter Lecture Series. Lawrence, Kansas: University of Kansas Press.
- HOOKE, D. (1958). *Evidence of Prenatal Function of the Central Nervous System in Man*. James Arthur Lecture on the Evolution of the Human Brain for 1957. New York: American Museum of Natural History.
- HUMPHREY, T. (1964). Some observations on the development of the human hippocampal formation. *Trans. Am. neurol. Ass.* **89**, 207-209.
- HUMPHREY, T. (1966a). Correlations between the development of the hippocampal formation and the differentiation of the olfactory bulbs. *Ala. J. med. Sci.* **3**, 235-269.
- HUMPHREY, T. (1966b). The development of the human hippocampal formation correlated with some aspects of its phylogenetic history. Int. Symp. on *Phylogensis and Ontogenesis of the Forebrain*. pp. 104-116, Stuttgart: Georg Thieme.
- LORENTE DE NÓ, R. (1934). Studies on the structure of the cerebral cortex. II. Continuation of the study of the ammonic system. *J. Psychol. Neurol., Lpz.* **46**, 113-177.

- MACCHI, G. (1951). The ontogenetic development of the telencephalon in man. *J. comp. Neurol.* **95**, 245–305.
- MALL, F. P. (1903). On the transitory or artificial fissures of the human cerebrum. *Am. J. Anat.* **2**, 333–339.
- MALL, F. P. (1918). On the age of human embryos. *Am. J. Anat.* **23**, 397–422.
- McLARDY, T. (1963). Some cell and fibre peculiarities of uncus hippocampus. *Prog. Brain Res.* **3**, 71–88.
- PATTEN, B. M. (1946). *Human Embryology*. Philadelphia and Toronto: Blakiston.
- PEELE, T. L. (1961). *The Neuroanatomic Basis for Clinical Neurology*, 2nd ed. New York and London: McGraw-Hill.
- PIERSOL, G. A. (1930). *Human Anatomy*, 9th ed., revised under the supervision of G. C. Huber. Philadelphia: Lippincott.
- RETZIUS, G. (1901). Zur Frage von den sogenannten transitorischen Furchen des Menschengehirnes. *Anat. Anz. (Suppl.)* **19**, 91–92.
- ROSE, M. (1926). Über das histogenetische Prinzip der Einteilung der Grosshirnrinde. *J. Psychol. Neurol., Lpz.* **32**, 97–160.
- ROSE, M. (1927). Die sog. Riechrinde beim Menschen und beim Affen. II. Teil des 'Allocortex bei Tier und beim Mensch'. *J. Psychol. Neurol., Lpz.* **34**, 261–401.
- SHANKLIN, W. M. (1930). The central nervous system of *Chameleon vulgaris*. *Acta zool.* **11**, 425–490.
- SHARP, J. A. (1959). The junctional region of cerebral hemisphere and third ventricle in mammalian embryos. *J. Anat.* **93**, 159–168.
- STREETER, G. L. (1912). The development of the nervous system. In *Manual of Human Embryology*, 2 vols. 1910–12, **2**, 1–156. Eds. F. Keibel and F. P. Mall. Philadelphia: Lippincott.
- STREETER, G. L. (1920). Weight, sitting height, head size, foot length, and menstrual age of the human embryo. *Contr. Embryol.* **11**, 143–170.
- STRONG, O. S. & ELWYN, A. (1964). *Human Neuroanatomy*, 5th ed., revised by R. C. Truex and M. B. Carpenter. Baltimore, Maryland: Williams and Wilkins.
- TILNEY, F. (1938). The hippocampus and its relations to the corpus callosum. *Bull. neurol. Inst., N.Y.* **7**, 1–77.
- VAZ FARREIRA, A. (1951). The cortical areas of the albino rat studied by silver impregnation. *J. comp. Neurol.* **95**, 177–243.