J. Anat. (1967), **101**, 3, pp. 505–532
With 11 *figures*
Printed in Great Britain

The innervation of the knee joint. An anatomical and histological study in the cat

M. A. R. FREEMAN AND BARRY WYKE

Neurological Laboratory, Department of Applied Physiology,
Royal College of Surgeons of England, and
Department of Orthopaedic Surgery, Westminster Hospital, London

INTRODUCTION

The subject of articular neurology has been neglected in contemporary anatomy, physiology and clinical surgery (Barnett, Davies & MacConaill, 1961). For this reason, a systematic study of the general field of articular neurology has been undertaken; and as interpretation of experimental studies of any aspect of articular neurology is dependent upon precise knowledge of the innervation of the joint being studied, this investigation was carried out to provide information on the cat's knee joint.

Previous attempts at a comprehensive study of the innervation of the cat's knee joint are by Gardner (1944) and Skoglund (1956): more limited studies have been reported by Sasaoka (1939*a*, *b*), Samuel (1949, 1952), Andrew & Dodt (1953), Boyd & Roberts (1953), Andrew (1954), Boyd (1954), Cohen (1955) and Fidel'-Osipova, Yemets & Burichenko (1961).

This paper describes the extrinsic nerve supply of the cat's knee joint, the principal morphological characteristics of the variety of articular nerve endings innervated therefrom, and their distribution within the individual tissues of the joint. Preliminary accounts of some of this work have already been give by Wyke (1961, 1966) and Freeman & Wyke (1963, 1966): and a comprehensive review of the relevant literature is provided in Wyke (1967).

MATERIALS AND METHODS

A total of forty-one knee joints in thirty-one mature cats weighing between 2·8 and 5·5 kg (average weight 4 kg) was studied macroscopically and microscopically.

Extrinsic innervation

Four procedures were employed in the examination of the extrinsic nerve supply of the knee joint.

(1) In fresh, unfixed cadavers twenty knee joints were dissected under magnifying lenses to identify the articular branches of the peripheral nerves in the limb. Some of these articular branches were traced into various regions of the joint under a stereoscopic dissecting microscope.

(2) Surgical dissections of the major articular nerves to the knee joint were performed with magnifying lenses in twenty-one animals under pentobarbitone anaesthesia, preparatory to their division or electrical stimulation. Segments of these

nerves were subsequently removed for histological examination (*q.v.*). The functional effects of the articular neurectomies have been described by Freeman & Wyke (1966).

(3) Microdissection of nerves within the substance of the muscles related to the knee joint was performed in nine animals, after partial maceration of the tissues in 1 % acetic acid at 39 °C. This displayed the accessory articular nerves (*q.v.*).

(4) The articular nerve trunks and their branches were examined with a modified paraffin silver technique (based on Holmes's (1942) method) to determine their nerve fibre composition and their relations to adjacent structures. Analyses of the numbers and diameters of myelinated and unmyelinated nerve fibres in sections of the articular nerves were made with the aid of a plastic graticule on photomicrographs enlarged 1000 times.

Articular nerve endings

Fresh tissues (fibrous capsule, ligaments, fat pads, menisci and synovial tissue) removed from the knee joints of the animals were each treated with at least three different histological methods, and examined microscopically for nerve fibres and endings. Serial sections from each type of tissue were studied. Measurements of the dimensions of end-organs and of nerve fibres were made on enlarged photomicrographs, using an appropriate micrometer scale.

The histological techniques employed in this study involved gold chloride, methylene blue, frozen silver* and paraffin silver methods; and each was specially modified to give maximum differential staining of the neural elements in articular tissues. The detailed steps in each such method are not described here, as they are recounted in full in Wyke (1967).

OBSERVATIONS

The extrinsic innervation of the knee joint

Macro- and microdissection studies show that the knee joint of the cat is supplied by two groups of articular nerves, the disposition of each of which varies somewhat in individual animals. These articular nerves may be classified as *primary* (posterior, medial and lateral) and *accessory* (arising from muscular nerves), the latter group being the more variable.

Primary articular nerves

The posterior articular nerve (PAN). This nerve (Fig. 1) is the larger and more constant of the primary articular nerves. It usually arises alone as a single trunk from the posterior tibial nerve, just below the popliteal fossa and about 1 cm distal to the plane of the knee joint, and forms the first branch of the posterior tibial nerve. Its origin is about 0·5 cm distal to the origin of the nerve to the medial head of the gastrocnemius muscle from the medial popliteal nerve, and about 0·3 cm proximal to the second branch of the posterior tibial nerve—which is a short trunk, about 3–4 mm long, that fans out into a leash of fine branches supplying the gastrocnemius muscle (Fig. 1). In some animals, however, the PAN does not arise separately, but instead is

---

* This method is a modification of that developed by Dr M. J. T. Fitzgerald, of the Department of Anatomy, University College, Cork, Eire (Fitzgerald, 1963). The authors are especially indebted to him for his considerable help in developing its application to articular tissues.

incorporated into the trunk of muscular branches just mentioned—in which case, the articular nerve is the first or second rostral branch of that trunk. The PAN is the only branch of the posterior tibial nerve to the knee joint in the cat: but in one instance the posterior tibial nerve gave off two posterior articular branches to the joint. A very fine branch arose in the usual position, whilst another even finer branch (an accessory posterior articular nerve) was given off from the posterior tibial nerve about 1 cm proximal to the former branch.

At its origin from the posterior tibial nerve, the PAN is embedded in the fascia covering the deep surface of the lateral head of the gastrocnemius muscle; and when the head is reflected laterally (as in Fig. 1), the nerve can be seen curving medially and rostrally in the deep fascia towards the inferior end of the popliteal fossa. As it lies *in situ*, the nerve runs anteriorly and upwards into the fatty tissue that surrounds the posterior tibial vessels at the upper end of the tibia, being accompanied by a fine branch of the posterior tibial artery that provides the vasa nervorum of the PAN. When the nerve (to this point being about 1 cm long) reaches the posterior tibial artery it turns rostrally, and ascends for another 0·5–1 cm to the back of the knee joint embedded in the fibro-adipose connective tissue that surrounds the artery. As it approaches the joint from below, the nerve passes across the junction of the posterior and anterior tibial veins, and then bifurcates (Fig. 1) into medial and lateral branches—still embedded in the fatty tissue that ensheaths the continuation of the posterior tibial artery from the popliteal artery. The lateral of these two branches is usually the larger, and sometimes itself bifurcates again before entering the joint capsule.

Each branch of the PAN diverges from the popliteal artery, breaking up into finer twigs at it does so. Most of these twigs pass laterally and medially to join the corresponding genicular arteries, whose branches they follow into the posterolateral and posteromedial regions of the fibrous capsule of the knee joint; whilst others enter the posterior capsule of the joint independently. One such independent twig enters the back of the knee joint through a small midline aperture in the inferior attachment of the posterior capsule to the tibia: this twig gives off filaments to the adjacent intercondylar fat pad as it enters the joint capsule, and then terminates in the attachment of the posterior cruciate ligament to the tibia. Some of the laterally directed twigs of the PAN pass round in the inferior edge of the posterior capsule of the knee joint to reach the lateral collateral ligament and the posterior capsule of the superior tibio-fibular joint; whilst a few of the medially directed filaments reach the medial collateral ligament, on whose surface they mingle with a plexus formed from the medial articular nerve (*q.v.*).

From these observations, the PAN appears to be distributed (Fig. 5) mainly to the lateral and medial regions of the posterior capsule of the knee joint, the posterior fat pads, the posterior oblique ligament, the posterior cruciate ligament, and the posterior parts of the annular ligaments surrounding the lateral and medial menisci. It contributes more nerve fibres to laterally situated than to medially situated articular tissues; but on each side of the joint capsule some filaments extend forwards to reach the respective collateral ligaments. On the medial side of the joint its branches overlap into the territory supplied by the medial articular nerve (*q.v.*); and on both sides its distribution overlaps with that of various accessory articular

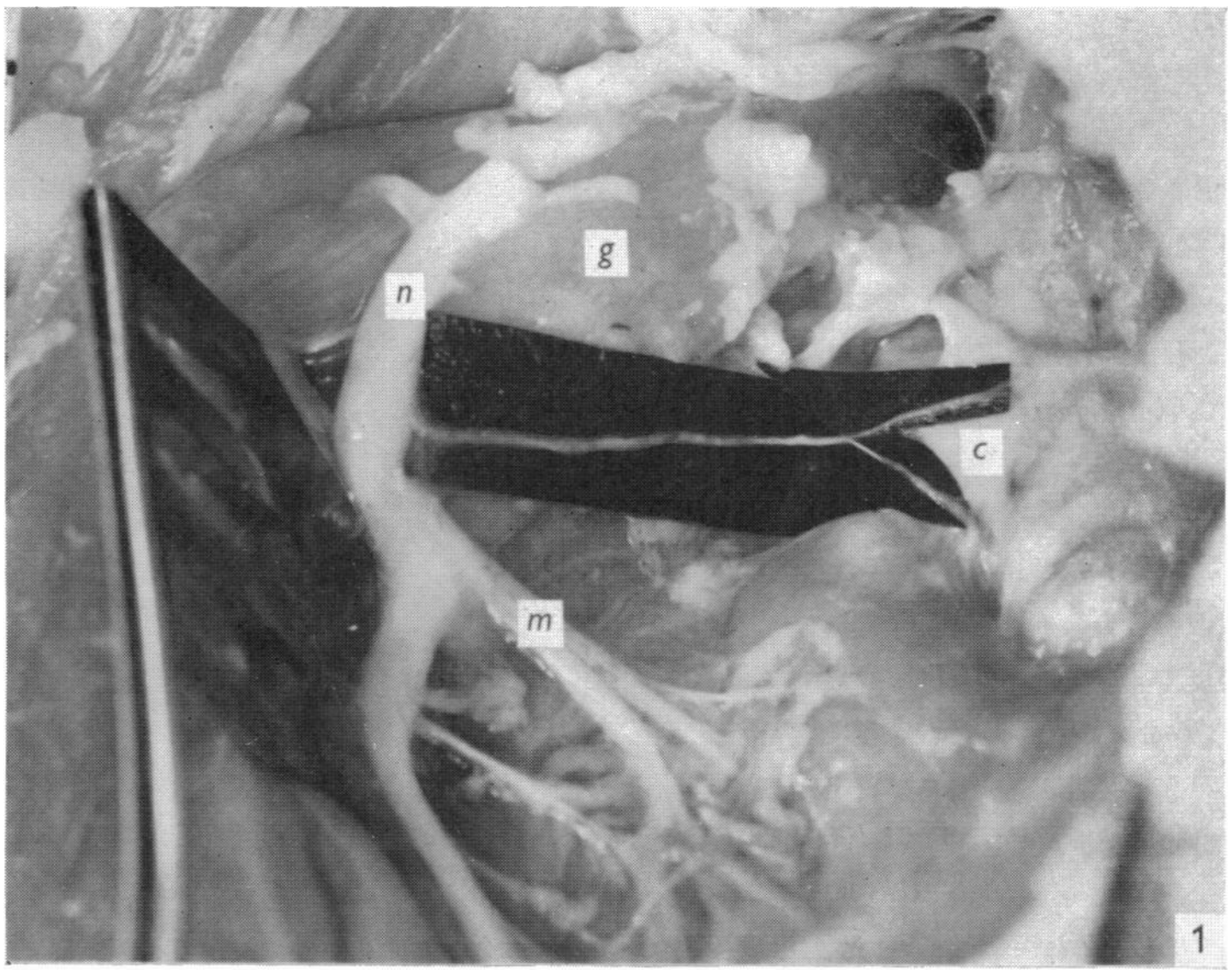

1

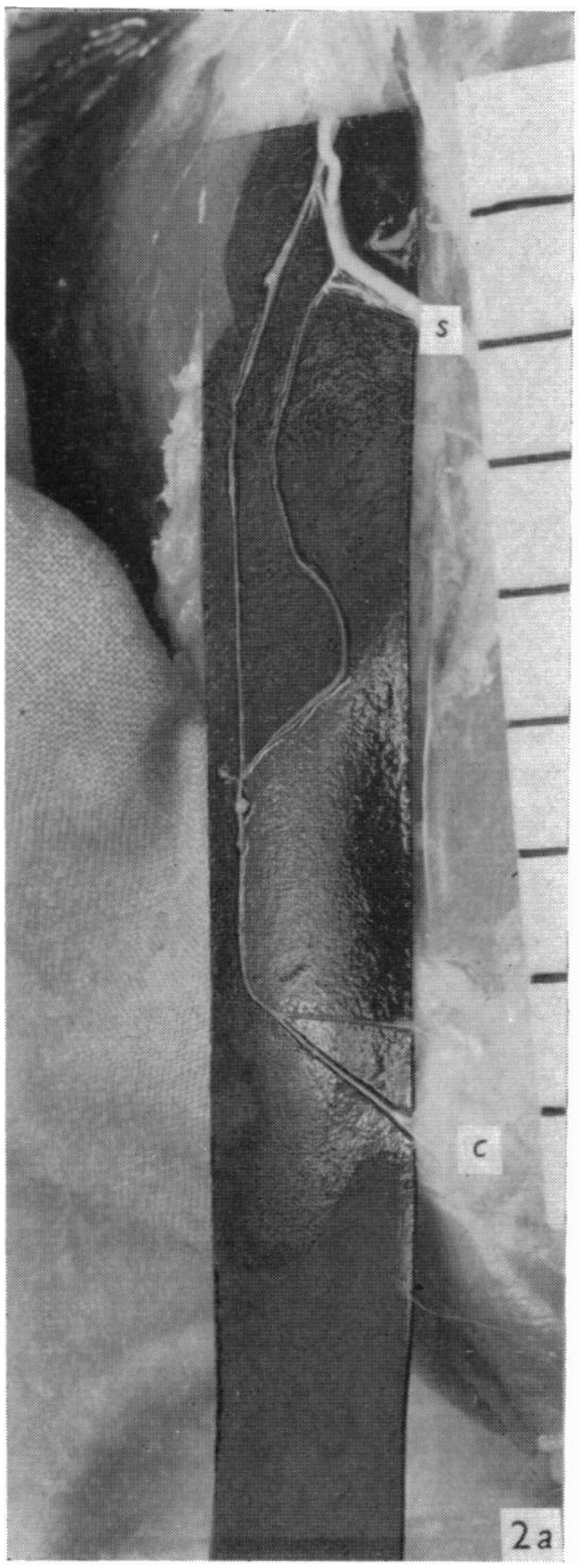

2a

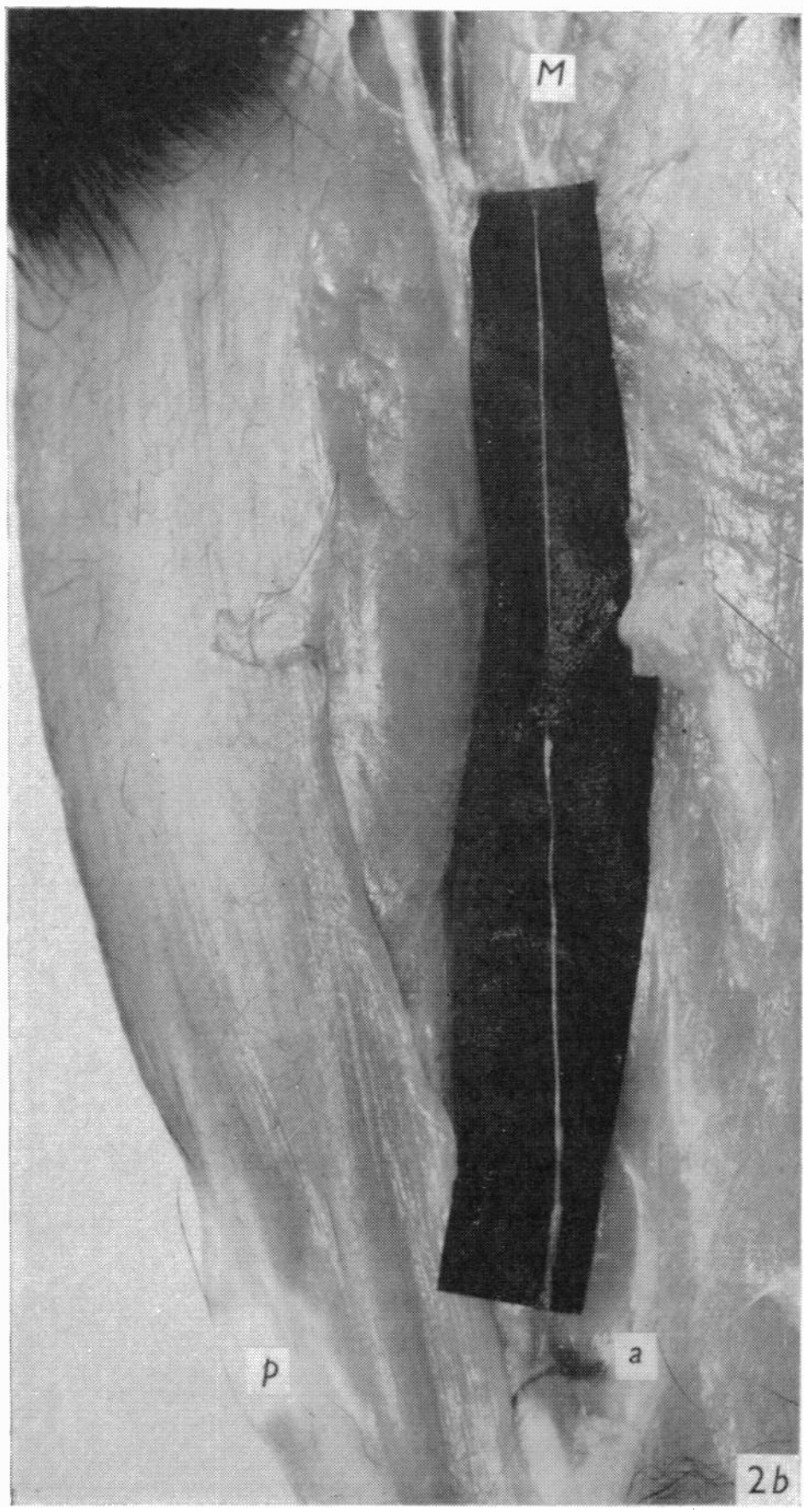

2b

nerves (*q.v.*). The PAN innervates only articular tissues of the knee joint (together with a small part of the superior tibio-fibular joint), and so is available experimentally as a pure articular nerve: its surgical exposure has been described by Freeman & Wyke (1966).

The total length of the posterior articular nerve—from its origin from the posterior tibial nerve to its bifurcation at the back of the knee joint—is 1·5–2·0 cm. The overall diameter of the nerve trunk averages about 0·9 mm. The average number of nerve fibres (both myelinated and unmyelinated) contained in the posterior articular nerve is 387. Of these nerve fibres, 58 % are myelinated and 42 % are unmyelinated: the largest myelinated nerve fibres are about 17 μm in diameter. These data are summarized in Table 1, for comparison with those of previous workers: for further details of the fibre diameter spectrum of this nerve see Wyke (1967).

The medial articular nerve (*MAN*). The medial articular nerve (Fig. 2) is a much finer and more variable nerve than the posterior articular nerve; but, like the latter, its distribution is entirely confined to the tissues of the knee joint.

The MAN arises in the antero-medial region of the thigh, usually as a branch of the saphenous nerve (Fig. 2*a*). In some animals it is derived from the obturator nerve (Fig. 2*b*), whilst in others it may be formed by fusion of branches from each of these nerves. When derived from the saphenous nerve, the MAN is given off as its first branch before it enters the subsartorial canal: but sometimes (as in Fig. 2*a*) the articular nerve arises by two rootlets from the saphenous nerve.

It joins the descending genicular artery and vein (*genu suprema* branches of the femoral artery and vein) immediately, and descends—embedded in the connective tissue ensheathing these vessels, and in the fascia over the vastus medialis muscle—deep to the medial edge of the sartorius muscle, to reach the upper medial aspect of the knee joint (Fig. 2). When derived from the obturator nerve, the MAN is given off deep to (or within) the adductor magnus muscle, and emerges through its antero-medial surface (Fig. 2*b*) to cross the femoral vein and join the descending genicular vessels in the upper thigh. In the more unusual double origin from both the saphenous and obturator nerves, the branch from the latter nerve pieces the superficial surface of the adductor magnus muscle to join the saphenous branch at the lower edge of the muscle: the common trunk thus formed descends with the genicular vessels to the knee joint.

In its course from the upper thigh to the knee joint, the MAN shows several variations in its relation to the descending genicular vessels. In the more common situation, the nerve is present as a single trunk embedded in the connective tissue binding the descending genicular artery and vein together, lying either on the antero-medial (*i.e.* superficial) or postero-lateral (*i.e.* deep) aspect of the vascular bundle as

---

Fig. 1. Dissection of the complete left posterior articular nerve (after removal of all the related blood vessels), showing its origin from the posterior tibial nerve (*n*), and its terminal bifurcation near the posterior capsule of the knee joint (*c*); (*m*) muscular branches of the posterior tibial nerve. The retractor is holding the lateral head of the gastrocnemius muscle (*g*). × 1·5.

Fig. 2. (*a*) Dissection of the right medial articular nerve, showing its origin by two branches from the saphenous nerve (*s*), and its terminal bifurcation near the medial capsule of the knee joint (*c*). × 1·1 (*b*) Dissection of the right medial genicular nerve emerging through the adductor magnus muscle (*M*) from its origin from the obturator nerve. (*a*) genicular artery, joined by the rostral branch of the medial articular nerve; (*p*) patella. × 1·5.

it descends beneath the sartorius muscle across the surface of the vastus medialis. Less often the nerve consists of two small trunks lying on either aspect of the vascular bundle—particularly when it has a double origin from the saphenous and obturator nerves, in which case the more posterior trunk contains the obturator fibres. Less often still, there is no medial articular nerve trunk; and the nerve is then represented by a leash of fine filaments that twine in a plexiform manner around the fatty connective tissue sheaths of the descending genicular vessels.

The MAN terminates at the upper border of the medial condyle of the femur by dividing (Fig. 2*a*) into two branches (proximal and distal), each of which gives off fine filaments that spread out to form a plexus on the medial surface of the capsule of the knee joint. This bifurcation occurs deep to the flattened lower end of the sartorius muscle, at the attachment of the joint capsule to the femur; and most of the terminal twigs of the two branches join the branches of the superior and inferior medial genicular arteries as they enter the joint capsule (Fig. 2*b*), or continue into the joint with the branches of the descending genicular artery. A few twigs from the proximal branch of the nerve curve forwards across the antero-medial aspect of the joint capsule to join a fine plexus on the surface of the ligamentum patellae, whilst others ramify over the external surface of the medial collateral ligament. Other twigs pass posteriorly from the distal branch of the nerve, beneath the tendons of the semimembranosus and gracilis muscles, to mingle with terminal filaments from the posterior articular nerve on the postero-medial aspect of the joint capsule.

The MAN appears to supply (Fig. 5) the medial and antero-medial aspects of the fibrous capsule of the knee joint, the medial collateral ligament, the medial part of the annular ligament attached to the medial meniscus, the ligamentum patellae and the infrapatellar fat pad, and the medial part of the patellar periosteum. Its terminal twigs overlap with those of the posterior articular nerve, and with the terminations of some of the accessory articular nerves (*q.v.*), as shown diagrammatically in Fig. 5. As stated above, it innervates only the tissues of the knee joint, and so (like the posterior articular nerve) is available experimentally as a pure articular nerve. Its surgical exposure is described by Freeman & Wyke (1966).

The total length of the medial articular nerve—from its origin from the saphenous nerve to its bifurcation at the supero-medial edge of the knee joint—is 7–8 cm. The average diameter of the nerve, when present as a single trunk, is 0·3 mm. The number of nerve fibres (both myelinated and unmyelinated) contained in the medial articular nerve averages 291. About 54 % of these nerve fibres are myelinated, and 46 % are unmyelinated (Table 1); and the largest myelinated fibres in the nerve have a diameter of about 16 μm. Further details of the fibre diameter spectrum of the nerve are given by Wyke (1967).

The lateral articular nerve (LAN). This nerve is an inconstant recurrent branch of the lateral popliteal nerve. It arises (Fig. 3) as a fine twig from the trunk of the lateral popliteal nerve as the latter approaches the back of the neck of the fibula across the lateral head of the gastrocnemius muscle, and runs upwards and forwards (embedded in the fascia on the surface of the lateral head of the gastrocnemius muscle) to the infero-lateral part of the capsule of the knee joint. As it approaches the posterior edge of the lateral collateral ligament it divides (as shown in Fig. 3) into two branches, one of which ascends along the ligament to break up into fine filaments that ramify over the rostral part of the ligament and the infero-lateral part of the fibrous capsule of the knee joint. The other branch runs obliquely upwards to the posterior edge of the lateral condyle of the knee joint, where it ramifies in the related parts of the joint capsule (Fig. 5).

Table 1. *Composition of primary articular nerves to the knee joint*

(Figures in parentheses are percentages of the total nerve fibre counts.)

	Posterior articular nerve			Medial articular nerve		
	Total number of fibres (mean)	Myelinated fibres (mean)	Un-myelinated fibres (mean)	Total number of fibres (mean)	Myelinated fibres (mean)	Un-myelinated fibres (mean)
Sasaoka (1939*a*, *b*)	225	159 (70·5)	66 (29·5)	—	—	—
Gardner (1944)	286	171 (59·8)	115 (40·2)	266	144 (54·1)	122 (45·9)
Skoglund (1956)	—	176	—	—	145	—
Fidel'-Osipova *et al.* (1961)	—	150	—	—	120	—
Freeman & Wyke (1967)	387	224 (58)	162 (42)	291	157 (54)	131 (46)

A second twig is usually given off from the lateral popliteal nerve about 5 mm distal to the origin of the lateral articular nerve (Fig. 3). Almost at once, this twig divides into an ascending and a descending branch; the ascending branch runs upwards and forwards to supply the capsule of the superior tibio-fibular joint and the lower end of the lateral collateral ligament, whilst the descending branch curves forwards (parallel with the lateral popliteal nerve) to enter the peroneal muscle mass (Fig. 3). In some instances, however, this second twig does not arise from the lateral popliteal nerve independently of the LAN, but instead the two nerves arise in common. The LAN then appears to give off branches that innervate the superior tibio-fibular joint and the peroneal muscles, as well as the infero-lateral tissues of the knee joint.

Accessory articular nerves

As Hilton (1863) suggested long ago for joints in general, the knee joint of the cat is also innervated by articular branches arising from the nerves supplying some of the muscles operating over the joint. These intramuscular articular nerves arise within the substance of the muscles from branches of the main muscle nerves and run to the knee joint between the muscle fasciculi, sometimes passing through or along the related tendons and aponeuroses.

The disposition of the intramuscular articular nerves supplying the knee joint in the cat is extremely variable from animal to animal, and no constant pattern can be identified. For descriptive purposes, however, these nerves can be considered in terms of the individual muscles within which they have been traced. In general, the accessory intramuscular articular nerves are more numerous in muscles above the knee joint than below it, and are present in extensor muscles of the joint rather than in flexors.

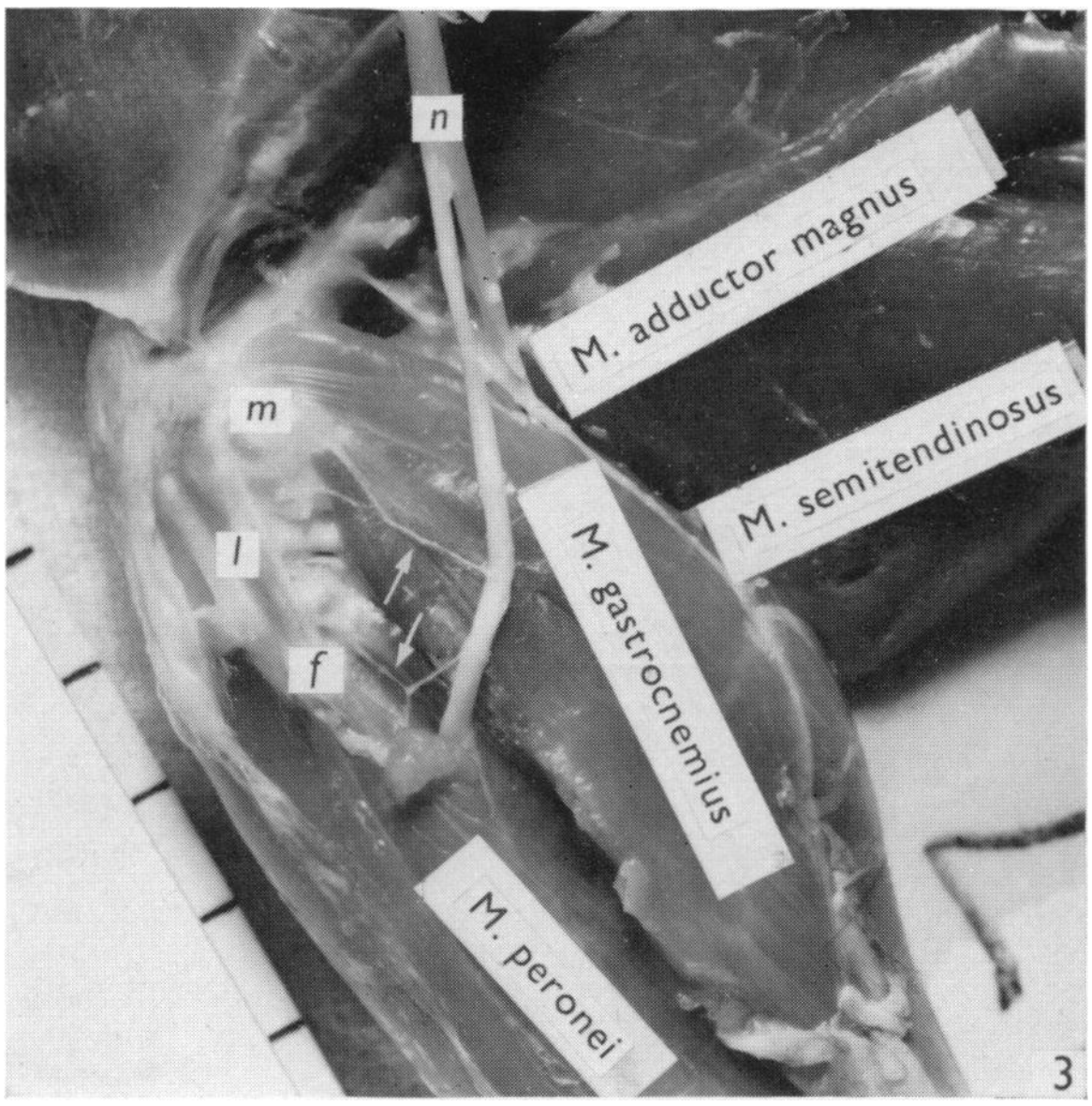

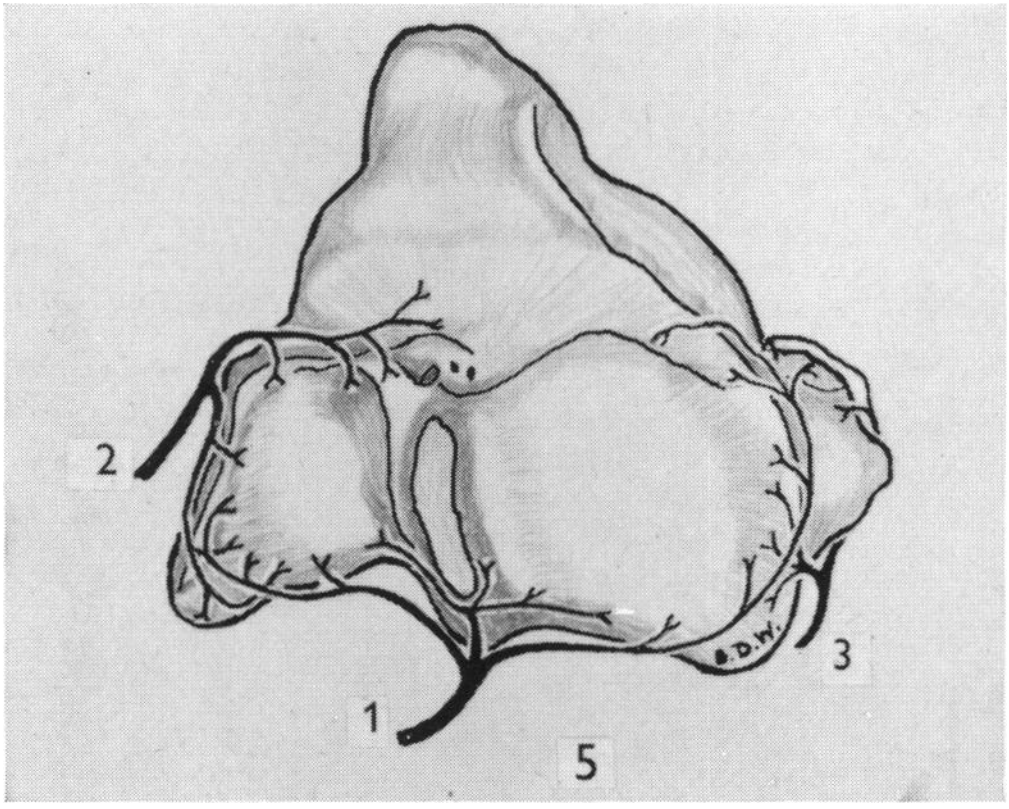

Fig. 3. Dissection showing the lateral articular nerve (indicated by upper arrow) arising from the lateral popliteal nerve (*n*); (*m*) lateral capsule of knee joint; (*l*) lateral collateral ligament; (*f*) tibio-fibular joint. The lower arrow shows the supplementary articular nerve to the tibio-fibular joint. × 1·1.

Fig. 4. Dissection showing the termination of accessory articular filaments (lower arrow) derived from an intramuscular nerve in the vastus intermedius muscle (upper arrow) in the capsule of the knee joint (*k*). (*F*) femoral nerve; (*O*) obturator nerve. × 1·1.

Fig. 5. Diagram showing the distribution of the posterior articular (1), medial articular (2) and lateral articular (3) nerves to the right knee joint of the cat. The nerves are depicted in relation to the tibial surface of the joint, viewed from above.

Vastus intermedius. The most regular of the intramuscular articular nerves is present in the vastus intermedius muscle. This nerve (Fig. 4) is formed as a single trunk within the rostral part of the muscle by the fusion of twigs from muscular branches of the femoral and obturator nerves (both of which supply the vastus intermedius muscle in the cat). It then descends in the substance of the muscle close to the medial side of the femur (Fig. 4), accompanied by an intramuscular artery and vein. About 2 cm rostral to the medial condyle of the femur the nerve curves posteriorly within the muscle, and breaks up into fine filaments that pass from its deep surface into the periosteum covering the antero-medial aspect of the lower end of the femur (as shown in Fig. 4). These filaments then terminate in the patellar periosteum, the upper end of the ligamentum patellae and the infrapatellar fat pad, the upper end of the medial collateral ligament, and the capsule of the knee joint over the medial condyle of the femur. Some twigs may also reach the lining of the suprapatellar bursa. Occasionally, additional articular branches of the muscle nerves may be found running to the knee joint in more superficial and medial parts of the muscle.

Vastus medialis. Sometimes the intramuscular branches of the femoral nerve supplying this muscle may give off descending articular twigs that run to the knee joint. A few of these twigs pass down to the quadriceps tendon within the deep parts of the muscle, close to the femur, whilst others are more superficially placed in the medial parts of the muscle. The articular filaments extend along the medial edge of the quadriceps tendon to reach the patellar periosteum, the ligamentum patellae, the supero-medial part of the joint capsule at its attachment to the femur, and possibly the rostral end of the infrapatellar fat pad.

Vastus lateralis. Branches of the femoral nerve supplying this muscle may give off one or more fine twigs at its rostral end that descend, close to the femur in the substance of the muscle, to the quadriceps tendon. The terminations of these twigs then run along the lateral edge of the patella (to whose periosteal plexus they contribute) to reach the proximal end of the ligamentum patellae and the underlying fat pad, and the antero-lateral part of the femoral attachment of the capsule of the knee joint.

Rectus femoris. This muscle receives branches from the femoral and obturator nerves in its upper one-third; and twigs from these two sources combine within the muscle to form one or two descending articular nerves. These run to the quadriceps tendon in the deep surface of the muscle, or in its posterior fascial sheath, and fan out on the deep surface of the tendon into the patellar periosteum, the suprapatellar bursa and the intercondylar attachment of the capsule of the knee joint.

Sartorius muscle. Very rarely, elevation of the flat aponeurotic attachment of the lower end of this muscle discloses a few fine nerve filaments passing from its deep surface into the lower part of the medial capsule of the knee joint. These filaments are derived from the intramuscular branches of the femoral nerve that supply the muscle.

Gastrocnemius muscle. Equally rarely, the nerve to the *medial head* of the gastrocnemius muscle (arising from the medial popliteal nerve in the popliteal fossa) may give off an articular twig just before, or as it enters the muscle belly. This twig then turns anteriorly and laterally to enter the middle of the posterior capsule of the knee joint in front of the popliteal vessels. It is also possible that, in those instances in which the LAN (see above) is absent, it may be replaced by an intramuscular articular twig that sometimes runs through the *lateral head* of the gastrocnemius into the postero-lateral part of the knee joint capsule.

Intramuscular articular nerves have not been found by us in any of the other muscles related to the knee joint, although they have been sought. Such muscles, however, have not yet been examined (by us, or by others) in a sufficient number of animals to be able to state whether or not their nerve supply may contribute occasionally to the innervation of the tissues of the knee joint.

Articular nerve endings in the knee joint

As revealed by the histological techniques mentioned at the beginning of this paper, the nerve endings present in the tissues of the cat's knee joint (and innervated from the extrinsic articular nerves just described) may be classified morphologically into four main categories (Table 2). This classification also has functional correlates (Wyke, 1961); and its physiological implications are described by Wyke (1966, 1967). Three of these categories of articular nerve ending (types I, II and III) appear to function as mechanoreceptors of differing behavioural characteristics, discharging impulses into myelinated afferent fibres in the articular nerves. The remaining category of ending (type IV) comprises unorganized nerve terminals, some of which function as pain-receptors whilst others are visceral efferent (vasomotor) endings.

An arbitrary numerical classification has been adopted for the articular nerve endings to avoid the preconceptions inherent in, and the confusion caused by, attempts to homologize them with nerve endings in non-articular tissues. The features to be described for each of the categories of ending listed in Table 2 are those that emerge from a mutual comparison of the findings obtained with the histological procedures noted at the beginning of this paper; and all regions and tissues of the knee joint were examined for this purpose.

Type I endings

These nerve endings (Fig. 6) are globular or ovoid encapsulated corpuscles, averaging 100 μm in maximum diameter and 40 μm in minimum diameter. Each corpuscle consists of a fine, filmy capsule enclosing a coarse arborization of coiled and beaded unmyelinated nerve fibres embedded in a slightly granular amorphous matrix. The capsule is made up of one or two layers of connective tissue cells disposed tangentially; and at one side of the corpuscle there is a small hilar indentation that gives it a bean-shaped appearance. At this hilum, a small myelinated terminal axon about 2–5 μm in diameter enters the corpuscle, loses its myelin lamellae at this point so that its last node of Ranvier is located at the hilum, and breaks up into between three and five unmyelinated branches from which further filaments arborize within the corpuscle.

A slender capillary blood vessel approaches each corpuscle alongside the axon, and breaks up into fine capillary arcades on its capsular surface; and from these arcades, still finer capillary twigs enter the substance of the corpuscle by penetrating through its capsule to ramify amongst the arborizing nerve terminals. A very fine unmyelinated accessory axon also enters the corpuscle alongside the main axon, and then breaks up into filaments that are distributed along the walls of the intracorpuscular capillary twigs.

Type I endings are found mainly in the fibrous capsule of the joint—particularly in its peripheral (*i.e.* superficial) layers (Fig. 6), where they are disposed three-dimensionally in small clusters of three to six corpuscles—on all aspects of the joint. Each member of such a cluster is innervated from the same parent axon, which is a small myelinated nerve fibre (usually 5–8 μm in diameter, but sometimes as large as 10 μm) that breaks up into the appropriate number of terminal branches, each some 2–5 μm in diameter (Fig. 6). From a functional point of view the receptor unit is not an individual type I corpuscle, but the cluster of such corpuscles, each member of which is innervated from the same afferent nerve fibre in the related articular nerve. It should also be noted that no axon that supplies such a cluster of type I endings contributes branches to any other of the types of nerve ending described below.

Table 2. *Characteristics of articular nerve endings*

Type	Primary morphological features	Average dimensions (μm)	Location	Diameter of parent nerve fibre (μm)	Principal functional characteristics	Previous eponymous or descriptive designations
I	Globular or ovoid corpuscles. Fine capsule (1–2 layers). Arborizing nerve terminal. Linked in clusters of 3–6 corpuscles	100 × 40	Fibrous capsule (diffuse in peripheral layers). (A few on extrinsic ligaments, and in para-articular periosteum and related tendons)	5–8 (small myelinated)	Mechanoreceptor, afferent (low threshold, slowly adapting)	Ruffini ending. Golgi–Mazzoni ending. Meissner corpuscle. Spray-type ending. Basket ending. Ball-of-thread ending. Bush-like ending
II	Cylindrical or conical corpuscles. Thick laminated capsule (up to 10–12 layers). Single nerve terminal:* may be bifid or trifid. Linked in clusters of 2–3 corpuscles	280 × 120	Fibrous capsule (in groups in deeper layers, fibro-adipose junctions, fat pads. Near blood vessels)	8–12 (medium myelinated)	Mechanoreceptor, afferent (low threshold, rapidly adapting)	Krause's Endkörperchen. Vater'schen Körper. Pacinian corpuscle. Vater-Pacinian corpuscle. Modified Pacinian corpuscle. Simple Pacinian corpuscle. Paciniform corpuscle. Golgi–Mazzoni body. Meissner corpuscle. Gelenknervenkörpenschen. Corpuscle of Krause. Club-like ending. Bulbous corpuscle. Corpuscula nervosa articularia
III	Fusiform corpuscles. Thin capsule (1–3 layers). Densely arborizing nerve terminal. Usually single, but occasionally linked in clusters of up to 3 corpuscles.	600 × 100	Ligaments (intrinsic and extrinsic). (Also in related tendons)	13–17 (large myelinated)	Mechanoreceptor, afferent (high threshold, very slowly adapting)	Golgi ending. Golgi–Mazzoni corpuscle
IV	(*a*) Unmyelinated plexuses.	< 1·5	Fibrous capsule. Ligaments. Fat pads. Adventitia of blood vessels. Subsynovial tissue. (Related tendons and periosteum)	2–5 (fine myelinated)	Pain receptor, afferent (non-adapting)	—
	Unmyelinated free nerve endings	0·5–1·5	Ligaments (and related tendons)	< 2 (unmyelinated)	„	—
	(*b*) Unmyelinated nerve terminals	< 1·0	Walls of small arteries and arterioles	< 2 (unmyelinated)	Vasomotor, efferent	—

* In some species (*e.g.* the dog (*see* Poláček, 1963)) multiple filamentous axons may replace the single axon in the type II ending; but this does not occur in the cats' knes joint (although it has been observed very rarely in type II receptors in the laryngeal joints of the cat (Kirchner & Wyke, 1964*a*).

The type I endings are present at or near the surface of all regions of the fibrous capsule of the knee joint; but they are more densely aggregated on the posterior and anterior aspects of the joint than on its medial and lateral sides. They become much less numerous in the deeper layers of the fibrous capsule; and they are entirely absent from the subsynovial and synovial tissues of the joint, and from the articular fat pads. Similar endings (ovoid rather than globular) are present in small numbers on the surfaces of joint ligaments—such as the medial and lateral collateral, and pos-

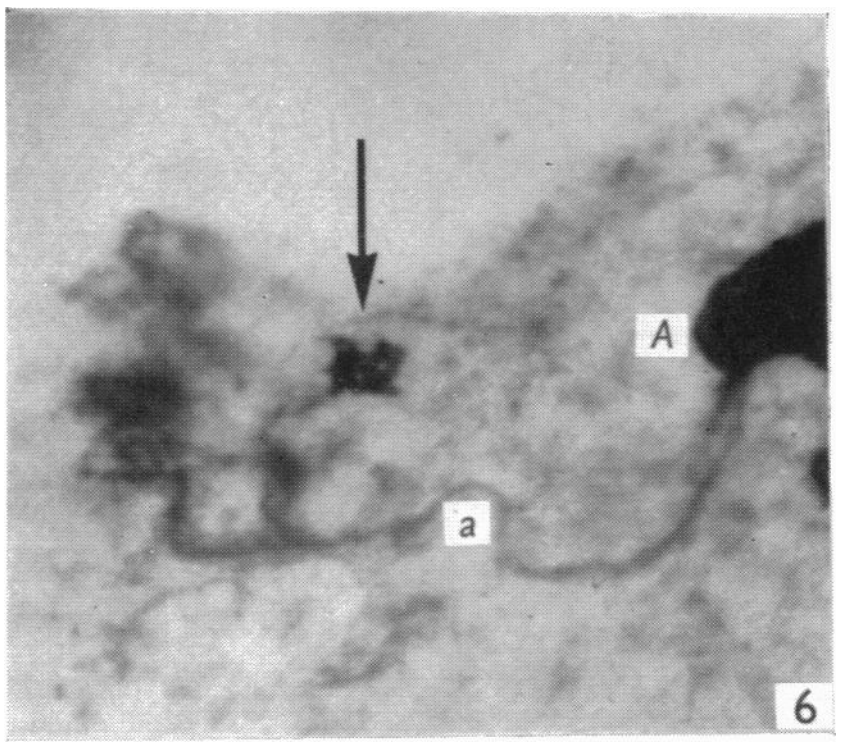

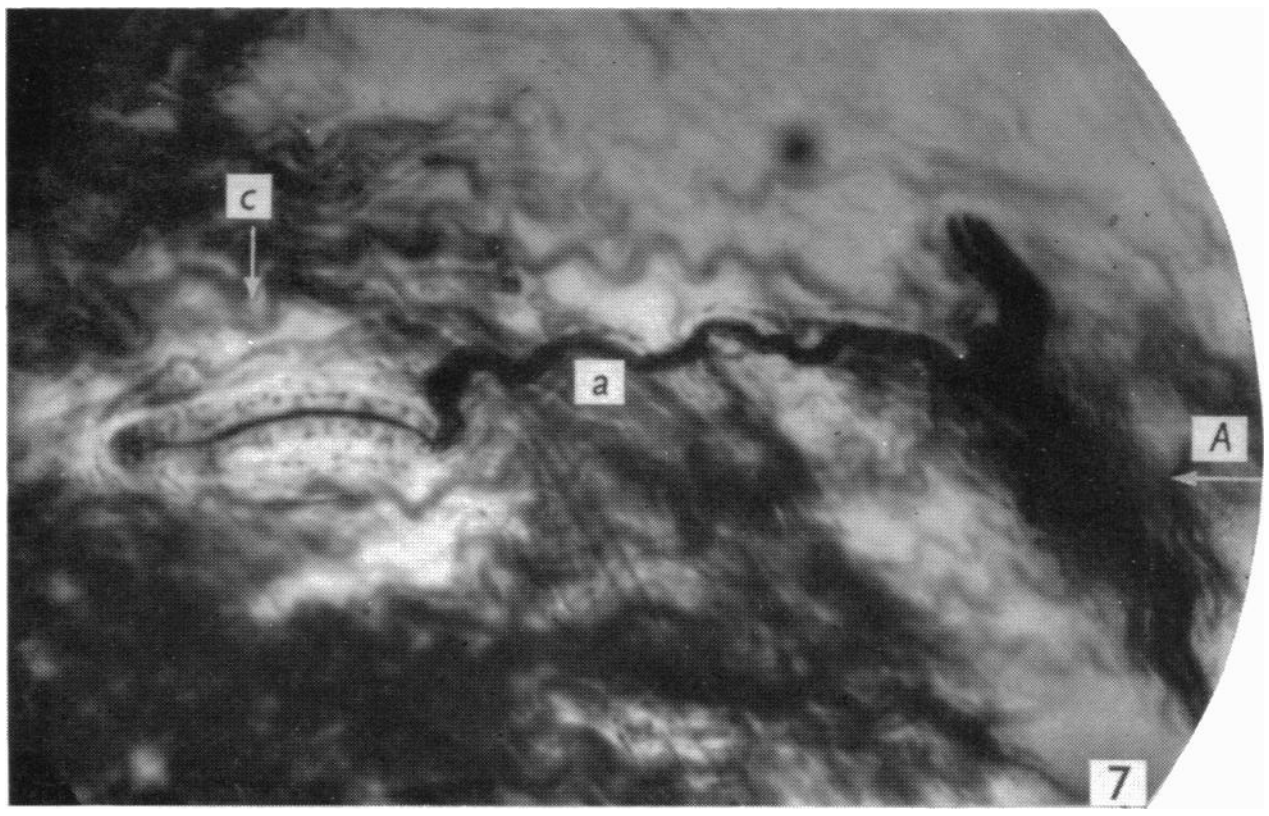

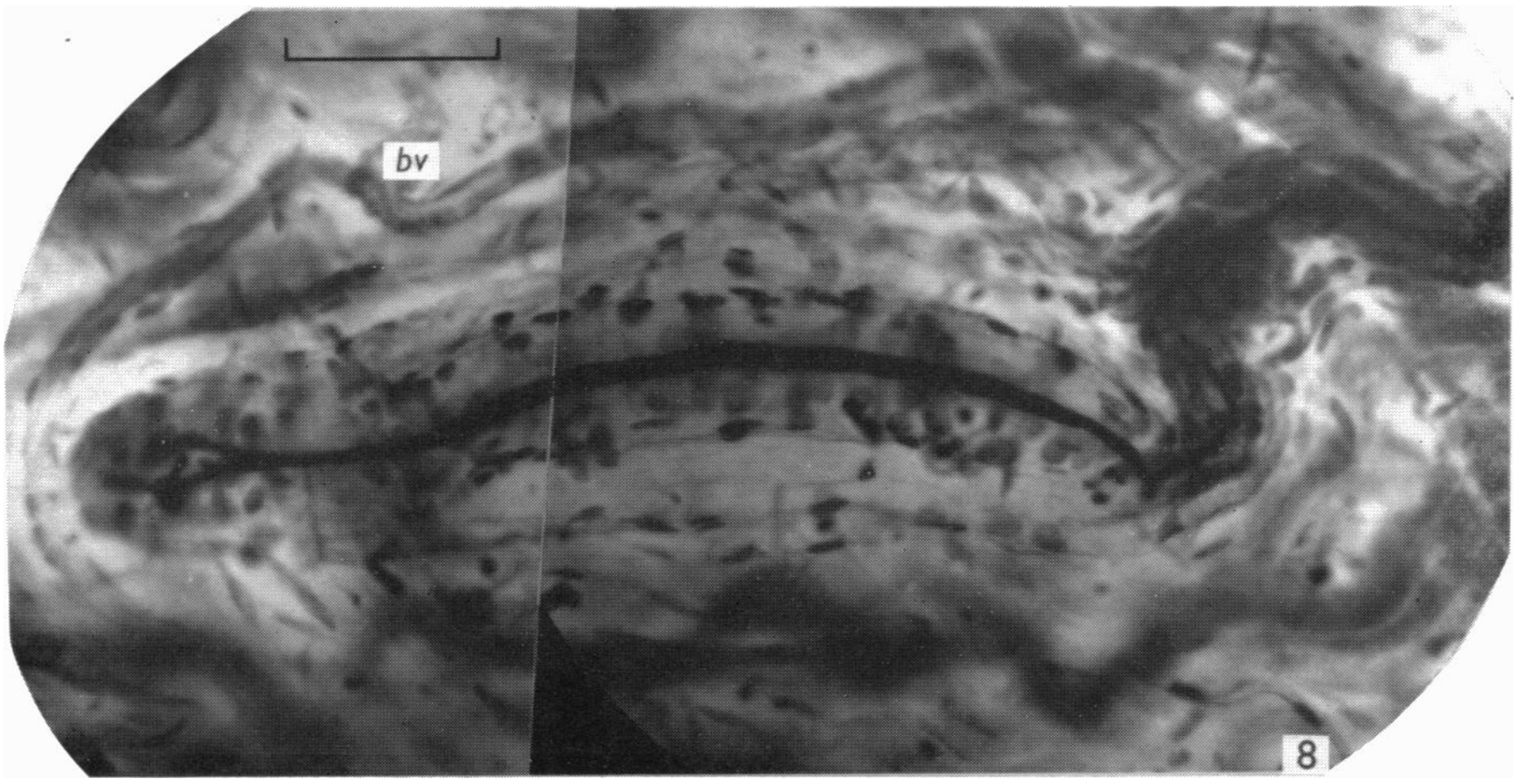

Fig. 6. Portion of a cluster of type I corpuscles (one of which is indicated by the arrow) at the surface of the fibrous capsule of the knee joint. The afferent fibre (*a*) joins a larger parent articular nerve fibre (*A*). Gold chloride preparation. × 670.

Fig. 7. Type II corpuscle (*c*) embedded in the deep layers of the fibrous capsule of the knee joint. The thick fibrous capsule of the corpuscle, encircled by a capillary loop and enclosing the palisade layer of cells and the central axon, can be seen. The afferent fibre (*a*) joins a larger parent axon (*A*) on the right, from which other branches supply further type II corpuscles (not in the plane of this section). Frozen silver preparation (30μm section). × 200.

Fig. 8. Higher power photo-montage of the type II corpuscle in Fig. 7, to show the structural details described in the text. The encircling capillary arcade is indicated (*bv*). Frozen silver preparation (30 μm section). × 1600.

terior oblique ligaments—near their capsular attachments, at the edges of the ligamentum patellae, and in the superficial layers of the annular ligaments at the periphery of the menisci where they blend with the joint capsule. These endings are not present in the cruciate ligaments, nor in the joint menisci themselves.

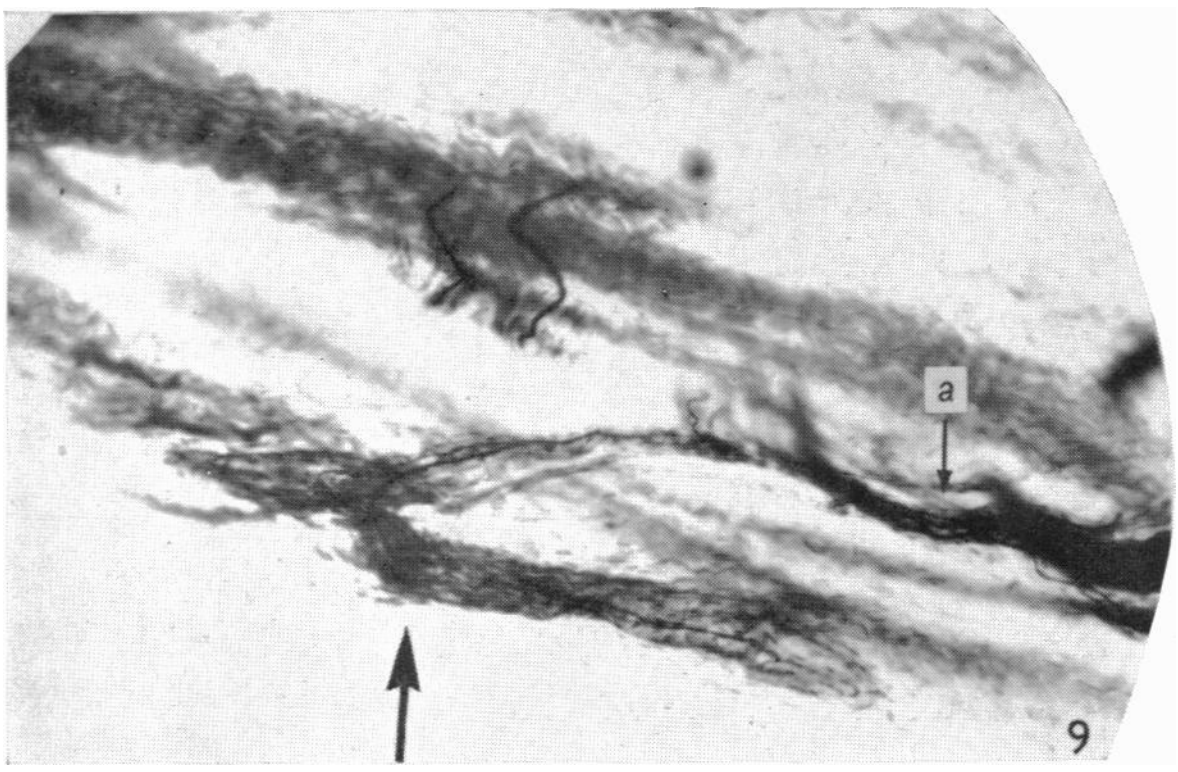

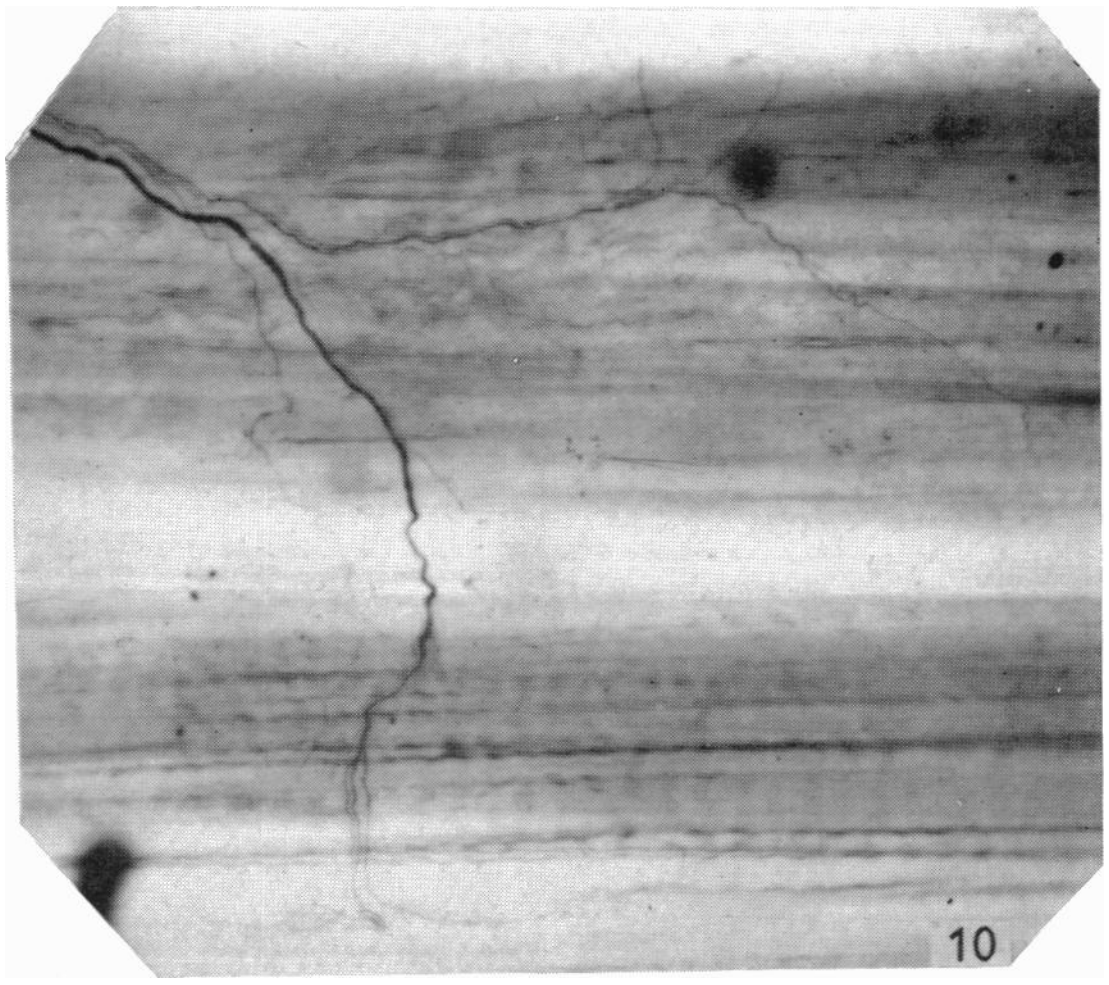

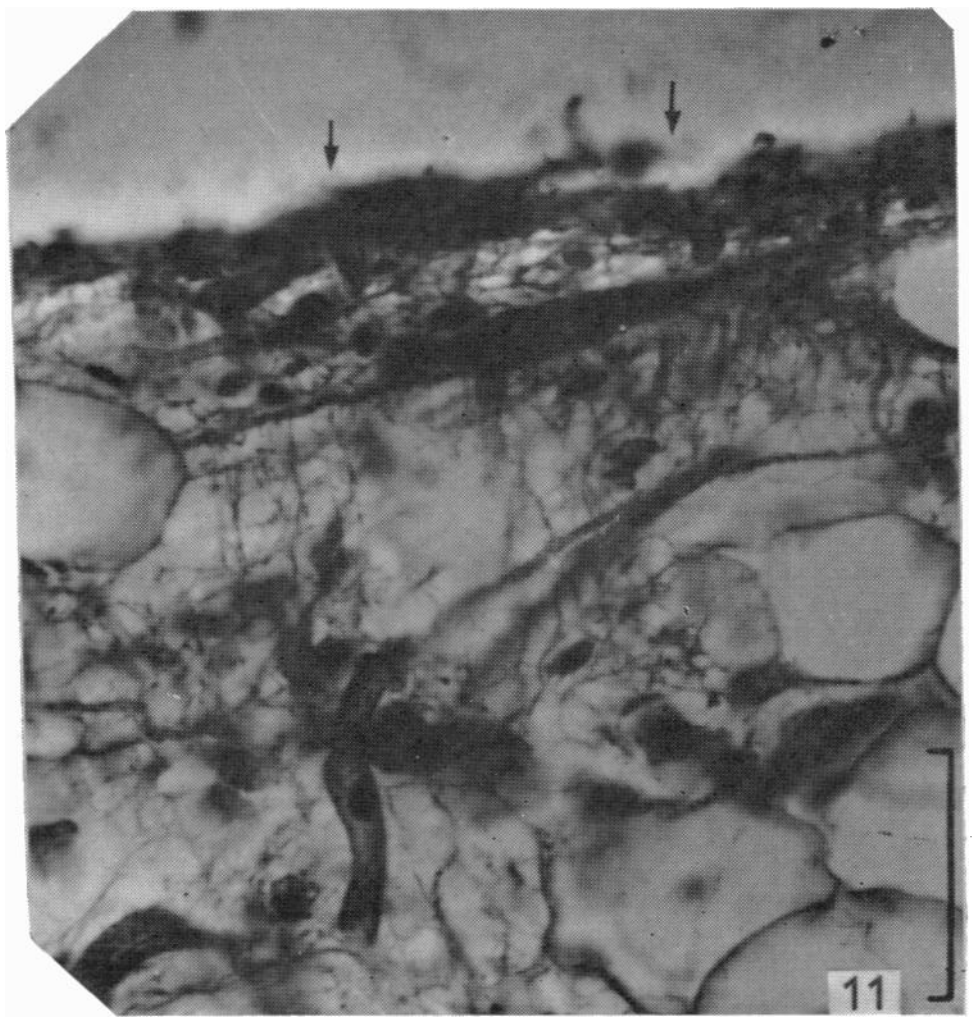

Fig. 9. Type III corpuscle (large arrow) on the surface of the tibial attachment of the posterior cruciate ligament of the knee joint. The afferent fibre is indicated by the small arrow (*a*). Frozen silver preparation (30 μm section). × 200.

Fig. 10. Type IV (*a*) free nerve endings ramifying amongst the fibres of the lateral collateral ligament of the knee joint. Frozen silver preparation (30 μm section). × 200.

Fig. 11. The dense fibrillary appearance presented by the subsynovial tissue of the knee joint in methylene blue preparations. Synovial surface indicated by arrows. Methylene blue preparation (80 μm section). × 800.

Occasional clusters of type I endings are also present on the surfaces of the tendons and aponeuroses that are closely related to the capsule of the knee joint; and rather more are located in the femoral and tibial periosteum at the points of attachment of the fibrous capsule. A few such endings are likewise present in the peripheral edges of the patellar periosteum.

Type II endings

Type II end-organs (Figs. 7, 8) are elongated, conical corpuscles averaging 280 μm in length and 120 μm in diameter. Each corpuscle (Fig. 8) has a thick (60–100 μm), multi-laminated connective tissue capsule containing elongated fibroblast nuclei in which up to twelve layers may be recognized. This capsule is thicker near the base of the corpuscle (where the afferent axon joins it) and tapers off towards the apex, so that the end-organ usually has the form of a blunt cone in outline (Fig. 7). At the base of the corpuscle a terminal myelinated nerve fibre (some 5μm in diameter) joins the end-organ, and there loses its myelin lamellae so that the last node of Ranvier is located at or just within the base of the cone. A single unmyelinated axon then continues on (often expanded by as much as 30 % in relation to the diameter of the extra-capsular axon (Fig. 8)) in the central axis of the corpuscle, to terminate near its tip either in a small bulbous expansion or in a Y-shaped bifurcation.

Within the connective tissue layers of the capsule of the end-organ, the central axon is ensheathed (Figs. 7, 8) by a palisade-like layer of columnar cells with a clear but slightly granular cytoplasm, and with peripherally situated nuclei. These palisade cells appear morphologically to be an intra-corpuscular extension of the Schwann cell sheath that invests the extra-corpuscular axon; but they contain no myelin lamellae, and are more closely packed (and are more columnar in shape) than the extra-corpuscular Schwann cells. Furthermore, the staining reactions of the intra-corpuscular palisade cells—in both gold and silver preparations—are different from those of true Schwann cells. Some previous workers have taken this palisade layer of cells to be the sheath of the corpuscle, and so have given figures for its dimensions (about 200 μm × 30 μm) that are smaller than those noted above (Table 2). The diameters of the type II ending that we have measured include the whole of the connective tissue sheath of the corpuscle, and so represent the entire width and length of the end-organ.

As with the type I endings, a capillary blood vessel is specifically related to each type II corpuscle. In Figs. 7 and 8, this blood vessel approaches the base of the corpuscle alongside the axon, and then loops around the external surface of the entire connective tissue sheath to form a capillary arcade with the end-organ lying in its concavity. From this arcade, finer capillary twigs pass centripetally into the connective tissue sheath of the corpuscle, to ramify amongst its multiple layers. Again like the type I endings, one or more fine accessory unmyelinated nerve fibres may be related to the type II corpuscle and its capillary system.

The type II endings, like the type I corpuscles, are found mainly in the fibrous capsule of the knee joint; and in places, the two types of ending intermingle—although always innervated from independent parent articular nerve fibres. However, the distribution of the type II endings in the joint capsule is different from, and spatially more restricted than that of the type I endings. A few type II endings are present occasionally (mainly posteriorly) in the more superficial layers of the fibrous capsule, along with larger numbers of type I endings; but in all regions of the joint most of them are distributed in clusters of two to four endings in the deeper (*i.e.* internal) layers of the fibrous capsule. They are particularly located at the junction between the deep layers of the fibrous capsule and the fibro-adipose subsynovial tissue, usually in close proximity to (or extended alongside) the branching articular blood vessels. Clusters of type II endings are present on all aspects of the knee joint, but are more numerous on its medial and lateral sides than on its anterior and posterior aspects—in contrast to the type I endings. They are also present on the surfaces of the lobulated articular fat pads, where these are attached to the joint capsule; but they are entirely absent from all the joint ligaments, from the joint menisci and from the synovial tissue itself. A few type II endings are present, amongst larger numbers of type I endings, beside the blood vessels passing between the tibial and femoral periosteum and the attachments of the joint capsule, and in the sheaths of the tendons related to the knee joint.

Each member of a cluster of type II endings is innervated by a small myelinated axon, between 4 and 5 μm in diameter, that branches from a larger parent myelinated nerve fibre (Fig. 7) some 8–12 μm in diameter—but which may be as much as 14–15 μm in diameter in the case of the larger clusters. Like the type I endings, then, the type II corpuscles are arranged in receptor units of several endings, each unit being innervated from a single afferent fibre in the related articular nerve. This afferent fibre, however, is of larger diameter than that supplying receptor units of the type I variety—although the number of corpuscles in a type II unit is smaller. Afferent fibres from type II endings therefore have a faster conduction velocity than type I afferents, and display a lower threshold to direct electrical stimulation of the articular nerve trunks.

Within any one joint capsule, the type II corpuscles display individual variations in morphology that may indicate different degrees of maturation (see below). In their simplest form, the corpuscles are single cones that may be straight, curved or bent in their long axis (Figs. 7, 8), or coiled in a spiral around a blood vessel. Most of the type II endings in any joint are of this unitary form; but more elaborated forms are always present in numbers that vary from joint to joint. Thus, in all joints there are some bifid forms of the type II ending, in which the corpuscle divides into two cones from a common base; and rarely, trifid forms are present as well. In these instances, the central axon passes into the common base of the end-organ, after losing its myelin lamellae, for some 30–40 μm; it then breaks up into two or three divergent branches, each of which extends into a separate terminal cone. Different members of the same cluster of type II endings may display these varying morphological features; and such multiplied forms of the type II corpuscle are encountered especially in relation to the branching blood vessels at the junction between the deep layers of the fibrous capsule and the fibro-adipose sub-synovial tissue.

Type III endings

The type I and type II articular endings are alike in that their distribution is largely within the fibrous capsule of the knee joint. In contrast, the type III endings (Fig. 9) are distinguished by the fact that they are entirely absent from the capsular tissues of the joint, being confined instead to the joint ligaments (both extrinsic and intrinsic*). The type III articular ending, then, may be regarded as the characteristic ligament receptor.

Each type III ending (Fig. 9) is a large fusiform body measuring some 600 μm in length and 100 μm in maximum width, enclosed in a fine connective tissue capsule containing one to three layers of tangentially disposed cells. It is applied in plate-like fashion to the surface of the ligament, its capsule blending with the connective tissue elements that ensheath the fibres of the ligament. The long axis of the end-organ is disposed in the long axis of the related ligament, usually with one end-organ at one or other end of the ligament. Sometimes however (as in the cruciate, medial collateral and patellar ligaments), there may be a cluster of two or three type III endings at either end of the ligament.

Type III endings are each innervated from a large myelinated afferent fibre about 14–16 μm in diameter that enters the capsule from the side, near the middle of the end-organ, and immediately breaks up into diverging branches from which densely arborizing filaments arise within the end-organ. The parent axon loses its myelin lamellae as it enters the end-organ, so that all the intracorpuscular branches are unmyelinated. The intracorpuscular filaments show multiple fusiform or globular expansions along their length, whose presence gives the end-organ a coarsely granulated appearance—and such expansions are apparent in both silver and gold stained material, as well as in methylene blue preparations.

These corpuscles are the largest end-organs present in the articular tissues of the knee joint, and their afferent nerve fibres constitute the largest (and hence the fastest conducting and most excitable) fibres in the articular nerves supplying the joint. When there is more than one type III ending in relation to a ligament, each corpuscle is smaller (about 450 μm × 100 μm) than when there is a solitary ending; and all the endings are then innervated together as a cluster, from a common parent axon that is 16–17 μm in diameter. No accessory unmyelinated axons have been found to innervate the type III endings, nor do they have any particular relation to blood vessels—indeed, they lie in the least vascular of all the articular tissues.

Type III endings have been identified in all the ligaments related to the knee joint—that is, in the medial and lateral collateral and posterior oblique ligaments, in the anterior and posterior cruciate ligaments, and in the ligamentum patallae. However, similar end-organs—the tendon organs of Golgi—are present in all the tendons related to the knee joint; and there is every reason to believe (see below) that the type III endings represent the articular equivalent (both structurally and functionally) of the tendon organs.

Type IV endings

The three types of articular nerve ending described thus far are all well differentiated corpuscular end-organs. The type IV variety of articular nerve ending consists of relatively undifferentiated non-corpuscular terminations, composed of unmyelinated nerve filaments.

This category may be subdivided into unmyelinated receptor endings in the form

---

* In this paper, the term 'extrinsic' refers to ligaments outside the joint cavity (*i.e.* ligaments in or attached to the joint capsule), whilst the term 'intrinsic' refers to the internal (*i.e.* cruciate) ligaments.

of plexuses or free nerve endings (type IV*a*), and unmyelinated efferent terminals (type IV*b*). The former group of endings is widely distributed throughout most (but not all) of the articular tissues of the knee joint, whilst the latter group innervates the smooth muscle tissue in the walls of the articular blood vessels. It is probable that the type IV*a* endings constitute the pain-sensitive system of the joint tissues, whereas the type IV*b* endings represent the vasomotor innervation of the joint vasculature.

Type IVa endings

The type IV*a* endings are present in two forms in the articular tissues. In one form, unmyelinated nerve fibres (each between 0·5 and 1·5 μm in diameter) are distributed throughout the articular connective tissues as a close-meshed *network*. Afferent nerve fibres (also unmyelinated) leave the network at its nodes, and join larger parent axons that are often thinly myelinated (and then range in diameter from about 2–5 μm). These latter nerve fibres course through the articular tissues usually in company with blood vessels—although some also run independently through the fibrous and adipose tissues of the joint capsule. Networks of this type are dispersed throughout the fibrous capsule of the knee joint, and through the adjacent periosteum on the tibia, femur and patella; they are distributed throughout all the articular fat pads (where they are more closely meshed than elsewhere in the joint tissues); and they are present in the adventitial sheaths of all the small arteries and arterioles in the articular tissues. Such networks are absent, however, from the joint ligaments and menisci, and from the synovial tissue itself.

The second form of type IV*a* ending consists of tapering unmyelinated *free nerve terminals* (Fig. 10), whose diameter is often less than 1 μm. They branch out between the collagen and elastic fibres of the articular connective tissues from parent axons that are themselves usually unmyelinated and whose diameter is 1–2 μm. Some groups of free nerve endings also arise as the terminal ramifications of thinly myelinated nerve fibres that are between 2 and 4 μm in diameter. These unmyelinated and myelinated parent axons are themselves intra-articular extensions of the small (less than 5 μm) diameter fibres in the articular nerves. Free nerve endings are most numerous in the ligaments of the joint (Fig. 10), and are present in all of them—whether extrinsic or intrinsic. They are also present in the tendons related to the knee joint capsule, and in the associated aponeuroses. In the ligaments and tendons, the free nerve endings spread out in all directions in the areolar tissue between the fibres of the ligament or tendon, sometimes twining around such fibres in part of their course. Sparsely distributed free nerve endings can also be found in the deeper layers of the fibrous capsule of the joint, in addition to the more prominent unmyelinated nerve network; but they are absent from all other articular tissues of the knee joint—including the synovial tissue and the menisci.

Type IVb endings

These endings are confined to the articular blood vessels, in whose walls they are exclusively distributed and within which they terminate. They are distinct from the perivascular plexuses of the type IV*a* variety, in that they terminate in the tunica media of the small arteries and arterioles—whereas the type IV*a* endings are confined to the adventitial connective tissue sheaths of the blood vessels.

The type IV*b* endings are derived from unmyelinated parent axons less than 2 μm in diameter that coil round the blood vessels in their adventitial sheaths, through the meshes of the type IV*a* plexus located therein. These parent axons give off fine collateral branches (which are often less than 1 μm in diameter) along their course in the blood vessel wall; and these branches pass obliquely through the central connective tissue layers of the adventitia into the tunica media. Within the tunica media, the terminal filaments form fine plexuses on and around the smooth muscle cells located therein.

DISCUSSION

Extrinsic innervation

The posterior articular nerve

No worker has found the PAN to be absent in any animal examined, except for two instances in which Skoglund (1956) failed to find it. Comparison with previous accounts (Gardner, 1944; Skoglund, 1956) shows that the origin of the nerve from the posterior tibial nerve and its course to the back of the knee joint (Fig. 1) are sufficiently constant to permit its ready identification. The two occasional variations that we have reported should be noted, however. Although almost all the fibres in the PAN are distributed to tissues in the knee joint, a very small (but unknown) proportion of its fibres terminates in para-articular periosteum (particularly that on the back of the tibia), whilst other fibres innervate the popliteal fat pad and the back of the superior tibio-fibular joint.

The spatial extent of the tissues of the knee joint that is innervated from this nerve (Fig. 5) varies somewhat in different animals, and its territory is overlapped to different degrees by other nerves supplying the joint (Skoglund, 1956; Stener, 1959). The posterior articular nerve contributes most of the innervation of the intercondylar region of the capsule on the back of the knee joint and of the related posterior oblique ligament. We also confirm Skoglund's (1956) suggestion that the posterior articular nerve gives off a separate perforating branch that innnervates the tibial end of the posterior cruciate ligament; this branch was found by Skoglund to contain a high proportion of very large diameter (12 μm or more) myelinated fibres whose size is that of the fibres innervating the principal receptor end-organs in this ligament (see below). It is also possible (Gardner, 1944—foetal material) that a few filaments from the PAN may enter the tendinous attachments of the two heads of the gastrocnemius muscle—although we have never found this to be so in adult animals.

Most of the branches of the PAN accompany the ramifications of the genicular arteries in their course through the joint capsule; but we cannot agree with Gardner (1944) that this nerve does not become associated with blood vessels until it enters the joint capsule. On the contrary, the nerve accompanies blood vessels throughout its course—being associated first with its nutrient artery, and then with the posterior tibial artery, before it branches out to join the genicular vessels.

The medial articular nerve

The MAN was first identified by Gardner (1944) and described in more detail by Skoglund (1956) and Stener (1959). Our observations agree in general with these reports; but the origin and course of this nerve are more variable than is the case with the posterior articular nerve and sometimes it is not present as a distinct trunk, being then replaced by a plexus of fine nerve filaments surrounding the descending genicular vessels.

The lateral articular nerve

Articular branches of the peri-fibular part of the lateral popliteal nerve were noted by Gardner (1944), Samuel (1949) and Skoglund (1956). Our findings (Figs. 3, 5) are in accord with, and extend, their data; but, like Skoglund (1956), in a few specimens we have been unable to find any branches to the knee joint from the lateral popliteal nerve.

Accessory (intramuscular) articular nerves

Hilton's (1863) Law has usually led workers in this field to seek intramuscular articular nerves to the knee joint; but, because of the difficulties of dissection, generally in foetal material (Gardner, 1944).

We have not studied foetal specimens, preferring to try to identify the intramuscular articular nerves in adult animals. We have found (Fig. 4) variable intramuscular articular nerves to be derived from branches of both the femoral and obturator nerves, and to be present (on varying occasions) in the vastus intermedius, vastus medialis, vastus lateralis, rectus femoris and (rarely) sartorius muscles, and (also rarely) in the medial head of the gastrocnemius muscle. We have been unable to to find articular nerves in the hamstring muscles, in the adductor muscles of the thigh, or as intramuscular branches of the nerves supplying the calf muscles (except for the rare example of the medial head of the gastrocnemius muscle).

The principal intramuscular accessory articular nerves to the knee joint are provided from the femoral and obturator nerves by the nerve trunks innervating the quadriceps muscle group. In other words, such accessory articular nerves are related primarily to muscles that extend the joint; and nerves supplying flexor and adductor muscles in the thigh have little or no share in the innervation of the knee joint. If this be so, it follows that Hilton's Law may have a more limited application than is generally assumed, in that branches of nerves supplying some groups of muscles moving a joint may make little or no contribution to its innervation. A further point that requires emphasis is the implication that a considerable (but variable) proportion of the fibres in the nerves supplying the quadriceps musculature is represented by articular afferents. It cannot be assumed, therefore, that all the afferent fibres in these muscle nerves are derived from receptor endings in the muscles themselves—although such an assumption has been made generally in the past (Barker, 1962).

Some articular nerve fibres supplying the tissues of the knee joint are derived from related cutaneous nerves—as also stated in Hilton's Law. We have made no specific study of this aspect of the subject, nor have the other workers already mentioned; but it has been considered by Stilwell (1957*a*, *b*), whose material included the knee joint region in cats. Stilwell found that a proportion both of free nerve endings and of corpuscular end-organs in the ligamentum patellae, in the patellar periostum, and in the aponeurotic portion of the attachment of the quadriceps muscle mass to the capsule of the knee joint was innervated through branches of the adjacent cutaneous nerves. Most of the corpuscular endings in the capsular insertion of the quadriceps were, however, supplied from the accessory articular branches of the nerves within the muscle. Whilst cutaneous nerves do make some contribution to the innervation of the tissues of the knee joint, we feel that it is of negligible significance in comparison with that from the other sources. Nevertheless, in particular experimental and surgical situations the existence of this additional accessory cutaneous innervation of the knee joint may have to be kept in mind.

Articular nerve endings

Previous attempts at the histological study of nerve endings in joint tissues have been complicated, not only by the problems that beset the study of nerve endings in connective tissues generally, but also by difficulties peculiar to the articular tissues themselves. Chief amongst these have been the obligations of earlier histologists to homologize their observations with eponymously designated nerve endings identified in other tissues (Table 2); the difficulty in obtaining adequate and consistent differentiation of neural elements from the dense and strongly argyrophilic articular tissues with individual conventional staining techniques (Gardner, 1950); and the tendency of some workers to try to fit their morphological observations into a preconceived functional frame of reference regarding nerve endings in joints (Wyke, 1967).

Classification of articular nerve endings

We have attempted to obviate these difficulties by adopting an arbitrary numerical system of classification of articular nerve endings that is applicable to all joints (Wyke, 1961, 1966, 1967; Freeman & Wyke, 1963, 1965; Greenfield & Wyke, 1963; Kirchner & Wyke, 1964, 1965*b*), the criteria for which are summarized in Table 2; and by using several specially modified staining techniques on the same tissue, the results of all the methods being compared with one another.

In addition, we have undertaken parallel neurophysiological studies of the behaviour of the articular nerve endings in various joint systems (Freeman & Wyke, 1964, 1965, 1966; Kirchner & Wyke, 1965*a*, *b*; Wyke, 1966, 1967), the results of which can be correlated with our observations.

The *type I endings* of our classification (Fig. 6) correspond with those regarded by previous workers most often as Ruffini corpuscles. Occasionally these same end-organs have been designated as Golgi-Mazzoni bodies or as Meissner corpuscles—erroneously, in our opinion—or have merely had descriptive names (Table 2) applied to them. If these articular endings have to be homologized with end-organs present in other tissues of the body, it is our view that their morphological and physiological characteristics relate them most closely to the connective tissue endings beneath the skin and in fasciae originally described by Ruffini (1894, 1905).

The *type II endings* (Figs. 7, 8) have usually been regarded as some kind of modification of the Pacinian corpuscle. Sometimes, however, they have been related to Golgi-Mazzoni, Meissner or Krause corpuscles; regarded as a specific articular end-organ; or merely designated descriptively (Table 2). The possible homologies of this end-organ have been discussed by Hromada (1960) and Poláček (1961, 1963), and more critically by Fitzgerald (1962). We do not regard the type II ending as a Pacinian corpuscle in any form (whether 'simple', 'modified' or 'paciniform'), in view of its structural, developmental (Hromada, 1960; Fitzgerald, 1962; Poláček, 1961, 1963) and functional characteristics; and we reiterate (Samuel, 1949, 1952; Gardner, 1950) that true Pacinian corpuscles are not found in articular tissues, but only in tissues external to joints. Furthermore, we are unable to accept Poláček's (1963) view that the type II receptors represent a developmental extension of the life history of the type I end-organs—although it seems possible that they might lie somewhere along a different stream of development that eventually culminates (in non-articular tissues) in the Pacinian corpuscle, as Hromada (1960) and Poláček (1961, 1963) have proposed. Support for this latter view is provided by the fact that end-organs identical with the type II articular receptors are found in non-articular tissues (such as subcutaneous tissue, fascia, periosteum and interosseous membranes) in which Pacinian corpuscles are also present (Ruffini, 1894, 1905; Stilwell, 1957*a*, *b*; Barker, 1962).

Oppenheimer, Palmer & Weddell (1958) have claimed that endings of this type are not true end-organs, but are artefactual stages in the life cycle of afferent nerve terminals, or else represent the Perroncito apparatus (*see* Ramón y Cajal, 1928). On the basis of our study of the structure of the type II ending (Figs. 7, 8), we cannot subscribe to this view; and we are reinforced by Fitzgerald (1962). These structures are specific mechanoreceptor end-organs; and direct physiological evidence in support of this assertion is provided by the characterization of their specific stimulus-response characteristics by Boyd & Roberts (1953), Andrew & Dodt (1953), Boyd (1954), Skoglund (1956), Fidel'-Osipova *et al.* (1961), Kirchner & Wyke (1965*a*) and Wyke (1966, 1967).

The *type III ending* (Fig. 9), from the time of its first identification in the medial collateral ligament of the knee joint by Andrew (1954), has generally been homologized with the tendon organ of Golgi; although attempts have been made to relate it to the Golgi–Mazzoni or Ruffini corpuscle. We agree that the structure and dimensions of the type III end-organs in ligaments correspond with those of the tendon organs of Golgi; but acceptance of their functional identity with the tendon organs depends upon demonstration of their reflex inhibition of motor unit activity, and of their high threshold to, and slow adaptation following, mechanical stimulation. Certainly some evidence to this end is already available in the studies of Andrew & Dodt (1953), Andrew (1954), Skoglund (1956), Stener (1959), Andersson & Stener (1959) and Wyke (1966); but the matter requires further specific physiological investigation before it can be regarded as settled.

Previous writers (Barnett *et al.* 1961; Wyke 1966, 1967) have given descriptions of the plexuses and free endings of fine nerve fibres in the tissues of the cat's knee joint that form our *type IV category*. Our observations indicate that free nerve endings are most prominent in all joint ligaments and that they are sparsely distributed elsewhere in the articular tissues. Plexuses of small myelinated and unmyelinated nerve fibres, on the other hand, are dense in the intra- and extra-articular fat pads, in the fibrous capsule of the knee joint (especially on its posterior aspect), and in the adventitial sheaths of all the articular arteries and arterioles. We believe this system of free nerve endings and plexuses (our *type IVa endings*) to be of somatic origin, and to constitute the pain receptor system of the joint tissues (Samuel, 1949, 1952).

Apart from the adventitial plexus system of nerve endings, we have traced additional unmyelinated nerve fibres through the connective tissue sheaths of the small blood vessels into the tunica media, where they ramify round the smooth muscle cells. Such a direct relation of nerve endings to the smooth muscle coat of blood vessels has never been satisfactorily demonstrated (Appenzeller, 1964), but it is clearly revealed in our preparations of articular blood vessels. In view of Samuel's (1949, 1952) previous observations on sympathectomized animals, we have little doubt that these *type IV endings* are post-ganglionic sympathetic vasomotor terminals that regulate the diameter of the articular blood vessels.

Relation of nerve endings to articular nerve fibres

The myelinated fibres in the articular nerves supplying the knee joint (Table 1) range in diameter from 2 to 17 μm, and all are afferent in function. There are also many unmyelinated fibres (less than 2 μm in diameter) in these nerves; and some of these latter are afferent in function, whilst others are efferent.

The type IV *a* endings (plexuses and free nerve terminals) in the articular tissues are innervated from the smaller myelinated fibres (between 2 and 5 μm in diameter) in the articular nerves, as well as from many of the unmyelinated nerve fibres. The remaining unmyelinated fibres in the articular nerves are sympathetic post-ganglionic axons, contributing a considerable vasomotor innervation (type IV *b* endings) to the blood vessels in all of the articular tissues (Gardner, 1944, 1950; Samuel, 1949, 1952).

The slightly larger myelinated fibres (between 5 and 8 μm) in the articular nerves are mechanoreceptor afferents, innervating (Table 1) the clusters of slowly adapting type I endings located mainly in the peripheral layers of the fibrous capsule—but present also on the surfaces of the extrinsic ligaments of the joint. The still larger myelinated fibres—those between 8 and 12 μm in diameter—are likewise mechanoreceptor afferents, but innervate (Table 1) the clusters of rapidly adapting type II corpuscles located in the deeper layers of the fibrous capsule and in the articular fat pads.

The small proportion of very large diameter (13–17 μm) myelinated fibres in the articular nerves are again mechanoreceptor afferents, most of which innervate the large, slowly adapting type III corpuscles in the intrinsic and extrinsic ligaments of the knee joint. A few of them probably supply, in addition, the rapidly adapting large Pacinian corpuscles in the peri-articular tissues—including the extra-articular fat pads (Table 2).

We have stated earlier in this paper that the type II end-organs (innervated in clusters of two to four corpuscles by fibres between 8 and 12 μm in diameter) outnumber, in the joint capsule as a whole, the type I endings (innervated in clusters of up to six corpuscles by fibres between 5 and 8 μm). On the other hand, Sasaoka (1939 *a*, *b*) and Skoglund (1956) found that in the posterior articular nerve the highest proportion of myelinated fibres lay in the 6–10 μm range. We are unable finally to resolve this discrepancy until we complete our own analysis of the fibre diameter spectra of the articular nerves. But it may be that while most of the afferent fibres from type I endings in the superficial layers of the posterior capsule of the knee joint traverse the posterior articular nerve, many of those from the more deeply located type II endings enter other accessory articular nerves; and in this respect, it is relevant that Skoglund (1956) found many fibres in intramuscular articular nerves whose diameters were up to 12 μm. Furthermore, in the posterior region of the joint capsule, type II endings are less numerous in relation to type I endings than in other regions; and calculations made from Skoglund's (1956) data reveal that in the posterior articular nerve 30 % of the myelinated fibres have diameters embracing the range of our type I afferents (i.e. 5–8 μm), whereas 25 % lie in the range (8–13 μm) that includes our type II afferents. On the other hand, in his medial articular nerve spectra 29 % of the myelinated fibres lie in the 8–13 μm range, and only 20 % are in the 5–8 μm range.

Distribution of articular nerve endings

In the light of the information presented in this paper, it now seems possible to provide a systematic description of the innervation of the individual tissues of the cat's knee joint (other than bone and cartilage).

Fibrous capsule. All regions of the fibrous capsule of the knee joint contain a mixture of types I, II and IV nerve endings—but their relative population densities differ in the various regions of the joint capsule. Furthermore, in each region of the fibrous capsule the type I endings are more numerous in the superficial (*i.e.* peripheral) layers, whereas the type II endings are more numerous in the deeper (*i.e.* central) tissue strata—especially at the junction of the internal layers of the fibrous capsule with the subsynovial fibro-adipose tissue. In the superficial layers of the fibrous capsule, the type I endings outnumber the type II endings—particularly on the posterior and, to a lesser extent, on the anterior aspects of the joint. The type I receptor population is thus especially dense in those regions of the fibrous capsule of the joint that undergo the greatest stresses during movement of the knee (Eklund & Skoglund, 1960): in regions less subject to stress, the predominance of type I over type II receptors is not apparent.

In the central (*i.e.* internal) layers of the fibrous capsule, type I endings are rare on all aspects of the joint: and at the junctional zone between the fibrous capsule and the subsynovial fibro-adipose tissue they are everwhere absent. The only organized receptor ending present in this latter situation (on all aspects of the joint) is the type II corpuscle. Although, as stated above, the type I endings are the more numerous variety in the superficial layers of the fibrous capsule (especially on the posterior aspect of the joint), this is not so for the capsule of the knee joint considered as a whole—for then the type II endings far outnumber the type I variety.

Thus we cannot agree with the statements of some previous workers that 'Ruffini-type' endings (*i.e.* type I corpuscles) are the most prominent end-organs in the capsule of the knee joint—unless this claim be made only in respect of the superficial layers of the posterior capsule. Our findings accord rather with those of Samuel (1949) and Hromada & Poláček (1958), who observed that most of the encapsulated end-organs in the knee joint capsule are 'paciniform' (*i.e.* type II) corpuscles. We can also confirm that the type II corpuscles are clustered particularly around the ramifications of the articular blood vessels in the deeper layers of the fibrous capsule of the joint, often extending longitudinally along the vessel wall (*c.f.* Fitzgerald, 1962) or coiling around it in spiral fashion.

The type IV*a* category of ending is represented throughout the fibrous capsule of the knee joint by a plexus of fine myelinated and unmyelinated nerve fibres whose density varies on different aspects of the joint. Thus, the plexus is most dense in the posterior part of the capsule, and least dense on the sides of the joint. In each region, moreover, the plexus is denser in the superficial layers of the joint capsule (where it contains both small myelinated and unmyelinated fibres), and becomes more sparse (and contains fewer myelinated nerve fibres) as the deeper layers are reached. The corpuscular end-organs in the various parts of the fibrous capsule lie in the interstices of this plexus.

In our material, the characteristic type IV*a* ending throughout the fibrous capsule is the plexus formation, rather than free nerve endings. In addition, a finer plexus (mainly of unmyelinated nerve fibres) ramifies in the adventitial sheaths of all the arteries and arterioles distributed through the fibrous capsule. In the fibrous capsule of the knee joint, then, the type IV*a* ending consists of plexuses that are both extravascular and perivascular (Gardner, 1944, 1950; Samuel, 1949, 1952).

No other type of nerve ending has been found by us anywhere in the fibrous capsule of the cat's knee joint. In particular, Pacinian corpuscles are entirely absent from this tissue—although they are numerous in the adjacent peri-articular tissues.

Ligaments. The ligaments of the knee joint contain three varieties of nerve ending—types I, III and IV—although there is a difference between the intrinsic and extrinsic ligaments in respect of the particular types of ending that are present therein.

The most prominent end-organ in all the ligaments—those (extrinsic) in the joint capsule, as well as the (intrinsic) cruciate ligaments—is the type III corpuscle, identified previously by others as a 'Golgi-type' corpuscle. Similar end-organs are present also in the tendinous attachments of the muscles to the joint capsule and related periosteum. A type III ending is usually applied to the surface of each ligament near one or other end; but in some instances more than one such ending may be present—as in the cruciate liaments, where several type III endings are present at either extremity close to the attachments of the ligament.

The extrinsic ligaments related to the joint capsule, but not the intrinsic cruciate ligaments, also have a few type I receptor clusters applied to them. These end-organs are identical with the type I endings present elsewhere in the fibrous capsule of the joint, and are located superficially at the edges of the ligaments where they blend with the joint capsule. Similar type I endings are also found on the surfaces of the tendons and aponeuroses that are attached to the capsule of the knee joint, in addition to the tendon organs of Golgi.

In all the ligaments (both extrinsic and intrinsic), the type IV*a* ending is represented by large numbers of unmyelinated free nerve endings, rather than by plexus formations. In fact, it is in the joint ligaments that most of the free nerve endings in articular tissues generally are found. These free nerve endings ramify amongst, and coil around, the bundles of ligamentous fibres as they run in parallel, and are derived from small myelinated and unmyelinated articular nerve fibres that spread out (with the blood vessels) over the superficial surfaces of the ligaments. In the cruciate ligaments, the free nerve endings are particularly dense near their bony attachments, but are sparse in the more central parts of the ligaments.

Synovial tissue. The innervation of synovial tissue is the most difficult problem in articular neurology, and its description is in a confused state (Gardner, 1950; Barnett *et al.* 1961). The first difficulty is presented by the term 'synovial membrane', which has meant different things to different authors, some of whom even deny the existence of any such 'membrane'. In this paper, the term 'synovial tissue' is used to designate the tissue lining the cavity of the knee joint, consisting (Barnett *et al.* 1961) of an internal (intimal) sheet of lining cells applied externally to a layer of fibro-adipose subsynovial (or subintimal) tissue of varying thickness.

Examination of all synovial material stained with the gold, silver and methylene blue techniques makes it clear that no organized end-organs are present in the synovial tissue of the knee joint. The corpuscles nearest to the synovial lining are type II endings—but these are located peripherally in the subsynovial tissue, at its junction with the deep layers of the fibrous capsule. We have never seen a single corpuscle (types I, II or III, or Pacinian corpuscle) lying close to the synovial lining or in the immediately subjacent fatty tissue. This statement conflicts with some early claims that corpuscular end-organs are present 'in the synovial membrane'; but it accords with the findings of more recent workers that such end-organs are not involved in the innervation of synovial tissue. This aspect of the problem of synovial innervation may then be regarded as settled—but there is still a difficulty in respect of unorganized nerve endings.

This difficulty arises because the tissue immediately beneath the intimal layer of synovial cells is particularly rich in fine reticular and elastic fibres (Samuel, 1949; Barnett *et al.* 1961); and differentiation of unmyelinated nerve filaments from these connective tissue elements in stained material presents a major problem—particularly if the stain be methylene blue (Fig. 11). Several earlier workers with cat material have described fine plexuses of varying density, or free unmyelinated endings, in the 'synovial membrane'—sometimes extending even into the synovial villi. However, comparison of these reports with one another and with our own material reveals that the density of this supposed synovial innervation varies with the staining technique employed—being greatest with methylene blue, less with silver methods, and least with gold chloride techniques.

As seen in methylene-blue preparations (Fig. 11), there is a dense filamentous meshwork beneath the synovial surface that extends right up to the lining cell layer, and which is partly perivascular and partly extravascular in distribution. In silver and gold preparations of the same material, however, the extravascular portion of this meshwork is barely apparent; and in such preparations most of the stained fibres are restricted to the immediate vicinity of the arterioles and capillaries that lie beneath the synovial surface. Furthermore, if the methylene-blue preparations be compared with sections of synovial tissue stained specifically to show the elastic tissue elements, it becomes apparent that much of the filamentous meshwork displayed in synovial tissue by methylene-blue staining (as in Fig. 11) consists of fine connective tissue elements rather than of nerve fibres.

In our view then, the synovial tissue of the cat's knee joint has no specific innervation. That is to say, neither organized nor unorganized nerve endings are present amongst the lining cell layers, nor are such endings present independently of blood vessels in the subintimal connective tissue. However, the arterioles and capillaries ramifying beneath the synovial surface are surrounded by plexuses of fine unmyelinated nerve fibres, representative of the type IV category of ending and identical with the plexus system related to blood vessels in the other articular tissues. Some of these nerve fibres form a plexus confined to the adventitial sheaths of the subintimal blood vessels (type IV*a* endings), and provide what we believe to be a perivascular pain sensitive system beneath the synovial surface (Gardner, 1944, 1950; Samuel, 1949, 1952). Other nerve fibres can be traced from the adventitia of the subintimal arterioles into the tunica media (type IV*b* endings), and probably represent sympathetic vasomotor fibres innervating the synovial blood vessels. These views receive support from Samuel's (1949) observations of the changes in the nerve fibre population of the synovial tissue of the cat's knee joint following sympathectomy.

Menisci (*semilunar cartilages*). Our material shows that, in the menisci of the cat's knee joint, nerve endings are confined solely to the connective tissue of the annular ligaments that surround the periphery of the discs, and that these endings are of the type IV variety only. Nerve elements are entirely absent from the central fibro-cartilaginous portions of the menisci in the adult cat; and in the annular ligaments, the only nerve terminals present are free endings and sparse unmyelinated perivascular plexuses surrounding the blood vessels as they enter the peripheral layers of the ligaments—apart from an occasional type I corpuscle embedded in the attachment of the meniscus to the fibrous capsule of the joint.

The menisci of the knee joint are therefore devoid of a corpuscular mechanoreceptor innervation; but the peripheral layers of the surrounding annular ligaments are provided with a sparsely distributed pain-sensitive system of type IV*a* endings, and with an occasional type I mechanoreceptor.

Fat pads. In the cat's knee joint, localized collections of fibro-adipose tissue form fat pads within the joint capsule, as well as outside it, in which prominent connective tissue septa (containing elastic fibres and blood vessels) separate the fat cells into lobules of varying sizes.

In the *intra-articular fat pads* we have found two types of nerve ending. The only encapsulated variety of end-organ consists of small clusters of two or three type II corpuscles, scattered at infrequent intervals along the blood vessels traversing the interlobular septa; these are confined to the more peripheral lobules of the fat pad. The more prominent variety of nerve ending consists of a dense plexus of unmyelinated nerve fibres (type IV*a*) that is distributed throughout the entire fat pad—not only in the interlobular septa, but also along the borders between individual fat cells (Poláček, 1954). This fat pad plexus is the densest nerve plexus in the entire joint—being more dense, for instance, than the plexus system in the fibrous capsule.

In the extra-articular fat pads (*e.g.* the popliteal fat pad), a similar but less dense plexus of unmyelinated nerve fibres is present (Poláček, 1954), as are small clusters of type II corpuscles. But these corpuscles are here confined to the vicinity of the blood vessels in the deep central (*i.e.* juxta-capsular) parts of the fat pad. In addition, however, large 'true' Pacinian corpuscles are embedded in the peripheral interlobular septa of the extra-articular fat pads, and in the fascia covering their external surfaces, and are quite distinct from any of the corpuscular end-organs present within the articular tissues themselves. These are identical with Pacinian corpuscles that are present also in the periosteum covering the femoral and tibial surfaces near the attachments of the joint capsule; and such extra-articular sites are the only locations in which Pacinian corpuscles are related to the knee joint.

This description of the type IV plexus system in the articular fat pads accords with MacConaill's (1944) and Poláček's (1954) accounts. We cannot agree with

MacConaill's statement that all the nerve endings in the fat pads are unencapsulated, for type II corpuscles are present in both the intra-articular and extra-articular fat pads; and in the extra-articular fat pads, Pacinian corpuscles are present in addition.

Our observations suggest that the internal and external articular fat pads are provided with rapidly adapting mechanoreceptors, and with a considerable pain-sensitive plexus system.

SUMMARY

The extrinsic innervation of the cat's knee joint is described in terms of primary and accessory articular nerves, on the basis of microdissection studies.

Neurohistological studies (with specially modified gold chloride, frozen silver, paraffin silver and methylene-blue techniques) have been made of all the tissues of the knee joint (other than bone and cartilage).

Four principal categories of articular nerve ending have been identified and classified as types I, II, III and IV on a morphological and functional basis.

The characteristics of each of the four varieties of nerve ending, and their distribution within the individual tisses of the knee joint, are described.

Some functional implications of this pattern of articular innervation are considered.

The authors are grateful to Professor G. Causey, to Professor M. A. MacConaill, and to Mr H. E. Harding, F.R.C.S., for their interest in and encouragement of this work. They are also grateful tor the technical assistance of Mr J. Gitau and Mr G. Swayne, and to Mr C. H. Redman and Mr K. McCarthy for their skilled help with the photographic work. One of us (B.W.) acknowledges grants from the Postgraduate Medical Federation of the University of London and from the Camilla Samuel Fund.

REFERENCES

ANDERSSON, S. & STENER, B. (1959). Experimental evaluation of the hypothesis of ligamento-muscular protective reflexes. II. A study in the cat using the medial collateral ligament of the knee joint. *Acta physiol. scand.* **48** (Suppl. 166), 27–49.

ANDREW, B. L. (1954). The sensory innervation of the medial ligament of the knee joint. *J. Physiol., Lond.* **123**, 241–250.

ANDREW, B. L. & DODT, E. (1953). The deployment of sensory nerve endings at the knee joint of the cat. *Acta physiol. scand.* **28**, 287–296.

APPENZELLER, O. (1964). Electron microscopic study of the innervation of the auricular artery in the rat. *J. Anat.* **98**, 87–91.

BARKER, D. (ed.) (1962). *Symposium on Muscle Receptors.* Hong Kong University Press.

BARNETT, C. H., DAVIES, D. V. & MACCONAILL, M. A. (1962). *Synovial Joints. Their Structure and Mechanics.* London: Longmans.

BOYD, I. A. (1954). The histological structure of the receptors in the knee joint of the cat correlated with their physiological response. *J. Physiol., Lond.* **124**, 476–488.

BOYD, I. A. & ROBERTS, T. D. M. (1953). Proprioceptive discharges from the stretch-receptors in the knee joint of the cat. *J. Physiol., Lond.* **122**, 38–58.

COHEN, L. A. (1955). Activity of knee joint proprioceptors recorded from the posterior articular nerve. *Yale J. Biol. Med.* **28**, 225–232.

EKLUND, G. & SKOGLUND, S. (1960). On the specificity of the Ruffini-like joint receptors. *Acta physiol. scand.* **49**, 184–191.

FIDEL'-OSIPOVA, S. I., YEMETS, G. L. & BURICHENKO, A. V. (1961). Electrophysiological and histomorphological characteristics of the joint capsule receptors. (Ukranian text). *Fȳzȳol. Zh.* **7**, 197–205.

FITZGERALD, M. J. T. (1962). On the structure and life history of bulbous corpuscles (*corpuscula nervorum terminalia bulboidea*). *J. Anat.* **96**, 189–208.

Fitzgerald, M. J. T. (1963). A general-purpose silver technique for peripheral nerve fibres in frozen sections. *Stain Technol.* **38**, 321–327.

Freeman, M. A. R. & Wyke, B. D. (1963). The innervation of the cat's knee joint. *J. Anat.* **98**, 299–300, (1964).

Freeman, M. A. R. & Wyke, B. D. (1964). Articular contributions to limb muscle reflexes. I. An electromyographic study of the influence of ankle joint mechanoreceptors upon reflex activity in the gastrocnemius muscle of the cat. *J. Physiol., Lond.* **171**, 20–21 *P*.

Freeman, M. A. R. & Wyke, B. D. (1965). Reflex innervation of the ankle joint. *Nature, Lond.* **207**, 196.

Freeman, M. A. R., & Wyke, B. D. (1966). Articular contributions to limb muscle reflexes. The effects of partial neurectomy of the knee joint on postural reflexes. *Br. J. Surg.*, **53**, 61–69.

Gardner, E. D. (1944). The distribution and termination of nerves in the knee joint of the cat. *J. comp. Neurol.* **80**, 11–32.

Gardner, E. D. (1950). Physiology of movable joints. *Physiol. Rev.* **30**, 127–177.

Greenfield, B. E. & Wyke, B. D. (1963). The innervation of the cat's temporomandibular joint. *J. Anat.* **98**, 300 (1964).

Hilton, J. (1863). *Lectures on Rest and Pain.* London: Bell.

Holmes, W. (1942). A new method for impregnation of nerve axons in mounted paraffin sections. *J. Path. Bact.* **54**, 132–136.

Hromada, J. (1960). Beitrag zur Kenntnis der Entwicklung und der Variabilität der Lamellenkörperchen in der Gelenkkapsel und im periartikulären Gewebe beim menschlichen Fetus. *Acta anat.* **40**, 27–40.

Hromada, J. & Poláček, P. (1958). A contribution to the morphology of encapsulated nerve endings in the joint capsule and in the periarticular tissue. *Acta anat.* **33**, 187–202.

Kirchner, J. A. & Wyke, B. D. (1964). The innervation of the laryngeal joints in the cat. *J. Anat.* **98**, 684.

Kirchner, J. A. & Wyke, B. D. (1965*a*). Afferent discharges from laryngeal articular mechanoreceptors. *Nature, Lond.* **205**, 86–87.

Kirchner, J. A. & Wyke, B. D. (1965*b*). Articular reflex mechanisms in the larynx. *Ann. Otol. Rhinol. Lar.* **74**, 749–769.

MacConaill, M. A. (1944). Nerve endings in joint tissues. *Irish. J. med. Sci.* **6**, 136.

Oppenheimer, D. R., Palmer, E., & Weddell, G. (1958). Nerve endings in the conjunctiva. *J. Anat.* **92**, 321–352.

Poláček, P. (1954). The innervation of fat cells of the joint capsule and its environs. (Czech. text). *Čslká Morf.* **2**, 190–198, 315–316.

Poláček, P. (1961). Differences in the structure and variability of encapsulated nerve endings in the joints of some species of mammals. *Acta anat.* **47**, 112–124.

Poláček, P. (1963). Variability of bush-like nerve endings in joints. (Russian text). *Čslká Morf.* **11**, 257–265.

Ramón y Cajal, S. (1928). *Degeneration and Regeneration of the Nervous System.* (Translated and edited by R. M. May). Oxford University Press.

Ruffini, A. (1894). Sur un nouvel organe nerveux terminal et sur la presence des corpuscles Golgi-Mazzoni dans le conjunctif sous-cutané de la pulpe des doigts de l'homme. *Archs ital. Biol.* **21**, 249–265.

Ruffini, A. (1905). Les dispositifs anatomiques de la sensibilité cutaneé. Sur les expansions nerveuses de la peau chez l'homme et quelques autres mammifères. *Rev. gén. Histol.* **1**, 420–540.

Samuel, E. P. (1949). The innervation and sensitivity of the articular capsule of the human and feline knee joint M. D. Thesis. Victoria University, Manchester.

Samuel, E. P. (1952). The autonomic and somatic innervation of the articular capsule. *Anat. Rec.* **113**, 53–70.

Sasaoka, S. (1939*a*). Über das Kaliber den Markhaltigen Nervenfasern im Gelenkast. *Jap. J. med. Sci.* (*Anat.*) *Trans. Abstr.* **7**, 315–322.

Sasaoka, S. (1939*b*). Characteristika in den Kaliberverhältnissen der Markscheide bei den Muskel-, Haut- und Gelenkästen. *Jap. J. med. Sci.* (*Anat.*), *Trans. Abstr.* **7**, 323–342.

Skoglund, S. (1956). Anatomical and physiological studies of knee joint innervation in the cat. *Acta physiol. scand.* **36** (Suppl. 124), 1–101.

Stener, B. (1959). Experimental evaluation of the hypothesis of ligamento-muscular protective reflexes. I. A method for adequate stimulation of tension receptors in the medial collateral ligment of the knee joint of the cat, and studies of the innervation of the ligament. *Acta physiol. scand.* **48** (Suppl. 166), 5–26.

Stilwell, D. L. (1957*a*). Regional variations in the innervation of deep fasciae and aponeuroses. *Anat. Rec.* **127**, 635–653.

Stilwell, D. L. (1957*b*). The innervation of tendons and aponeuroses. *Am. J. Anat.* **100**, 289–317.

Wyke, B. D. (1961). Neurophysiological aspects of joint function. *J. Bone Jt Surg.* **43** *B*, 396–397.

Wyke, B. D. (1966). The neurology of joints (Arris and Gale Lecture.) *Ann. R. Coll. Surg.* (in the Press).

Wyke, B. D. (1967). *Studies in the Neurology of Joints*, Vol. I. *The Limb and Spinal Joints.* Amsterdam: Elsevier. (To be published.)