

## OBSERVATIONS ON THE INNERVATION OF THE CORNEA

BY E. ZANDER\* AND G. WEDDELL

*From the Department of Human Anatomy, University of Oxford*

## INTRODUCTION

A vast literature has accumulated on the innervation of the cornea, and there exist more than 300 publications dealing with various aspects of the subject.

Nevertheless, in 1910 Virchow, who summarized the literature up to that date, was struck by the fact that little attempt had been made to correlate the results of anatomical and physiological studies. The only serious attempt to synthesize morphological and functional observations was made by Ranvier as long ago as 1881, and since the time of Virchow the tendency towards specialization has become even more marked. That the need for correlation is still urgent may be instanced by the papers of Sédan and his colleagues (1947, 1948). Their clinical observations indicate that commonly accepted anatomical and physiological data cannot be satisfactorily harmonized and require both revision and amplification.

Clearly, before any further attempt can be made to integrate morphology and function, it is necessary to inquire critically into the present state of our knowledge concerning all aspects of corneal innervation.

The present conception of the morphology of the corneal nerves is based chiefly on the work of Attias (1912) and appears in current text-books of ophthalmology. Some authors, however, in particular Boeke & Heringa (1923), Boeke (1925, 1935) and Reiser (1935-6, 1936-7), have questioned some of Attias's findings. This lack of agreement on the precise anatomy of corneal innervation has wide implications. Thus it is not at present possible to compare normal and pathological anatomical observations in clinical medicine, even though nerve fibres can be observed in the normal living human cornea under the slit-lamp microscope. Prendergast (1940) suggests that diseases involving peripheral nerves, such as leprosy, can indeed be recognized at an early stage by such a comparison; but it is clear that his observations would be of greater significance if the anatomy of normal corneal innervation were known with certainty.

Since there is doubt concerning the anatomy of corneal innervation, the morphological approach cannot at present be used to settle physiological controversies, in particular those concerning the sensations which can be aroused from the cornea.

Until recently it was believed that pain was the only sensation which could be aroused from the cornea proper (von Frey, 1894, 1922; von Frey & Webels, 1922; von Frey & Strughold, 1926). Despite von Frey's assertions, Nagel (1895), Goldscheider & Brückner (1919), Franceschetti (1932*a, b*), Nafe & Wagoner (1937), Altschüler (1940), and a number of other authors, believe that touch as well as pain can be aroused from the normal cornea, but none of them has described any clear-cut anatomical arrangement which might lend weight to their subjective observations.

\* Holding a grant from the Swiss 'Stiftung für biologisch-medizinische Stipendien'; on leave from the Neurosurgical Clinic, University of Zürich.

Tower (1935, 1940, 1942) has shown by electrophysiological methods that the sensory receptive mechanism in the cornea consists of an aggregation of overlapping 'sensory units' which are physiologically independent. Weddell, Sinclair & Feindel (1948) have suggested that the quality of sensation (in particular pain) which can be aroused from tissues is connected in some way with the mode of distribution of the nerve terminals in the tissue.

There are a number of clinical observations that are related to the anatomical arrangement and to the functions of the corneal nerves. In cases of neuralgia treated by trigeminal tractotomy Sjöqvist (1938*a, b*), Rowbotham (1939), Grant, Groff & Lewy (1940), and Falconer (1949) found that pain sensibility was abolished and in some cases also the corneal reflex, but that stimulation of the cornea now gave rise to a sensation described as touch.

A number of clinical observations have been recorded which, at first sight, suggest that corneal nerves may have more than a purely sensory role. For instance, keratitis neuro-paralytica develops more commonly after section of the fifth nerve distal to the trigeminal ganglion than it does if the central root of the ganglion alone is divided, despite the fact that corneal sensation is entirely abolished in both cases (Magendie, 1824; Claude Bernard, 1858). There is as yet no experimental evidence that any sensory nerve fibres have 'trophic' functions (von Brücke, Hellauer & Umrath, 1949). Nevertheless, these clinical observations cannot at the moment be explained on purely anatomical and physiological grounds.

It is clear, therefore, that much basic work remains to be done before any attempt at a broad synthesis of knowledge is possible in the manner suggested by Virchow.

In this paper an attempt has been made to fill to some extent the gaps in our knowledge of the anatomy of corneal innervation, in such a way that an eventual integration of morphological and functional observations may be possible.

#### LITERATURE

Hoyer (1873), Ranvier (1881) and Virchow (1910) surveyed and summarized the literature up to the date of their publications. We shall, therefore, only refer to selected works which appeared before 1910, to indicate the development of thought on the nature of corneal innervation. We shall review all the publications known to us which have appeared since 1910.

For 20 years following the work of Schlemm (1831), who demonstrated, by ordinary dissecting methods, nerve fibres passing from the sclera as far as the corneo-scleral junction in man, stags and oxen, there was much controversy as to whether the cornea proper contained any nerve fibres whatever. Arnold (1832), Hueck (1839), and Beck (1847) held that the cornea was devoid of nerves, whereas Bochdalek (1837, 1839), working on corneas of large mammals and man, and Pappenheim (1839, 1840), working on the cornea of the ox and the stone eagle, held that the cornea proper was innervated. They noted the opaque whitish nerve fibres advancing from the sclera towards the corneal limbus described by Schlemm, but were able to demonstrate in addition fine translucent flattened threads arising from the nerve fibres and advancing for some millimetres into the substantia propria of the cornea.

The next phase of activity resulted from the development of histological methods.

Purkinje (1845), using corneas from different mammals, Koelliker (1848), using corneas from rabbits and frogs, Luschka (1850), using rabbits' corneas, Kühne (1862), using frogs' corneas, and Ciaccio (1863, 1881), using corneas from sparrows, eels, frogs, mice and man, found that after immersion of the tissue in dilute acetic acid they were able to see under the microscope nerve fibres in the substantia propria. They all gave good and more or less parallel descriptions of the arrangement of the corneal nerve fibres, and discussed the possibility of the axons ending in the form of a 'terminal net'.

His (1863) also studied the innervation of the cornea, using simple histological methods. He was in substantial agreement with his contemporaries concerning most points, but differed from them in that he believed the cornea to contain many nerve ganglion cells.

Kühne even discussed the relation of the nerve fibres to the cellular elements of the cornea, believing that they entered them, and he thereby started a controversy which has yet to be satisfactorily resolved. Kühne also believed that some of the corneal nerve fibres and cellular elements had a motor function and that they were in some way responsible for maintaining the translucency of the tissue. Lightbody (1867), in addition to publishing an excellent comparative anatomical study on vertebrate corneal innervation, also held that 'trophic' nerves entered the cornea from the region of the limbus where the capillary loops terminate. He also believed that the cornea contains many nerve ganglion cells.

Hoyer (1866), using impregnation methods involving silver nitrate and chromic acid, claimed that he was able to trace some nerve fibres through Bowman's membrane (anterior elastic lamina), on the surface of which they ramified, but was unable to trace any nerves beyond the membrane into the epithelium itself. Hoyer used corneas from newts, frogs, fish, birds, guinea-pigs, rabbits and man, but mentioned no major species difference in their mode of innervation.

The next step forward was taken by Cohnheim (1866, 1867), who introduced the gold chloride impregnation technique, and in a classical paper demonstrated that there are nerve fibres within the corneal epithelium in birds, frogs, rabbits and guinea-pigs. Despite Cohnheim's convincing drawings, however, Brand (1888) disputed his findings, maintaining that what Cohnheim described as nerve fibres were in fact precipitates of gold on the walls of the epithelial cells. He asserted his belief in the truth of Hoyer's statement that the corneal nerve fibres all terminate beneath the epithelium after penetrating Bowman's membrane.

As might have been expected, a large number of papers on corneal innervation followed the introduction of the gold chloride method. The majority of them were collected together and well reviewed by Ranvier. Unfortunately, however, the terminology used by the individual authors varies so widely that a critical assessment of their observations is not possible. Papers by Koelliker (1866), Engelmann (1867), Moseley (1871), Ladowsky (1872), Klein (1871, 1880), Hoyer (1873), Waldeyer & Yzquierdo (1880), and Ranvier (1881), are probably the most important contributions which appeared during this period. They studied variously corneas from mammals, birds, reptiles, amphibia and fish.

Arnstein (1887) and Dogiel (1890) took advantage of the work of Ehrlich (1886) and introduced the technique of methylene-blue staining of corneal nerve fibres.

Arnstein studied corneas from birds and amphibia. Dogiel (1891) made some particularly interesting observations on what he believed to be complicated terminations of nerve fibres in corneas taken from monkeys and from human subjects. He also demonstrated the presence of Krause end bulbs in the conjunctiva in these species.

Crevatin (1903), Bielschowsky & Pollack (1904) and Cajal (1909), using silver methods, studied corneas from mammals, birds and reptiles. Crevatin described the manner in which the nerve fibres ramify in the epithelium. Bielschowsky & Pollack noted particularly that many of the nerve bundles were flattened antero-posteriorly and called them nerve bands. Cajal, describing the innervation of the mammalian cornea, noted the absence of myelin sheaths and gave a good description of beaded axons terminating between the cells in all layers of the epithelium. Curiously enough, however, Cajal believed that there were no Schwann elements in any part of the cornea.

The next, or consolidation, period is notable for the papers of Virchow (1910), Attias (1912) and Agababow (1912). These authors mainly used methylene blue. They not only summarized the observations which had already been made (chiefly on animals) concerning corneal innervation, but themselves studied the human cornea in some detail. They were, however, chiefly concerned with the general pattern of innervation and the establishment of an agreed nomenclature, rather than with finer morphological details such as the exact position and mode of termination of the corneal nerve fibres, although they discussed these matters at some length. The paper of Attias is particularly notable for its solidity and for the fact that it has remained the standard anatomical reference on the innervation of the cornea up to the present day.

During this period, Nageotte (1911 *a-c*) published a series of papers dealing with the Schwann elements in relation to peripheral nerves, using a special technique developed for the purpose. In one of these papers (1911 *c*) he refers to the corneal nerve fibres in the rabbit. The only other papers dealing specifically with corneal Schwann elements appeared much later (Nageotte & Guyon, 1926; Nageotte, 1932; Boeke, 1935).

After 1912 no important papers specifically related to corneal innervation appeared until 1923, when the most recent phase of activity opened. It is concerned chiefly with the finer details of the innervation of the cornea. In 1923 Boeke & Heringa and in 1925 and 1935, Boeke published papers on the innervation of corneas from birds, frogs and macaque monkeys. They used silver and gold chloride impregnation methods to demonstrate the nerve fibres, and claimed that the axis cylinders eventually terminated within the cytoplasm of either the 'corneal corpuscles' or the epithelial cells. They also stated that a few corneal nerve fibres ended in an organized and complicated manner somewhat resembling a mode of termination described by Dogiel in 1891. Boeke differentiated between somatic and autonomic nerve fibres on the grounds that the former were thicker than the latter.

Eisler (1930), writing in the Schieck and Brückner *Handbook of Ophthalmology*, gave a description of corneal innervation based on the work of Attias, but, in addition, claimed that the nerve fibres terminated within the corneal cells in accordance with the views of Boeke. Nakajima (1930), using methylene blue in albino rabbits and pathological human eyes, also gave a description of the innervation of the cornea and in the main confirmed the findings of Attias, but did not refer to the work of Boeke.

Yokomatsu (1931), quoted by Reiser (1935-6), used a 'vital staining method' and claimed that the cornea contains a large number of different organized terminals.



Egorow (1934), using methylene blue, stained the corneal nerves in guinea-pigs and also claimed to have demonstrated many types of complicated terminals in the substantia propria and also organized nerve end-organs in the epithelium. In 1934 Ernyei, using osmic acid and silver methods, searched for myelinated nerve fibres and ganglion cells in the cornea of the rabbit. He examined many thousands of sections with negative results. Goto-Yotaro (1935), quoted by Reiser (1935-6), like Yokomatsu, used a 'vital' staining method and likewise claimed that the cornea contains many different types of organized terminals.

Reiser (1935-6, 1936-7), using silver methods, claimed that corneal nerve fibres ended in a 'terminal reticulum'. He also claimed that the innervation of the cornea in pigs and rabbits was very similar to that in man. He believed, like Stöhr (summarized in Stöhr, 1941), that the neurone theory was untrue, for he stated that he had evidence that peripheral nerve terminals are arranged in the form of a protoplasmic continuum. Lauber (1936), writing in von Möllendorff's *Handbuch*, gave a description of the innervation of the cornea based on the work of Attias (1912), Knüsel & Vonwiller (1922) and Knüsel (1923). The illustrations, which were furnished by Kolmer, are particularly good. Borri (1939), using silver methods combined with a vascular injection technique, noted the close relation between nerve fibres and blood vessels at the limbus of the rat's cornea, and believed that this might have a functional significance related to the secretion of the aqueous humour. Martinez (1940), using silver methods in human corneas, came to the conclusion that the nerves do not ramify within the syncytium formed by the corneal corpuscles, as claimed by Kühne and Boeke, but rather proceed along the surface of the cells. On the other hand, he claims to have seen nerve fibres forming protoplasmically continuous nets, and thus doubted whether the neurone doctrine could be taken quite literally.

Peris (1947, 1948), also using silver methods, has examined corneas from the following animals: bulls, sheep, rabbits, pigs, cats, chickens, frogs (*Rana esculenta*), snakes (*Tropinodotus natrix*) and man (foetal, prepubertal and adult specimens). He notes that his observations have revealed a fundamental similarity in the morphological arrangement of the corneal nerves in all the specimens he has examined, and that there are only minor species differences. His observations are in agreement with those of Martinez in so far as both authors deny that nerve fibres terminate within the cytoplasm of any of the cellular elements of the cornea. However, whilst Martinez is somewhat non-committal on the existence of nerve fibres in the epithelium, Peris is more definite and states that he has never seen nerve fibres within the corneal epithelium and does not believe in their existence.

Rodger (1950) investigated the innervation of the rabbit's cornea, using gold impregnation and methylene-blue staining. He observes that there are two types of nerve fibres in multifibre bundles; large beaded ones with fine dendrite links, and a second in which the beads are 'masked'. The fibres in which the beads are 'masked' he believes, on morphological grounds, to be autonomic.

In conclusion we shall review the work done on the innervation of the normal intact human cornea by workers using the slit-lamp and corneal microscopes. The first observations on the subject were made by Wolff in 1912. Erggelet (1914) merely confirmed Wolff's findings, but added nothing new. In 1919, Koeppel gave a fairly full account of the innervation of the cornea, using this method, and claimed to have

confirmed the findings of Attias. In 1922, Knüsel & Vonwiller and in 1923, Knüsel combined methylene-blue staining and the slit-lamp technique both in man and the rabbit and again claimed to confirm the findings of Attias in man. They did, however, note that there was a species difference in the pattern of corneal innervation without defining the differences clearly. So far, no facts concerning the neuro-anatomy of the normal cornea have been described by this method which are at variance with the work of Attias.

In summary, then, it is clear that the descriptive anatomy of corneal innervation given by Attias is still assumed in general to be correct and to apply, with minor differences, to all vertebrate species. There is no agreement, however, as to the manner in which the corneal nerves terminate.

#### MATERIAL AND METHODS

We have examined corneas from the following vertebrates: the dogfish (*Scyllium canicula*—10 animals), the frog (*Rana temporaria*—15 animals), the white rat (10 animals), the guinea-pig (many varieties—25 animals), the rabbit (many varieties—104 animals), the monkey (*Macaca mulatta*—4 animals), and man (5 subjects). The details of the special techniques that we have employed in this investigation have already been published (Weddell & Zander, 1950). They include:

(1) Direct observation of untreated corneas *in situ*, using the slit-lamp and corneal microscopes. (54 examinations.)

(2) The immediate examination of whole preparations, or razor slices from the untreated corneas of anaesthetized animals, under the phase-contrast microscope. (52 specimens.)

(3) Vital staining methods employing methylene blue. (211 specimens.)

(4) Impregnation methods employing gold and silver salts. (75 specimens.)

(5) Myelin stains. (4 specimens.)

(6) Nageotte's method for demonstrating Schwann cells. (4 specimens.)

(7) Methods for demonstrating connective tissue elements following silver impregnation (see Holmes & Young, 1942).

#### NOMENCLATURE

Since there is no agreement as to the precise meaning of certain terms in common use, we felt that it was necessary to state exactly what we wish to imply when, for the sake of necessity or continuity, we employ terms which at present lack definition.

(1) The term nerve bundle refers to an aggregation of either myelinated or non-myelinated nerve fibres running in close proximity to one another for some distance. The individual axis cylinders within the nerve bundle may be running either towards or away from the central nervous system, and may or may not divide when traced in continuity along the bundle. If a nerve bundle is surrounded by a demonstrable epineurial connective tissue sheath, this fact will be specifically referred to in the course of our description.

(2) The terms branch or division, when used in relation to nerve bundles, are used in their colloquial sense; that is, it is implied that a proportion of the nerve fibres from the bundle pass into each branch or division. If axon multiplication takes place at or in a branch or division, this will be specifically referred to.

(3) The term plexiform arrangement is likewise used in its colloquial sense, but also specifically implies that axons derived from different sources do not fuse with one another when entering into this relationship.

(4) The term net formation implies the fusion in protoplasmic continuity of one or more of the axis cylinders derived by branching from a single parent axon.

(5) The term Schwann element implies the presence of one of the following: Schwann nucleus, Schwann cell cytoplasm, Schwann cell membrane, Schwann sheath (neurilemma) or endoneurium. When we can be more specific we shall be, and then the terms we use will have the meaning assigned to them by Holmes & Young (1942).

#### OBSERVATIONS

##### (1) *The arrangement of the nerve bundles supplying the cornea in the rabbit*

###### (a) *Origin of nerve bundles*

Bundles from the ciliary nerves pass forward as far as the ciliary bodies. The majority advance towards the limbus between the sclera and the choroid in the stratum perichoroideum; the remainder in the substance of the sclera. The corneal nerve fibres diverge from those passing to the ciliary body and iris just proximal to the corneo-scleral junction. We have never seen bundles of nerve fibres approaching the cornea from other sources.

The nerve bundles entering the cornea are between 61 and 68 in number, of which about 30 contain between 15 and 30 axons, the remainder containing less than 15 (Table 1). For the purpose of description they can be said to lie in three planes: the

Table 1. *Number of nerve bundles at corneo-scleral junction*

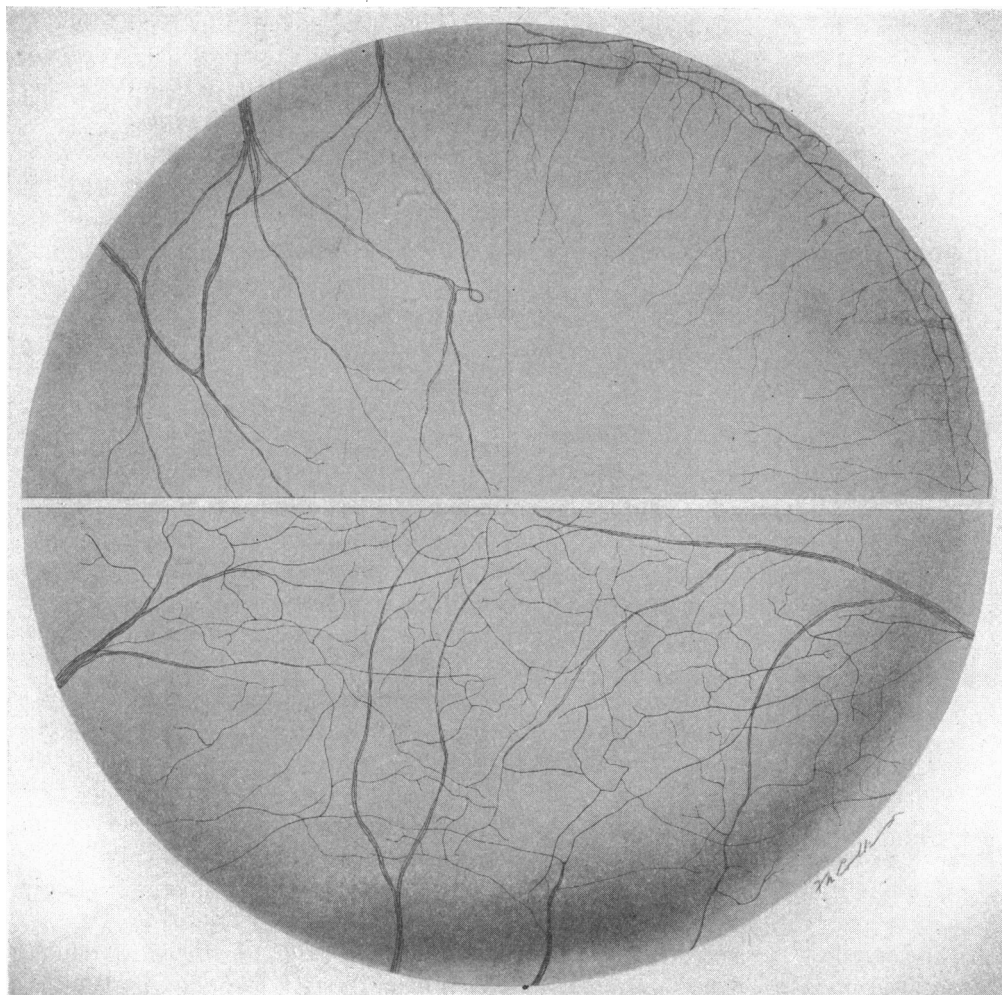
No.	Frog	Rabbit	Macaque monkey	Man
1	24	66 (32)	72 (37)	82
2	28	64 (31)	67 (33)	84
3	22	61 (34)	68 (32)	76
4	23	68 (29)	—	78
5	29	62 (33)	—	—

The figures in brackets indicate the number of bundles containing fifteen or more axons.

scleral, the episcleral and the conjunctival. The nerve bundles entering in the scleral plane are arranged in many different ways as illustrated in Text-fig. 1 (left upper quadrant). The bundles entering from the episcleral position are derived as follows: a proportion of nerve bundles leaves the sclera to pass directly into an episcleral position, where they join with medium-sized bundles derived from those which have entered the cornea in the deeper scleral plane; together they give rise to an episcleral pericorneal plexus (plexus paramarginalis of Attias; plexus annularis of Ranvier) (Text-fig. 1, right upper quadrant; Pl. 1, fig. 1). From this ring-like scaffold of nerve bundles, which incidentally is best demonstrated by the method of intravenous injection of methylene blue, further nerve bundles arise and pass into the most superficial layers of the substantia propria of the cornea.

The subconjunctival bundles are small and proceed towards the limbus from the deepest subepithelial layer of the conjunctiva, most of them being derived from the episcleral pericorneal plexus, but a few coming directly from those proceeding to

the limbus in the scleral position. The subconjunctival bundles can readily be distinguished from those forming the episcleral annular plexus, for they are in close



Text-fig. 1. This diagram illustrates the arrangement and behaviour of the various nerve bundles which enter the periphery of the cornea in different planes. The drawing is a composite one based upon observations from a large number of methylene-blue stained rabbits' corneas. The form and behaviour of nerve bundles entering the cornea from the scleral position is shown in the upper left quadrant. The form and behaviour of nerve bundles entering the cornea from the episcleral and subconjunctival positions are illustrated in the upper right quadrant. In the lower half of the drawing is shown the manner in which the plexiform pattern of nerve fibres arises from the nerve bundles. It also shows the passage of nerve bundles across the centre of the cornea from limbus to limbus, and the fact that not all the nerve bundles in the cornea are radially disposed.

relation to blood vessels and have a similar sinuous course (Pl. 1, figs. 2, 3). The sinuosity is not a fixation artefact, for vessels and nerves can be seen under the corneal microscope to take such a course in the living eye. The branches which leave the

subconjunctival bundles pass both into the superficial layers of the substantia propria and into the epithelium of the cornea. The possibility that a few of the nerve bundles which enter the cornea from the subconjunctival position are derived from extraorbital branches of the fifth cranial nerve cannot be excluded by the method of direct observation, but no large bundles have ever been seen to approach the cornea in this manner. In addition, recent degeneration experiments have confirmed that few, if any, corneal nerves are derived from other than the ciliary nerves.

Apart from those in the rabbit, we have made comparative observations on the origin of the corneal nerves only in the macaque monkey and man. In both these species the general plan is similar to that in the rabbit. The number of bundles entering the cornea in the macaque monkey is about the same as in the rabbit, but in man there are about 70–80 bundles, of which about 40 contain 15–20 axons, the remainder containing less than 15 fibres. The number of nerve bundles entering the frog's cornea is about 15–20 (Table 1). We have not determined the number of bundles in any other species.

*(b) Arrangement of nerve bundles*

The general arrangement of the nerve bundles in the rabbit's cornea is shown in Text-fig. 1. Although this figure is based on the analysis of numerous preparations, each bundle represents in form, size and position one which has actually been seen. Although certain bundles can be seen dividing in a simple manner (Pl. 1, figs. 4, 5), it is not profitable to segregate these bundles into a few clear-cut categories, for each would merge too freely into the other. There are certain points, however, to which we should like to draw attention.

Most of the large bundles entering the cornea are arranged in a radial manner (Pl. 2, fig. 19), and ultimately give rise to the plexiform aggregation of nerve fibres which pervades the substantia propria (Pl. 2, fig. 16). The top left-hand quadrant in Text-fig. 1 shows the form taken by the large nerve bundles entering the cornea from the sclera. They enter the middle third of the substantia propria of the cornea and branch, subdivide and join in the manner indicated. These bundles also give rise to further bundles which take part in the formation of the pericorneal nerve plexus seen in the upper right quadrant in Text-fig. 1.

Fine bundles of nerve fibres leave the pericorneal plexus and, together with bundles derived from the scleral and subconjunctival positions, also take part in the formation of the plexiform aggregations pervading the substantia propria.

In the lower half of Text-fig. 1 and Pl. 20, figs. 2, 21, are shown bundles of nerve fibres which join with one another, but which spring from widely separated positions on the periphery of the cornea.

The smaller nerve bundles all combine to form the plexiform aggregations of nerve fibres disposed in up to five layers (plexus fundamentalis of Ranvier, or Hauptplexus of Attias) throughout the substantia propria of the cornea from Descemet's (posterior elastic lamina) to Bowman's membrane (Pl. 2, figs. 16–18). The density of the plexiformly arranged nerve bundles is greater towards the surface of the substantia propria.

In the macaque monkey and in man the number of radially arranged nerve bundles which join to form loops is greater towards the centre and less towards the periphery

of the cornea than in the case of the rabbit. In the rat and in the guinea-pig the plexiformly arranged nerve fibres do not form so fine a meshwork as they do in the rabbit, for the number of layers in which they are disposed is reduced to two or three, and the number of axons in each aggregation is greater. In the frog and dogfish the meshwork appears even less dense, and it is difficult to define more than one main layer, situated closer to Descemet's membrane than in the case of the mammals which we have examined. No other important species differences were noted.

(2) *The form and behaviour of individual nerve fibres in the substantia propria of the rabbit's cornea*

(a) *Behaviour of axons in large nerve bundles*

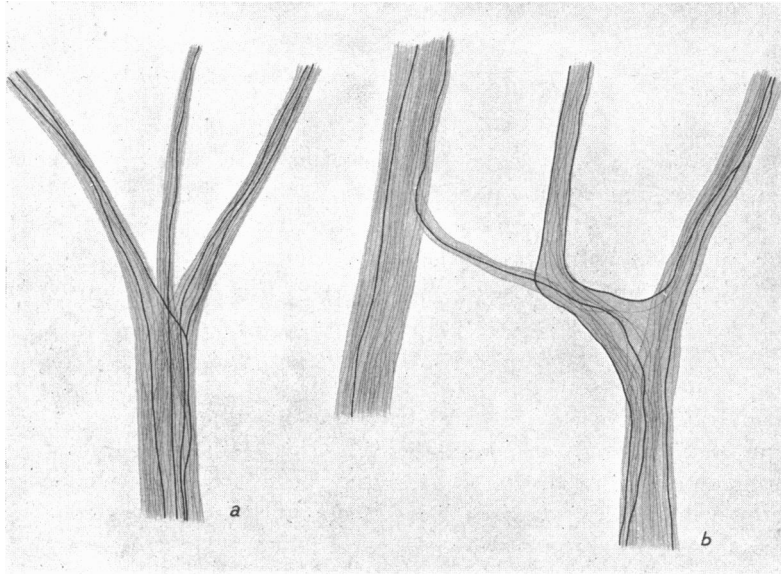
Myelinated nerve fibres are seen only in the scleral and episcleral bundles at the periphery of the cornea (Pl. 1, fig. 6). Most of them shed their myelin sheaths after proceeding for not more than 1 mm. from the limbus. No myelinated fibres have ever been seen to extend farther than 2 mm. from the corneo-scleral junction. The myelin sheath may end abruptly or the axis cylinder may be surrounded by one or two short detached myelin segments before proceeding towards its termination in company with other non-myelinated axis cylinders. No nerve fibres in the cornea beyond 2 mm. from the limbus have nodal points along their course. Myelinated nerve fibres which are scattered in a random way throughout the nerve bundles entering the cornea may give rise to collateral branches at nodal points. The collateral branches are nearly always non-myelinated (Pl. 1, fig. 7); in fact, only on one occasion have we seen an exception to this (Pl. 1, fig. 8). There are no morphological criteria which distinguish the axis cylinders derived from myelinated fibres from those which enter the cornea in the unmyelinated state.

At the limbus when a large nerve bundle divides, axon multiplication is rare (Text-fig. 2*a, b*). In bundles which divide closer to the centre of the cornea, axis cylinder multiplication takes place more often, but at the same time individual axons are seen to be pursuing more complicated courses. In Text-fig. 3*a-d* are drawings of the course taken by different axons in such positions. In Table 2 figures are given illustrating the extent of axon multiplication, having regard, in so far as possible, to the difficulties illustrated in Text-fig. 3. That the course taken by a certain number of axons was nevertheless recurrent cannot be excluded (Pl. 1, fig. 9), for detailed examinations were made only in the vicinity of the bifurcations. Degeneration experiments suggest that the counts are in fact of some quantitative value, for, although the course of some axons is recurrent in the manner suggested, the number that would have been missed by careful examination in the region of the division is very small.

In nerve bundles which pass across the centre of the cornea, such as those seen in Text-fig. 1, and Pl. 2, figs. 20, 21, some axons extend from one limbus through the centre of the cornea towards the opposite limbus, but so far it has not been possible to trace an individual axon further than three-quarters of the way across the cornea.

Single axons within nerve bundles entering the cornea pursue varying and complicated courses and give rise to numerous daughter axons. When traced from their entry towards their terminations, individual axons have never been seen to give rise

to more than two daughter axons at any point of division. Axon division is occasionally seen in the course of a nerve bundle, in which case one of the daughter axons is usually of smaller diameter than the other, which passes on its way little diminished in size (Pl. 1, figs. 7, 8). In rare instances, however, both parent and daughter axons appear to be of the same diameter. One of the daughter axons always springs from the parent axon approximately at a right angle (Pl. 1, figs. 10, 12), then abruptly changes its course to that of the direction of the main nerve bundle itself.



Text-fig. 2 (*a-b*). These drawings are from methylene blue-stained rabbits' corneas. They summarize the actual course and behaviour of individual axons which have been seen at points of division of nerve bundles at the limbus. Axon multiplication is rare.

It is, of course, possible to argue that these appearances are the result of fusion taking place between daughter axons derived from different parent axons. In cases in which it was possible to determine the course and destination of the axis cylinders concerned, two axons were always traced to terminations within the cornea and the remaining axon to a single parent stem entering the cornea. In recent experiments in which corneas were examined some 3 weeks after a number of the nerve fibres supplying them had been destroyed it was possible to confirm these observations more easily. In no cornea has fusion ever been seen to take place between collaterals derived from different parent axons.

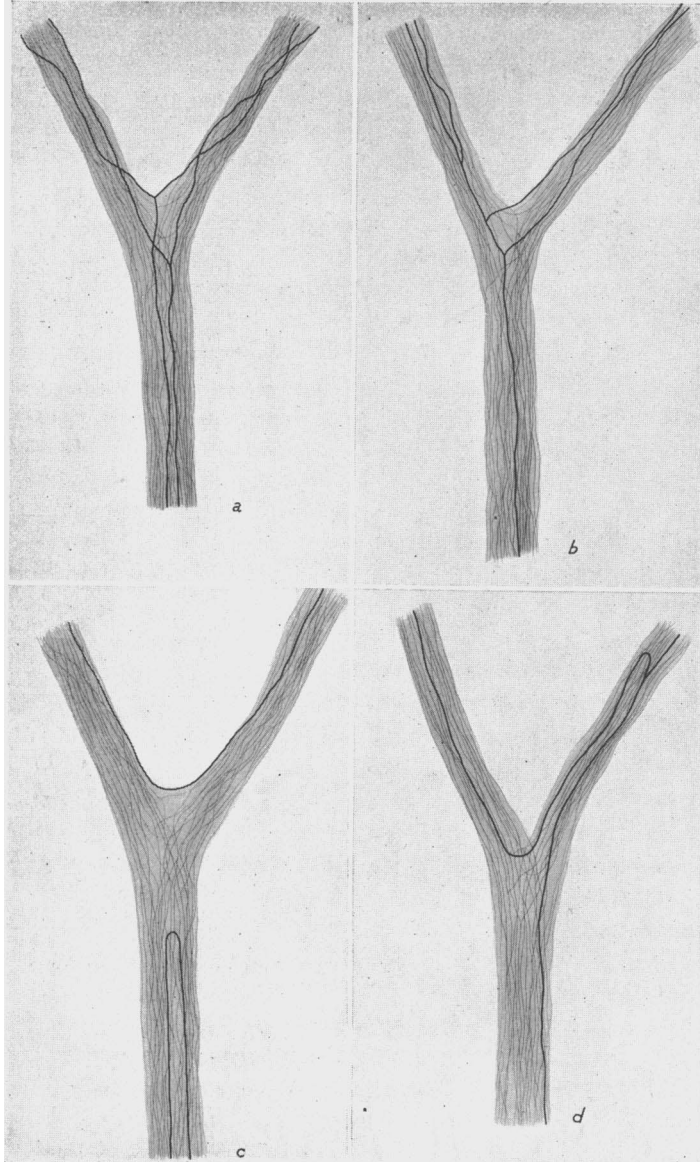
In any nerve bundle in the cornea the diameter of the axis cylinders apparently varies from 1 to 5  $\mu$ . The axons of larger diameter are those at some distance from their terminations, and, when traced peripherally, they progressively decrease in diameter. At points of bifurcation one daughter axon may be of greater diameter than the other (Pl. 1, fig. 11). However, in every case which we have analysed, the axon of smaller diameter gave rise to fewer branches and terminated before the

Table 2

Rabbit no.	Bundles	Number of fibres in stem	Number of fibres continuing without division (A)	Number of fibres dividing (B)	Number of fibres passing from one axon to another branch (C)	Number of fibres in 1st daughter branch	Number of fibres in 2nd daughter branch	Total fibres in daughter branches
1	1	17	13	4	1	$\frac{9A + 4B + 1C}{14}$	$\frac{4A + 4B + 1C}{9}$	23
	2	20	15	5	2	$\frac{10A + 5B + 2C}{17}$	$\frac{5A + 5B + 2C}{12}$	29
	3	16	12	4	—	$\frac{6A + 4B}{10}$	$\frac{6A + 4B}{10}$	20
	4	15	13	2	—	$\frac{6A + 2B}{8}$	$\frac{7A + 2B}{9}$	17
2	5	21	14	7	2	$\frac{4A + 7B + 2C}{13}$	$\frac{10A + 7B + 2C}{19}$	32
	6	19	11	8	1	$\frac{7A + 8B + 1C}{16}$	$\frac{4A + 8B + 1C}{13}$	29
	7	18	15	3	—	$\frac{11A + 3B}{14}$	$\frac{4A + 3B}{7}$	21
	8	19	14	5	3	$\frac{6A + 5B + 3C}{14}$	$\frac{8A + 5B + 3C}{16}$	30
3	9	16	13	3	1	$\frac{8A + 3B + 1C}{12}$	$\frac{5A + 3B + 1C}{9}$	21
	10	18	14	4	—	$\frac{9A + 4B}{13}$	$\frac{5A + 4B}{9}$	22
	11	15	11	4	—	$\frac{7A + 4B}{11}$	$\frac{4A + 4B}{8}$	19
	12	19	13	6	—	$\frac{4A + 6B}{10}$	$\frac{9A + 6B}{15}$	25
4	13	20	15	5	1	$\frac{5A + 5B + 1C}{11}$	$\frac{10A + 5B + 1C}{16}$	27
	14	17	14	3	—	$\frac{9A + 3B}{12}$	$\frac{5A + 3B}{8}$	20
	15	18	12	6	2	$\frac{7A + 6B + 2C}{15}$	$\frac{5A + 6B + 2C}{13}$	28
	16	16	14	2	1	$\frac{6A + 2B + 1C}{9}$	$\frac{8A + 2B + 1C}{11}$	20
5	17	19	13	6	2	$\frac{4A + 6B + 2C}{12}$	$\frac{9A + 6B + 2C}{17}$	29
	18	18	14	4	—	$\frac{7A + 4B}{11}$	$\frac{7A + 4B}{11}$	22
	19	20	16	4	1	$\frac{7A + 4B + 1C}{12}$	$\frac{9A + 4B + 1C}{14}$	26
	20	17	11	6	—	$\frac{4A + 6B}{10}$	$\frac{7A + 6B}{13}$	23



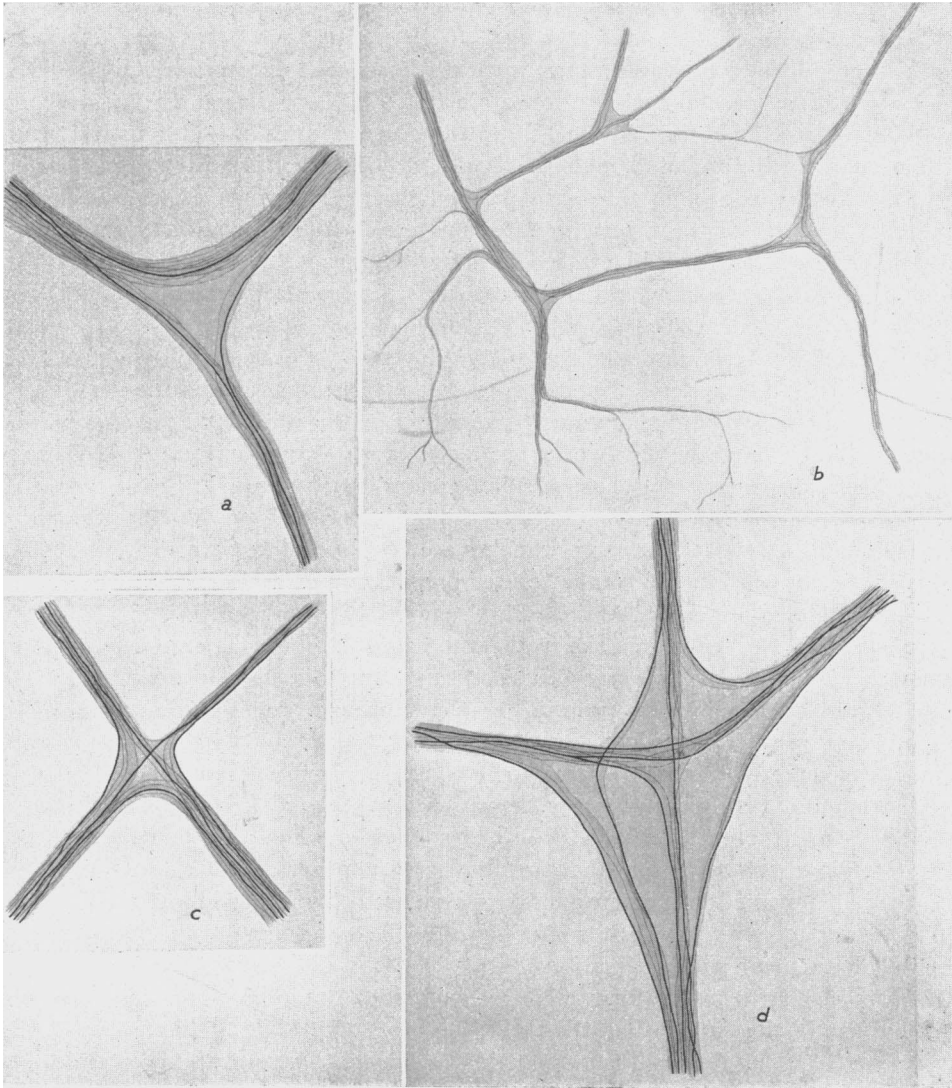
larger axon. In methylene blue-stained specimens, swellings often appear at the position of axon division (Pl. 1, figs. 12, 13). In some instances the swelling is large, being up to five times the diameter of the axons. In every case all three axis cylinders appear to enter and become continuous with the swelling (Pl. 1, fig. 13).



**Text-fig. 3 (a-d).** These drawings are from methylene blue-stained rabbits' corneas. They summarize the actual course and behaviour of individual axons at points of division of nerve bundles in the middle third of the cornea. See table 2 for quantitative data.

*(b) Behaviour of axons in the plexiformly arranged nerve bundles*

Axons in the plexiformly arranged nerve bundles usually bifurcate at the angles of the meshwork to which they give rise, but not invariably. The behaviour of those which do not divide is shown in Text-fig. 4*a-d*. Axon multiplication, however, is rare other than at the points of division of nerve bundles. The axons forming these patterns lie between the laminae of the substantia propria and are flattened antero-



Text-fig. 4 (*a-d*). These drawings are from methylene blue-stained rabbits' corneas. They summarize the actual course and behaviour of individual axons in the plexiform arrangement of nerve fibres in the substantia propria. The prominent axons displayed are the rarer ones which did not divide.

posteriorly, the nerve fibres tending to lie side by side rather than in cable form. The nerve fibres connecting them pass steeply, sometimes almost vertically, from one layer to the next and are also flattened, but in a vertical plane which makes their arrangement difficult to resolve under the microscope (Pl. 1, figs. 14, 15).

*(c) Behaviour of axons terminating in the substantia propria*

With the methods at our disposal we can distinguish corneal nerve fibres from one another only by virtue of the fact that they have different destinations. In general, the nerve fibres have only two destinations: the substantia propria and the epithelium. In three instances only were there exceptions to this generalization. Single large cells which had an appearance reminiscent of autonomic ganglion cells were seen in the cornea of each of three albino rabbits (Copenhagen strain), of which ninety-eight were examined. The cells had three nerve fibres associated with them, all smooth in outline and of diameter equivalent to the largest axons in neighbouring nerve bundles. Single axons entering nerve bundles at the limbus left them half way towards the centre of the cornea to enter the cells in the substantia propria. Two axons left the cells and could be traced for some distance in the substantia propria in company with other axons; but in no case was it possible to trace them to their terminations (Pl. 3, fig. 22).

The nerve fibres terminating in the substantia propria are usually derived from the larger nerve bundles, but may spring from the plexiformly arranged bundles (Pl. 3, figs. 23–25). The origin of the axons terminating in the substantia propria cannot always be determined, but in two instances we know that they were derived from myelinated axons entering the cornea. Whole axons or axon branches leave the nerve bundles approximately at right angles to the general course pursued by the nerve fibres (Pl. 3, figs. 24, 25). The axon branches are fine, being less than  $1\mu$  in diameter, but they are not beaded. Even in untreated preparations examined under the phase-contrast microscope some 60 min. after removal, they appear as fine threads, whereas the fine nerve fibres in the epithelium contain numerous large beads. After leaving the bundles the fine non-beaded nerve fibres pursue a long and tortuous course through the substantia propria, but they appear to remain approximately in the same layer as that in which they entered (Pl. 3, figs. 24 and 26–28). The distance pursued by some of these fibres from where they leave the nerve bundles to their termination may be three-quarters of the way across the cornea. During their course they give rise to more than twenty branches, each of which commonly leaves the parent trunk at right angles, so that the divergence appears to be T-shaped. We have seen that the terminals of a single axon leaving a nerve trunk to end in the substantia propria cover an area equivalent to a quadrant of the cornea, on most of the occasions when we have made such estimations.

Each branch ends in the form of a series of up to 100 interconnected beads, the terminal bead being larger than the preceding beads (Pl. 3, figs. 23 and 25–27). We have never seen any terminal nerve nets in the substantia propria such as are sometimes seen in the epithelium. The axons change their direction many times, but never re-enter nerve bundles once they have left them, even when by doing so they would reach their destination more directly.

A number of axons give rise to daughter axons at intervals along their course in

a bundle. Each daughter axon behaves and terminates in the same way, but is situated in a different layer of the substantia propria. Nerve fibres and terminals of this kind are seen in every layer of the substantia propria from Bowman's to Descemet's membrane, but in the rabbit they are far more numerous towards the epithelium.

Occasionally in methylene blue preparations droplets of stain are seen lying amongst the polygonal cells lining Descemet's membrane, but they do not appear to be terminal axon beads, for when preparations of these cells are stripped away from the substantia propria they are found to be free from nerve fibres and terminals (Pl. 3, fig. 30). None of the other methods we have used to demonstrate nerve fibres and terminals has shown any to be situated in close relation to Descemet's membrane.

We have never seen any complicated or organized nerve terminations on the corneal side of the limbus in specimens which have been carefully prepared for microscopic examination.

It has not been possible to demonstrate any protoplasmic connexion between the cellular elements in the substantia propria and the axons under phase-contrast conditions. In thin (3–5  $\mu$ ) *silver impregnated* sections, however, it was exceedingly difficult to be quite certain on this point (Pl. 3, fig. 29).

As regards species differences, in the rabbit, the monkey and man the axons terminating in the substantia propria appear to be equally abundant. They are not so numerous in the guinea-pig and rat, and still less numerous in the dogfish and frog, where they are more deeply situated.

#### (d) *The arrangement of the Schwann elements*

The relation of the Schwann elements to the axis cylinders in the nerve bundles and smaller aggregations of nerve fibres in the substantia propria of the cornea and to the axons which leave them to terminate in beads is in sharp contrast. Schwann cell nuclei and cytoplasm can be demonstrated by overstaining with methylene blue (Pl. 4, figs. 31, 32) or by silver impregnation (Pl. 4, fig. 33). They can also be seen under phase-contrast conditions in fresh untreated specimens mounted in saline (Pl. 4, fig. 34). Whatever method is used, it appears that the axons lie on the surface of Schwann cell cytoplasm during their course along the nerve bundles and finer nerve fibre aggregations, and even for a short distance when proceeding as single axons.

The single axons which terminate in the substantia propria, however, proceed for a large part of their course lying naked among the fibrous elements which make up the substantia propria (Pl. 4, figs. 33 and 35–38), where they come in close relation to corneal corpuscles or their plasmatic processes (Pl. 3, fig. 29; Pl. 4, fig. 38). It has not been possible to demonstrate unequivocally the existence of perineurial or endoneurial connective tissue in relation to any of the aggregations of nerve fibres in the cornea by the methods we have used.

#### (3) *The innervation of the corneal epithelium in the rabbit*

Nerve fibres leave the plexiform arrangement and penetrate Bowman's membrane almost perpendicularly to reach the epithelium (Pl. 4, fig. 39; Pl. 5, figs. 42, 43). At the limbus a few fibres enter the corneal epithelium directly from the conjunctiva.

The axons which enter through Bowman's membrane appear to pass through definite apertures in an otherwise homogeneous substance. On entering the corneal epithelium from whatever position, the axons shed their Schwann cell companions and pursue their course entirely naked, lying in direct relation to the surfaces of the cells composing the epithelium.

After penetrating Bowman's membrane the naked axis cylinders often divide into a leash of as many as fifteen fibres, all of which in methylene blue-stained and gold-impregnated specimens are beaded (Pl. 4, figs. 39, 41; Pl. 5, figs. 42-47). Under phase-contrast conditions and after gold impregnation the nerve fibres are seen to run in between the cells of the basal layer of the epithelium and not in a plane between Bowman's membrane and the cells (Pl. 4, figs. 40, 41; Pl. 6, fig. 49). In the rabbit the leash of fibres is orientated radially, the fibres tending to advance towards the centre of the cornea, except at the limbus where they scatter in many directions (Pl. 2, fig. 17; Pl. 5, figs. 42, 43).

Many axons terminate in the plane of the basal layer of the epithelium (Pl. 6, fig. 50). Occasionally, in methylene blue-stained material, adjacent axis cylinders derived from a single axon penetrating Bowman's membrane appear to fuse with one another, forming a protoplasmatically continuous net, but this is uncommon (Pl. 6, fig. 55). Under phase-contrast conditions such appearances have been seen, but are even more uncommon than after methylene-blue staining (Pl. 6, fig. 52). The possibility that they are an optical illusion cannot be dismissed, for the only specimens which can be used for an assessment of this kind are thicker than is desirable on optical grounds. We have never seen fusion between branches derived from axons piercing Bowman's membrane separately. The majority of axons terminate freely without making interconnexions, but the plane in which they terminate varies slightly (Pl. 6, figs. 48, 57).

Arising from the fibres which pierce Bowman's membrane and from fibres of the leashes into which they divide, are further branches which pass into the superficial layers of the epithelium (Pl. 6, figs. 53-55), advancing between the cells. The fibres may pass vertically towards the surface and end in between the cells of the most superficial layer, or take a more oblique course between the epithelial cells. These fibres and their beads are in every way similar to those lying between the cells of the basal epithelial layer. As the fibres advance through the epithelium, they multiply by axon branching (Pl. 6, figs. 55-57). The more vertically disposed fibres are arranged in a tree-like manner and their branches terminate between the epithelial cells of all layers (Pl. 6, fig. 57); they are usually about twice the diameter of the more obliquely disposed fibres. The latter tend to arborize in a plane parallel to the surface of the cornea, and here again branches from a single axon may appear to fuse to form protoplasmically continuous nets which lie in a single plane. The 'nets' are polyhedral in form and are disposed between the cells of the epithelium. From the 'nets' arise terminal branches ending in adjacent layers between the epithelial cells.

We have referred to 'vertically' and 'obliquely' disposed fibres passing towards the surface of the epithelium. Between these two extremes lies a continuous spectrum of fibre diameters approaching the surface of the epithelium at varying degrees of obliquity.

The axons in the corneal epithelium pursue independent courses towards their

termination. Although they overlap with their neighbours, they do so in different planes, and there is no close interweaving of fine unmyelinated beaded axons such as is seen just beneath the epidermis in the skin (Pl. 6, figs. 48–51).

The axons connecting the beads in the epithelium, even when examined in the whole preparations under unfavourable optical conditions, appear to be less than  $1\mu$  in diameter, although there is a variation in the diameter between the fibres and along the course of a single fibre in the proportion of about one to three (Pl. 6, fig. 51). The variation in diameter is accounted for, in part, by the fact that the fibres become progressively, although irregularly, finer as they are traced towards their terminations.

Since, on optical grounds, it is not possible to make quantitative measurements of fibre diameters in whole preparations, we prepared frozen sections of methylene blue-stained corneal epithelium. The axons connecting the beads in these preparations also appear to be less than a micron in diameter, and are thus too fine to be measured accurately even under these conditions (Pl. 6, figs. 51, 56 and 57). In the best silver preparations the appearances are similar (Pl. 6, fig. 58). The beads are approximately two or three times the diameter of the connecting axons, and hence along the thicker fibres the beads appear larger and more prominent than along finer fibres (Pl. 6, fig. 51). The terminal bead is commonly somewhat larger than the other beads (Pl. 6, figs. 55–58). The distance between the beads does not vary much, being approximately  $10\mu$ . Under phase-contrast conditions the beads along the course of axons in the epithelium may appear smaller than after methylene-blue staining or gold impregnation (Pl. 6, figs. 49, 52 and 53). In preparations examined *immediately* after removal the beads are not more than half as large again as the connecting axon. In specimens kept for a longer period the beads appear similar to those described above.

Under phase-contrast conditions we have never seen any nerve terminals lying within the cytoplasm of an epithelial cell; neither were we able to demonstrate any basket-work of fine fibrils proceeding from terminal beads to envelop any cellular elements present.

In the guinea-pig an axon piercing Bowman's membrane gives rise to a leash of between six and ten daughter axons (Pl. 5, figs. 43, 44); in the macaque monkey and man between ten and twenty axons. In the frog an axon, after piercing Bowman's membrane gives rise to a stellate formation rather than a leash of daughter axons. In the guinea-pig the more vertically disposed axons appear in somewhat greater number than they do in the rabbit and in man.

#### DISCUSSION

In 1910, Virchow stated that the chief anatomical problems in relation to corneal innervation which required investigation were three in number: the structure of the axis cylinders and the tissues immediately surrounding them; the relation of the corneal nerves and their terminals to the tissues composing the cornea; and finally the significance of the plexiform arrangement of the axons in the cornea. In the literature published since then, the descriptive anatomy of the innervation of the cornea given by Attias in 1912 is in general accepted as correct, but there is no agreement as to the nature of corneal innervation.

Most of the literature on the innervation of the cornea is in German and some relevant publications are not available in this country. Moreover, no critical review of the literature has appeared since Virchow's time. For these reasons we shall discuss the controversies raised in the literature in some detail, reviewing them in the light of our own observations.

(1) *The distribution and termination of the corneal nerves*

We have shown by improved histological methods that there are direct pathways in the form of nerve bundles of varying sizes passing from one limbus to the other through the centre of the cornea, a fact disputed by Attias. Moreover, we have been able to trace single axons from one limbus three-quarters of the way through the centre of the cornea towards the opposite limbus before they were seen to terminate.

Apart from this, both Attias' and Knüsel's descriptions of the arrangement of the corneal nerves in the rabbit are in general similar to ours. In man, however, they were unable to observe any plexiformly arranged nerve fibres except in the periphery of the cornea, where they noted the existence of a 'plexus paramarginalis superficialis'. On the other hand, we have been able to demonstrate the existence of plexiformly arranged nerve fibres throughout the human cornea. Species differences between man and the rabbit may account in part for the findings of Attias and Knüsel. In man more nerve bundles proceed in a straight course almost to the centre of the cornea before terminating in branches which go to form the plexiformly arranged pattern of nerve fibres. The bundles give off branches on their course just as they do in the rabbit, but nevertheless contrive to give the appearance of a more extended radial formation.

Our findings in relation to the descriptive anatomy of the nerve bundles in man are in broad agreement with those of Reiser (1935-6), using silver methods, and those of Schornstein (1934) in pathological cases in man in which the corneal nerves were myelinated. In the frog we have confirmed the findings of Lipmann (1869), who demonstrated that the plexiform arrangement of nerve fibres was denser in the depths of the substantia propria rather than beneath Bowman's membrane—the reverse of the condition seen in man.

We have also demonstrated, by the examination of fresh untreated specimens under phase-contrast conditions, that nerve fibres terminate between the cells in all layers of the corneal epithelium, even between the cells of the most superficial layer, but that they do not terminate between Bowman's membrane and the cells of the basal layer of the epithelium. These facts have been much disputed in the past and no clear-cut decision on the subject emerges from a perusal of the literature.

It appears that only under phase-contrast conditions is it possible to examine the corneal epithelium in its unshrunk state, and that previous workers have been handicapped by having to use histological methods involving fixatives in which a variable degree of shrinkage is inevitable.

The corneal epithelium is innervated by beaded terminals disposed 'in depth' throughout its whole extent, unlike the epithelium of the skin in which the fine beaded nerve fibres appear to terminate chiefly by a process of interweaving with one another in a plane just beneath the basal layer of the epithelial cells.

Nerve terminations are seen throughout the whole extent of the substantia propria

in all the species which we examined. They take the form of a few small terminal beads arising from single fine nerve fibres, smooth in contour, which have pursued an exceedingly complex course through the substantia propria. They are far less numerous (in proportion of about 1 to 50 in the rabbit) than those seen in the epithelium, and the beaded terminal is characteristically short. There is no doubt that the staining was adequate in our preparations, for their appearance is similar under phase-contrast conditions; moreover, terminals of this type can be demonstrated by silver and gold impregnation techniques.

As long ago as 1867, Engelmann described nerves ending freely in the substantia propria. Attias, however, describes the presence of only a few fine nerve fibres ending in small terminal expansions in this position in man.

The most recent accounts of the single nerve fibres in the substantia propria of the cornea are by Nageotte (1932) and Boeke (1935). Nageotte, however, is more concerned with the relationship of the Schwann cells to the axons than with their terminations. He apparently did not observe any nerve terminals ending freely, for he does not mention them; moreover, he believes that all axons in the substantia propria are related to Schwann cells, which we have shown not to be the case. He gives a good description of the close relation between axis cylinders and occasional corneal corpuscles, and also describes at some length the numerous beaded cytoplasmic processes associated with fixed and shrunken Schwann cells. Boeke describes the presence of 'isolated' axons in the substantia propria, but states that they are surrounded throughout their course by the cytoplasm of what he terms 'orthoklone' connective tissue cells. We are not able to agree with Boeke, for we have shown that, although single axons may be intimately related to the cytoplasm of corneal corpuscles for some distance, they do not enter them. In addition, we have shown that single axons pursue the greater part of their course in the naked state. We agree with Boeke in that we could not demonstrate epineurial sheaths surrounding nerve bundles, nor could we demonstrate endoneurial tubes in the cornea.

Dogiel (1891) described a number of special 'Nervenendapparaten' in the substantia propria of the cornea in man; they took the form of end-loops, hooks, coils and plates, and were situated in the periphery approximately  $1\frac{1}{2}$  mm. from the limbus, mainly in a plane just beneath Bowman's membrane; such endings were even more numerous in the conjunctiva, where some of them took the form of Krause end-bulbs. Attias was unable to confirm the presence of any coils in the substantia propria, but occasionally saw nerves ending in the form of loops, hooks and plates about 1 mm. from the limbus. Boeke (1935) claimed to have demonstrated 'end coils' similar to those described by Dogiel, but when their respective drawings are compared the terminals do not seem to resemble each other at all closely.

We have been unable to confirm the findings of Dogiel, Attias or Boeke. In view of the observations in our previous paper (Weddell & Zander, 1950), we are convinced that the appearances which they describe are artefacts appearing in the course of the preparation of the specimens for histological examination. Although we have confirmed the existence of Krause end-bulbs in the conjunctiva in man, they are not so numerous as depicted in Dogiel's drawings, and we believe that some of the terminals he saw were also artefacts arising in a similar manner. We have not seen Krause end-bulbs in the conjunctiva of the rabbit, guinea-pig or rat.



In 1862, Kühne stated his belief that nerve fibres terminated within the cytoplasm of the corneal corpuscles. This announcement aroused much controversy and his views were not generally accepted; Waldeyer & Izquierdo (1880), Lipmann (1869) and Königstein (1875, 1877) agreed with Kühne, but Engelmann, Koelliker (1848, 1866), Petermoeller (1869), Hoyer, Ranvier, Dogiel, Virchow and Attias stated that they were not able to confirm his findings. Virchow, in his review in 1910, said that the evidence was overwhelmingly in favour of the view that nerves do not end in the cytoplasm of the cells of the substantia propria and that it should be accepted that they do not do so. However, Boeke & Heringa (1923) and Boeke (1935) restated the problem, for they claimed to have demonstrated nerve fibres running in the cytoplasm of the corneal corpuscles and terminating within them. Reiser (1936-7) also adhered to the views of Boeke. In contrast to these observations, Nageotte & Guyon (1926) and Martinez (1940) were convinced that there were no intracellular nerve fibres in the substantia propria. Martinez even denied the existence of free terminals, and believed that the nerve fibres in this situation ended in the form of an extracellular protoplasmically continuous network.

In view of our observations on fresh untreated corneas under phase-contrast conditions we believe that Virchow was correct, and that the findings of Boeke and Reiser are artefacts resulting from shrinkage during the course of preparation of the tissue for microscopical examination as well as non-specific impregnation methods. However, nerve fibres in the substantia propria occasionally end on the surface of the corneal corpuscles and also occasionally on the surface of histiocytes which are found in the cornea. If staining with methylene blue is prolonged, the histiocytes in particular take up the dye and their cytoplasm becomes filled with blue granules. Under such circumstances nerves may indeed appear to end intracellularly, and we believe that appearances similar to this would account for Boeke's observations and also for the observations of Dogiel and Egorow in relation to their special 'Nervenendapparaten'.

Nerve fibres in the corneal epithelium have variously been supposed to end in the following ways:

- (1) As 'end-nets'—the nerve fibres forming a protoplasmically continuous network throughout the epithelium.
- (2) In the form of end-nets and terminal knobs.
- (3) Freely and in the form of terminal knobs.
- (4) In the form of terminal knobs alone.
- (5) In special 'Nervenendapparaten'.
- (6) Within the cytoplasm of the epithelial cells.
- (7) As free nerve terminals lying between the epithelial cells.

Observations under phase-contrast conditions indicate that the corneal epithelial nerves end in one of two ways: (1) very rarely, in the form of protoplasmically continuous finely beaded nerve nets, such nets being formed only by the fusion of daughter axons derived from neighbouring nerve fibres; (2) more commonly, in the form of beaded axons which lie in between the cells composing the epithelium, the terminal beads usually being larger than the preceding beads. The terminal beads, however, do not seem to us to be in any way specialized structures, as claimed by Attias, who, incidentally, denied the existence of protoplasmically continuous nets. Our observations are more in accordance with those of Virchow than of any other

author's, save that we have shown that 'end-nets' are very rare. We have not been able to demonstrate any organized or complicated nerve terminals in the corneas of the species we have examined.

So far, we have been unable to demonstrate any endoneurial tubes by the methods we have employed, nor indeed do there seem to be any clearly demonstrable connective sheaths surrounding any of the nerve bundles present. It seems that the bundles lie free between laminae of the connective tissue fibres which compose the substantia propria, being flattened in an antero-posterior plane. The axons appear to lie on the surface of a longitudinal series of Schwann cells when travelling in bundles, but when travelling singly in the substantia propria they lose their Schwann cell pathway shortly after leaving the nerve bundle and proceed naked for distances up to three-quarters of the diameter of the cornea lying among the connective tissue elements. This observation is in disagreement with Nageotte's (1932) statement that there are no naked nerve fibres in the substantia propria.

Following prolonged methylene-blue staining, after silver impregnation, and following the examination of fresh untreated tissues under phase-contrast conditions, we were unable to demonstrate Schwann cells in the corneal epithelium, the axons pursuing their course in the naked state. In this, we are in agreement with Nageotte (1932).

## (2) *Corneal innervation and the neuron theory*

Before the appearance of Hoyer's and Cohnheim's (1866) papers it was generally accepted that corneal nerve fibres ended in the form of a net within the substantia propria. It was believed, as far as can be judged by the descriptions and terminology used, that all the nerves fused with one another in the form of a protoplasmically continuous network. The demonstration by Cohnheim (1866) of nerve fibres in the corneal epithelium indicated, however, that this system of 'end-nets' could no longer be regarded as the ultimate termination of the corneal nerve fibres.

Virchow's and Attias' descriptions of corneal innervation, still acknowledged as classical, show that they probably regarded the neuron theory as acceptable. Thus, for instance, they were at pains to point out that the terms 'net' and 'plexus' should be avoided. Nevertheless, Virchow (1910) retained the term 'Schlussnetz' for the plexiform arrangement situated just beneath Bowman's membrane.

Unfortunately, it is not possible to determine from the descriptions given by previous authors exactly what they believed the position of corneal innervation to be in relation to the neuron theory. This is due both to the multiplicity of terms used and to the difficulty of defining their meaning with any precision. For instance, the plexiform arrangement just beneath Bowman's membrane is referred to as a 'Schlussnetz' by Koelliker (1848), as an 'Endnetz' by His (1863), and as a 'Terminalnetz' by Saemisch (1862). Cohnheim in 1867, however, spoke of 'mehreren in verschiedenen Ebenen übereinander liegenden Netzen und Geflechten', to describe the pattern of innervation of the cornea; a definition which is not at variance with any of the observations we have made, yet is, we believe, not precise enough to be used as an argument for or against the validity of the neuron theory.

In 1873, Hoyer used the term 'mehrschichtiges Geflecht' to describe the general pattern of the nerves in the cornea and even gave a separate term, 'sub-basalar

plexus', to the plexiform arrangement just beneath Bowman's membrane. Ranvier (1881) speaks of a 'plexus fundamendale' to describe the plexiform arrangement just beneath Bowman's membrane, and Bach (1896) has accepted this description and expressed it in German as the 'Fundamentalplexus'. In 1887, Schwalbe describes this plexiform arrangement as a 'Grundplexus'. Dogiel (1890) described nerve fibres as occurring throughout the cornea, but specifically named the plexiform arrangement just beneath Bowman's membrane as a 'Hauptgeflecht'. Virchow (1910), realizing the unsatisfactory nature of the terms used by previous authors, introduced the word 'Gerüst' to describe the arrangement of the nerves in the larger bundles, a better term, but, as he himself admitted, still not entirely satisfactory, for it implies a rigidity which does not in fact exist. Nakajima's (1930) publication is very difficult to interpret, for he used a combination of both Attias's and Virchow's terms.

All the terms referred to are readily understandable in the light of our observations, but unfortunately they all avoid the issue as to whether or not the nerve fibres contained in the plexiform arrangement of nerve bundles enter either partially or completely into protoplasmic continuity with one another. Thus none of the publications before the time of Attias (1912) can be used as evidence for or against the validity of the neuron theory.

In 1935-6 Reiser, using silver-impregnation methods, deliberately used the anatomy of corneal innervation to attack the validity of the neuron theory, claiming that all corneal nerve fibres enter a protoplasmically continuous 'praeterminales Netzwerk', this preterminal network in turn giving rise to a 'terminal reticulum' which surrounds and penetrates each corneal cell like a honeycomb. His objections to the neuron theory were further strengthened by the following experimental observations. Reiser extirpated the Gasserian ganglion in rabbits and demonstrated that after 30-72 hr., although signs of nerve degeneration were apparent in nerve trunks, there was very little change in the 'preterminal network' and no change at all in the 'terminal reticulum'. He explained these findings on the grounds that undamaged nerve fibres entering the cornea from the conjunctiva ended in the protoplasmically continuous 'terminal reticulum' and were sufficient to keep the 'preterminal network' partly, and the 'terminal reticulum' wholly, in a normal condition throughout the cornea despite the removal of the majority of the corneal nerves.

Our observations do not lead us to the same conclusions as Reiser's. When methylene blue-staining of the cornea is prolonged beyond the time found necessary to stain only the axis cylinders specifically, the Schwann cells also take up the dye and their cytoplasm appears to contain a network of fine fibrils (Weddell & Zander, 1950). Under such conditions it is difficult to exclude the possibility that axis cylinders do not give rise to the stained threads seen in association with the Schwann cytoplasm. Moreover, these stained threads appear to fuse with similar processes from neighbouring cells, particularly at the level of the plexiformly arranged nerve fibres. The pattern given is, in fact, very similar to that described by Reiser as the 'preterminal network'. In our opinion such an appearance is the result of non-specific staining and cannot be used as an argument for or against the neuron theory. That it is the Schwann cytoplasm which becomes stained after prolonged treatment with methylene blue, and that the fibrils seen are not in direct continuity with the nerve axis cylinder, can be demonstrated in two ways. If nerves supplying the cornea

are sectioned and a sufficient time left for all the axis cylinders to degenerate—a period of between 20 and 25 days—it is still possible to stain the Schwann cells with methylene blue and to obtain a picture which is in every way similar to that seen after prolonged staining with methylene blue before nerve section, save that the axis cylinders are either completely absent or else represented by small blue-stained fragments which remain in the position of the original course of the axons (Pl. 4, fig. 32). Secondly, if fresh untreated corneal tissue is examined under phase-contrast conditions, the axons are seen to course along the surface of the Schwann cell cytoplasm and to be free from processes which enter the cells. Moreover, under these conditions the Schwann cells are seen to be unshrunk and devoid of beaded processes if the tissue is examined immediately after removal from the animal. In preparations which have been mounted in saline and ringed with vaseline for some 60 min. the Schwann cells are shrunk; their cytoplasm appears granular and commencing to resolve itself into beaded processes. These are even better developed sometime later.

In Reiser's demonstration of the persistence of the 'terminal reticulum' after nerve section, periods of not longer than 72 hr. were allowed for nerve degeneration. Experimental work now in progress has shown that this period is too short, in the case of the cornea, for any but the earliest signs of degeneration to become manifest, and it is therefore not surprising that fine axons persisted in his preparations 72 hr. after nerve section, a fact which, together with the use of a non-specific histological method, would naturally have led him to the conclusion that he drew.

We, like Boeke (1935), have been unable to demonstrate by any method at our disposal the honeycomb-like network of fine fibrils of Reiser's 'terminal reticulum'. Reiser himself published neither photographs nor drawings illustrating these elements in relation to the cells of the corneal epithelium which in any way correspond with his descriptions. Consequently, it is not possible for us to make any further observations on this point.

We have never seen fusion between daughter axons originating from neighbouring nerve fibres. On the other hand, in the epithelium, in methylene blue-stained preparations, we have occasionally seen protoplasmically continuous nets formed by the fusion of daughter axons originating from the same parent fibre. It was probably observations similar to these which led Martinez, who used silver techniques, to have serious doubts about the absolute validity of the neuron theory. These doubts can, we believe, be resolved only by the examination of nerve fibres in whole preparations, and thus it would not have been possible for Martinez, when examining silver-impregnated sections, to have been more definite than he was. For the reasons just discussed, therefore, we do not believe that there is any evidence that corneal innervation can be used in any way to attack the validity of the neuron theory.

### (3) *Corneal innervation and the autonomic nervous system*

Boeke (1935) claims that in the larger bundles in the substantia propria of the cornea there are two types of nerve fibre: somatic fibres and what he terms a 'sympathetic ground plexus'; but he does not indicate why he believes that the 'ground plexus' is of autonomic origin.

We have been able to produce photographs from specimens which are comparable

in every way with the pictures published by Boeke. However, we again had to employ the methods of non-specific staining or impregnation which we used to demonstrate the 'preterminal network' of Reiser. This fact, together with the results of further degeneration experiments, have convinced us that the 'sympathetic ground plexus' in corneal nerve bundles also consists of stained cytoplasmic threads of shrunken and distorted Schwann cells. In preliminary observations following a series of cervical sympathetic neurectomies in the rabbit, we were unable to see any diminution in the number of nerve fibres present in the cornea, or any nerve fibres undergoing degenerative changes. Moreover, a 'sympathetic ground plexus' could still be demonstrated by the use of non-specific histological methods. These experiments are not, of course, conclusive for there are many autonomic ganglion cells scattered along the course of the cerebral vessels, some of which might supply the cornea, but they do suggest that the cornea does not receive a large sympathetic nerve supply. In this we are in agreement with Boeke (1935). We disagree only as to the existence of the 'sympathetic ground plexus' in the larger nerve bundles: a system which Boeke believes to persist, despite the removal of all the nerve fibres supplying the tissues in which they are found.

In a recent paper (Rodger, 1950) reference is made to the fact that the cornea contains sympathetic nerve fibres which are distinguishable from somatic nerve fibres on morphological grounds. The evidence upon which this statement is based is not given. Moreover, the methods used to demonstrate nerve fibres are, in our opinion, quite inadequate for the solution of this problem.

It seems possible that on rare occasions there are a few autonomic nerve fibres to be found in the cornea, for we have seen cells which resemble autonomic ganglion cells (Pl. 3, fig. 22) in three out of over 300 corneas which we have examined. Cells of this type have not been described previously; in fact the presence of ganglion cells has been denied by Ernyei (1934) and Rodger (1950); this is hardly surprising, for if the cells we have described are ganglion cells, they must be very rare. The existence of stray or aberrant autonomic ganglion cells in the distribution of the 5th cranial nerve is common, however, and perhaps their occasional presence in the cornea need cause no surprise (Boyd, 1950).

#### (4) *Correlation of anatomical with physiological observations*

It has now been demonstrated on a number of occasions that a sensation akin to touch can be aroused from the cornea by a light stimulus after the operation of trigeminal tractotomy, which has the effect, in successful cases, of abolishing all corneal pain sensibility. This observation can most easily be explained on the basis of the presence of tactile as well as pain nerves and terminals in the cornea.

When a number one nylon suture is lightly applied to, or drawn across, the corneal epithelium, it arouses a sensation of pain. Two minutes following the instillation of a dilute solution of Pantocaine into the conjunctival sac, however, pain can no longer be aroused in this way, but a sensation akin to touch is perceived whenever the stimulus is applied so as to deform the cornea. The sensation of 'touch' can in turn be abolished by the instillation of a higher concentration of the same anaesthetic. Observations of a similar nature were made by Goldscheider & Brückner in 1919.

In the light of our anatomical findings it is tempting to suggest that these observations can be explained in the following way. The nerves ending in the corneal

epithelium in the form of free-beaded terminals subserve pain; those ending in the substantia propria, also in the form of free-beaded terminals, subserve tactile sensibility.

If this explanation is true, it is of distinct interest and importance, for it suggests that the form in which sensory nerves terminate peripherally cannot necessarily be used as an argument in favour of the type of sensation which will be perceived if they are stimulated.

Tower has shown that a single ciliary nerve fibre transmits action potentials when stimuli are applied over a wide area of the cornea and, in addition, that these sensory units are physiologically independent and overlap one another. The anatomical basis for these physiological demonstrations is now clear.

The arrangement of the nerve terminals in the epithelium in 'depth' rather than as a series of interweaving fibres in a single plane, as in the skin, suggests, on the basis of the observations of Weddell *et al.* (1948), that the quality of pain sensibility aroused from the cornea will be similar to that which tends to give rise to autonomic responses when evoked from the skin.

The significance of the plexiform arrangement of the nerve fibres in the cornea is still unexplained unless it is assumed that the axon terminations have other functions to perform in addition to their sensory role. Such a distribution might be expected if, for instance, the axon terminations behave in a manner in which Lewis (1942) suggested that the 'nocifensor' nerves behave in the skin, but such properties have yet to be demonstrated.

#### SUMMARY

1. A study of the innervation of the cornea in a selected series of vertebrates is presented.
2. A variety of histological methods was used to determine: (a) the general arrangement of the nerve fibres, (b) the structural details of these fibres and their terminations, and (c) their relationship to the tissues which surround them.
3. The observations are discussed in relation to: (a) the literature, (b) the neuron theory, (c) their functional significance.

This investigation was made possible by a grant from the Rockefeller Foundation to whom we wish to express our gratitude.

We would also like to thank Mr Arthur Dent for his skilled technical assistance and Mrs Purves for her excellent drawings.

#### REFERENCES

- AGABABOW, A. (1912). Über die Nerven in den Augenhäuten. *v. Graefes Arch. Ophthalm.* **83**, 317-380.
- ALTSCHÜLER, H. (1940). La sensibilité normale de la cornée humaine. Thèse No. 1742, Genève, Kundig.
- ARNOLD, F. (1832). *Anatomische und physiologische Untersuchungen über das Auge des Menschen*. Heidelberg: Karl Groos.
- ARNSTEIN, C. (1887). Die Methylenblaufärbung als histologische Methode. *Anat. Anz.* **2**, 125-135.
- ATTIAS, G. (1912). Die Nerven der Hornhaut des Menschen. *v. Graefes Arch. Ophthalm.* **83**, 207-316.
- BACH, L. (1896). Die Nerven der Hornhaut und Sklera mit der Golgi-Cajal'schen Osmiumbichromat-Silber-Methode. *Arch. Augenheilk.* **33**, 161-167.
- BECK, B. (1847). *Über die Verbindungen der Sehnerven mit dem Augen- und Nasenknoten*. Heidelberg: J. Groos.

- BERNARD, CLAUDE (1858). *Leçons sur la Physiologie et la Pathologie du Système Nerveux*. Paris: J.-B. Baillière.
- BIELSCHOWSKY, M. & POLLACK, B. (1904). Zur Kenntnis der Innervation des Säugetierauges. *Neurol. Zbl.* **23**, 387–394.
- BOCHDALEK, V. (1837). *Nerven der Cornea*. Bericht über die Versammlung deutscher Naturforscher und Ärzte in Prag.
- BOCHDALEK, V. (1839). Über die Nerven der durchsichtigen Hornhaut und über einiges anderweitiges Verhalten der letzteren. *Med. Jahrbücher oesterr. Staates*, **29**, 185–194, 398–412.
- BOEKE, J. (1925). Die intrazelluläre Lage der Nervenendigungen im Epithelgewebe und ihre Beziehungen zum Zellkern. *Z. mikr.-anat. Forsch.* **2**, 391–428.
- BOEKE, J. (1935). Innervationsstudien. VIII. Zur Innervation der Cornea bei Säugern. Die Innervierung des Bindegewebes der Cornea bei *Macacus rhesus*. *Z. mikr.-anat. Forsch.* **38**, 549–618.
- BOEKE, J. & HERINGA, G. C. (1923). The nervous elements and their relation to the connective tissue in the cornea of the frog's eye. *Versl. gewone Vergad. Akad. Amst.* **27**, 24–32.
- BORRI, N. (1939). Contributo alla conoscenza del contingente nervoso corneale. *Z. Zellforsch.* **29**, 128–137.
- BOYD, J. D. (1950). Nerve supply of the tonsil. *J. Anat., Lond.*, **84**, 79.
- BRAND, E. (1888). Die Nervenendigungen in der Hornhaut. *Arch. Augenheilk.* **19**, 267–276.
- BRÜCKE, H. VON, HELLAUER, H. F. & UMRATH, K. (1949). Azetylcholin- und Aneurinegehalt der Hornhaut und seine Beziehungen zur Nervenversorgung. *Ophthalmologica*, **117**, 19–35.
- CAJAL, S. RAMON Y (1909). *Histologie du Système Nerveux de l'homme et des Vertébrés*, **1**, 460–464. Paris: A. Maloine.
- CIACCIO, G. (1863). On the nerves of the cornea and on their distribution in the corneal tissue of man and animals. *Quart. J. micr. Sci.* **3**, 77–93.
- CIACCIO, G. (1881). Sopra il distribuzione e terminazione delle fibre nervee nella cornea, e sopra l'interna costruzione del loro cilindro dell'asse. *Mem. Accad. med. Genova*, **2**, 577–596.
- COHNHEIM, J. (1866). Über die Endigung der sensiblen Nerven in der Hornhaut der Säugethiere. *Zbl. med. Wiss.* **4**, 401–404.
- COHNHEIM, J. (1867). Über die Endigung der sensiblen Nerven in der Hornhaut. *Virchows Arch.* **38**, 343–385.
- CREVATIN, F. (1903). Beitrag zur Kenntnis der epithelialen Geflechte der Hornhaut der Säugetiere. *Anat. Anz.* **23**, 151–154.
- DOGIEL, A. S. (1890). Die Nerven der Cornea des Menschen. *Anat. Anz.* **5**, 483–494.
- DOGIEL, A. S. (1891). Die Nervenendkörperchen (Endkolben, W. Krause) in der Cornea und Conjunctiva bulbi des Menschen. *Arch. mikr. Anat.* **37**, 602–619.
- EGOROW, I. (1934). Nerven-elemente der Cornea im Meerschweinchenauge. *v. Graefes Arch. Ophthal.* **131**, 531–553.
- EHRlich, P. (1886). Über die Methylenblaureaktion der lebenden Nervensubstanz. *Dtsch. med. Wschr.* **12**, 49–52.
- EISLER, P. (1930). Die Anatomie des menschlichen Auges. *Kurzes Handbuch der Ophthalmologie*, **1**, 1–386, edited by Schieck and Brückner. Berlin: Springer.
- ENGELMANN, TH. W. (1867). *Über die Hornhaut des Auges*. Leipzig: W. Engelmann.
- ERGGELET, H. (1914). Die Bedeutung der Fickschen Kontaktgläser für die Beurteilung des zweiäugigen Sehens durch Brillengläser. *Klin. Mbl. Augenheilk.* **17**, 240–246.
- ERNYEI, I. (1934). Ein Beitrag zur Kenntnis der Nerven der Augenhäute. *v. Graefes Arch. Ophthal.* **132**, 140–154.
- FALCONER, M. A. (1949). Intramedullary trigeminal tractotomy and its place in the treatment of facial pain. *J. Neurol. Neurosurg. Psychiat.* **12**, 297–311.
- FRANCESCHETTI, A. (1932a). *Discussion sur la communication de M. Marx relative aux recherches sur la sensibilité de la cornée*. Société Française d'Ophthalmologie. Alençon, France: Masson et Cie.
- FRANCESCHETTI, A. (1932b). *Zur Sensibilität der Hornhaut*, pp. 242–249. Bericht über die XLIX Zusammenkunft der Deutschen Ophthalmologischen Gesellschaft in Leipzig.
- FREY, M. VON (1894). Beiträge zur Physiologie des Schmerzsinnes. *Ber. d. math. phys. Kl. königl. sächs. Ges. d. Wissensch., Leipzig*. pp. 185–196.
- FREY, M. VON (1922). Die Sensibilität der Hornhaut und Bindehaut des menschlichen Auges. *Dtsch. med. Wschr.* **48**, 212.
- FREY, M. VON & WEBELS, W. (1922). Über die der Hornhaut und Bindehaut des Auges eigentümlichen Empfindungsqualitäten. *Z. Biol.* **74**, 173–190.

- FREY, M. VON & STRUGHOLD, H. (1926). Weitere Untersuchungen über das Verhalten von Hornhaut und Bindehaut des menschlichen Auges gegen Berührungsreize. *Z. Biol.* **84**, 321-334.
- GOLDSCHIEDER, A. & BRÜCKNER, A. (1919). Zur Physiologie des Schmerzes. Die Sensibilität der Hornhaut des Auges. *Berl. klin. Wschr.* **56**, 1125-1126.
- GOTO-YOTARO, (1935). Über die Innervation der Hornhaut des Auges. *Arch. Augenheilk.* **109**, 251-280. (Reference taken from Reiser 1935-6.)
- GRANT, F. C., GROFF, R. A. & LEWY, F. H. (1940). Section of descending spinal root of fifth cranial nerve. *Arch. Neurol. Psychiat.* **43**, 498-509.
- HIS, W. (1863). Über die Einwirkung des salpetersauren Silberoxydes auf die Hornhaut. *Schweizerische Z. Heilk.* **2**, 1-25.
- HOLMES, W. & YOUNG, J. Z. (1942). Nerve regeneration after immediate and delayed suture. *J. Anat., Lond.*, **77**, 63-96.
- HOYER, H. (1866). Über den Austritt von Nervenfasern in das Epithel der Hornhaut. *Arch. Anat. Physiol. wissenschaft. Med.* pp. 180-195.
- HOYER, H. (1873). Über die Nerven der Hornhaut. *Arch. mikr. Anat.* **9**, 220-281.
- HUECK, A. (1839). *Die Bewegung der Krystalllinse*. Dorpat: C. A. Kluge.
- KLEIN, E. (1871). On the peripheral distribution of non-medullated nerve fibres. *Quart. J. micr. Sci.* **11**, 405-416.
- KLEIN, E. (1880). On the termination of the nerves in the mammalian cornea. *Quart. J. micr. Sci.* **20**, 459-475.
- KNÜSEL, O. (1923). Vitale Färbungen am menschlichen Auge. *Z. Augenheilk.* **50**, 23-38.
- KNÜSEL, O. & VONWILLER, P. (1922). Vitale Färbungen am menschlichen Auge. *Z. Augenheilk.* **49**, 157-188.
- KOELLIKER, A. (1848). Über einige anatomisch-physiologische Gegenstände. 2. Über die Nerven der Hornhaut des Menschen und der Wirbeltiere. *Mitt. d. naturf. Ges. in Zürich* (1. Heft), pp. 89-92.
- KOELLIKER, A. (1866). Über die Nervenendigungen in der Hornhaut. *Würzburger naturw. Z.* **6**, 121-127.
- KOEPPE, L. (1919). Klinische Beobachtungen mit der Nernstspaltlampe und dem Hornhautmikroskop. *v. Graefes Arch. Ophthalm.* **99**, 1-15.
- KÖNIGSTEIN, L. (1875). Das Verhältnis der Nerven zu den Hornhautkörperchen. *S.B. math.-naturw. Kl. kgl. Akad. Wiss. Wien*, **71**, 297-302.
- KÖNIGSTEIN, L. (1877). Beobachtungen über die Nerven der Cornea und ihre Gefässe. *S.B. math.-naturw. Kl. kgl. Akad. Wiss. Wien*, **76**, 37-53.
- KÜHNE, M. W. (1862). Note sur un nouvel ordre de nerfs moteurs. *C.R. Acad. Sci., Paris*, **54**, 742-743.
- LADOWSKY, M. (1872). Das Saugadersystem und die Nerven der Cornea. *Arch. mikr. Anat.* **8**, 538-567.
- LAUBER, H. (1936). Die Nerven der Hornhaut: in W. v. Möllendorff's *Handbuch mikroskopischer Anatomie d. Menschen*. III/2, 42-59.
- LEWIS, TH. (1942). Observations upon the vascular axon reflex in human skin, as exhibited by a case of urticaria; remarks upon the nocifensor nerve hypothesis. *Clinical Science*, **4**, 365-384.
- LIGHTBODY, W. H. (1867). Observations on the comparative microscopic anatomy of the cornea of vertebrates. *J. Anat., Lond.*, **1**, 15-43.
- LIPMANN, H. (1869). Über die Endigung der Nerven im eigentlichen Gewebe und im hinteren Epithel der Hornhaut des Frosches. *Virchows Arch.* **48**, 218-227.
- LUSCHKA, H. (1850). Die Nerven der durchsichtigen Augenhaut. *Z. rat. Med.* **10**, 20-30.
- MAGENDIE, F. (1824). De l'influence de la cinquième paire de nerfs sur la nutrition et les fonctions de l'œil. *Physiol. exp. path.* **4**, 176-182.
- MARTINEZ, R. (1940). Étude sur l'innervation de la cornée humaine. *Trab. Inst. Cajal. Invest. Biol.* **32**, 75-109.
- MOSELEY, H. N. (1871). Some remarks on the nerves of the cornea of the rabbit and frog. *Quart. J. micr. Sci.* **11**, 261-262.
- NAFE, J. P. & WAGONER, K. S. (1937). The insensitivity of the cornea to heat and pain derived from high temperatures. *Amer. J. Psychol.* **49**, 631-635.
- NAGEL, W. A. (1895). Die Sensibilität der Conjunctiva und Cornea des menschlichen Auges. *Pflüg. Arch. ges. Physiol.* **59**, 563-595.
- NAGEOTTE, J. (1911a). Le syncytium de Schwann et les gaines de la fibre à myéline dans les phases avancées de la dégénération wallérienne. *C.R. Soc. Biol., Paris*, **70**, 861-865.
- NAGEOTTE, J. (1911b). Le réseau syncytial et la gaine de Schwann dans les fibres de Remak. *C.R. Soc. Biol., Paris*, **70**, 917-921.



- NAGEOTTE, J. (1911c). Syncytium de Schwann, en forme de cellules névrogliales; dans les plexus de la cornée. *C.R. Soc. Biol., Paris*, **70**, 967-971.
- NAGEOTTE, J. (1932). Sheaths of the peripheral nerves. Nerve degeneration and regeneration in W. Penfield, *Cytology and Cellular Pathology of the Nervous System*, pp. 191-232. New York: Paul B. Hoeber.
- NAGEOTTE, J. & GUYON, L. (1926). Le syncytium de Schwann dans les plexus de la cornée, ses connexions avec l'épithélium. *C.R. Ass. Anat.* 21 réunion, pp. 430-436.
- NAKAJIMA, M. (1930). Experimentelle und klinische Beobachtungen der Hornhautnerven der Menschen- und Kaninchenaugen durch vitale Färbung. *Keijo J. Med.* **1**, 99-222.
- PAPPENHEIM, (1839). Über die Nerven der Cornea. *M Schr. Med. Augenheilk. Chir.* **3**, 84-91.
- PAPPENHEIM, (1840). Nachträge zu meinen Untersuchungen über die Nerven der Hornhaut. *M Schr. Med. Augenheilk. Chir.* **3**, 84-91.
- PERIS, E. F. (1947). Morfologia comparada de los fibrocitos de la córnea. *Arch. Esp. Morf.* **5**, 475-485.
- PERIS, E. F. (1948). La invasión corneal: consideraciones clínicas. *Arch. Oftal. hisp.-amer.* **9**, 237-244.
- PETERMOELLER, H. (1869). Die Nerven der Cornea. *Z. rat. Med.* **34**, 88-103.
- PRENDERGAST, J. (1940). Ocular leprosy in the United States. *Arch. Ophthal.* **23**, 112-137.
- PURKINJE, J. E. (1845). Mikroskopisch-neurologische Beobachtungen. *Arch. Anat. Physiol. wissenschaft. Med., Berlin*, pp. 281-295.
- RANVIER, L. (1881). *Leçons d'anatomie générales faites au Collège de France; année 1878-1879*. Paris: J. B. Baillière et fils.
- REISER, K. A. (1935-6). Über die Innervation der Hornhaut des Auges. *Arch. Augenheilk.* **109**, 251-280.
- REISER, K. A. (1936-7). Die Veränderungen am Hornhautnervenapparat nach Exstirpation des Ganglion semilunare beim Kaninchen. *Arch. Augenheilk.* **110**, 253-283.
- RODGER, F. C. (1950). The pattern of the corneal innervation in rabbits. *Brit. J. Ophthal.* **33**, 107-113.
- ROWBOTHAM, G. F. (1939). Observations on the effects of trigeminal denervation. *Brain*, **62**, 364-380.
- SAEMISCH, TH. (1862). *Beiträge zur normalen und pathologischen Anatomie des Auges*. Leipzig: W. Engelmann.
- SCHLEMM, T. F. W. (1831). Nerven der Cornea. Ammon's *Z. Ophthal.* **1**, 113-114.
- SCHORNSTEIN, TH. (1934). Ein Beitrag zur Hornhautinnervation des menschlichen Auges. *Arch. Augenheilk.* **108**, 601-613.
- SCHWALBE, G. (1887). *Lehrbuch der Anatomie der Sinnesorgane*. Erlangen: E. Besold.
- SÉDAN, J. & SÉDAN-BAUBY, S. (1947). Deux faits d'anesthésie cornéenne, conjonctivale et cutanée durable après crises de glaucome aigu. *Rev. Oto-Neuro-Ophtal.* **19**, 251-256.
- SÉDAN, J. & REINHARD, C.-H. (1948). Nouveaux faits d'anesthésie cornéenne en secteur d'origine choroidienne. *Rev. Oto-Neuro-Ophtal.* **20**, 345-350.
- SJÖQVIST, O. (1938a). Eine neue Operationsmethode bei Trigeminalneuralgie: Durchschneidung des Tractus spinalis trigemini. *Zbl. Neurochir.* **2**, 271-281.
- SJÖQVIST, O. (1938b). Studies on pain conduction in trigeminal nerve; contribution to surgical treatment of facial pain. *Acta psychiat.* **17**, 1-13.
- STÖHR, PH. (1941). Zusammenfassende Ergebnisse über die normale und pathologische Histologie der sympathischen Ganglienzellen und der Endapparate im vegetativen Nervensystem. *Z. ges. Anat.* (3. *Ergebn. Anat. Entw. Gesch.*), **33**, 135-284.
- TOWER, S. S. (1935). Nerve impulses from receptors in the cornea. *Proc. Soc. Exp. Biol.* **32**, 590-592.
- TOWER, S. S. (1940). Units for sensory reception in cornea; with notes on nerve impulses from sclera, iris and lens. *J. Neurophysiol.* **3**, 486-500.
- TOWER, S. S. (1942). Pain: definition and properties of the unit for sensory reception. *Res. Publ. Ass. nerv. ment. Dis.* **23**, 16-43.
- VIRCHOW, H. (1910). Mikroskopische Anatomie der äusseren Augenhaut und des Lidapparates. *Graefes-Saemisch Handb. Augenheilk.* **2**, 193-232.
- WALDEYER, W. & YZQUIERDO, V. (1880). Über die Endigungsweise der sensiblen Nerven. *Arch. mikr. Anat.* **17**, 367-382.
- WEDDELL, G., SINCLAIR, D. C. & FEINDEL, W. H. (1948). An anatomical basis for alteration in quality of pain sensibility. *J. Neurophysiol.* **11**, 99-109.
- WEDDELL, G. & ZANDER, E. (1950). A critical evaluation of methods used to demonstrate tissue neural elements, illustrated by reference to the cornea. *J. Anat., Lond.*, **84**, 168-195.
- WOLFF, H. (1912). Über die zentrische reflexlose Mikro-Ophthalmoskopie. *Z. Augenheilk.* **28**, 307-324.
- YOKOMATSU, K. (1931). Über die Innervation der Hornhaut des Auges. *Arch. Augenheilk.* **109**, 251-280. (Reference taken from Reiser, 1935-6.)

## EXPLANATION OF PLATES

## PLATE 1

- Fig. 1. From a methylene blue-stained (intravenous drip method) rabbit's cornea. It shows the arrangement of the subconjunctival and episcleral nerve bundles. ( $\times 80$ .)
- Fig. 2. An infra-red flash photograph from a methylene blue-stained rabbit's cornea *in situ* in the living anaesthetized animal. It shows small nerve bundles arranged in a characteristic manner lying among blood vessels at the corneo-scleral junction. The arrows point to the nerve bundles. ( $\times 120$ .)
- Fig. 3. From a silver impregnated monkey's cornea. It shows in more detail the arrangements seen in fig. 2. ( $\times 350$ .)
- Fig. 4. From a methylene blue-stained rabbit's cornea (intravenous drip method). It shows a bundle at the corneo-scleral junction dividing into three branches. Simple pictures of this sort are not common. ( $\times 150$ .)
- Fig. 5. From a methylene blue-stained rabbit's cornea. It shows axon multiplication at the point of division of a small nerve bundle at the corneal limbus. Such pictures are rare. ( $\times 200$ .)
- Fig. 6. From a methylene blue-stained rabbit's cornea. It shows a nerve bundle at the corneo-scleral junction which contains a single myelinated nerve fibre. ( $\times 400$ .)
- Fig. 7. From the periphery of a methylene blue-stained rabbit's cornea, and shows a myelinated axon in a small nerve bundle entering the cornea giving rise to an unmyelinated daughter axon. ( $\times 280$ .)
- Fig. 8. From the periphery of a methylene blue-stained monkey's cornea and shows a number of myelinated axons. One of the myelinated axons is giving rise to two daughter myelinated axons. This is the only example of such an occurrence we have seen. ( $\times 290$ .)
- Fig. 9. From a methylene blue-stained rat's cornea. It shows an axon taking a recurrent course in a small nerve bundle in the substantia propria. ( $\times 280$ .)
- Fig. 10. From a methylene blue-stained rabbit's cornea and shows a daughter axon leaving a small nerve bundle in the substantia propria and subdividing again almost at once. This kind of picture is rare. ( $\times 400$ .)
- Fig. 11. From a silver impregnated rabbit's cornea. It shows an axon dividing in the substantia propria into two branches each of a different diameter. ( $\times 550$ .)
- Fig. 12. From a methylene blue-stained rabbit's cornea and shows axon multiplication in a small nerve bundle in the substantia propria. Note the abrupt change in direction of one of the daughter axons, and the slight swelling at the point of division. ( $\times 650$ .)
- Fig. 13. From a methylene blue-stained rabbit's cornea following alcohol fixation. It shows axon multiplication at the point of division of a small nerve bundle in the substantia propria. Note the exaggerated swelling of the axis cylinder in this instance. Such swellings are difficult to distinguish from 'ganglion cells' or Schwann cell nuclei. ( $\times 650$ .)
- Fig. 14. From a methylene blue-stained (slightly overstained) rabbit's cornea. It shows a branch leaving a nerve bundle in the substantia propria. The axons in the branch are flattened in a plane at right angles to that in which the axons of the main nerve bundle are flattened. ( $\times 390$ .)
- Fig. 15. From a methylene blue-stained rabbit's cornea. Bundles of axons are seen to be passing in different directions and again to be flattened in different planes as they pass between the layers of the substantia propria. ( $\times 420$ .)

## PLATE 2

- Fig. 16. From a methylene blue-stained guinea-pig's cornea. It shows a nerve bundle terminating in the plexiform arrangement of nerve fibres. ( $\times 300$ .)
- Fig. 17. From a methylene blue-stained rabbit's cornea. It shows the plexiformly arranged nerve fibres lying deeply (out of focus) in the centre of the cornea and giving rise to beaded fibres (in focus) in the epithelium. ( $\times 150$ .)
- Fig. 18. From a gold impregnated rabbit's cornea. It shows a nerve bundle halfway between the sclera and the centre of the cornea dividing into a number of branches. ( $\times 250$ .)
- Fig. 19. From a methylene blue-stained guinea-pig's cornea. It is somewhat 'overstained', but gives a good idea of the way nerve bundles divide after entering the cornea. Almost all the cornea is seen in the picture. ( $\times 90$ .)
- Fig. 20. From a methylene blue-stained rabbit's cornea. The tip of the incision is approximately at the centre of the cornea. A large nerve bundle can be seen passing from one limbus to the other equatorially across the cornea, and another bundle can be seen joining it near the tip of the incision. ( $\times 60$ .)

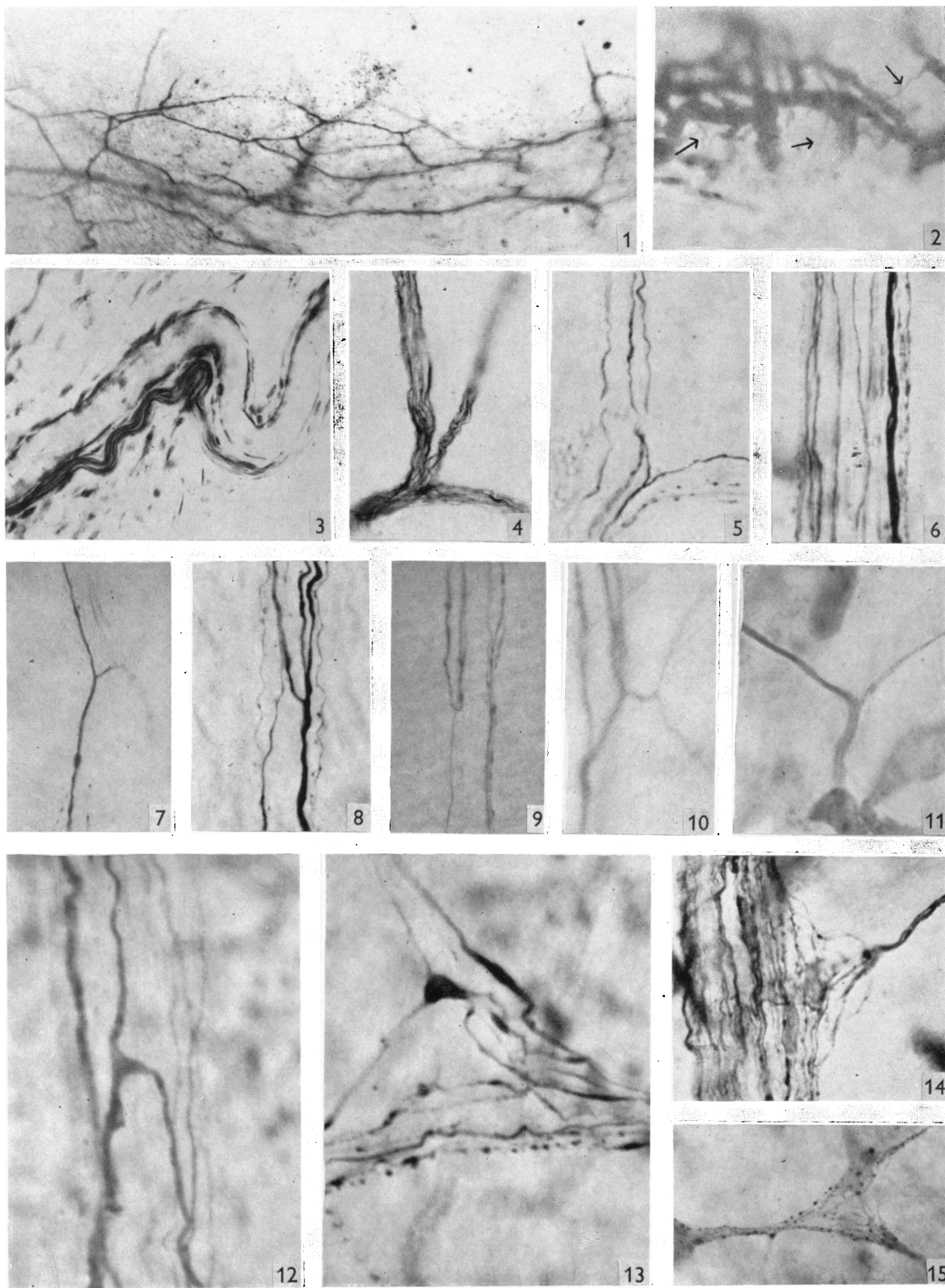
Fig. 21. From a gold impregnated rabbit's cornea. It shows a medium-sized nerve bundle passing from one limbus to the other across the centre of the cornea. Almost the whole cornea is represented. ( $\times 90$ .)

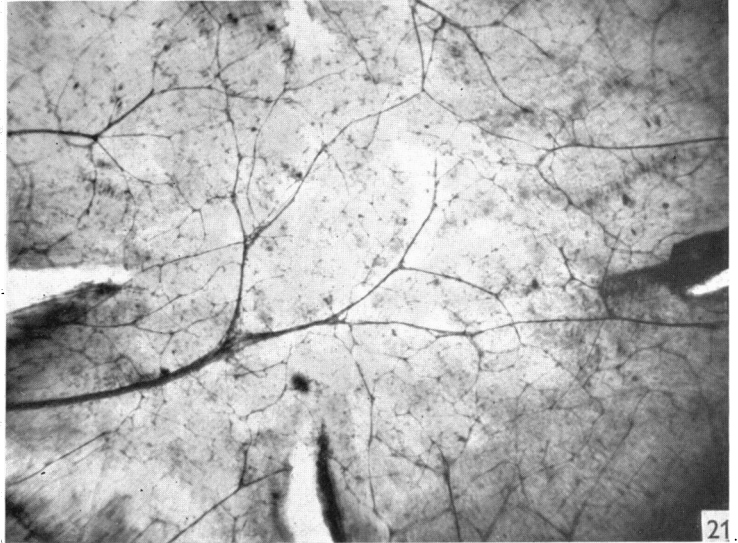
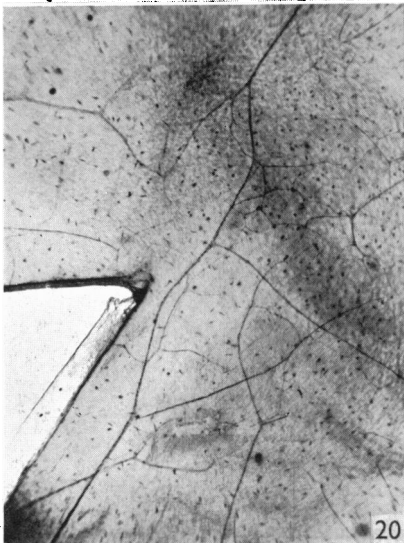
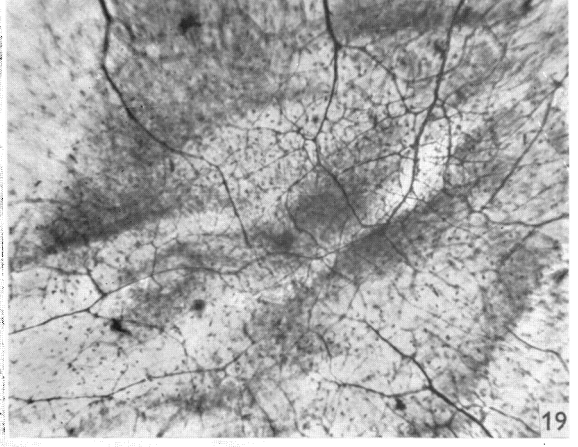
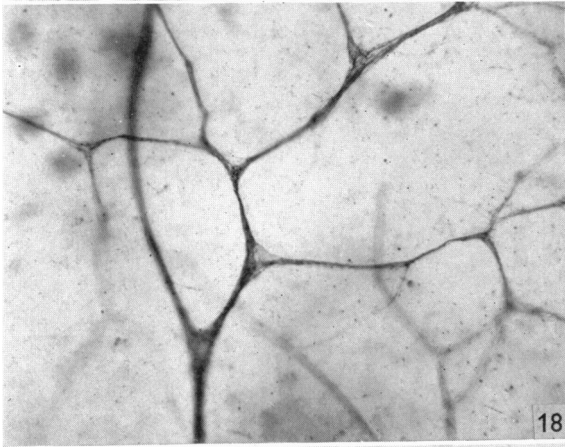
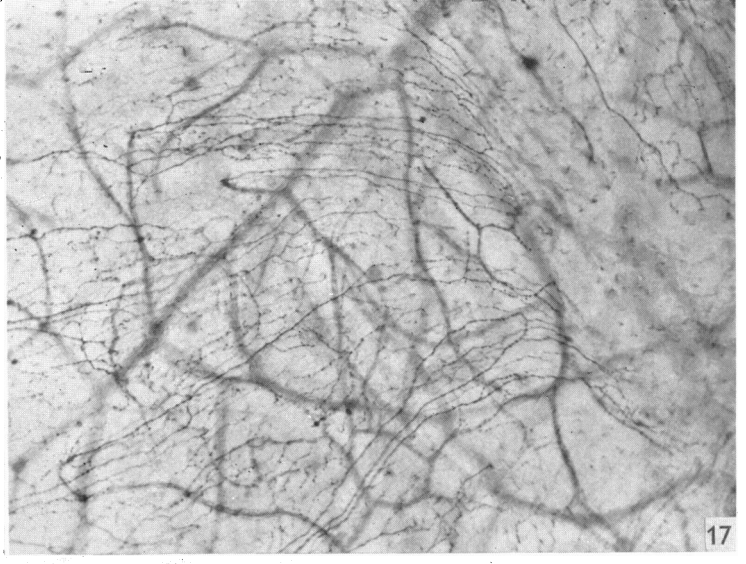
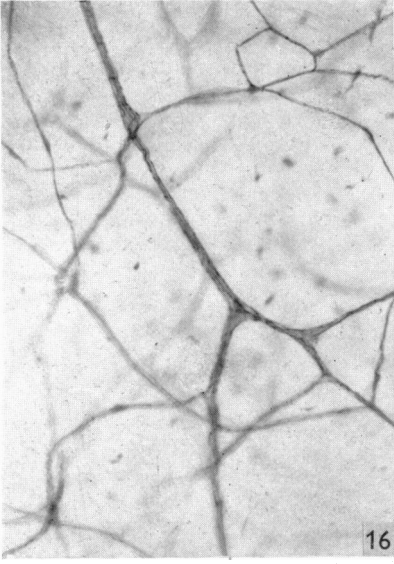
## PLATE 3

- Fig. 22. From a methylene blue-stained rabbit's cornea. It shows a nucleated 'ganglion' cell in the substantia propria. Such cells are very rare. ( $\times 700$ .)
- Fig. 23. From a methylene blue-stained rabbit's cornea. It shows an axon which gives rise to terminals in the substantia propria arising from a nerve bundle. ( $\times 350$ .)
- Fig. 24. From a methylene blue-stained guinea-pig's cornea. It shows an axon which gives rise to terminals in the substantia propria arising from a nerve bundle. This figure should be compared with figs. 23 and 25. ( $\times 300$ .)
- Fig. 25. From a methylene blue-stained rabbit's cornea. It shows an axon which gives rise to terminals in the substantia propria arising from the plexiform arrangement of nerve fibres. ( $\times 200$ .)
- Fig. 26. Also from a methylene blue-stained rabbit's cornea, showing the complex pattern formed by nerve fibres before they terminate in the substantia propria. ( $\times 350$ .)
- Fig. 27. From a methylene blue-stained rabbit's cornea. It shows a complete spray of terminal beads in the substantia propria. ( $\times 350$ .)
- Fig. 28. From a methylene blue-stained rat's cornea. It also shows the complex pattern formed by a nerve fibre terminating in the substantia propria. This figure should be compared with fig. 26. ( $\times 350$ .)
- Fig. 29. From a silver impregnated rabbit's cornea and shows an axon (associated with a Schwann cell nucleus and cytoplasm) in the substantia propria passing in close relation to a corneal corpuscle and giving rise to what appears to be a branch which ends on its surface. ( $\times 800$ .)
- Fig. 30. From a methylene blue-stained rabbit's cornea. It shows a sheet of corneal epithelium lining the anterior chamber which has been stripped away from Descemet's membrane. No nerve fibres are seen but there are a few circular blobs of stain lying between the cells. ( $\times 400$ .)

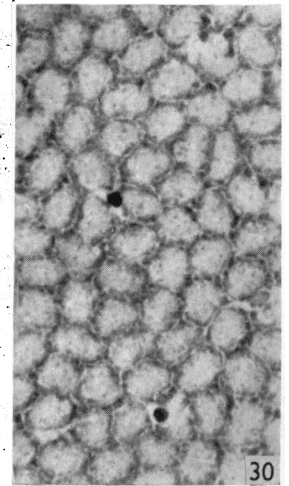
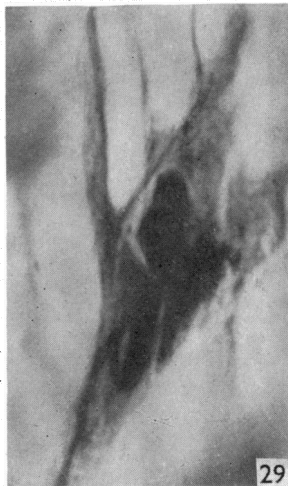
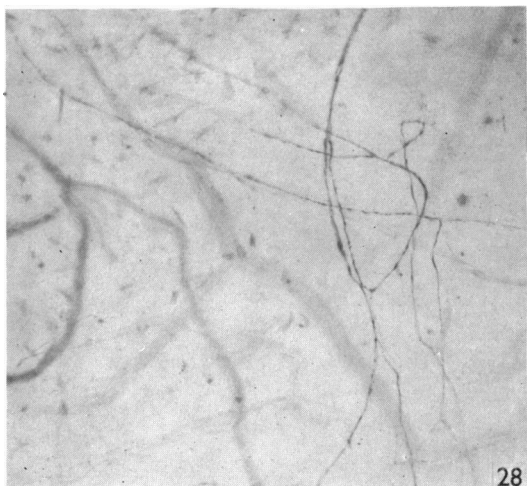
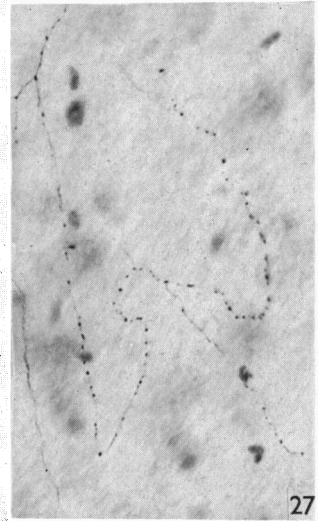
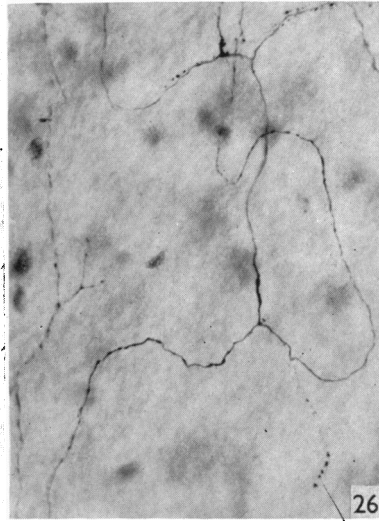
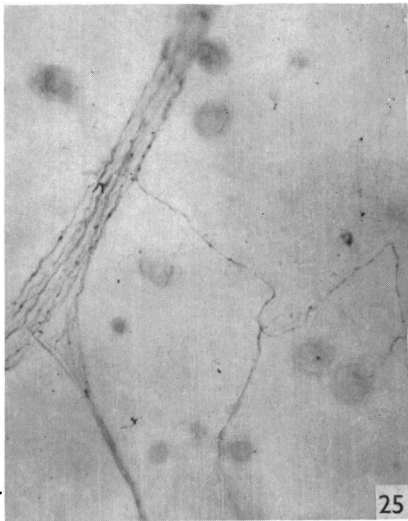
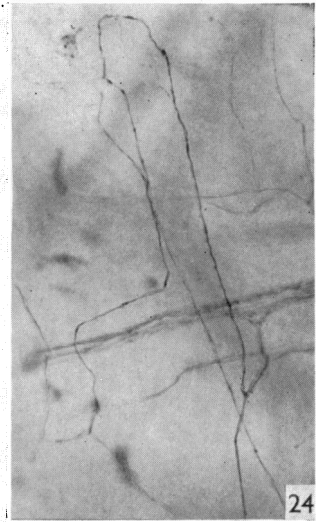
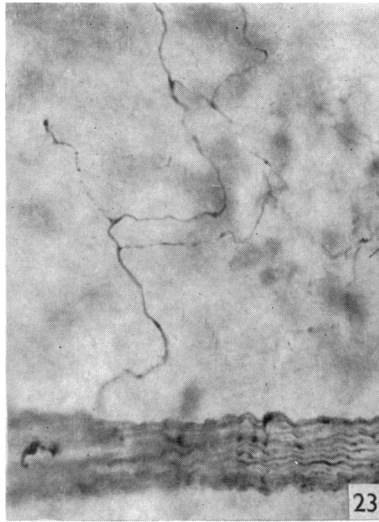
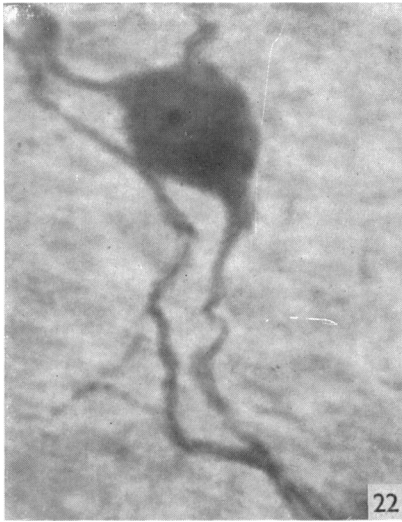## PLATE 4

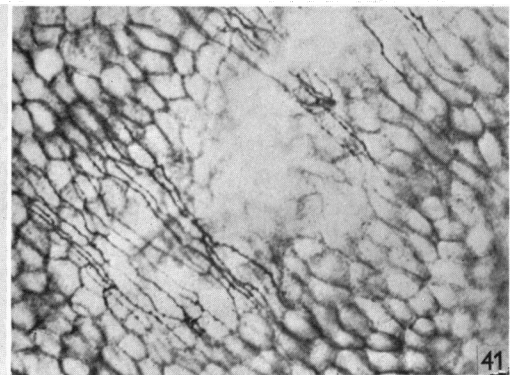
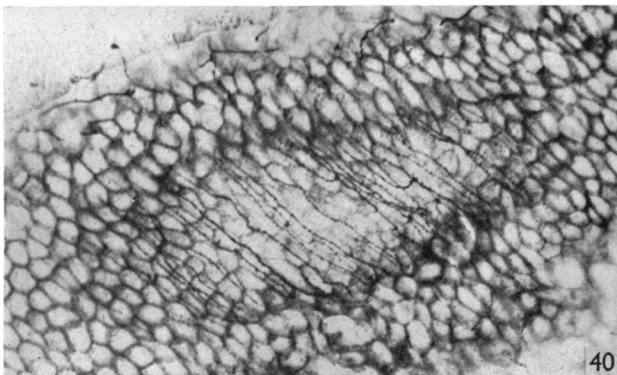
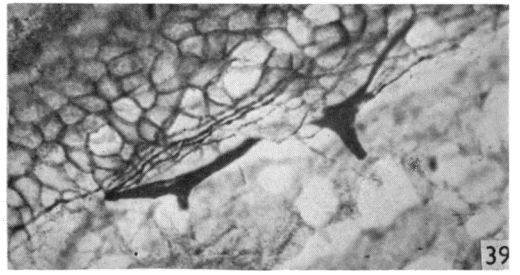
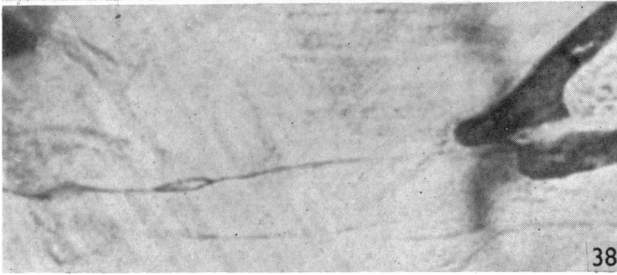
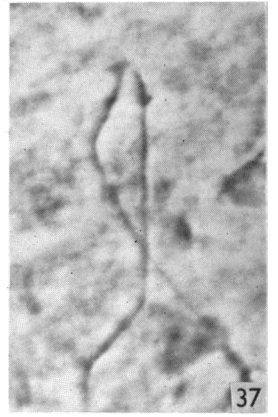
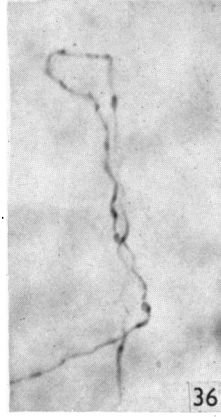
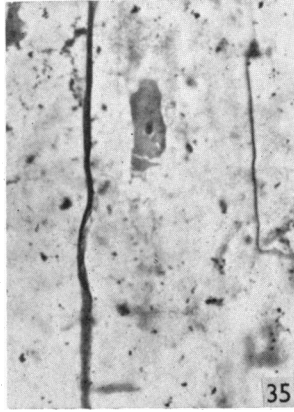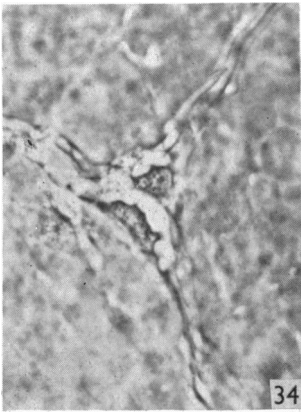
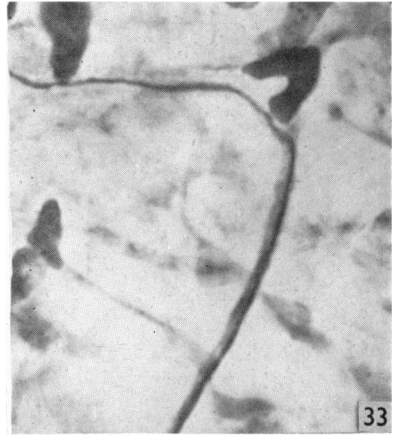
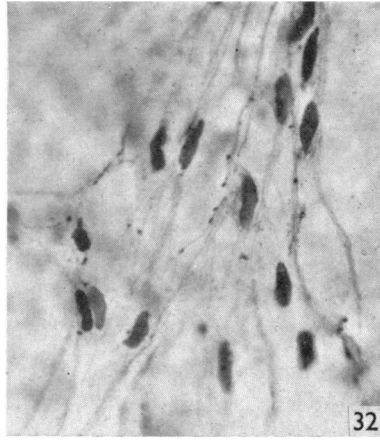
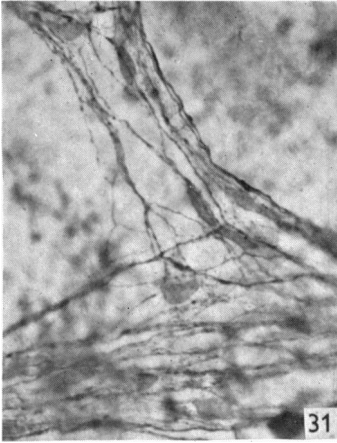
- Fig. 31. From a rabbit's cornea which has been deliberately overstained with methylene blue. It shows a nerve bundle in which the nerve axis cylinders have been stained as well as the Schwann cells. The Schwann cell nuclei can be identified easily, but the cytoplasm is so shrunken and distorted that it is impossible to distinguish some of the cellular processes from nerve axis cylinders. ( $\times 45$ .)
- Fig. 32. From the centre of a methylene blue-stained rabbit's cornea. The central two-thirds of this cornea had been excised and replaced as an autoplasmic graft 20 days previously. It shows Schwann cell nuclei surrounded by shrunken and distorted cytoplasm. No nerve fibres can be seen. Compare this figure with figure 31. ( $\times 450$ .)
- Fig. 33. From a silver impregnated rabbit's cornea. It shows a single nerve fibre related in the lower half of the picture to a Schwann cell; when traced distally the axon proceeds in an apparently naked state. ( $\times 700$ .)
- Fig. 34. From a monkey's cornea. The preparation is a fresh unstained razor slice. It shows the appearance of a small nerve bundle in the substantia propria under phase-contrast conditions. Note the Schwann cell nuclei and cytoplasmic pathways. ( $\times 450$ .)
- Fig. 35. From a gold impregnated rabbit's cornea. It shows two axons in the substantia propria. The thick axon is related to Schwann cytoplasm whilst the thin axon is apparently naked. ( $\times 480$ .)
- Fig. 36. From a methylene blue-stained rabbit's cornea. It shows the peculiar course taken by a number of single axons in the substantia propria. Compare with fig. 37. ( $\times 600$ .)
- Fig. 37. From a rabbit's cornea examined under phase-contrast conditions. It shows a single axon in the substantia propria behaving in a manner resembling that seen in fig. 36. ( $\times 600$ .)
- Fig. 38. From a silver impregnated rabbit's cornea showing a single nerve fibre in the substantia propria apparently terminating on the cytoplasm of a corneal corpuscle. Note the slight irregularity and splitting of the axon. ( $\times 900$ .)
- Fig. 39. From a gold impregnated rabbit's cornea. It shows nerve bundles giving rise to a penicillium of beaded axons which ramify between the cells of the basal layer of the epithelium. ( $\times 350$ .)
- Figs. 40, 41. Both are from gold impregnated rhesus monkey corneas. They are taken at different depths from the surface and illustrate clearly that there are no nerve fibres ramifying in the plane between Bowman's membrane and the basal epithelial layer. ( $\times 300$ ;  $\times 350$ .)

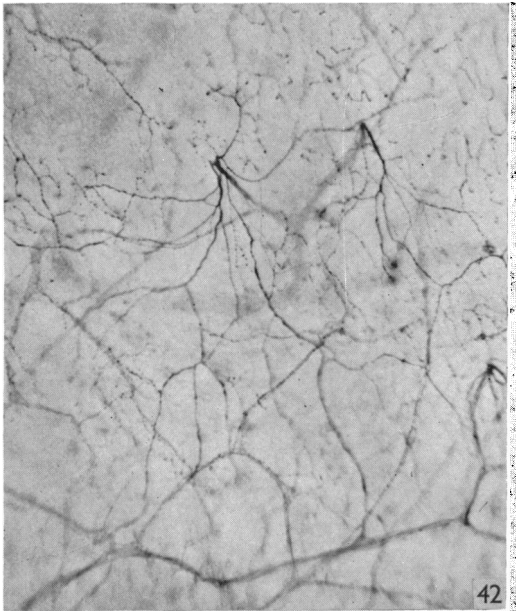




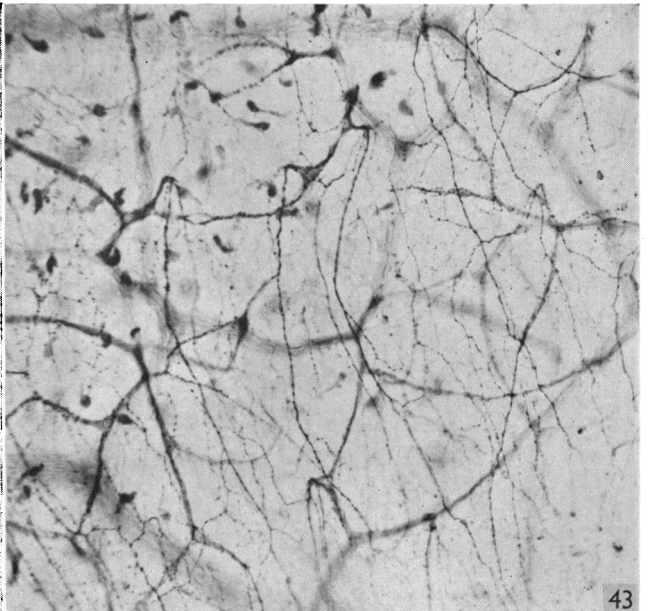




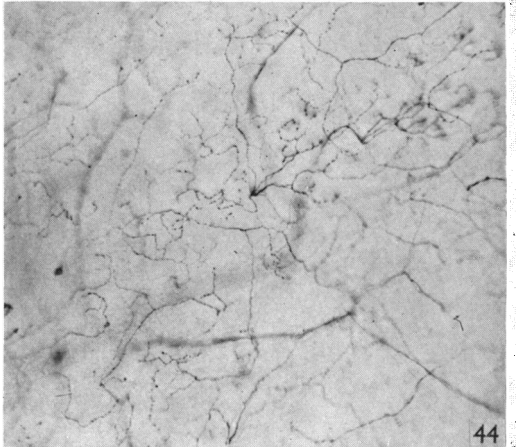




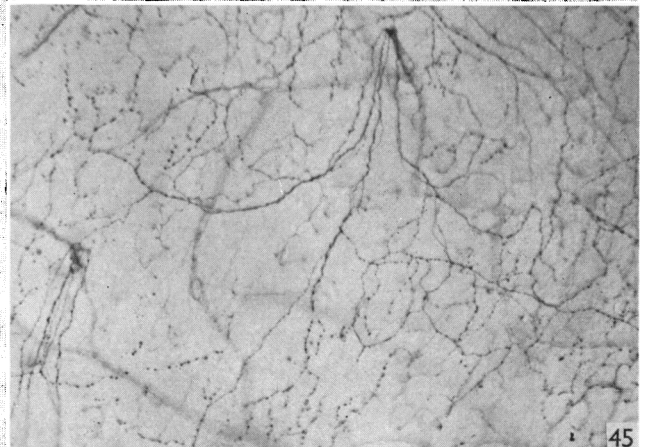
42



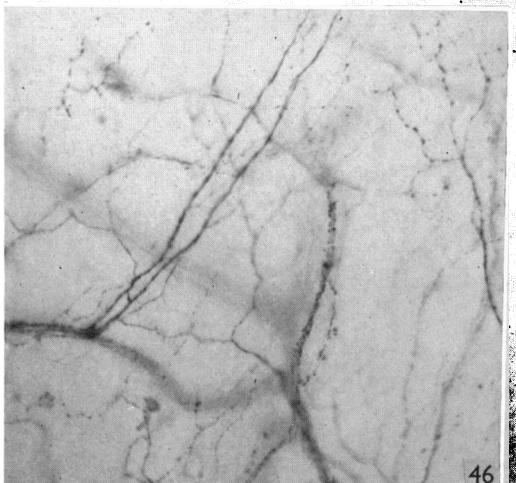
43



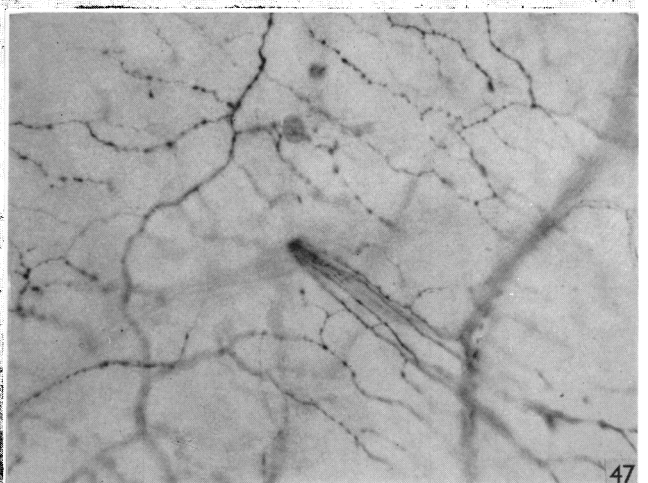
44



45

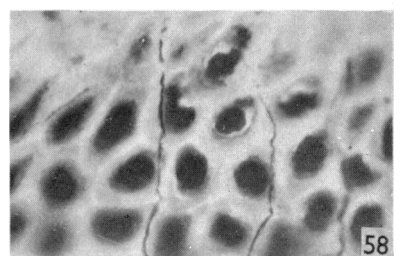
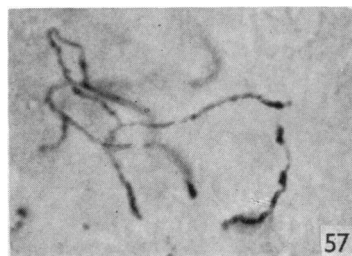
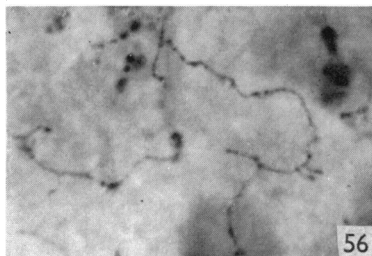
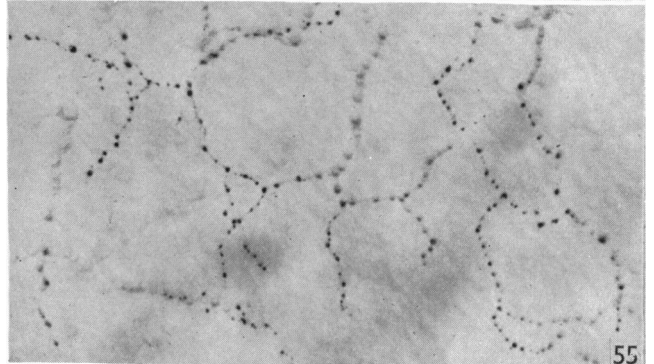
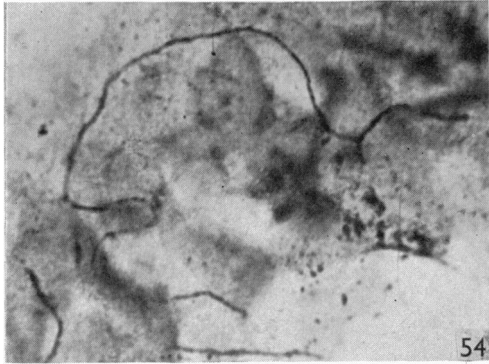
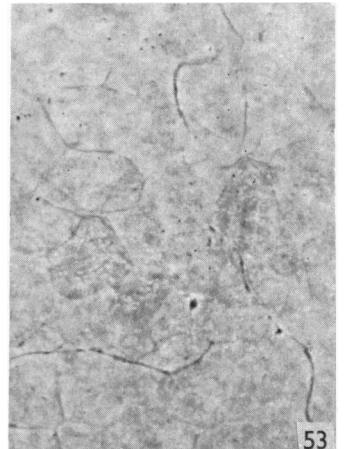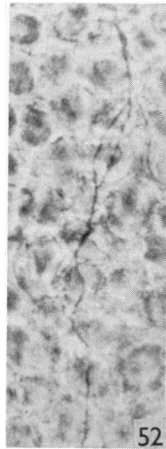
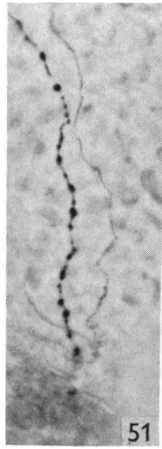
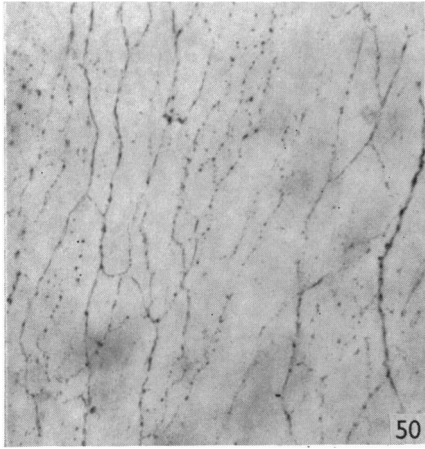
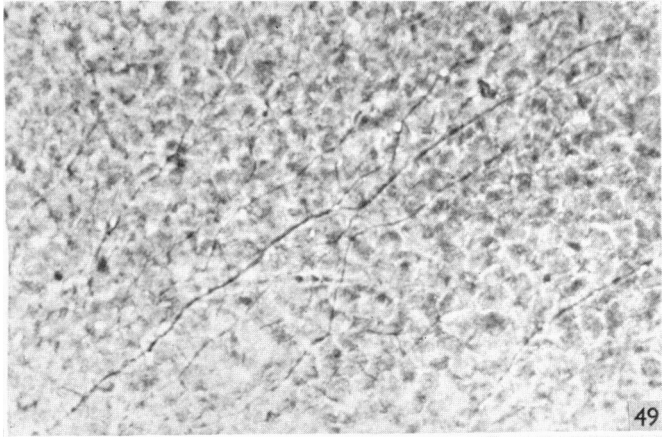
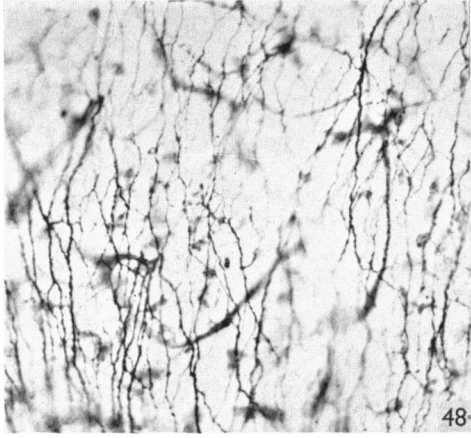


46



47





## PLATE 5

All figures are from methylene blue-stained preparations.

- Fig. 42. From the periphery of a rabbit's cornea. It shows axons piercing Bowman's membrane, multiplying and passing in all directions in the epithelium. ( $\times 150$ .)
- Fig. 43. From a position not far from the centre of a rabbit's cornea. It also shows axons piercing Bowman's membrane almost vertically, multiplying and passing in a radial direction in the epithelium. ( $\times 160$ .)
- Fig. 44. From the periphery of a guinea-pig's cornea. It shows axons piercing Bowman's membrane, multiplying and passing in all directions in the epithelium. ( $\times 140$ .)
- Fig. 45. From a position near the centre of a rabbit's cornea. It also shows axons piercing Bowman's membrane almost vertically, multiplying and passing in all directions in the epithelium. ( $\times 130$ .)
- Fig. 46. From a rabbit's cornea and shows an axon dividing into two after piercing Bowman's membrane. ( $\times 280$ .)
- Fig. 47. From a rabbit's cornea and shows an axon dividing into numerous branches after piercing Bowman's membrane. ( $\times 300$ .)

## PLATE 6

- Fig. 48. From a methylene blue-stained rabbit's cornea. It shows axons ramifying at different depths in the epithelium. ( $\times 300$ .)
- Fig. 49. From a monkey's cornea examined under phase-contrast conditions. It shows much the same thing as fig. 50, but the epithelial cell bodies can also be seen. ( $\times 350$ .)
- Fig. 50. From a methylene blue-stained monkey's cornea. It shows beaded axons ramifying in the basal part of the epithelium. ( $\times 300$ .)
- Fig. 51. From a tangential frozen section of a methylene blue-stained rabbit's cornea. It shows two beaded axons of different diameters situated in about the middle third of the epithelium. The finer of the two axons shows very little beading. ( $\times 450$ .)
- Fig. 52. From a rabbit's cornea. The preparation was a fresh untreated razor slice of corneal epithelium. The appearances are those seen under phase-contrast conditions. Note that the beads are very fine. ( $\times 600$ .)
- Fig. 53. From a monkey's cornea. The preparation was a fresh untreated razor slice of corneal epithelium examined under phase-contrast conditions *immediately* after removal. Note the narrow diameter of the nerve fibres, and the extreme fineness of the beads along their course. The nerve fibres and their terminals are all situated extracellularly. ( $\times 600$ .)
- Fig. 54. From a gold impregnated rabbit's cornea. It shows nerve fibres in the epithelium. The fibres towards the surface are beaded. ( $\times 500$ .)
- Fig. 55. From a methylene blue-stained monkey's cornea. It consists solely of epithelium, which has been stripped off the substantia propria. It shows beaded nerve fibres terminating extracellularly in end-beads passing in between cells in the middle-third of the epithelium. ( $\times 500$ .)
- Fig. 56. From a methylene blue-stained rabbit's cornea. It is from a tangential frozen section and shows finely beaded nerve fibres lying between the corneal epithelial cells. ( $\times 500$ .)
- Fig. 57. From a methylene blue-stained rabbit's cornea. It is also from a tangential frozen section and shows finely beaded nerve fibres in the epithelium. Note the enlarged end-beads. ( $\times 600$ .)
- Fig. 58. From a silver impregnated vertical section of a dogfish's cornea. It shows fine nerve fibres becoming beaded as they approach the more superficial layers of the epithelium. They lie between the epithelial cells. The finest fibres cannot be demonstrated by this method. ( $\times 600$ .)