

Cardioangiographic findings in patients with arrhythmogenic right ventricular dysplasia

CARINA BLOMSTRÖM-LUNDQVIST,* KJELL SELIN,† ROBERT JONSSON,‡
STEN R JOHANSSON,* DAVID SCHLOSSMAN,† S BERTIL OLSSON*

*From the *Division of Cardiology, Medical Department I, Sahlgren's Hospital; †Department of Diagnostic Radiology, Sahlgren's Hospital, Gothenburg; ‡Department of Statistics, University of Gothenburg, Gothenburg, Sweden*

SUMMARY The dimension, contractility, and regional wall motion of the right and left ventricles were scored on the angiograms of 13 patients with arrhythmogenic right ventricular dysplasia. In 10 patients the right ventricle was enlarged, in eight the contractility of the right ventricle was reduced, and in all but one patient there were regional wall motion abnormalities of the right ventricle. The most common abnormality of regional wall motion was mild hypokinesia. There were bulging or dyskinetic areas in seven patients. Regional wall motion abnormalities of the left ventricle were found in five patients, two of whom also had bulging or dyskinetic areas. The reproducibility of right ventricular dimension, contractility, and regional wall motion scores was generally fair but varied unexpectedly both within and between two observers (Kendall's Tau 0.38-0.92). The score values of regional wall motion for some of the segments differed considerably within and between observers. One of the observers consistently gave higher scores than the other.

These data suggest that a more objective approach is needed for evaluating angiographic changes in arrhythmogenic right ventricular dysplasia.

Patients with arrhythmogenic right ventricular dysplasia usually have recurrent right ventricular tachycardia¹⁻³ and variable replacement of right ventricular myocardial tissue by adipose and fibrous tissue.⁴⁻⁶ The clinical diagnosis is based on demonstration of morphological changes in the right ventricular wall in the absence of any other identifiable structural heart or pulmonary disease.^{1,2} Although right ventricular wall motion abnormalities can also be detected by echocardiography,⁷⁻⁹ radionuclide angiography,^{7,10,11} and cine-computed tomography,¹² right ventricular angiography is generally regarded as the standard in the diagnosis of arrhythmogenic right ventricular dysplasia.^{2,3,8} Recently, certain regional right ventricular angiographic characteristics were suggested as diagnostic criteria for this disorder.¹³ It is not known how reproducible these measurements are, however.

The objective of our study was to describe and

evaluate the angiographic findings in a group of patients with arrhythmogenic right ventricular dysplasia, and to try to assess the reproducibility of global and regional right ventricular findings within and between observers.

Patients and methods

We studied 13 patients (nine men and four women, mean age 34) referred with ventricular tachycardia and with a history and clinical findings consistent with arrhythmogenic right ventricular dysplasia (table 1). All patients had ventricular tachycardia with a left bundle branch block configuration. Electrophysiological testing in 10 confirmed the right ventricular origin of the ventricular tachycardia. No patient was in cardiac failure at the time of the study. Arrhythmogenic right ventricular dysplasia was diagnosed on the basis of the characteristics of ventricular tachycardia, the results of signal-averaged surface electrocardiogram and electrophysiological studies, echocardiographic findings, and radionuclide angiography or cinecardioangiography or both. No patient had clinical or angiographic evidence of coronary artery disease or

Requests for reprints to Dr Carina Blomström-Lundqvist, Division of Cardiology, Medical Department I, Sahlgren's Hospital, S-413 45 Gothenburg, Sweden.

Accepted for publication 13 October 1987

Table 1 Clinical details and a summary of right ventricular wall motion abnormalities in 13 patients with arrhythmic right ventricular dysplasia

Case No	Age (yr) and sex	Symptom duration (months)	ECG T inv	Q waves	X ray heart size	AA treatment during study	Total RW-MS
2	25 M	144	V1-V4	0	↗ (RV+)	0	25
3	31 M	288	V1-V4	V6	↗ (RV+)	Quinidine, digitalis	23
7	41 M	3	V1, III	0	N	Sotalol	13
8	15 M	5	V1-V4, aVF-III	0	N	0	9
9	41 F	31	0	0	N	Mexiletine, disopyramide	10
10	35 M	84	V1-V4, III	aVF-III	↗	Metoprolol, tocainide	9
11	25 M	7	V1-V3	V1-V3	N	Flecainide	30
13	49 F	300	V1	0	N	0	11
14	49 F	48	V1-V2	0	N (RV+)	0	12
15	40 M	4	V1	0	N	Metoprolol	8
16	25 M	48	V1-V2, aVF-III	0	↗ (RV+)	0	24
17	36 M	12	V1	0	↗ (RV+)	0	13
19	31 F	12	V1	0	N	Sotalol	16

Heart size was measured by calculating the relative cardiac volume. AA, antiarrhythmic; N, normal; RV+, prominent right ventricle; RWMS, right ventricular regional wall motion score; T inv, T wave inversion; ↗, increased heart size.

other organic heart disease. The long term follow up of ten patients in this series has been reported earlier, and the case numbers assigned to them have been retained.¹⁴

CARDIOANGIOGRAPHY

Right ventricular cineangiography was performed from the femoral approach with an 8 F Grollman catheter. Contrast was injected into the right atrium in three patients, into the right ventricle in seven, and into both cavities in three patients. The left ventricle was visualised in the levophase after injection of radio-opaque dye into the right ventricle in five patients and by selective left ventricular angiography in eight patients. Approximately 50 ml of Isopaque Coronar (metrizoate), 370 mg I/mol, was injected at a rate of 13 ml/s. Angiograms were acquired at 75 frames per second and presented in both right anterior oblique and left anterior oblique projections. The ventriculograms were reviewed independently by experienced observers who did not know the patient's identity and clinical status. The evaluations were performed according to a standardised protocol, but the observers were also instructed to comment on abnormal findings not included in the protocol. Right and left ventricular dimensions were visually assessed as normal, mildly, moderately, or considerably enlarged (scored 1, 2, 3, and 4 respectively). The overall contractility was classified as normal, fair, poor, or as severely hypokinetic (scored 1, 2, 3, and 4 respectively).

To evaluate regional wall motion, the right and left ventricles were divided into segments (fig 1). Each segment was classified as normal, mildly, or severely hypokinetic, akinetic or dyskinetic (scored as 1, 2, 3, 4, and 5 respectively). The right ventricular outflow tract was classified as normal or wide (scored as 1 and

5 respectively). Segment scores were added, and the wall motion score of the right ventricle was expressed numerically. The minimum/maximum wall motion score for the right ventricle was 8/40. The left ventricular ejection fraction, measured in 11 patients, was calculated by the single plane area length technique.¹⁵ Each patient had coronary arteriography. In some patients medication could not

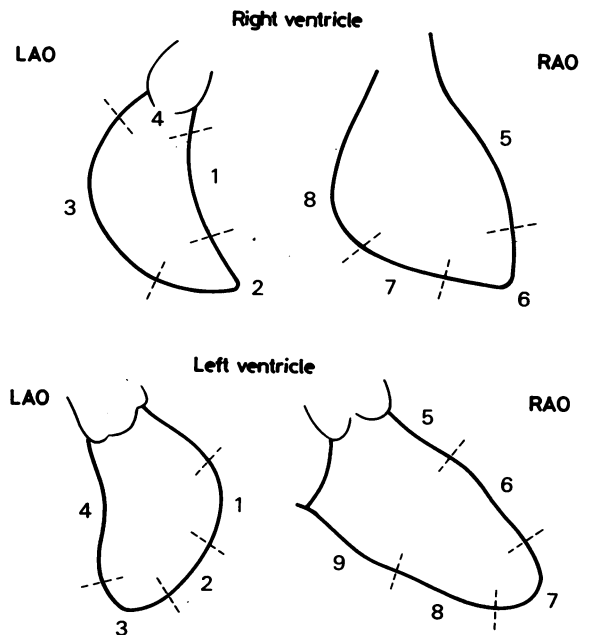


Fig 1 In the left anterior oblique (LAO) view each ventricle was divided into four segments. In the right anterior oblique (RAO) view the right ventricle was divided into four and the left ventricle into five segments.

Table 2 Right ventricular regional wall motion scoring in 13 patients with arrhythmogenic right ventricular dysplasia

Region	Normal	Mild hypokinesia	Severe hypokinesia	Akinesia	Dyskinesia (wide)	Total abnormalities (cases)
LAO:						
R1	9	2	1	0	1	4
R2	7	4	1	0	1	6
R3	9	0	2	1	1	4
R4	7	—	—	—	(6)	6
RAO:						
R5	9	4	0	0	0	4
R6	8	4	0	0	1	5
R7	6	4	1	1	1	7
R8	5	3	1	0	4	8
Total (regions)	60	21	6	2	9 (6)	

The numbers of patients are shown unless stated otherwise. Mild hypokinesia was the most frequent regional wall motion abnormality (21 regions); this was evenly distributed among the segments in the right ventricle. Dyskinesia was most often seen in the inferobasal region (R8), which was also the most commonly involved region in arrhythmogenic right ventricular dysplasia. LAO, left anterior oblique view; R, right ventricular segment; RAO, right anterior oblique view.

be safely discontinued at the time of the study (table 1).

STATISTICAL METHODS

To assess the reproducibility of right ventricular findings, between and within observers, each angiogram was interpreted both by a pair of observers on one occasion (observers 1) and also by one observer (observer 2) on two occasions separated by an interval of several weeks. We assessed the reproducibility by calculating Kendall's Tau_b, which is a measure of rank correlation.¹⁶ Kendall's Tau was also used to test the null hypothesis of zero correlation in the underlying population.

To assess whether there was any bias in awarding high or low scores we compared the proportions of high scores for each of the ten variables (dimension, contractility, and regional wall motion in segment R1

to R8) awarded by observers 1 and 2 and between the first and second interpretation of observer 2. Scores of 3 and 4 or 4 and 5 were defined as high for global and regional changes respectively. The two sided exact binomial test (sign-test) was used to compare the proportions.

Results

MORPHOLOGICAL FINDINGS

The following angiographic findings were reported by the two observers. The right ventricle was enlarged in ten patients, eight of whom also had a reduced overall contractility. All but one patient (case 15) had abnormal regional wall motion of the right ventricle. This patient, however, was twice judged by observer 2 to have abnormal wall motion on angiography. The most frequent local wall motion abnormality was a

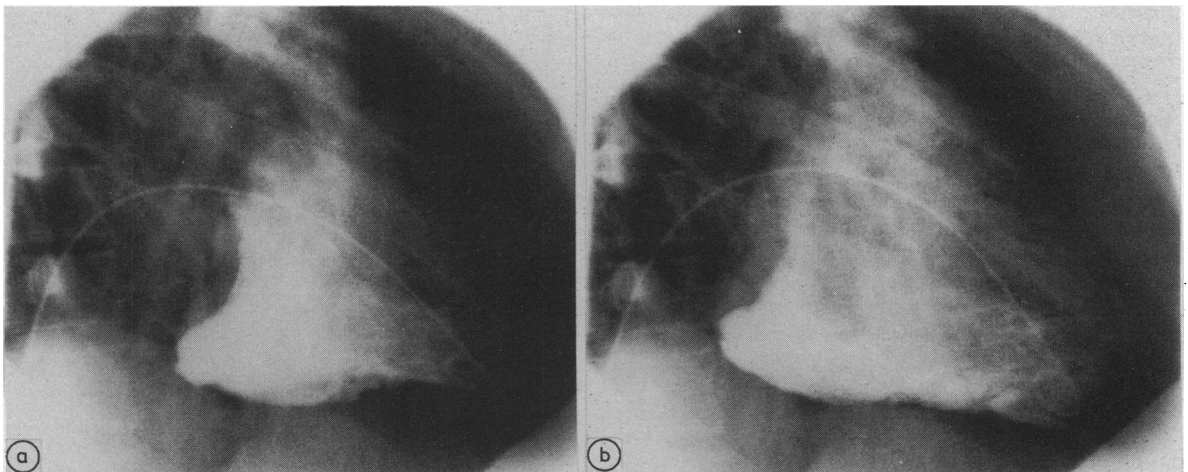


Fig 2 Right ventriculogram of patient 16 from the right anterior oblique view. There are dyskinetic outpouchings in the inferior segments of the right ventricle where stagnation of contrast is evident. (a) End systole and (b) end diastole.

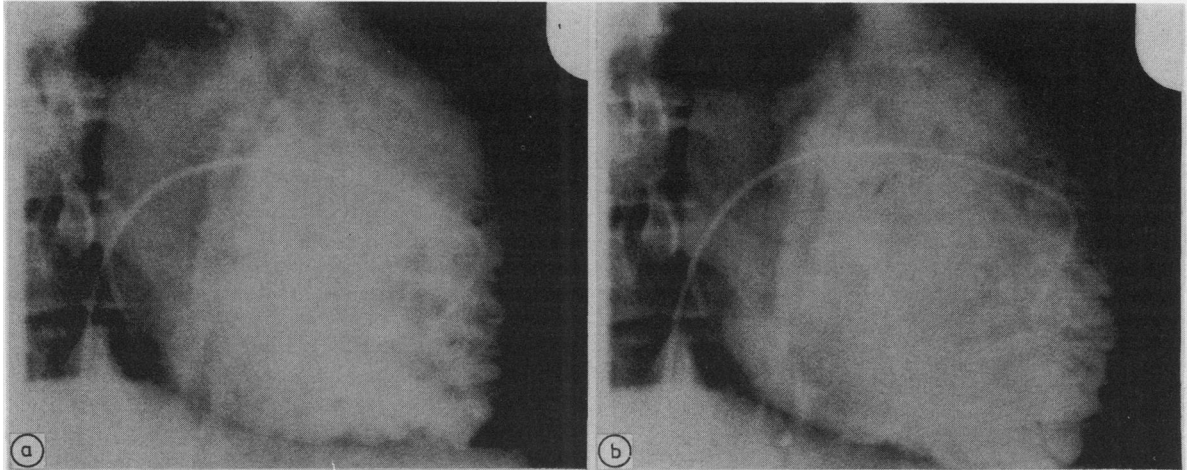


Fig 3 Right ventriculogram of patient 3 from the right anterior oblique view. Note the fissuring of the anterior wall. (a) End systole and (b) end diastole.

mild hypokinesia (table 2). Most changes in regional wall motion were found in the inferior portion of the right ventricle (segments R7 and R8). Pronounced bulging, outpouchings, or dyskinetic areas were found in seven patients. These changes were most common in the inferior segments (fig 2), but were also seen in the anterolateral, septal, and apical regions (table 2). Elimination of dye in the dyskinetic regions was always slow. Deep fissuring of the anterior right ventricular wall was evident in one patient (case 3) (fig 3). A wide right ventricular outflow tract was found in six patients. The right ventricle was considerably trabeculated in two patients (cases 2 and 3) (fig 4). In two patients (cases 8 and 13) abnormal

regional wall motion was recognised only in one projection; this was the left anterior oblique and right anterior oblique respectively.

The left ventricle was slightly or moderately enlarged in three patients (cases 3, 11, and 16), all of whom had a considerably enlarged right ventricle. The overall contractility was classified as fair in two patients (cases 16 and 19) and poor in one (case 3), but it was normal in all other patients. Abnormal regional wall motion of the left ventricle was found in four patients, all of whom had evidence of functional impairment and three of whom had only mild hypokinesia. Outpouchings or dyskinetic regions were found in only one patient (case 3). This patient

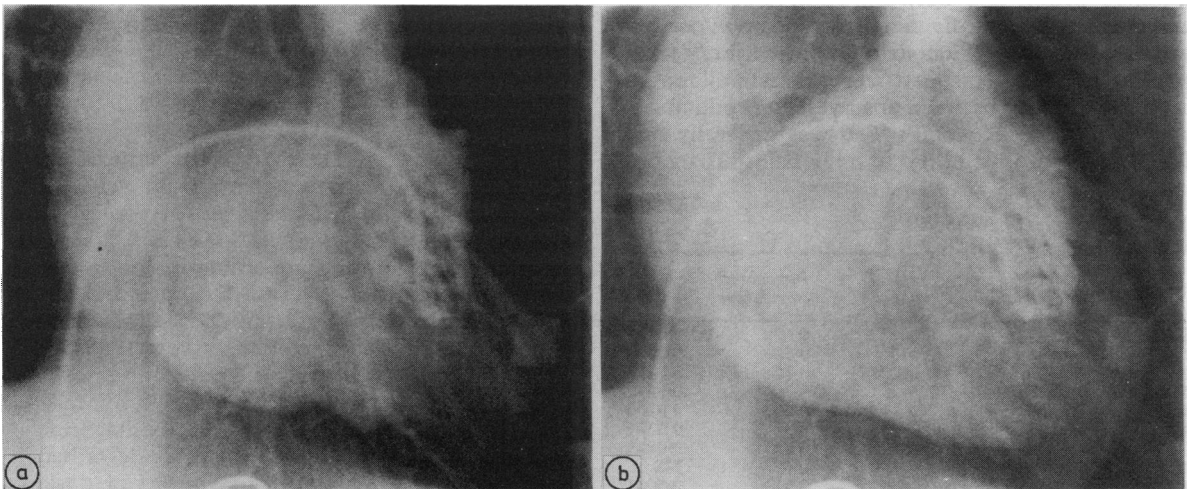


Fig 4 Right ventriculogram of patient 2 from the right anterior oblique view. The right ventricle is enlarged, hypokinetic, and considerably trabeculated. There is dyskinesia in the inferobasal segments. (a) End systole and (b) end diastole.

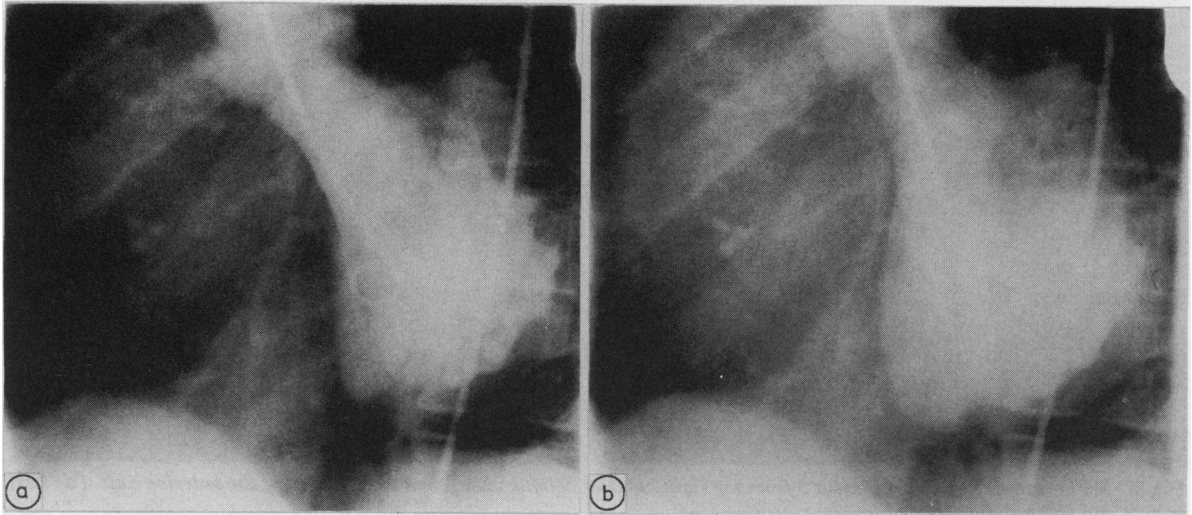


Fig 5 Left ventriculogram of patient 3 from the left anterior oblique view. There is dyskinesia in the posterior segments. (a) End systole and (b) end diastole.

also had pronounced abnormalities of right ventricular wall motion (fig 5), and the posterior region of the left ventricle was as trabeculated as the right. The left ventricular ejection fraction was normal ($> 60\%$) in all but one patient (43% in case 3). There was no important tricuspid or mitral valve regurgitation or other valve abnormality. The coronary arteriograms showed no significant stenosis.

REPRODUCIBILITY OF RIGHT VENTRICULAR FINDINGS

Table 3 shows the reproducibility of right ventricular findings within and between observers. Although there was a statistically significant positive correlation between dimension scores, contractility scores, and, in most segments, between regional wall motion scores within and between observers, reproducibility as measured by Kendall's Tau was generally only fair. The reproducibility of regional wall motion

Table 3 Values of Kendall's Tau,

	Interobserver correlation	p value	Intraobserver correlation	p value
Dimension	0.92	0.0002	0.62	0.0123
Contractility	0.65	0.0131	0.70	0.0089
R1	0.55	0.0403	0.82	0.0036
R2	0.38	NS	0.76	0.0050
R3	0.48	NS	0.63	0.0160
R4	0.85	0.0031	0.63	0.0304
R5	0.94	0.0007	0.54	0.0433
R6	0.43	NS	0.47	NS
R7	0.73	0.0044	0.71	0.0061
R8	0.59	0.0213	0.68	0.0095

R, right ventricular segment; NS, not significant.

scores within and between observers varied widely among the different segments (fig 6). It was poor for segments R2, R3, and R6 between observers 1 and 2, and also for segment R6 between the first and second interpretations of observer 2 (table 3).

The differences in score values within and between observers were considerable for some segments. For example segments R7 and R8 were both scored as 5 by observer 1 while observer 2 scored them as 2 and 1 respectively. The proportion of high and low scores differed significantly between observers 1 and 2, the former consistently gave higher scores ($p < 0.05$). This pattern of preference towards high or low scores was not seen between the interpretations from observer 2 (NS).

Discussion

Most cardiologists use selective right ventriculography to diagnose arrhythmogenic right ventricular dysplasia, especially in patients with atypical clinical signs or electrocardiographic findings.^{1,2} The right ventricular angiographic abnormalities in this disorder have been described as localised bulges or diverticular outpouchings, a feathery appearance of or non-opacified areas in the outflow tract, deep fissuring or cauliflower-like appearances of the anterior wall, and slow clearance of dye adjacent to poorly contracting areas.^{2,17,18} The segmental impairment of the right ventricle has also been described in terms of regional hypokinesia, akinesia, or dyskinesia.^{3,19,20} In a recent review of angiograms in eight patients with arrhythmogenic right ventricular dys-

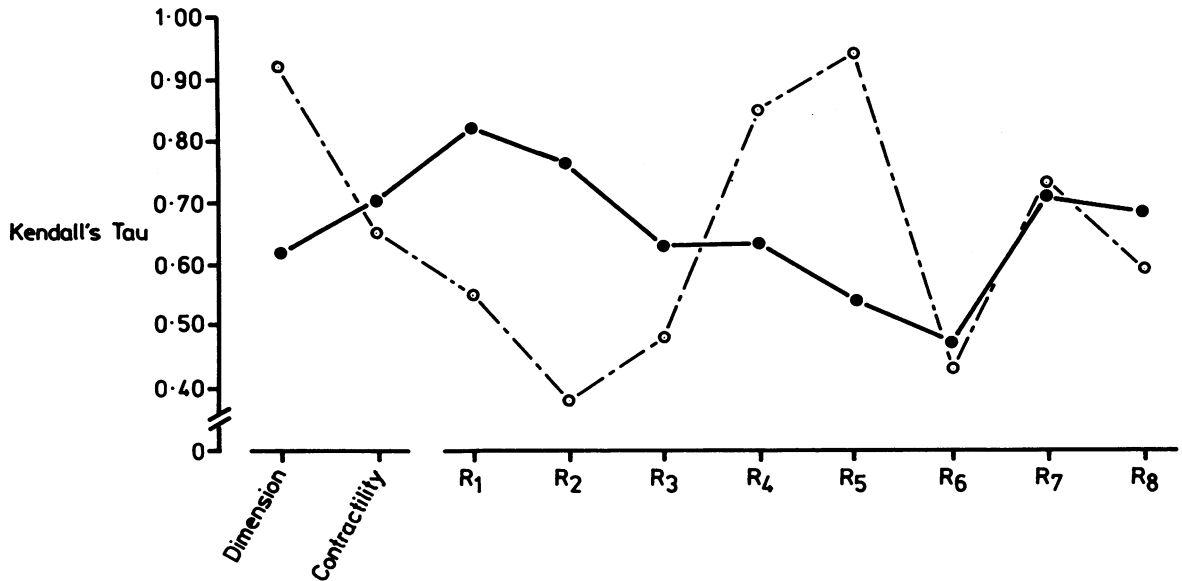


Fig 6 Degree of correlation, as measured by Kendall's Tau, for right ventricular dimension, contractility, and regional wall motion in eight segments (R1–R8), within (dotted lines) and between (continuous lines) observers.

plasia, the presence of four predetermined regional changes was assessed and diagnostic criteria were established.¹³ Fissuring distal to the moderator band, stagnation of contrast in the inferior regions, and irregular opacification of the infundibulum were found in most patients. None of these lesions was found in a comparable group of cases with dilated cardiomyopathy, and this emphasises the segmental nature of the morphological changes in arrhythmogenic right ventricular dysplasia.

The right ventricular findings in the present group of patients accorded with earlier descriptions of angiographic changes in arrhythmogenic right ventricular dysplasia. The effect of antiarrhythmic drugs on cardiac contractility is unpredictable in an individual patient and such agents may have accounted for the reduced global contractility in some of our patients. The functional impairment of the left ventricle was, however, minor and limited to a few patients, which argues against any important effect on the observed regional wall motion abnormalities of the right ventricle.

Unlike previous studies, the angiograms in the present report were systematically examined according to a standardised protocol in order to obtain unbiased interpretations. Moreover, right ventriculography was performed in both the right anterior oblique and left anterior oblique projections—in some studies only the right view was used¹³ and in others the views used were not clearly stated.^{2,3}

If only right anterior oblique projections are used, the geometry of the right ventricle may make it difficult to exclude right ventricular wall motion abnormalities with confidence. This was demonstrated in one of our patients in whom a localised lesion was recognised in the left anterior oblique view only. This shows that it is important to use both the right anterior oblique and left anterior oblique views for radiography of the right ventricle. Previous studies found that the most frequent areas of localised lesions were the infundibulum, the apex, and the inferior wall of the right ventricle.² In our study the inferior wall was most commonly affected, whereas there was an even distribution of regional changes among the other segments.

The types of regional wall motion abnormalities in the left ventricle were similar to and contiguous with those on the right side. Although there was a relatively large number of left ventricular abnormalities in the present series, most of them were mild. It is not known how commonly the left ventricle is affected in arrhythmogenic right ventricular dysplasia; however, it may be more than previously recognised.^{10,21} In the largest series published to date only one out of 22 patients showed angiographic evidence of left ventricular abnormalities.² Radionuclide angiography during exercise showed that in patients with arrhythmogenic right ventricular dysplasia the left ventricle was affected more often than previously recognised.¹⁰ The frequency with which

left ventricular abnormalities are detected may thus be a reflection of the method used. None the less, since there is evidence of a close interrelation between the functions of the right and left ventricles,²² it is conceivable that the left ventricular involvement seen in our patients was secondary to a compromised right ventricular function, particularly as the segments affected adjoined the right ventricle.

The sensitivity and the specificity of angiographic changes in identifying patients with arrhythmogenic right ventricular dysplasia are not known, and will presumably be difficult to assess. There are no published reports of evaluations of regional wall motion by right ventricular angiography in normal subjects. Owing to the high radiographic exposure, we did not consider it ethical to perform angiography in healthy individuals. The assessment of the reproducibility of right ventricular angiographic estimations within and between observers was thus all the more important, particularly because as far as we know this aspect has not been studied before. Since our data consisted of non-numerical observations (ranked classes, scores) any statistical computation based on numerical operations of the data beyond ranking was not possible.

The correlation between right ventricular scores was positive and statistically significant both within and between observers for most variables, but it varied considerably among segments. The right ventricular apical segment (R6) gave poor reproducibility both within and between observers for scores of regional wall motion. This segment was also regarded as the most difficult one to image and to evaluate. The larger proportion of high scores reported by observer 1 compared with observer 2 was discouraging but may be related to their different experiences. The most important finding, however, was that there were large differences in the scores for some of the variables, both within and between observers. There is thus a considerable subjective element in the visual assessment of right ventricular changes by angiography. This has important clinical implications for the diagnostic accuracy of qualitatively evaluated angiograms in arrhythmogenic right ventricular dysplasia, especially since right ventricular angiography is the standard method for assessing the diagnostic value of echocardiography and radionuclide angiography in this group of patients.^{7,8} The specificity of the angiographic features in arrhythmogenic right ventricular dysplasia is unknown. In addition, right ventricular angiographic abnormalities are not invariably present in these patients^{2,23,24} and the diagnosis may not be evident until a histological examination of myocardial tissue is obtained.^{2,25} The precise relation between the angiographic features and pathological

features remains to be defined. These circumstances may have led some to reject the diagnosis of arrhythmogenic right ventricular dysplasia in patients with right ventricular tachycardia and angiographically proven right ventricular regional wall motion abnormalities unless confirmed by histological data.^{26,27}

To sum up, the poor concordance and large differences within and between observers for some of the variables indicate the need for a more objective approach to the evaluation of angiographic changes in arrhythmogenic right ventricular dysplasia. Further work must be done to achieve quantitative standards for angiography. The irregular shape of the right ventricular chamber, however, makes calculations of volumes difficult and relies on geometric assumptions,²⁸ particularly in patients with arrhythmogenic right ventricular dysplasia, who have regional wall motion abnormalities.

This study was supported by grants from the Medical Society of Gothenburg and The Swedish National Association Against Heart and Chest Disease.

References

- 1 Fontaine G, Guiraudon G, Frank R, *et al.* Stimulation studies and epicardial mapping in ventricular tachycardia: study of mechanisms and selection for surgery. In: Kulbertus HE, ed. *Re-entrant arrhythmias. Mechanisms and treatment*. Lancaster: MIP Press, 1977:334-50.
- 2 Marcus FI, Fontaine GH, Guiraudon G, *et al.* Right ventricular dysplasia: a report of 24 adult cases. *Circulation* 1982;65:384-98.
- 3 Reiter MJ, Smith WM, Gallagher JJ. Clinical spectrum of ventricular tachycardia with left bundle branch morphology. *Am J Cardiol* 1983;51:113-21.
- 4 Fontaine G, Guiraudon G, Frank R, *et al.* Dysplasie ventriculaire droite arythmogene et maladie de Uhl. *Arch Mal Coeur* 1982;75:361-72.
- 5 Fontaine G, Frank R, Tonet JL, *et al.* Arrhythmogenic right ventricular dysplasia: a clinical model for the study of chronic ventricular tachycardia. *Jpn Circ J* 1984;48:515-38.
- 6 Hasumi M, Sekiguchi M, Hirol M, Kasanuki H, Hirosawa K. Endomyocardial biopsy approach to patients with ventricular tachycardia with special reference to arrhythmogenic right ventricular dysplasia. *Jpn Circ J* 1987;51:242-9.
- 7 Manyari DE, Duff HJ, Kostuk WJ, *et al.* Usefulness of noninvasive studies for diagnosis of right ventricular dysplasia. *Am J Cardiol* 1986;57:1147-53.
- 8 Robertson JH, Bardy GH, German LD, Gallagher JJ, Kisslo J. Comparison of two-dimensional echocardiographic and angiographic findings in arrhythmogenic right ventricular dysplasia. *Am J Cardiol* 1985;55:1506-8.

- 9 Baran A, Nanda NC, Falkoff M, Barold SS, Gallagher JJ. Two-dimensional echocardiographic detection of arrhythmogenic right ventricular dysplasia. *Am Heart J* 1982;103:1066-7.
- 10 Manyari DE, Klein GJ, Gulamhusein S, et al. Arrhythmogenic right ventricular dysplasia: a generalised cardiomyopathy? *Circulation* 1983;68:251-7.
- 11 Bourguignon MH, Sebag C, Le Guludec D, et al. Arrhythmogenic right ventricular dysplasia demonstrated by phase mapping of gated equilibrium radioventriculography. *Am Heart J* 1985;111:997-1000.
- 12 Dery R, Lipton MJ, Garret JS, Abbott J, Higgins CB, Scheinman MM. Cine-computed tomography of arrhythmogenic right ventricular dysplasia. *J Comput Assist Tomogr* 1986;10:120-3.
- 13 Drobinski G, Verdier C, Fontaine GH, Frank R, Fechner J, Grosogeat Y. Diagnostic angiocardiographie des dysplasies ventriculaires droites. *Arch Mal Coeur* 1985;78:544-51.
- 14 Blomström-Lundqvist C, Sabel KG, Olsson SB. A long term follow up of 15 patients with arrhythmogenic right ventricular dysplasia. *Br Heart J* 1987;58:477-88.
- 15 Kennedy JW, Trenholme SE, Kasser IS. Left ventricular volume and mass from single-plane cineangiogram. A comparison of anteroposterior and right anterior oblique methods. *Am Heart J* 1970;80:343-52.
- 16 Kendall MG. *Rank correlation methods*. London: Charles Griffin and Company, 1962:34-6.
- 17 Fontaine G, Guiraudon G, Frank R, Cabrol C, Grosogeat Y. The arrhythmogenic right ventricular dysplasia syndrome. In: Hayase S, Murao S, eds. *Cardiology*. Amsterdam: Excerpta Medica (International Congress Series 470), 1979:955-8.
- 18 Rossi P, Massumi A, Gillette P, Hall RJ. Arrhythmogenic right ventricular dysplasia: clinical features, diagnostic techniques, and current management. *Am Heart J* 1982;103:415-20.
- 19 Dungan WT, Garson A, Gillette PC. Arrhythmogenic right ventricular dysplasia: a cause of ventricular tachycardia in children with apparently normal hearts. *Am Heart J* 1981;102:745-50.
- 20 Rowland E, McKenna WJ, Sugrue D, Barclay R, Foale RA, Krikler DM. Ventricular tachycardia of left bundle branch block configuration in patients with isolated right ventricular dilatation. Clinical and electrophysiological features. *Br Heart J* 1984;51:15-24.
- 21 Webb JG, Kerr CR, Huckell VF, Mizgala HF, Ricci DR. Left ventricular abnormalities in arrhythmogenic right ventricular dysplasia. *Am J Cardiol* 1986;58:568-70.
- 22 Bove AA, Santamore WP. Ventricular interdependence. *Prog Cardiovasc Dis* 1981;23:365-88.
- 23 Slama R, Leclercq JF, Coumel Ph. Paroxysmal ventricular tachycardia in patients with apparently normal hearts. In: Zipes DP, Jalife J, eds. *Cardiac electrophysiology and arrhythmias*. Orlando: Grune and Stratton, 1985:545-52.
- 24 Strain JE, Grose RM, Factor SM, Fisher JD. Result of endomyocardial biopsy in patients with spontaneous ventricular tachycardia but without apparent structural heart disease. *Circulation* 1983;68:1171-81.
- 25 Deal BJ, Miller SM, Scagliotti D, Prechel D, Gallastegui JL, Hariman RJ. Ventricular tachycardia in a young population without heart disease. *Circulation* 1986;73:1111-8.
- 26 Pietras RJ, Lam W, Bauernfeind R, et al. Chronic recurrent right ventricular tachycardia in patients with ischemic heart disease: clinical, hemodynamic, and angiographic findings. *Am Heart J* 1983;105:357-66.
- 27 Foale RA, Nihoyannopoulos P, Ribeiro P, et al. Right ventricular abnormalities in ventricular tachycardia of right ventricular origin: relation to electrophysiological abnormalities. *Br Heart J* 1986;56:45-54.
- 28 Gentzler RD, Briselli MF, Gault JH. Angiographic estimation of right ventricular volume in man. *Circulation* 1974;50:324-30.