

## **Missed myocardial ischaemia in the accident & emergency department: E.C.G. a need for audit?**

W. A. McCALLION, P. A. TEMPLETON,  
L. A. McKINNEY & J. D. S. HIGGINSON

*Accident and Emergency Department, The Ulster Hospital, Dundonald, Belfast, BT16 0RH, Northern Ireland*

### SUMMARY

Accident & Emergency Department Senior House Officers rely heavily on their ECG interpretation skills in the diagnosis and management of patients with chest pain. This prospective double-blind study was designed to test the accuracy with which Accident & Emergency Senior House Officers interpret ECGs, by comparing their interpretation with that of a Consultant Cardiologist. ECGs from 279 of 314 consecutive patients with chest pain were analysed.

Ninety per cent of normal electrocardiographs and 57% of abnormal ECGs were correctly interpreted. Despite the inaccurate interpretation of 43% of abnormal ECGs, 96.5% of the patients in the study were considered to have been managed correctly. Audit of all ECGs recorded in the Accident & Emergency Department should be undertaken by someone with experience of ECG interpretation. New A&E staff should receive training in the interpretation of ECGs.

### INTRODUCTION

When first appointed, Senior House Officers in the Accident & Emergency Department frequently lack experience of patients complaining of chest pain.

The electrocardiograph is of fundamental importance in assessing these patients.

We have studied the accuracy with which Casualty Officers interpret electrocardiographs in patients presenting to the Accident & Emergency Department with anterior chest pain and make recommendations based on our findings.

---

*Correspondence: Mr L. A. McKinney FRCS, Accident & Emergency Department, The Ulster Hospital, Dundonald, Belfast, BT16 0RH, Northern Ireland*

## METHODS

In a prospective double blind study of 314 consecutive patients attending the Accident & Emergency Department of the Ulster Hospital with anterior chest pain the Casualty Officers (three GP trainees and five Surgical Senior House Officers) were asked to interpret the electrocardiographs as 'normal' or 'abnormal'. If 'abnormal', they were asked to state in detail the abnormality. All electrocardiographs were studied by two Accident & Emergency Senior House Officers (including W. McC), neither of whom knew the opinion of the other. Electrocardiographs were assessed as normal, borderline or abnormal. All borderline and abnormal electrocardiographs were submitted to a Consultant Cardiologist (DH) for his opinion concerning the nature of the abnormality. His opinion was then compared with that of the Accident & Emergency SHO who first saw the patient. ECGs considered 'normal' were reviewed by a Senior Registrar in A&E Medicine and, where any doubt about the ECGs remained, they were further examined by a Consultant Cardiologist.

## RESULTS

The total number of new patients attending the Accident & Emergency Department during the 2-month study period was 7738. The number of patients presenting with anterior chest pain was 314. Thus, 4% of new attenders to the Accident & Emergency Department present with chest pain. (Average age 53 (SD 15.4); 184 males (59%); 130 females (41%)). One hundred and three of the 314 patients were admitted. (Average age 62 (SD 13.6) years; 65 males (63%), 38 females (37%). The remaining 211 patients were discharged from Casualty. Eighty-seven patients were admitted to the cardiac unit, 25 of whom were subsequently shown to have sustained an acute myocardial infarction. Sixteen patients were admitted to other wards (Table 1).

Two hundred and seventy-nine electrocardiographs were validated. Electrocardiographic data were not available for 35 patients; 5 patients were transferred to the Coronary Care Units of other hospitals and were not followed up; 16 electrocardiographs were not commented on by the Casualty Officers; and 14 patients had no electrocardiograph recorded in Casualty.

**Table 1** Final diagnosis of those patients admitted to medical or surgical wards with chest pain.

Oesophagitis	2
Angina	2
Congestive cardiac failure	6
Chest infection	4
Pneumothorax	2

Of the 279 electrocardiographs validated, 139 were normal and 140 abnormal. Table 2 shows how accurately electrocardiographs were interpreted by the Casualty Officers. Fourteen (10%) of the normal electrocardiographs were misinterpreted as false positives — 11 were erroneously thought to show an 'old infarct', usually an old inferior infarct, and 3 were erroneously thought to show acute ischaemic changes. Sixty (43%) of the abnormal electrocardiographs were misinterpreted; 4 in a false positive manner and 57 as false negatives. One electrocardiograph had both a false positive and false negative misinterpretation. Of the 57 abnormal electrocardiographs misinterpreted as false negatives 50 patients were managed correctly in casualty. The remaining 7 patients were inappropriately discharged from the Accident & Emergency Department on the basis of electrocardiograph misinterpretation. Thus, 7/279 (2.5%) patients attending casualty with chest pain were inappropriately discharged. One patient (0.4%) was subsequently shown to have suffered a myocardial infarction, and a further patient was thought likely to have suffered infarction on the basis of electrocardiographic changes. The remaining five patients had acutely ischaemic or potentially acutely ischaemic electrocardiographs, and they should at least have been assessed by the Cardiology Registrar on call prior to discharge.

Figure 1 is the electrocardiograph of a 59-year-old male who presented to casualty with a 1 h history of increasing upper chest and shoulder pain. He had had a myocardial infarction 10 years previously. The electrocardiograph was interpreted as showing no abnormality, a diagnosis of musculo-skeletal pain made and the patient discharged. This trace shows Q waves in V2–V4 leads (in keeping with a previous anteroseptal infarction), and ST segment depression in lead II and V4–V6, suggesting acute lateral myocardial ischaemia.

Figure 2 is the electrocardiograph of a 68-year-old female who presented with a 2-week history of intermittent chest pain. On the day of presentation she became short of breath and vomited once. The electrocardiograph was interpreted as showing no abnormality, a diagnosis of anxiety was made and the patient was discharged. This electrocardiograph shows ST segment depression in leads V4–V6, suggesting acute lateral myocardial ischaemia.

Figure 3 is the electrocardiograph of a 69-year-old male who gave a history of severe chest pain two days previously and intermittent pain thereafter. When seen in casualty he was painfree. The electrocardiograph was interpreted as showing an

**Table 2** Validated electrocardiographs

Casualty SHO Interpretation	Normal ECGs (Total 139)	Abnormal ECGs (Total 140)
Correctly interpreted	125 (90%)	80 (57%)
Incorrectly interpreted	14 (10%)	60 (43%)
– false positive	14	4
– false negative	0	57

Difference in interpretation ability Normal vs Abnormal ECGs  $\chi^2 = 38.9$   
df = 1 P less than 0.001.

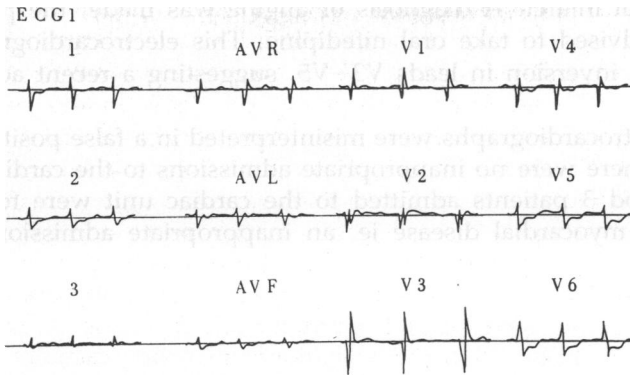


Fig. 1 Electrocardiogram of a 59-year-old male.

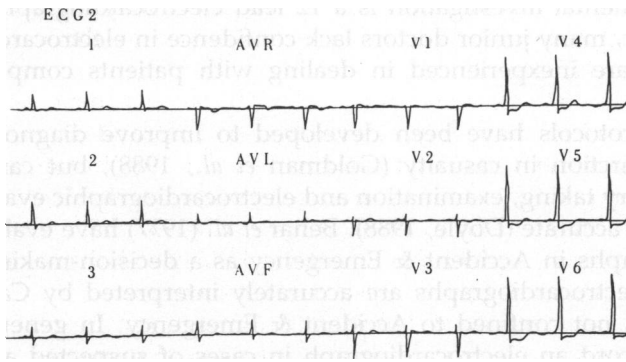


Fig. 2 Electrocardiogram of a 68-year-old female.

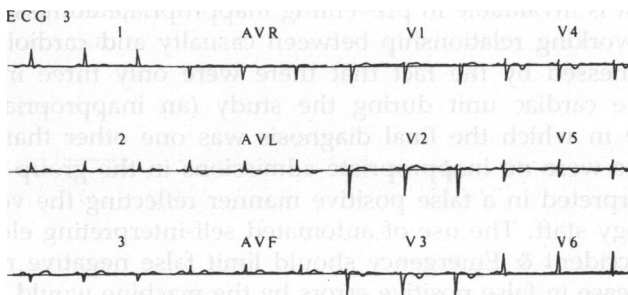


Fig. 3 Electrocardiogram of a 69-year-old male.

old infero-lateral infarct. A diagnosis of angina was made, the patient was discharged and advised to take oral nifedipine. This electrocardiograph shows abnormal T wave inversion in leads V3–V5, suggesting a recent acute myocardial infarction.

Eighteen electrocardiographs were misinterpreted in a false positive manner but in this group there were no inappropriate admissions to the cardiac unit. During the study period 3 patients admitted to the cardiac unit were found not to be suffering from myocardial disease ie. an inappropriate admission rate of 3/314 (less than 1%).

## DISCUSSION

Four per cent of all attenders at Accident & Emergency complain of anterior chest pain. A fundamental investigation is a 12 lead electrocardiograph (Hedges *et al.*, 1988). However, many junior doctors lack confidence in electrocardiographic interpretation and are inexperienced in dealing with patients complaining of chest pain.

Computer protocols have been developed to improve diagnostic accuracy of myocardial infarction in casualty (Goldman *et al.*, 1988), but careful clinical assessment (history taking, examination and electrocardiographic evaluation) appears to be at least as accurate (Doyle, 1988). Behar *et al.* (1977) have evaluated the use of electrocardiographs in Accident & Emergency as a decision-making tool but they assume that electrocardiographs are accurately interpreted by Casualty Officers. The problem is not confined to Accident & Emergency. In general practice only 28% of GPs record an electrocardiograph in cases of suspected acute myocardial infarction during surgery hours (Colquhoun, 1989) and it has been suggested that many GPs lack the skill required to interpret them (Davies, 1989).

How, then, does one improve the accuracy of electrocardiograph interpretation in Accident & Emergency? The availability of previous electrocardiographs for comparison significantly increases diagnostic accuracy (Lee *et al.*, 1986). The opinion of a cardiologist is invaluable in preventing inappropriate admission or discharge. The excellent working relationship between casualty and cardiology staff in this hospital is witnessed by the fact that there were only three inappropriate admissions to the cardiac unit during the study (an inappropriate admission is defined as one in which the final diagnosis was one other than a cardiological disorder). There were no inappropriate admissions in the group of electrocardiographs misinterpreted in a false positive manner reflecting the vetting procedure by the cardiology staff. The use of automated self-interpreting electrocardiograph machines in Accident & Emergency should limit false negative misinterpretation whilst any increase in false positive errors by the machine would be vetted by the cardiologist-on-call. In view of our findings, we suggest that:

(1) There should be regular electrocardiograph audit in the Accident & Emergency Department and recommend that the electrocardiographs of those patients discharged from Accident & Emergency be reviewed the same day by a member of the cardiology staff;

- (2) There should be regular teaching sessions for Casualty Officers in electrocardiograph interpretation and;
- (3) Undergraduate medical students should be encouraged to develop skills in electrocardiograph interpretation and this should be reinforced as pre-registration House Officers.

In this Hospital the first two measures have been implemented and there are plans for an introductory course for pre-registration House Officers to include electrocardiographs interpretation.

## ACKNOWLEDGEMENTS

We thank Mr J. Shaw, FRCS (Consultant in Accident & Emergency Medicine) for permission to report his patients and for his considerable help and encouragement.

## REFERENCES

- Behar S., Schor S., Kariv I., Barell V. & Modan B. (1977) Evaluation of electrocardiogram in emergency room as a decision-making tool. *Chest* **71**, 486–91.
- Colquhoun M. C. (1989) General Practitioners' use of electrocardiography: Relevance to early thrombolytic treatment. *British Medical Journal* **299**, 433.
- Davies A. (1989) Electrocardiographs in general practice. *British Medical Journal* **298**, 408–9.
- Doyle Y., Conroy R. & Mulcahy R. (1988) Can we improve on the diagnostic accuracy of chest pain in Accident & Emergency Departments? *Irish Medical Journal* **81**, 21–24.
- Goldman L., Cook E. F., Brand D. A., *et al.* (1988) A computer protocol to predict myocardial infarction in Emergency Department patients with chest pain. *New England Medical Journal* **318**, 797–803.
- Hedges J. R. & Kobernick M. S. (1988) Detection of myocardial ischaemia in the Emergency Department patient with chest discomfort. *Emergency Medicine Clinics of North America* **6**, 317–40.
- Lee T. H., Cook E. F., Weisberg M., *et al.* (1986) Impact of the baseline electrocardiograph on the accuracy of triage of emergency room patients with chest pain. *Clinical Research* **34**, 373.