

ON A CASE OF RUDIMENTARY FIRST THORACIC RIB
IN A HORSE. By O. CHARNOCK BRADLEY, M.B.,
Professor of Anatomy, Royal Veterinary College, Edinburgh.

NOT unnaturally the vertebral column has received much attention at the hands of morphologists, and no problem in connection therewith has been more productive of controversy than that arising out of its capacity for numerical variation. The discussion of the possible factors concerned in the advent of an additional vertebra, or the suppression of a normal one, has resulted in the formulation of several hypotheses. Not the least important of these—when judged by the degree of its acceptance at the hands of anatomists—is that enunciated by Rosenberg (1). This writer's views are so well known that all that need be here stated is that his theory resolves itself into the recognition of two factors which, acting upon the thoracic part of the spine, are gradually causing its absorption into the lumbar and cervical regions. According to this theory the thoracic part of the vertebral column is the most primitive, and the disappearance of ribs is an indication of progression, whereas the occurrence of a larger number than normal is to be viewed as a retrogressive variation. That there are difficulties in the way of unconditional acceptance of this hypothesis is admitted; but, in spite of this, the majority of morphologists are prepared to make use of it until such time as some other theory, attended by fewer difficulties and equally in line with the doctrine of descent by evolution, shall be submitted.

Wiedersheim (2), on phylogenetic grounds, also holds that the skeleton of the thorax is gradually being absorbed.

But Rosenberg's views are not unopposed. The idea that a variation from the normal in the number of vertebræ may be produced by intercalation or excalation is entertained by some. Jhering (3), Albrecht (4), and Baur (5) have expressed themselves as convinced that the number of segments, in any region, may be augmented by intercalation. Leboucq (6) is also of the same opinion, and has, comparatively recently, recorded two cases in

which he considers that an additional cervical vertebra was so produced. In both these cases there were eight cervical vertebræ. In each case the 2nd and 3rd segments were joined together. Leboucq expresses his conviction that, in both instances, the intercalated vertebra was the 3rd, and inclines to the view that the space between the 2nd and 3rd vertebræ is a critical point in the cervical region.

The latest contribution to this subject is from the pen of Professor Dwight (7) who, accepting the conception of a *vertebra fulcralis*—the vertebra most concerned in the support of the ilium—as a comparable point in any two spines, desires to disagree with Rosenberg's views in an unqualified form. Dwight wishes to substitute the theory of a vital principle which produces a change in development under changed circumstances. The fundamental differences between the views of Rosenberg and Dwight appear to be capable of summary as follows. The former authority holds that the vertebræ of any two spines are to be homologised number for number; for example, the 19th segment of one vertebral column must be compared with the 19th segment in any other vertebral column. Dwight, on the other hand, holds that it is only the *vertebra fulcralis* of one subject which is to be compared with the similar vertebra in another

Closely correlated with the subject of numerical vertebral variation is that of deviation from the normal, either in number or in degree of development, of the ribs; and the object of the present communication is, not to discuss the above-mentioned opposed theories, but to describe a case in which the ribs showed an abnormality in development. This abnormality was found in an aged mare used as a subject for dissection in the Practical Anatomy class in this College. Fortunately it was recognised that there was something unusual before the dissection of the thorax had proceeded so far as to prevent a careful examination of the abnormal structures. The following points were disclosed as the dissection proceeded.

The shaft of the 1st rib on both sides of the body was considerably reduced, being represented by a tapering piece of bone about 5 cm. in length (fig. 1, D). The head of each rib was much smaller than usual, but the tubercle was of

ordinary dimensions. A triangular flattened piece of bone,

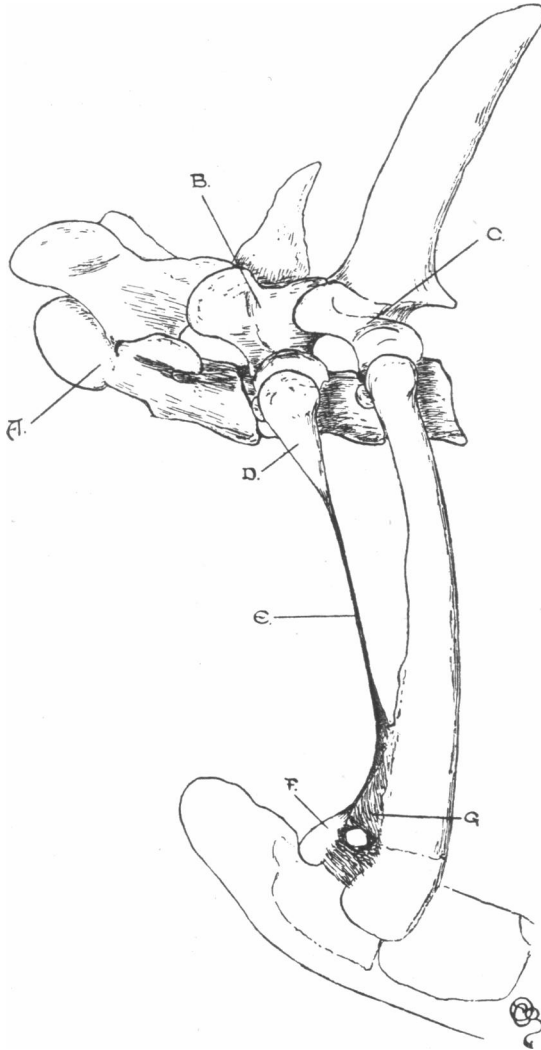


FIG. 1.—A=seventh cervical vertebra ; B=first thoracic vertebra ; C=second thoracic vertebra ; D=rudimentary first thoracic rib ; E=fibrous cord continuing rudimentary rib ; F=nodule of bone representing sternal end of rudimentary rib ; G=fibrous tissue filling in ventral part of first interspace.

attached by fibrous tissue to the sternum, doubtless represented

the sternal end of each rib (fig. 1, F). The intervening segment of the rib was replaced by a strong, rounded fibrous cord of about 4 mm. in thickness (fig. 1, E). This was firmly attached to a rough and slightly projecting surface close to the junction of the middle and ventral thirds of the cephalic border of the 2nd rib. Excepting that its ventral part was somewhat broader than usual, the second rib presented no noteworthy features.

As a consequence of the attachment of the fibrous continuation of the 1st to the border of the 2nd rib, the first intercostal space was divided into two unequal parts, the dorsal of which was

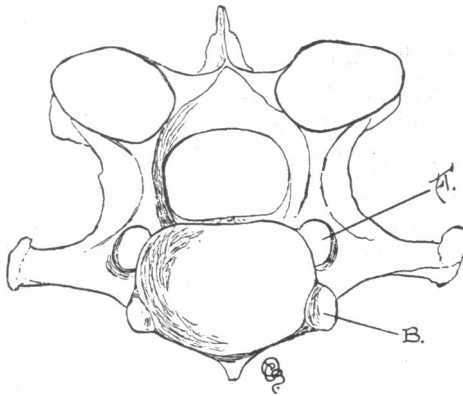


FIG. 2.—Seventh cervical vertebra.

A = vertebral arterial foramen.

B = concavity for articulation with the head of the first rib.

occupied by intercostal muscles in the ordinary way. The ventral, and smaller, portion of the interspace was filled in by a strong sheet of fibrous tissue in which was an opening for the passage of a large perforating branch of the internal mammary artery (fig. 1, G).

In correspondence to the reduced size of the head of the first rib, the concavity formed by the bodies of the 7th cervical and 1st thoracic vertebræ was much smaller than usual. The 7th cervical vertebra presented a remarkable feature inasmuch as there was a vertebral arterial foramen piercing the root of each of its transverse processes (fig. 2).

The scaleni muscles, failing to find a sufficiently ample area

for attachment on the rudimentary rib and its fibrous continuation, were largely inserted into the cephalic border of the 2nd rib. For a similar reason the pectoral prolongation of the rectus abdominis was attached to the 2nd rib instead of the 1st.

The vertebral artery passed through the vertebrarterial foramen of the 7th vertebra.

Otherwise than in the above particulars, the disposition of the structures in the neighbourhood of the entrance to the thorax followed the text-book descriptions with a remarkable degree of closeness.

Bearing in mind the circumstance that the development of cervical ribs is, from phylogenetic reasons, of more frequent occurrence than the imperfect development of the 1st thoracic rib, and remembering, moreover, that some observers are of opinion that many, if not most, of the variations usually placed in the latter category should by rights be regarded as belonging to the former, the question which first suggested itself was whether this case might not be one in which cervical ribs were present. There seems little doubt that this question may be answered in the negative. The vertebræ were present in the usual number, and, apart from the possession of vertebrarterial foramina by the 7th, their form did not present any peculiarities. There could be no doubt that the vertebra to which the rudimentary rib belonged was the 1st thoracic. Further, the brachial plexus was examined with care and was found to be constituted, in the usual way, by the 6th, 7th, 8th, 9th, and 10th spinal nerves; these nerves sharing in its formation in the customary proportions. Taking all the facts into account, there can be little doubt that it was the first pair of thoracic ribs which had failed to attain to their normal degree of development.

Although the occurrence of cases in which the 1st thoracic rib—if we accept Rosenberg's views—is undergoing a change of a progressive nature is generally held to be rare, a study of the literature leads one to conclude that, in all probability, the rarity has been over-estimated.

Helm (8) collected sixteen cases recorded between the years 1853 and 1885; but it is very probable that his list is not

complete. This supposition is originated by his omission of several cases of so-called bicipital ribs mentioned in a paper by Turner (9), who considers them to be the result of fusion of the 1st and 2nd thoracic ribs; cases which should, without doubt, be included in the list.

Since the appearance of Helm's paper several communications have been published in which rudimentary 1st ribs have been described. Hertslet and Keith (10) have put on record a case in which the condition was present on both sides of the body, and Low (11) one with a unilateral deficiency. Leboucq (5) has discussed at some length three occurrences of the abnormality, two of which are of rudimentary 1st ribs as generally recognised, while the third is of a rib divided into vertebral and sternal portions 25 mm. from the lateral border of the sternum, an articulation occurring between the two segments. A parallel to this last form of variation is found in a record by Heusinger (12).

The most recent addition to the literature is made by Dwight (7) in a paper on the human spines showing numerical variation in the Warren Museum of the Harvard Medical School. Forty-five complete spines are passed under review, among which are two cases of rudimentary 1st thoracic rib, both unilateral. In addition to these forty-five complete spines, some thirteen incomplete specimens are mentioned, from which two examples of rudimentary 1st rib are obtained, and one of fusion of the 1st and 2nd ribs.

Dwight's paper, valuable for many reasons, is useful in that it affords a means by which the relative frequency of cervical and rudimentary 1st thoracic ribs may be computed. No previous writer has given such full data. In the forty-five complete specimens cervical ribs occur seven times, whereas rudimentary thoracic ribs are only present twice. Among the thirteen disjointed fragments there are two instances of each of these deviations from the normal, and one example of fusion of the 1st and 2nd ribs. The much rarer character of a defect in the 1st rib is strikingly illustrated.

All the papers mentioned above deal with human spines. The literature is not nearly so rich in instances in the lower animals, possibly because the defect is less common in them

than in man, but very probably because so much attention has not been paid to variations in the skeleton of members of the animal kingdom other than *Homo*.

I have only been able to find records of two cases that were not human. Struthers (13), in a foot-note to his very valuable paper on vertebral and costal variations, states that, in the skeleton of a three-toed sloth (*Bradypus tridactylus*) the 1st thoracic rib "on the right side begins by head and tubercle attachments, but its shaft is only half an inch in length and terminates, in the macerated bone, by an irregular blunt end."

Hermann Adolphi (14) describes a case in a dog in which the 1st rib was defectively developed on both sides of the body. On the right side the head and tubercle were normal, but the body was slender and short, and did not reach the sternum. There was no evidence of a costal cartilage. On the left there was neither head nor neck, but the body was of more perfect development than on the right side, and a costal cartilage was present. Considerable interest attaches itself to this case because of an attempt at the formation of a rib on the right side of the 21st vertebra; the same side of the body, it will be noted, as that on which the 1st rib was the more rudimentary.

The case in the horse, which is the subject of the present paper, is worthy of record for several reasons. Not the least important of these is the fact that the vertebræ were normal in number, and, with the exception of the 7th cervical, also in form. The 7th vertebra had the ordinary general form, but was unusual in that the transverse processes were provided with foramina. This is a condition which, though varying much in different mammals, is very rarely found in the horse. An examination of all the equine 7th vertebræ in the osteological collection of this College fails to unearth any specimen in which there is even an attempt at the production of a foramen. Struthers (13) notes that there is a horse's skeleton in the Anatomical Museum of the University of Aberdeen in which "the foramen is present on the right side and is fully as large and as rounded as that of the 6th vertebra, and bounded below by as thick a bony wall, fully

ankylosed." In my case the foramen is present on both sides, and is large and well formed; but the transverse processes do not otherwise differ from the normal either in size, shape, or direction; whereas in Struthers' case the process beyond the foramen "is thickly bifurcated; the superior part prolonged backwards; the inferior projecting forwards, and also continued backwards on the body of the vertebra."

The degree of development, or rather of defect of development, does not appear to be greater than has been found in many of the cases already recorded. It appears, further, that it is not unusual for that part of the rib which has failed to ossify to be represented by a fibrous cord. And there is apparently a great tendency for this cord to establish a connection with the 2nd rib. Indeed it seems to be almost a law that a rudimentary 1st rib seeks to become blended with its more perfect next-door neighbour, this being most evident in those fusions which result in so-called bicipital ribs.

The presence of a nodule of bone attached to the sternum is also not uncommon, and is of great interest as showing that it is the middle part of the body of the rib that becomes defective, the dorsal and ventral ends remaining more or less perfect. A fact of some importance in this connection has been observed by Leboucq (6). He points out that the 1st rib has apparently a tendency to divide into two segments—a vertebral and a sternal—and that it is at the level of this division that the rib first inclines to become rudimentary. Moreover, in cases where cervical ribs are present, a sternal nodule is sometimes found. And, again, it is admitted that the manubrium normally contains the sternal ends of ribs.

The altered attachment of muscles in these cases gives an indication of how a muscle may be lengthened or shortened because of its having to seek a new and sufficiently firm foothold when its usual origin or insertion is no longer physiologically possible.

In conclusion, it may perhaps be permissible to emphasise the fact that, in the case I have described, the condition was symmetrical; a feature not usual, but of some phylogenetic importance.

LIST OF REFERENCES.

- (1) ROSENBERG, E., "Über die Entwicklung der Wirbelsäule und das Centrale carpi des Menschen," *Morpholog. Jahrbuch.*, Bd. i., 1875; "Über eine primitive Form der Wirbelsäule des Menschen," *Morpholog. Jahrbuch.*, Bd. xxvii., 1899.
- (2) WIEDERSHEIM, R., *Der Bau des Menschen Zeugniß für seine Vergangenheit*, 1893.
- (3) JHERING, *Das peripherische Nervensystem der Wirbelthiere*, 1878.
- (4) ALBRECHT, P., "Note sur une hémivertèbra gauche sur-nuéraire de Python Sebæ (Dum.)," *Bull. du Musée roy. d'Hist. Nat.*, Bruxelles, ii., 1833.
- (5) BAUR, G., "On intercalation of vertebræ," *Journal of Morphology*, iv., 1891.
- (6) LÉBOUCQ, H., "Recherches sur les variations anatomiques de la première Côté chez l'homme," *Archives de Biologie*, t. xv., 1898.
- (7) DWIGHT, T., "Description of the human spines showing numerical variation in the Warren Museum of the Harvard Medical School," *Anat. Anz.*, Bd. xix., 1901.
- (8) HELM, F., "Einseitige rudimentäre Entwicklung der ersten Rippe nebst einer Anzahl anderer Anomalien am Thorax einer und derselben Person," *Anat. Anz.*, Bd. x., 1895.
- (9) TURNER, W., "Cervical ribs and the so-called bicipital ribs in man," *Jour. Anat. and Phys.*, vol. xvii., 1883.
- (10) HERTSLET, L. E., and KEITH, A., "A comparison of the anomalous parts of two subjects, the one with a cervical rib, the other with a rudimentary first rib," *Jour. Anat. and Phys.*, vol. xxx., 1896.
- (11) LOW, A., "Description of a specimen in which there is a rudimentary first rib along with thirteen pairs of ribs and twenty-five pre-sacral vertebræ," *Jour. Anat. and Phys.*, vol. xxxiv., 1900.
- (12) HEUSINGER, "Merkwürdige Metamorphose des Brustbeins und der ersten Rippen," *Meckel's Archiv*, vi., 1820. (Quoted by Leboucq.)
- (13) STRUTHERS, J., "On variations of the vertebræ and ribs in man," *Jour. Anat. and Phys.*, vol. ix., 1875.
- (14) ADOLPHI, H., "Über die Wirbelsäule und den Brustkorb zweier Hunde," *Morpholog. Jahrbuch.*, Bd. xxvii., 1899.