ON THE MEDULLATED FIBRES OF SOME OF THE CRANIAL NERVES, AND THE DEVELOPMENT OF CERTAIN MUSCLES OF THE HEAD. By F. H. EDGEWORTH, M.B. (Cantab.), B.Sc. (Lond.), *Assistant Physician to the Bristol Royal Infirmary.* (PLATES X.–XXII.).

THIS paper may conveniently be divided into the following sections:—i. Introduction; ii. Individual Cranial Nerves; iii. Classification of Muscular Branches; iv. Development of Certain Cranial Muscles; v. Classification of Cranial Motor Nuclei; vi. Collateral Evidence from Disease; vii. Sensory Branches; viii. General Conclusions.

i. INTRODUCTION.

The observations which are here described were begun some years ago, at the suggestion of Dr Gaskell, with the intention of investigating the sensory branches only of the cranial nerves in the dog. The investigation was extended to mixed and motor branches, and to the origin and development of some of the cranial muscles.

The paper may be considered, in so far as it contains new views, as a series of proposed amendments to Dr Gaskell's paper on the cranial nerves.[1]

The nerves are described more or less in order from before backwards, and subsequently the various motor and sensory fibres are separately discussed. One or two preliminary remarks are, however, needful. The medullated fibres in any nerve, or branch of a nerve, are said to vary in size up to a certain maximum diameter. By this is meant that fibres of all sizes occur from about 1·5 μ in diameter up to the number given. It was not found possible to separate nerve fibres of similar sizes into groups, by reason of differing thickness of medullary sheath or size of axis-cylinder. Though a little variation exists, yet in general the thickness of the sheath, and

---

[1] *Jour. of Phys.*, vol. ix.

so the size of the axis-cylinder, was found to be very closely proportional to the diameter of the fibre. Hence, though Gaskell[1] has shown that conclusions as to the morphological position of the structures innervated can be drawn from the maximum diameter of the nerve fibres, and has correspondingly stated these only, yet in the following description the fibres are said to vary up to a certain diameter in each case.

Small differences in the maximum size of the fibres in any one nerve, cut close to its superficial origin from the brain, were found in specimens taken from different dogs. For instance, the maximum diameter of the fibres in the III nerve was found to vary between 16 and 17·6 μ,[2] and in one or two instances was as low as 14·4 μ.

If sections of any one nerve were made at various distances from its origin, it was found that the maximum size of the fibres was somewhat less the more distal the section. For instance, the maximum diameter of the fibres in the ophthalmic branch of the V just beyond its exit from the Gasserian ganglion was found in one case to be 17·6 μ, whilst in the various branches no fibres of diameter greater than 16·8 μ were seen. Diminution in size from these causes takes place in different degrees in different animals; for instance, the maximum diameter of the fibres in the nerve to the crico-thyroid muscle, cut about ¼ inch outside its entry into the muscle, was found in some cases to be as high as 12·8, in others as low as 9·6 μ.

In the following descriptions the average maximum diameter found in any nerve, or branch of a nerve, is recorded; subsequently, in discussing the various motor and sensory fibres, consideration is given to the question whether the extremes of variation invalidate the generalisations.

The nerves were stained in osmic acid, imbedded in paraffin, and examined in cross section, and measurements were taken only in cases where no puckering or shrinking of the nerve fibres existed.

---

[1] *Loc. cit.*

[2] The maximum size of the fibres found in the III and certain other nerves is stated by Gaskell to be 18 μ. Possibly owing to the class of dogs dissected—mongrel English terriers—I have not come across quite so high a figure; the difference, however, is unessential.

ii. THE CRANIAL NERVES.

The III, IV, and VI nerves consist each of medullated fibres, varying in diameter up to 16 μ. Although the majority of the fine fibres (*i.e.*, fibres under 4 μ in diameter) in the III pass to the ciliary ganglion, yet not all do so; thus each external ocular muscle receives small as well as larger medullated fibres.

The branch of the VI to the retractor bulbi contains fibres up to the same maximum diameter as occur in the continued trunk of the VI to the external rectus.

Each of the oculo-motor nerves receives one or more fine filaments from the carotid plexus, consisting mainly of grey fibres, together with one or two medullated fibres up to 6·4 μ in diameter. Each also receives a fine branch from the ophthalmic division of the V, consisting of grey fibres and a few fine medullated fibres up to 5·6 μ in diameter. As all the grey fibres in the ophthalmic division of the V come from the carotid plexus, and none from the Gasserian ganglion, the grey fibres in these fine branches to the oculo-motor nerves must eventually have the same origin.

V.—If serial sections be made through the roots of the trigeminal nerve, it can be seen that the first two divisions and the sensory branches of the third division (with exception of the mylo-hyoid) do not receive any fibres from the motor root.

These sensory branches can be divided into two classes by the maximum size of their medullated fibres.

Grey fibres and medullated fibres up to 16 μ in diameter are found in the long ciliary, ethmoidal, and infratrochlear branches of the ophthalmic division; in the lacrymal, subcutaneus malæ, infraorbital (both dental and skin branches), palatinus major, and nasalis posterior, from the superior maxillary division; and in the auriculo-temporal, buccal, terminal branches (*i.e.*, to skin) of the mylo-hyoid, mental and dental branches of inferior dental, from the inferior maxillary division.

Grey fibres and medullated fibres up to 11·2 μ in diameter occur in the palatinus minor from the superior maxillary division; in the lingual, orbital gland branches of the buccal and parotid gland branches of the auriculo-temporal, from the inferior maxillary division.

The Gasserian ganglion does not give rise to any grey fibres, which come, together with a few smallish fibres, from the carotid plexus. The nasalis posterior, palatinus major and minor also receive grey fibres from or through the spheno-palatine ganglion; and the sensory branches of the inferior maxillary division, some grey ones from or through the otic ganglion.

The branches of the V which pass to muscles can also be divided into two sets by the maximum sizes of their medullated fibres. Grey fibres and medullated fibres up to a maximum diameter of 16 μ occur in the branches passing to the temporal, masseter, pterygoids, and anterior portion of the digastric muscles.[1]

Grey fibres and medullated fibres up to a maximum diameter of 11·2 μ occur in the nerves to the tensor tympani, tensor veli palatini, and mylo-hyoid muscles.

The grey fibres in the motor branches come from the carotid plexus.

VII *nerve.*—The roots of the facial nerve are described by Gaskell[2] as consisting of a 'large-fibred' portion and a 'small-fibred' portion (n. intermedius). The large-fibred portion consists of "a few fibres of the smallest size, but is mostly composed of the motor fibres of the facial muscles, which are very uniform in size, and measure about 10·8 μ. In addition to these, there are a very large quantity of fibres which measure between 7 and 8 μ." The n. intermedius "is essentially a small-fibred formation, with a few much larger fibres."

In the dogs examined, the fibres of the facial nerve were found to be of all diameters up to 11·2 μ; there were also to be seen a few fibres of larger size up to 16 μ in diameter. Some of these larger fibres were aggregated together at that part of the facial root most remote from the n. intermedius, but a few were also seen throughout it. The larger fibres of the n. intermedius or sensory root of the facial were found to be of all diameters up to 11·2 μ. With one exception, all the branches

---

[1] The anterior and posterior digastric form a muscle with one belly in the dog. *Vide* Ellenberger and Baum, *Anatomie des Hundes.*

[2] *Loc. cit.*

of the facial distal to its exit from the stylo-mastoid foramen, and also the branch to the stapedius muscle, were found to consist of grey fibres and medullated fibres up to 11·2 μ in diameter. The exception is that branch[1] of the facial which divides into two to supply the posterior digastric and stylo-hyoid muscles. This branch, and each of its two divisions, were found to consist of grey fibres and medullated fibres, of all diameters up to 16 μ. The largest fibres it contains can, as described by Gaskell, be distinguished in the facial root, traced down laterally to the geniculate ganglion, and seen to separate gradually out from the facial trunk to help to form the branch in question.

The chorda tympani consists of medullated fibres of various diameters up to 11·2 μ; of these the small fibres are far more numerous.[2]

The great superficial petrosal consists of grey fibres and medullated fibres up to 11·2 μ in diameter; it is a very small nerve, and contains but few fibres.

No fibres can be traced, by microscopical examination only, directly from the n. intermedius into the great superficial petrosal, or from the great superficial into the nerve which, issuing from the geniculate ganglion, runs down alongside the facial, and which consists of grey fibres and medullated ones, of all diameters up to 11·2. From examination of serial sections across the facial trunk in the bone, it appears that of the nerve fibres issuing from the geniculate ganglion, some of the medullated ones separate off to form the chorda tympani, though a large number of the grey ones join the motor part of the facial, and become mingled with them. (This is confirmed by the experiment mentioned later.) Vulpian[3] stated that if the root of the facial, including the n. intermedius, be cut through in the dog, the chorda, with exception of a very few fibres, five to ten at most, remains intact, whereas the facial fibres degenerate. It is not stated, however, whether any undegenerated fibres were finally left in the facial trunk. The further experiments of Vulpian are to the effect that intra-cranial section of the V

---

[1] This is the branch described by Gaskell as leaving the facial trunk just before its exit from the bone, the distribution of which, however, he did not trace.

[2] *Vide* Langley, *Jour. of Phys.*, vol. xi.

[3] *Gaz. méd. de Paris*, 1878.

in rabbits, the VII being uninjured, caused almost total degeneration of the chorda.

These experiments do not harmonise with the fact stated above, that the number of medullated fibres in the chorda is much greater than in the great superficial petrosal, and are in disaccord with the embryological researches of Dixon,[1] who has shown that the great superficial petrosal grows out from the geniculate ganglion.

All the branches of the facial, with exception of the chorda, contain grey fibres, whilst the root of the nerve does not. It follows that they come into the nerve *viâ* the great superficial petrosal. As the facial is traced outwards in the bone, the grey fibres are seen to increase markedly in numbers, probably by division.

IX, X, *and* XI *nerves.*—The roots of the IX, X, and medullary part of the XI consist of medullated fibres of various sizes up to 11·2 μ in diameter. One of the upper rootlets of the X contains larger fibres up to 16 μ in diameter. These larger fibres, together with a few grey ones, pass off just below the jugular ganglion as the auricular branch of the vagus, and below that point no medullated fibres of diameter greater than 11·2 μ are found in the IX, X, and medullary XI nerves.

It is stated by Gaskell[2] that the small fibres of the spinal part of the XI join the vagus below the jugular ganglion.

The roots of the spinal portion of the XI contain medullated fibres of all sizes up to 16 μ in diameter. The external branch of the XI, which is derived solely from the spinal portion of the XI, consists of grey fibres and medullated fibres, of all diameters up to 16 μ. The grey fibres can be traced into the external branch from the superior cervical ganglion. Examination of serial sections taken through the X and XI shows that all the fibres of the spinal portion of the XI pass off into its external branch, and that none join the X, whereas all the fibres of the medullary portion of the XI join the X below the jugular ganglion. Spencer[3] also states that in the monkey and man the spinal roots of the XI form the external branch only, and the medullary roots join the X.

---

[1] *Trans. Roy. Dub. Soc.*, series ii. vol. iv.

[2] *Loc. cit.*

[3] *Lancet*, 1895.

The spinal accessory proper (spinal roots of XI) is then distinct, both in origin and distribution, from the vago-accessory (medullary roots of XI).

The recurrent laryngeal consists of very few grey fibres and medullary fibres, up to 11·2 μ in diameter. A septum of perineurium separates the fibres into two groups—the abductors and adductors of the vocal cords.[1] No histological distinction can be drawn between the fibres on either side the septum; there are no visible differences in the diameters of the axis-cylinders, or in the thicknesses of the medullary sheaths, to which the differences in vulnerability[2] between the abductor and adductor fibres might have been attributed. It would appear, then, that the differences in vulnerability between the abductor and the adductor ganglion cells in the medulla[3] extend to, and are shared by, their axis-cylinder processes.

The communicating branch between the superior and inferior laryngeal, which Howell and Huber[4] have shown to be a branch of the former nerve, and sensory in function, consists of a few grey fibres and medullated ones, up to 11·2 μ in diameter.[5] The terminal portion of the superior laryngeal, after it has given off its communicating branch, has the same structure as its branch. The terminal portion of the lingual branch of the IX, and also its branch to the keratoglossus, and the pharyngeal branches of the IX and X, consist of grey fibres and medullated fibres up to 11·2 μ.

The cardiac branches of the vago-sympathetic,[6] the cardiac branches of the recurrent laryngeal, the pulmonary nerves, and the vagus beyond the pulmonary have the same structure. The number of grey fibres in these nerves varies: the vagus beyond the pulmonary consists very largely of them, the cardiac nerves contain relatively fewer, and the pulmonary a still smaller number. The number of larger medullated fibres is very great in the pulmonary, small in the cardiac nerves, and least in the

---

[1] Risien Russell, *Proc. Roy. Soc.*, 1892.

[2] Semon and Horsley, *Phil. Trans. Roy. Soc.*, 1890.

[3] Semon, *Brain*, 1892.

[4] *Jour. of Phys.*, vol. xii.

[5] The contrast between the communicans and the recurrent laryngeal, which lie alongside each other below the larynx, in respect to the large number of small medullated fibres in the former and their fewness in the latter, is very striking.

[6] For anatomy, *vide* Lim Boon Keng, *Jour. of Phys.*, vol. xiv.

vagus beyond the pulmonary. To ascertain approximately what proportion of the medullated fibres in the pulmonary and cardiac nerves come from the vagus and sympathetic (the latter *vià* the annulus of Vieussens), an inch of the vagus was cut out in the neck of a dog, and the nerves examined five weeks subsequently. It was found that the pulmonary and cardiac nerves had lost the greater portion of their medullated fibres, but that some were intact in each branch examined.

One or two conclusions result from a comparison of the structure of the various branches of the IX, X, and medullary XI.

Motor fibres of all sizes up to 11·2 μ are found in the recurrent laryngeal, crico-thyroid branch of superior laryngeal, in the superior and inferior pharyngeal, in the pharyngeal branch of the IX, and in the stylo-pharyngeus branch of the IX.

It is not possible, by microscopical examination simply, to determine their exact origin in the roots of the IX, X, and medullary XI, but it has been shown by Horsley and Beevor,[1] and by Rethi,[2] that the stylo-pharyngeus is innervated by the IX, and by Rethi that the palato-glossus, palato-pharyngeus, constrictores pharyngei, levator veli palatini, and azygos uvulæ are innervated by the X, whilst the laryngeal muscles are supplied from the medullary XI. And it is stated by Spencer[3] that the crico-thyroid is innervated by the IX.

Sensory medullated fibres, up to 11·2 μ in diameter, are found in the lingual branch of the IX, in the superior laryngeal and its communicating branch, and in branches where (from the character of the muscles supplied) it is probable that similar fibres are also sensory in function, *i.e.*, in the cardiac and pulmonary branches, and in the vagus below the origin of the pulmonary nerves. Probably, also, some of the medullated fibres in the pharyngeal IX, in the superior and inferior pharyngeal nerves, are also sensory.

As to the origin of these sensory fibres, it has been shown by Gaskell that the medullary XI passes by the g. jugulare of the X, so that it appears probable that they come from the IX and

---

[1] Horsley and Beevor, *Proc. Roy. Soc.*, 1888.

[2] *Sitzungsber. der Kais. Akad. d. Wissenschaft*, Wien, 1892 and 1893.

[3] *Lancet*, 1895, and literature referred to by him.

X roots, with posterior root ganglia in the jugular ganglia of these nerves.

It is to be remarked that no histological distinction can be drawn betwen the medullated fibres in the superior laryngeal—which, as regards respiration, conduct only expiratory stimuli—and those in the pulmonary nerves—which conduct both expiratory and inspiratory stimuli, nor between these fibres and those found in the lingual branch of the IX, and in the cardiac nerves.

It follows that there are no fibres of specialised diameter or sheath-thickness concerned in carrying expiratory or inspiratory stimuli, or in conveying afferent cardiac impulses, or those impulses which pass up the lingual branch of the IX. The specialisation of these fibres, from a functional point of view, is not dependent on, or has not led to, histological differentiation, but must be due either to their peripheral or central terminations, or to both of these factors.

One other point may be noticed. From the results of clinical examination, it is held[1] that taste impulses passing up the lingual branch of the IX do not reach the central nervous system by the root of the IX, but turn aside through the n. tympanicus to reach the V.

The n. tympanicus, which Dixon[2] has shown to grow up from the IX, consists of grey fibres and medullated ones up to 11·2 μ in diameter, but the number of medullated fibres is very few. The IX also gives off the branches described by Langley[3] to the tympanic plexus.

In the case, then, both of the chorda and lingual IX, the number of medullated fibres which might possibly have come from the V forms a very small proportion of those which they contain.

XII.—The roots of the XII were described by Gaskell[4] as consisting of fine fibres, and of fibres of from 7·2 to 10·8 μ. In the dogs examined, it was found that whereas the upper rootlets of the hypoglossal contain medullated fibres of all sizes up to 11·2 μ, in the lower rootlets the maximum diameter was as great as 16 μ.

---

[1] *Vide* Gowers' *Dis. of Nerv. System*, vol. ii.

[2] *Loc. cit.*

[3] *Proc. Phys. Soc.*, 1893.

[4] *Loc. cit.*

The rootlets converge to form the trunk of the nerve, throughout which the largest fibres are uniformly scattered. The nerve also receives the ganglionated root of Froriep and Gaskell, which consists of medullated fibres up to 11·2 μ in diameter. It receives extra-cranially one or two fine branches from the vagus and pharyngeal plexus, consisting of medullated fibres up to 11·2 μ in diameter, and a largish branch from the sympathetic, consisting mostly of grey fibres, with a few small medullated ones. It does not receive any branch from the 1st cervical.

The branches of distribution may be divided into two sets by the maximum diameter of the medullated fibres. In the descendens hypoglossi (and each of its branches to the thyro-hyoid, and anterior portions of the sterno-hyoid and sterno-thyroid), and in the genio-hyoid, the maximum diameter is 16 μ, whilst in all the other branches the maximum diameter is 11·2 m. All the branches contain grey fibres, which have come from the sympathetic.

In the dog, then, the XII innervates the tongue muscles, the genio-hyoid, thyro-hyoid, and anterior portions of the sterno-hyoid and sterno-thyroid; whilst the communicans hypoglossi, which sends a small branch to the descendens and innervates the lower part of the sterno-hyoid and sterno-thyroid (the omo-hyoid being absent in the dog), comes from the first cervical nerve.[1]

On comparing this with the experimental investigations of Horsley and Beevor[2] and of Risien Russell[3] in the monkey, a difference is seen to exist. In both animals the genio-hyoid is innervated by the hypo-glossal roots; but whereas in the monkey the descendens hypoglossi comes from the first and the communicans from the second cervical root, in the dog the descendens is a part of the hypo-glossal, and the communicans comes from the first cervical.

The hyoid depressors are, then, post-fixed[4] in the monkey as compared with the dog.

The anatomy of the nerves in man suggests that the condition is like that in the monkey.

---

[1] *Vide* Ellenberger and Baum, *Anatomie des Hundes.*

[2] *Proc. Roy. Soc.*, 1888, and *Brit. Med. Jour.*, 1888.

[3] *Brain*, 1887.

[4] Using Sherrington's nomenclature.

Medullated fibres of sympathetic origin.—Before any attempt is made to classify the medullated fibres in the various branches of the cranial nerves, the medullated fibres which have entered these branches from the sympathetic must first be considered. They are, as stated above in describing individual nerves, exceedingly few in number, and are mostly under 4 μ in diameter, and the largest seen had a diameter of only 6·4 μ. The general statements made below will therefore not be affected by the existence of these scanty medullated fibres of sympathetic origin.

iii. CLASSIFICATION OF MUSCULAR BRANCHES.

If the diameters of the fibres in the branches of the cranial nerves passing to muscles be compared with one another, it is seen that the nerve fibres may be separated into two divisions by their maximum sizes.

(*a*) Nerve fibres of all sizes up to 16 μ in diameter are found in the III (external ocular muscles), IV (superior oblique), VI (external rectus and retractor oculi), V (temporal, pterygoids, masseter, and anterior digastric), VII (posterior digastric and stylo-hyoid), XII (genio-hyoid, thyro-hyoid, and anterior portions of sterno-hyoid and sterno-thyroid), and XI spinal (sterno-mastoid and trapezius).

(*β*) Nerve fibres of all sizes up to 11·2 μ in diameter are found in the V (mylo-hyoid, tensor tympani, and tensor veli palatini), VII (facial muscles), IX (stylo-pharyngeus), X (palato-glossus, palato-pharyngeus, constrictores pharyngei, azygos uvulæ, and levator veli palatini), XI (medullary laryngeal muscles), and XII (genio-glossus, hyo-glossus, and intrinsic tongue muscles).

As regards variation of maximum diameter in different animals, it was found that the maximum diameter of the fibres placed in the first division might be as high as 17·6 μ or as low as 14·4 μ, whereas that of the fibres in the second division varied between 12·8 μ and 9·6 μ. The maximum diameters of the two classes, then, do not overlap, but are separate and distinct.

Before the import of the existence of these two classes of cranial nerves can be discussed, consideration must be given to the question whether all the fibres in these branches are motor (or at any rate direct) fibres, or whether some of the fibres in at least some of the branches may not be root ganglion fibres.

The first group of fibres in which the maximum diameter is as great as 16 μ may be taken first. It is obvious that the III (external ocular muscles), IV, VI, and XI (spinal) have no posterior root ganglia. All the medullated fibres in them come directly from the central nervous system. This suggested that the other muscles of this group were also devoid of root ganglion fibres. An attempt was made to decide the question by inspection of serial sections through the roots of the nerves. In the case of the VII and XII it was not found possible to come to any decision, the fibres become so inextricably mingled. In the V, however, it was quite easy to see that the branches to the temporal, masseter, and pterygoid muscles come exclusively from the motor root, and receive no fibres from the sensory root of the V.[1] The branch to the anterior digastric separates from the mylo-hyoid nerve so low down that it might or might not (as far as microscopical examination went) have fibres in it coming from the sensory root.

Further, Dr Aldren Turner was good enough to divide the VII nerve intra-cranially (*i.e.*, above the geniculate ganglion) in a rhesus monkey. The branches were examined after an interval of three weeks. Inspection of the nerve fibres of the facial nerve on the uncut side showed that the maximum diameter of those passing to the posterior digastric and stylo-hyoid muscles was 14·4 μ, whilst that of the nerve fibres in the other muscular branches of the facial was 12·8 μ. This is a difference similar to that which occurs in the dog. On the cut side it was found that in the branch of the facial to the posterior digastric and stylo-hyoid muscles, all the medullated fibres had disappeared with exception of three only, all of which were under 4 μ in diameter. On the other hand, in the continued trunk of the facial, after it had given off this branch, although a very large number of the medullated fibres had gone, many (? a third of the original number) persisted: these were of all diameters up to 11·2 μ as a maximum. Insomuch as it is probable that the

---

[1] It was subsequently ascertained, from Dixon's paper (*loc. cit.*), that this fact had previously been stated by His.

three small fibres in the posterior digastric and stylo-hyoid branch come into the facial from without, possibly from the sympathetic, *viâ* the great superficial petrosal, it is concluded that whereas these muscles have no posterior root ganglion fibres passing to them, the other muscles innervated by the facial nerve receive not only motor fibres, but also many muscle-sensory fibres, having their posterior root ganglion cells in the geniculate ganglion.

In regard to the XII nerve, it is stated by Sherrington[1] that in an amyelous human fœtus, in which "there existed not a single motor (ventral) spinal nerve root in any segment," "the hypo-glossal trunk reaches the tongue, and gives off a large leash of lingual twigs, as well as its usual branches to stylo-glossus, hyo-glossus, genio-hyoideus, genio-hyo-glossus, and thyro-hyoideus. It gives off n. descendens noni as usual. Tracing the normal-looking nerve trunk backward, however, it seems to be almost exclusively formed by a branch from the 2nd cervical ganglion and another from the vagus below the vagus ganglion. I say almost, because a filament of it seems to be traceable to the base of the skull posterior to the vagus exit, and I then lose it." From this it appears probable that in the dog the muscles innervated by the XII and placed in the first division receive muscle-sensory as well as motor nerve-fibres.

Of the first group of muscles, then, it may be said that they receive no muscle-sensory nerves. To this statement the anterior digastric (V) is a doubtful, and the genio-hyoid, thyro-hyoid, and anterior portion of the sterno-hyoid and sterno-thyroid (XII) a positive, exception. On the other hand, the evidence as yet available points to the view that the muscles of the second group receive muscle-sensory fibres of all sizes up to a maximum diameter little short of that of their motor fibres. The above-described experiment gives positive evidence in the case of the facial nerve; and Sherrington states that in the above-mentioned fœtus the branches of the vagus, including the recurrent laryngeal, the glosso-pharyngeal, and the V, were easily found, and, as above mentioned, that the lingual twigs of the XII were present.

The cranial motor nerve-fibres were divided by Gaskell[2] into

---

[1] *Jour. of Phys.*, vol. xii.

[2] *Loc. cit*

two groups,—'somatic,' supplying the muscles developed in the dorsal portions, and 'non-ganglionated splanchnic,' supplying the muscles developed in the ventral portions of the head somites. The III, IV, VI, and XII were included in the first, the V, VII, IX, X, XI (spinal and medullary) in the second division. This suggests that the muscles placed in the first division made above are somatic, and those in the second splanchnic in origin. This hypothesis is obviously a repetition of Gaskell's classification in regard to the III, IV, VI, V (mylo-hyoid, tensor tympani, and tensor veli palatini), VII (facial muscles), IX, X, XI (medullary), XII (genio-hyoid, thyro-hyoid, and anterior portions of sterno-hyoid and sterno-thyroid). It differs from Gaskell's classification in that the temporal, masseter, pterygoids (V), posterior digastric and stylo-hyoid (VII), sterno-mastoid and trapezius (XI spinal) are held to be somatic, and that the tongue muscles (XII) are considered to be splanchnic structures. Evidence for these views was sought by tracing the development of the muscles in question.

iv. DEVELOPMENT OF CERTAIN CRANIAL MUSCLES.

The rabbit was first taken, and an endeavour made to trace the first formation of the muscles of the head, but it was found that they develop so relatively late from what appears to be indifferent mesoblast that the question could not be decided. The tadpole of the toad was subsequently investigated, with the results which are here described.

Before giving a detailed account of the phenomena observed, it is to be remarked that Van Wijhe[1] states that in Elasmobranchs no muscles are developed from the myotomes of the 4th and 5th cranial segments (*i.e.*, that the V and VII nerves supply no somatic muscles), whilst the myotome of the 6th cranial segment remains very rudimentary. He also states that the myotomes of the 7th, 8th, and 9th cranial segments give rise to "vom Schädel zum Schultergürtel ziehende Muskeln nebst dem vordersten Theile des Sternohyoideus."

---

[1] "Über die Mesodermsegmente und die Entwickelung der Nerven des Selachier kopfes."

The tadpoles were fixed in a solution of mercuric perchloride, stained in borax-carmine, imbedded in paraffin, and cut into serial sections in various planes.

In the earliest stage depicted, 2¼ mm. in length, transverse and longitudinal sections (*vide* figs. 1 and 13) show that there are three gill-slits, the hyo-mandibular and 1st and 2nd branchial, and that the mesoderm of the head forms a continuous sheet on either side the gut, with no trace of a body-cavity.

By the time the embryo has attained a length of 2½ mm. a split has appeared in the ventral part of the mesoderm of the 6th and succeeding segments, the cavity of which is continuous with the pleuro-peritoneal cavity behind, of which it forms the anterior portion.

No trace of a body-cavity is found at any stage of development in the dorsal portions of any of the segments of the head, or in the ventral portions of the 4th and 5th head segments.

Successive gill-slits are formed behind the first three, and when the tadpole has reached the length of 3 mm. there are five—the hyo-mandibular and the 1st, 2nd, 3rd, and 4th branchial (fig. 2). This figure also shows that there is a progressive retardation from before backward in the aggregation of cells to form the myotomes of the respective segments). When the tadpole is 2½ mm. long the mesoderm of the 4th segment forms, on either side of the gut, a continuous sheet, the cells of which are all alike (figs. 3 and 4). At a length of 3 mm. the differentiation of the mesoderm of the 4th segment has begun, and there is on either side of the gut a long vertically placed strip of cells, more closely aggregated together than the rest of the mesoderm on each side of the strip (figs. 5 and 6). The outer side of this strip of aggregated cells is more sharply defined than its inner side, and nuclei in a state of karyokinesis are more frequent in it than in the rest of the mesoderm. As will be shown below, this band of cells is the first definite trace of certain of the muscles which are developed in this segment.

The band is better defined and more clearly marked off from the rest of the mesoderm when the tadpole has attained a length of 4 mm. (fig. 7). By the time the tadpole is 4½ mm. long it is seen that the band has separated into two portions,—an upper, situated dorso-lateral and lateral to the gut, and a lower, situated ventro-lateral to the gut (fig. 8).

A similar series of changes takes place in the 5th cranial segment. At a length of 2½ mm. there is a layer of undifferentiated mesoderm on either side of the gut (*vide* fig. 9). When the tadpole is 3 mm. long, this has separated into a vertical band of closely-packed cells, on each side of which the mesoderm is looser in texture (fig. 10). The hyo-mandibular cleft is seen in this section, and it appears as if the vertically-placed strip were outside the gill-cleft: this appearance is due to the fact that the hyo-mandibular cleft projects forwards as well as outwards (*vide* fig. 2). In fig. 11, from a tadpole 4 mm. in length, the section depicted is relatively a little more caudalwards, and just behind the springing of the hyo-mandibular cleft.

By the time the tadpole is 4½ mm. long (fig. 12) this vertically placed band of mesoderm has nearly separated[1] into an upper and lower portion, the upper situated dorso-laterally, the lower ventro-laterally of the gut, exactly as in the case of the 4th segment.

The mesoderm of the 6th cranial segment, when the tadpole is 2¼ mm. long, is undifferentiated, and there is no pleuro-peritoneal cavity (fig. 13). Shortly afterwards a slit appears in the ventro-lateral portion of the mesoderm—the beginning of the body-cavity in this segment (fig. 14, from a tadpole 2½ mm. long).

The mesoderm dorsal to the body-cavity, by the time the tadpole is 3 mm. long, has separated into a closely packed strip of cells, on each side of which are a few scattered ones (fig. 15). This strip is better marked when the tadpole is 4 mm. in length (fig. 16).

The mesoderm of the 7th segment is barely formed when the tadpole is 2¼ mm. long (fig. 1). As it grows in length the mesoderm of the 7th segment is seen, in transverse sections of a tadpole 2½ mm. long, to be a uniform band of mesoderm just behind the 2nd branchial cleft, whilst there is a body-cavity in the ventro-lateral portion (fig. 17).

When the tadpole is 3 mm. in length, the mesoderm of the

---

[1] The figure shows that the separation is complete, but a little further back (*vide* fig. 48—taken from the same tadpole) it is incomplete.

7th segment, dorsal to that portion where the pleuro-peritoneal cavity has appeared, has differentiated into a central closely-packed mass, on either side of which are a few scattered cells (fig. 18). The process has advanced further by the time the tadpole is 4 mm. long (fig. 19).

Longitudinal horizontal sections show that a similar process takes place in the 8th and 9th segments, and that the ventral portions of the successive strips of packed mesoderm cells of the 7th, 8th, and 9th are early united together from before backwards to form a continuous sheet (figs. 24 and 25).

These strips of aggregated mesoderm cells are the rudiments of certain cranial muscles, the development of which will be subsequently traced, but before doing so their morphological value must be considered.

It is clear that the lower portions of the bands in the 4th and 5th segments, which have separated off from the upper portions by the time the tadpole has attained a length of 4½ mm., are situated ventro-laterally to the gut, and correspond in part to the 'Seitenplatten' of v. Wijhe, *i.e.*, are splanchnic.

The upper portions on either side of the gut, both of these and of the succeeding segments, might be regarded as either an upper splanchnic portion, or represent the myotomes of v. Wijhe, *i.e.*, might be somatic.

In favour of the former view there is the statement of v. Wijhe, as mentioned above, that in Elasmobranchs the myotomes of the 4th and 5th segments atrophy early in development, and the myotome of the 6th segment remains very rudimentary.

On the other hand, it is much more probable that they are somatic, corresponding to the myotomes of Elasmobranchs, and for the following reasons.

If these dorsal portions represent splanchnic structures only, it might be expected that some rudiments of aggregations of cells would appear dorsal to them, and then vanish: this does not happen.

Again, the upper limit of the dorso-lateral strip of cells in, say, the 4th segment (fig. 5) is exactly similar to that depicted by v. Wijhe in the case of the myotomes of Elasmobranchs; the difference lies only in the fact that the lower limit of this dorso-lateral strip extends more ventrally in the tadpole than in the Elasmobranch. And, lastly, v. Wijhe says, as quoted above, that in Elasmobranchs the anterior portion of the sterno-hyoid is developed from the myotomes of the 7th, 8th, and 9th segments. Now, as will be shown below, the dorso-lateral strips of cells of the 7th, 8th, and 9th segments of the tadpole give origin to the genio-hyoid, sterno-hyoid and omo-hyoid. Hence it is fairly certain that they are somatic, and therefore the similarly situated muscle-rudiments in the 6th, 5th, and 4th segments are also somatic. Compare fig. 19 (7th segment) with figs. 16 (6th segment), 12 (5th segment), and 8 (4th segment). It is concluded that the myotomes of the 4th, 5th, and 6th segments do not atrophy or remain rudimentary in the tadpole as they do in the Elasmobranch, but persist and develop into muscles, as will now be shown.

The further development of the muscles may be conveniently taken in groups, and those of the 4th and 5th segments first of all. The changes undergone by the ventro-lateral groups of mesoblast cells are simple. Their lateral ends become attached to Meckel's cartilage and the cerato-hyal respectively, and their inner ends join together, forming the meckelian and hyoidean mylo-hyoid muscles (*vide* figs. 24, 25, 26–32, 39–41). The meckelian mylo-hyoid is a thin broad sheet, whilst the hyoidean mylo-hyoid is a thick band of muscle. One or two of the posterior fibres of the hyoidean mylo-hyoid become attached to the 1st branchial cartilage.

During metamorphosis these two muscles fuse together to form the mylo-hyoid muscle of the toad (*vide* figs. 63, 64), which differs from that of mammals in that it has a hyoidean as well as a meckelian portion, and is innervated by the VII as well as by the V nerve.

The myotome of the 4th segment, which is at first placed dorso-ventrally, soon becomes tilted so that its dorsal end is more posterior than its ventral extremity. This process, which is fairly evident in fig. 7, from a tadpole 4 mm. long, is very marked by the time a length of 4½ mm. is attained (figs. 21–25). It results in the myotome lying across and on the inner side of the myotome of the 5th segment.

The 4th myotome gradually becomes separated into two, the anterior digastric muscle, passing from the outside and inner surface of the suspensorium to Meckel's cartilage, and a long strip of muscle lying on the inside of the suspensorium, with its front end attached to the dorsal surface of Meckel's cartilage (*vide* figs. 21–25). This long strip becomes divided into three portions,—the pterygoid, which arises posteriorly from the under surface of the pedicle of the suspensorium, and the temporal and masseter, which arise from the inner surface of the suspensorium, and from the dorsal surface of its pedicle (*vide* figs. 26–32 and 33–41).

The myotome of the 5th segment develops into (1) the posterior digastric muscle, which passes from the outside of the orbitar process of the suspensorium to the top of the cerato-hyal, and (2) a muscle which, lying just below the anterior digastric, passes from the cerato-hyal to Meckel's cartilage (*vide* figs. 20–23, 28–32, and 33–36).

This condition of the muscles, developed thus early in tadpole life, persists until metamorphosis begins. The changes which then take place occur concurrently with those in the cartilages. Meckel's cartilage elongates backwards, so that from being a small mass attached to the front end of the suspensorium, it becomes a long bar directed antero-posteriorly; at the same time the front end of the suspensorium rotates downwards and backwards, and its orbitar process atrophies.[1]

The beginning of the changes in the muscles is seen in figs. 42–46. Little alteration takes place in the relative position of the muscles on the inner surface of the suspensorium; the pterygoid is seen to be attached to the inside edge of Meckel's cartilage, whilst the masseter and temporal are inserted into its outside edge. The muscle which, developed from the 5th myotome, connects together the cerato-hyal and Meckel's cartilage, atrophies early in metamorphosis. The greatest change takes place in the posterior digastric: as the orbitar process of the suspensorium atrophies, the upper end of the posterior digastric extends upwards to the roof of the skull, whilst its lower end loses its attachment to the top of the cerato-hyal and becomes fixed to the hind end of the now elongated Meckel's cartilage. The anterior digastric, owing to this forward movement of the posterior digastric and the elongation backwards of Meckel's

---

[1] *Vide* Balfour. Comp. *Embry.*, vol. ii.

cartilage, now lies on the inner side of the latter muscle, and the two muscles together form the depressor mandibulæ of the toad, which is innervated by the Vth and VIIth nerves.

The myotome of the 6th segment was left as a mass of cells lying lateral to the gut, just behind the 1st branchial cleft (*vide* figs. 16 and 47, from tadpoles 4 mm. long). It gradually becomes divided into an upper and lower portion (*vide* figs. 48–50, from a tadpole 4½ mm. long), the former of which becomes the most anterior petro-hyoid muscle (*vide* figs. 50 and 51), whilst the latter assumes a more and more ventral position (*vide* fig. 25). From this lower portion is formed a muscle which connects the ventral end of the 2nd branchial cartilage to the upper surface of the cerato-hyal cartilage (*vide* fig. 39). This muscle persists during the whole of tadpole life, and only disappears as metamorphosis comes on.

The myotomes of the 7th, 8th, and 9th segments were left as strips of cells lying laterally to the gut (*vide* fig. 19, from a tadpole 4 mm. long). From these myotomes two sets of muscles are developed: from the upper ends are formed the 2nd, 3rd, and 4th petro-hyoid muscles (*vide* figs. 51–53, 56, and 57), exactly as in the case of the 6th segment; whilst the lower portions shift ventrally so as to lie dorso-laterally to the pleuro-peritoneal cavity between this and the developing branchial chamber (*vide* figs. 24, 25, 55, and 56). The lower portion of the myotome of the 7th segment forms the genio-hyoid muscle; its front end rapidly extends forward (*vide* fig. 54) and becomes attached to the inferior labial cartilage, whilst its hind end is fixed to the basi-branchial plate (*vide* fig. 41). No further change in the position and connections of the genio-hyoid muscle takes place during tadpole life; shortly before metamorphosis, its anterior portion divides into two parallel slips, an inner and outer (*vide* figs. 42–46, 63, 64). As metamorphosis comes on, the inferior labial cartilage disappears, and the front end of the genio-hyoid becomes attached to the anterior extremity of Meckel's cartilage (*vide* figs. 63, 64).

The lower portions of the 8th and 9th myotomes fuse antero-posteriorly (*vide* figs. 24 and 25), and form a strip of cells occupying at first the same position in regard to the pleuro-peritoneal cavity and branchial chamber as the genio-hyoid. Subsequently, its hind end assumes a still more ventral position, and figs. 40 and 57 show the strip of cells as a flattish band of muscle between the pleuro-peritoneal cavity and the branchial chamber, with its posterior end more ventral than its front end, which is attached to the ventral end of the 3rd branchial cartilage. Very little further change takes place until the development of the shoulder girdle, shortly before metamorphosis, when the posterior end of the band of muscle, hitherto free, becomes attached to it, the lateral edge forming the omo-hyoid, and the median the sterno-hyoid (*vide* fig. 71). A few fibres of these muscles are continued forward into the genio-hyoid, but the main mass is inserted into the hyoid plate.

It would appear, then, that the ventral longitudinal muscles of the neck are formed from the ventral portions of the myotomes of the 7th, 8th, and 9th segments; they originate, at about the same period, by a downward shifting from their respective myotomes,—the genio-hyoid from the 7th, the sterno- and omo-hyoid from the 8th and 9th segments. Whereas the genio-hyoid early assumes its permanent form, the sterno- and omo-hyoid only do so later, on the development of the shoulder girdle. These facts may be correlated with the early importance of the jaws and the late development of the shoulder girdle in the tadpole.

On comparing the development of the sterno- and omo-hyoid in the Elasmobranch and the tadpole, a difference is found to exist. In the former, v. Wijhe says, as quoted above, that the 7th, 8th, and 9th myotomes give rise to the fore part of the sterno-hyoid and to muscles passing from the skull to the shoulder girdle. In the tadpole no muscles other than the 2nd, 3rd, and 4th petro-hyoids and the genio-sterno- and omo-hyoid are formed from the 7th, 8th, and 9th myotomes of the head, and no elements are added to the hind ends of the latter muscles from the myotomes of the trunk. The sterno- and omo-hyoid are the representatives in the head of the ventral longitudinal muscles of the trunk, and the explanation of the difference between the tadpole and the Elasmobranch in their development possibly lies in the very anterior position of the shoulder girdle in the former animal. Thus the scapula, when first formed, lies directly over the transverse process of the 1st cervical vertebra in the tadpole.

Tongue muscles.—No trace of the tongue muscles is seen until shortly before metamorphosis begins. Thus in longitudinal and transverse sections of tadpoles 14 mm. in length (figs. 58 and 59) the genio-hyoid muscle is seen passing from the 1st basi-branchial cartilage to the inferior labial cartilage, whilst there are a few scattered cells only below the buccal epithelium, lying between the basi-hyal and Meckel's cartilages, and well above the genio-hyoid muscle. Soon after the hind legs have appeared, these cells are seen to have proliferated, forming a mass below the epithelium of the floor of the mouth, and from this mass there is an outgrowth backwards to form the hyo-glossus muscle (figs. 60 and 61). A little later (fig. 62) the hyo-glossus is seen to have extended backwards, and an outgrowth spreading forwards, to form the genio-glossus, has appeared, and the protuberance of the tongue is greater. In the tadpole with well developed hind legs it is seen (figs. 63 and 64) that the hyo-glossus has spread backwards, and is attached to the hind edge of the hyoid plate internal to the genio-hyoid, and that the front end of the genio-glossus has extended forwards to Meckel's cartilage, whilst the tongue is much greater in bulk.

The tongue, then, together with the genio-glossus and hyo-glossus, begins to be developed late in the tadpole stage, and only becomes completely formed just before the front legs appear externally. It is not developed, as is generally held, from the front end of the ventral longitudinal muscles,[1] but is quite independent in origin, being derived from cells lying between Meckel's cartilages and the basi-hyal, just beneath the epithelium of the floor of the mouth, from cells, which can be traced from the tadpole stage of 2½ mm. in length, lying dorsal to the mylo-hyoid between this and the floor of the mouth (*cp.* figs. 28, 8, 6, 5).

It is concluded that the tongue, genio-glossus, and hyo-glossus are splanchnic in origin, inasmuch as they are developed from that portion of mesoblast, ventral and ventro-lateral to the gut, which does not develop into the mylo-hyoid. It is by reason of this, and also because of the development of the submentalis

---

[1] *Vide* Wiedersheim. Comp. *Anat. of Vertebrates*, trans. by Parker.

at about the same period from the splanchnic mesoblast just in front of the tongue (*vide* figs. 62–64), that the masses of mesoblast cells which develop into the mylo-hyoid muscle cannot be considered to represent altogether the 'Seitenplatten' of Elasmobranchs in these segments.

The sections do not show whether the tongue is derived solely from the 4th, or from both this and the 5th segment; its development takes place too late in the life-history of the tadpole. The growth of the genio-glossus and hyo-glossus respectively, forward and backward, suggest that possibly mesoblast cells from both segments play a part in their origin.

Laryngeal muscles.—The larynx is formed as a median pouch in the ventral wall of the gut, in the region of the 4th branchial arch. It first becomes visible when the tadpole is 5 mm. long. Similarly, at the same stage, a trace of the laryngeal muscles is first seen; they are developed from hitherto undifferentiated mesoblast cells lying ventral to the gut, between this and the pericardium, on either side of the median laryngeal diverticulum (*vide* fig. 72). The position of these cells in relation to the gut is the same as that of the cells from which the tongue muscles are developed. Both the larynx and the laryngeal muscles remain rudimentary until shortly before metamorphosis (*vide* fig. 71). The laryngeal muscles, then, are developed from the splanchnic mesoblast of the 9th segment of the head.

Sterno-mastoid and Trapezius.—No trace of the sterno-mastoid and trapezius muscles is visible until a very late stage in tadpole life. Thus, in figs. 65–67, from a tadpole 14 mm. long, it is seen that the trunk myotomes do not reach quite up to the back of the auditory capsule, and that just outside the pronephros there is the beginning of a fore limb. There is no scapula, and no trapezius nor sterno-mastoid muscle. By the time the hind legs have appeared, the first trunk myotome has become attached to the back of the skull (fig. 68), but is still undifferentiated. At a little later stage, in which there are small hind legs (figs. 69, 70), the first trunk myotome has split up into portions, of which the following (in fig. 69) may be distinguished. Just outside the medulla there is, dorsally, a portion of the myotome simple and undivided, and at its foot there are three muscles which pass from the skull to the transverse portion of the 1st cervical vertebra; whilst more to the side three masses of muscles can be distinguished, of which the dorsal one is the trapezius, the middle one the sterno-mastoid, and the lower one the levator anguli scapulæ. In fig. 70, a little further back, the scapula is visible, the trapezius, sterno-mastoid, and levator anguli scapulæ have already been inserted into the scapula, whilst the two outer of the muscles passing from the skull to the transverse process of the 1st cervical vertebra have united, so that there are two muscle masses only at the foot of the undivided portion of the myotome. In fig. 71, taken from a tadpole with large hind legs, the insertion of the sterno-mastoid into the anterior border of the scapula can be seen on the right hand side, whilst on the left (which is a little more anterior) the trapezius and sterno-mastoid are seen nearer their point of origin.

The sterno-mastoid and trapezius are thus absent during the greater part of tadpole life. They are developed from the 1st trunk myotome as metamorphosis comes on, in correlation with the appearance of the scapula. They are therefore not splanchnic, but somatic in origin.

On surveying the development of the myotomes of the head, it is clear, in the first place, that from each of the 8th and 9th myotomes (3rd and 4th branchial) is developed dorsally a petro-hyoid muscle, and ventrally a constituent of the strip of muscle, which becomes the sterno-hyoid and omo-hyoid. Similarly, from the myotome of the 7th segment (2nd branchial) is developed dorsally a petro-hyoid muscle, and ventrally the genio-hyoid muscle. Similarly, again, from the myotome of the 6th segment (1st branchial) is developed dorsally the foremost petro-hyoid muscle, and ventrally the muscle which passes from the 2nd branchial cartilage to the cerato-hyal, which muscle, however, has only a larval existence. In the next succeeding segments, the 5th and 4th (hyoid and maxillary), such a division of the myotomes into a dorsal and ventral portion is not so obvious, possibly by reason of the changes dependent on the development of a suctorial mouth. The 4th and 5th myotomes, like those which follow, are at first placed vertically, but the 4th soon rotates about a horizontal transverse axis, so as to lie on the inner side of and across the 5th myotome. The

5th myotome separates into the posterior digastric (which has much the same position as the petro-hyoid muscles, only differing in that its upper end is attached to the orbitar process of the suspensorium), and into the muscle connecting the cerato-hyal to Meckel's cartilage, but whether the latter is to be regarded as a forward continuation of the ventrally placed portions of the branchial myotomes seems doubtful. Like the muscle developed from the ventral portion of the 6th myotome, the muscle connecting the cerato-hyal to Meckel's cartilage has only a larval existence. There is no trace of a dorso-ventral division of the 4th myotome, unless the anterior digastric, which is separated off from its front (morphologically ventral) end, be regarded as the ventral part equivalent to those in the branchial segments. Determination, by experiment, of the existence or absence of posterior root-ganglion fibres for this muscle would shed light on the question. If they are present, the anterior digastric may be regarded as the ventral part of the 4th myotome, and the most anterior representative of the ventral longitudinal muscles. The rest of the 4th myotomes becomes split up longitudinally into the temporal, masseter, and pterygoid muscles.

In regard to the muscles which originate in the splanchnic portions of the head segments, the mylo-hyoid is early developed in the 4th and 5th segments, while later on, towards the end of larval life, the submentalis is developed in the 4th, and the tongue muscles (intrinsic and extrinsic) from the 4th and (?) 5th segments. No skeletal muscles are developed in the splanchnic portions of the 6th, 7th, and 8th (1st, 2nd, and 3rd branchial) segments, whilst in that of the 9th (4th branchial) the laryngeal muscles can be seen at an early stage, though undergoing but little development until shortly before metamorphosis.

There are certain differences between the head muscles of the toad and the dog: there are, for instance, muscles which exist in the tadpole only, but not in the toad or dog, viz., the muscle connecting the cerato-hyal to Meckel's cartilage, and that connecting the 2nd branchial cartilage to the cerato-hyal. The petro-hyoid muscles of the toad are absent in the dog. In the toad there is one pterygoid muscle, in the dog two, and the anterior digastric is differently placed. In the dog there is the stylo-hyoid muscle, not present in the toad, lying alongside the posterior digastric, and, like it, innervated by the facial nerve. The ordinarily accepted view that this muscle is delaminated from the posterior digastric is supported by the facts that the size of its nerve fibres is the same as that of those going to the latter muscle, and that it has no posterior root ganglion fibres. Again, the hyoid constituent of the mylo-hyoid muscle is wanting in the dog.

The tongue is more complex in the dog than the toad: the tongue of the latter is the representative only of the tuberculum impar[1] of the dog, and similarly grows upwards in the floor of the mouth, between the ventral ends of the maxillary and hyoid arches, whilst the part derived in the dog from the hyoid and 1st branchial arches (furcula) is not developed. Such a view is supported by consideration of the origin of the sensory nerves of the tongue in the two animals; and by the fact that in the toad the duct of the thyroid gland, though disappearing before the development of the tongue begins, yet opens into the mouth just in front of the basi-hyal, and so behind the tongue. The extrinsic muscles of the tongue are also more complicated in the dog than the toad: in the latter they consist of the hyo-glossus and genio-glossus only, whilst in the dog there is additionally the stylo-glossus. It may be inferred that the intrinsic muscles of the tongue in the dog are developed from the 4th, 5th, and 6th, and the extrinsic muscles from the 4th and 5th segments.

The stylo-pharyngeus, crico-thyroid, palato-pharyngeus, constrictors of the pharynx, levator veli palatini, azygos uvulæ, present in the dog, are absent in the toad, and their morphological position can only be inferred from their nerve supply; and similarly in the case of the tensor tympani and tensor veli palatini.

The trapezius and sterno-mastoid muscles in the toad are developed from the first trunk myotome only, whereas in the dog the extended origin of the spinal portion of the XIth nerve suggests that possibly in that animal they are developed from some of the succeeding trunk myotomes as well.

The ventral longitudinal muscles of the neck are a little different in the two animals. In the toad they consist of the

---

[1] *Vide* Quain, vol. i. pt. i.

genio-hyoid, sterno-hyoid, and omo-hyoid, whilst in the dog the omo-hyoid is absent, and there is a deeper muscle layer, consisting of the thyro-hyoid and sterno-thyroid. A more important question is the origin of these muscles in the dog. In the toad they are developed from head myotomes only, whereas in the dog it is possible that, like the Elasmobranch, the posterior portions of these muscles are derived from trunk myotomes. As suggested above, the difference is possibly connected with the relative position of the shoulder girdle.

Of the somatic muscles of the head of the dog, only the ventral longitudinal ones have posterior root ganglion fibres.[1] The causes of these differences are obscure, and but little light is shed on the problem by the fact of the development of the latter muscles from the ventral ends of the myotomes from which they are derived, and by the consideration that they are the representatives in the head of the ventral longitudinal muscles of the trunk. And the difficulty is accentuated by the fact that no posterior root ganglion fibres accompany the spinal part of the XIth nerve.[2]

Notwithstanding, then, the differences between the head muscles of the toad and the dog, it would seem a legitimate deduction from the above that in the latter animal the temporal, pterygoids, masseter, anterior digastric, posterior digastric, and stylo-hyoid, sterno-mastoid, and trapezius muscles are somatic, whilst the tongue muscles (intrinsic and extrinsic) are splanchnic in origin, as indeed the maximum size of their motor fibres suggested.

The following classification of the muscles of the head of the dog can be made from the above:—

v. CLASSIFICATION OF CRANIAL MOTOR NUCLEI.

One or two conclusions result from the foregoing as to the cranial nuclei which innervate cross-striped muscles.

---

[1] With the doubtful exception of the anterior digastric; see above.

[2] The sterno-mastoid and trapezius muscles, however, possibly have posterior root ganglion fibres entering them with the additional motor supply from the 1st, 2nd, and 3rd cervical nerves, discovered by Risien Russell, *Brain*, 1897.

Segment	*Somatic.* Their motor fibres have a maximum diameter of 16 μ.		*Splanchnic.* Their motor fibres have a maximum diameter of 11·2 μ.			
1.	Rect. sup., Lev. palp. sup., Rect. inf. and int., Obliq. inf.	iii	0			
2.	Obliq. sup.	iv	0			
3.	Rect. ext. and Retract. oculi	vi	0			
4. (maxillary)	Temporal, masseter, pterygoids, anterior digastric	v	Mylo-hyoid, tensor tympani, tensor veli palatini	v	Tongue muscles Intrinsic, 4th, 5th, and 6th segments Extrinsic, 4th and 5th segments	xii
5. (hyoid)	Posterior digastric, stylo-hyoid	vii	Other facial muscles	vii		
6. (1st branchial)	0		Stylo-pharyngeus Crico-thyroid	ix		
7. (2nd branchial)	Genio-hyoid	xii	Palato-phary., Constrict. pharyngei Levator veli palatini Azygos uvulæ	x		
8. (3rd branchial)	Sterno-hyoid Sterno-thyroid (? anterior part only) Thyro-hyoid	xii and 1st cervical				
9. (4th branchial)			Laryngeal muscles (9th segment)	xi medullary		
1st cervical (? 1st only)	Sterno-mastoid and trapezius	xi spinal				

It was held by Gaskell[1] that the motor nuclei in the mid and hind brain can be arranged as follows:—α, an anterior cell column, a continuation of the spinal anterior cornu, formed by the XII, VI, IV, and III nuclei; and β, a lateral cell column, a continuation of the lateral horn of the spinal cord, formed by the XI spinal, nucleus ambiguus of the XI, medullary X and IX, the VII and the V.

If, however, they be arranged according to the above proposed revision of the morphological position of some of these muscles, we should have the following classification of the nuclei according, in Hughlings Jackson's phrase, to the muscles they 'represent':—α, a cell column innervating muscles developed in the somatic portions of the head segments; and β, a cell column innervating those muscles developed in the splanchnic portions of the head segments, *i.e.*, corresponding to the table given above.

The cell-column α will be homologous with the anterior cornual cells. Correspondingly, it is found that the maximum size of the large fibres in the spinal anterior roots in the non-limb regions of the spinal cord is the same as that of the nerve fibres passing to the somatic muscles in the cranial region. (In the region of the limbs, however, the maximum diameter of the fibres in the anterior spinal roots is greater—in the specimens examined as much as 20·8 μ.) Cell-column β will be homologous with the lateral cornual cells of the spinal cord innervating splanchnic muscles.

Whereas splanchnic muscles in the body are not cross-striped, those in the head are cross-striped. And insomuch as this development of cross-striped muscles in the splanchnic mesoderm of the head may in all probability be connected with the development of the branchial bars there, the term 'branchial' may perhaps be applied to their motor nerve-fibres and nuclei of origin, in place of 'non-ganglionated splanchnic' employed by Gaskell.

The motor fibres of the cranial nerves, with exception of the hypoglossal, innervate cross-striped muscles developed in the corresponding segments only. The hypoglossal, on the other hand, is the nerve of no individual segment, but innervates

---

[1] *Loc. cit.*

splanchnic muscles developed in the 4th, 5th, and 6th, and somatic muscles, derived from the 7th, 8th, and 9th, segments.

The motor fibres of the IX, X, and medullary XI innervate two sets of splanchnic muscles, cross-striped and unstriped; and it is stated by Gaskell[1] that the n. ambiguus is the motor nucleus of the former, the dorsal nucleus that of the latter.[2] There is, then, in regard to these nerves an overlapping of splanchnic nuclei of cross-striped and involuntary muscles, but it is to be remarked that the latter muscles, other than the cardiac, are developed from body, not head, segments.

The sterno-mastoid and trapezius are cervical, not head muscles; they are developed from the 1st trunk myotome in the toad, possibly from more than one in the dog; and correspondingly their nerve, the external portion of the XI, arises from the spinal cord.

The above results suggest that it should be possible to split up the Vth, VIIth, and XIIth nuclei, each into two portions, supplying somatic and branchial muscles respectively. Though this can only be determined by the application of v. Gudden's or Nissl's methods, yet there are already indications that it may be possible.

Kölliker[3] holds that the descending root of the V is motor, and goes on to remark, "welche Muskeln dieser Wurzel untersteht ist freilich nicht von Ferne zu errathen, doch darf man vielleicht an den Tensor veli palatini und den Tensor tympani denken, schwerlich an den Mylo-hyoideus und Biventer anterior." And Tooth and Turner[4] state that in a case of atrophy of the masticatory muscles, the motor nucleus of the V was found to be atrophied.

This suggests that the descending root of the V supplies the branchial muscles, mylo-hyoid, tensor veli palatini, and tensor tympani; whilst the somatic muscles—temporal, masseter, pterygoids, and anterior digastric—are innervated by the main nucleus of the V.

---

[1] *Loc. cit.*

[2] This theory, that the dorsal nucleus is motor to unstriped muscles, has been confirmed by Marinesco (*Comptes rendus de la Société de Biologie*, 1897), by Bruce (*Brain*, 1898), and by Van Gehuchten (*Jour. de Neurologie*, 1898).

[3] *Handbuch der Gewebelehre des Menschen.*

[4] *Brain*, 1891. They do not, however, say whether the anterior digastric muscle was atrophied or not.

From the recent researches of Van Gehuchten[1] on the nucleus of the VII, it may be inferred that the somatic muscles (posterior digastric and stylo-hyoid) are innervated by a portion of the external-inferior division, and the other, branchial, muscles by the remainder of the facial nucleus.

As to the XII nucleus, it is possible that whereas the tongue muscles are innervated by the hypoglossal nucleus proper, the somatic muscles (genio-hyoid in the monkey; this together with the thyro-hyoid and anterior portions of the sterno-hyoid and sterno-thyroid in the dog) are innervated from the front end of the anterior cornu of the spinal cord, which sends fibres into the hypoglossal.[2]

vi. COLLATERAL EVIDENCE FROM DISEASE.

There are a few obscure cases of disease of the motor nuclei in the mid and hind brain, which are of interest in connection with this classification of them.

Thus, somatic nuclei occasionally atrophy in common; *e.g.*, in the patient of Ferrier, whose case was published by Hughlings Jackson,[3] external ophthalmo-plegia and atrophy of the masticatory muscles occurred.

On the other hand, Hughlings Jackson[4] states that paralysis of the orbicularis palpebrarum is rare in cases of ophthalmoplegia externa; now, whereas the external ocular muscles are somatic, the orbicularis palpebrarum is branchial in origin. In bulbar paralysis the atrophy affects primarily branchial nuclei, and only rarely spreads to the somatic nuclei of the V, VI, IV, and III nerves.

In some cases of congenital ptosis contraction of the levator palpebræ superioris—a somatic muscle—takes place on certain movements. It is of interest to note that these movements are all executed[5] at least in part by somatic muscles, for they are

---

[1] *Jour. de Neurologie*, Mars 20, 1898.

[2] *Cp.* fact that the largest fibres in the hypo-glossal roots are found in the hindmost ones only.

[3] *Lancet*, 1893.

[4] *Loc. cit.*

[5] Hughlings Jackson, *Lancet*, 1894; Gunn, *Trans. Oph. Soc.*, vol. iii.; Sinclair, *Oph. Rev.*, 1893; Snell, *Sheff. Med. Jour.*, 1893; Swanzy, *Diseases of Eye.*

those of mastication, opening the mouth, and deglutition; whereas no cases are on record in which elevation of the upper lid has taken place in association with movements of branchial muscles only, *e.g.*, of the face, tongue, or larynx.

vii. SENSORY FIBRES OF THE CRANIAL NERVES.

The sensory branches of the cranial nerves may be separated into two divisions by the maximum size of the nerve fibres they contain. Medullated nerve fibres of all diameters up to 16 μ are found in the frontal, long ciliary, ethmoidal, and infra-trochlear from the 1st division of the V; the lacrymal, infra-orbital, subcutaneus malæ, dental branches of the infra-orbital, palatinus major, and nasalis posterior, from the 2nd division of the V; the auriculo-temporal, buccal, terminal (skin) branches of mylo-hyoid, mental and dental branches of inferior dental, from the 3rd division of the V; and the n. auricularis of the X.

Medullated fibres of all diameters up to 11·2 μ are found in the palatinus minor, lingual, orbital gland branches of the buccal, parotid gland branches of the auriculo-temporal, chorda tympani, lingual branch of IX, superior laryngeal, communicans laryngei, cardiac and pulmonary branches of X, and vagus trunk beyond the pulmonary branches.

The maximum diameter of the fibres placed in the second division was in some cases as low as 9·6 μ, in others as high as 12·8 μ. The maximum diameter of the fibres placed in the first division varied between 17·6 μ and 14·4 μ. In three cases, the long ciliary, the mental branch of the inferior dental, and the skin branches of the mylo-hyoid (all of which are placed in the 1st division), it was very occasionally found that the maximum diameter of the fibres might be as low as 12·8 μ; but insomuch as the variations in the maximum diameter of these nerve fibres are from this figure upwards only, it would appear that the two divisions of nerve fibres proposed are fairly distinct.

From a comparison of this with embryological evidence, it follows that ectodermal structures (skin, nasal epithelium, and stomodeum) have passing towards them fibres of various diameters up to 16 μ as a maximum, whilst in the case of endodermal structures the maximum diameter of the nerve fibres does not exceed 11·2 μ. But to this there is an apparent exception—the salivary glands have only the smaller sized fibres passing to them, though developed, according to received opinion, from the stomodeum.[1] This ordinarily accepted view, as far as I can learn, is based on evidence from comparative anatomy, and not from embryological investigation.

It seemed possible that the line of junction of epiblast and hypoblast on the floor and sides of the mouth might be found to be a little further forward than is thought, so that these glands might be hypoblastic in origin—as is suggested by the size of the nerve fibres. The point was investigated in the rabbit, but with inconclusive results. The line of junction of stomodeal epiblast and hypoblast ceased to be visible by the 12th day, whilst the salivary glands did not begin to develop until the 15th day of embryonic life.

The evidence cited above with regard to sensory fibres in the nerves of the cross-striped splanchnic muscles of the head goes to show that their maximum diameter is the same as that of the sensory fibres of the endoderm in the head region.

Sensory fibres of various diameters, up to a similar maximum, are found in the sympathetic, and pass to splanchnic structures.

It seems, then, possible to group all these fibres together as visceral sensory fibres, supplying both endoderm and splanchnic mesoderm.

The sensory fibres of the ectodermal structures of the head have a distinctly higher maximum of size than the visceral sensory fibres. (To this general statement, the nerves of the salivary glands form a doubtful exception.)

As regards the origin of the afferent fibres of the cranial nerves, it is to be noted that Gaskell[2] divided them into 'somatic afferent,' *i.e.* the ascending root of the trigeminal, and 'splanchnic afferent,' *i.e.* the ascending root of the vagus.

From the above described observations it would appear that there are three additional groups of sensory fibres to be accounted for—the splanchnic afferent fibres of the Vth (muscle sensory and sensory fibres of the splanchnic sensory branches, such as the lingual), the splanchnic afferent (muscle sensory

---

[1] Vide *Quain's Anatomy*, vol. i. pt. i.

[2] *Loc. cit.*

and sensory fibres of the chorda tympani) fibres of the VIIth, and the somatic afferent (n. auricularis) of the Xth nerves.

Bruce[1] has described the sensory root of the Vth as consisting of two portions on either side of the gelatinous substance of Rolando; and it is possible that the inner and smaller portion consists of the splanchnic afferent, and the outer and larger division of the somatic afferent fibres. The splanchnic afferent fibres of the VII, with the geniculate as their posterior root ganglion,[2] end as the ascending root of the facial;[3] whilst the central connections of the n. auricularis are very possibly to be found in those few fibres of the 'vagus' which, according to Ramon y Cajal,[4] on entering the medulla, turn aside to join the descending root, and apparently, from the picture, the outer descending root, of the V. If this be so, the central terminations of the somatic (ectodermal) and splanchnic afferent fibres of the cranial nerves are quite separate and distinct—all the ectodermal sensory fibres finding their way into the outer descending root of the V; whilst the splanchnic sensory fibres end in the inner descending root of the V, and the descending roots of the VII, IX, and X.

viii. GENERAL CONCLUSIONS.

The observations above described may be summed up as follows:—

1. Somatic muscles are developed from each segment of the head. Their motor nerve-fibres have a maximum diameter which is the same as that of those innervating somatic muscles of non-limb regions of the body.

2. Whereas the splanchnic mesoderm of the body develops unstriped muscles only, that of the head develops cross-striped

---

[1] "Nerve tracts of the mid and hind brain."

[2] Which, according to His (as stated by Schäfer, *Quain*, vol. i. pt. i.), is derived from the same ganglionic mass as that which furnishes the ganglia of the auditory nerve, and from which fibres grow centrally into the brain and peripherally along the nerve.

[3] *Vide* Kölliker, *loc. cit.*

[4] "Beiträge zum Studium des Medulla oblongata." It was not determined whether these fibres come from the glosso-pharyngeal or the vagus proper.

muscles.[1] This is probably primarily dependent on the presence of gill-arches in the head. The motor nerve-fibres of these branchial cross-striped muscles have a maximum diameter which is greater than that of those supplying the splanchnic unstriped muscles of the body, and less than that of those which pass to somatic muscles.

3. The somatic muscles of the head differ from those of the body in not possessing root ganglion muscle-sensory nerve-fibres. To this statement the anterior digastric is a doubtful, and the ventral longitudinal muscles a positive exception.

4. The splanchnic muscles of the head probably have muscle sensory fibres, the maximum diameter of which betrays their splanchnic destination; these form a particular group of the splanchnic sensory fibres.

5. The sensory fibres of the ectodermic structures of the head have a maximum diameter which is greater than that of the splanchnic sensory fibres. To this the nerves to the salivary glands form a doubtful exception.

6. The maximum diameter of the nerve-fibres, both motor and sensory, passing to any structure, is dependent on the morphological position of that structure, and not on the nature of the impulses carried by them.

I have, finally, to express my hearty thanks, to Dr Gaskell for much help and criticism, and to Prof. Weldon for advice in connection with the embryological work. It is, of course, scarcely necessary to say that my former teachers are not responsible for any errors, in fact or theory, on my part. I have also to thank Prof. Schäfer for permission to do an experiment in his laboratory, and Dr Aldren Turner for performing a most difficult operation for me.

The expenses of the investigation have been defrayed by a Government grant from the Royal Society.

---

[1] And also, in the branchial region, the heart muscle.

DESCRIPTION OF PLATES X.-XXII.

The outlines of the structures were drawn with a camera lucida; figs. 4 and 6 under a magnification of Zeiss oc. 3, obj. D; the others under one of oc. 3, obj. A.

FIG.

1. Longitudinal horizontal section, 2¼ mm. long.
2. Ditto, 3 mm. long.
3. Transverse section, 2½ mm. long, at level of 4th segment. Right side more anterior.
4. The right side of section 3, under higher power. The outline of each individual cell drawn under the camera lucida.
5. Transverse section, 3 mm. long, at level of 4th segment.
6. Right side of section 5, under higher power. The outline of each individual cell drawn.
7. Transverse section, 4 mm. long, at level of 4th segment. The right side of the section is a little anterior to the left.
8. Transverse section, 4½ mm. long, at level of 4th segment. The right side of the section is a little posterior to the left.
9. Transverse section, 2½ mm. long, at level of 5th segment.
10. Ditto, 3 mm. long, ditto.
11. Ditto, 4 mm. long, ditto. The right side of the section is a little anterior to the left.
12. Ditto, 5 mm. long, ditto. The left side is a little anterior to the right.
13. Transverse section, 2¼ mm. long, at level of 6th segment.
14. Ditto, 2½ mm. long, ditto.
15. Ditto, 3 mm. long, ditto.
16. Ditto, 4 mm. long, ditto. The right side is a little anterior to the left.
17. Transverse section, 2½ mm. long, at level of 7th segment.
18. Ditto, 3 mm. long, ditto.
19. Ditto, 4 mm. long, ditto.

20–25. Serial vertical longitudinal sections through a tadpole 4½ mm. long, 20 being the most external.

26–32. Transverse vertical sections through tadpole 9 mm. long. The right side is the more anterior; 19 is the front end.

33–41. Longitudinal serial sections through tadpole 9 mm. long; 33 is the most external.

42–46. Transverse serial sections through tadpole in which hind legs are large; 42 is the most anterior.

FIG.

47. Transverse section from tadpole 4 mm. long, in 5th and 6th segment. The left and ventral sides are more anterior; this section is of a tadpole of same length as fig. 16, but is drawn so as to render the appearances seen in figs. 48–50 more intelligible.

48–50. Transverse serial sections through tadpole 4½ mm. long, in 5th and 6th segments. The left and ventral sides are more anterior than the right and upper parts.

51–53. Longitudinal vertical serial sections through tadpole 7½ mm. long; 51 is the most external.

54. Longitudinal vertical section through tadpole 5 mm. long. The anterior end of the genio-hyoid here shown is its furthest forward limit; it does not extend further forwards in adjacent sections.

55. Transverse section through tadpole 4½ mm. long, at level of 7th segment. The left side is anterior to the right.

56. Transverse section, 6 mm. long, through 7th segment; the upper part of the figure is more anterior than the lower.

57. Ditto, 9 mm. long, through 8th segment.

58. Longitudinal section, 14 mm. long.

59. Transverse section, 14 mm. long. The left side is anterior to the right.

60. Longitudinal section through tadpole in which hind legs have just appeared.

61. Transverse section, ditto. The left side is anterior to the right.

62. Longitudinal section through tadpole in which hind legs are of moderate size.

63, 64. Longitudinal serial sections of tadpole in which hind legs are large; 63 is the more internal.

65–67. Transverse serial sections from tadpole 14 mm. long, through 1st trunk myotome.

68. Transverse section of tadpole in which hind legs are small, through 1st trunk myotome.

69, 70. Transverse serial sections of tadpole in which hind legs are of medium size, through 1st trunk myotome; 69 is the more anterior.

71. Transverse section through tadpole in which hind legs are large, through 1st trunk myotome. The left side of the section is anterior to the right.

72. Transverse section through tadpole 5½ mm. long. The upper and left-hand sides of the section are more posterior than the lower and right-hand sides.

A.	auditory vesicle.
ad.	anterior digastric.
B.	brain.
b.c.	branchial chamber.
b.b.	basi-branchial.
br.	branchial arch.
*br.*1.	1st branchial arch, etc.
b.b.p.	basi-hyo-branchial plate.
b.h.	basi-hyal.
b.s.	branchial cleft.
1 *b.s.*	1st branchial cleft, etc.
c.h.	cerato-hyal.
E.	eye.
ec.	ectoderm.
f.l.	fore limb.
g.g.	genio-glossus.
g.h.	genio-hyoid.
g.h.i.	internal slip of genio-hyoid.
g.h.e.	external slip of genio-hyoid.
h.	heart.
h.g.	hyo-glossus.
h.s.	hyo-mandibular cleft.
hy.	hypoblast.
I.	infundibulum.
i.l.	inferior labial cartilage.
lev. ang. scap.	levator anguli scapula.
lar.	larynx.
lary,m.	laryngeal muscles.
l.	liver.
ma.	masseter.
m. 4.	myotome of 4th cranial segment, etc.
me.	Meckel's cartilage.
mes.	mesoderm.
m.h.h.	hyoidean mylo-hyoid.
m.h.m.	meckelian mylo-hyoid.
m.m.h.	muscle connecting Meckel's cartilage to cerato-hyal.
m.b.h.	muscle connecting 2nd branchial to cerato-hyal.
N.	nose.
n.	notochord.
œ.	œsophagus.
o.s.	orbitar process of suspensorium.
om.hy.	omo-hyoid.
p.	pedicle of suspensorium.
p.d.	posterior digastric.
per.	pericardium.
ph.	pharynx.
p.p.g.	palato-pterygoid bar.
pt.	pterygoid.
pr.	pronephros.
ppc.	pleuro-peritoneal cavity.
precor.	pre-coracoid.
pet.hy.	petro-hyoid.
S.	suspensorium.
sb.m.	sub-mentalis.
s.l.	superior labial cartilage.
scap.	scapula.
sterno.m.	sterno-mastoid.
st.hy.	sterno-hyoid.
tg.	tongue.
th.	thyroid.
tr.	trabecula.
tem.	temporal.
1 *t.m.*	1st trunk myotome.
trap.	trapezius.

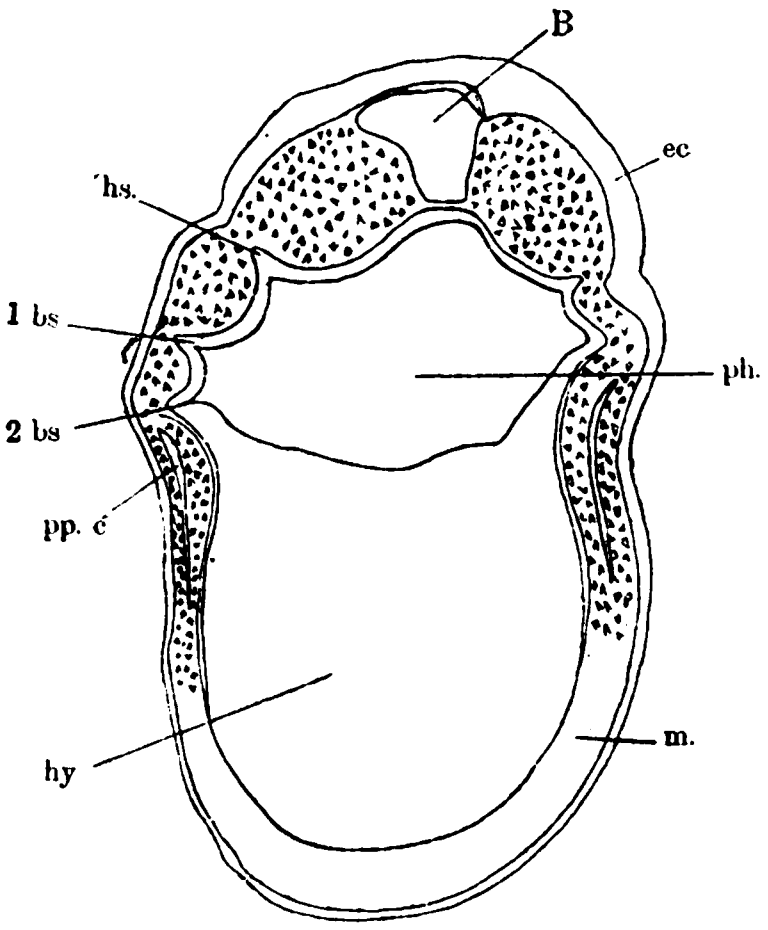

Fig. 1.

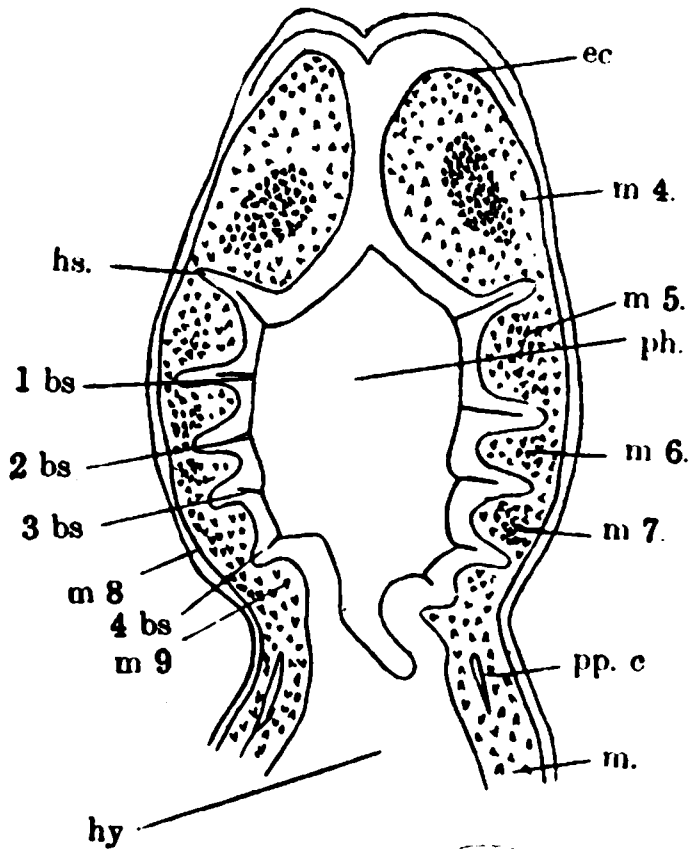

Fig. 2.

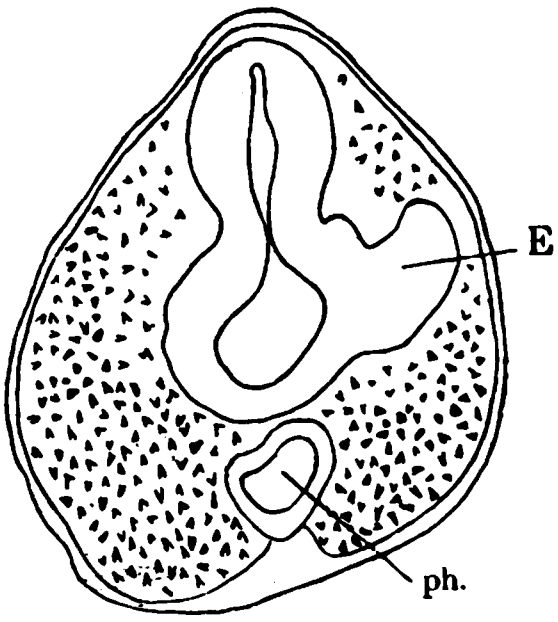

Fig. 3.

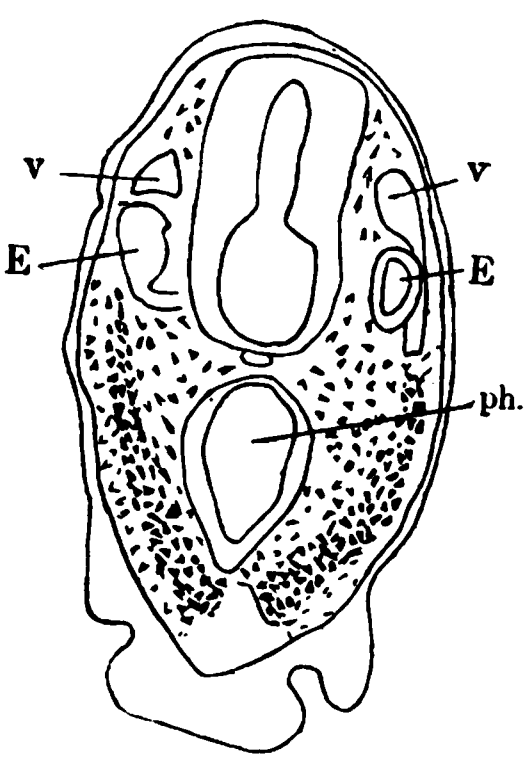

Fig. 5.

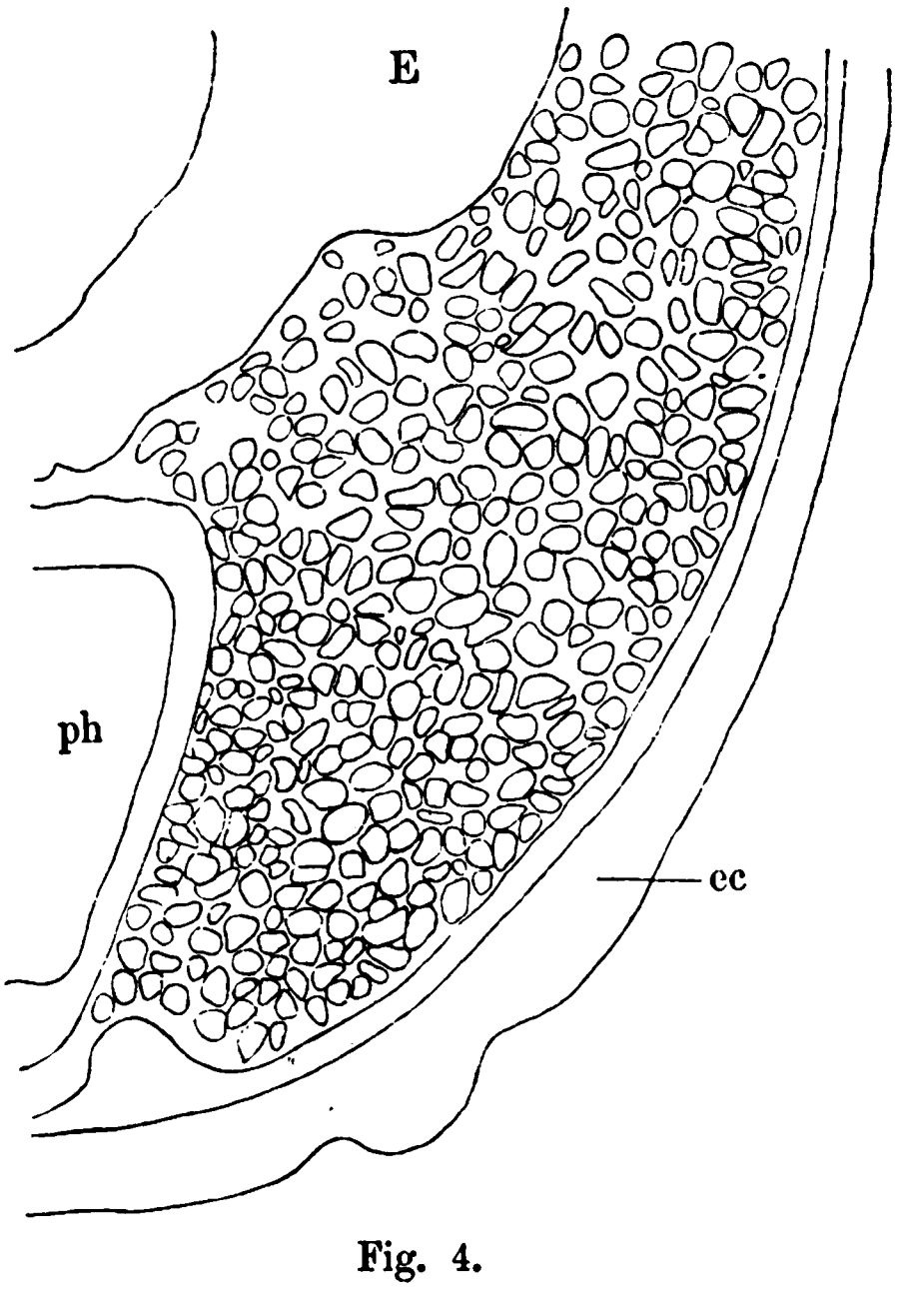

Fig. 4.

MR EDGEWORTH on Medullated Fibres of Cranial Nerves.

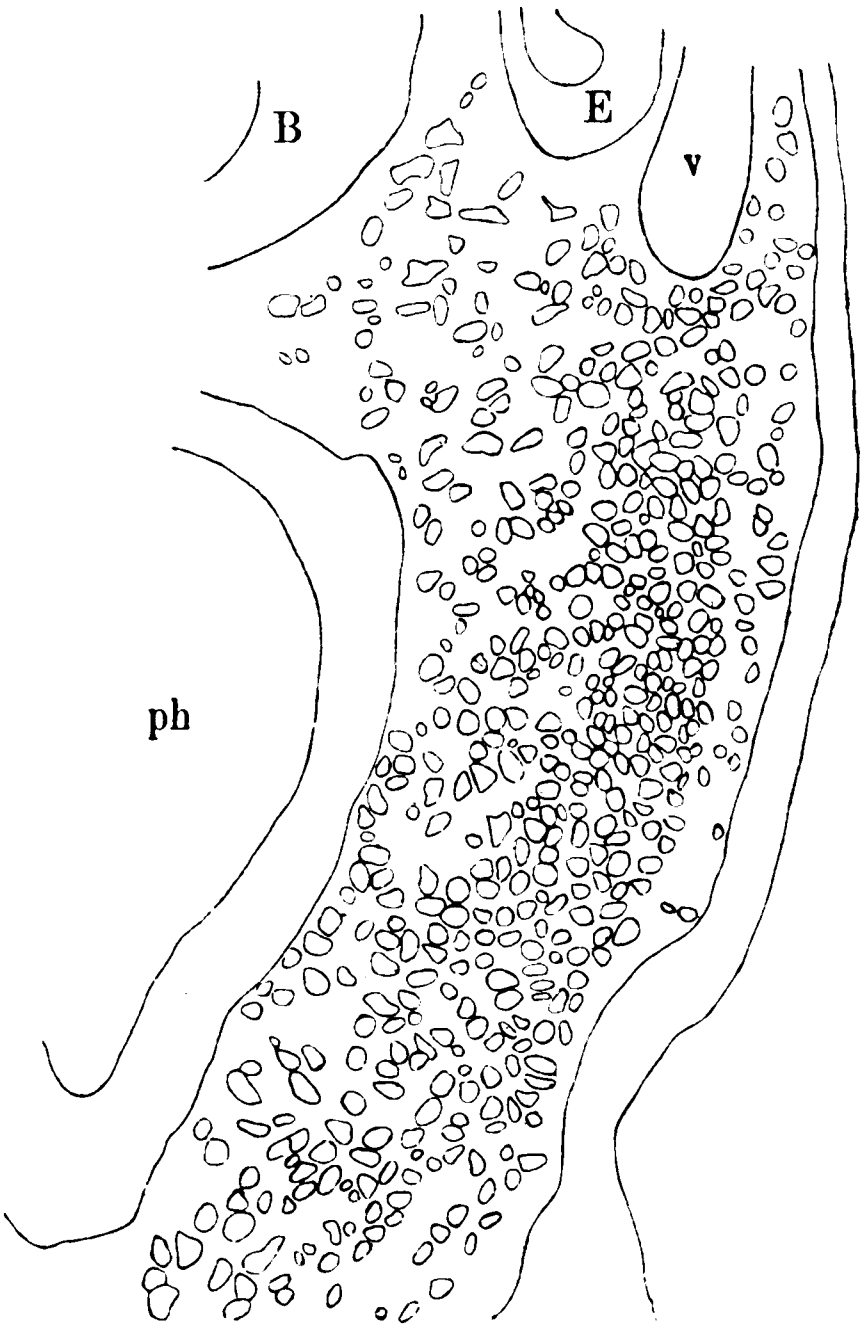

Fig. 6.

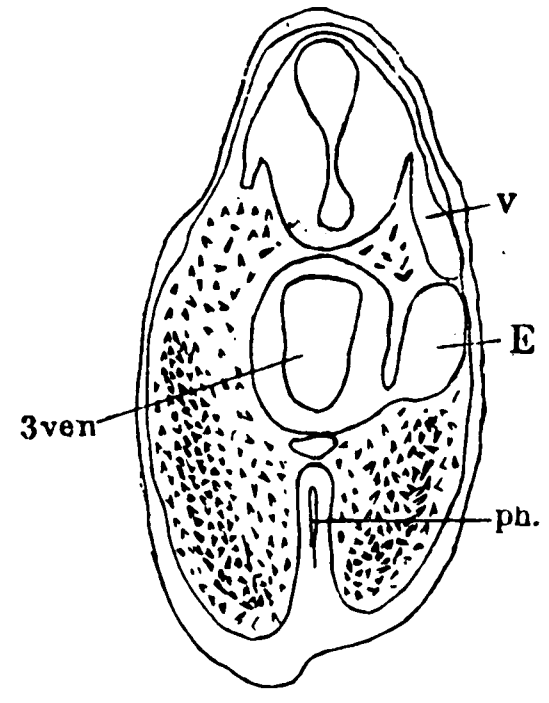

Fig. 7.

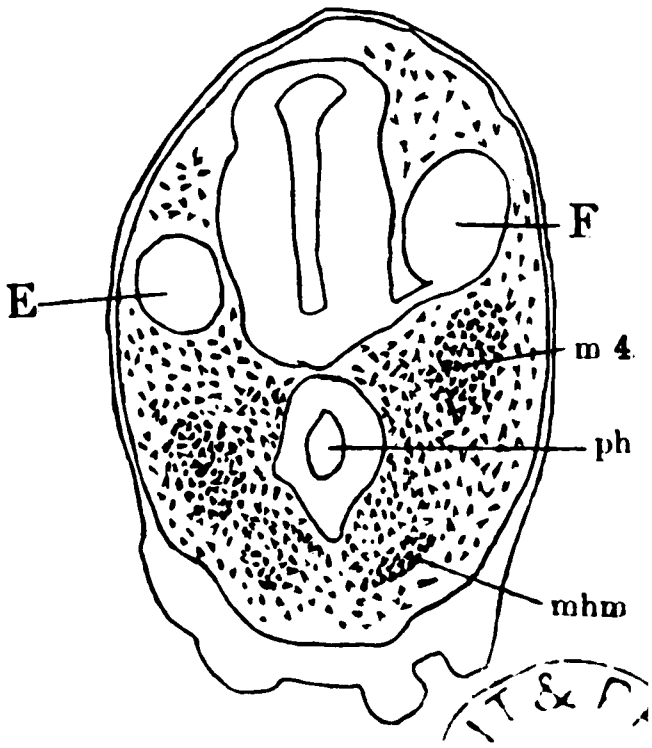

Fig. 8.

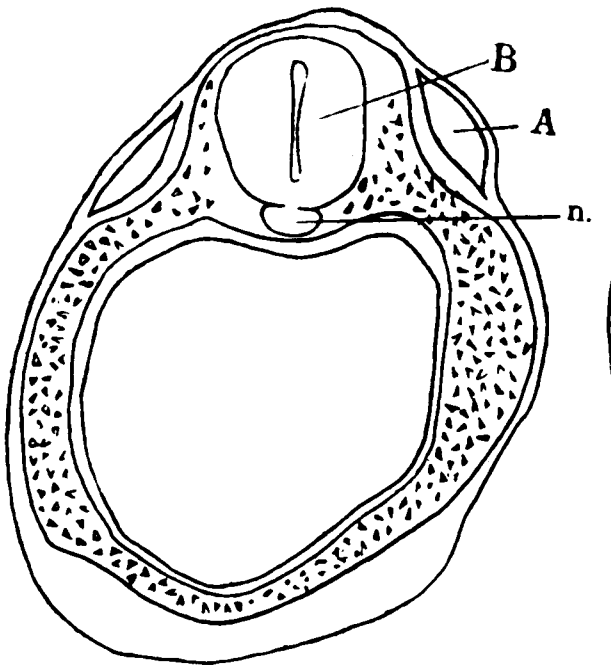

Fig. 9.

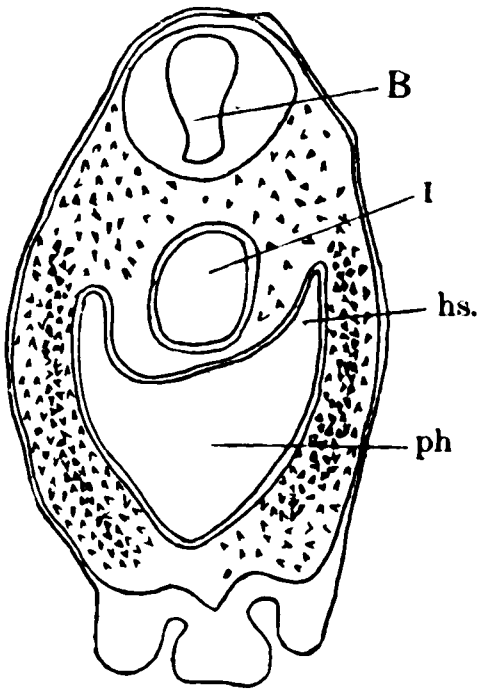

Fig. 10.

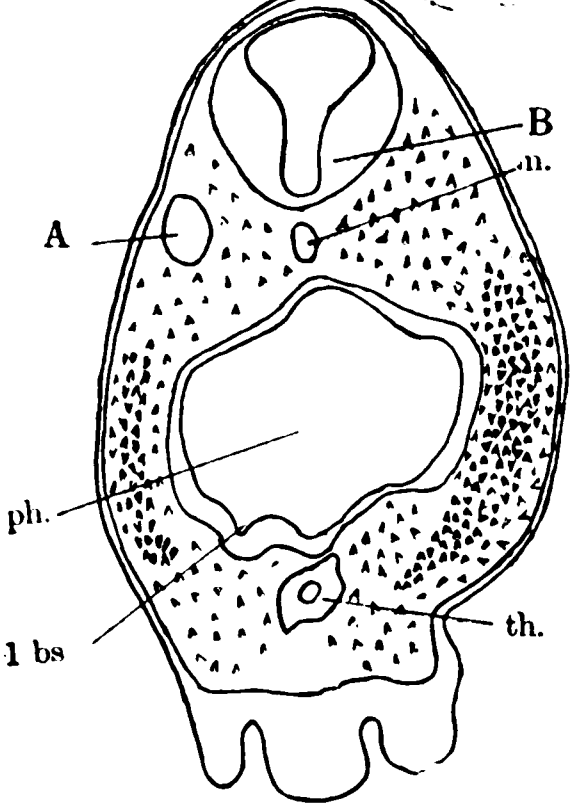

Fig. 11.

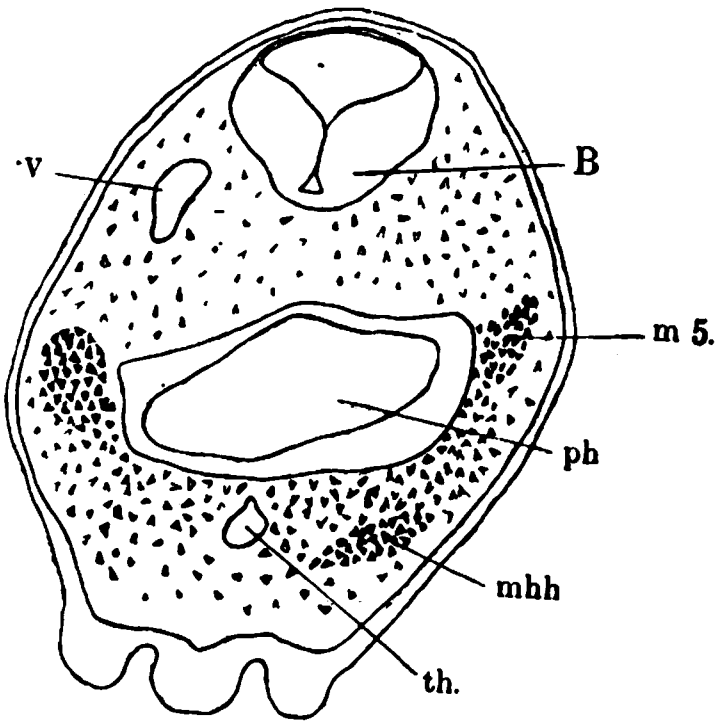

Fig. 12.

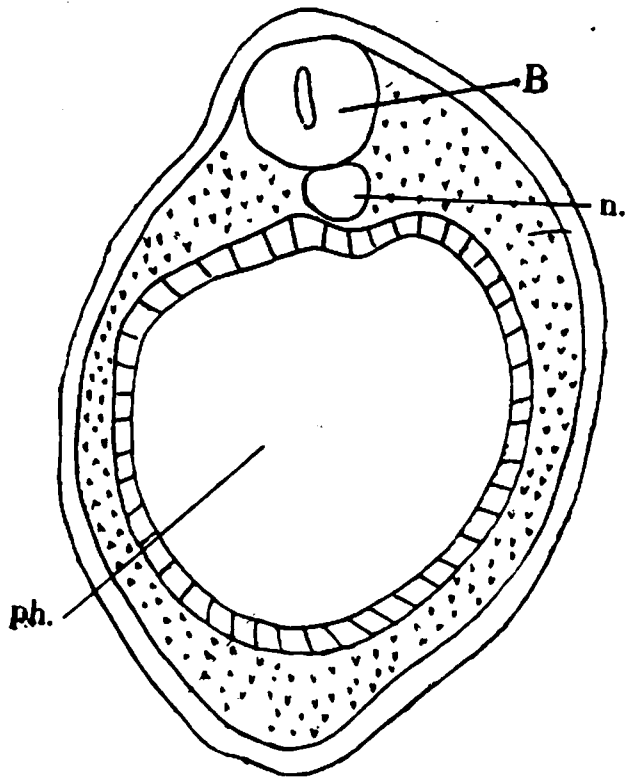

Fig. 13.

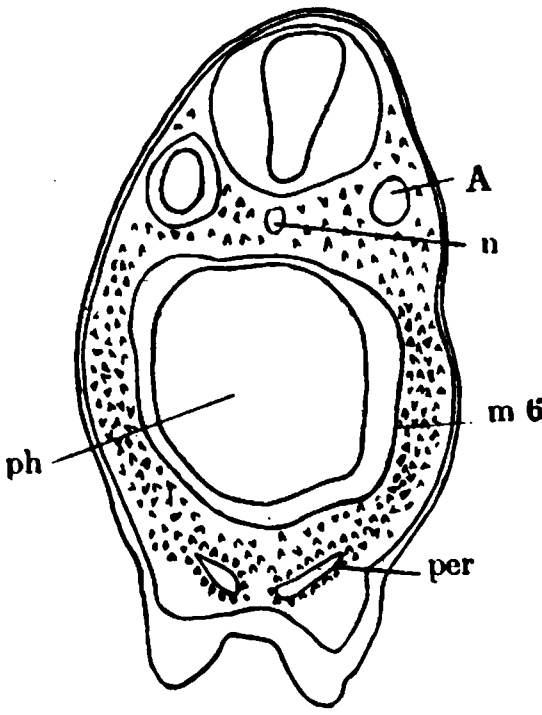

Fig. 15.

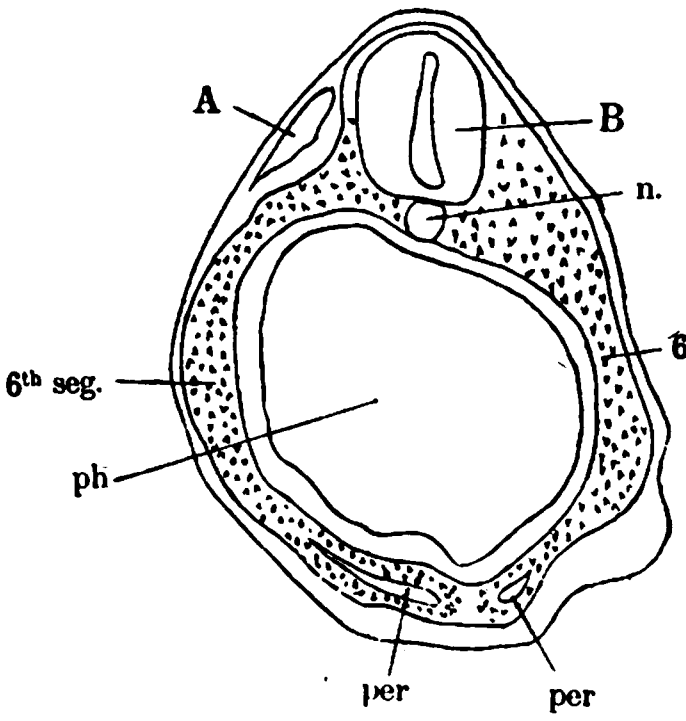

Fig. 14.

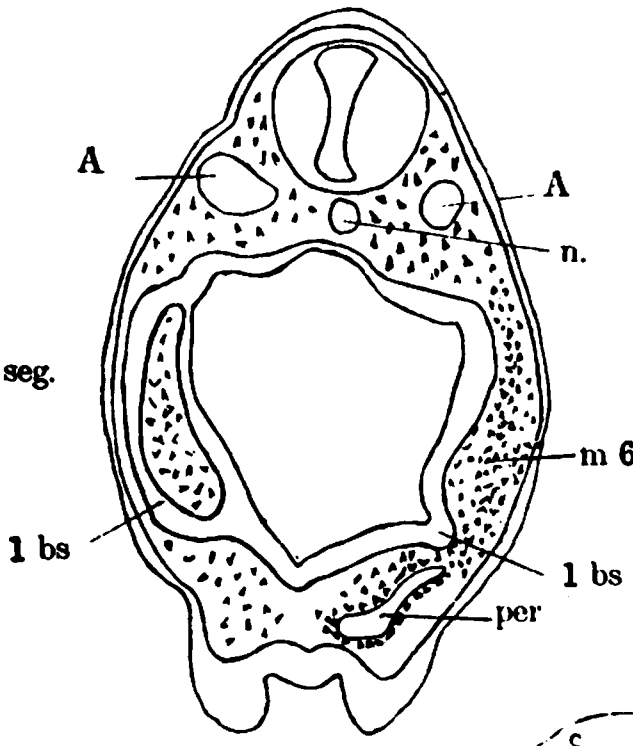

Fig. 16.

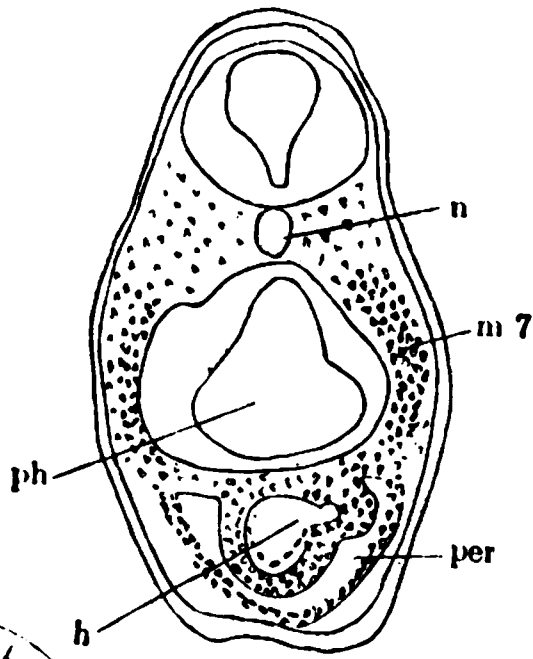

Fig. 18.

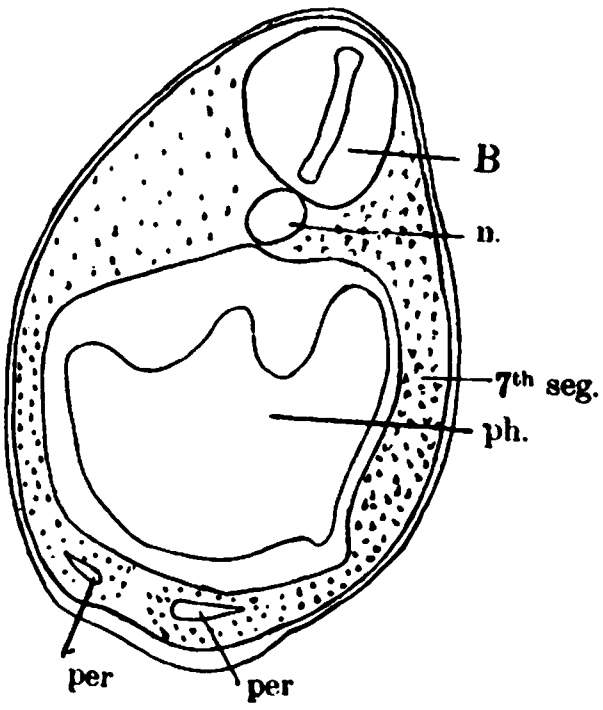

Fig. 17.

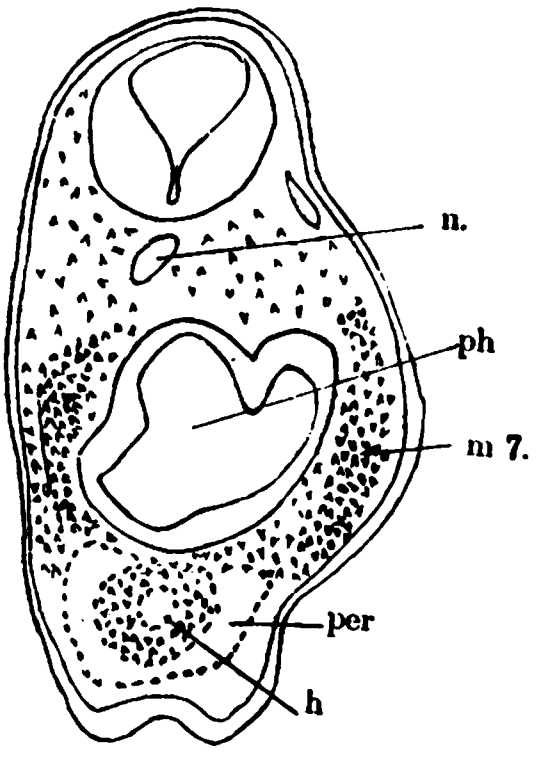

Fig. 19.

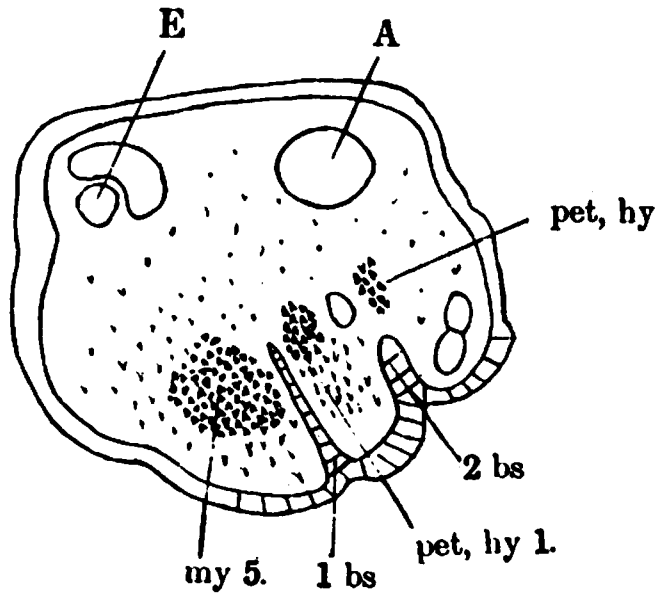

Fig. 20.

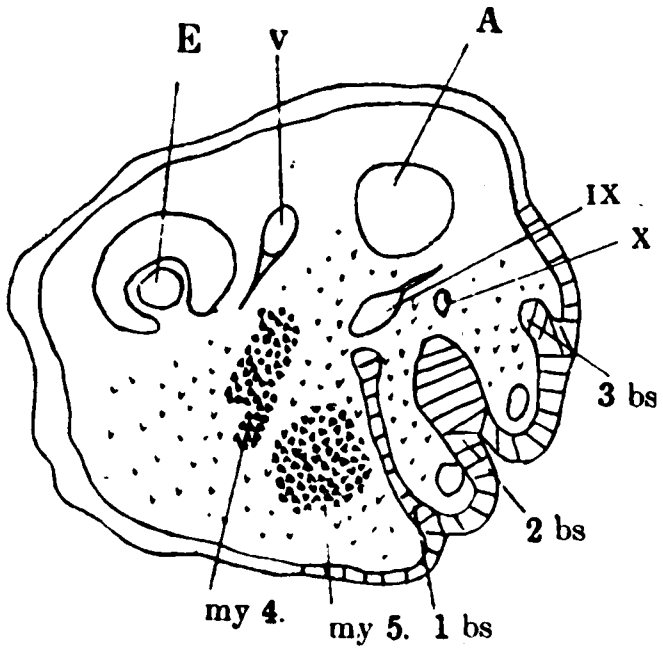

Fig. 21.

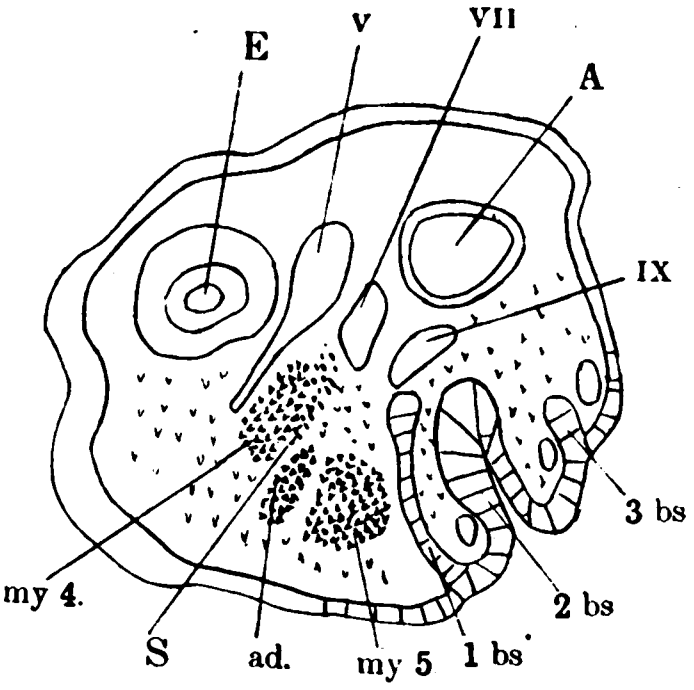

Fig. 22.

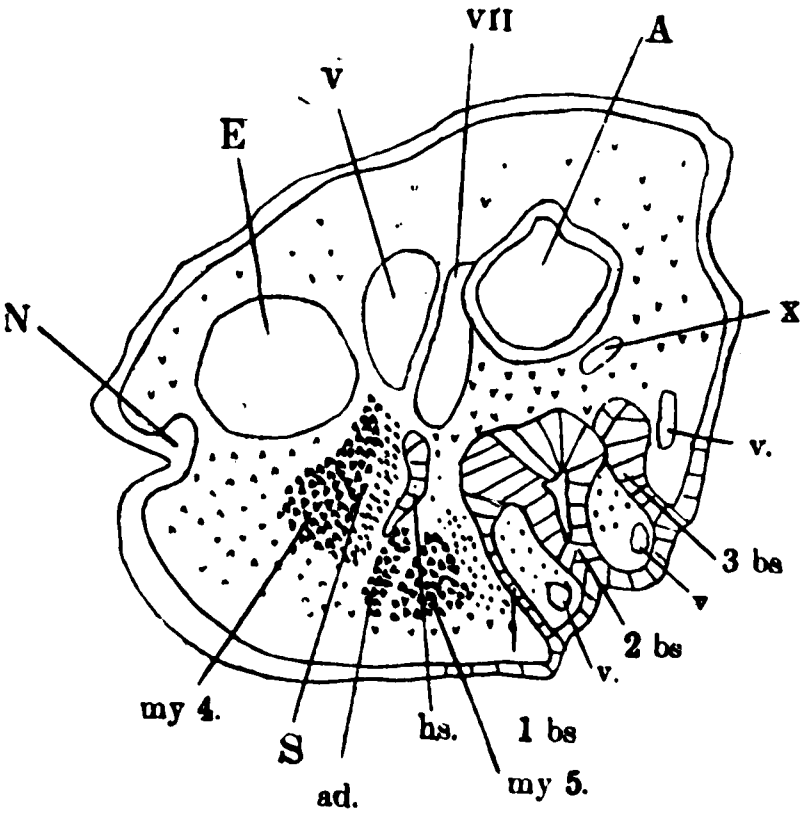

Fig. 23.

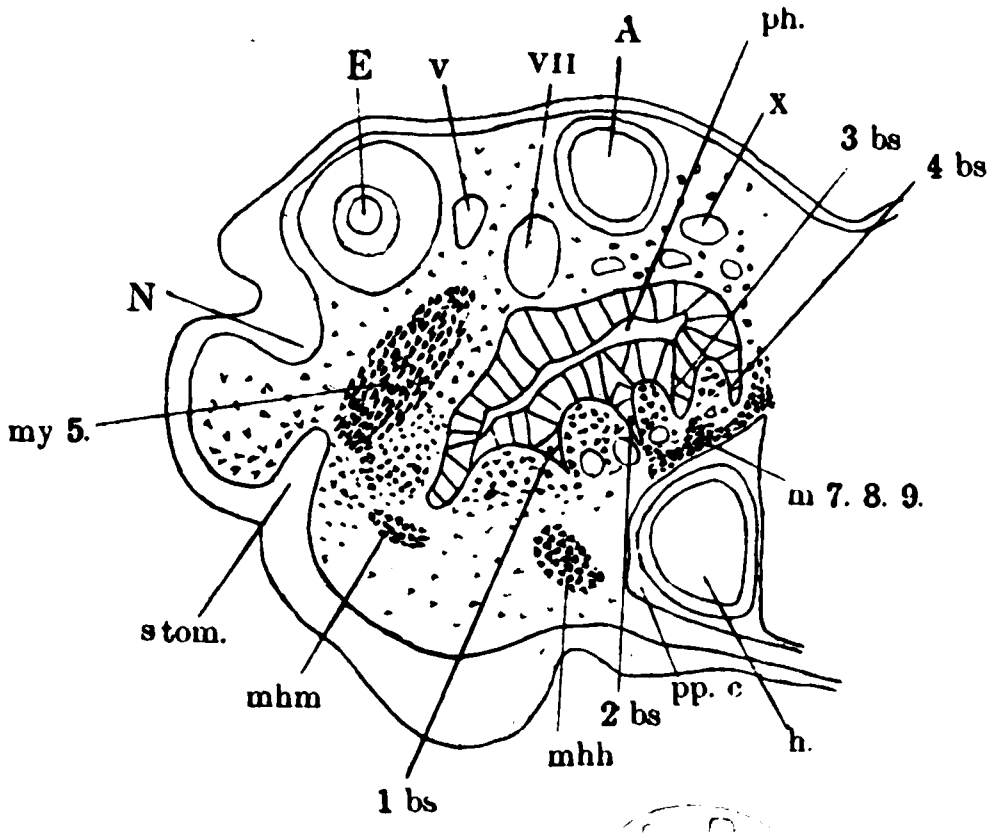

Fig. 24.

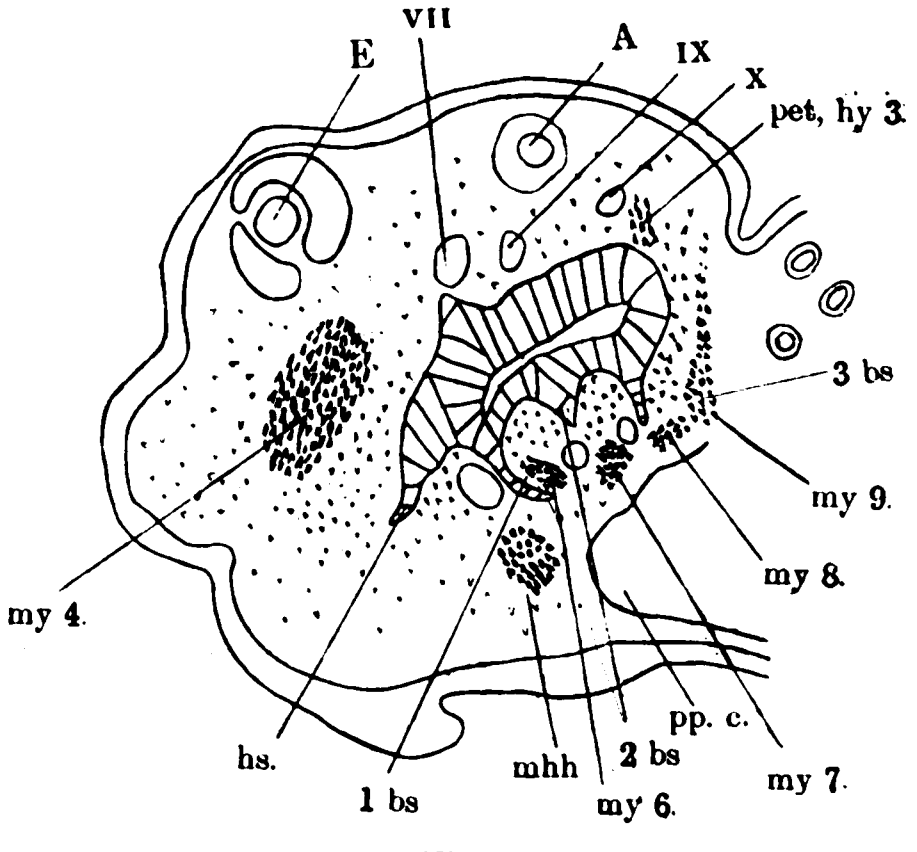

Fig. 25.

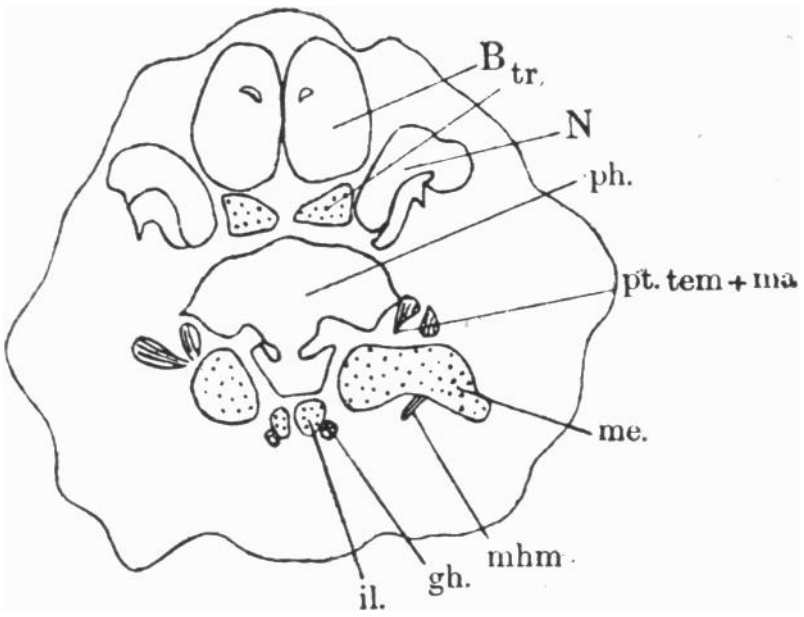

Fig. 26.

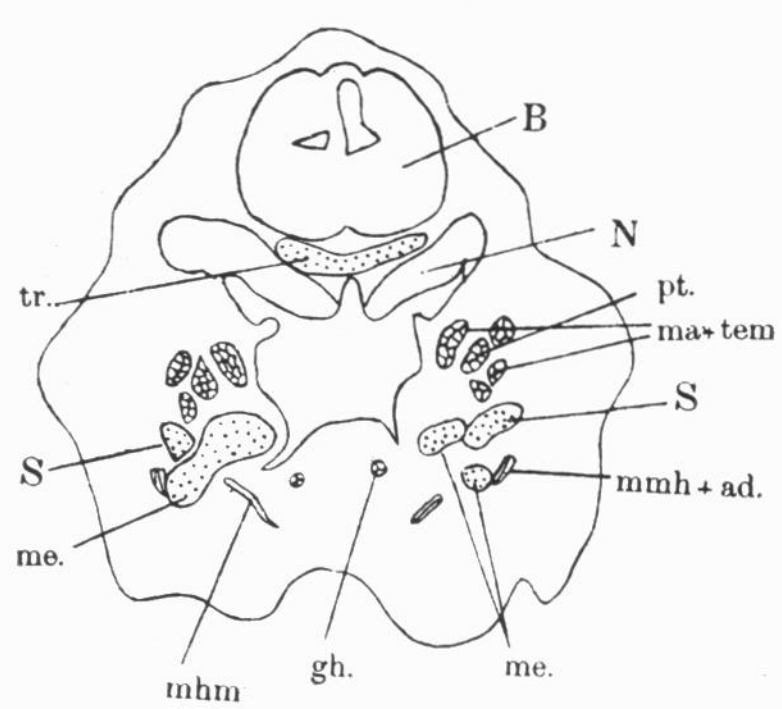

Fig. 27.

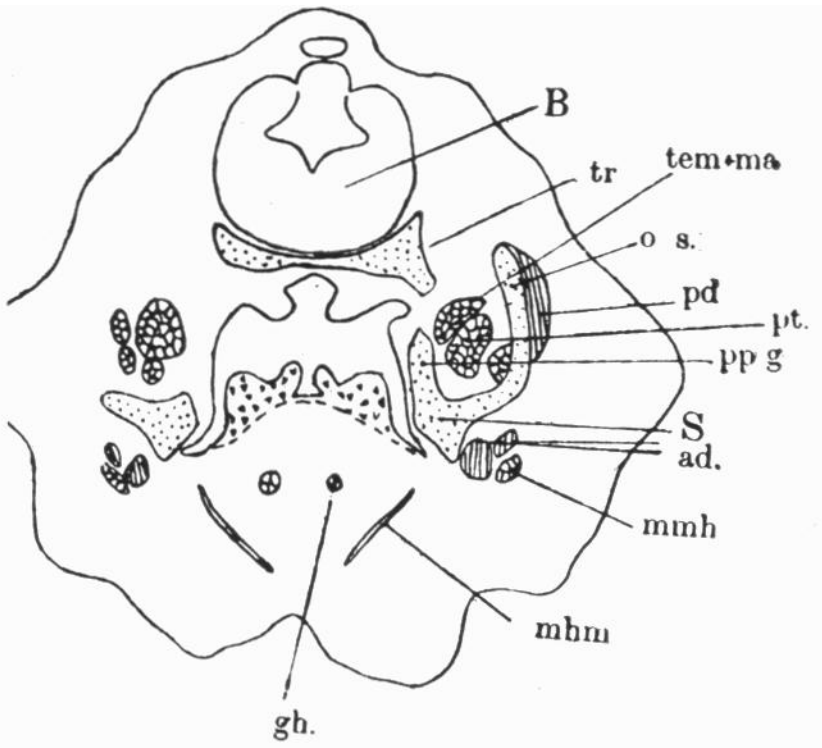

Fig. 28.

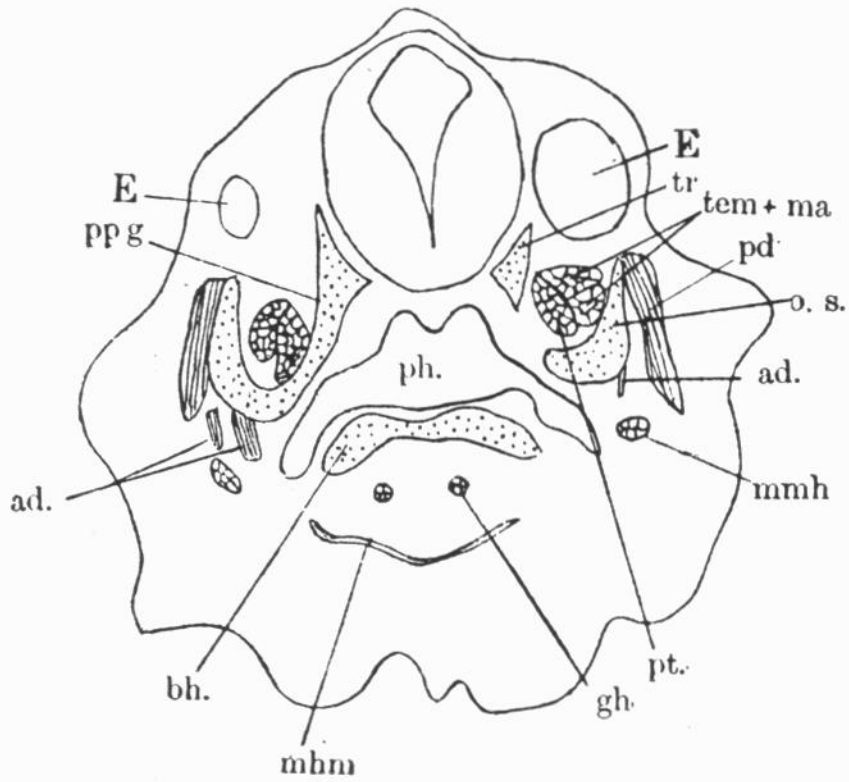

Fig. 29.

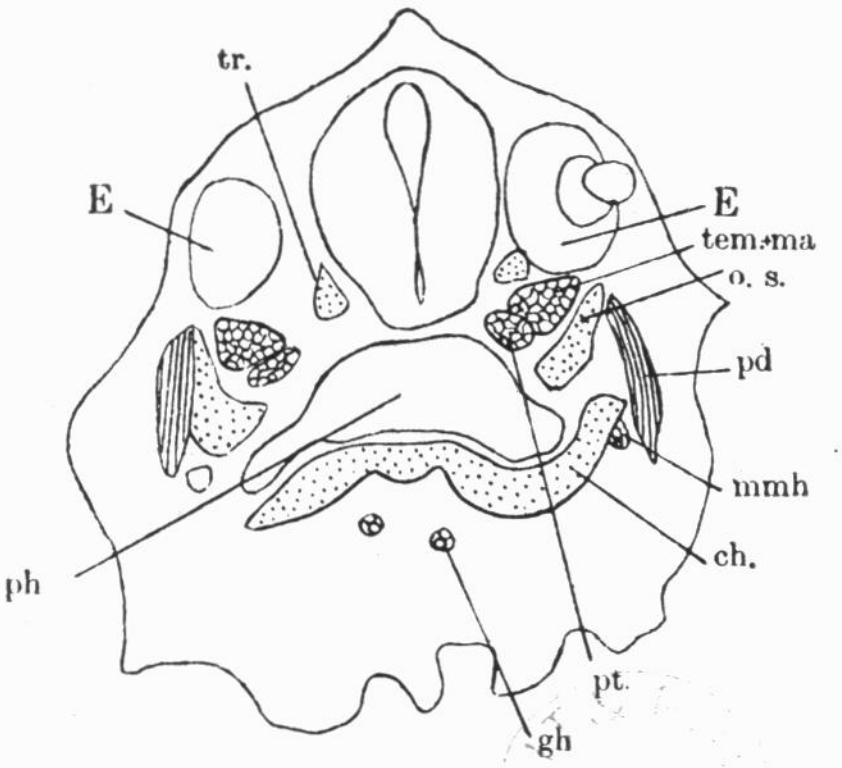

Fig. 30.

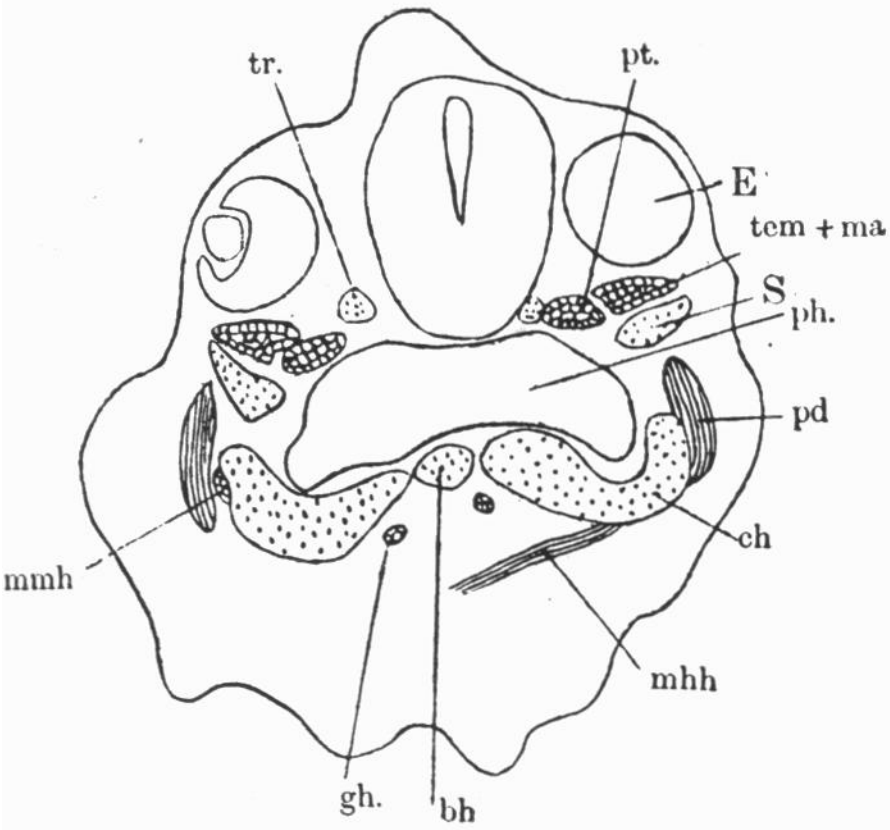

Fig. 31.

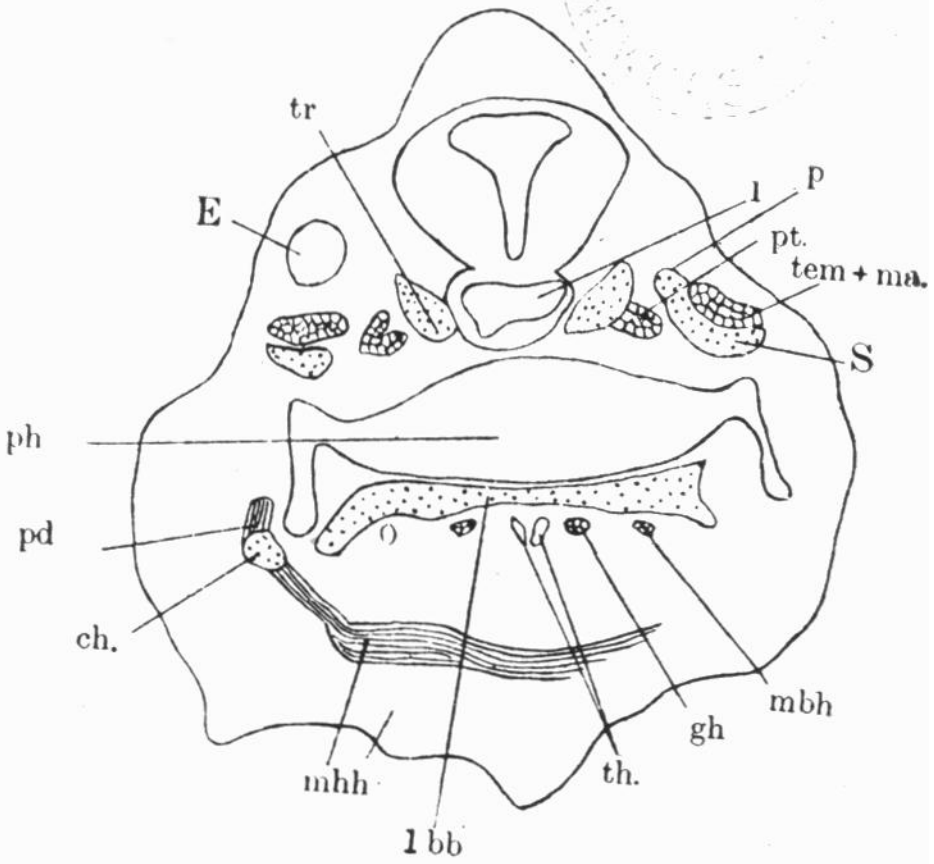

Fig. 32.

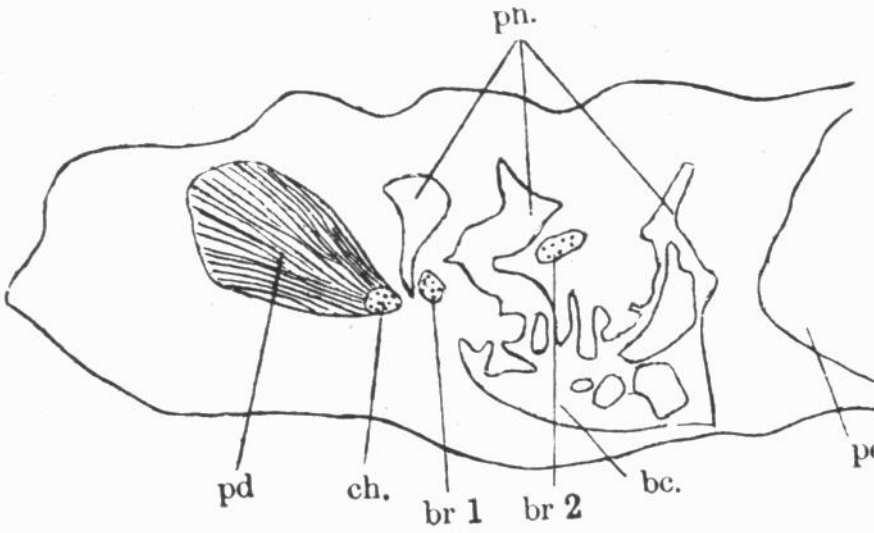

Fig. 33.

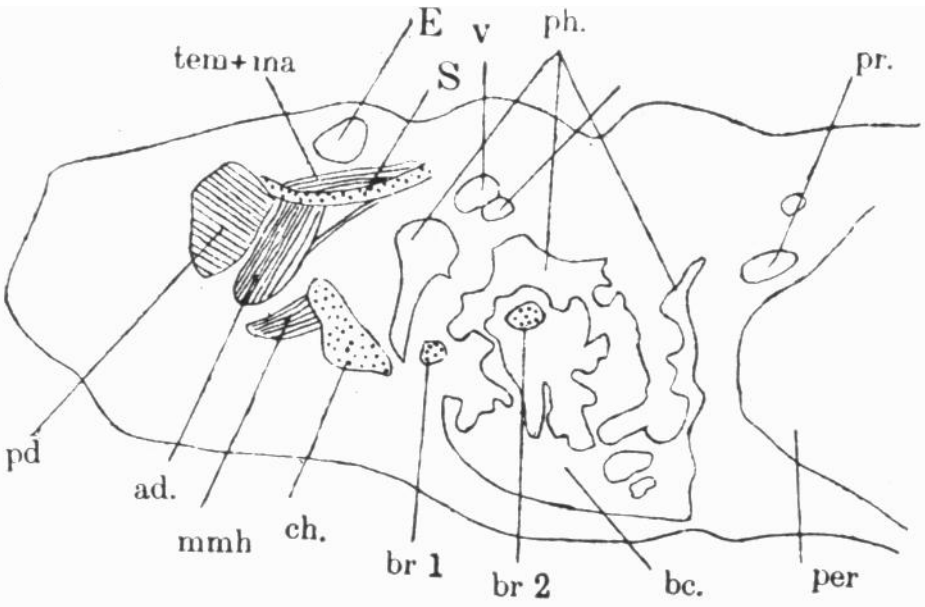

Fig. 34.

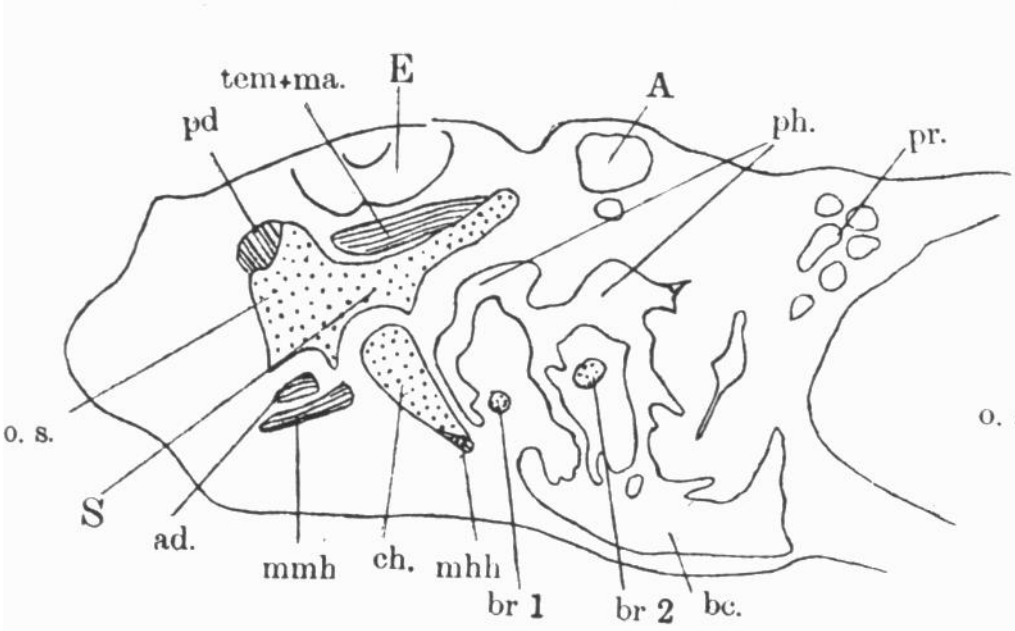

Fig. 35.

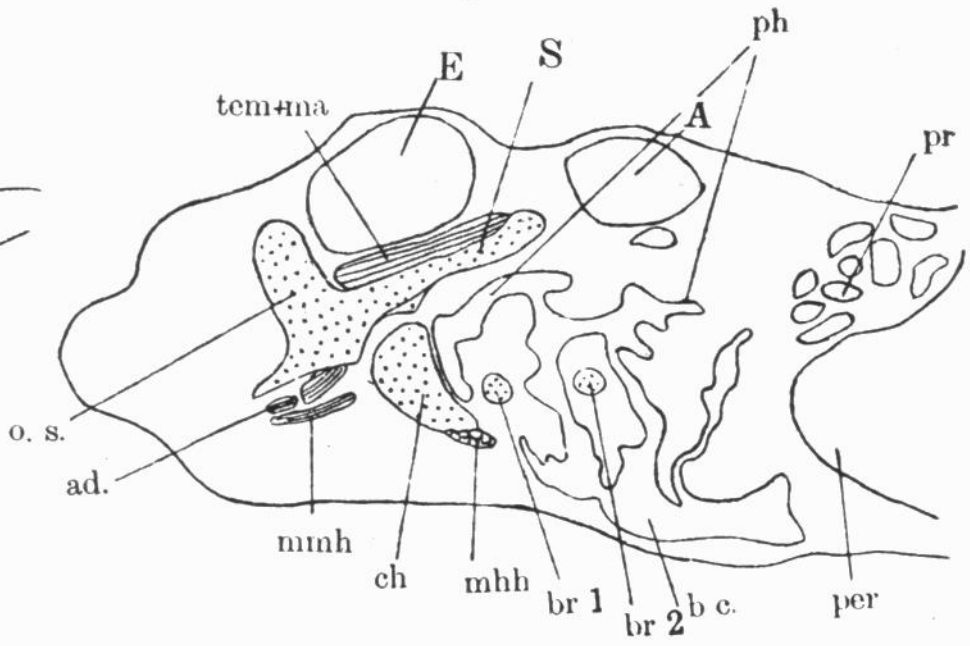

Fig. 36.

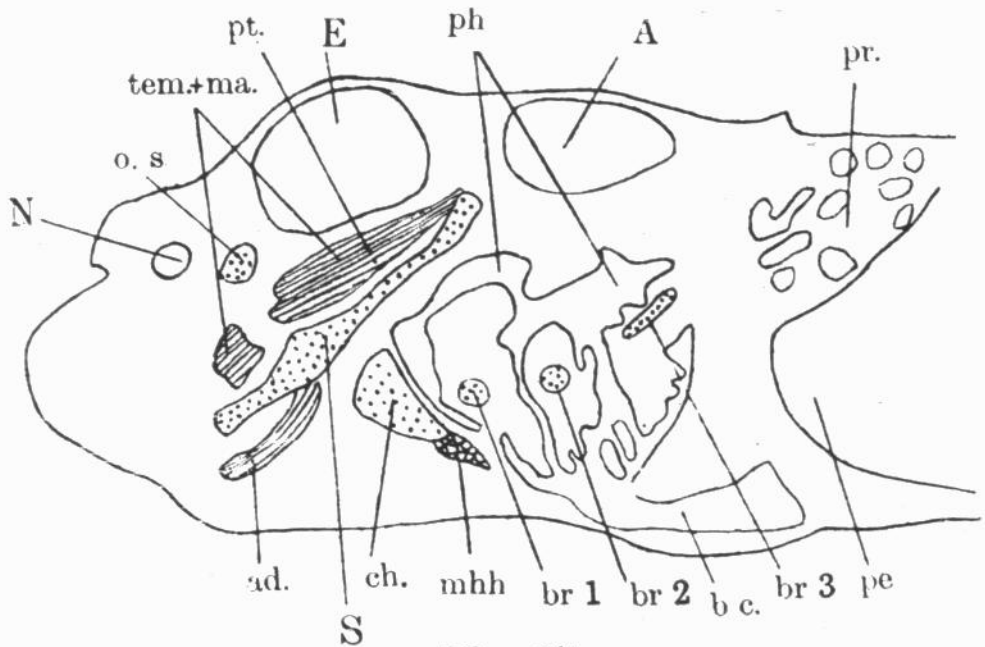

Fig. 37.

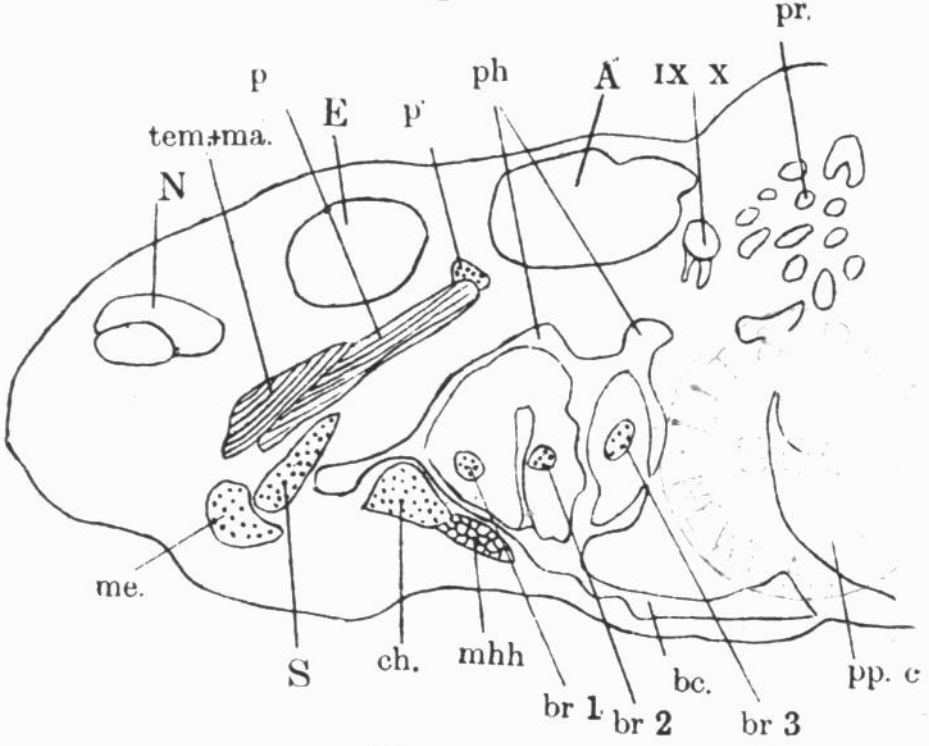

Fig. 38.

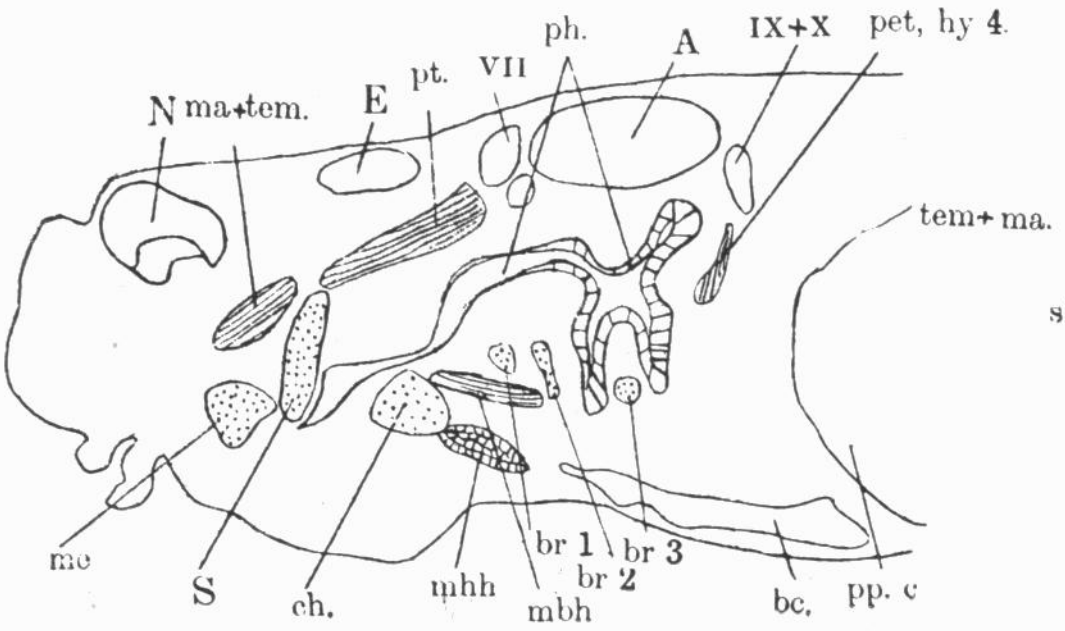

Fig. 39.

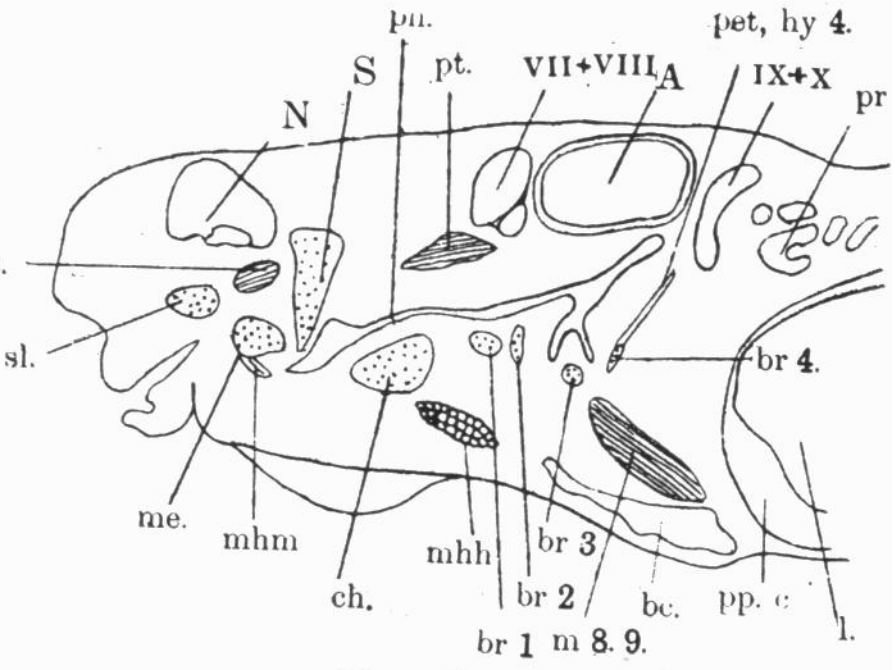

Fig. 40.

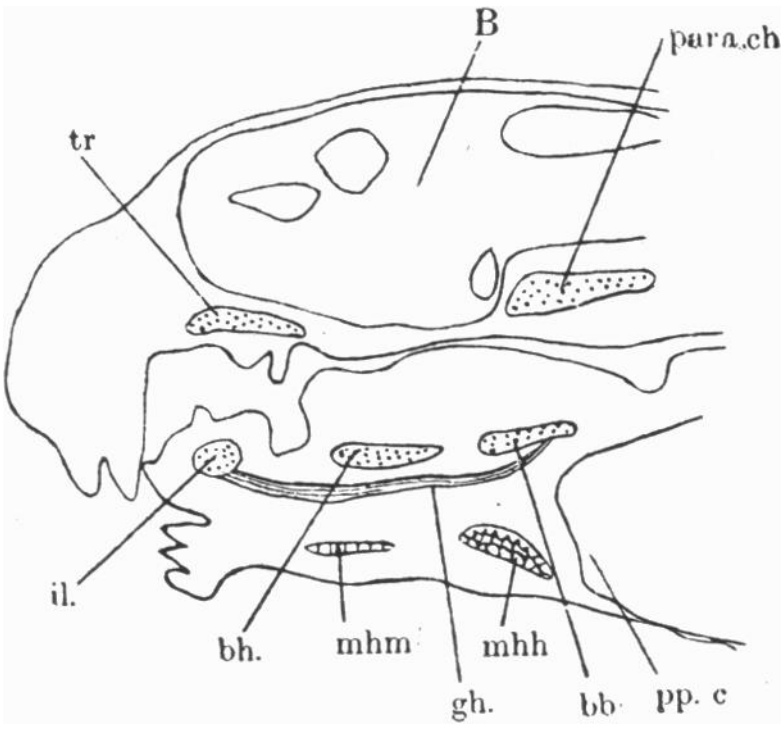

Fig. 41.

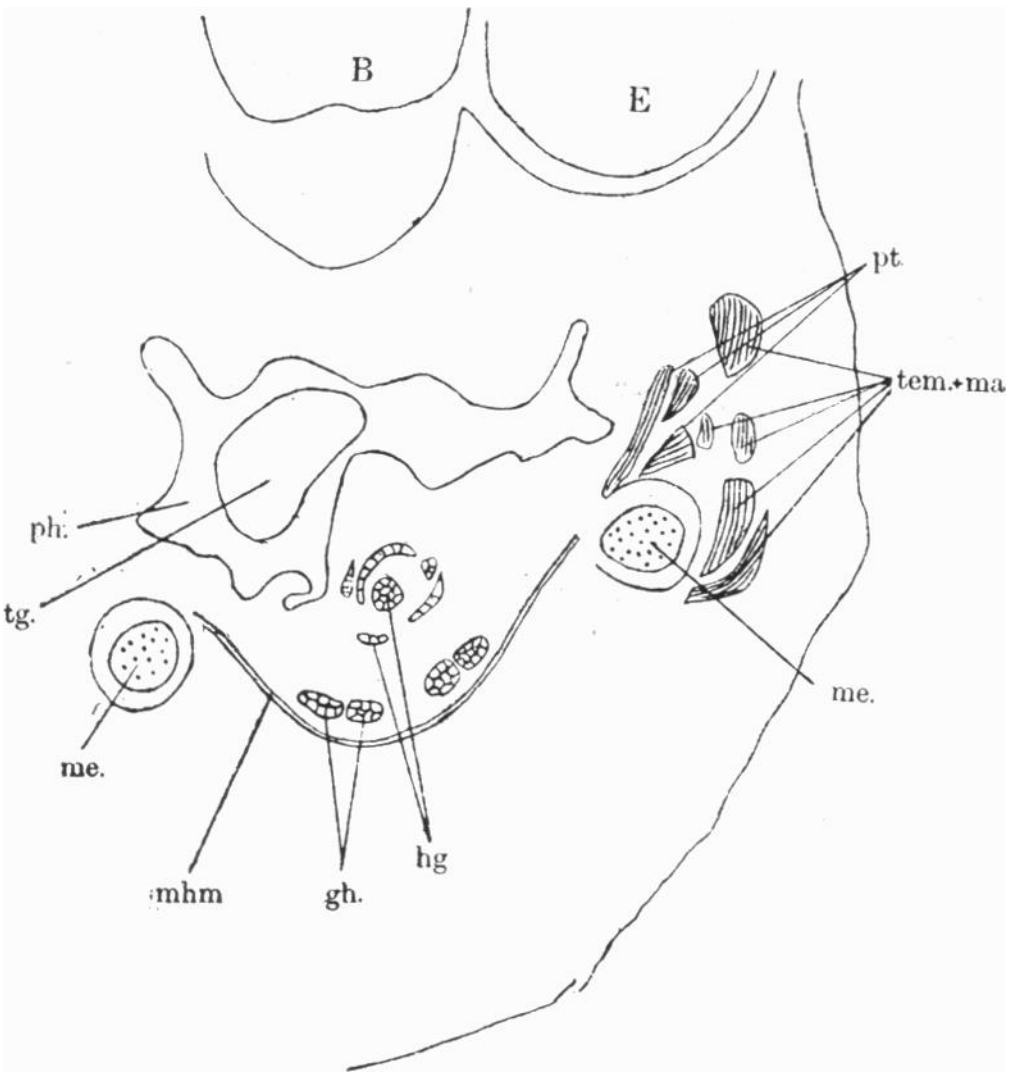

Fig. 42.

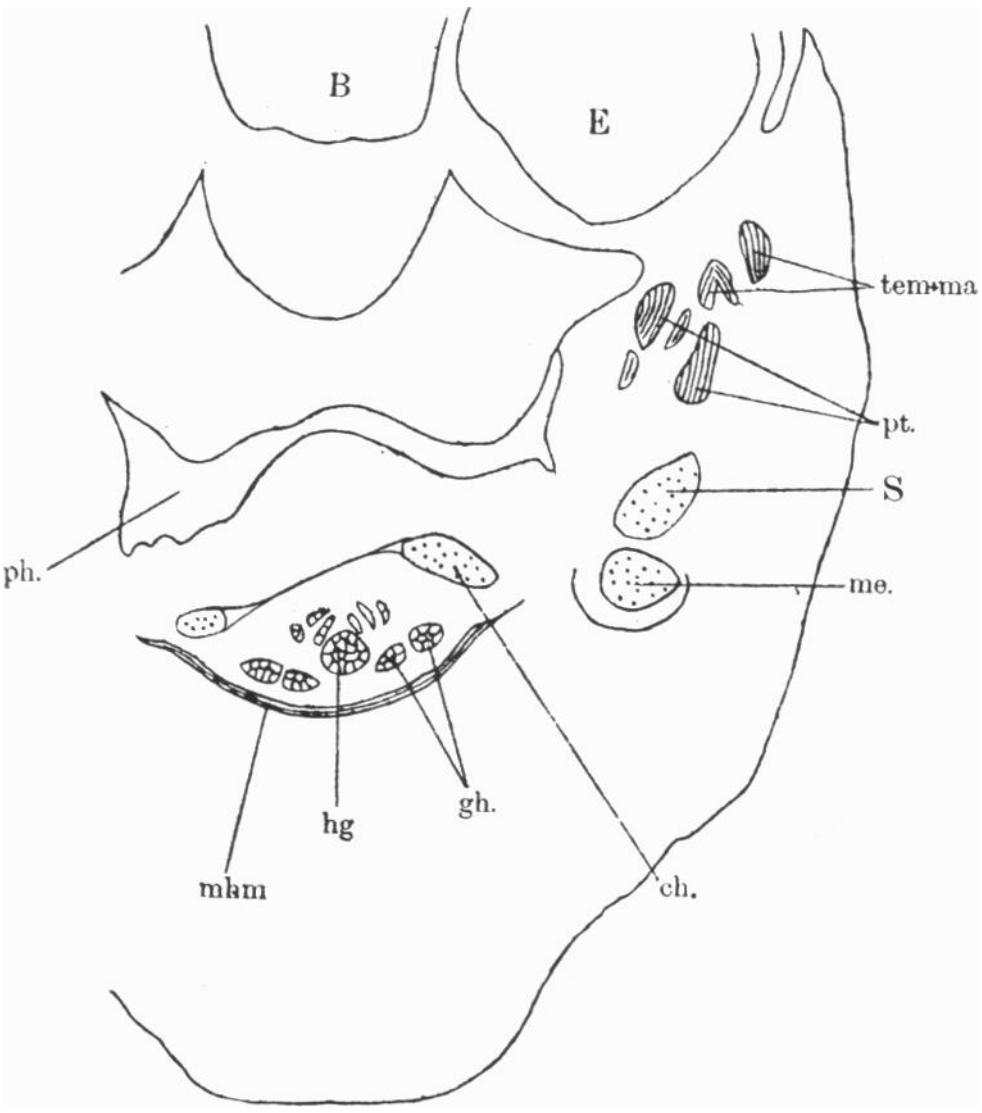

Fig. 43.

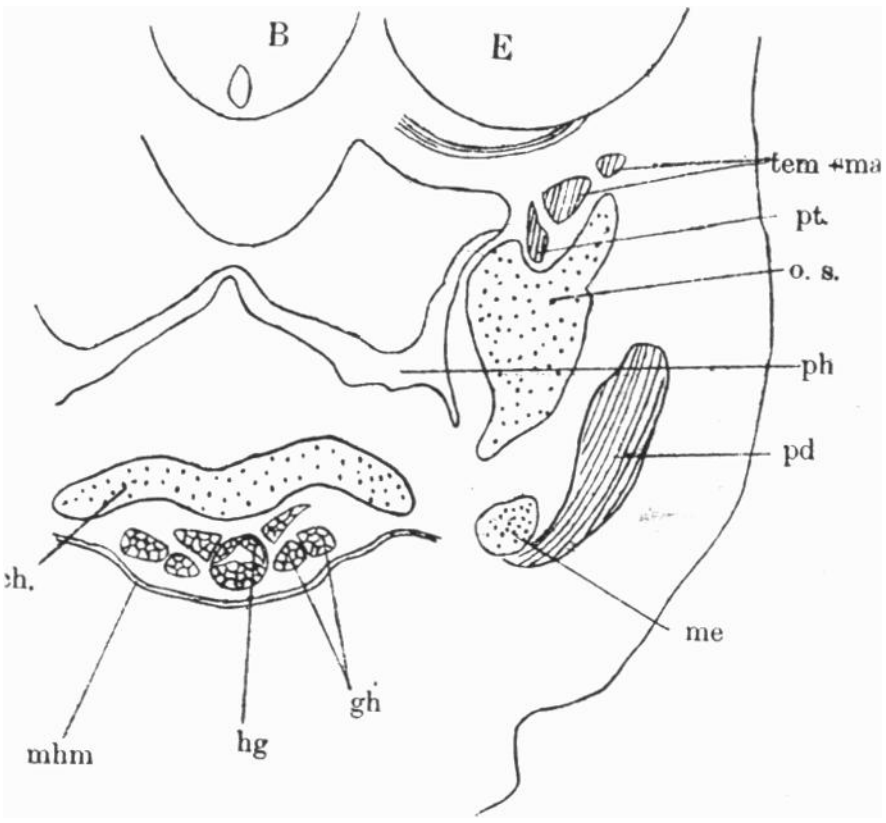

Fig. 44.

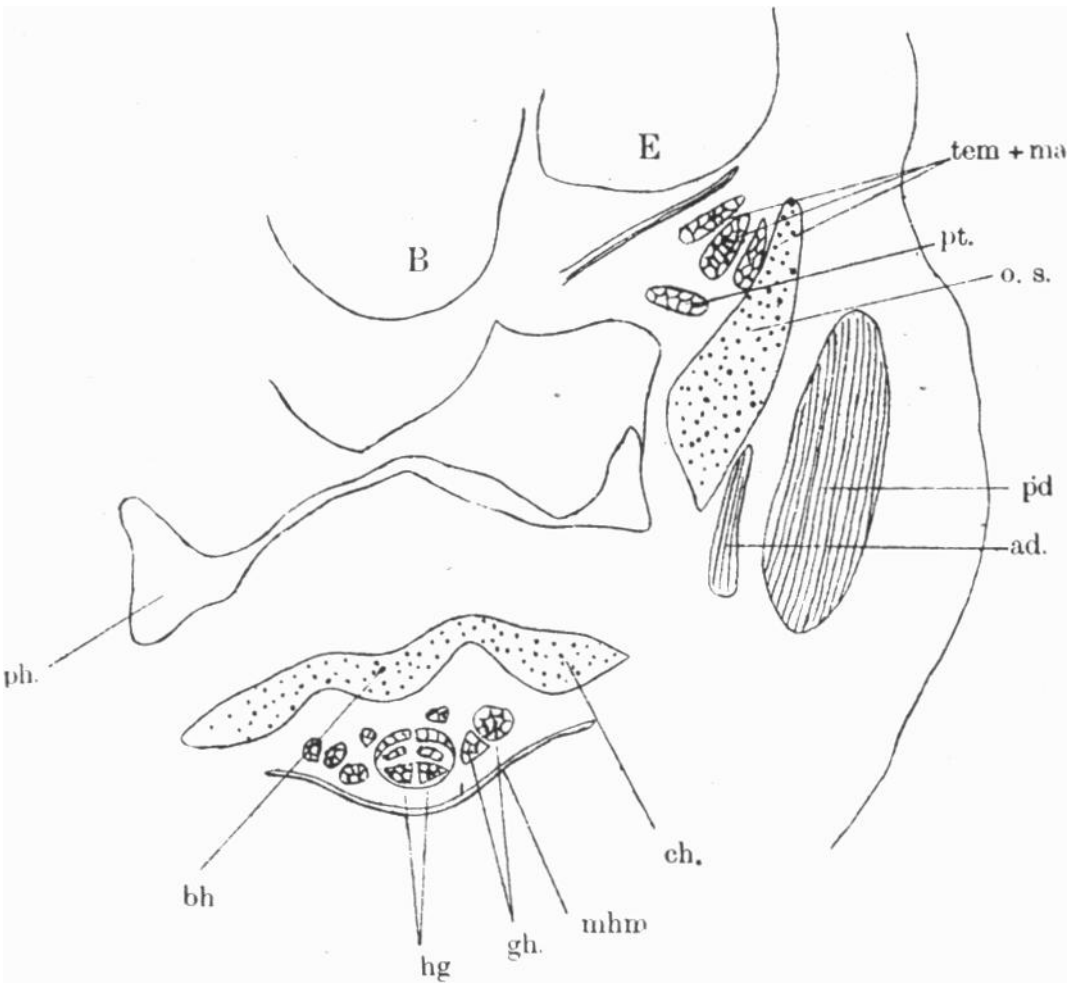

Fig. 45.

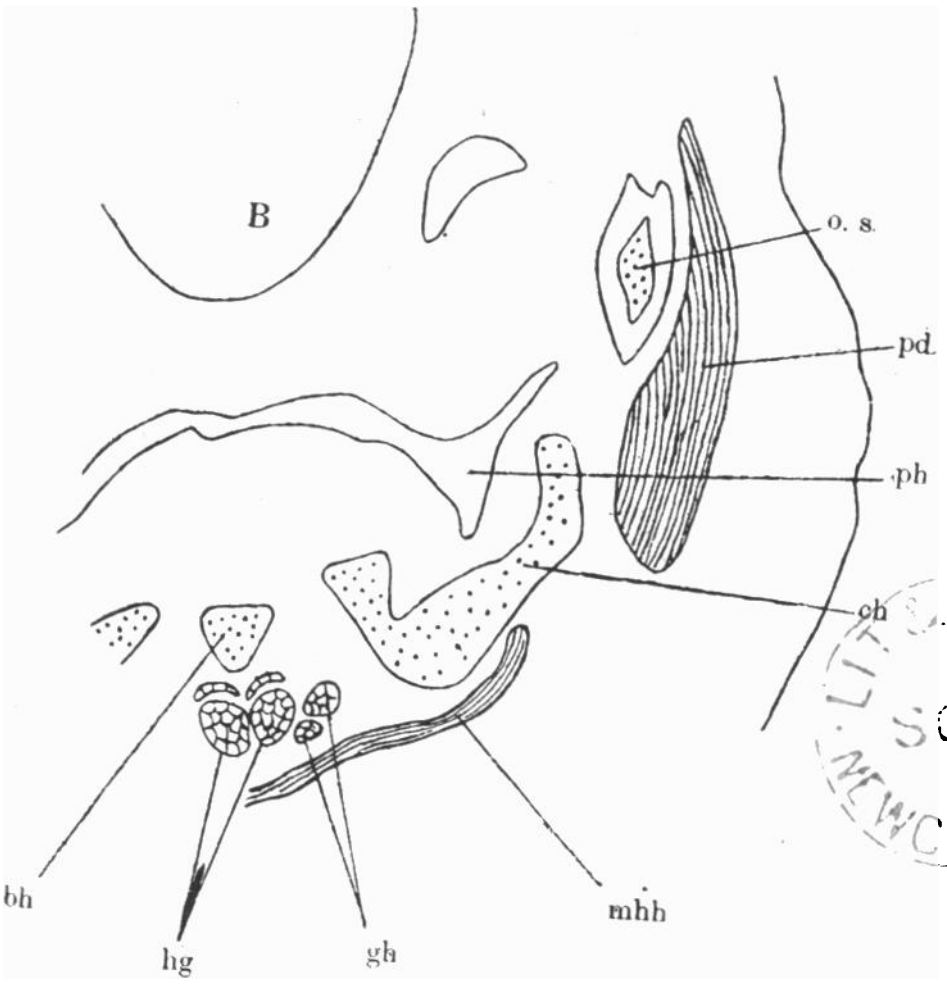

Fig. 46.

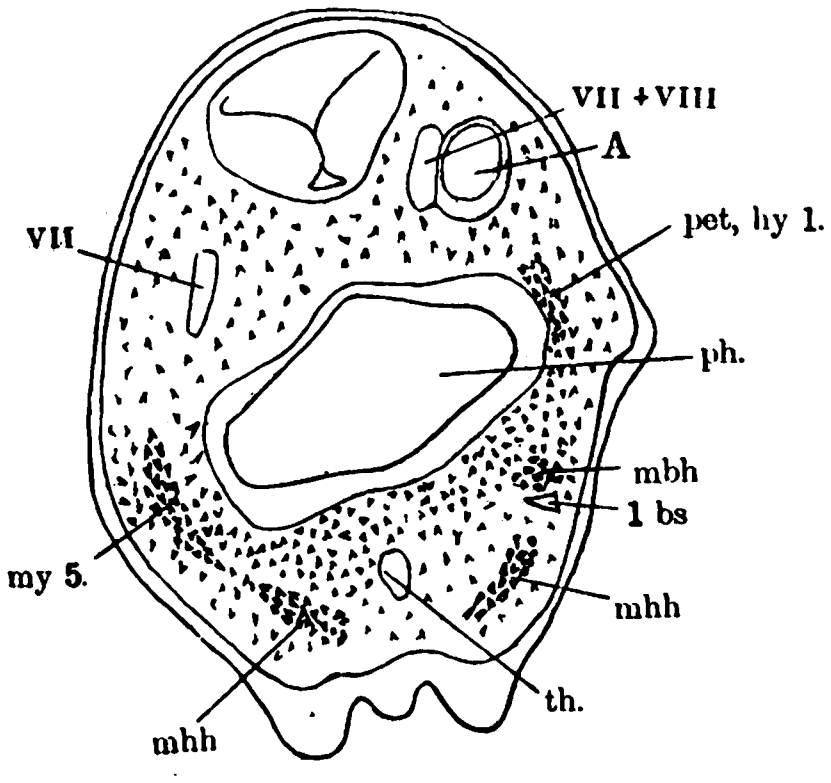

Fig. 49.

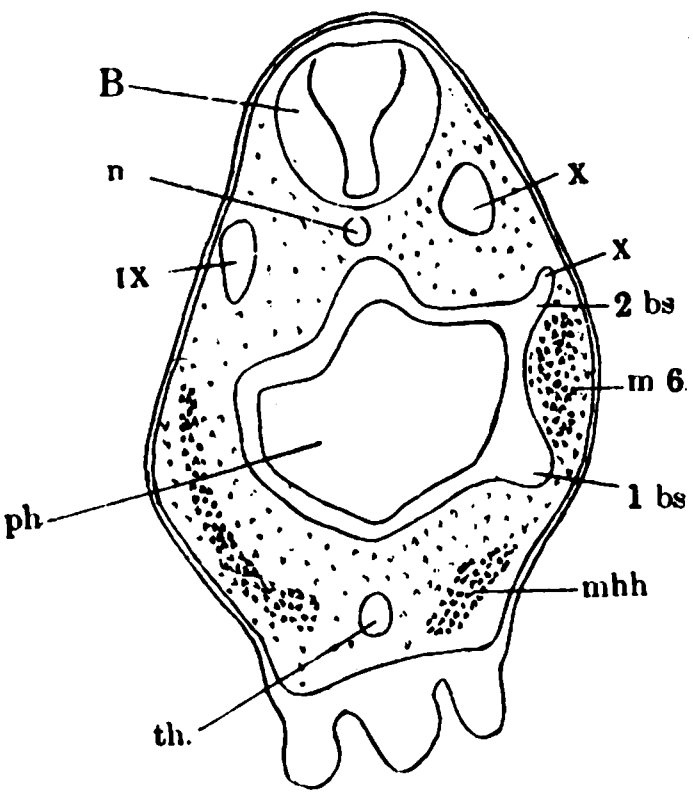

Fig. 47.

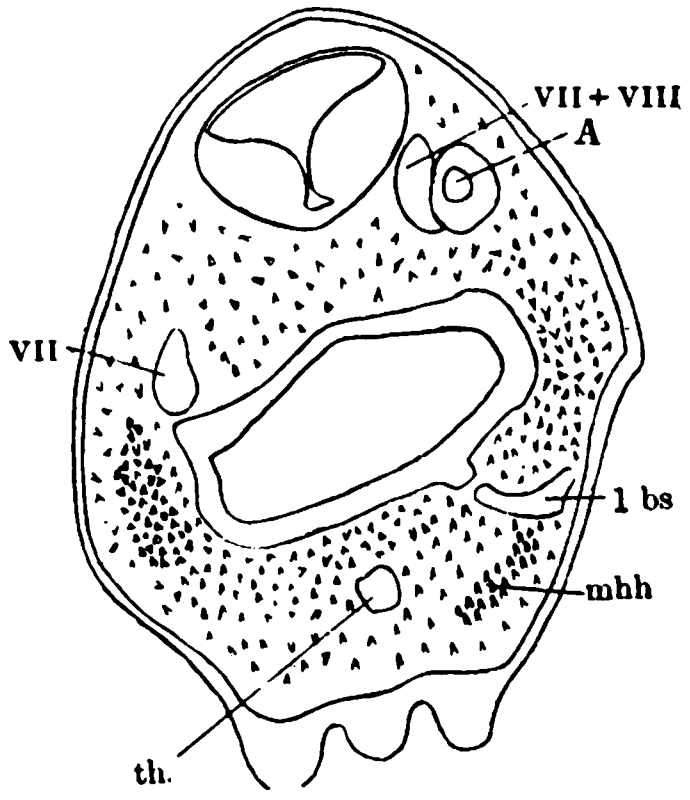

Fig. 48.

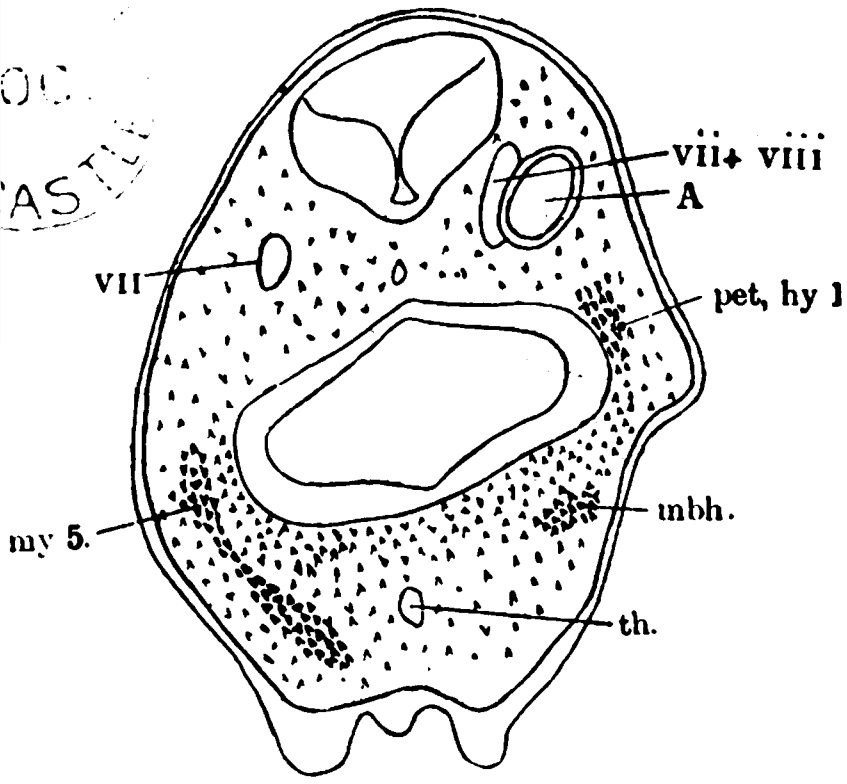

Fig. 50.

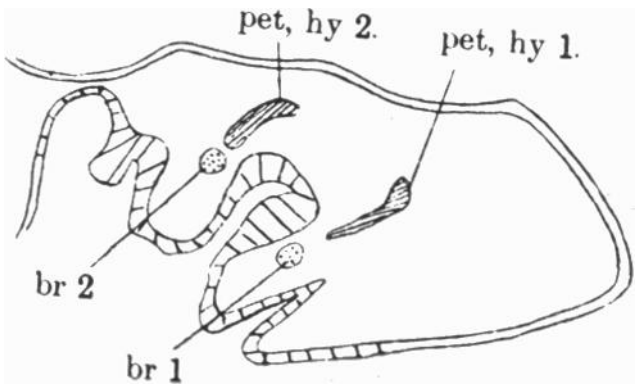

Fig. 51.

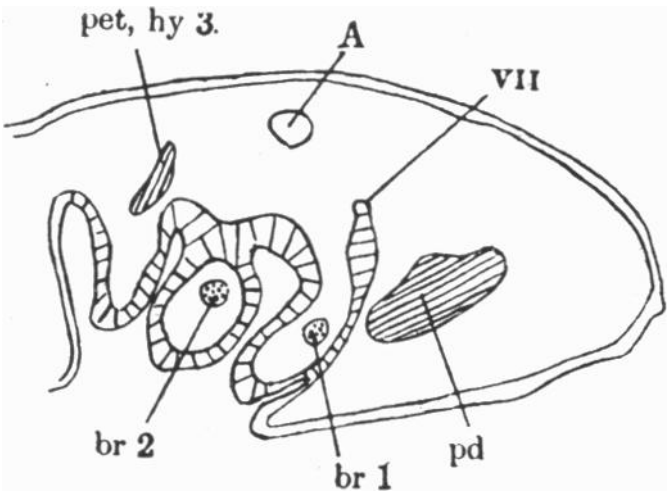

Fig. 52.

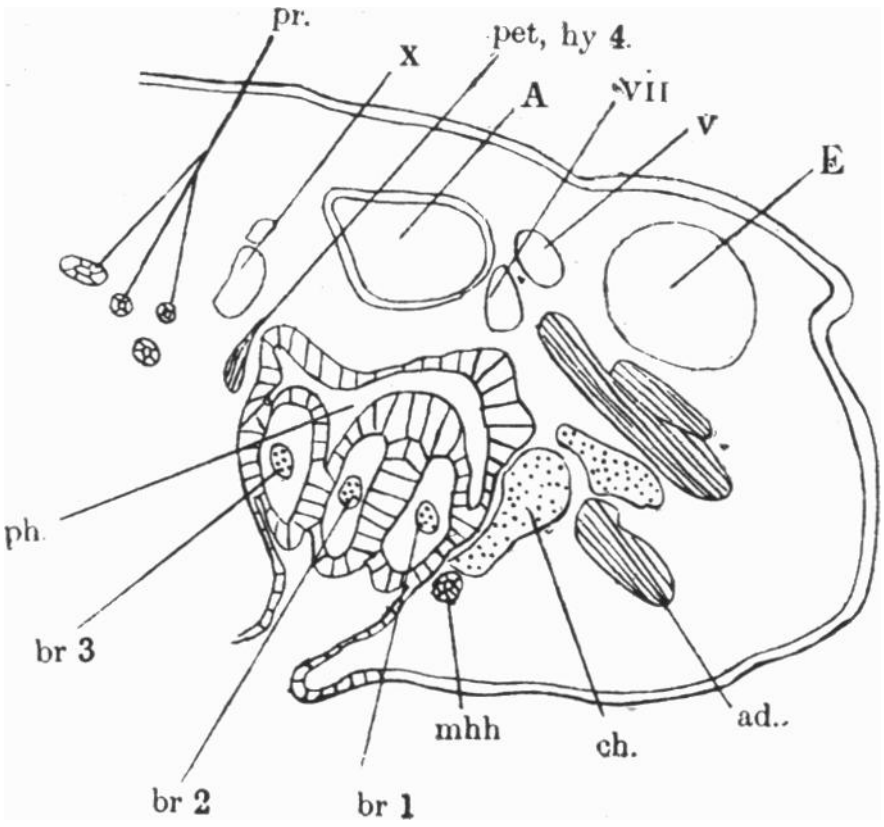

Fig. 53.

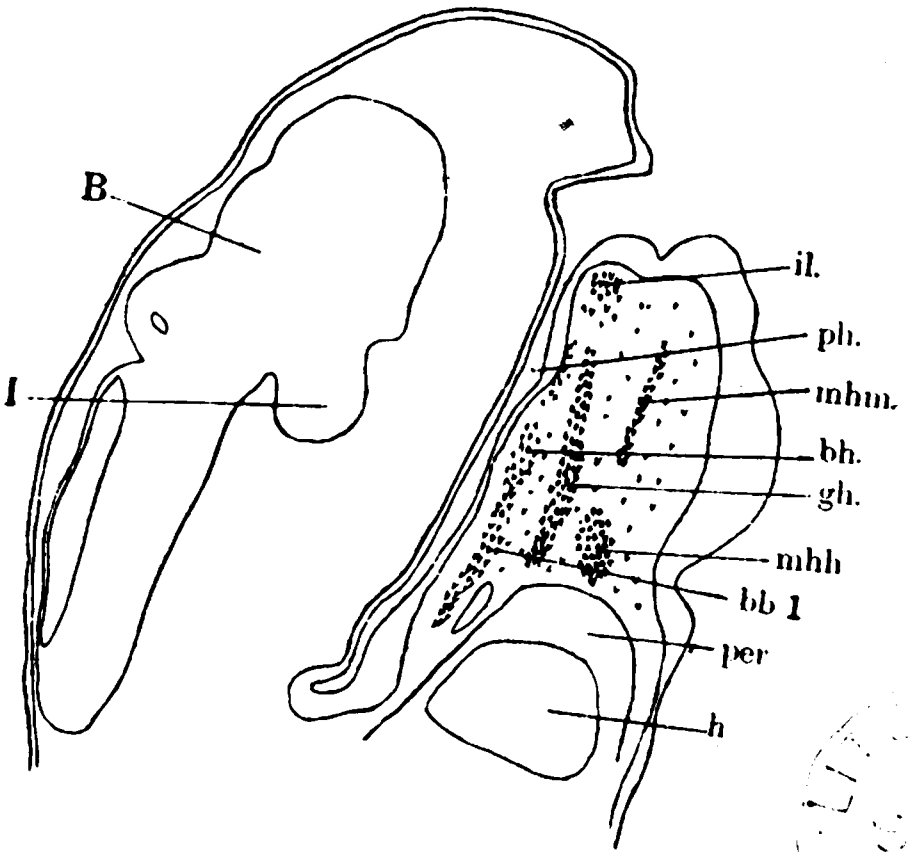

Fig. 54.

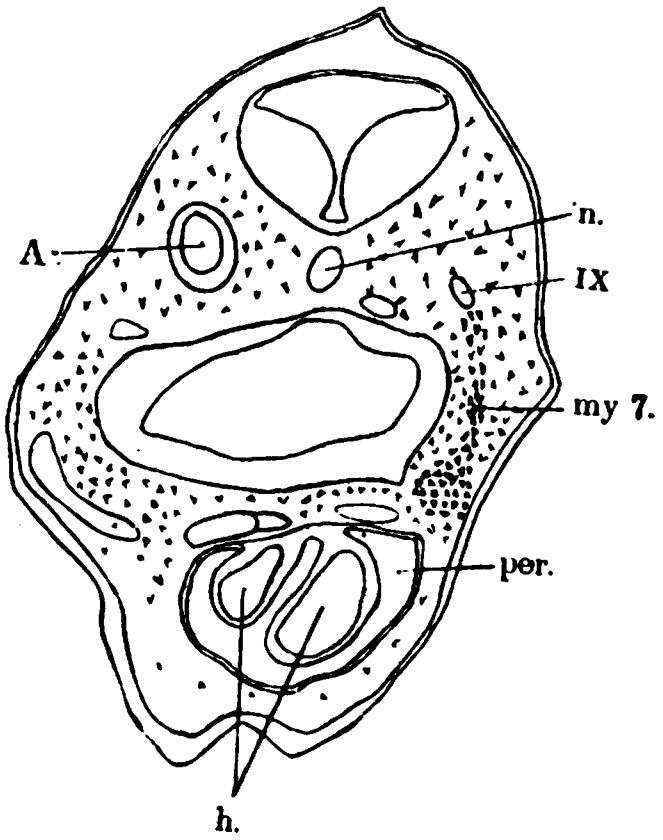

Fig. 55.

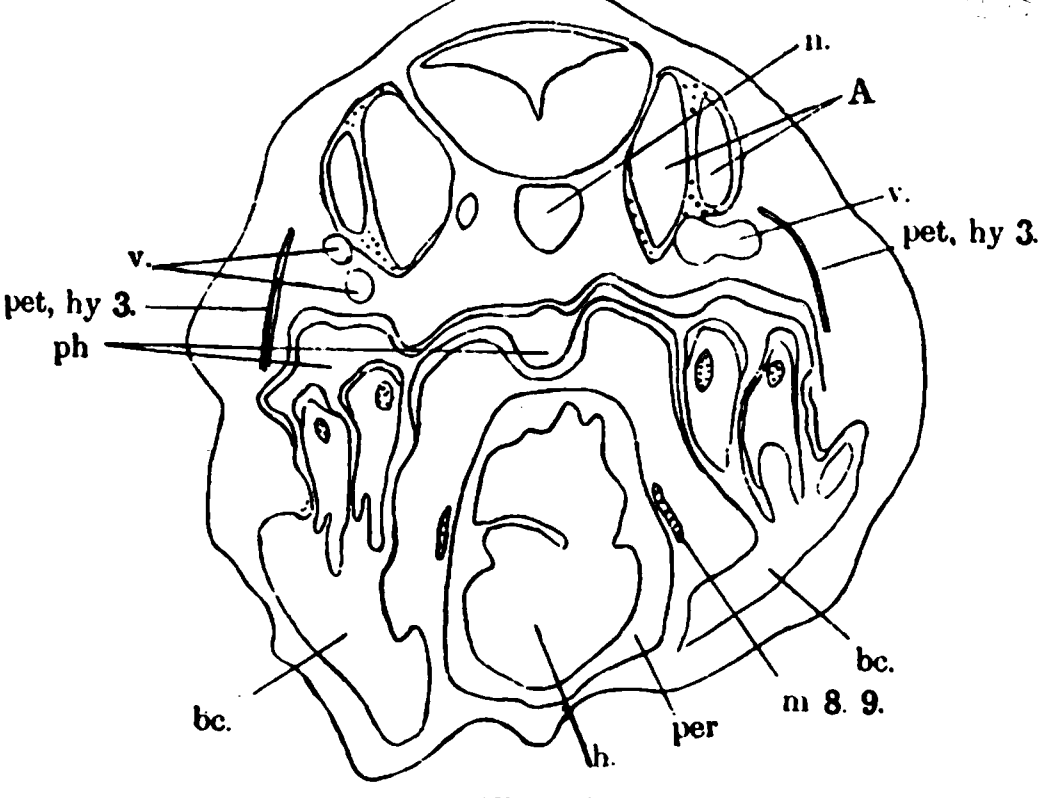

Fig. 57.

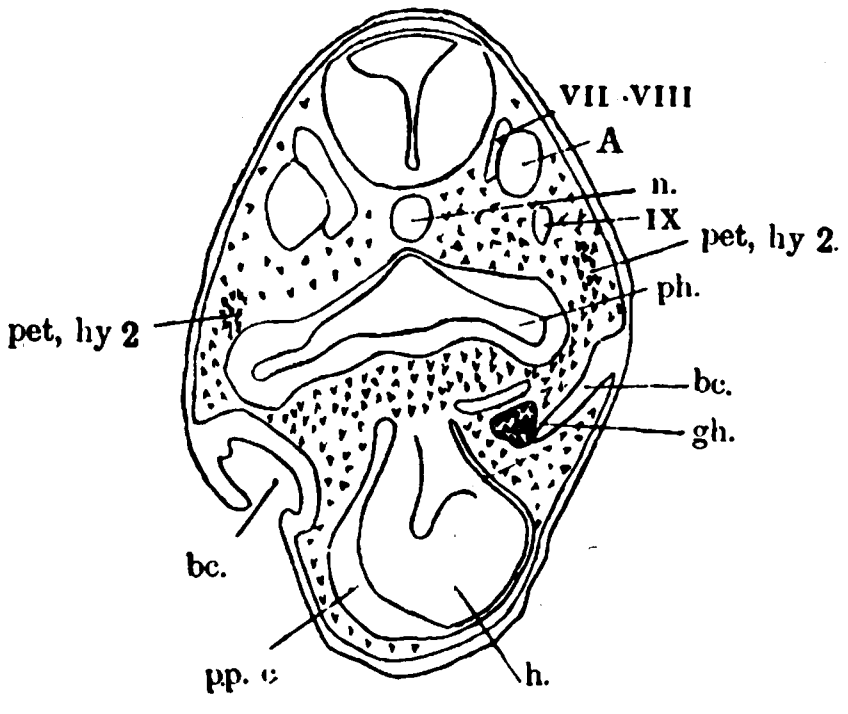

Fig. 56.

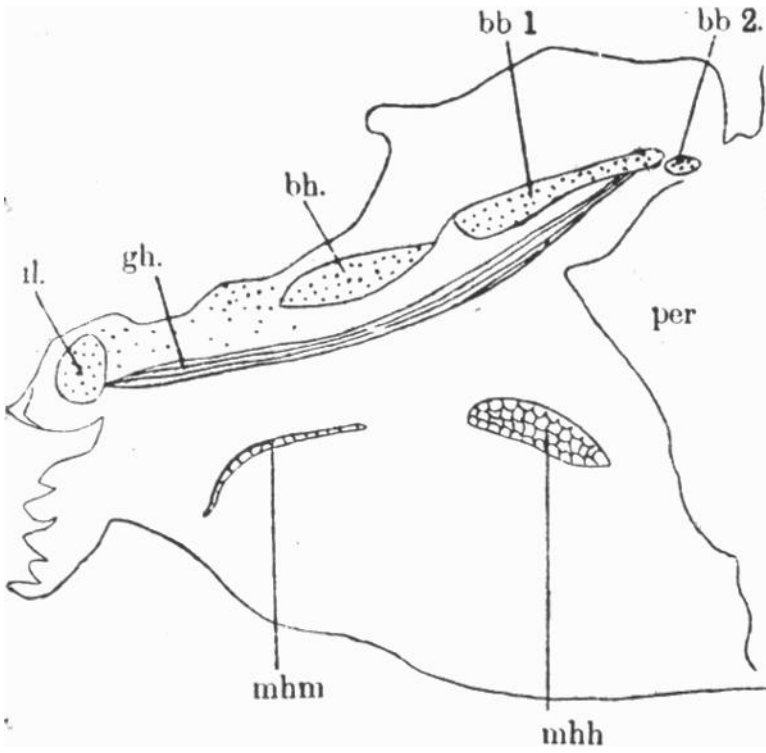

Fig. 58.

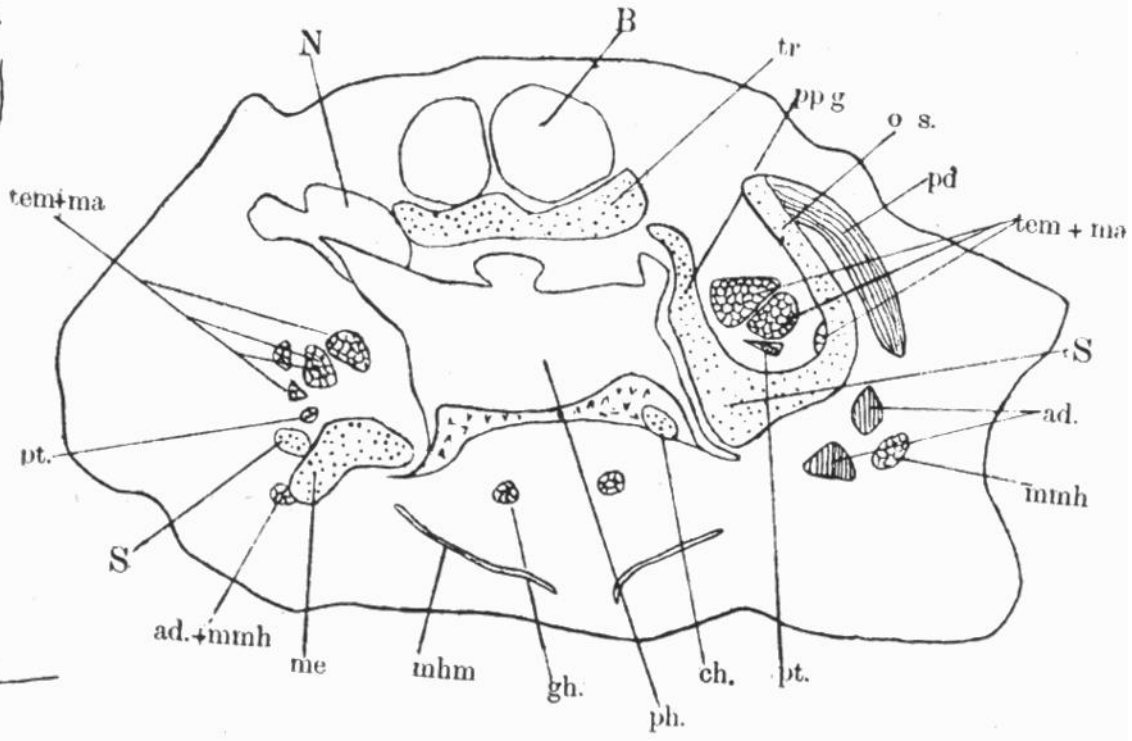

Fig. 59.

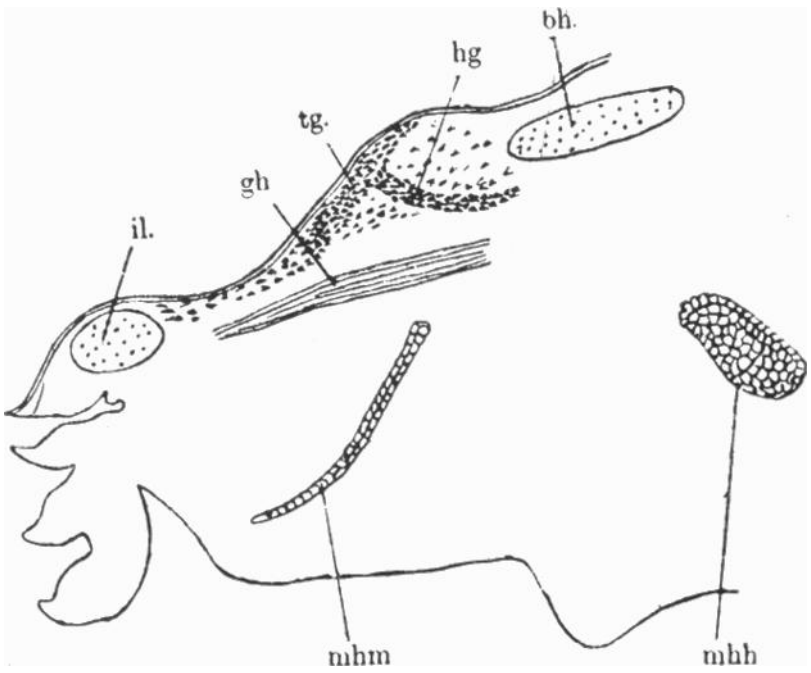

Fig. 60.

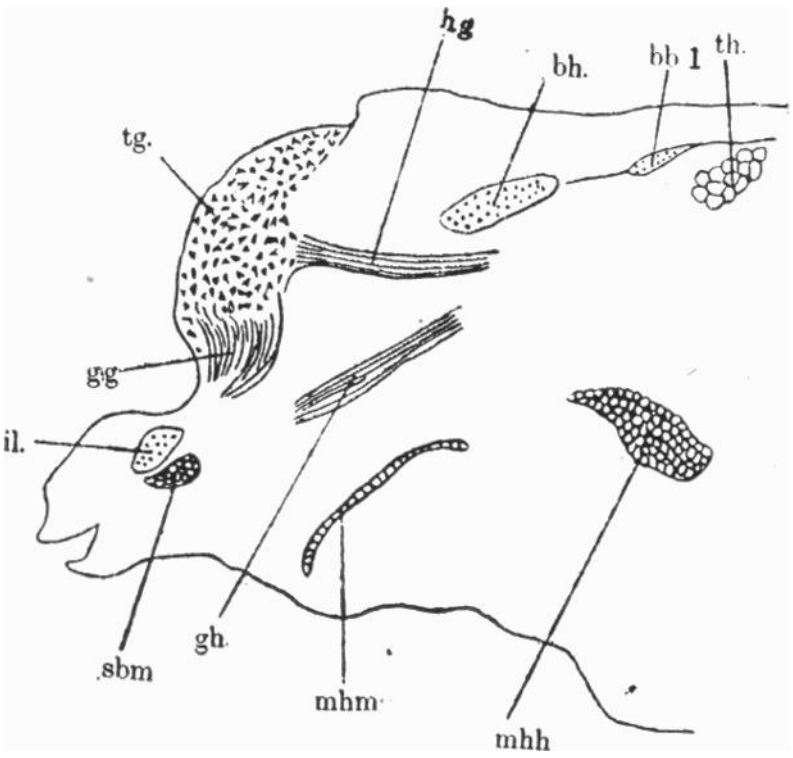

Fig. 62.

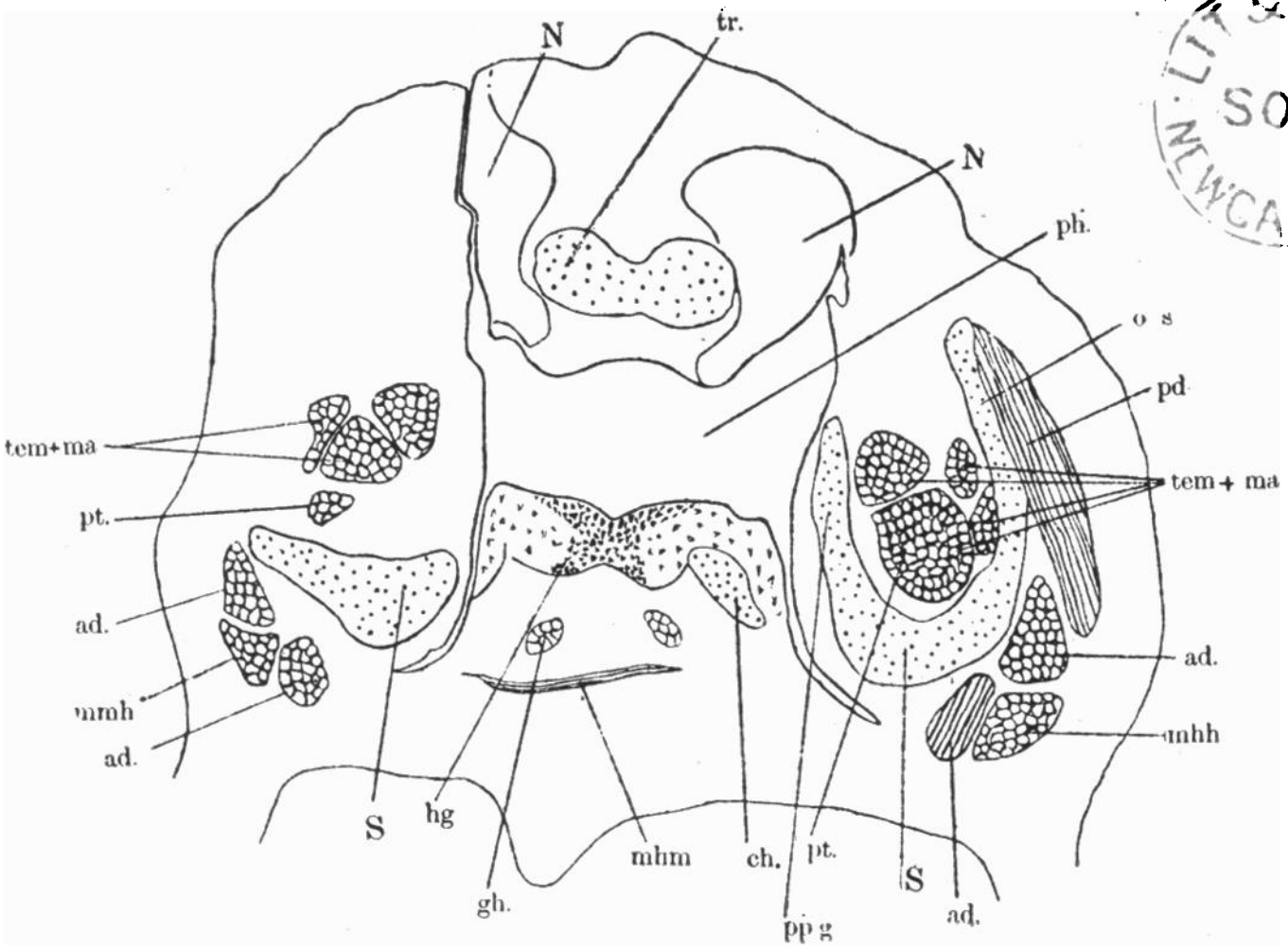

Fig. 61.

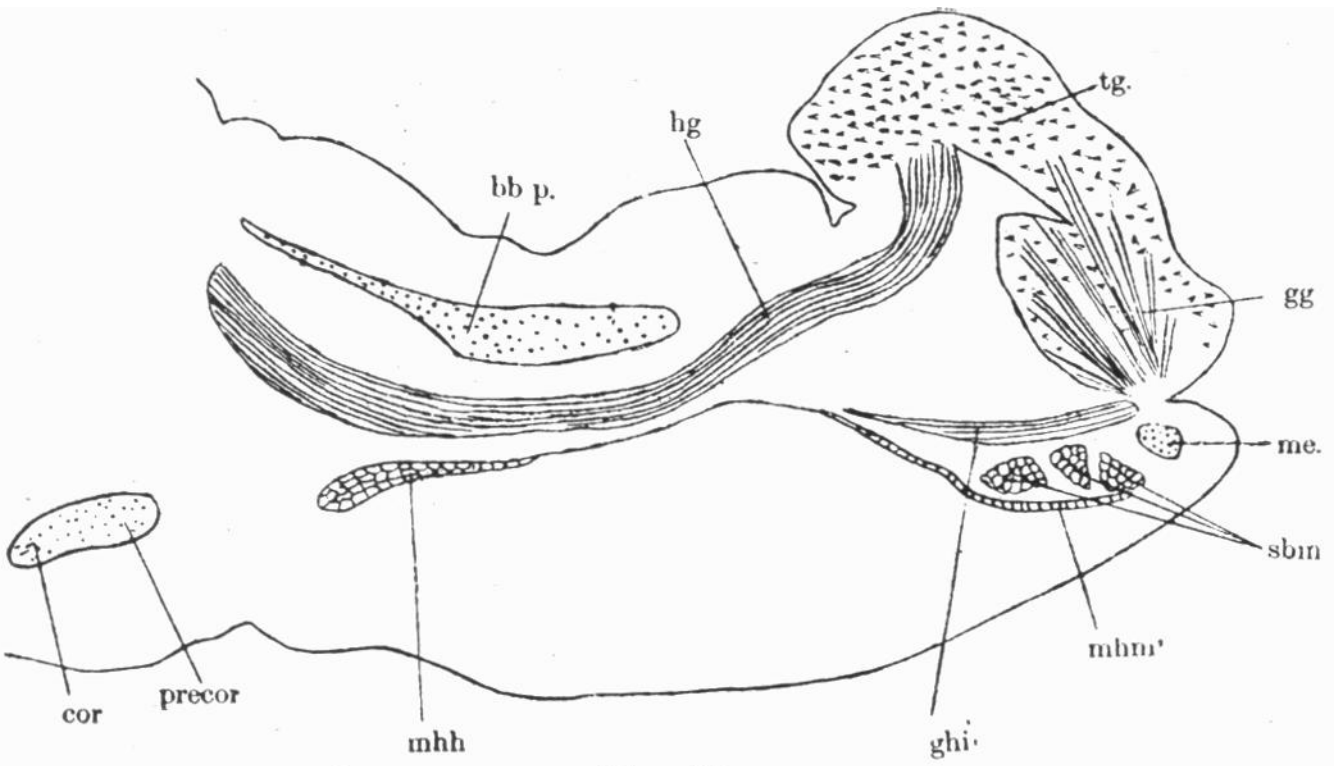

Fig. 63.

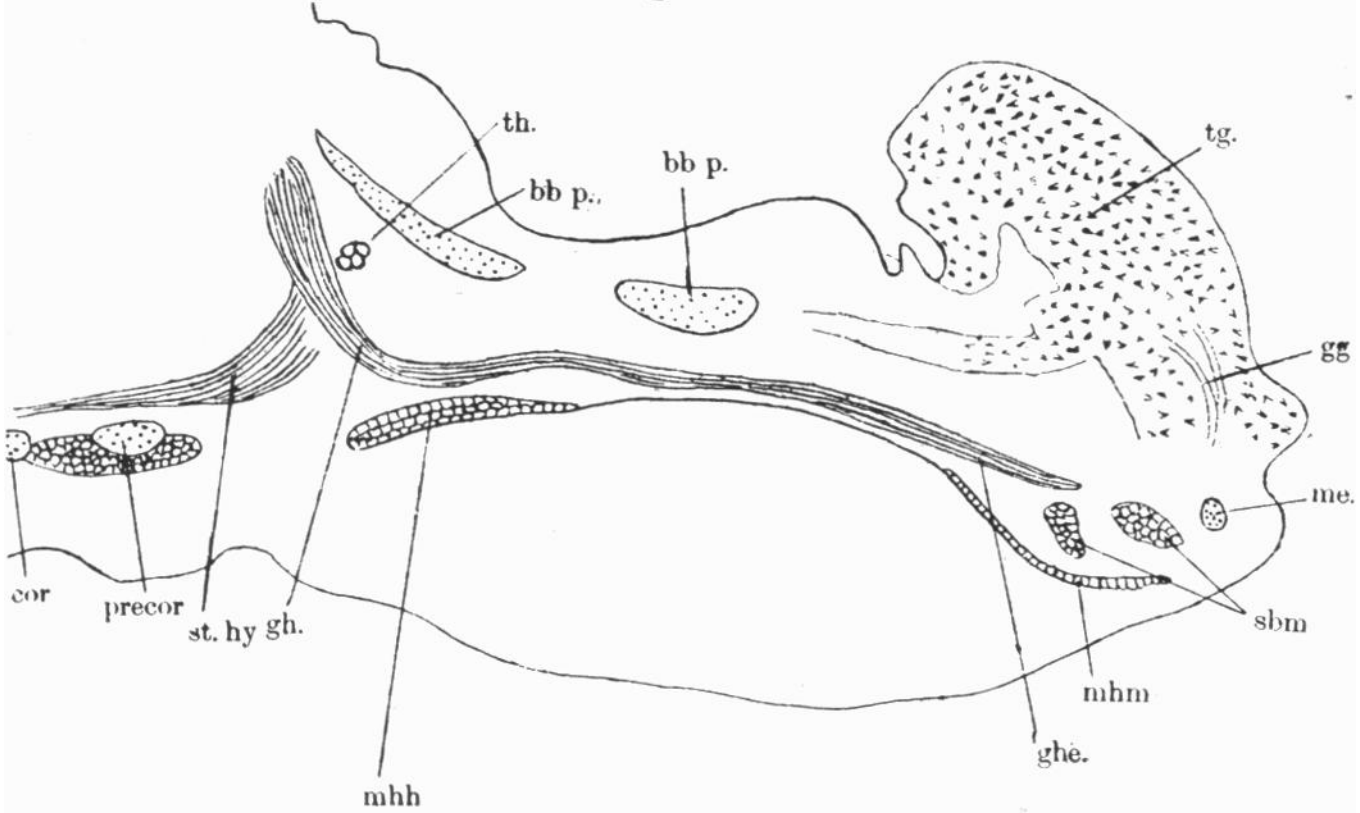

Fig. 64.

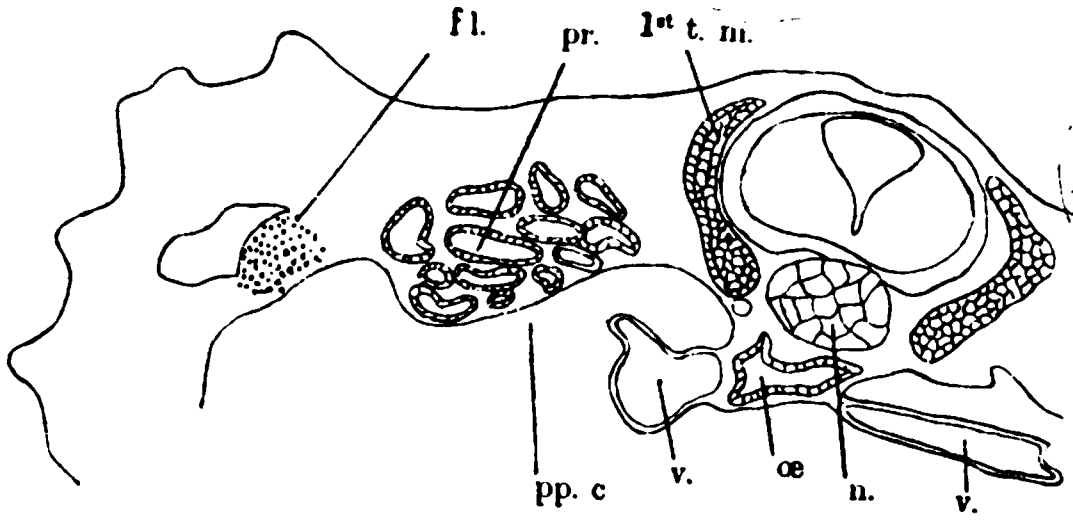

Fig. 65.

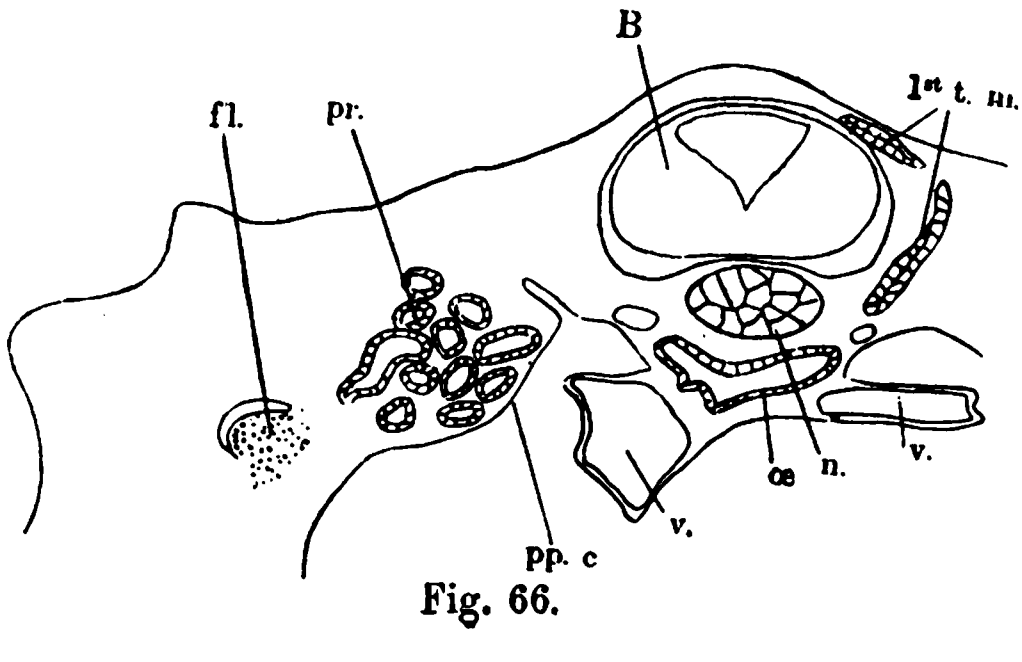

Fig. 66.

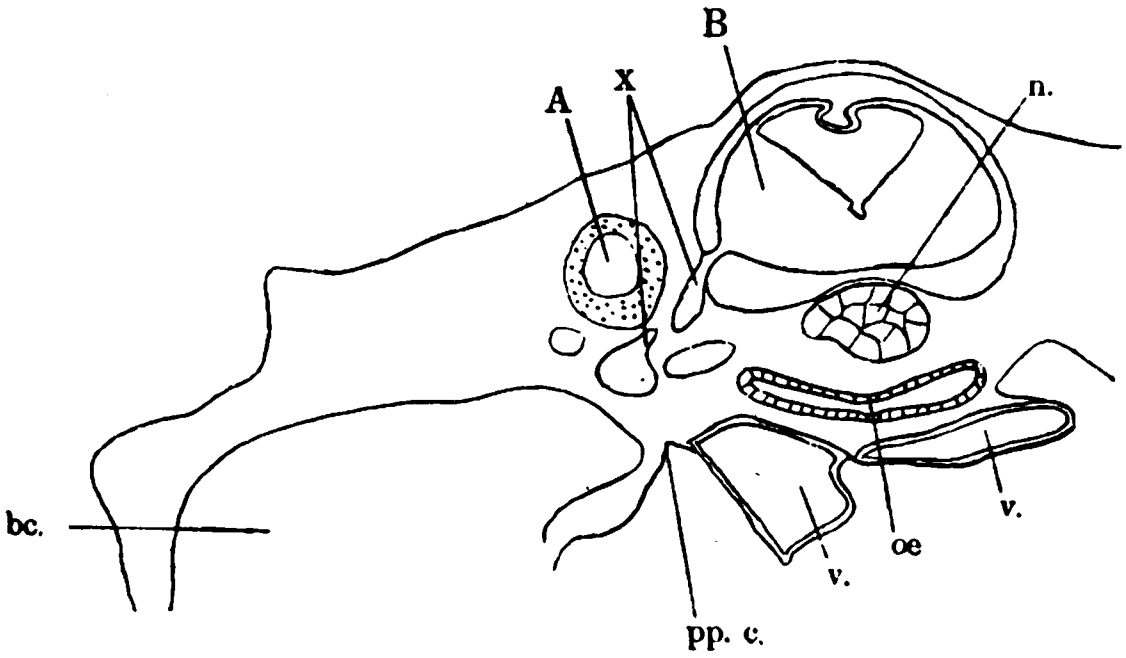

Fig. 67.

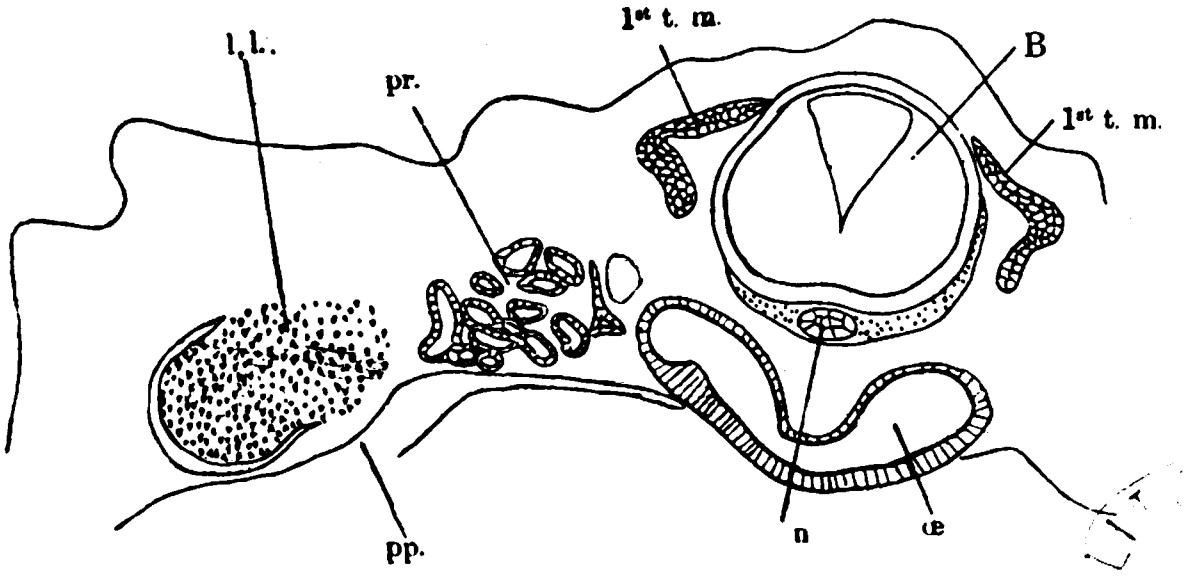

Fig. 68.

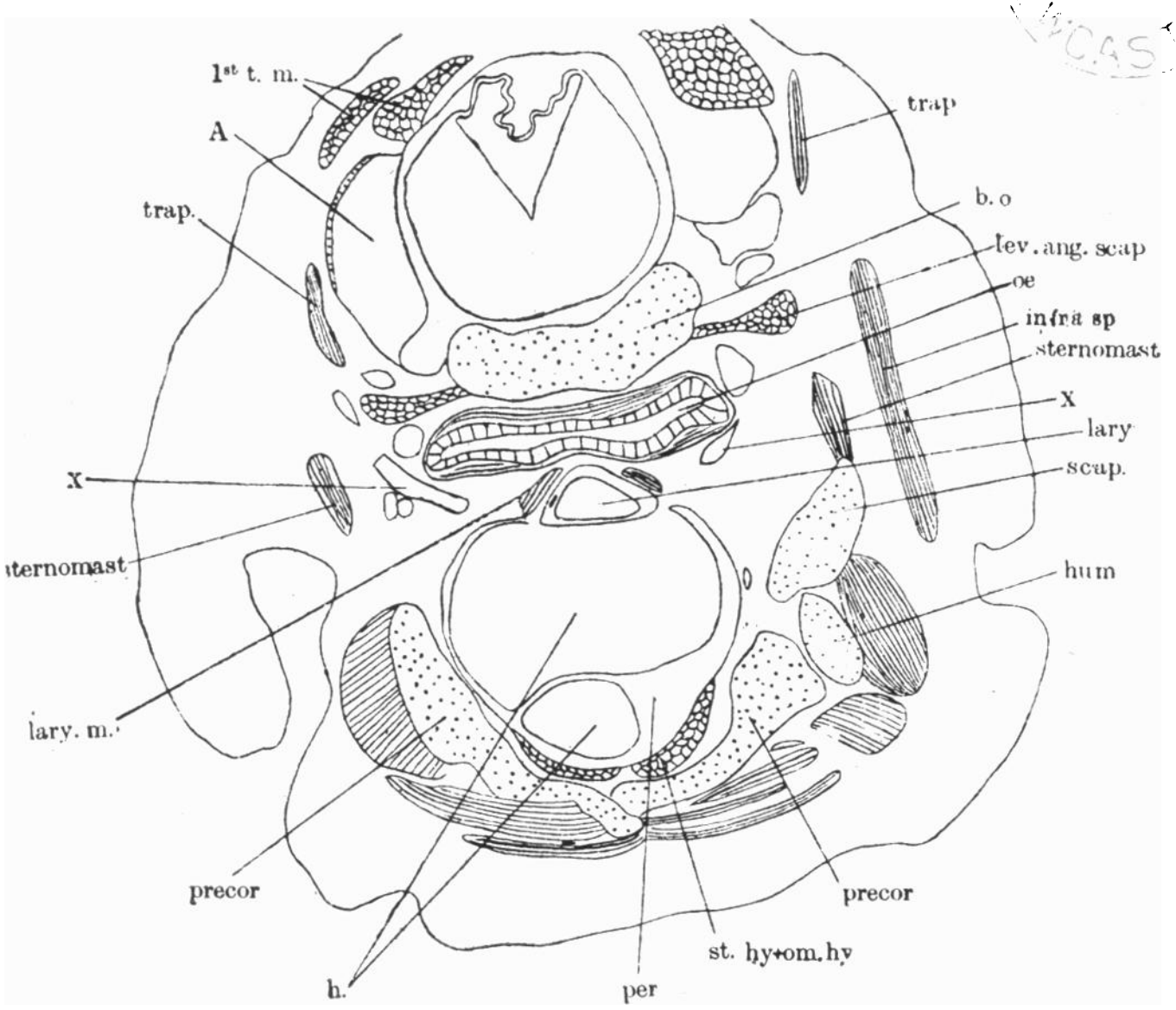

Fig. 71.

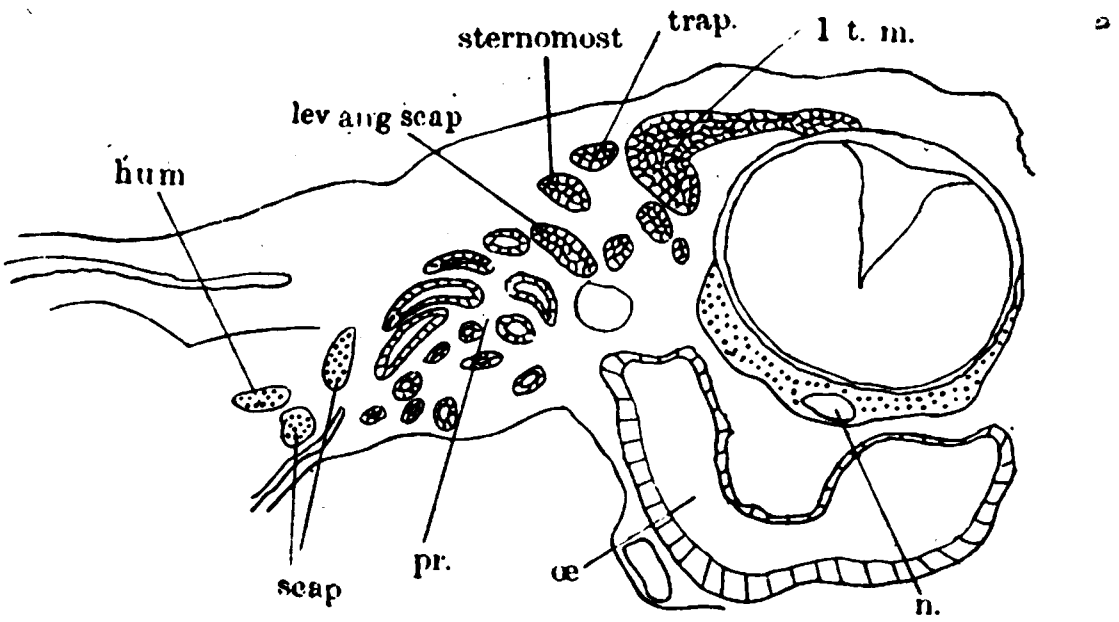

Fig. 69.

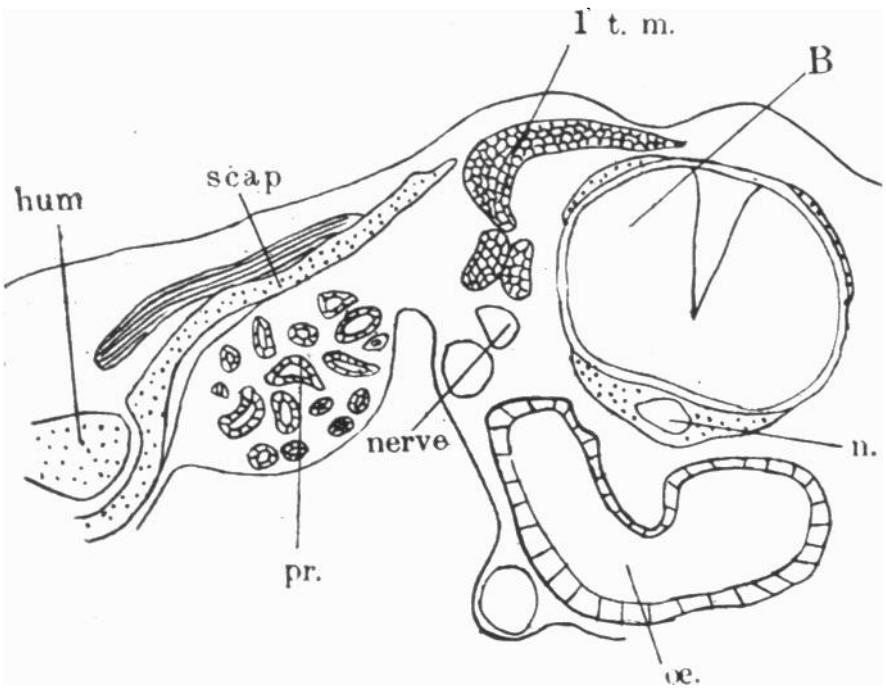

Fig. 70.

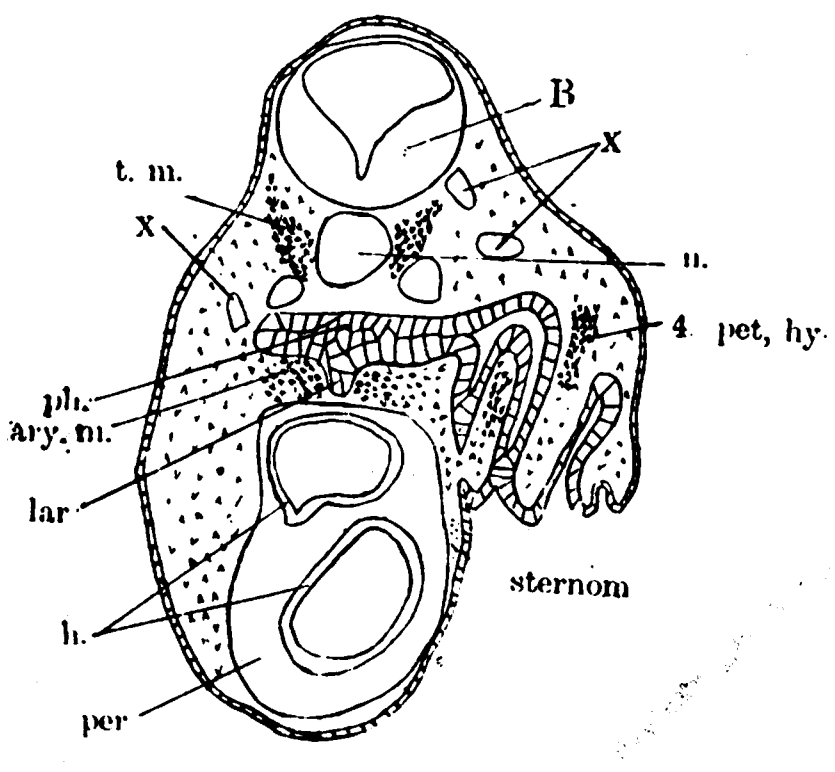

Fig. 72.