

THE RELATIONS OF THE THORACIC OPERCULUM CON-
SIDERED IN REFERENCE TO THE ANATOMY OF
CERVICAL RIBS OF SURGICAL IMPORTANCE. By
T. WINGATE TODD, M.B., Ch.B., *Lecturer in Anatomy, Manchester
University.*

DURING the present winter session, three subjects exhibiting cervical ribs, such as are of surgical importance, were dissected in the Anatomy Department at Manchester.

As there is still need for further information concerning the arrangements of the soft parts in such cases, as well as the investigation of widely spread changes in other parts of the vertebral column often associated with the presence of cervical ribs (1), it was considered desirable to make a thorough examination of these three bodies.

This led to the renewed study of certain points in the varying relations of the normal first rib which are now under discussion. During the course of this work clinical observations have been carried out on a number of cases of cervical ribs for the purpose of inquiring into the possible anatomical reasons for the occurrence of certain symptoms.

A large number of points have presented themselves in the course of this work, many of which are of surgical bearing.

The detailed description of the three cases dissected I do not propose to submit at present. I have, however, embodied many of the interesting facts brought to light in the substance of this paper, and these will be referred to as occasion may arise.

In the first place, the relations exhibited between the rib on the one hand and the vessel and nerve on the other were such as suggested those of the normal first rib to these structures, but in an exaggerated form.

Hence it seemed advisable to continue the study of the relation of the soft parts to the normal first rib, especially as the observations made last year in Manchester, by Dr Wood Jones, have been challenged. It was plain that considerable variation occurs in these relations, not only in different individuals, but also between the right and left sides of the same body.

This was so obvious that I dissected five subjects, taken at random, specially for this purpose, to find out any definite association in these variations.

In each case the dissection was begun with the arm to the side, and relations investigated both before and after abduction of the limb. It was not found (these subjects being hardened with formalin) that abduction made any real alteration in the relations of the several structures. In each case the standard taken was the relation of the structures to the inner margin of the first rib, that being the point of closest association with the bone.

It is important in this connection to remark that the subjects used in this work were preserved with strong solution of formalin, whereas those used last year by Dr Wood Jones were preserved with carbolic acid containing only half the quantity of formalin.

The nerve and vessels being thus fixed in position, abduction of the arm would not tend to alter their relation to the first rib, as occurs normally in the living through this movement. For there is no doubt that this alteration of relation between nerve and rib is responsible for the clinical fact that pain in cases of cervical rib is relieved by raising the arm from the side.

RELATIONS OF THE NORMAL FIRST RIB.

The simplest arrangement found was that where both vessels and the lowest brachial cord all rested on the rib (see fig. 1).

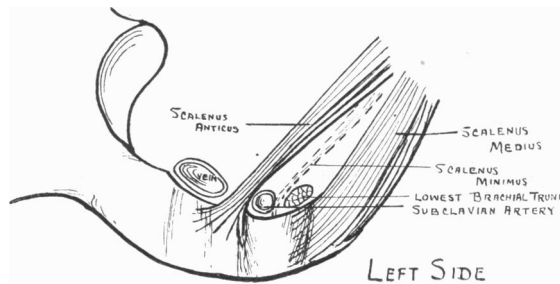


FIG. 1.

In such a case the scalenus minimus was only present if the artery and nerve were separated by an appreciable distance, and neither scalenus anticus nor medius was expanded at its insertion.

In four out of the ten dissections, however, the lowest nerve cord did not actually touch the rib (see fig. 2). In these cases the insertion of scalenus medius was found to expand in a forward direction. The higher the nerve cord was raised from the surface of the rib, the further forward came the anterior extremity of the insertion of this muscle.

This was found to be a survival of the foetal condition, and reference will be made to it later.

It was found that the nerve lay in contact with the rib more frequently on the right side than on the left in the proportion of four to two.

The study of the relation of artery to rib revealed the fact that in each of the special dissections undertaken, the right subclavian artery was not in contact with the rib, while the left artery lay directly on the rib (see figs. 1, 2, 3).

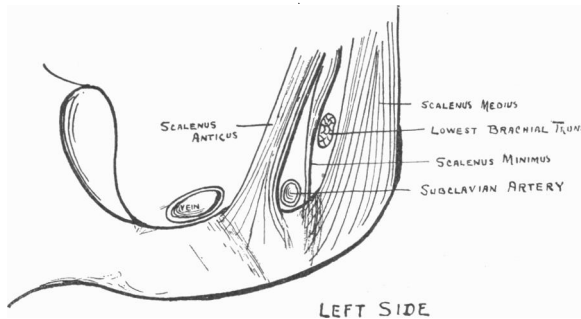


FIG. 2.

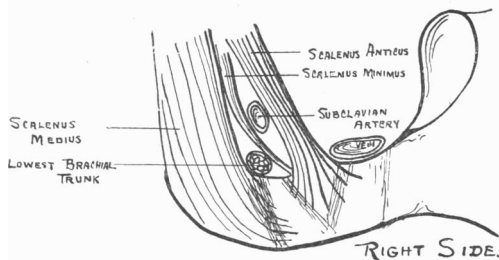


FIG. 3.

From this one would judge that there is a tendency for the right artery to lie at a higher level than the left at the inner border of the first rib; and considering the origin and course of these arteries, this is in accordance with what one would expect, the right vessel running more horizontally than the left.

Concerning the relation of artery to nerve in this situation, dissection showed that at the inner border of the rib these two structures may be closely in contact, or may be separated by a considerable interval. This interval may be as much as an inch in extent, and in such cases either artery or nerve may be the higher.

In the dissected cases it was found that the nerve more frequently lay in contact with the rib on the right side and the artery on the left.

Such a statement is apt to be misleading unless qualified. It does not infer that a different structure is responsible for the similar groove existing on right and left sides of the body. It merely suggests that, for some reason not yet apparent, in the position of rest, *i.e.* with the arm to the side, the nerve exhibits a tendency to lie in somewhat closer contact with the rib on the right side than on the left, while the artery tends to lie more frequently in close contact with the rib on the left side.

Mouchet (2) states that the nerve cord never lies under cover of the artery as it crosses the first rib, nor have I ever seen it in this position; but in two out of a series of two hundred macerated specimens of first rib it seems possible that the nerve may have taken this course.

While noting the above, the relation of the vein to the rib was also observed.

This vessel was much more constantly in contact with the rib than the artery, and only slight variation ever occurs.

It was at first surmised from dissection that the right vein exhibited a tendency to closer contact with the rib, but this was proved to be fallacious by the study of macerated specimens.

MARKINGS ON THE FIRST RIB.

Dealing now more particularly with the markings on the first rib, it is found that while some specimens show on the upper surface two grooves separated by a slight ridge or mound, many show only one groove (the sulcus subclaviæ B.N.A.). It is more frequent to find the distinction marked between these twin grooves at the inner border of the bone than on the upper surface. At the inner border this distinction is marked either by a tiny spicule or by distinctly different modes of bevelling of the margin. Very frequently these two signs were present on the same specimen. In such a case the border of the rib at the sulcus subclaviæ was simply rounded anterior to the spicule, as though some structure had been loosely lying on the upper surface of the bone, while posterior to the spicule the inner border of the rib was so sharply bevelled as to suggest that some structure had been passing from below on to the upper surface of the rib, and had been more or less tightly stretched across this margin of the bone.

By dissection of the recent specimens it is obvious that in the anterior of these twin grooves, when present, lies the subclavian artery, while the posterior lodges the lowest brachial nerve cord.

It is evident that the form and depth of the groove associated with the

passage over the rib of the first dorsal trunk will be influenced by variations in the position of the thoracic operculum, as represented by the two first ribs and the manubrium.

These variations are—

- (1) Obliquity of the plane of the operculum from the horizontal.
- (2) Distance from the middle line of the body, of the inner border of the first rib.

Concerning the first of these, observations have been carried out on twenty-five patients. This investigation is not yet complete, but evidence at present suggests that the obliquity varies in different individuals, and at different periods of the respiratory cycle. Especially would this latter appear to be the case in females.

Theoretically, if there be but comparatively little departure from the horizontal in the "lie" of the rib, then the lowest nerve trunk will tend to groove the bone more deeply. And this grooving will be most obvious at the inner border of the rib. In the macerated specimens the bone was occasionally found to be distinctly "sagged" downwards, the deepest part of the curve being at the nerve groove.

As regards the second factor mentioned, it is found that the right and left halves of the operculum do not always form mirror pictures the one of the other. They may be asymmetrical in that the inner border of one first rib may be nearer the middle antero-posterior plane of the body than the corresponding border of its fellow.

In these cases the rib lying nearer the median plane shows better marking for the nerve, as though the latter structure had been more tightly stretched across the inner border of that rib than the corresponding nerve on the other side.

In view of recent discrepancy of opinions concerning the sulcus subclaviæ B.N.A., I would state briefly the result of observations on the macerated rib. Two hundred specimens have been examined (98 right; 102 left).

The sulcus varies greatly in depth and breadth. In 75 (37.5 per cent.) it was not present at all, and in 25 (12.5 per cent.) it was only to be distinguished at the inner border of the rib. When well marked, it was in all but one or two cases too broad to be entirely occupied by either nerve or artery alone, unless that structure were freely movable backwards and forwards with the movement of the pectoral girdle. This mobility seems hardly likely in view of the fact that 17 specimens showed the subdivision of the sulcus into two channels across the upper surface of the rib.

The number of cases showing subdivision of the sulcus at the inner border of the rib, either by spicule or differences in bevelling, was 30, *i.e.* 15 per cent.

The rib itself showed considerable variation in shape. Frequently it would lie quite flat on the table, being practically wholly in the one plane. But several specimens were found where the rib was so twisted that it lay like a rocker on the table.

Intermediate forms between these extreme types were also noted. Possibly the twist was due to a sagging downwards of the middle of a rib forming part of a more horizontal operculum than usual. There has, however, been no opportunity as yet of dissecting such an example.

The twist of a "rocker" rib was sometimes very sharp, and was always most pronounced at the nerve (*i.e.* posterior) groove, which invariably formed the deepest part of the twist. These types have also been described by Wood Jones (3).

A well-marked arterial (*i.e.* anterior) groove was not associated with any special variety in the form of the rib. Nor was the anterior groove ever deep like the posterior, save in one case of seventh cervical rib.

From this one would infer that the nerve is the real factor in determining the shape of the rib, but owing to other factors already mentioned (the obliquity and asymmetry of the ribs), the relation of nerve to rib may vary considerably.

It is impossible to say in how many of the macerated specimens the groove was due to the nerve, inasmuch as above 108 showed a single groove of indeterminate character.

The elasticity of the artery is presumably the reason for the comparatively slight effect of this structure on the shape of the bone.

STATISTICS OF MACERATED RIBS.

Total ribs examined (98 R. 102 L)	200
Total with single groove inner border (58 R. 62 L.)	120
Total with double groove inner border (12 R. 18 L.)	30
Total with single groove upper surface (49 R. 59 L.)	108
Total with double groove upper surface (10 R. 7 L.)	17
Total with vein groove (61 R. 64 L.)	125

THE CAUSATION OF SYMPTOMS IN CASES OF CERVICAL RIB.

Referring now to the symptoms of cervical rib, a series of thirty cases of this condition have been gathered together, and in this work I have been greatly helped by Mr Stopford, to whom I wish to express my thanks.

Of these thirty cases twenty-two presented symptoms. The other eight were discovered accidentally. From this latter statement one would gather that the presence of cervical ribs without symptoms is not very uncommon.

In all cases they were bilateral, and in five they occurred in persons of mature age. It is known that cervical rib-elements are normally present in the foetus.

It would then appear that these unnecessary ribs become absorbed very frequently in early life. The foetal rib, which most frequently disappears altogether, is that connected with the seventh cervical vertebra. The preceding ribs remain in rudimentary form as part of the transverse processes. Man is not alone in this peculiar and complete disappearance of the seventh cervical rib, as the same total absence of a rib element in connection with the seventh cervical vertebra occurs in the gibbon.

But it is not always the more unusual presence of the seventh cervical rib which causes symptoms. Anatomically the anomalous rib may prove to be a rudimentary first dorsal, *i.e.* a rudimentary rib connected with the eighth vertebra. This is a reproduction of the normal appearance of this rib in the gibbon. As the radiograms I have seen have never shown the number of vertebræ preceding that in connection with which the "cervical" rib occurs, I am unable to give statistics regarding this matter.

It is certain, however, that the normal first rib (*i.e.* of the eighth vertebra) may be the real cause of symptoms.

I have seen a few cases where, though cervical ribs were present, it was proved on operation that the normal first dorsal rib was the true offender. In these cases the cervical element was small, and lay behind the nerve trunks. Owing, however, to the impossibility of determining the size of the cervical rib by radiography, the real cause was not discovered till the operation.

Reference will be made later to this fact.

In the twenty-two cases where symptoms occurred, it was found invariably that the subjective symptoms were associated with the nerves. It is self-evident that with the brachial plexus in its normal situation, the lowest nerve cord will be more intimately related to a cervical than a normal first dorsal rib. The lower trunks will, in crossing the cervical rib, have further to travel to their distribution, and in consequence one may imagine a certain "stretched" condition of the nerve cord over the rib. Associated with this, one would expect a deeper nerve groove on the cervical rib. This is present on those specimens I have dissected, and it has been frequently noted in the relations of cervical ribs.

Eisler (quoted by Wood Jones (3)) affirms that there is a tendency of the brachial plexus to move in a cephalic direction when a cervical rib is present.

My dissections of cervical ribs show that this is not so in all cases.

And one would here like to suggest that the cases of "rocker" ribs

previously mentioned may possibly be those in which symptoms caused by an apparently normal first rib would tend to be present.

As to the age at which symptoms appear, it is found on reference to notes of the cases that in the great majority (twelve out of sixteen in which the onset is noted) the symptoms occurred in early adult life, *i.e.* between 20 and 30 years of age. In one case the symptoms appeared between 30 and 40, and in three they were said to occur later in life. All these cases, however, had had symptoms "some considerable time," which statement rather obscures the date of onset.

Considering, therefore, that in the majority of cases symptoms appear in early adult life, there would seem to be anatomical evidence that such is in accordance with the growth of the body.

It has been already mentioned that two factors will have some "stretching" effect on the lower brachial trunks, namely:—

- (1) Diminished obliquity of the operculum.
- (2) Distance of the inner border of the first rib from the median line of the body.

These will have exaggerated effect in cases of cervical rib.

Moreover, they are assisted in their effect by certain other consequences of the growth of the body.

These are—

- (3) The relative widening of the chest.
- (4) The growth of the clavicle.
- (5) The sinking of the pectoral girdle.

Concerning the first of these no proof is required, as this obviously occurs along with the growth of the clavicle.

As regards this latter, the clavicle attaining its full development and complete ossification about 22 to 25, one would expect its full stretching effect on the nerves to be apparent at about this age, when the shoulders reach their adult position.

The angle at which the clavicle projects will also have influence on the nerves. Should it project upwards and outwards, as frequently occurs in men, there will be less consequent stretching of the brachial nerve trunks than if it projects downwards and outwards, as is general in women.

The sinking of the pectoral girdle is more difficult of proof. In another paper I propose to deal with this in full. At present it will be sufficient to state that in lower forms, where the fore limb is placed relatively nearer the head, the brachial plexus does not fit so closely to the thoracic operculum as in higher forms, *e.g.* man, where the whole shoulder tends to be set back over the upper part of the chest. It is also certain from dissection that in primates there tends to be cephalic migration of the brachial

plexus as the erect posture is attained, and in man, where the shoulder has dropped furthest backward on to the chest, the brachial plexus is set most anteriorly. The post-fixed brachial plexus is, however, not very uncommon in man, and in such a case there would be greater tendency towards symptoms.

Again, between birth and adult age the neck grows comparatively longer. This would appear to be due not to excessive growth in the cervical vertebræ, but to the gradual sinking of the shoulder girdle as the final adult form evolves.

All these factors in the production of symptoms would most naturally come into operation about the period of early adult age, and this is the most frequent age at which to find patients complaining of this malady.

In the next place, out of the thirty cases, twenty-six occurred in women.

In a clinical study of twenty-five cases in the wards, it was found that there is an altered obliquity of the thoracic operculum in the different phases of respiration. In women this was much more marked than in men, who only showed comparatively slight raising of the operculum even in deep inspiration. In one woman suffering from Glenard's disease the raising of the operculum during inspiration was most marked. In women, therefore, with the greater movement in the upper chest there is considerably more likelihood of the nerve trunks being interfered with by the first rib, even if that be normal, and this will be more pronounced if cervical ribs be present.

Lastly, out of twenty of the cases where the side on which symptoms occurred was noted, ten showed symptoms in the right arm only, five had both arms affected, and in five the left side only was involved.

It has already been stated that anatomically the right plexus was found in closer connection with the corresponding rib than the left.

One would suggest that this may be associated with right-handedness. For here, besides the factors already mentioned, there are the thoracic changes associated with the slight convex lateral curvature of the spine to the right, so frequently found in right-handed persons. And these, together with the greater use of the right arm—and consequently the greater drop of the right shoulder—would tend to bring the plexus and the rib into closer relation on this side.

In one case only is right- or left-handedness distinctly mentioned, and that is in one of the cases where symptoms occurred on the left side only, and this patient was a young lady who was left-handed.

All these factors would be counteracted and hence ease given temporarily by raising the arm. This is in accordance with known facts.

Other causes for the nervous symptoms have been mentioned.

Murphy (4) states that the causation of both nervous and vascular symptoms is due to muscular compression caused by the pressure exerted by the growing rib on the nerve and artery against the scalenus anticus muscle. I cannot say that this does not ever occur, but my dissections lead me to surmise that it is unlikely, and insufficient cause.

Again, Thorburn (5) and others have referred to a common belief that complete ossification of the cervical rib is responsible for the symptoms, and

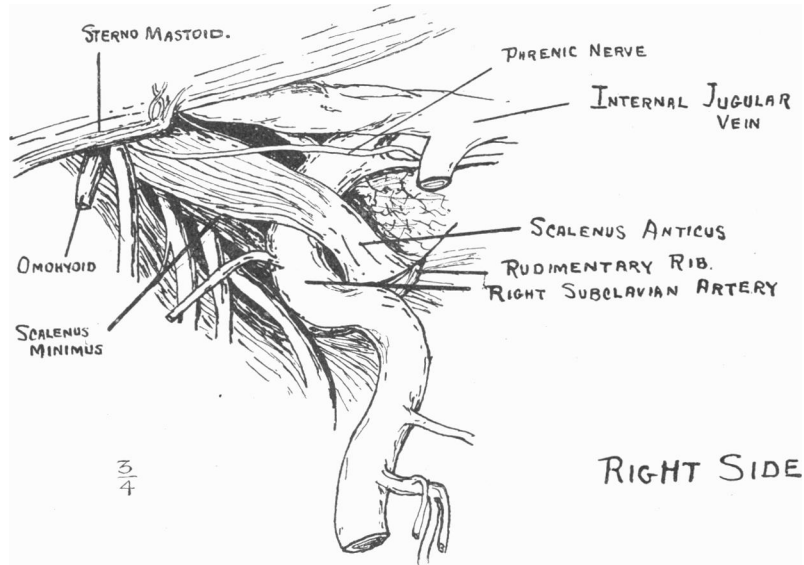


FIG. 4.—Right side. Body in horizontal position.

that this occurs in early adult age. There is no reason to suppose that the ossification of a cervical rib should be so long delayed beyond the normal period for a thoracic rib. Moreover, the collection in Manchester shows cases of cervical rib completely ossified and even united with the first dorsal rib before puberty.

With regard to vascular symptoms, besides those forces mentioned as influencing the nerve relations, the following possible factors may be mentioned:—

- (1) Action of the scalenes in inspiration.
- (2) Descent of the diaphragm in inspiration.
- (3) Descent of the heart in inspiration.

Concerning the first of these, muscular compression may have a distinct

influence on the artery, which always pursues a more or less tortuous course through the muscular wall, and this is more pronounced in cases of cervical rib (fig. 4).

It is self-evident that if the subclavian artery is at all pressed upon by the rib, the radial pulse will, in inspiration, because of the above causes, become diminished and even obliterated.

It is an accepted fact that the subclavian artery is the artery of the seventh cervical segment, and therefore passes out above a seventh cervical rib, but under cover of a sixth cervical rib. I have not had the opportunity of confirming this in man, but only in lower animals.

While discussing the vascular symptoms, it is interesting to note the clinical pseudo-aneurysmal appearance present in some cases of cervical rib.

Murphy (4) considers this to be due to a flattening of the artery over the upper surface of the rib. This might possibly be a post-mortem formalin change.

A simpler explanation would seem to be that the artery is more tortuous than usual.

In my dissected cases of cervical rib the subclavian artery lay in an S-shaped manner at the junction of arm and trunk. It took a forward curve on the upper surface of the "cervical" rib, running as it were in a groove between scalenus anticus and medius, and then turning outwards again to become the axillary artery (fig. 4).

Dissections of the fœtus showed the same condition normally. And the tortuous artery, though not so pronounced in type, was found to be very frequent in normal dissecting-room subjects.

It would appear then that there is a tendency to tortuosity of this artery which is exaggerated in cases of cervical rib. This is probably because the artery reaches the internal surface of the chest wall more posteriorly than usual, owing to the oblique direction of the scalenus anticus.

The veins have never shown a similar condition.

SUMMARY.

1. The first thoracic rib may display grooves for nerve or artery, or both.
2. On the right side in right-handed people the nerve plexus tends to be in closer contact with the rib than on the left side.
3. In consequence of its general direction the left subclavian artery is more frequently in contact with the corresponding rib than the right artery.

4. In cases of cervical rib the nervous symptoms are caused by an exaggerated form of the normal relation existing between the brachial plexus and the first rib.

5. In consequence of this, symptoms are more frequent on the right side.

6. The greater frequency of symptoms in women is probably due to the greater use of the upper chest in respiration.

7. The age at which symptoms occur would appear to be connected with the development and position of the chest and shoulder as adult age is reached.

8. Arterial symptoms are caused by the action, directly by the scalenes and indirectly by the diaphragm, on an artery with a further and more tortuous course to pursue than is usual.

BIBLIOGRAPHY.

Only references to authors actually quoted are cited.

(1) ELLIOT SMITH, G., "Significance of Fusion of Atlas and Occipital Bone and the manifestation of Occipital Vertebrae," *British Medical Journal*, 29th Aug. 1908.

(2) MOUCHET, *Anatomischer Anzeiger*, 9th June 1910.

(3) WOOD JONES, *Journal of Anatomy and Physiology*, vol. xlv.

(4) MURPHY, *Annals of Surgery*, vol. xli., 1905.

(5) THORBURN, *Dreschfeld Memorial Volume*.