

# ANIRIDIC GLAUCOMA: THE RESULTS OF GONIO-SURGERY TO PREVENT AND TREAT THIS PROBLEM\*

BY *David S. Walton*, MD

## INTRODUCTION

THE NEED PERSISTS TO PROVIDE SURGICAL TREATMENT FOR GLAUCOMA ASSOCIATED with congenital aniridia. Surgical therapeutic procedures are often unsuccessful. These failures combined with the frequent inadequacy of medical therapy for aniridic glaucoma have underscored the potential importance of a prophylactic operation for this condition. During the last 12 years I have performed goniotomy operations in 24 children with aniridia. Fifty-one of the operations were performed prophylactically in 16 congenital aniridic children (28 eyes) without glaucoma in an effort to prevent progression of changes in the filtration angle that could lead to glaucoma. Eighteen goniotomy operations were done with therapeutic intent in nine children (14 eyes) with established aniridic glaucoma.

In 1952 Blake<sup>1</sup> reported to this society on the uncertainty of surgery for treatment of glaucoma complicating congenital aniridia. In 1974 Grant and I<sup>2</sup> described detailed gonioscopic observations in our patients with congenital aniridia. We reported finding progressive filtration angle abnormalities to explain development of glaucoma in later childhood. Grant was the first to recognize the progressive changes in the angle in development of glaucoma in aniridia, and was the first to propose the idea of performing prophylactic gonio-surgery to prevent this condition. Grant was also the first to perform prophylactic surgery, with encouraging results, in two young patients in 1966. In doing this he had the strong moral support of Paul A. Chandler and Carl C. Johnson. Grant and Chandler have encouraged me to pursue this subject, and this I have done.

The purpose of this report in 1986 is to share the results of gonio-surgery for the prevention of aniridic glaucoma and for treatment of glaucoma uncontrolled by medical therapy.

\*From the Department of Ophthalmology, Massachusetts Eye & Ear Infirmary, Harvard Medical School, Boston, Massachusetts.

## THE PATIENTS

The 16 patients who received *prophylactic* surgery consist of 7 boys and 9 girls. Their average age when first examined was 28 months; 8 of 16 were 12 months of age or younger. The average period of observation before prophylactic surgery was performed was 2 years; however, 13 of 28 eyes were operated after 1 year or less of observation. A family history of aniridia was present in 12 of these 16 patients. Eleven of 12 of these parents with congenital aniridia had glaucoma.

The nine children for whom *therapeutic* goniotomies were performed consisted of seven girls and two boys. Their average age was 7 years when first examined, and nearly all of their gonio-surgery was performed within 1 month of the initial examination. A family history of congenital aniridia was present in three of nine patients; two of these three parents had glaucoma.

## SURGICAL INDICATIONS

From observations on the two patients operated earlier in one eye by Grant to interrupt development of aniridic glaucoma, we learned that this procedure was technically possible and, at least in the short term, that the progression of the trabecular blockage could be interrupted. I have been influenced by multiple factors to modify the criteria for prophylactic surgery that Grant and I<sup>2</sup> proposed in 1974. Ever present is the tragic condition of most aniridic parents of young aniridic children. The parents themselves frequently suffer significant visual loss secondary to the complications of aniridia, including glaucoma. Furthermore, I was impressed by the difficulty encountered with older aniridic glaucoma patients who were inadequately controlled with medical therapy, and who as a group repetitively demonstrated disappointing results from surgery performed at an advanced stage. Finally, although by repeat gonioscopic examinations I could detect progressive angle defects in the young children, this did not provide me with certain information in respect to when the process should be interrupted. When was soon enough? It had become painfully clear that to do this surgery after pressure elevation had occurred could be too late.

After consideration of these realities, I used the following criteria to select patients for the prophylactic surgery reported in this paper. All eyes without glaucoma, with congenital aniridia became candidates. Almost all patients were very young children. Both eyes were considered for surgery with procedures performed on only one eye at a time, with few exceptions. Because of the shallow anterior chamber present during

the first year of life, surgery was avoided during this interval; however, regular office gonioscopy and tonometry did begin during this period. After 1 year of age, gonioscopy dictated the recommendation for surgery. If office examination produced uncertain observations, examination under general anesthesia was recommended. If the trabecular meshwork was found unobstructed for greater than half of its circumference, no surgery was recommended. If, however, covering of the posterior trabecular meshwork by apparent extension of tissue from the peripheral iris was present for more than half of its circumference, then surgery was recommended.

All parents for whose children *prophylactic* surgery was recommended were advised fully of the risks of surgery and anesthesia and of the uncertain benefit of this procedure. The opportunity for its potential benefit was never declined by any parents, and each patient has completed the recommended program, which often has consisted of two goniotomy operations for each eye.

Goniotomy for *therapeutic* reasons was usually considered as the initial surgical procedure for children with aniridic glaucoma uncontrolled by medical therapy. This procedure was advised especially for younger patients with less advanced filtration angle defects where the covering of the trabecular meshwork appeared less confluent and sunken into the trabecular tissue.

#### THE SURGICAL TECHNIQUE

The surgical procedure for both prophylaxis and treatment of aniridia departs very little from the therapeutic operation introduced by Barkan<sup>3</sup> for congenital glaucoma, with which we are all familiar. I have found, however, that attention to certain details is important.

The operator should be experienced with goniotomy technique before applying this skill to the aniridic eye. Familiarization with the range of aniridia angle defects, as previously described,<sup>2</sup> is appropriate further preparation. Under general anesthesia careful gonioscopy before any surgery is essential. We have found Koeppel gonioscopy with a hand-held microscope to be very satisfactory. After confirming the presence of appropriate grounds for surgery, angle landmarks must be established for use during the surgical procedure.

I have usually performed the goniotomies in aniridic eyes with a loupe and nontapered, nonirrigating knife. Use of an operating microscope and/or irrigating knife are alternatives that can be considered.

The globe is entered nasally or temporally, under visualization. It is

desirable to use an operating lens, somewhat smaller than usually used in nonaniridic patients with larger corneas, to allow ease of entry through peripheral clear cornea. The direction of entry must be somewhat more posterior than is customary to avoid a lengthy corneal passage. Rotation of the globe by the assistant during the procedure allows a larger arc of surgery to be performed.

The tip of the gonioscopy knife is allowed to engage the abnormal tissue extending anteriorly over the trabecular meshwork (Fig 1). Gentle pressure posteriorly will initiate the removal of this tissue off the meshwork. Such tissue is frequently vascularized with visible red vessels, but I have not encountered bleeding during the procedure or afterward. Posterior movements of the knife tip are continued as the blade is rotated circumferentially. After completion of approximately 3 hours, I return the knife to the starting meridian and sweep the sulcus which has been produced to eliminate any persistent iridotrabecular attachments. The operation is then continued for the full extent of the angle that can be easily visualized, and the knife is removed.

The prophylactic procedure departs from the technique for treatment of glaucoma by intentionally avoiding injury to the trabecular tissue.

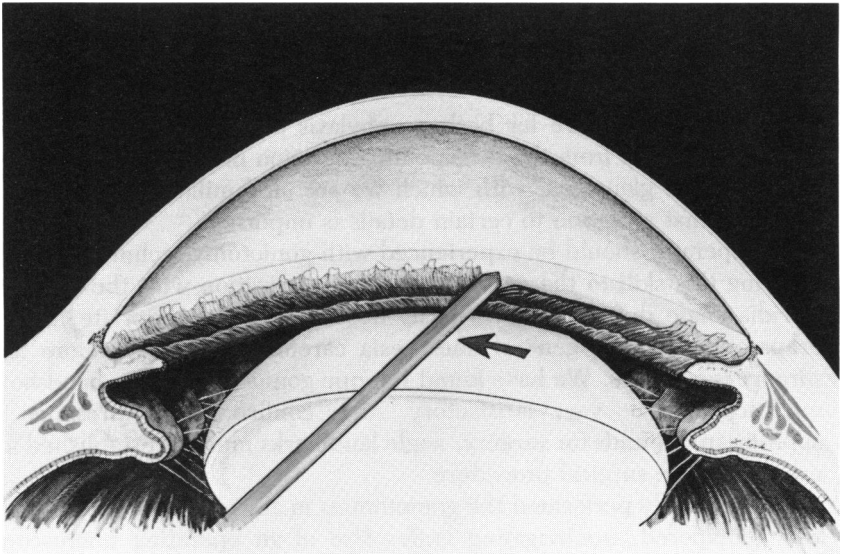


FIGURE 1

Prophylactic gonio-surgery. Tip of goniotomy knife engages tissue on face of trabecular meshwork and displaces it posteriorly.

When goniotomy has been done for treatment of aniridic glaucoma, I have often produced a superficial cleft in the trabecular tissue over most of the circumference that has been exposed by removal of the iris.

#### SURGICAL RESULTS

##### PROPHYLACTIC GONIO-SURGERY FOR ANIRIDIC GLAUCOMA

Fifty-one prophylactic operations were performed for 28 eyes of 16 children. The behavior of the intraocular pressure after this prophylactic gonio-surgery is summarized in Table I. Preoperative and most recent

TABLE I: PROPHYLACTIC GONIO-SURGERY FOR ANIRIDIA PREOPERATIVE AND POSTOPERATIVE PRESSURE MEASUREMENTS

PREOPERATIVE PRESSURE (mm Hg)	POSTOPERATIVE PRESSURE/INTERVAL	
	mm Hg	YEARS
15	14	1
15	16	1
20	11	1
20	11	1
20	16	1
20	16	1
18	16	1
18	14	1
18	18	1
18	18	1
16	11	3
16	11	2
20	35	3
13	12	5
17	17	6
17	17	6
14	28	7
14	26	7
16	17	8
16	22	8
18	15	10
12	10	10
12	10	10
12	14	10
15	15	11
15	15	11
12	18	11
12	18	11

postoperative pressures are recorded, accompanied by the postoperative time period for each eye.

These preliminary results describe a favorable maintenance of normal eye pressures following this surgery. It must be recognized that most of my patients were young children with an average age at surgery of 4 years (49 months), which followed an average interval of preoperative observation of 2 years. The incidence of glaucoma in aniridia is uncertain; estimates vary from 6% to 75%.<sup>4</sup> It is my impression that progressive angle defects in aniridia can usually be expected to result in glaucoma between the ages of 7 to 15 years in most patients.

To achieve the desired anatomic result two operations were done on 23 eyes and one operation on 5 eyes. No surgical complications were encountered during surgery or recognized after surgery as being related to the procedures done. No acceleration of lens or corneal defects was observed.

Repetitive gonioscopic observation throughout the postoperative interval of each patient confirmed our initial impression that the surgical separation of iris and trabecular meshwork would persist. Eyes having two operations had an average of 8.5 hours of iridotrabecular separation, while one operation produced an average of 5 hours change. Qualitatively, in the operated regions progression of the aniridia angle abnormality was halted in all patients and produced a conspicuous contrast to unoperated areas. In the operated regions typically the trabecular meshwork appeared clean with no remaining iris attachments, abnormal vessels, or uveal meshwork tissue.

#### **THERAPEUTIC GONIOTOMY FOR ANIRIDIC GLAUCOMA**

Goniotomy to treat glaucoma after it had become a real problem was performed in nine aniridic children. Eighteen operations were done on 14 eyes. Five eyes had two operations and eight eyes one operation. The average age at surgery was 7 years.

The results of this surgery in terms of pressure are summarized in Table II. These results are disappointing and reveal that only 2 of 18 operations controlled the intraocular pressures. Failure to control eye pressure was evident in the immediate postoperative period in all unsuccessfully operated eyes. Most procedures were done for eyes that were inadequately controlled medically, and which went on to require alternative procedures following failed goniotomy surgery.

No surgical complications were encountered. A surgical cleft was produced for an average of 4 hours in those eyes having a single operation and 9 hours in those having two goniotomy operations.

TABLE II: THERAPEUTIC GONIOTOMY SURGERY FOR ANIRIDIA PREOPERATIVE AND POSTOPERATIVE PRESSURE MEASUREMENTS

AGE (YRS)	REPEAT OPERATION (YRS)	PREOPERATIVE PRESSURE (mm Hg)	POSTOPERATIVE PRESSURE/INTERVAL	
			mm Hg	YEARS
2 mos		40	13	2
2	5	35	35	8
3	6	20	30	7
4		35*	20*	6
5	5	40*	35*	Re-op†
5		40*	30*	Re-op†
7		35*	27*	3
7		24*	40*	Re-op†
7	7	40*	40*	Re-op†
7		22*	26*	11
7		23*	25*	11
8		28	14	5
9		35	37	Re-op†
15		30*	40*	Re-op†

\*On glaucoma medication.

†Re-op = immediate reoperation following unsuccessful goniotomy.

#### DISCUSSION

Congenital aniridia is an uncommon disease with an incidence of approximately 1:80,000.<sup>4</sup> Autosomal dominant inheritance has caused its repetitious occurrence over many generations in some families and places future generations at risk after its sporadic occurrence. Congenital aniridia is a poorly understood disease of the eyes which causes progressive deterioration of ocular tissues including the cornea, iris, filtration angle, and lens, and is associated with congenital macular hypoplasia. Visual deficit early in life is followed in later decades by further loss of vision secondary to progressive corneal opacification, cataract formation, and optic nerve injury secondary to glaucoma. The biochemical defect or defects responsible for these changes are unknown.

#### PROPHYLACTIC SURGERY

In this report the results of prophylactic surgery in 16 aniridia patients suggests favorable results. Generally, two goniotomy procedures have been required for each eye. Though 14 operated eyes have been followed less than 5 years, 14 other eyes have been followed 6 or more years after surgery. Noteworthy was the loss of control after only 3 years (Table I) in one eye of one patient. This child was operated on at 3 and 4 years of age. Two procedures were done inferior-nasally, which opened her angle for

only 2 hours, compared to the 8 hours of surgical alteration in the angle created in most other patients. Glaucoma in the unoperated eye preceded its occurrence in the operated eye. A second patient described in Table I experienced an elevation of eye pressure from 14 in each eye to 28 and 26 mm Hg after 7 years. This child, first operated on at 3 years of age, had goniotomies that produced only 3 hours of opening in one eye and 4 hours in the other. Both of these patients had less extensive surgery than most other children in this group.

I am encouraged enough by these results to continue prophylactic gonio-surgery on selected congenital aniridia patients. It seems possible that the surgical technique described may protect some patients from glaucoma at least in childhood. It is further encouraging to see an occasional adult with congenital aniridia without glaucoma and to find on gonioscopy that their trabecular meshwork is unobstructed and apparently protected by the presence of an unusually wide ciliary body band. I am concerned that in time, however, even without obstruction of the trabecular meshwork by the iris, that other changes may occur in this tissue, leading perhaps to endothelialization of this tissue and secondary obstruction of aqueous outflow.

#### THERAPEUTIC SURGERY

Results of therapeutic glaucoma surgery in congenital aniridia have been disappointing. Blake<sup>1</sup> reported in 1952 that it was the third choice of procedures for this condition among members of our society. One year later Barkan<sup>3</sup> reported careful observations made on a child under 1 year of age with congenital aniridia and glaucoma. He reported an extension of tissue anteriorly from the iris root toward Schwalbe's line and speculated that it was the cause of obstruction to aqueous outflow. Successful goniotomy by Barkan was followed by gonioscopy, revealing unobstructed "normal" trabeculum in the operated area. Callahan<sup>5</sup> in 1949 noted the repetitive failure of goniotomy surgery in older aniridic children and suggested that obliteration of Schlemm's canal by long-standing pressure elevation might explain these results.

This report describes the results of goniotomy for established glaucoma in 14 eyes of nine patients. Eighteen procedures were done with 2 procedures in each of five eyes. No surgical complications occurred. Only two operations were clearly beneficial. These results are discouraging and tend to support the conclusions of both Barkan<sup>3</sup> and Callahan.<sup>5</sup> The average age of these patients was nearly twice that of those who received prophylactic gonio-surgery. One of the two patients with a favorable result presented at 2 months of age; gonioscopy revealed no blockage of



the trabeculum by iris tissue, and a single goniotomy has controlled her intraocular pressure. This experience is reminiscent of Barkan's reported success in an infant with aniridia and glaucoma.<sup>3</sup>

The second patient whom I treated successfully with goniotomy had been carefully followed for the development of glaucoma by his own ophthalmologist. Referral occurred promptly at 8 years of age following the early recognition of glaucoma. Gonioscopy revealed densely pigmented uveal meshwork associated with anterior position of the peripheral iris. Goniotomy was done in the angle region with the least abnormality and controlled his pressure. Surgery was repeated to produce 10 hours of exposed trabecular meshwork. The fellow eye received prophylactic goniotomy surgery. He now has been followed 8 years without the recurrence of glaucoma.

These results suggest that, for most children with *established* aniridic glaucoma, goniotomy will probably be of little help. However, in infancy, when aniridia and glaucoma are present and the angle is found open, goniotomy may prove helpful and should be tried.

#### SUMMARY AND CONCLUSIONS

1. Repetitive gonioscopy of children with congenital aniridia confirms the presence of an angle abnormality which can be progressive and cause glaucoma. This abnormality features obstruction of the trabecular meshwork by variable mixtures of anterior migration of the peripheral iris and thickening of the uveal meshwork associated with a vascular net over exposed trabecular meshwork adjacent to the anterior edge of the iris.

2. Preliminary results of *prophylactic* gonio-surgery in 28 eyes of 16 children with an average age of 4 years was reported. This surgery was performed without complication and produced a permanent exposure of the trabecular meshwork to the anterior chamber for an average of 8 circumferential hours, if two procedures were performed. Preliminary results suggest a stabilization of eye pressures at least through childhood and encourage the continuation of these prophylactic operations on selected eyes with congenital aniridia.

3. *Therapeutic* goniotomy for established acquired glaucoma in congenital aniridia cannot be relied on, but may be a benefit for early detected cases or for glaucoma associated with aniridia in infancy.

#### REFERENCES

1. Blake EM: The surgical treatment of glaucoma complicating congenital aniridia. *Trans Am Ophthalmol Soc* 1952; 50:47.

2. Grant WM, Walton DS: Progressive changes in the angle in congenital aniridia, with development of glaucoma. *Trans Am Ophthalmol Soc* 1974; 72:207.
3. Barkan O: Goniotomy for glaucoma associated with aniridia. *Arch Ophthalmol* 1953; 49:1.
4. Nelson LB, Spaeth GL, Nowinski TS, et al: Aniridia: A review. *Surv Ophthalmol* 1984; 28:621.
5. Callahan A: Aniridia with ectopia lentis and secondary glaucoma. *Am J Ophthalmol* 1949; 32:28.

### DISCUSSION

DR DOUGLAS R. ANDERSON. I have greatly looked forward to hearing Doctor Walton's paper and learning the outcome of preventive angle surgery in aniridia. Most of us don't have enough cases of aniridia to develop a meaningful experience with the management of such cases. The report is of particular note when delivered by such a careful and thoughtful observer.

The results to date are happy. The pressure control has been fabulous. The complication rate of the procedure is quite low, at least in the hands of a meticulous surgeon who has experience with this type of procedure.

The statistic we don't know is how many of this group of patients would have experienced an elevated pressure had they not undergone surgery, and at what age such pressure would have developed. Those who would have been destined to develop pressure elevation late in the second decade of life, for example, are not yet old enough to document that they do not develop the pressure elevation at a time that they were otherwise destined to have it. I don't know how to estimate accurately the incidence of glaucoma in patients with aniridia. I myself rarely see a patient with aniridia who does not have glaucoma. However, no matter how numerous they might be, aniridic patients without glaucoma are not likely to present themselves to my glaucoma-oriented practice.

The uncertainty of the incidence of glaucoma in aniridia and the age at which glaucoma might begin reduces the certainty with which we can conclude that preventive angle surgery is helpful. We must acknowledge this scientific uncertainty, while at the same time acknowledging that the results we have heard today are remarkably promising and that there is a rational basis for thinking that the procedure would be beneficial.

This brings us to a major philosophical problem in clinical research. Clinicians often have to make a decision about whether or not to use a certain treatment approach without any firm scientific evidence one way or the other. If their best guess is that a certain treatment should work (perhaps because there is a reasonable rational basis for it), they may select such a treatment as being most likely beneficial for their patients. This is what a physician does—he makes a judgment about what he *thinks* is best for his patients. Then when he thoughtfully looks back on his experience, he may wish he knew with greater certainty that his judgment has been correct. When, acting as a scientist, a clinician decides he wants to *prove* that a certain treatment works, he must have some kind of unbiased control group against which to make a comparison. He may wish to

embark on a prospective controlled study. A randomized clinical trial would be the typical modern way to establish the efficacy of a certain treatment. However, if deep down in his heart a clinician believes that a certain treatment is very likely beneficial, he may not want to deny that treatment to half of the patients under his care in order to establish the fact conclusively. Someone who had balanced expectations and doubts about the benefits of the treatment is more ready to conduct the study.

The problem of prophylactic angle treatment in aniridia is ideally suited for such a study, as one eye (randomly selected) can be treated with preventive goniotomy and the other eye can be left untouched in symmetrical cases. The attractiveness of this kind of study is that if the procedure turns out to have complications or undesired long-term effects, only one eye of the patient has been subjected to the risk. Likewise, no matter which is more beneficial (to have the procedure or not to have the procedure), at least one eye of each patient will have the benefit of the best management.

If one believes a new treatment to be beneficial but can't convince his colleagues, there is a sense in which it may be unethical not to perform a randomized study. As long as it remains unproven, many clinicians will elect not to use the beneficial treatment, and both eyes of many patients across the country may go without the purported benefit of the preventive treatment. Thus while a clinician convinced of the benefit may not want to subject half of the eyes of his patients to a nontreatment status, by not performing the study he is in essence subjecting many more patients (the ones not under his personal care) to nontreatment instead of having the benefit of the procedure he believes to work. But is a physician's greater obligation to the individuals who seek his care or to society at large?

DR A. EDWARD MAUMENEE. Is Doctor Irene Maumenee in the audience? Sorry about that. I will try to give a comment and in the *Transactions* she can correct what I am saying. But some years ago I had a patient in his 60s who had total aniridia and 20/20 visual acuity. This was such a rare entity to me that I just couldn't believe it and so I sent the patient to Doctor Irene, and she and Doctor Fred Elsas went up to Pennsylvania and studied the family. I think they studied something like 190 members of the family and the patients wanted to know why they were being studied since they felt they were all entirely normal with nothing wrong with them. None of those patients had glaucoma, none had corneal calcification, and none had cataracts. So it appears that there is congenital hereditary aniridia of one type that does not have all the complications and there is aniridia of another type that has the complications that Doctor Walton mentioned. I would like to ask you if you looked at the family history of your patients to find out which one of the two groups they fell into. Did the parents have the calcification of the cornea, cataracts, and glaucoma?

DR DAVID WALTON. The incidence of glaucoma in one parent of my patients was very high. The numbers are in the paper that I just presented. I think Doctor

Elsas' patients represent a special group; they did have a very low incidence of glaucoma. There are recognizable subsets of aniridia. This includes two pedigrees with cerebellar aniridia, another subset with a chromosome deletion (11p<sup>-</sup>) with a very high propensity for renal tumors, as well as the most common autosomal dominantly inherited type. So, there are recognizable groups within the family of aniridia patients. Also, the expression of the disease is very variable, even within the same family or sibship. So, the expression of the problem is really very variable.

I would like to emphasize that I did find it very difficult to deny surgery and treat one eye. I don't have the answer to this dilemma, but I think that it is not asking too much to commit ourselves, yourselves, to the careful examination of these patients, if not in preparation for prophylactic surgery, at least to find out better what's going on in them. With this information and experience I think the clinician can make intelligent choices, especially in respect to the importance of the gonioscopic findings and later in considering prophylactic gonio-surgery.

When one sees a young aniridic child, their eyes are beautiful, the corneas are clear, the lenses are beautiful; their eyes stand out like pearls on their faces in contrast to the appearance of their parents after so much opacification has occurred.

The average interval from first seeing a patient until surgery was done was approximately 2 years. They were followed serially, and when it was established that there was significant obstruction, or if not obstruction at least covering of the meshwork, surgery was considered. Begin with careful examinations because it is necessary to be familiar with the aniridia angle before one can feel comfortable with gonio-surgery.