

# Clinical Investigation

---

## Phase II Trial of $\beta$ -All-trans-Retinoic Acid for Cervical Intraepithelial Neoplasia Delivered via a Collagen Sponge and Cervical Cap

VIVIAN GRAHAM, RN; EARL S. SURWIT, MD; SHELDON WEINER, MD, and  
FRANK L. MEYSKENS, Jr, MD, Tucson

*Retinoids are effective suppressors of the phenotypic development of cancer in many animal systems, whether the process is initiated by chemical, physical or viral carcinogens. Cases of cervical intraepithelial neoplasia are excellent for studying the effectiveness of retinoids as chemopreventive agents because the process can be closely followed by serial colposcopic and pathologic (cytology or biopsy) means and changes in the condition safely monitored. We have previously conducted a phase I study of trans-retinoic acid (Tretinoin) given topically by a collagen sponge and cervical cap. A dose of 0.372% was selected for phase II trial. We have treated 20 patients with topical retinoic acid, and a complete response with total regression of disease was obtained in 50%. Systemic and cervical side effects were mild and vaginal side effects moderate but tolerable. These results provide a clinical basis for a randomized, double-blind phase III study to definitely answer the question of whether retinoic acid is an effective chemopreventive agent for cervical cancer.*

(Graham V, Surwit ES, Weiner S, et al: Phase II trial of  $\beta$ -all-trans-retinoic acid for cervical intraepithelial neoplasia delivered via a collagen sponge and cervical cap. West J Med 1986 Aug; 145:192-195)

---

Vitamin A and its natural and synthetic derivatives (retinoids) can inhibit proliferation of transformed cells in many biologic systems including murine and human melanoma, human neuroblastoma and promyelocytic cells.<sup>1-5</sup> They also block the phenotypic progression of preneoplastic cells to cancer both in vitro and in vivo.<sup>6-8</sup> In addition, clinical responses of premalignant and malignant skin and mucosal lesions to retinoids have been documented.<sup>9-14</sup>

To attempt to reverse established preneoplasia such as cervical dysplasia using chemoprevention is a relatively new concept. Dietary studies have also suggested that total vitamin A intake is low in patients with this disease.<sup>15</sup> Cervical dysplasia or cervical intraepithelial neoplasia is an ideal model for the study of chemoprevention in humans because it is a well-defined pathologic disorder that can be easily evaluated on an outpatient basis. This condition is also suitable for topical therapy, thereby possibly obviating many of the systemic side effects of the chosen intervention.

In 1981 we tested a delivery system using a collagen sponge and diaphragm, but found that patients had undesirable vulvovaginal toxicity because of leakage of retinoids around the diaphragm.<sup>16</sup> We next developed a new delivery device consisting of a collagen sponge and a cervical cap.<sup>17,18</sup> A phase I study of  $\beta$ -all-trans-retinoic acid (TRA) using the sponge and cap established that after two days evidence of effect on the cervix was present, four days of therapy was the maximum duration of treatment that most patients conveniently tolerated and side effects were tolerable with this regimen. A dose of 0.372% was determined for phase II studies.<sup>18</sup> The phase I study also suggested a dose-response effect, with only 2 of 14 patients responding at TRA concentrations of 0.5% to 0.116%, while 10 of 22 patients responded at concentrations of 0.158% to 0.484%. Pharmacokinetic studies using tritiated TRA have also shown rapid uptake of the retinoid into cervical tissue, with large amounts measured after four hours and nearly complete clearing by 24 hours. No

---

From the Departments of Medicine, Obstetrics and Gynecology, University of Arizona Health Sciences Center, and the Arizona Cancer Center, Tucson. Presented in part at the 20th annual meeting of the American Society of Clinical Oncology, Toronto, Ontario. Supported in part by the National Cancer Institute (grants Nos. CA 27502, CA 40889 and NO-1-CM 17500) and Ortho Pharmaceuticals, Raritan, NJ. Reprint requests to Frank L. Meyskens, Jr, MD, Arizona Cancer Center, Tucson, AZ 85724.

measurable amount of retinoids was detected in serum as determined by high-pressure liquid chromatography.<sup>19</sup> We report here the results of a phase II trial of TRA (delivered by a collagen sponge and cervical cap device) for cervical intraepithelial neoplasia.

**Patients, Materials and Methods**

*Patient Characteristics*

For all patients in this study (in accord with a protocol approved by the University of Arizona Institutional Review Committee), a colposcopically directed biopsy specimen was used to determine if dysplasia was mild (9 patients), moderate (11 patients) or severe (5 patients). For all patients, a negative endocervical curettage and results of the pretreatment Papanicolaou smear were consistent with the ectocervical biopsy finding. The lesion and the entire transformation zone were completely visualized. The extent of the lesion was documented by colpophotographs.

*TRA Administration*

TRA was delivered in a cream-based vehicle that contained polyethylene 400, butylated hydroxytoluene and 55% alcohol and was a gift of G. Thorne, MD (Ortho Pharmaceuticals, Raritan, NJ). A dose of 1.0 ml 0.372% TRA was chosen based on our phase I study.<sup>18</sup>

The delivery system consisted of a cervical cap that was lined with a collagen sponge. The characteristics and properties of the collagen sponge and delivery system have been extensively described previously.<sup>17-20</sup> The cervical cap was made of the hydrogel Hypan (Sky Polymers, Princeton, NJ), which adheres to wet tissue surfaces by differential osmotic pressures. The sponges were made from pure collagen isolated from bovine skin, swollen at pH 3.0 and stabilized into the physical form of a sponge layer. Glutaraldehyde was used as a cross-linking agent to provide high resilience and fluid-binding capacity. The pore size was 400 nm (range 80 to 1,400). The sponges were cut into thin, round wafers approximately 3 to 4 mm thick and an appropriate diameter to fit the cervical caps.

One milliliter of TRA was applied to the sponge and this device was carefully inserted into the top of the vaginal vault. The position was checked to ensure placement of the cap around and against the cervix. A new collagen sponge-cervical cap device with TRA was inserted daily for four days. Patients returned at three, six and nine months for follow-up and maintenance treatment consisting of TRA at a concentration of 0.372% inserted daily for two days. The frequency and duration of maintenance treatment were selected based on the following factors: two days of treatment was the minimum time at which cervical changes were evident, retreatment for two but not for four days was acceptable to most patients, responses in the phase I trial lasted three to four months and this frequency of retreatment was deemed acceptable by most patients in a poll conducted during planning of the phase II study.

*Evaluation of Efficacy and Side Effects*

Patients were followed up at three-, six- and nine-month intervals with Papanicolaou smears and colposcopy. A smear having no features indicative of dysplasia or cancer cells was considered negative. At 12 months, all patients were evalu-

ated for response with Papanicolaou smear and colposcopy. If results of either the smear or colposcopy examination were positive, ectocervical biopsy specimens were taken from the colposcopically identified lesion or the previous site of disease. The data involving the changes have been reported only for the end point of the study. The smear and biopsy results were scored blindly. Patients were considered to have a complete response if both the Papanicolaou smear and findings of colposcopy were negative or if both the Papanicolaou smear and colposcopically directed biopsies were negative 12 months after the start of treatment. At the end of the study, 15 patients had a repeat biopsy (10 nonresponders and 5 of the complete responders).

Toxicity was evaluated on days 1 through 4, day 8 and at the completion of each maintenance treatment by clinical evaluation, colposcopy and colpophotographs. Table 1 outlines the grading system for cervical and vaginal toxicity.

**Results**

*Response to Treatment*

A total of 25 patients began the phase II trial, of whom 20 were considered evaluable. Two patients were removed from the study during the induction treatment, one because of family illness and one because of inability to tolerate the cervical cap. Two patients were lost to follow-up after induction and one patient after the first maintenance treatment.

In 50% (10/20) of the patients, disease completely disappeared. Of the ten patients with a complete response, five had mild and five moderate dysplasia (Table 2). No difference in response rate was seen in patients with mild and moderate dysplasia; too few patients had severe dysplasia to evaluate. Photographs of the cervix of a patient with moderate dysplasia show the cervix before (Figure 1, left) and after (Figure 1, right) treatment.

The comparison of responders to nonresponders by the number of quadrants involved with cervical intraepithelial neoplasia, established by colposcopic examination at the beginning of treatment, is presented in Table 3. The relationship of the extent of cervical involvement to the response rate was

TABLE 1.—Clinical and Colposcopic Grading for Cervical and Vaginal Side Effects

Grade	Description
0 . . . . .	None
1+ (Mild) . . . . .	Cervical erythema; vaginal burning, irritation, itching or discharge not bothersome to patient
2+ (Moderate) . . . . .	Cervical erythema, vascularity; vaginal burning, itching or irritation bothersome to patient; erythema or increasing vascularity of vaginal mucosa, or both
3+ (Severe) . . . . .	Cervical ulceration; vaginal burning, itching, irritation or discharge leading to discontinuation of treatment; ulceration or bleeding, or both

TABLE 2.—Comparison of Grade of Dysplasia to Response

Severity of Dysplasia	Complete Response*
Mild . . . . .	5/8 (62%)
Moderate . . . . .	5/10 (50%)
Severe . . . . .	0/2

\*Number of patients with response versus number treated.

as follows: 100% of patients with one-quadrant disease, 50% with two- and three-quadrant disease and no patients with four-quadrant disease. In seven of the complete responders, 25% to 50% of their cervix was involved with cervical intra-epithelial neoplasia, while in three patients 75% of the cervix was involved at the start of the treatments.

No patient in this series showed worsening of their dysplasia. Biopsy results in the ten nonresponders showed that five patients had improvement in the severity of their lesion whereas five patients showed no change.

*Side Effects and Toxicity*

The cervical side effects during the induction and maintenance treatments are summarized in Table 4. Acceptable cervical toxicity (mild to moderate) was seen in 78% of patients (18/23) during the induction treatments. Inflammation was the most frequently noted side effect, occurring in 11 patients. Increased cervical vascularity was recorded for seven patients. During maintenance treatments cervical side effects were minimal, with 9 of 50 occurrences showing mild to moderate toxicity. One patient experienced severe toxicity with cervical bleeding during the induction and first maintenance treatments.

Vaginal side effects are also summarized in Table 4. Vaginal toxicity occurred more frequently during induction as compared with the three maintenance treatments. During induction, 12 of 23 patients (52%) experienced no or mild toxicity, with increased vaginal discharge and itching occurring most frequently. During the maintenance treatments,

80% of the patients had no or mild toxicity, with increased vaginal discharge occurring most frequently. One patient experienced severe toxicity during the induction and first maintenance treatment.

The systemic side effects that occurred were very mild and included dry skin, chapped lips, decrease in appetite, change

TABLE 3.—Comparison of Extent of Cervical Involvement to Response

Number of Quadrants	Complete Response	No Response*
1 . . . . .	3	0
2 . . . . .	4	3
3 . . . . .	3	4
4 . . . . .	0	3
Total . . . . .	10	10

\*Two patients received no maintenance therapy, one patient received one maintenance dose.

TABLE 4.—Cervical and Vaginal Side Effects

Severity of Side Effects	Induction		Maintenance*	
	Cervical	Vaginal	Cervical	Vaginal
None . . . . .	4	2	41	19
Mild . . . . .	11	10	8	22
Moderate . . . . .	7	10	1	9
Severe . . . . .	1	1	1	1

\*Total number of occurrences at three-, six- and nine-month treatments.

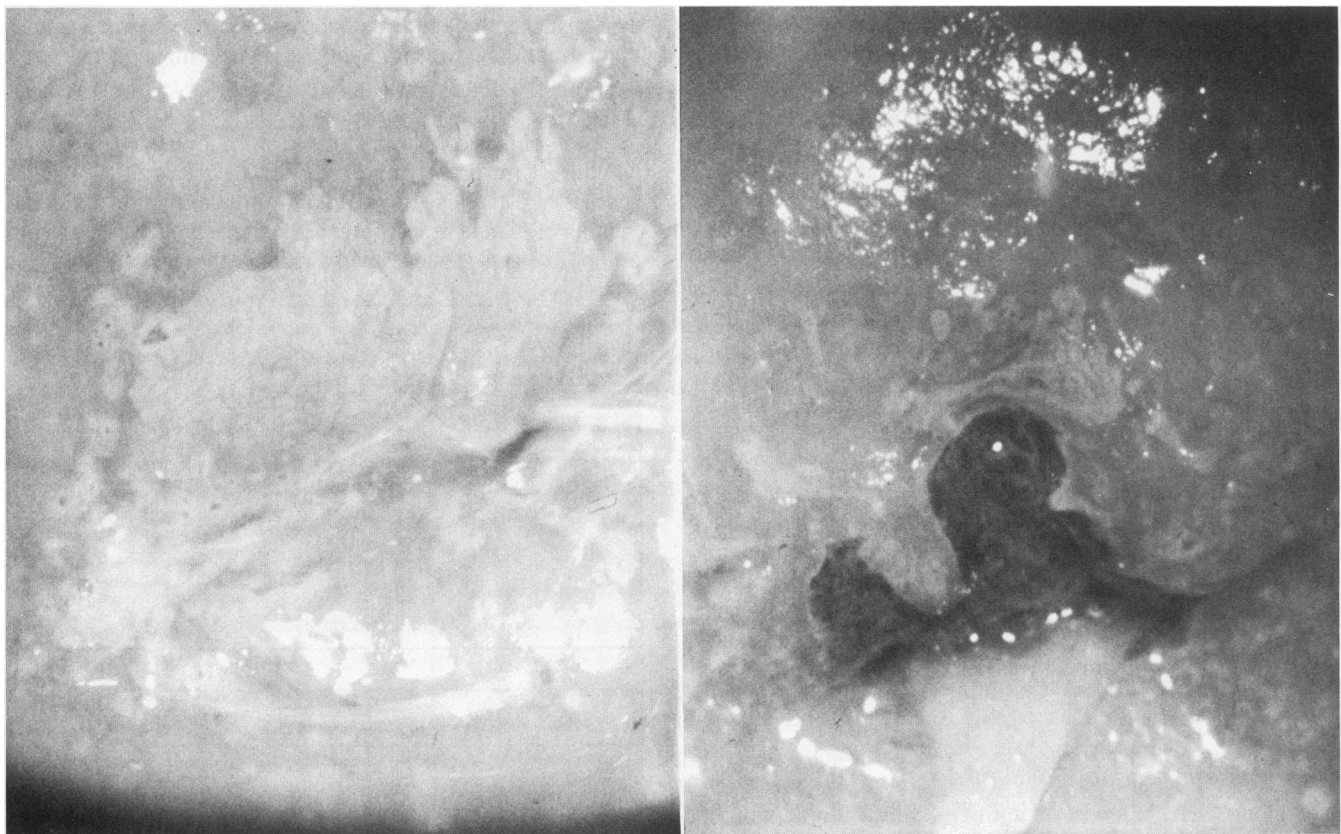


Figure 1.—Colposcopic view of a patient with moderate cervical dysplasia. Left, Day 1 before therapy. White epithelium is present on the anterior surface of the cervix with mosaicism evident from 9 to 12 o'clock. Right, Day 374 after induction and three maintenance treatments, three months after last treatment. A colposcopic examination shows a normal cervix.

in moods, fatigue, headaches, fever and abdominal cramping. These systemic side effects occurred more frequently during induction (9/23 patients) as compared with the three maintenance treatments (3/16 patients). Subsequent follow-up of the ten patients in complete remission a minimum of one year after the last application showed no late sequelae and nine of ten patients remained free of disease.

## Discussion

The data from this study suggest that TRA suppressed cervical intraepithelial neoplasia in 50% of patients as indicated by complete regression of their disease. Whether a more intense or longer treatment would have produced a higher response rate needs to be explored and will influence, to some degree, how long these patients remain in complete response without subsequent retreatment. The severity of the dysplasia did not appear to affect the rate of response as five of eight patients with mild dysplasia and five of ten patients with moderate dysplasia had a complete response. The extent of cervical involvement with dysplasia may alter the response to topical retinoids as there was a trend towards a better response in those patients with less involvement by the cervix (Table 3). More experience will be required, however, to definitively determine whether the degree or extent of dysplasia affects response rate.

The systemic side effects seen during this phase II trial were mild and also occurred less frequently in each of the three maintenance treatments than during the induction treatments. This regression of disease was achieved with negligible cervical toxicity, as was also reported in our phase I trial.<sup>18</sup> Vaginal side effects, although commonly experienced during the induction treatment, were only mild to moderate and acceptable to the patients. Furthermore, during the three maintenance treatments, vaginal toxicity was seen less often and was only mild (Table 4).

The substantial suppression of cervical intraepithelial neoplasia and the absence of significant side effects during the induction and maintenance treatments provide an important basis to definitely answer whether TRA is an effective chemopreventive agent for cervical cancer. Similar conclusions have recently also been reached by Romney and colleagues who conducted a feasibility study of topical retinyl acetate administered by a vaginal applicator.<sup>21</sup> The eventual general clinical usage of retinoids in women of child-bearing age will need to be tempered by the knowledge that these agents<sup>22</sup> are potentially embryopathic and that cryosurgery and laser therapy are well proved as effective treatment for this disease. The end point of this trial and our other studies has not been to find a new treatment for cervical dysplasia. Rather, we are

attempting to define the role of retinoids as an effective chemopreventive agent by reversing a preneoplastic process.

Although spontaneous regression rates for mild to moderate dysplasia may be as high as 30%, the time over which this would appear would be longer than the interval for the response seen in this study. Nevertheless, to definitely answer the question of whether TRA is an effective chemopreventive agent for cervical cancer, a phase III randomized double-blind study has been initiated to compare TRA 0.372% with a placebo cream in patients with moderate and severe dysplasia. The broad implications of a positive chemoprevention trial in this area to the field of oncology are substantial.

## REFERENCES

1. Lotan R: Effects of vitamin A and its analogues (retinoids) in normal and neoplastic cells. *Biochim Biophys Acta* 1980; 605:33-81
2. Meyskens FL Jr, Fuller BB: Characterization of the effects of different retinoids on the growth and differentiation of a human melanoma cell line and selected subclones. *Cancer Res* 1980; 40:2194-2196
3. Sidell N: Retinoic acid-induced growth inhibition and morphologic differentiation of human neuroblastoma cells in vitro. *JNCI* 1982; 68:589-596
4. Breitman TR, Selonick SE, Collins SJ: Induction of differentiation of the human promyelocytic leukemia cell lines (HL60) by retinoic acid. *Proc Natl Acad Sci USA* 1980; 77:2936-2940
5. Meyskens FL Jr, Salmon SE: Inhibition of human melanoma colony formation by retinoids. *Cancer Res* 1979; 39:4055-4057
6. Sporn MB, Dunlop NM, Newton DL, et al: Prevention of chemical carcinogenesis by vitamin A and its synthetic analogues (retinoids). *Fed Proc* 1976; 35:1332
7. Peck GL: Chemoprevention of cancer with retinoids. *Gynecol Oncol* 1981; 12:331-340
8. Bertram JS: Inhibition of neoplastic transformation in vitro by retinoids. *Cancer Surveys* 1983; 2:243-262
9. Bollag W: Therapy of epithelial tumors with an aromatic retinoic acid analogue. *Chemotherapy* 1975; 21:236-245
10. Koch HF: Biochemical treatment of precancerous oral lesions: The effectiveness of various analogues of retinoic acid. *J Maxillofac Surg* 1978; 6:63-69
11. Levine N, Meyskens FL Jr: Topical vitamin-A-acid therapy for cutaneous metastatic melanoma. *Lancet* 1980; 2:224-226
12. Moriarity M, Dunn J, Dawagh A, et al: Etretinate in treatment of actinic keratosis. *Lancet* 1982; 1:364-365
13. Meyskens FL Jr, Gilmartin E, Alberts DS, et al: Activity of isotretinoin against squamous cell cancers and preneoplastic lesions. *Cancer Treat Rep* 1982; 66:1315-1319
14. Kessler JF, Levine N, Meyskens FL Jr, et al: Treatment of cutaneous T-cell lymphoma (mycosis fungoides) with 13-*cis* retinoic acid. *Lancet* 1983; 1:1345-1348
15. Romney SL, Palan PR, Outlagupta C, et al: Retinoids and the prevention of cervical dysplasias. *Am J Obstet Gynecol* 1981; 141:890-894
16. Surwit EA, Graham V, Droegemueller W, et al: Evaluation of topically applied *trans*-retinoic acid in the treatment of cervical intraepithelial lesions. *Am J Obstet Gynecol* 1982; 143:821-823
17. Dorr RT, Surwit EA, Meyskens FL Jr, et al: In vitro retinoid binding and release from a collagen sponge material in a simulated intravaginal environment. *J Biomater Res* 1982; 16:839-850
18. Meyskens FL Jr, Graham V, Chvapil M, et al: A phase I trial of  $\beta$ -all-*trans*-retinoic acid delivered via a collagen sponge and a cervical cap for mild or moderate intraepithelial cervical neoplasia. *JNCI* 1983; 71:921-925
19. Peng YM, Alberts DS, Graham V, et al: Cervical tissue uptake of all-*trans*-retinoic acid delivered via a collagen sponge-cervical cap delivery device in patients with cervical dysplasia. *Invest New Drugs*, in press, 1986
20. Chvapil M: Collagen sponge: Theory and practice of medical applications. *J Biomed Mater Res* 1977; 11:721-726
21. Romney SL, Dwyer A, Stagles S, et al: Chemoprevention of cervix cancer: Phase II: A feasibility study involving the topical vaginal administration of retinyl acetate gel. *Gynecol Oncol* 1985; 20:109-119
22. Lammer EJ, Chen OT, Hoar RM, et al: Retinoic acid embryopathy. *N Engl J Med* 1985; 313:837-841