

# A NEW CAMERA FOR STEREOSCOPIC FUNDUS PHOTOGRAPHY

BY *David D. Donaldson*, M.D.\*

IN RECENT YEARS, the importance of depth relationships within the fundus has become increasingly evident and this has been largely a result of the use of the binocular ophthalmoscope. The depth aspects of such conditions as excavation of the disc in glaucoma and the protrusion of the disc in papilledema are obvious. However, more subtle depth relationships in, for example, macular lesions, conditions involving the choroid, and location of vessels may be overlooked or not readily appreciated. In addition, when following a fundus lesion, such as a tumor, by means of photography, the addition of the third dimension greatly enhances this method. Thus, there is little doubt that the stereoscopic fundus photograph has a distinct advantage over that of the conventional type for the recording of fundus pathology.

For many years stereoscopic photographs have been made by various means. Apparently Thorner<sup>1</sup> in 1909 was the first to publish a method of taking such pictures. Although he published only one fundus photograph, a study of his equipment (Figures 1 and 2) indicates that it was complicated and not well suited to clinical use. The instrument utilized the indirect ophthalmoscopic principle and was arranged so that the pupillary area was divided in half in a vertical fashion. The illumination entered one half of the pupil while the other half was used for the emerging rays. By means of an ophthalmoscope lens these rays then formed an inverted image which was, in turn, photographed. After the first picture was taken, the instrument was inverted so that the opposite sides of the pupil were now used for the illumination and the emerging rays. The second picture was then taken and this resulted in a stereoscopic pair of photographs. It is interesting to note that the light used for focussing

\*From the Howe Laboratory, the Harvard University Medical School, and the Massachusetts Eye and Ear Infirmary, Boston, Massachusetts. This investigation was supported in part by United States Public Health Service Research Grant NB-01851 from the National Institute of Neurological Diseases and Blindness.

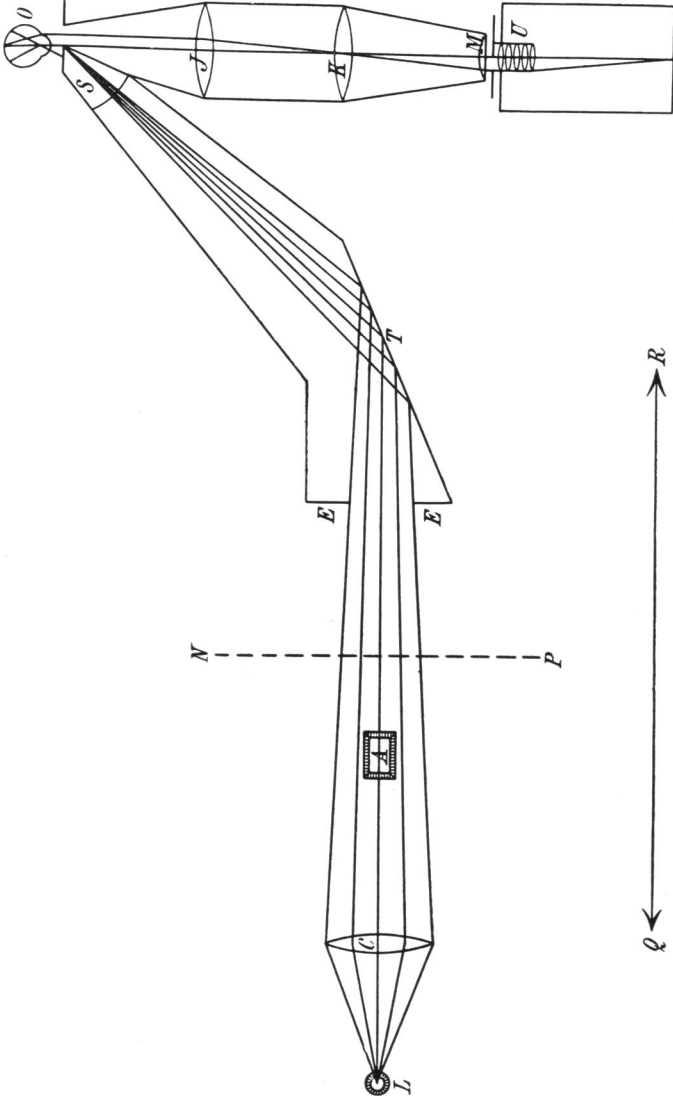


FIGURE 1. DIAGRAMMATIC DRAWING OF THORNER'S FUNDUS CAMERA.  
 L, kerosene lamp, A, magnesium powder flash. (See text for description.)




FIGURE 2

Two views of Thorner's fundus camera illustrating how it could be inverted between the taking of the first and second picture which resulted in a stereoscopic photograph. (See text for description.)

purposes was a kerosene lamp, but the picture was taken by means of igniting magnesium powder in front of the lamp.

Although several fundus cameras had been made by the time Nordenson<sup>2</sup> first reported his camera in 1915, it was the method that he used which subsequently made stereoscopic fundus photography a feasible procedure. The camera was based on principles that had already been laid down by Gullstrand.<sup>3</sup> The basic principle was that of central reflex free ophthalmoscopy. Gullstrand said that while it was necessary that the portion of the fundus being observed must also be illuminated, it was also necessary "that no part of the cornea or crystalline lens of the patient's eye shall be at once in the region of radiation of the illumination system and also in that of the observation system." In other words diffusely reflected light from the cornea and lens may be excluded if the emerging rays from the eye do not pass through the portion of the cornea and the lens being used for illumination of the fundus. He also stated that no light regularly reflected from the three reflecting surfaces of the eye will enter the pupil of the observer's eye if 2.4 mm. of the central portion in the plane of the entrance pupil of the patient's eye is shielded from the light. Gullstrand also produced data from which Zeiss made the first aplanatic ophthalmoscope lens requiring an aspheric surface. It was this lens which eliminated many of the aberrations and thus made possible the excellent detail in the fundus photographs produced by the Zeiss-Nordenson camera (Figure 3). This camera first became available in 1925. Nordenson originally used sunlight but Zeiss was able to design a special shutter so that the carbon arc light could be used. Although this light source was far from satisfactory, it was the best available for almost thirty years until Hansell and Beeson<sup>4</sup> introduced the xenon arc tube in 1953. Since that time, of course, the electronic flash tube (strobe light) has become an excellent source of light for the fundus camera. Not only does the new Zeiss Fundus Camera utilize this flash tube, but several other manufacturers also incorporate it in their cameras. As will be shown presently, it was the Zeiss-Nordenson Fundus Camera (Figure 3) which was used almost exclusively for stereoscopic fundus photography over a period of many years and thus it seems appropriate to describe the essential features of this camera. The three major components are: (1) an arrangement for introducing light into the eye, (2) an arrangement for collecting the emerging rays from the eye to form an image of the retina, and (3) a small reflex camera to photograph that image.

As already mentioned, the camera uses a carbon arc for illumination. Light from the carbon arc L is focussed on a crescent-shaped slit at S.

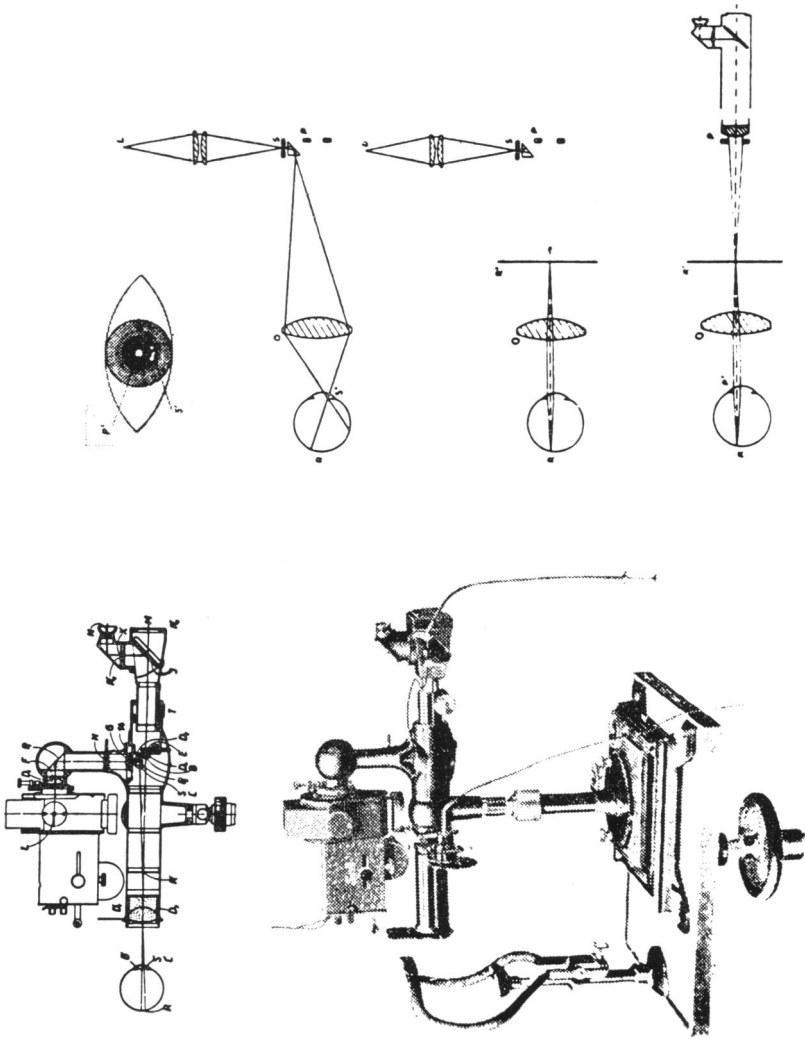


FIGURE 3. ZEISS-NORDENSON CAMERA.  
 (See text for description.)

The image of this slit is projected by means of a right-angle prism to the ophthalmoscope lens O which focusses it in the iris plane at S<sup>1</sup> and is placed just inside the lower pupillary margin. Therefore light enters the eye through the lower portion of the cornea to illuminate the retina. Rays of light from the retina R emerge from the eye through the central portion of the cornea to be collected by the ophthalmoscope lens O and brought to focus in the plane R<sup>1</sup>. A small reflex camera is focussed on the inverted serial image R<sup>1</sup> and so the retinal photograph is achieved. As stated before, the light is introduced into the eye to illuminate the fundus through the lower portion of the cornea while the emerging rays leave the eye through the central portion of the cornea. This arrangement strictly is in accordance with the principle of Gullstrand already discussed and eliminates all reflexes except for the one which is caused by internal reflection from the front (aspherical) surface of ophthalmoscope lens. This causes a white, somewhat irregular, central spot in the resulting photographs and this reflex is particularly objectionable in the stereoscopic fundus pictures which will subsequently be made with this camera. It was Hartinger<sup>5</sup> who introduced the method of removing this distressing reflex by placing a small, opaque spot on the back surface of the lens in the area where this light was focussed as it was reflected from the front surface. Thus, the reflex was absorbed by the spot and this resulted in a black area in the fundus photographs which was far less objectionable. Zeiss incorporated this feature in their camera. Recently, the spot has been made much smaller owing to the more focal type of illumination being used. In the new Zeiss Fundus Camera it is only 0.3 mm. in diameter and except in high myopes does not produce any visible defect in the photograph.

In 1927 Nordenson<sup>6</sup> proposed a method of taking stereoscopic fundus photographs with his camera and within that year Metzger,<sup>7</sup> Bedell,<sup>8</sup> Wessely,<sup>9</sup> and Stock<sup>10</sup> also described methods of taking stereoscopic fundus photographs. Metzger and Bedell were the only ones to publish photographs but these are remarkably good for the stereoscopic effect. The detail also appears to be of fairly good quality but this is difficult to evaluate owing to the small size (about 1½ inches in diameter) at which they are reproduced. However, all these photographs were made by a method which required taking two successive exposures in order to obtain the stereoscopic pair of pictures. Generally the Zeiss-Nordenson Camera was used. The common method was to have the patient change fixation slightly between the two exposures, but Bedell<sup>8</sup> and recently Allen<sup>11</sup> have advocated shifting the camera while the patient maintains the same

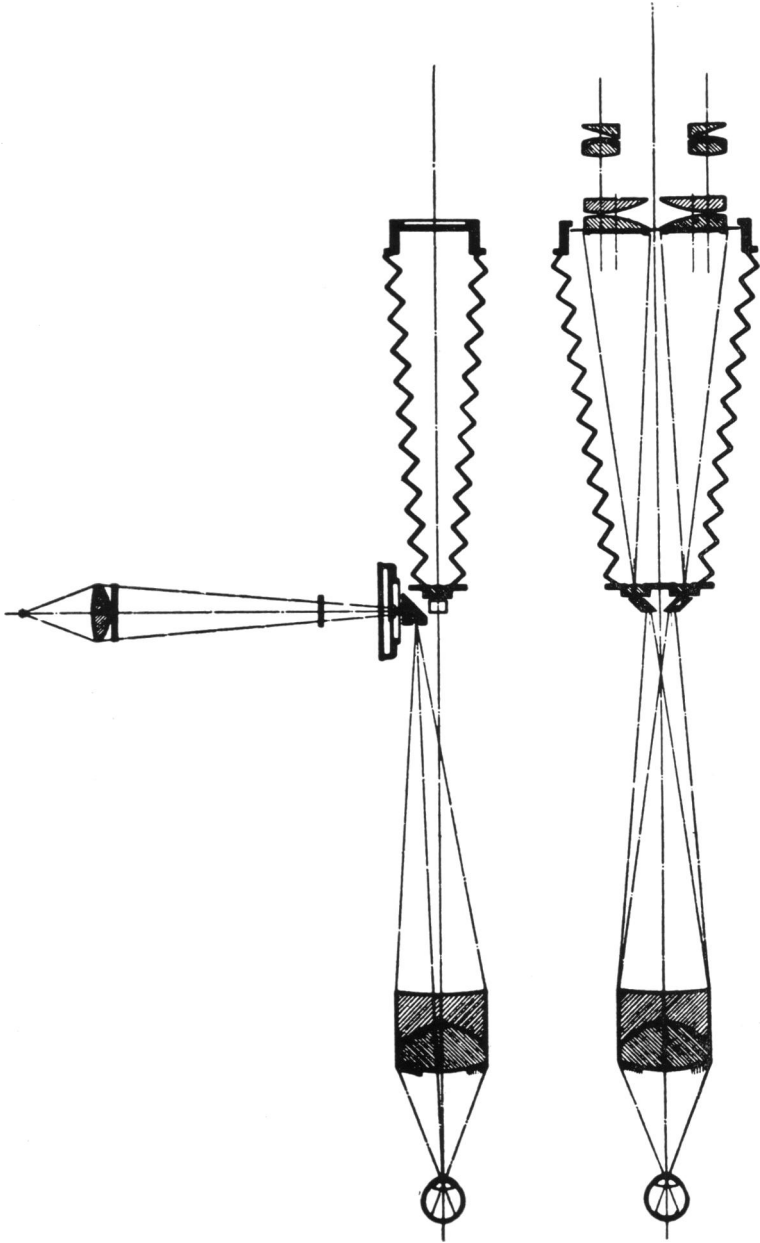


FIGURE 4  
 Diagrammatic drawing of light pathways in Nordenson's stereoscopic fundus camera. (See text for explanation.)

fixation. Stenstrom<sup>12</sup> has suggested rotating the camera through a small arc between the two exposures to produce the stereoscopic effect. This method of successive stereoscopic fundus photography can produce good results in certain instances but has several serious disadvantages. First, satisfactory stereoscopic photographs cannot be obtained in patients who cannot fixate accurately. Common reasons for this are poor central vision, nystagmus, and blindness of the second eye. Secondly, fixation between exposures is generally impossible in patients who cannot co-operate such as children, mentally retarded persons, and very sick or semi-comatose patients. Thirdly, the stereoscopic effect can be poor or completely lost because of changes in various factors between the two exposures such as focus, position of the patient's head, and light intensity. Fourthly, a dependably consistent depth effect cannot be obtained in pictures taken subsequently because it is practically impossible to duplicate exactly the degree of shift of the camera or the amount of fixation required to produce the stereoscopic effect. Even small differences can produce appreciable variations in the final result.

Some attempts have been made to photograph the fundus stereoscopically by taking the two pictures simultaneously but these methods have not been entirely satisfactory. As early as 1930, Nordenson<sup>13</sup> reported taking such photographs with a specially constructed Zeiss-Nordenson Camera (Figures 4 and 5). His report is brief and contains no details as to the optical principles used in the new camera. It is obvious that the illumination system and the ophthalmoscope lens are identical to those used in the conventional Zeiss-Nordenson Camera. He mentions a pair of small prisms just in front of the camera lenses (Figure 4), but he does not describe them further. At the time the article was written he was not able to observe the fundus images binocularly while focussing. He also states that a rather distressing distortion is produced in which the fundus image looks convex rather than concave as it should. Also, he says the pictures do not exhibit the definition found in the monocular type but that this disadvantage is outweighed by the advantage of the stereoscopic effect produced. Another difficulty which is evident from the published pictures is the unevenness of illumination of the fundus. Although this defect exists in all three of the pictures shown, in one picture less than half of the fundus is adequately illuminated.

In 1953 Norton<sup>14</sup> made stereoscopic fundus photographs by attaching a 35-mm. stereocamera to a Bausch & Lomb binocular ophthalmoscope. Even with a xenon arc lamp which he later added,<sup>15</sup> the






FIGURE 5. NORDENSON'S STEREOGRAPHIC FUNDUS CAMERA SHOWING THE BINOCULAR EYE PIECES.

exposure times for color films were longer than is desirable. Moreover, the published photographs indicated a serious lack of detail with this system. In 1957 Drews<sup>16</sup> reported having taken simultaneous stereoscopic fundus photographs using the principle of indirect ophthalmoscopy but the literature does not indicate that he ever refined his apparatus to obtain satisfactory pictures.

Because there was no known equipment which would produce consistently good simultaneous fundus photographs, the author undertook to design and make such a camera which is described here.

#### DESCRIPTION

The indirect ophthalmoscopic principle is used in this fundus camera and is illustrated in Figure 6. The fundus of the patient's eye (A) has an inverted image (C) formed by the aspheric lens (B) which is a modification of the one now used on the new Zeiss Fundus Camera designed by Littmann.<sup>17</sup> This inverted image is then re-imaged at the film plane (F) by the "field" lens (D) and camera

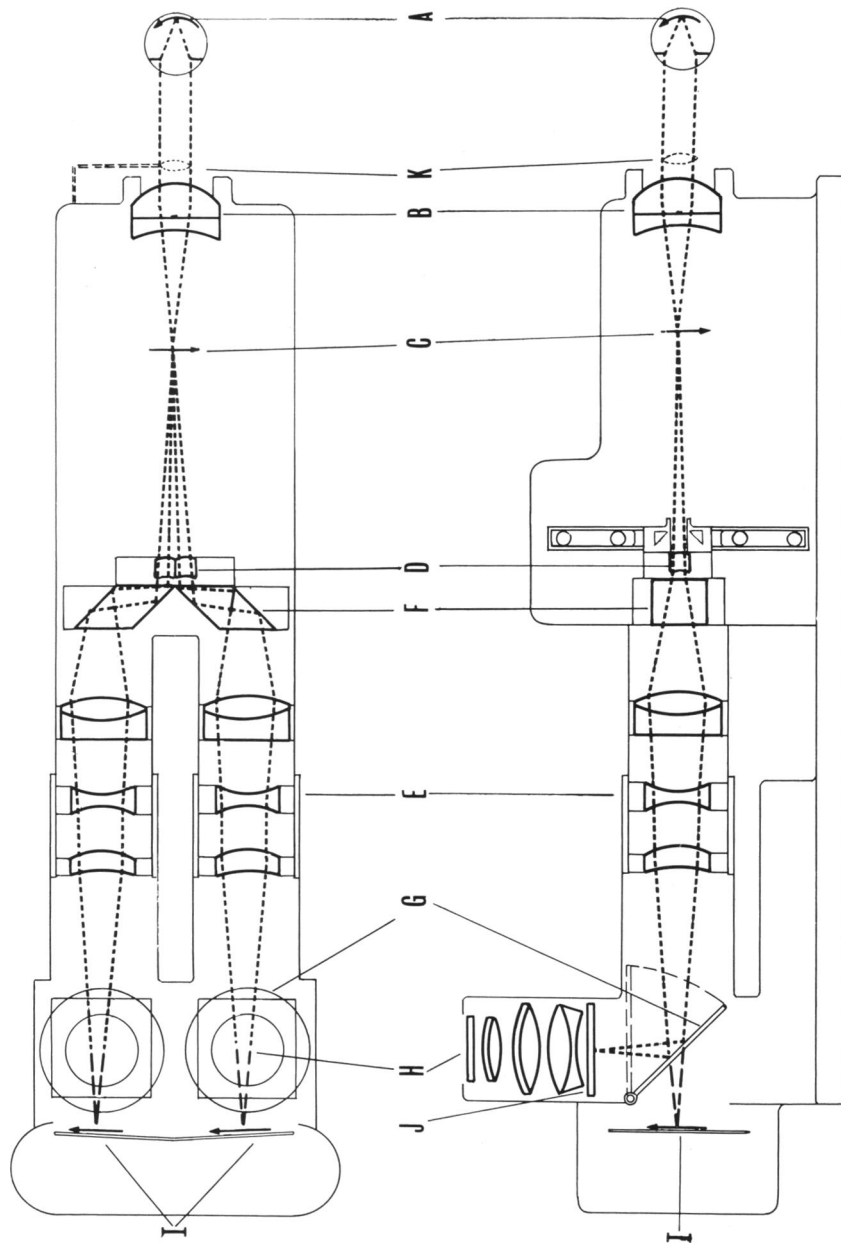


FIGURE 6. DIAGRAMMATIC DRAWING OF THE OPTICAL SYSTEM OF AUTHOR'S CAMERA, WITH TOP VIEW (ABOVE) AND SIDE VIEW (BELOW).

A, fundus of patient's eye; B, aspheric ophthalmoscope lens; E, paired camera lenses; F, modified rhomboid prisms; G, reflex mirror; H, ocular (focussing eyepieces); I, film plane; J, reticle; K, small plus spherical lens. See text for description of optical pathways and imagery.

lens of Zeiss design (E) both of which are paired to produce the stereoscopic photographs. The center-to-center distance of the "field" lenses is 9 mm. The modified rhomboid prisms (F) produce the proper separation of the paired images at the film plane. The modification consists of having one hypotenuse of each rhomboid prism ground and polished to 133½ degrees (rather than the conventional 135 degrees) to the face of the prism. This causes the two sets of rays emerging from the prisms to be parallel with each other rather than diverging. Because the focus of the image at the film plane (I) is not exactly at right angles to the focussing rays, it is necessary to angle each film carrier approximately three degrees.

Focussing of the image is accomplished by means of a double reflex mirror system (G) so that when the film holder and reflex housing is moved back and forth, the exact focus can be determined by observing the image binocularly through a pair of oculars (H). These oculars are high power (20x) and have a wide field so that the entire fundus image formed by the camera can be visualized. A conventional reticle (J) at the focal plane is used to avoid errors in focussing due to the accommodation of the person taking the photograph.

The lighting system illustrated in Figures 7 and 8 utilizes two electronic flash tubes (T) which are energized by a 200 watt-seconds (Joules) variable voltage power supply. The tubes used are of the

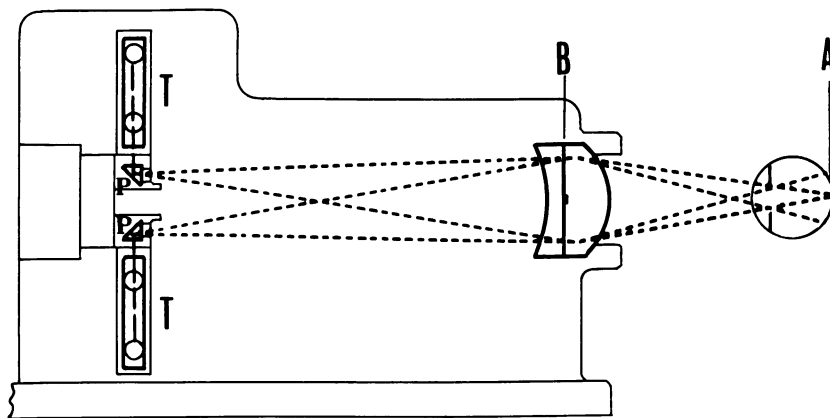


FIGURE 7. DIAGRAMMATIC DRAWING OF THE LIGHTING SYSTEM OF THE FUNDUS CAMERA.

A, fundus of patient's eye; B, aspheric ophthalmoscope lens; T, "end-on" electronic flash tubes. Note how the aspheric lens images the light from the electronic flash tubes at the plane of the patient's pupil in the 6 and 12 o'clock positions.

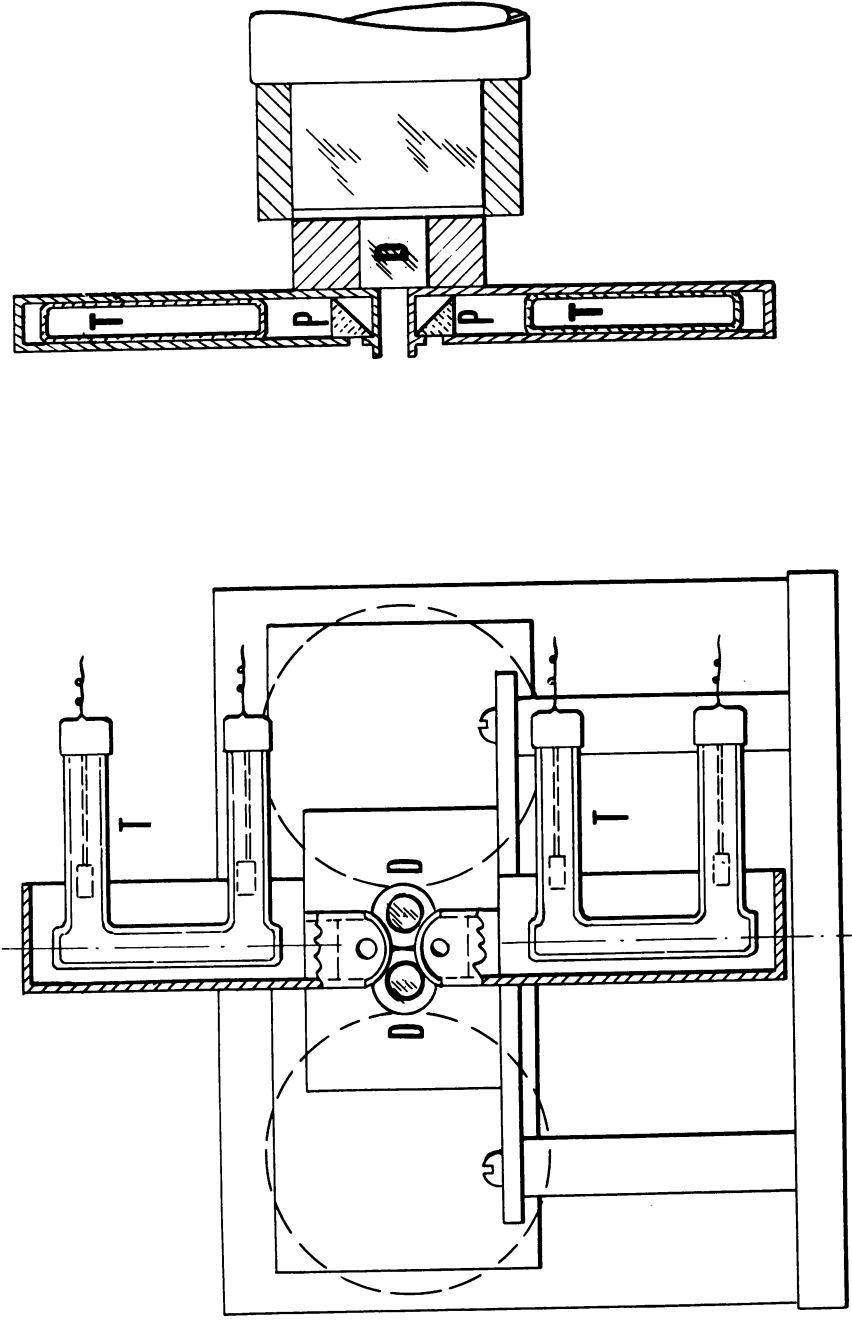


FIGURE 8. DRAWING OF THE LIGHTING SYSTEM IN FRONT VIEW (LEFT) AND SIDE VIEW (RIGHT).  
 D, small "field" lens; P, prism; T, "end-on" electronic flash tube. Note the close relationship of the "field" lenses to the emergence of the light from the electronic flash tubes.

“end-on” type and were designed specifically for this camera in collaboration with Dr. Harold Edgerton of the Massachusetts Institute of Technology. With this type of tube, the light which is emitted from the end of the tube is utilized and this gives a greater intrinsic brilliance than with the conventional lighting from the side of the tube. One end of these tubes faces into its own small right-angle prism (P) and these prisms are mounted just above and below the “field” lenses and face the aspheric lens. A small diaphragm having a 3-mm. aperture is mounted on the face of each prism and the center-to-center distance of these apertures is 14 mm. The light then passes through the aspheric lens (B) which images the apertures in the plane of the pupil so that one small spot of light passes through the dilated pupil at 12 o'clock while the other passes through at 6 o'clock. These two light sources then produce a uniform illumination of the portion of the fundus (A) being photographed.

Not only does the electronic flash produce one bright flash of approximately .001-second duration which takes the picture, but it also flashes at low intensity at a rate of 60 times per second. This


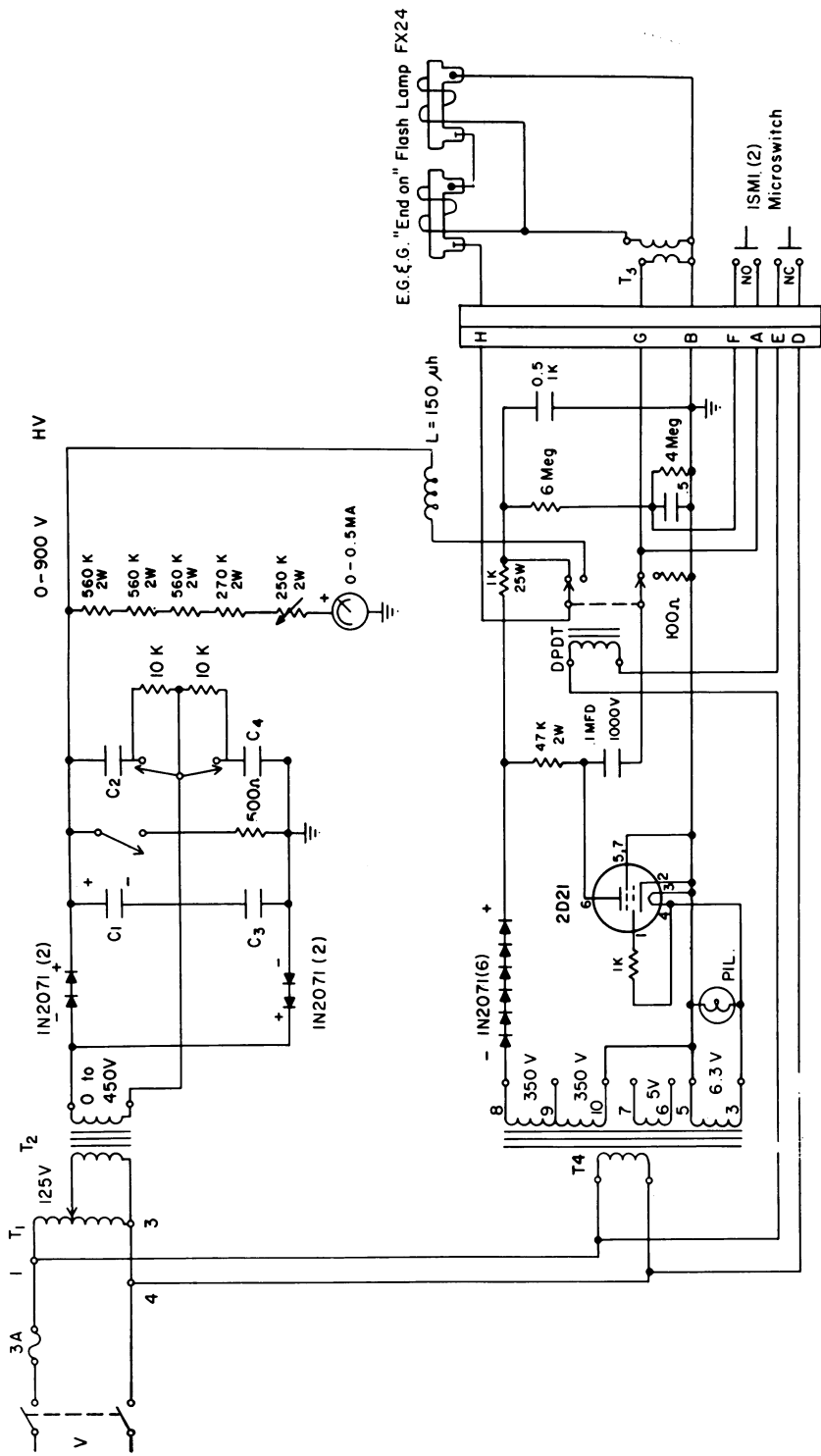


FIGURE 9. OBLIQUE VIEW OF FRONT PORTION OF CAMERA WITH THE COVER REMOVED TO SHOW OPTICAL AND ELECTRONIC COMPONENTS.

K, small plus spherical lens; B, aspheric ophthalmoscope lens. The unit at the left side of the photograph is comprised of the various components shown in Figure 8. The flash tubes are completely enclosed to avoid having extraneous light enter the aspheric lens.



T<sub>1</sub> - Powerstat Type 10  
 T<sub>2</sub> - Sencor P6425  
 T<sub>3</sub> - Modeletric Type "E"  
 C<sub>1</sub> - C<sub>4</sub> - Sprague D17923 525 MFD 450 V  
 T<sub>4</sub> - Chicago PSR 55

rapidly cycling light is used for focussing; a general method as first described by Jacobs and Ogle.<sup>18</sup> The advantage of this method of lighting lies in the fact that the light being used for focussing is identical in all respects, except intensity, to the light which finally takes the picture. The centering of the small spots of light in the pupil while focussing is a critical procedure and is greatly facilitated by a small plus spherical lens (K in Figures 6 and 9) which can be swung up in front of the aspherical lens (B) and is of sufficient power so that the pupil is seen in focus through the oculars. This is accomplished by pushing down on a small button just in front of the focussing knob.

The power supply is composed essentially of two parts. The one portion is a conventional electronic unit to produce the high intensity flash while the other portion produces low intensity rapid flashing for focussing the camera. The first portion is represented in the upper half of the schematic diagram (Figure 10) and is composed basically of a variable voltage transformer ( $T_1$ ) which supplies the primary of the power transformer ( $T_2$ ). The output of this transformer is rectified by silicon rectifiers and feeds a voltage-doubler circuit which charges four photoflash capacitors (525 mfd. each) in series-parallel with a maximum output of 200 watt-seconds at 900 volts. However, the charge on the capacitors can be varied by means of the variable transformer and the amount of charge can be determined by a milliammeter (0-0.5 ma.) in the bleeder circuit. This also compensates for variations in line voltage. The other portion of the power supply is represented by the lower half of the schematic diagram (Figure 10) and produces the rapid flashing of the electronic flash tubes as well as the triggering circuit. The flashing is produced by the power transformer ( $T_4$ ) whose output of 900 volts is rectified by silicon rectifiers and rapidly charges a 0.5 mfd. capacitor. A 2D21 thyatron tube which acts as a 60-cycle line-driven trigger tube discharges the capacitor through the primary of the voltage pulse transformer ( $T_3$ ) and triggers the tubes which produce flashing at a rate of 60 times per second. The normally closed microswitch is open while the focussing procedure is being carried out and at this time the DPDT relay connects the cycling discharges to the electronic flash tubes. When the reflex mirror in the camera is

---

FIGURE 10. SCHEMATIC DRAWING OF POWER SUPPLY FOR THE LIGHTING SYSTEM OF THE FUNDUS CAMERA.

The upper portion of the drawing represents the circuitry for the single bright flash of the electronic flash tubes while the lower portion represents the circuits for the low intensity rapid flashing of the tubes used in the focussing procedure. (See text for the details of the operation of this unit.)

released, the microswitch is closed causing the DPDT relay to close and this connects the capacitors for the high intensity flash to the tubes. This also stops the rapid flashing of the tubes. When the mirror reaches its horizontal position, it closes the normally open micro-switch and this triggers the electronic flash tubes producing the single high intensity flash. By means of this arrangement, at no time is there any tendency towards arcing across the contacts of the relay.

The camera is mounted on a Zeiss table, the type Zeiss ordinarily uses for both their slit-lamp and fundus camera (Figure 11). Various

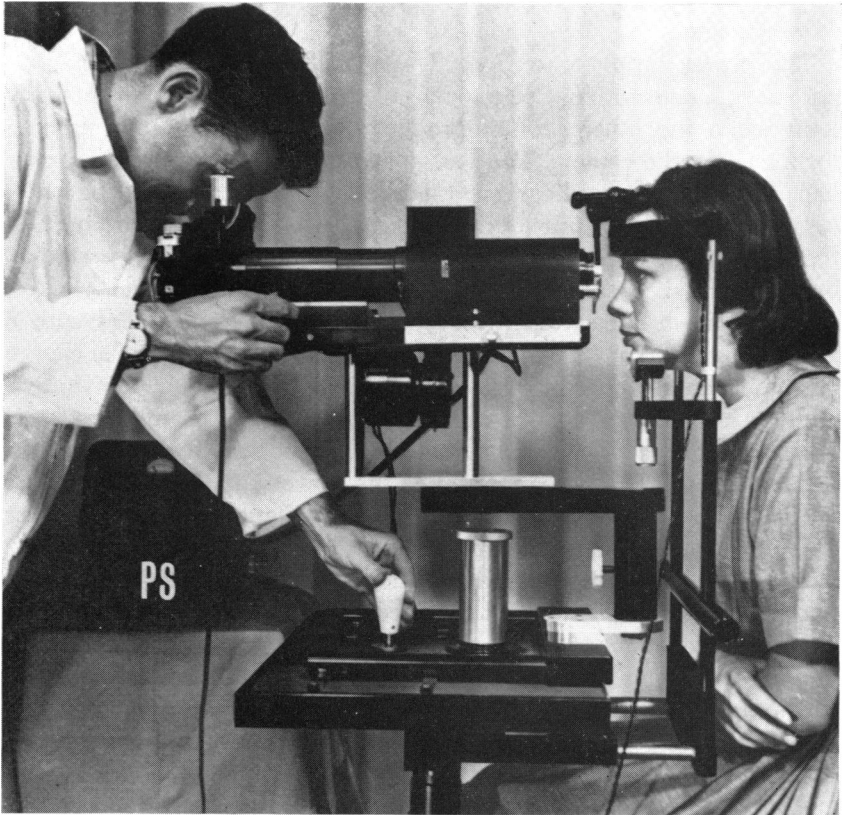

FIGURE 11. SIDE VIEW OF CAMERA SHOWING BOTH THE PATIENT AND THE OPERATOR IN POSITION.

The camera is mounted on a Zeiss table which utilizes the "joy-stick" for aligning the camera with the eye. The operator's right hand is on the focussing knob of the camera while the left hand is being used for alignment by means of the "joy-stick". The power supply, PS, is visible in the background. Note how the swivel point of the camera is immediately under the patient's eye which is being photographed,



minor modifications were made to adapt this table to the stereoscopic fundus camera. Although the "joy-stick" is easily reached when the operator is in a standing position, the vertical adjustment knob had to be extended upward. In addition, a short tube was mounted on the fixation light and at the opposite end of this tube was mounted a right-angle prism. By means of the arrangement the patient can look into the right-angle prism and view the fixation light. This allows the fixation light to be brought in from the side thus making possible a complete range of eye positions. Also, because the pivot point of this fundus camera is immediately below the patient's eye, no lateral adjustment is necessary to keep the fundus in view as the camera is swivelled to center the portion of the fundus being photographed.

#### OPERATION

The ease and speed with which a picture can be taken affects the quality of the picture. Every effort was made to make the operation of this camera both simple and fool-proof. The operation has been reduced to three main steps.




FIGURE 12. TOP VIEW OF FUNDUS CAMERA SHOWING THE PAIRED FOCUSING EYEPIECES (OCULARS) THROUGH WHICH IS SEEN A BINOCULAR VIEW OF THE FUNDUS. The knob (M) is for focussing while the small button (N) is used in the centralization procedure (see text).

(1) With the patient seated comfortably and the head completely in the head and chin rest (Figure 11), the power supply is turned on and the small button (N) (Figure 12) just in front of the focussing knob (M) is depressed. This makes it possible to view through the oculars the images of the rapidly flashing tubes in the pupil. By means of the "joy-stick" and the vertical adjustment knob these two small spots of light are brought into focus and centered in the pupil at 12 and 6 o'clock.

(2) On releasing the button, the binocular view of the fundus is seen through the focussing eyepieces and the entire camera is then swivelled to bring into view the area of the fundus to be photographed. If a change in vertical position is required, the fixation light is moved accordingly. If the fundus appears unusually dark or light, the meter on the power supply is adjusted to a higher or lower reading by means of the knob which controls the variable voltage transformer.

(3) Critical focussing is now accomplished by means of the focussing knob while viewing the fundus image through the oculars and at the same time the "joy-stick" is moved back and forth until there are no reflexes and the fundus is evenly illuminated. Momentarily, the centralization of the spots of light is again checked by pushing down the button. The foot switch is pressed which automatically turns off the flashing of the tubes and produces the one high intensity flash at the moment the reflex mirror is in the horizontal position. The focussing lights cannot be turned on again until the film is wound, thus avoiding double exposure.

#### DISCUSSION

There appears to be general agreement as to the desirability of the stereoscopic fundus picture over that of the conventional type. But it is surprising how little work has been done in this field. Moreover, what has been reported is generally so lacking in detail that it is difficult to acquire specific knowledge as to the equipment and techniques used. Stock,<sup>10</sup> for example, mentioned the fundus conditions he has photographed stereoscopically, but he does not say what camera was used. Bedell<sup>8</sup> reported that he displaced the camera laterally 24 mm. between the two exposures with the patient's fixation constant. It is obvious that this is either an error or that he rotated the camera as well as shifting it laterally. If this were not the case, he would completely miss the pupil on the second exposure. Metzger<sup>7</sup> determined how much shift should occur in the fixation of the patient by

“judging” the change in area of fundus image. More recently Norton and Sullivan<sup>19</sup> reported their more exact method in which a wedge prism was placed in front of the fixing eye after the first exposure. Even with the extensive and very excellent work done recently by Allen,<sup>11</sup> successive stereoscopic fundus photography still does not seem to be a very exact method. It would appear that judgment and experience are more important than reliance on mechanical measurements and controls.

Why has there not been a greater effort over the years to produce a satisfactory fundus camera for simultaneous photographs? Undoubtedly, one reason is that the successive type of stereophotography produced acceptable results on at least half of the patients on whom fundus photographs are required. By some persons certainly a much higher percentage than this can be obtained. However, the fact still remains that there are an appreciable number of instances in which it is important to obtain a stereoscopic fundus photograph and yet for various reasons it is not possible to take the successive type of photograph or, if it can be taken, the exact depth effect cannot be reproduced. The fundus photographs (Figures 13–20) have been selected especially to illustrate these facts.

Let us now consider why the previous attempts at producing a simultaneous stereoscopic fundus camera were apparently not successful. The camera Nordenson made in 1930 apparently was problematical for several reasons. First of all, the arc light did not illuminate evenly the area of the fundus being photographed. With the advent of the electronic flash tube, this is no longer a problem. In the author’s camera, which uses the “end-on” tubes, each of the two pencils of light is approximately 1 mm. in diameter at the iris plane. Yet at maximum intensity there is sufficient light for film having an A.S.A. rating of 10 (as Kodachrome I). It also might be pointed out that the type of circular light presently used on the new Zeiss Camera would not be satisfactory for use in a stereoscopic fundus camera. With the illuminating system traversing the same 3 and 9 o’clock portion of the cornea and lens through which the emerging rays are passing, a distracting flare would be produced.

A more serious problem in the stereoscopic Nordenson camera seemed to be the distortion and loss of detail. From the diagrammatic drawing of the light rays (Figure 4) it would appear that the rays were still diverging with respect to each other as they emerged from the camera lenses and were finally focussed at the film plane. As already pointed out, the rhomboid prisms in the author’s system are

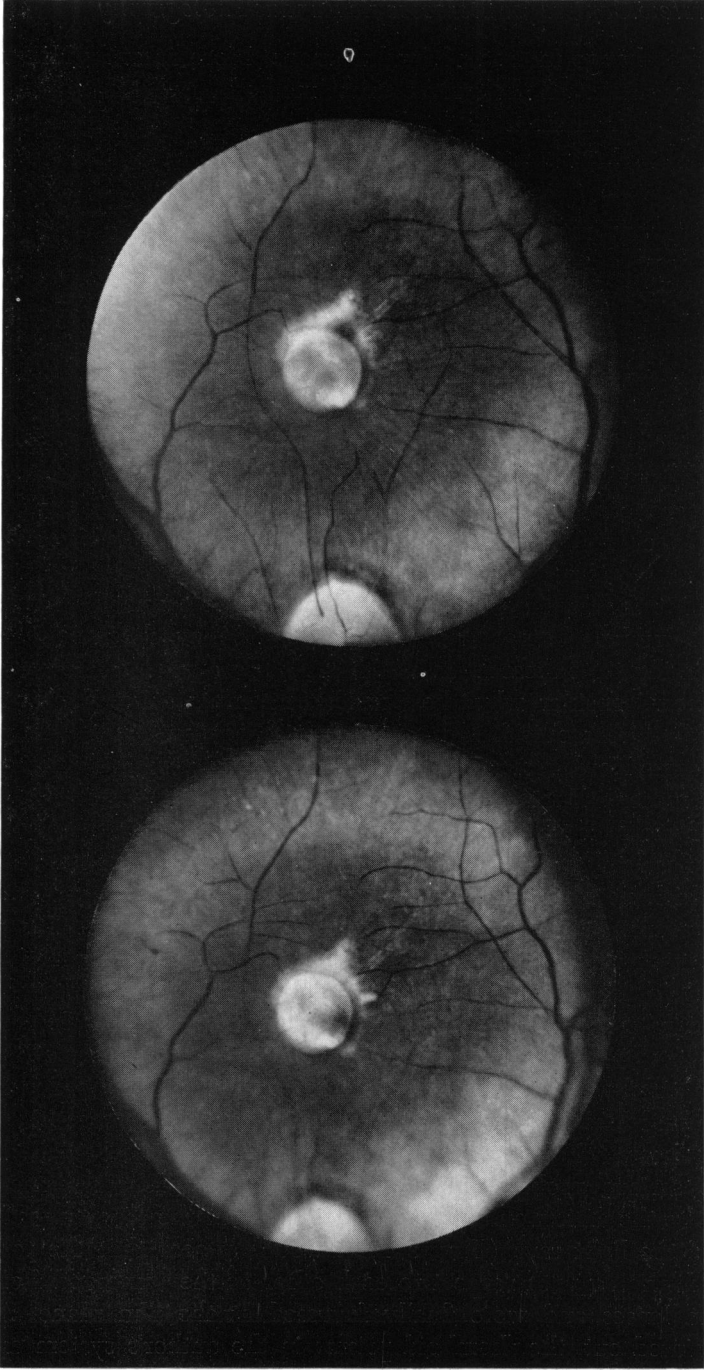


FIGURE 13. FUNDUS OF LITTLE GIRL WITH A PRESUMED NEMATODE CHOROIDITIS IN MACULAR REGION. Stereoscopically, the lesion is seen to extend well into the vitreous. Because the child was too young to co-operate, this picture could not have been taken by the successive photographic method. (Reproduced from a 35-mm. Kodachrome transparency.)

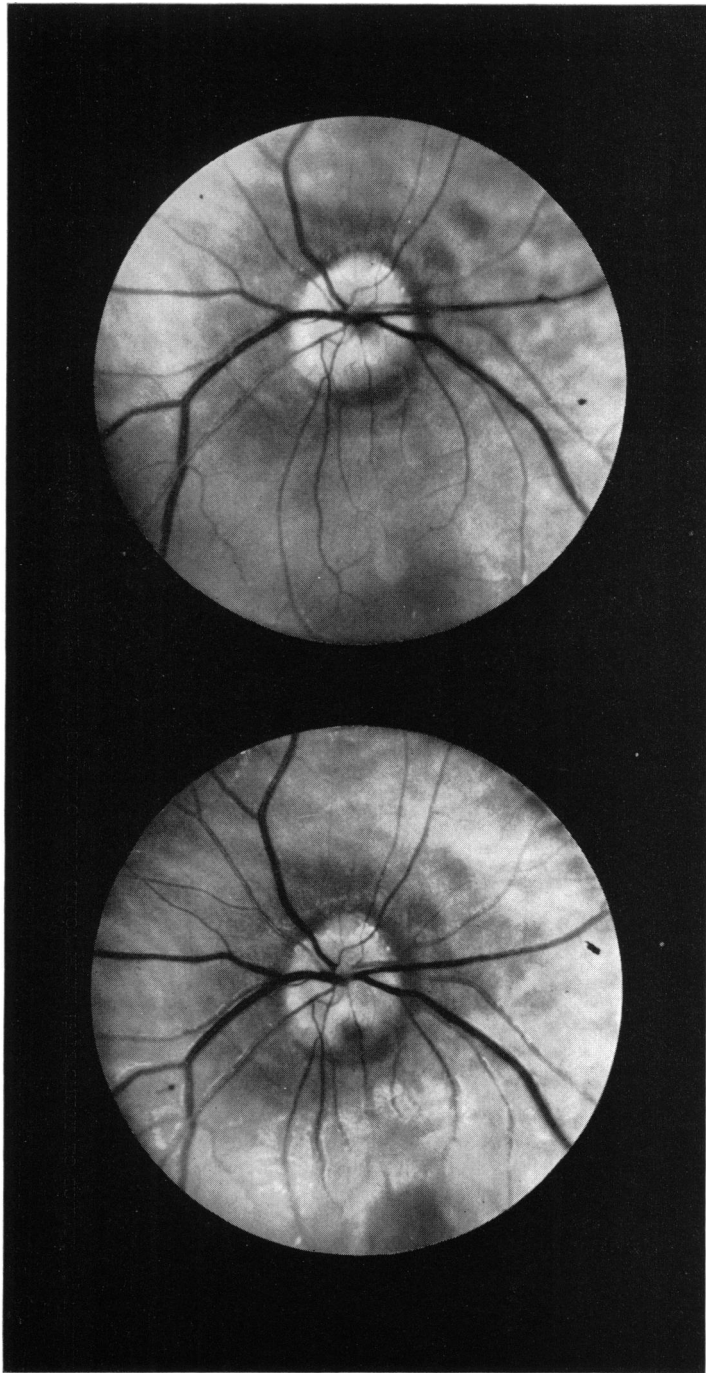


FIGURE 14. FUNDUS OF BOY WITH ELEVATION OF DISC (2-3D) AND OBVIOUS DRUSEN OF THE NERVE HEAD. Subsequent photographs showed the disc elevation to remain the same. Had the follow-up photographs been taken by the successive method, the appearance of the disc in regard to elevation would be meaningless. (Reproduced from a 35-mm. Kodachrome transparency.)

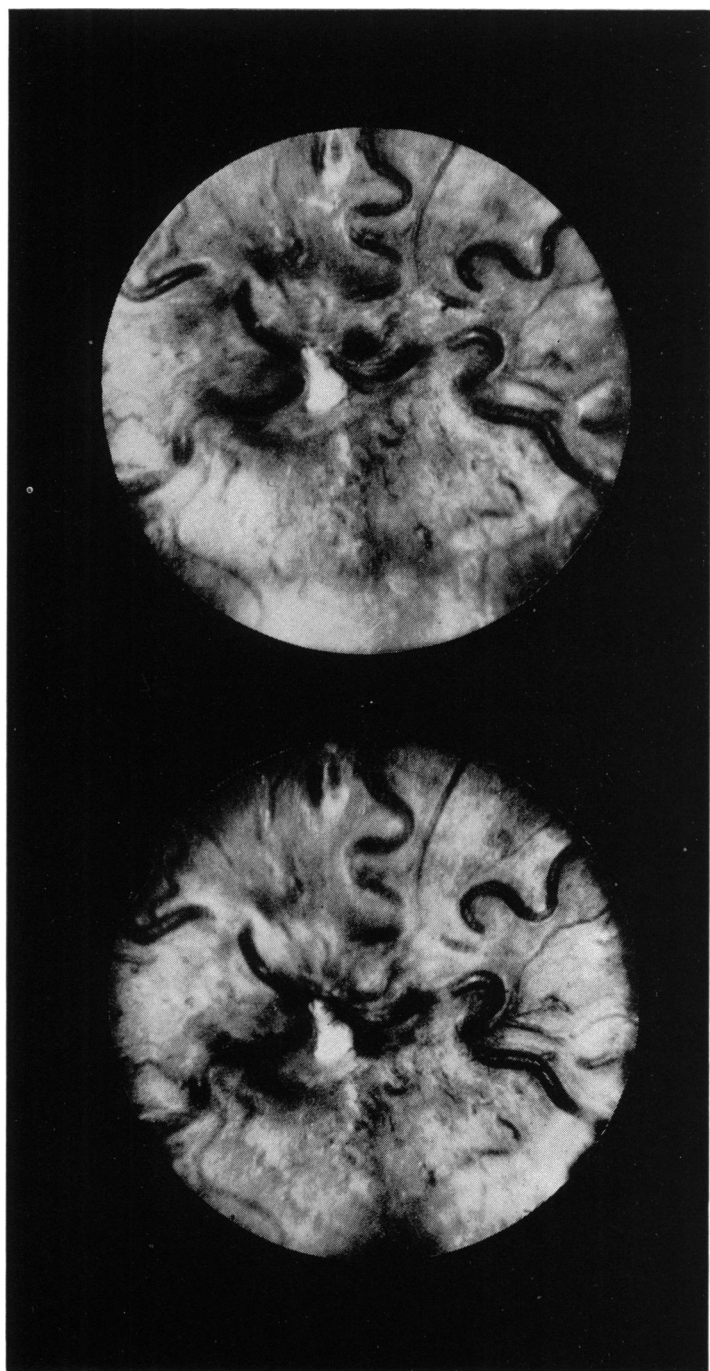
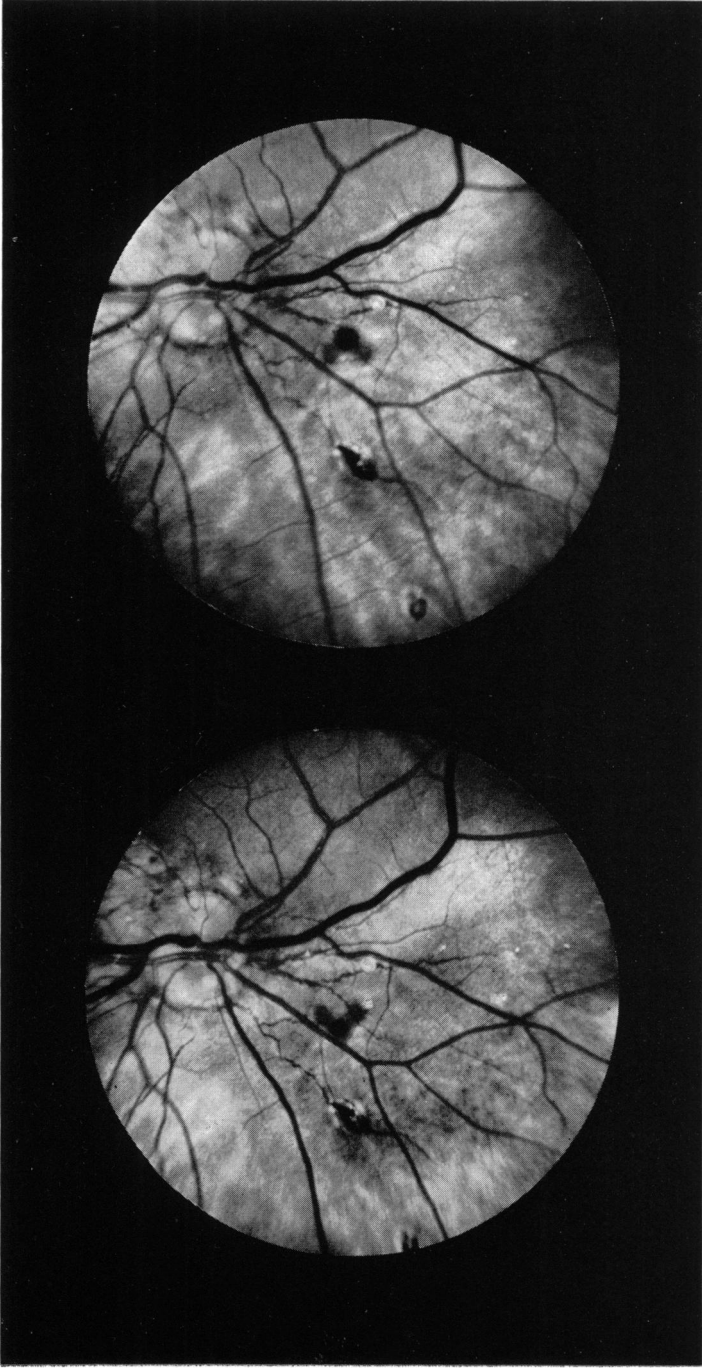

FIGURE 15. FUNDUS OF YOUNG MAN WITH ACUTE MYELOGENOUS LEUKEMIA, SHOWING MUCH PAPILLOEDEMA, TORTUOUS DILATED VESSELS AND EXUDATES.

The visual acuity was very poor and also the patient was semi-comatose so the successive photographic method was not possible. (Reproduced from a 35-mm. Kodachrome transparency.)



**FIGURE 16. FUNDUS OF YOUNG WOMAN WITH PSEUDOXANTHOMA ELASTICUM AND EARLY ANGIOID STREAKS. The streaks are easily visualized stereoscopically as being deep to the vessels. (Reproduced from a 35-mm. Kodachrome transparency.)**

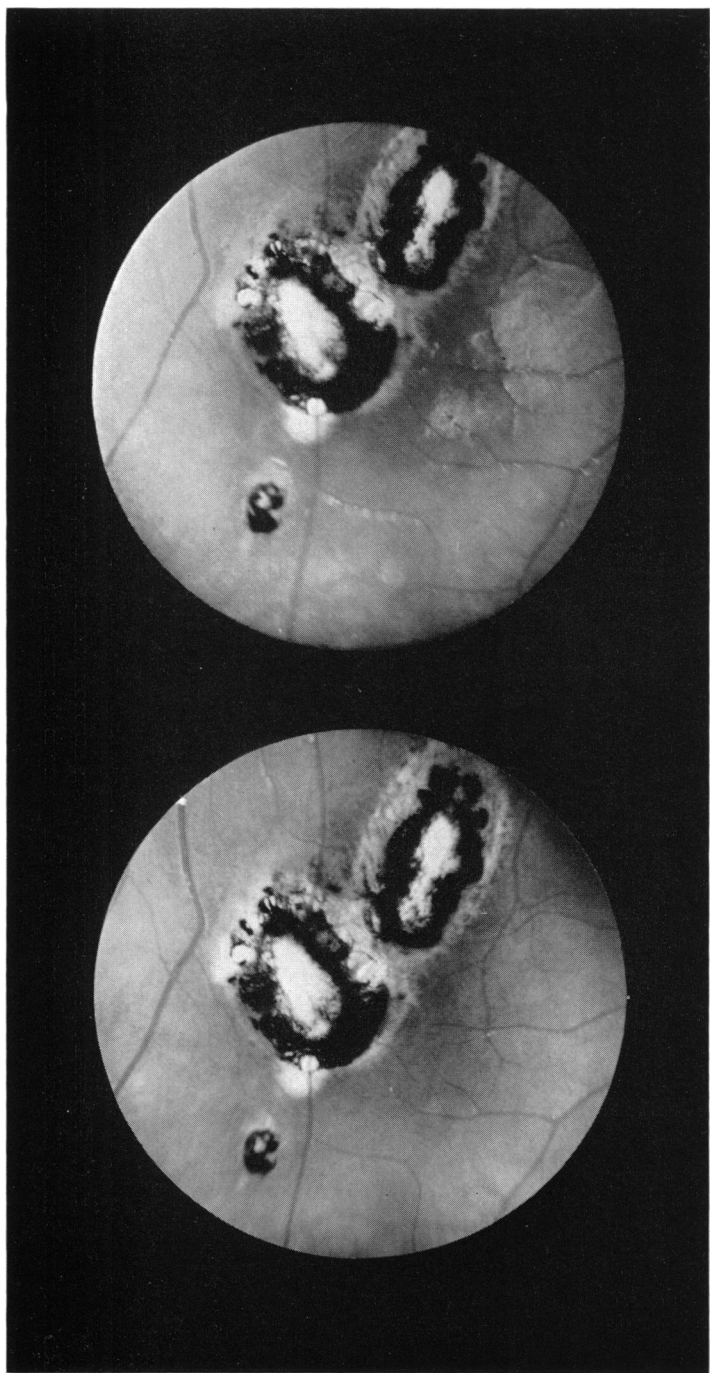


FIGURE 17. FUNDUS OF BOY WITH ACTIVE TOXOPLASMIC CHORIORETINITIS IN THE MACULAR REGION OF THE OTHER EYE AND INACTIVE LESIONS NEAR THE EQUATOR IN THIS EYE.

Between the two lesions is an area of retinal atrophy where it is possible to visualize stereoscopically the choroid deep in the surrounding retina. This patient could not fixate with the other eye so the successive type of photography could not have been used. (Reproduced from a 35-mm. Kodachrome transparency.)



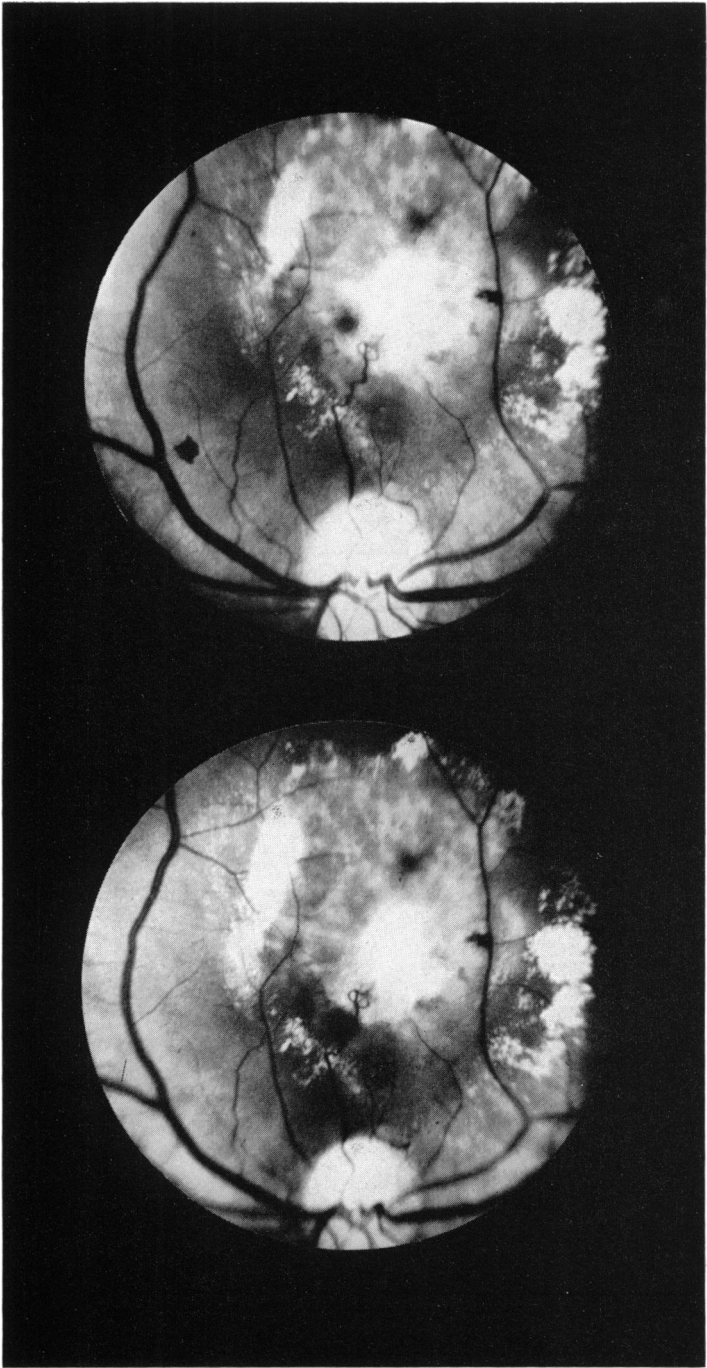


FIGURE 18. FUNDUS OF MIDDLE-AGED WOMAN WITH DISCIFORM DEGENERATION OF THE MACULA. The lesion is elevated several diopters and has a vessel which enters its surface and then extends down into the lesion. (Reproduced from a 35-mm. Kodachrome transparency.)

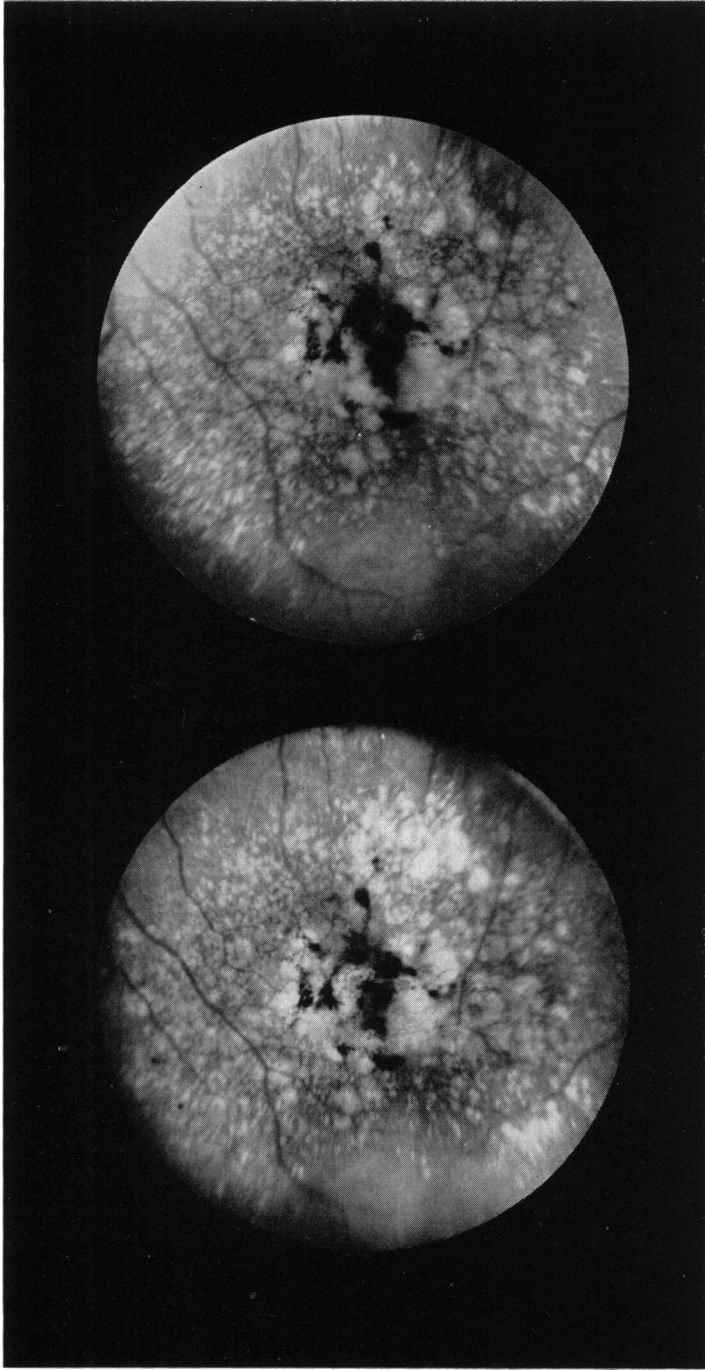


FIGURE 19. FUNDUS OF ELDERLY MAN WITH MANY DRUSEN ABOUT THE MACULAR REGION AND AN OLD PIGMENTED ELEVATED DISCIFORM DEGENERATION OF THE MACULA.

The other eye has the same condition so this patient could not have been photographed by the successive method. (Reproduced from a 35-mm. Kodachrome transparency.)

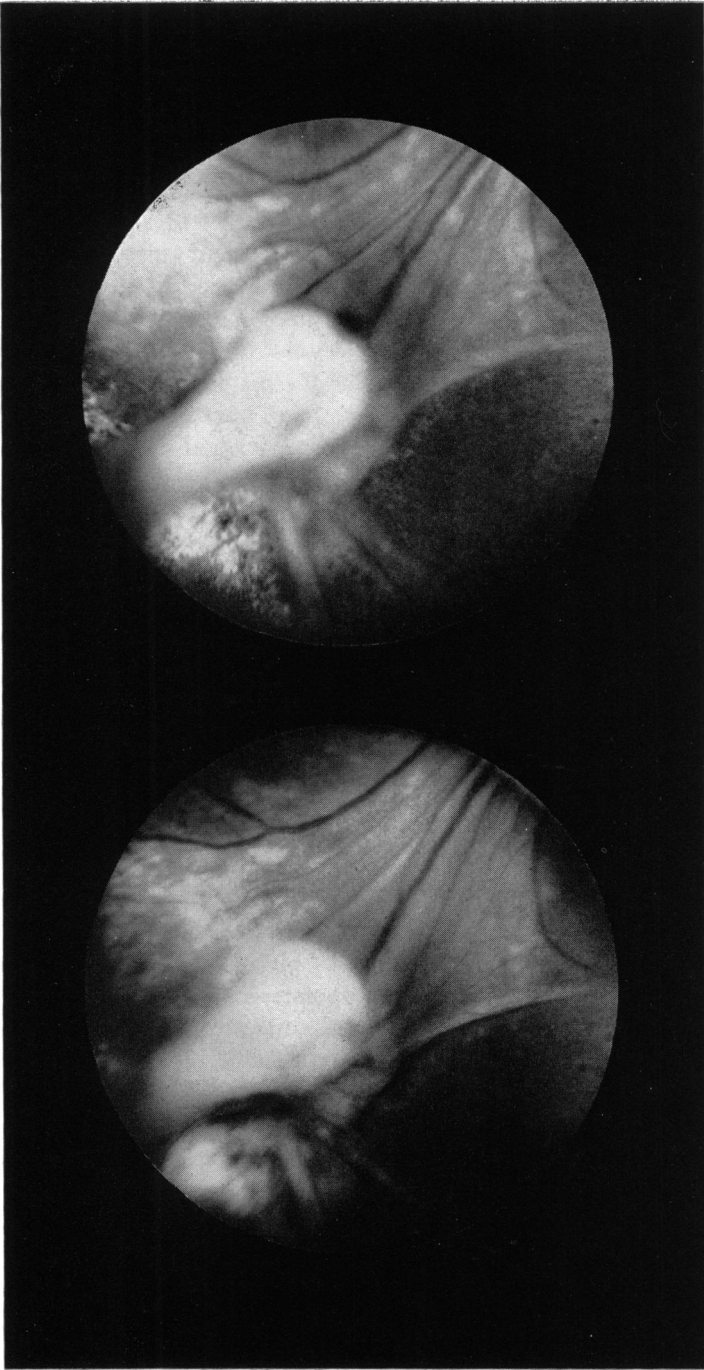

FIGURE 20. FUNDUS OF GIRL WITH PRESUMED CONGENITAL RETINAL FOLDS JUST BEYOND THE EQUATOR. Above the folds is a white mass (gliosis) in the vitreous. Patient has been photographed repeatedly over a period of several years but no change has occurred. (Reproduced from a 35-mm. Kodachrome transparency.)

modified so as to make the two sets of rays parallel with each other before entering the camera lenses. In addition, another possible source of distortion and loss of detail might be associated with the location of the two apertures which in Nordenson's camera are at the inner ends of the prisms and in the author's camera are at the "field" lenses. These apertures must be located in a plane which will be imaged by the ophthalmoscope lens at the pupil of the patient's eye. The light source must also be in this plane and is also imaged at the patient's pupil. In the author's camera, there is a magnification ratio of 3:1 resulting from the distance from the nodal point of the ophthalmoscope lens to the patient's pupil being only  $\frac{1}{3}$  of the distance from the nodal point to the plane in which the light sources and apertures of the "field" lenses are located. This means that the images formed in the pupil are  $\frac{1}{3}$  their original dimensions. Thus, the apertures of the light are 3 mm. but when imaged in the pupil are only 1 mm. Also their outer dimensions are 17 mm. (14 mm. center-to-center distance) so with a reduction in size to  $\frac{1}{3}$ , they would just fit into a 6-mm. pupil. The separation of the apertures at the "field" lenses determines the resulting depth effect. If these are too close, the picture will appear too shallow but if the separation is too great a hyperstereoscopic effect will result. A more serious situation would arise in the event the separation was too great: the aperture would be imaged at the outer edges of the pupillary area and would thus utilize a portion of the cornea and lens which produces more aberrations. This would tend to decrease detail and also cause distortion. In the author's camera, the apertures in front of the "field" lenses are 5 mm. in diameter and have a center-to-center distance of 9 mm. This means that the outside dimensions are 14 mm. and therefore they are imaged within the central 5 mm. of the pupil. This separation produces what appears to be a slightly hyperstereoscopic effect. Producing a somewhat hyperstereoscopic effect has an advantage of increasing the accuracy of the measurements which can be used to calculate from the stereoscopic pair of pictures the exact dimensions of the elevation or depression of a fundus lesion. Of course, this type of measurement can only be made with the photograph from a camera which takes simultaneous stereoscopic pictures.

#### SUMMARY

Depth relationships in the fundus are often of considerable importance and the stereoscopic fundus photograph records such relationships. With few exceptions, this type of photograph has been made by

two successive exposures using the conventional fundus camera. Between the two exposures, either the patient changes fixation or the camera is shifted to obtain stereoscopic effect. This method requires the complete co-operation of the patient and is not practical under a number of circumstances. Moreover, even though good stereoscopic pictures are obtained by the above method there is no assurance that the same depth effect will be produced in the subsequent photographs.

Therefore the author has designed and made a camera which takes simultaneous stereoscopic photographs. It utilizes the indirect ophthalmoscopic principle and is reflex free. A new type of electronic flash lamp is used for illumination and this produces sufficient light for ordinary 35-mm. color film. The fundus image is seen binocularly while focussing. Moreover, the ease and speed of operation of this new camera is equal to any of the monocular fundus cameras. The resulting stereograms are almost free of distortion, have a high degree of definition, and their depth effect is absolutely reproducible.

#### REFERENCES

1. Thomer, W., Die stereoskopische Photographie des Augenhintergrundes. *Klin. Monatsbl. Augenh.*, 47:481-90, 1909.
2. Nordenson, J. W., Om Centrisk Fotografering au Ogonbottnen. *Hygea*, 77:1538-52, 1915.
3. Gullstrand, A., Einführung in die Methoden der Dioptrik des Auges des Menschen. Leipzig, 1911.
4. Hansell, P., and E. J. G. Beeson, Retinal photography in color. *Brit. J. Ophth.*, 37:65-9, 1953.
5. Hartinger, H., Die vollkommen reflexfreie Retina-Camera nach Zeiss-Nordenson. XIII Concilium Ophthalmologicum, Zusammenfassungen, Amsterdam, 1929, S. 313.
6. Nordenson, J. W., Stereoskopische Ophthalmographie durch einfache Aufnahmen. *Upsala läk. forh.*, 32:295-7, 1927.
7. Metzger, E., Die Stereophotographie des Augenhintergrundes. *Klin. Monatsbl. Augenh.*, 78:338-48, 1927.
8. Bedell, A. J., Photographs of the fundus oculi. *New York J. Med.*, 27:951-71, 1927.
9. Wessely, K., Ber. deutsch. ophth. Gesellsch. Heidelberg, p. 426, 1927.
10. Stock, Ber. deutsch. ophth. Gesellsch. Heidelberg, p. 461, 1927.
11. Allen, L., Ocular fundus photography. *A.M.A. Arch. Ophth.*, 57:13-28, 1964.
12. Stenstrom, W. J., A modification of the new Zeiss fundus camera. *A.M.A. Arch. Ophth.*, 64:(Dec.), 1960.
13. Nordenson, J. W., Ueber stereoskopische Photographie des Augenhintergrundes. *Upsala läk. forh.*, 35:216-22, 1930.
14. Norton, H. J., Jr., Absolute three dimensional colored retinal photographs. *Tr. Am. Acad. Ophth.*, 57:612-13, 1953.
15. Norton, H. J., Jr., Absolute electronic retinal stereophotography. *Am. J. Ophth.*, 40:809-17, 1955.
16. Drews, R. C., Fundus photography by electronic flash. *Am. J. Ophth.*, 44:170-7, 356-9, 522-5, 633-7, 1957.

17. Littmann, H., Die Zeiss-Fundus-Kamera. Ber. deutsch. ophth. Gesellsch., 59:318-21, 1955.
18. Jacobs, M., and K. N. Ogle, Application of high speed flash tube to photographing the fundus of the eye in color. Rev. sci. Instr., 24:52-5, 1953.  
Ogle, K. N., and C. W. Rucker, Fundus photographs in color using a high speed flash tube in the Zeiss retinal camera. A.M.A. Arch. Ophth., 49:435-7, 1953.
19. Norton, H. J., and C. T. Sullivan, Practical dual-exposure stereophotography of the retina. A.M.A. Arch. Ophth., 60:455-60, 1958.