

# THE TREATMENT OF INTRARETINAL ANGIOMAS\*

BY *P. Robb McDonald*, MD, AND (BY INVITATION)

*Lov K. Sarin*, MD

LINDAU-VON HIPPEL'S SYNDROME affects males more than females of any age group and is bilateral in 36 per cent of the cases. It is a familial condition with dominant autosomal inheritance. The main lesions consist of one or several arteriovenous angiomas located at the equator or more peripherally with dilated and tortuous feeder vessels. Secondary changes are glial proliferation around the tumor and along the dilated vessels, exudation, and retinal detachment. Secondary glaucoma may also ensue.

Leber's miliary aneurysmal retinopathy occurs almost exclusively in young males, is unilateral, and is slowly progressive. The small arterial aneurysms are found usually at the posterior pole in a circumscribed area. They have associated exudates and may eventually produce Coats's disease.<sup>1</sup>

Telangiectasia retinae of Reese<sup>2</sup> is characterized by a circumscribed slightly elevated area over which are numerous small, sharply outlined red globules. Usually this is unilateral and only rarely presents itself at more than one site in a given eye. Reese believes this to be a precursor of Coats's disease.

We have seen three patients this past year who have had isolated vascular lesions of the posterior pole that do not fit into the category of angiomatosis retina, Coats's disease, Leber's miliary aneurysms, or telangiectasia of the retina as described by Reese. We think the lesion we are referring to is an intraretinal lesion occurring in an apparently healthy patient without any evidence of systematic disease. The retinal vessels are normal. In the area of edema there may be a small dark lesion not connected with the vessels, which can be seen by ophthalmoscopy or by fluorescein examination.

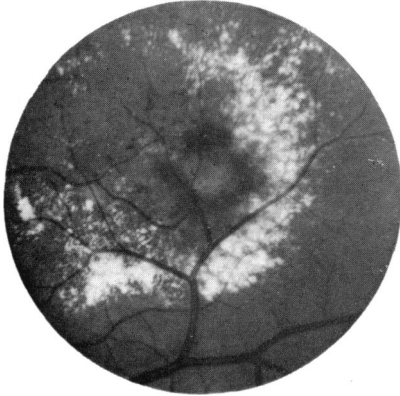## CASE REPORTS

### CASE I

Case I was that of a 46-year-old white female who noticed blurred vision

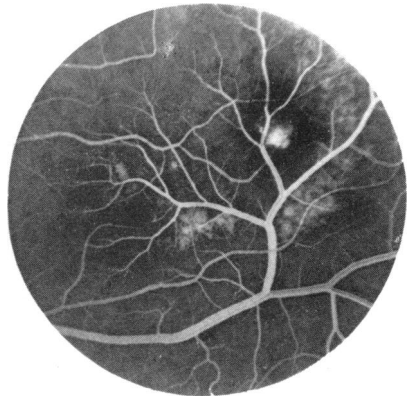
\*From the Retina Service, Wills Eye Hospital, Philadelphia, Pennsylvania.

in her left eye in December 1967. When we first saw her on 27 March 1968, vision was 20/20 in the right eye and 20/100 in the left eye. The fundus showed edema in a star-shaped figure practically surrounding the macula. There was a reddish lesion about one-fourth the size of the disk superior and temporal to the macula (Figure 1). The vision dropped to 20/400 before photocoagulation of the lesion on 1 April 1968. Figure 2 shows the fluorescein angiogram prior to therapy. Following photocoagulation, the edema residue was gradually absorbed (Figure 3). The



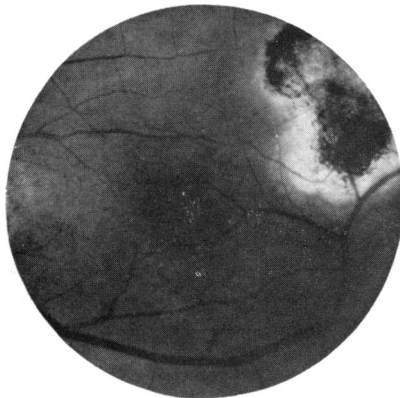**FIGURE 1**

Case I. Showing central dark lesion with surrounding edema residue. Vision 20/400, 1 April 1968.



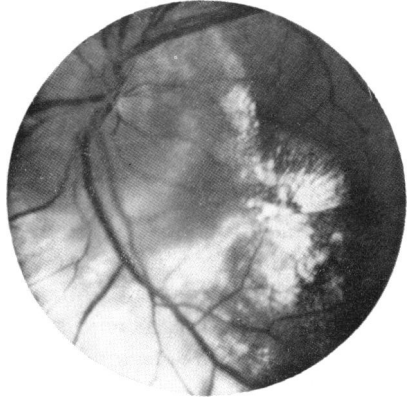
**FIGURE 2**

Case I. Fluorescein angiogram showing vessel passing over the lesion. Minimal staining with fluorescein, 1 April, 1968.



**FIGURE 3**

Case I. Showing absorption of edema residue, 11 September, 1968. Return of vision to 20/20.



**FIGURE 4**

Case II. Marked edema below left disk with star figure in macula, 19 November 1969.

patient regained 20/20 vision by 11 September 1968 and has maintained this ever since. Laboratory studies, including a spinal fluid examination, were all within normal limits.

CASE II

Case II was that of a healthy 31-year-old male first seen on 19 November 1969, having been referred because of poor vision and a peculiar lesion of the left eye. Vision at this time was 20/20 in the right eye and counting fingers in the left eye. Figure 4 shows the marked edema surrounding the nerve head with a small sharply demarcated star figure about the macula.

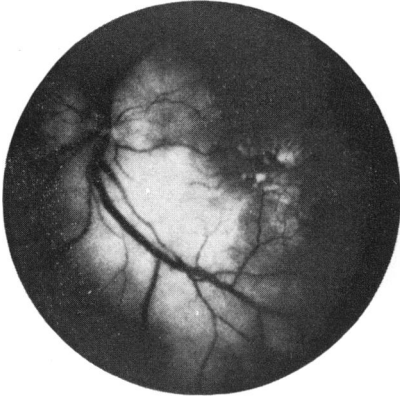


FIGURE 5

Case II. Fluorescein angiogram (late), 19 November 1969.

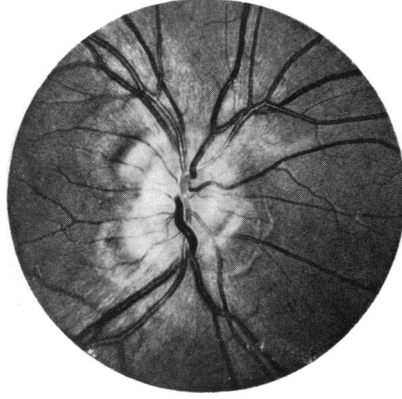


FIGURE 6

Case II. Red-free photograph of the right disk.

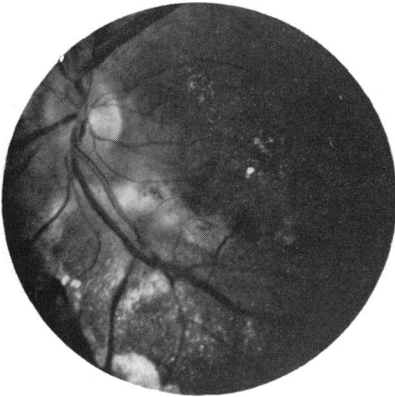

FIGURE 7

Case II. Resolution of edema following photocoagulation.

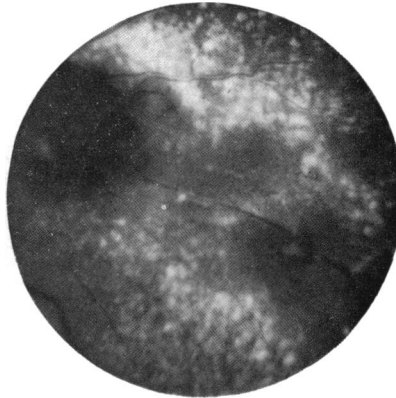


FIGURE 8

Case III. Angioma and edema residue nasally and inferior to the disk.

Figure 5 shows a late-stage fluorescein angiogram on the same date. Interestingly, the right eye showed a very abnormal peripapillary vascular lesion (Figure 6). The lesion in the left eye was photocoagulated on 9 January 1970 and again on 13 April 1970. There has been marked resolution of the edema residue, but unfortunately the vision has not improved (Figure 7).

### CASE III

Case III was that of a healthy 63-year-old male who was first seen by Dr Richard Goldberg on 9 October 1969. He complained of blurred vision

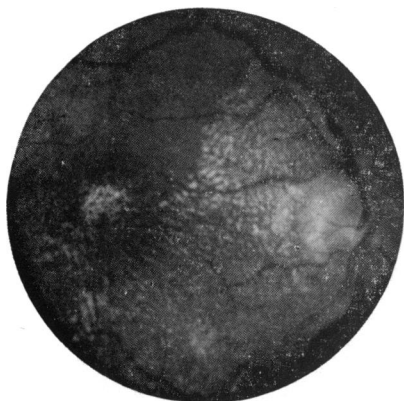


FIGURE 9

Case III. Edema residue in the macular region.

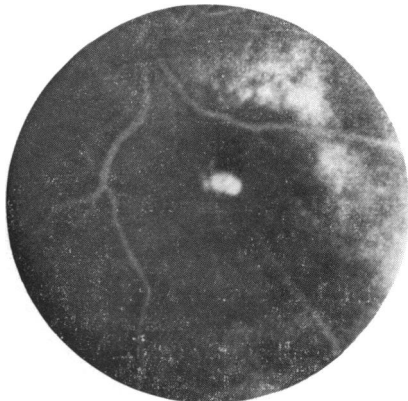

FIGURE 10

Case III. Fluorescein angiogram, 9 October 1969. Minimal staining with fluorescein.

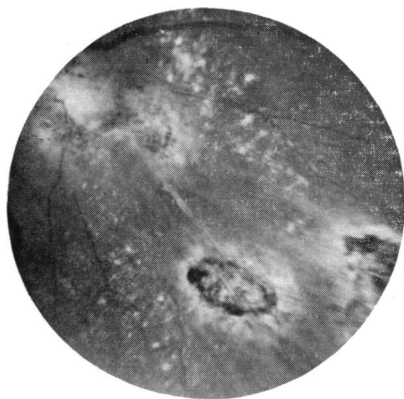


FIGURE 11

Case III. Showing absorption of edema residue following photocoagulation.

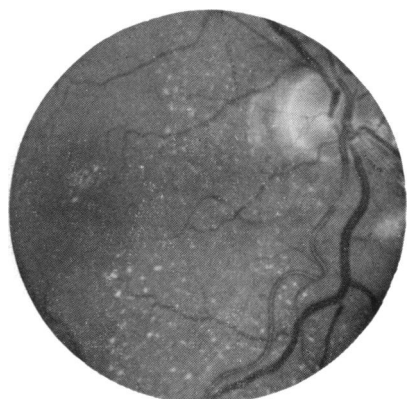


FIGURE 12

Case III. Absorption of edema residue in the macula.

of four days' duration. The visual acuity was counting fingers with the right eye and 20/20 with the left eye. He presented with a dark lesion inferior and nasal to the disk with some hemorrhage and edema residue inferior to the disk (Figure 8) and in the macular region (Figure 9). A fluorescein angiogram on the same date showed minimal staining at the site of the dark lesion (Figure 10). He was placed on 10 mg of prednisone four times a day. On 10 November 1969 the vision had improved to 20/80, and a second small angiomatous lesion was noted along the course of the inferior nasal artery. Photocoagulation was performed the same day. On 5 December 1969 the vision had dropped to 20/200. There was an excellent photocoagulation response. Subsequent examination showed disappearance of the dark angiomatous lesion (Figure 11) and almost complete disappearance of edema and edema residue at the site of the lesion and in the macula (Figure 12). The vision on 17 April 1970 was 20/70.

#### DISCUSSION

The lesion we are describing is difficult to classify. We do not think it falls into the category of the vascular lesions described by Coats, Leber, or Reese. The lesion is central, there are no visible feeder vessels or telangiectases. The dark lesion shown in two of our cases did not appear to be fed by a larger vessel. Gass<sup>3</sup> and Maumenee<sup>4</sup> have described similar lesions, although their fluorescein pictures reveal abnormal capillary dilatation and visible ophthalmoscopic microaneurysms more compatible with telangiectasia.

Edema with hard yellowish striae dominate the fundus picture. Undoubtedly it is the result of some circulatory disturbance giving rise to the edema, hemorrhage, and hard white retinal deposits representing residual edema.

Our results would add further confirmation to Maumenee's contention that the lipid deposits are the result of a vascular disturbance rather than an alteration in the metabolism of the neural cells caused by anoxia.

Leber's retinopathy consists of numerous sacculated and fusiform swellings of terminal arterioles usually located at or posterior to the equator in one area of the fundus. The yellowish intraretinal exudates are often part of the picture. Wise<sup>5</sup> feels that these changes are the result of retinal hypoxia, probably secondary to capillary or venous obstruction. He thought that this might be an area of Coats's disease, but also maintained that this could lead to angiomatosis. Reese<sup>6</sup> was of the opinion that these changes were a form of capillary hemangioma, but in a later article<sup>2</sup> he concludes that they are probably a

telangiectasia, which he believes to be the forerunner of Coats's disease. Maggi<sup>7</sup> believed that Leber's disease, Coats's disease, and retinal telangiectasia are separate entities. He also thinks that retinal telangiectasia affects only the capillary network.

Telangiectasia of the retina has been described in detail by Reese, who considered it to be abnormal vascular changes throughout the retina, the vessels having retinal tissue as their stroma, rather than stroma of their own. These vascular malformations seem to be confined to the venous rather than the arterial side of the vascular tree. They are composed of vascular atresia with the formation of collateral channels. Reese feels that the accumulation of polysaccharide as a thick basement membrane under the epithelium of the vessels leads to atresia and occlusion of the vessels, and thus causes edema, exudation, and hemorrhage.

Telangiectasia as described by Reese is not an aneurysmal change in itself, but the vascular atresia and passive congestion may cause aneurysmal dilatation. Again, according to Reese, this is seen in children and young adults.

The patients that we have described are all adults and fluorescein angiography has shown no involvement of the arterial and venous tree of the retinal vasculature. Fluorescein angiography does suggest involvement of the capillary bed. The pathogenesis of these vascular lesions is purely speculative.

Wise<sup>8</sup> in discussion of Coats's disease considers three possible causes: (1) some interference with the nutritional supply to the outer retina from the choroid, (2) a primary defect in the deep retinal capillary bed, (3) a disturbance in the internal metabolic pathways within the outer retinal cells. He presents histologic evidence to refute his two primary hypotheses. Although we do not have any histologic confirmation, we feel that what we have described represents a defect in the deep retinal capillary bed.

#### SUMMARY

Leber's aneurysmal dilatation, telangiectasia, and Coats's disease have a vascular abnormality as the primary pathology. The changes are associated with the arterial and venous tree. Aneurysmal dilatations, yellowish exudation, and retinal detachment have been clinically described with the above conditions. Fluorescein angiography has helped in the understanding of the clinical course and possible pathogenesis of the above conditions. Theoretically the capillary bed

of the retinal vascular system can be primarily involved and present with a similar clinical picture. It is with this idea that we have described these three patients, speculating of course, that the primary fault with vascular abnormality lies with the capillary system of the retinal vasculature.

#### REFERENCES

1. Coats, G., Forms of retinal disease with massive exudation, *Royal London Ophth. Hosp. Rep.*, 17:440, 1907-8.
2. Reese, A. G., Telangiectasis of the retina and Coats's disease, *Am. J. Ophth.*, 42:1-8, 1956.
3. Gass, J. D. M., A fluorescein angiographic study of macular dysfunction secondary to retinal vascular disease. v. Retinal telangiectasis, *A.M.A. Arch. Ophth.*, 80:592-605, 1968.
4. Maumenee, A. E., Fluorescein angiography in the diagnosis and treatment of lesions of the ocular fundus, *Tr. Ophth. Soc. U. Kingdom*, 88:529-56, 1968.
5. Wise, G. N., Coats's disease, *A.M.A. Arch. Ophth.*, 58:735-46, 1957.
6. Reese, A. G., *Tumors of the Eye*, New York: Paul B. Hoeber, 1951.
7. Maggi, C., Leber's retinal degeneration with miliary aneurysms, *Am. J. Ophth.*, 56:901-7, 1963.
8. Wise, G. N., and A. Horava, Coats's disease, *Am. J. Ophth.*, 56:17-23, 1963.
9. Tour, R. L., Miliary retinal aneurysms, *Am. J. Ophth.*, 43:426-33, 1957.
10. Colyear, B. H., Retinal vascular lesions treated by photocoagulation, *Am. J. Ophth.*, 63:262-70, 1967.
11. Rosen, E., Vascular malformations in the human retina, *Am. J. Ophth.*, 67:501-11, 1969.
12. Witmer, R., F. Verrey, and P. Spenser, Retinal angiomatosis: Atypical cases of retinal angiomatosis and telangiectasis, *Bibl. Ophth.*, 76:113-23, 1968.

#### DISCUSSION

DR A. EDWARD MAUMENE. I greatly enjoyed listening to Dr McDonald's interesting presentation on the treatment of intraretinal angiomas. I agree with him that fluorescein angiography and photocoagulation have contributed to our knowledge of retinal vascular disease. In spite of this, however, we still do not know why Lindau-von Hippel disease, Leber's miliary aneurysms of the retina, Coats's vascular abnormalities, or retinal telangiectasia develops in patients. It is possible, however, to explain some of the secondary changes that occur in these conditions. I will discuss these shortly.

Dr McDonald was kind enough to send me a copy of his paper and some kodachrome fundus pictures of the lesions that he has described, but unfortunately he was not able to send me the fluorescein angiograms. I would strongly suspect from inadequate review of his material, because of the lack of angiograms, that what he has described are minute vascular occlusions with secondary aneurysmal dilatation of the collateral circulation in the retina. I have followed several patients with fluorescein angiography

from the time they developed a small occlusion in the capillary bed of the retina to the point when they developed an aneurysmal dilatation of a vessel in the adjacent capillary bed, then on to further dilatation of the surrounding capillaries, and the development of a ringlike lipid deposit in the normal retinal tissue surrounding the vascular accident.

I mention that fluorescein angiography and photocoagulation have helped in understanding the course of events in abnormalities of the retinal vasculature. In all patients that I have studied in the above categories, I have found that there is an obliteration of some capillaries and dilatation of the adjacent capillaries, and that these dilated capillaries show an abnormal permeability to fluorescein. Over a period of time, lipid will accumulate in the surrounding normal retina. I believe that the lipid deposits are caused by a leakage of serum from the abnormal capillaries and an absorption of this serum in the area of the normal capillaries with a selective deposition of lipid. This idea is supported by the fact that photocoagulation of the abnormal capillaries results in a clearing of the lipid from the retina.

I do not have a clear explanation of why massive amounts of subretinal lipid can occur in conditions such as Coats's disease, or why lipid will form in great amounts in the macular area as a result of a vascular lesion in the periphery of the retina.

The concept of vascular leakage and selective absorption with deposition of lipid is not peculiar to the retina. Similar changes can be seen in the cornea, in the clear zone between the limbus and the arcus senilis, or at the tip of vessels that have grown into the cornea from various forms of vascular pathology.

Again, I wish to thank Dr McDonald for his very interesting presentation and to ask him if in the early fluorescein angiograms he noted any abnormal dilatation of the retinal capillaries surrounding the angiomas that he photocoagulated.

**DR McDONALD.** We have not taken angiograms in the very early stages. In the one slide of Coat's disease, however, even there you saw some dilatation and irregularity of some of the larger vessels in the retina. However, Dr Maumenee is quite correct: I think what we are talking about is just variations of a theme.

It is a vascular lesion, and some of these lesions probably occur within the retina itself in the smaller capillaries. We feel if these lesions are recognized early and are treated, this can only confirm Dr Maumenee's contention that the lipid deposits are the result of vascular change rather than due to hypoxia. Fortunately these lesions are central, but unfortunately the patients do not always come for treatment early. I am sure if we got early angiograms in some of these lesions at the posterior pole we might be able to effect considerable improvement in vision in some of these patients.