

## DRUSEN AND DISCIFORM MACULAR DETACHMENT AND DEGENERATION

BY *J. Donald M. Gass*, MD

ALTHOUGH THERE IS STILL CONTROVERSY CONCERNING THE TERMS *familial drusen*, *senile drusen*, *senile macular degeneration*, and *senile disciform macular degeneration*, the trend in recent years has been toward considering all of these names as synonymous for what is probably a single heredodegenerative disease. It is generally accepted now that Hutchinson-Tay's central guttate choroiditis,<sup>1</sup> Doyne's honeycomb choroiditis,<sup>2,3</sup> Holthouse-Batten's superficial chorioretinitis,<sup>4</sup> and malattia levan-tinese<sup>5</sup> are names describing the same disease, familial or dominantly inherited drusen. While some authors<sup>6,7</sup> believe these patients are different from those with senile drusen, the criteria for making this distinction are not clear.

For many years after the classical descriptions of macular drusen<sup>8</sup> and disciform macular detachment<sup>9-11</sup> were reported the close relationship of the two diseases was generally overlooked. More recently authors have stressed the frequency with which drusen are noted in the opposite eye of older patients with disciform macular lesions.<sup>12-15</sup>

The term *senile macular degeneration* has been used since the disease was first described as a clinical entity by Haab<sup>16</sup> in 1885. It refers to a variety of pigmentary and atrophic changes in the macular region which in most instances are indistinguishable from those described in patients with senile macular drusen and various stages of disciform detachment. While Duke-Elder<sup>17</sup> states that a hereditary tendency in senile macular degeneration is not marked, other authors<sup>13,15,16,18-20</sup> believe that it is a heredodegenerative disease.

While many forms of medical therapy have been proposed for these patients, there is no convincing evidence that any are of value. Recently photocoagulation has been proposed as a possible means of reversing early senile disciform detachment of the macula,<sup>15,21-30</sup> and also as a potential means of preventing disciform detachment.<sup>27-29</sup>

The evaluation of treatment in these patients is difficult because of

the paucity of information concerning the natural course of this disease. Only a few studies of large series of these patients are available.<sup>12,14,31</sup>

The purposes of this report are: (1) to summarize the clinical findings and course of 200 patients followed since 1960 at the Bascom Palmer Eye Institute (BPEI) for macular drusen and its complications; (2) to formulate guidelines for counseling patients concerning the natural course and therapy of the disease; (3) to evaluate the effectiveness of photocoagulation as a means of favorably influencing the natural course of this disease; and (4) to reinforce the concept that familial drusen, senile macular drusen, senile macular degeneration, and senile disciform macular degeneration are all terms for the same heredodegenerative disease which affects primarily the retinal pigment epithelium, Bruch's membrane, and the choriocapillaris, and only secondarily the retina.

#### METHODS AND MATERIALS

Between June 1963 and January 1972 approximately 16,500 patients had fundus photographs taken at the BPEI. Approximately 30 per cent of these patients have also had one or more fluorescein angiographic studies. Since July 1965 photographic evaluation has routinely included stereo color photographs and stereo black and white angiographs. The techniques of stereo fundus photography and angiography have been reported previously.<sup>32</sup> During the past three years the Baird Atomic Interference B4 filter and a No. 12 Wratten yellow filter have replaced the original Wratten 47 and 15 filters in the Zeiss fundus camera.

Fundus photographs of patients which were coded as drusen of Bruch's membrane, familial drusen, Doyme's honeycomb choroidopathy, senile macular degeneration, senile disciform macular degeneration, and Kuhnt-Junius macular degeneration, through December 1969, were reviewed. In 258 patients the media was sufficiently clear to obtain good quality photographs, and sufficient clinical information was on file to substantiate the diagnosis. Special care was taken to exclude patients with other causes of disciform detachment, such as myopic degeneration, pseudoxanthoma elasticum, Paget's disease, the presumed ocular histoplasmosis syndrome, and *Toxocara canis*, as well as patients with fundus flavimaculatus, fundus albipunctatus, and central areolar choroidal sclerosis.

During 1970 and 1971 an attempt was made to recall all of these patients for examination and to obtain interval and follow-up information from their referring physicians. Eighty-five of these patients were

lost to follow-up for a variety of reasons. One hundred and eighty patients with a two-year or greater follow-up were included in this study. An additional 20 patients treated with photocoagulation and with only a one-year follow-up were also included. Approximately 50 per cent of the 200 patients have been followed by the author at periodic intervals during the past eight years as a part of a large clinical study of macular diseases. One hundred and ninety patients had complete ophthalmic evaluation at the BPEI. The history and findings in 10 patients seen at the BPEI for photographic evaluation only were obtained from the referring physician. One hundred and forty-nine patients were photographed on two or more occasions over a period averaging four years. The remainder had photographs only on a single occasion. Most had one or more fluorescein angiographic studies.

Fifty-three of the 200 patients had photocoagulation in 56 eyes. The Zeiss xenon photocoagulator and the American Optical ruby laser were used in all but one eye which was treated with the Coherent Radiation argon laser.

Thirty-six of the 200 patients and 16 others with macular drusen and disciform detachment seen during the past year for the first time had electroretinography and electro-oculography utilizing the techniques of Arden<sup>33</sup> and the guidelines for interpretation suggested by Henkes.<sup>34</sup>

In this report the term *disciform detachment and degeneration* will be used to refer to the three basic pathologic processes which lead to significant loss of central vision in patients with drusen: (1) serous exudation from the choriocapillaris through an intact Bruch's membrane into the subpigment epithelial space and then into the subretinal space producing varying degrees of serous detachment of the pigment epithelium and retina; (2) neovascular ingrowth through breaks in Bruch's membrane into the subpigment epithelial space with serous and hemorrhagic detachment of the pigment epithelium and retina; and (3) geographic or areolar atrophy of the pigment epithelium usually with no evidence of defects in Bruch's membrane. Each of these pathologic alterations presents a characteristic ophthalmoscopic appearance that can be identified best with biomicroscopy, stereo fundus photography, and angiography.<sup>15,35</sup>

For purposes of presentation these patients with drusen in the macula and paramacular region are here subdivided into three groups, based on the findings when they were seen initially at the BPEI: group I – those with no evidence of disciform detachment and degeneration in either eye; group II – those with disciform lesions in only one eye; and group III – those with bilateral disciform detachment and degeneration.

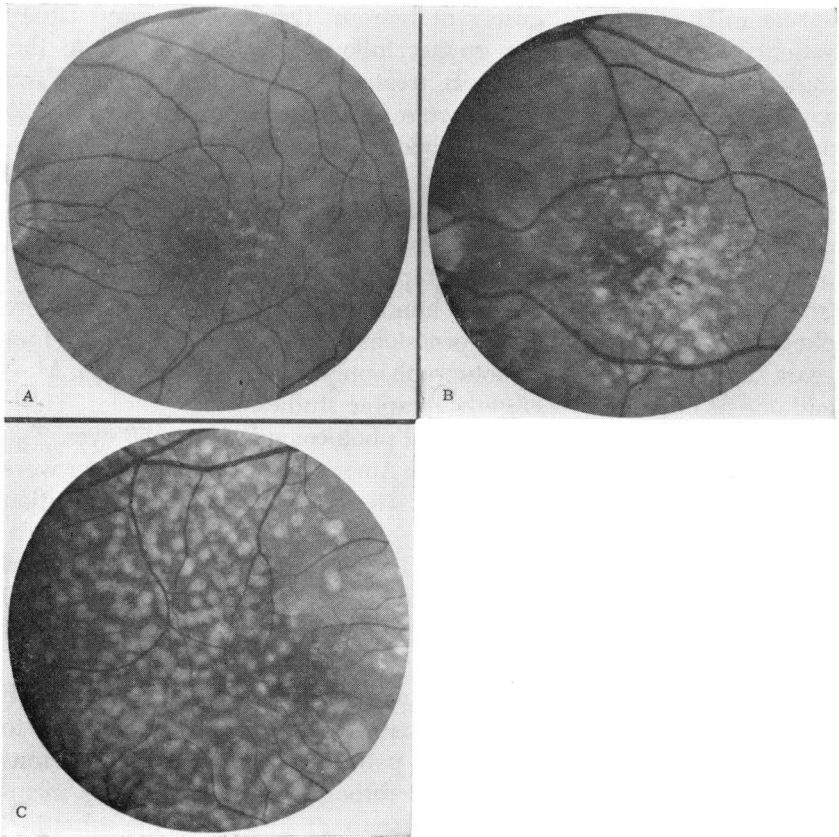


FIGURE 1

Grading of macular drusen. A: Grade I. B: Grade II. C: Grade III.

The size and number of drusen in the macular area were arbitrarily graded I, II, or III (Figure 1). Although in retrospect it would have been desirable to do so, no attempt was made to grade the degree of drusen deposition that was present in the peripheral fundi of all of these patients.

#### FINDINGS

##### GROUP I. BILATERAL DRUSEN WITHOUT DETACHMENT

###### *Initial Examination*

Forty-nine patients had drusen in the macula or paramacular region bilaterally when first seen at the BPEI. Seventeen were male and 32 were

female. Forty-seven were Caucasian and 2 were Negro. The average age when the patient was first seen at the BPEI was 61 years (range 29 to 81 years). When first examined at the BPEI, visual acuity in both eyes was 20/20 or better in 21 of the 49 patients, and 20/25 to 20/40 in 18 patients. Four patients had 20/50 to 20/200 vision in one or both eyes due to nuclear sclerotic cataracts. Three patients had vision of 20/70 to 20/400 in one eye because of other diseases affecting central vision (rhegmatogenous retinal detachment, optic atrophy, and acute multifocal posterior placoid pigment epitheliopathy<sup>36</sup>).

The drusen in the macular region in these patients were graded as follows: grade I – 15 patients; grade II – 26 patients; and grade III – 3 patients (Figure 1). Five patients had many drusen scattered in the perimacular, peripapillary, and peripheral regions, but virtually none centrally. In approximately two-thirds of the patients the size and distribution of drusen in the two eyes were symmetrical. In most the drusen were centered in the macular area. In some they were centered temporal to the macula, and in a few, nasal or above or below the macula. Biomicroscopic examination of the fundus often revealed many drusen not seen in the fundus photographs. Retro-illumination with the slit-lamp beam was helpful in detecting drusen that were not visible ophthalmoscopically because of the minimal thinning and loss of pigment from the overlying pigment epithelium. The three-mirror gonioscope was particularly useful in detecting the many small drusen scattered throughout the peripheral fundus in most of these patients. Fluorescein angiography also detected some drusen missed by other methods of examination.

### *Follow-up Examinations*

The average period of follow-up after the initial visit to the BPEI was 4.9 years. Thirty-three patients had two or more photographic studies over an average period of 4.7 years.

Nine of the 49 patients developed loss of central vision in one eye due to disciform macular detachment or degeneration during the follow-up period. The average age at the time of visual loss was 75 years (range 71 to 79 years). Three patients had grade I drusen and 6 patients had grade II drusen. Five of these 9 patients lost central vision in the second eye during the follow-up period. The average age of the patients at the time of visual loss in the second eye was 76 years (range 73 to 81 years). Eight patients lost central vision due to disciform detachment in 8 eyes and geographic atrophy of the pigment epithelium in 5 eyes. Visual loss in 1 patient followed only by his local

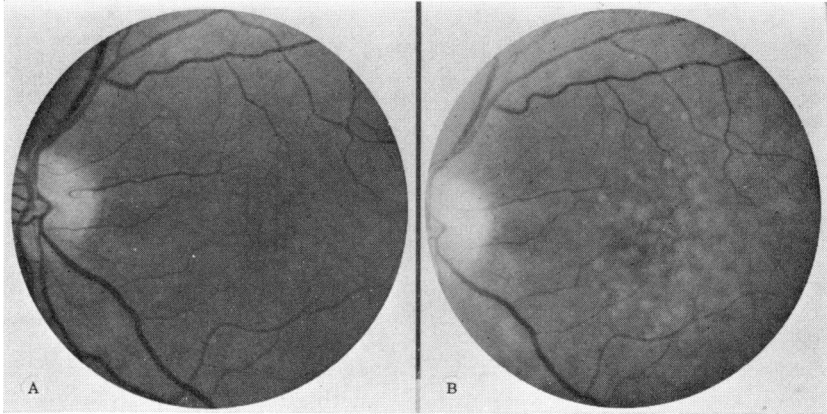
physician was attributed to senile macular changes of unspecified type. All 5 patients with bilateral involvement had less than 20/200 vision in both eyes within one year after onset of visual loss in the second eye.

Forty patients did not develop disciform detachment or degeneration during the course of the study. Twenty-one patients had no loss in acuity (decrease of more than one line of acuity) in either eye during the study. Fourteen lost two lines of acuity associated with changes in the appearance of the drusen in at least one eye. Four patients lost more than two lines of acuity in at least one eye. This was associated with confluence of drusen in 1 patient, immature cataract in 2 patients, and corneal edema in 1 patient. One patient treated prophylactically in one eye with the ruby laser maintained 20/25 vision in both eyes one year after treatment. The only patient with 20/200 vision secondary to cataracts on initial examination achieved 20/25 vision following cataract extraction. Follow-up photographs in 7 patients followed for an average period of three years showed no change in the macular region. Seventeen patients followed for an average of five years showed an increase in the number and size of the drusen in the macula (Figure 2). There was fading or disappearance of some of the drusen in 5 patients followed for an average of five years (Figure 3). Small areas of geographic atrophy of the pigment epithelium occurred in 5 patients followed for an average of five years (Figure 4).

#### GROUP II. PATIENTS WITH DISCIFORM DETACHMENT AND DEGENERATION IN ONE EYE

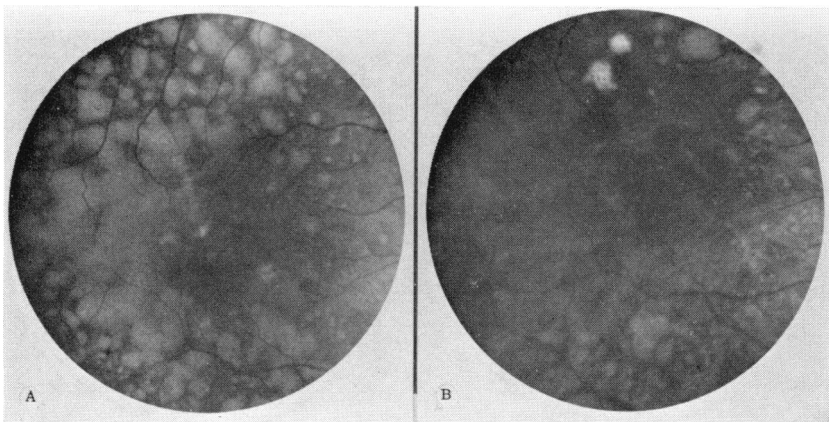
##### *Initial Examination*

Ninety-one patients, all Caucasian, had loss of central vision in one eye (50 right eyes, and 41 left eyes) secondary to disciform macular detachment or degeneration at the time of initial examination at the BPEI. All had drusen in the macula of the opposite eye. Fifty-two were female and 39 were male. The average age when first seen at the BPEI was 67 years (range 49 to 82 years). Determination of the time of onset of loss of central vision in the first eye was difficult in many patients. The average age when loss of central vision was first discovered in the first eye was 66 years (range 51 to 81 years). When seen initially at the BPEI, the visual acuity in the affected eye was 20/200 or less in 51 patients, and was 20/40 or better in 20 patients. The visual acuity in the opposite eye without detachment was 20/20 in 30 patients and 20/40 or better in all but 7 patients. Three of these latter patients had immature cataracts, 1 had a macular hole, 1 had an old central retinal artery occlusion, and 2 had suppression amblyopia.



**FIGURE 2**

Progressive development of drusen. A: August 1965. B: Same patient, December 1971.



**FIGURE 3**

Fading of drusen. A: October 1967; visual acuity 20/40. B: Same patient, December 1971; visual acuity 20/40.

Table 1 summarizes the findings in the symptomatic eye at the time of initial examination. In 6 patients there was a small extrafoveal serous detachment of the pigment epithelium underlying a serous detachment of the retina that extended into the macula. Ten patients had large serous detachments of the pigment epithelium underlying larger areas of serous retinal detachment that extended into the central macular area. Sixty-six of 91 eyes had various stages of serous and hemorrhagic

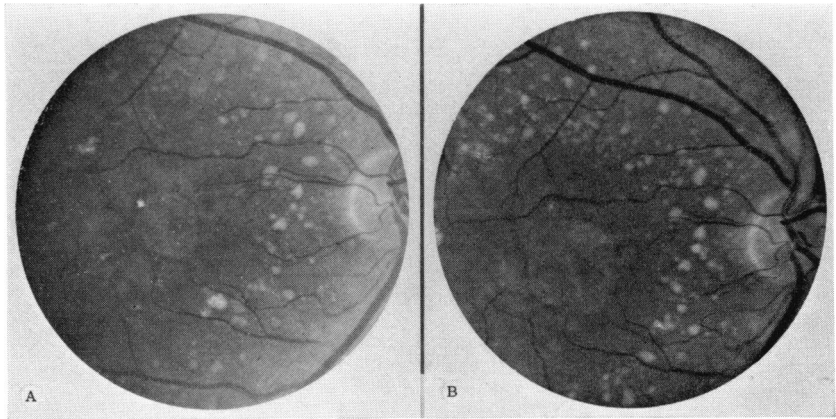


FIGURE 4

Progression of geographic atrophy. A: November 1969; visual acuity 20/200. B: Same patient, November 1971; visual acuity 20/200, despite enlargement of areas of geographic atrophy.

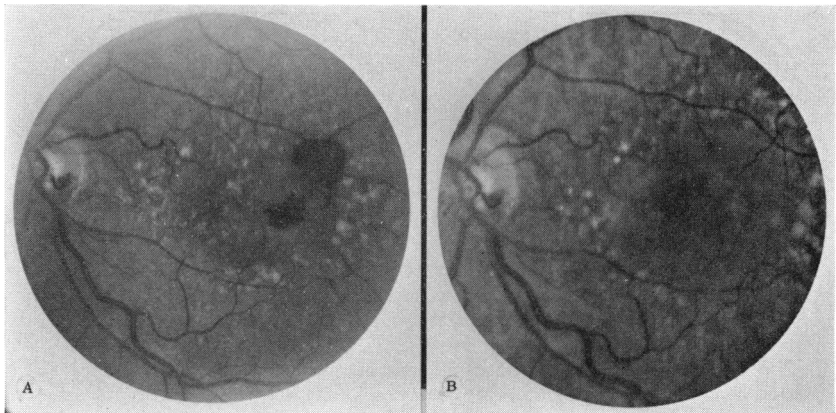


FIGURE 5

Spontaneous resolution of small hemorrhagic disciform detachment. A: August 1964; visual acuity 20/25. B: November 1971; visual acuity 20/40.

or cicatricial disciform detachment of the macula associated with neovascular ingrowth from the choroid into the subpigment epithelial space. Nine eyes had geographic atrophy of the pigment epithelium involving the central macular area.

The drusen in the opposite eye of each of the 91 patients were graded as follows: grade I - 30 patients; grade II - 55 patients; and grade III - 6 patients.



TABLE I. STAGE OF DISCIFORM MACULAR DETACHMENT AND DEGENERATION IN 211 EYES OF 151 PATIENTS WHEN SEEN INITIALLY AT THE BASCOM PALMER EYE INSTITUTE

	Number of eyes	
	Group II	Group III
Small serous detachment of pigment epithelium with overlying serous retinal detachment	6	3
Large serous detachment of pigment epithelium	10	15
Subpigment epithelial neovascular membrane (extrafoveal)	9	6
Subpigment epithelial neovascular membrane (foveal)	16	13
Hemorrhagic detachment of the pigment epithelium	7	6
Hemorrhagic detachment of retina secondary to extrafoveal subpigment epithelial neovascular membrane	2	3
Partly or completely organized disciform scar	32	60
Geographic atrophy of the pigment epithelium	9	14
TOTAL	91	120

### *Follow-up Examination*

These patients were followed for an average of four years after their initial visit to the BPEI. Fifty-nine of the 91 patients had two or more photographic studies. Thirty patients had photocoagulation in 32 eyes.

The visual acuity in the first eye at last examination was 20/200 or less, secondary to late stages of disciform detachment and degeneration in all but 18 eyes, and was 20/50 or better in only 10 eyes, 6 of which had received photocoagulation. There was remarkable retention of useful central vision in 2 eyes following spontaneous resolution of subretinal blood derived from an extrafoveal area of neovascularization (Figure 5). Two eyes with a small perifoveal macular disciform scar retained 20/50 vision.

Thirty-one of the 91 patients developed loss of central vision in the second eye secondary to disciform detachment and degeneration of the macula. Six had grade I drusen, 24 had grade II, and 1 had grade III drusen. The average age at the onset of visual loss in the second eye was 71 years (range 59 to 85 years). The average interval of time between the discovery of visual loss in the first eye and the onset of loss in the second eye was 3.7 years (range 0 to 10 years). Eighteen of the 31 patients had rapid and permanent loss of vision in the second eye secondary to disciform detachment. In 28 eyes the visual acuity was 20/200 or less when last seen. Two patients who received photocoagulation for serous detachment of the pigment epithelium and retina had resolution of their detachment and good acuity (20/30 and 20/25).

The ophthalmoscopic and fluorescein angiographic studies done in the second eye prior to development of detachment were of value in predicting future macular detachment in only 2 patients. Both showed prominent areas of fluorescein staining in the paracentral region where no lesion was noted clinically. Both patients developed disciform detachment of the macula within several months. Serial photography was of value in predicting future visual trouble in those patients with geographic atrophy of the pigment epithelium. The site of the geographic atrophy often began in the extrafoveal area and gradually enlarged in a concentric fashion to spread into the macular area over a period of many months.

Sixty patients with the average age of 70 years when last seen did not develop macular detachment in the second eye. Thirty-eight patients had multiple photographic studies. Thirty-six patients had no loss of acuity (a decrease of more than one line in acuity). The remaining patients lost from two to four lines of acuity (none less than 20/80) during the study. Thirty-six patients had at least 20/30 or better, and 50 patients had 20/50 or better acuity. Only 8 patients had lost three or four lines of acuity secondary to confluence of drusen (4 eyes), macular hole (1 eye), and cataract (1 eye). Serial fundus photographs were unavailable in 2 eyes.

Twenty of these eyes followed for an average of two years showed no change in the size or pattern of macular drusen. Twelve eyes followed for an average of over three years showed an increase in the number and size of macular drusen. In 4 eyes followed for an average of four years there was fading or partial disappearance of the drusen. Over a four-year period 1 patient developed calcification of the drusen, and 3 patients developed small localized areas of extrafoveal geographic atrophy of the pigment epithelium.

Twenty-three patients (average age 72 years) in group II were legally blind (20/200 or less in both eyes) from disciform detachment or degeneration when they were last seen. Only 2 of these were under 65 years of age.

#### GROUP III. PATIENTS WITH BILATERAL DISCIFORM DETACHMENT AND DEGENERATION

##### *Initial Examination*

Sixty patients had disciform detachment or central geographic atrophy of the pigment epithelium in both eyes at the time of initial examination at the BPEI. All were Caucasian. Thirty-one were male and 29 were female. Their average age was 70 years (range 54 to 86 years)

when they were seen initially at the BPEI. The average age of onset of discovery of visual loss in the first eye was 66 years (range 56 to 81 years). The right eye was affected first in 23 patients, and the left eye first in 21 patients; 16 patients were uncertain as to which eye was affected first. The average age of onset of loss of vision in the second eye was 70 years (range 53 to 81 years). The average interval between loss of central vision in the first eye and loss in the second eye was approximately four years (range 0 to 18 years). The visual acuity was 20/200 or less in 82 of the 120 eyes at the time of initial examination at the BPEI; it was 20/40 or better in only 13 eyes.

In 88 eyes with serous and hemorrhagic or late cicatricial stages of disciform detachment there was ophthalmoscopic and angiographic evidence of neovascular ingrowth from the choroid through Bruch's membrane into the subpigment epithelial space (Table 1). Blood or fibrovascular tissue or both extended beneath the pigment epithelium in the central macular area in 79 of the 88 eyes. In 9 eyes the blood and fibrovascular tissue were confined to the extrafoveal area. In 3 of these 9 eyes blood in the subretinal space extended into the central macular area. In only 18 eyes was there serous detachment of the pigment epithelium and retina without ophthalmoscopic or angiographic evidence of neovascular ingrowth through Bruch's membrane. In 10 eyes the pigment epithelial detachment extended beneath the fovea. Fourteen eyes had loss of central vision due to geographic atrophy of the pigment epithelium. Geographic atrophy was bilateral in 4 patients and associated with a disciform detachment in 6 patients.

### *Follow-up Examination*

The average period of follow-up in these 60 patients was 3.3 years after their initial visit to the BPEI. Forty-six patients had two or more fundus photographic studies. Twenty-three eyes of 22 patients were treated with photocoagulation. Twenty-six patients, including 9 treated with photocoagulation, became legally blind (20/200 or less in both eyes) within the first year after their initial visit. Forty-one patients (average age 73 years), including 16 treated with photocoagulation, were legally blind at their last examination. Only 5 legally blind patients were under 65 years of age. Only 9 patients in group III retained 20/50 or better vision in at least one eye.

The macular detachment resolved in 9 eyes, 7 of which had been treated with photocoagulation. In only 5, however, was the acuity 20/50 or better. Four eyes of 3 patients with persistent serous detachment of the pigment epithelium centrally maintained 20/40 or better

acuity for an average period of almost two years. One patient with geographic atrophy of the pigment epithelium maintained 20/50 acuity.

#### OTHER OCULAR FINDINGS

Approximately one-third of the 200 patients in this study had varying degrees of a reticular pigmented network (referred to at the BPEI as senile reticular pigmentary degeneration) in the equatorial area of the fundus. It was often more evident nasally. When prominent, it was confused by some observers with bone spicule pigment migration into the retina. With the gonioscopy it was noted that this peculiar pigment change was located beneath the retina and was closely associated with heavy drusen deposition. Figure 6 depicts these changes in a 75-year-old man with only a few drusen in the macular area. This eye was enucleated because of a malignant melanoma of the choroid. Microscopic examination revealed heavy drusen deposits, and in some areas focal collections of large pigment epithelial cells immediately adjacent to the drusen. These cells are presumed to be the cause of the reticular network noted ophthalmoscopically.

One patient with grade 1 macular drusen and many peripheral drusen had a localized serous detachment of the pigment epithelium, three disk diameters in size, at the equator temporally. It was initially diagnosed as a malignant melanoma of the choroid. During the past year I have seen two other patients with macular drusen and similar peripheral pigment epithelial detachments (one serous and one hemorrhagic) who were misdiagnosed as having a choroidal melanoma in one case, and a localized rhegmatogenous retinal detachment in the other.

#### GENERAL MEDICAL HISTORY

The great majority of these patients were in good health at the time of onset of visual loss. Twenty per cent of the patients had a history of hypertension of mild to moderate severity. Ten per cent had diabetes which in most cases was managed with diet alone or oral hypoglycemic medications. Only one had significant retinal microangiopathy, and that was discovered only after fluorescein angiography. Approximately 20 per cent gave a past history of some cardiovascular disorder, myocardial infarction being the most common. Other than appendectomy, cholecystectomy was the most common major operative procedure in this group (10 per cent).

In only a few instances was the patient able to relate the onset of visual difficulty to his general health. Detachment of the macula occurred in several patients during times of unusual mental stress. Four

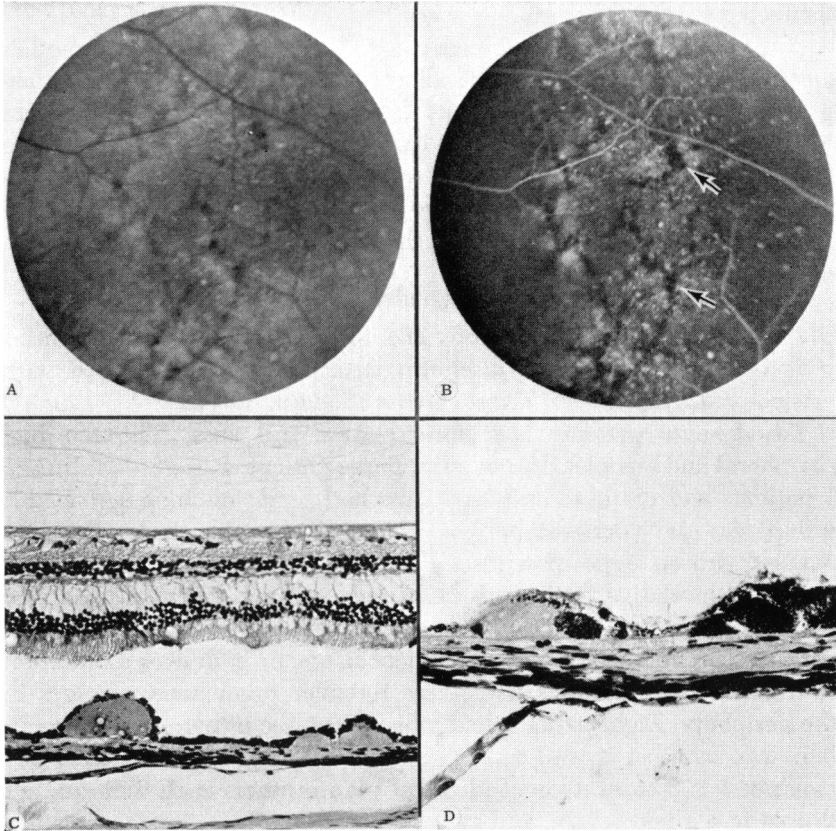


FIGURE 6

Senile reticular pigment epithelial degeneration. A: Multiple drusen and network of pigment in the peripheral fundus. B: Fluorescein angiography; dark areas (arrows) outline the subretinal pigment. C: Photomicrograph showing multiple drusen; hematoxylin-eosin,  $\times 100$ . D: Photomicrograph of large pigment epithelial cells adjacent to drusen; hematoxylin-eosin,  $\times 250$ .

patients developed hemorrhagic macular detachment while on anti-coagulant therapy.

#### FAMILY HISTORY

Thirty-eight patients, eight in group I and 15 each in groups II and III, gave a positive family history of similar macular disease in one or more members of the family. Twenty-seven had one other family member affected (14 mothers; 2 fathers; 7 sisters; 3 brothers, including 1 who was an identical twin; and 1 maternal uncle). Two female patients had

2 affected sisters. One female patient had 5 affected sisters (Figure 7). A parent and one or more siblings were affected in 5 cases. The mother and father of one patient were affected. Two sisters and a maternal grandfather were involved in one family. A brother and sister were involved in one family. I was able to confirm the familial history either by examination of the relative or by contacting the relative's ophthalmologist for 10 patients. The average age of the 38 patients with positive family histories was 66 years when they were first examined at the BPEI.

#### ELECTRO-OCULOGRAPHY AND ELECTRORETINOGRAPHY

Thirty-seven patients in this study and 15 others seen in recent months with macular drusen and disciform detachment were studied with electro-oculography (EOG) and electroretinography (ERG).

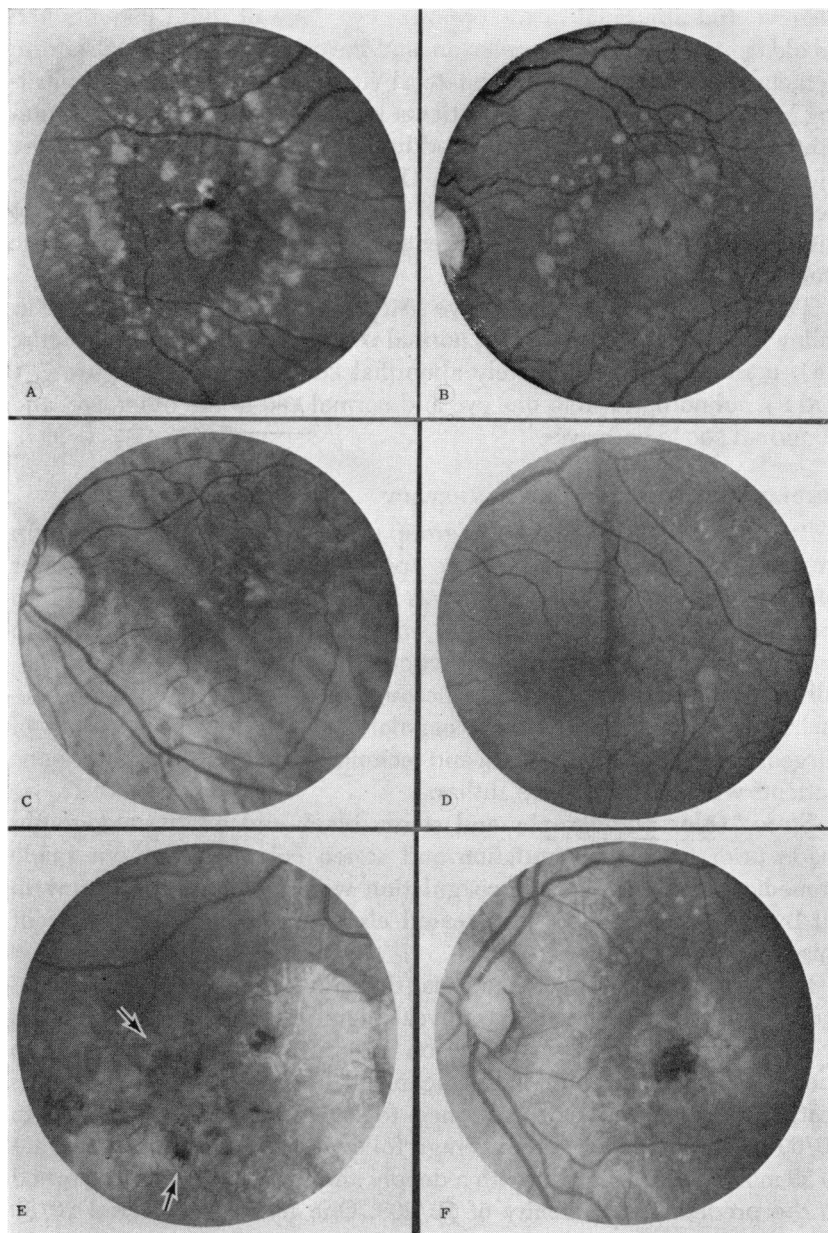
Twenty-nine patients had normal EOGs and ERGs. Thirteen had peripheral and macular drusen only. Three patients had grade I drusen, 7 patients had grade II, and 3 patients had grade III. Included in this group was the youngest patient (29 years) in the study. She had massive drusen deposition throughout the fundus and peripapillary region with relative sparing of the macula and paramacular areas. She had a negative family history. Sixteen patients had disciform lesions of various sizes and stages of development in one or both eyes in addition to drusen. Eight patients had senile reticular pigmentary changes in the periphery. Eight patients had a history of one or more family members who had lost central vision from macular degeneration. This was confirmed in 3 cases. One of identical twin brothers each with grade I drusen had a normal EOG and ERG.

Twelve patients had a normal ERG and a definitely abnormal EOG. Four patients had grade II drusen, 2 had grade III drusen, and 6 had various stages of disciform detachment in addition to drusen. Three of these 10 patients had a positive family history of macular degeneration. Two had senile reticular pigmentary changes in the periphery.

Eleven patients had abnormal EOG and ERG studies. Three patients gave a positive family history. In 2 patients the studies were normal in

FIGURE 7 (*opposite*)

Five sisters with macular drusen. A: Right eye of sister 1, age 63; visual acuity 20/50. B: Left eye of sister 2, age 60, showing serous detachment of the pigment epithelium. C: Left eye of sister 3, age 66. D: Left eye of sister 4, age 69; visual acuity 20/30. E: Right eye of sister 5, age 63; visual acuity 20/200; note disciform scar (arrows) and large area of geographic atrophy of pigment epithelium. F: Left eye of sister 5; visual acuity 20/40; note small central pigmented disciform scar and papillary geographic atrophy of the pigment epithelium.



one eye and abnormal in the opposite eye. One of these patients had an old central retinal vein occlusion, and the other had a large disciform detachment. One patient had bilateral vitreous hemorrhage complicating his macular disease. Two patients had generalized hypopigmentation of the pigment epithelium in addition to geographic atrophy of the pigment epithelium in the macula. One patient had angiographic evidence of diabetic microangiopathy. Five patients had no features to distinguish them from those patients with normal electrophysiologic studies.

The findings for three of the five sisters depicted in Figure 7 were as follows: sister one (Figure 7A), normal EOG and ERG; sister two (Figure 7B), normal ERG and definitely abnormal EOG; sister five (Figure 7, E and F), subnormal ERG in one eye and normal ERG in the other eye, and abnormal EOG in both eyes.

#### RESULTS OF PHOTOCOAGULATION THERAPY

Fifty-six eyes of 53 patients (1 in group I, 30 in group II, and 22 in group III) were treated with one or more applications of xenon or ruby laser photocoagulation. One patient was treated with argon laser. Two patients with drusen had multiple small ruby laser burns scattered in the extrafoveal area as a prophylactic measure to prevent detachment. All other patients had treatment because of serous or hemorrhagic detachment of the macula. Photocoagulation was done by a variety of surgeons using different criteria and techniques for treatment. Forty-one patients were treated by the author.

Stereo color photographs and stereo black and white angiographs made prior to photocoagulation and stereo color photographs made immediately following photocoagulation were available for review in all but one patient who was treated elsewhere during the course of this study.

Eight patients with serous retinal detachment in the macula secondary to one or more small extrafoveal pigment epithelial detachments were treated by ruby laser (or argon laser in 1 patient) application to the area of pigment epithelial detachment. In 6 patients the retina was reattached, and the acuity returned to levels ranging from 20/25 to 20/60 in 4 patients, with an average follow-up of 15 months (range 1 to 29 months). In 1 patient with a deeply amblyopic eye vision returned to the predetachment acuity of 20/200. One patient recovered 20/30 vision for approximately ten months before redetachment occurred. Four additional photocoagulation treatments resulted in reattachment of the macula. Following retrobulbar anesthesia for the last treatment,



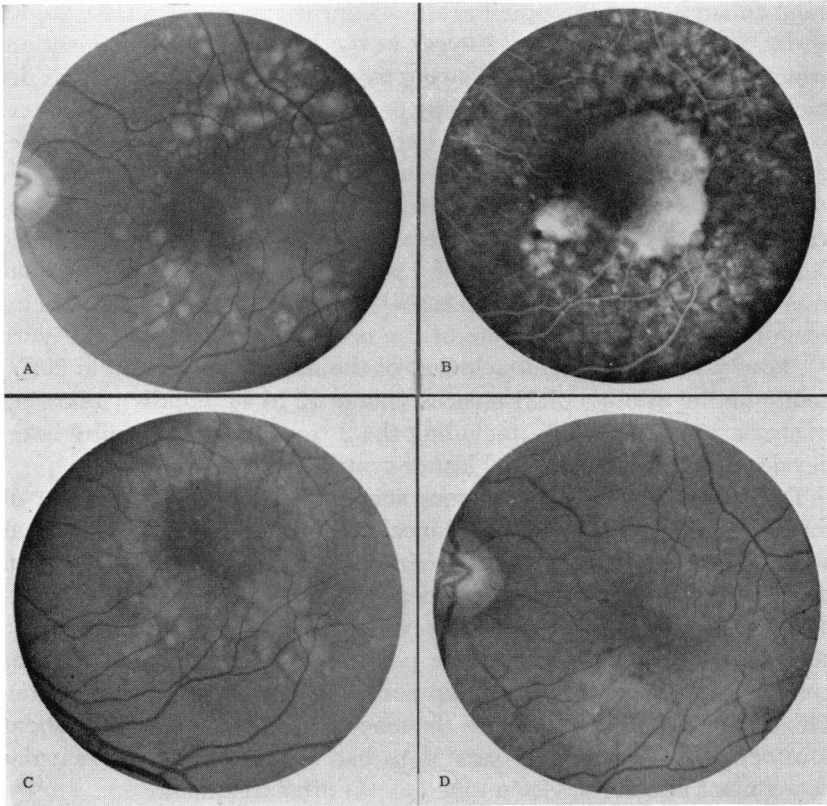


FIGURE 8

Collapse of serous detachment of the pigment epithelium following ruby laser photo-coagulation. **A:** July 1970; drusen in area of detachment have faded; visual acuity 20/40. **B:** Angiography outlines area of pigment epithelial detachment. **C:** Multiple applications of one degree ruby laser treatment to margins of the detachment. **D:** One month later the detachment, as well as many of the drusen, have disappeared; visual acuity 20/40.

however, she developed a retrobulbar hemorrhage and central retinal artery obstruction. Her present vision is counting fingers only. Two of the 8 patients developed ingrowth of new vessels into the macular area and were left with counting fingers vision.

Thirteen eyes of 12 patients with large serous detachment of the pigment epithelium extending beneath the fovea were treated with ruby laser applications to the margin of the detachment (Figure 8), as well as to several localized areas within the extrafoveal portion of the pigment epithelial detachment. In 7 eyes the pigment epithelial detach-

ment collapsed and the visual acuities returned to 20/30, 20/40, 20/40, 20/60, 20/100, and 20/200 (2 eyes) at the last follow-up examination, which averaged 16 months following treatment. In 1 eye the serous detachment of the pigment epithelium persisted, but was less elevated one year after treatment. The acuity had not improved. Five patients developed organized disciform scars and counting fingers vision.

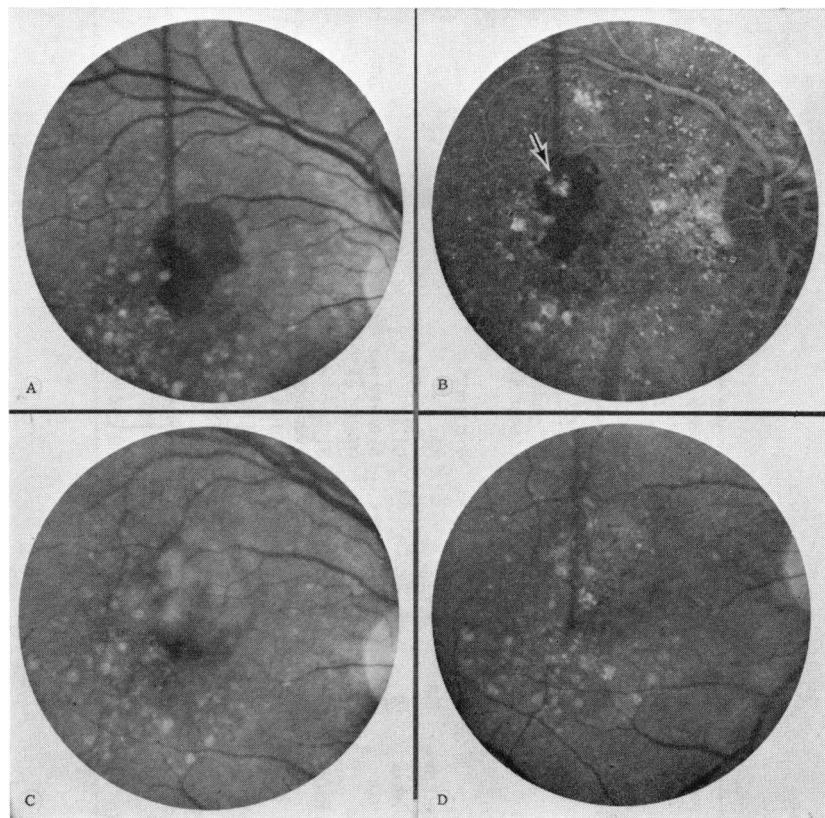
Seven patients with localized extrafoveal subpigment epithelial neovascular membranes and serous detachment (6 eyes) and hemorrhagic detachment (1 eye) of the retina extending into the central macular area were treated with xenon (5 cases) and ruby laser (2 cases) photocoagulation directed to the site of the neovascular membrane (Figure 9). Four patients had re-attachment of the macula and 20/30 to 20/50 acuity on the average of 21 months (range 12 to 44 months) following treatment. Three patients, including the 2 treated with the ruby laser, developed disciform scars and loss of central vision.

Twenty-five patients had various stages of disciform detachment of the macula in which there was clinical and angiographic evidence that subpigment epithelial neovascularization extended either to within one-fourth disk diameter of or beneath the fovea. In many eyes treatment was utilized only as a means of possibly reducing the size of the central scotoma by destroying the new vessels in the central macular area. Only 2 patients in this group achieved better than 20/200 vision. The treatment failed to reattach the macula in 24 patients. One patient considered to be a "poor" candidate had resolution of the macular detachment and 20/30 vision nine months after treatment.

#### DISCUSSION

Table 2 summarizes some of the clinical findings in this study. There was no statistically significant difference in the involvement of male and female. Only two patients in the study were Negro; neither developed disciform detachment of the macula. Six other Negro patients with drusen have been seen at the BPEI, but all were lost to follow-up examination. Only one had disciform detachment of the macula. It is of interest that disciform macular detachment from other causes, e.g., idiopathic central serous choroidopathy, the presumed ocular histoplasmosis syndrome, and *Toxocara canis*, is relatively rare in the Negro.

The question arises as to when macular drusen first appear. Little information is available concerning so-called senile macular drusen. Pearce<sup>6</sup> studied 76 affected members in six families with dominantly inherited drusen and found that they appeared first in the 20-to-30-year

**FIGURE 9**

Resolution of subretinal hemorrhage following xenon coagulation of an extrafoveal area of neovascularization. A: July 1970; visual acuity 20/70. B: Angiography indicates site of small neovascular membrane (arrow). C: Xenon photocoagulation. D: June 1971; visual acuity 20/40.

age group. Deutman<sup>7</sup> found familial drusen in 12- and 14-year-old patients. One 12-year-old patient with macular drusen was seen at the BPEI but was not included in the study because of inadequate follow-up. Few patients in the present study had had ophthalmoscopic examination earlier in life. One 71-year-old woman with grade III drusen and 20/20 vision in both eyes had had marked drusen for at least 46 years. She had no family history of macular drusen.

The results in this study and others<sup>6,7</sup> reveal that gradual changes do occur over a matter of years in the number, size, color, and distribution of the drusen in some patients. In general they increase in number

TABLE 2. SUMMARY OF 200 PATIENTS WITH MACULAR DRUSEN

	Group I	Group II	Group III
Number of patients	49	91	60
Male to female ratio	17/32	39/52	31/29
Average age when first seen at Bascom Palmer Eye Institute	61 years (range 29-81)	67 years (range 49-82)	70 years (range 54-85)
Average length of follow-up by local physician and Bascom Palmer Eye Institute staff	4.9 years	3.8 years	3.3 years
Number of patients with two or more photographic studies	33	59	46
Number and average age of patients losing central vision due to disciform detachment or degeneration in one eye	9 (average age 75 years (range 71-79 years))	91 (average age 66 years (range 51-81 years))	46 (average age 66 years (range 56-81 years))
Number and average age of patients losing central vision due to disciform detachment or degeneration in the second eye	5 (average age 76 years (range 73-81 years))	31 (average age 71 years (range 59-85 years))	60 (average age 70 years (range 53-81 years))
Average interval of time between visual loss in first and second eye	<1 year (range 0-3 years)	3.7 years (range 0-10 years)	4.0 years (0-18 years)
Number and average age of patients who were legally blind from disciform detachment and degeneration at end of study	5 (average age 76 years (range 73-81 years))	23 (average age 72 years (range 59-85 years))	41 (average age 73 years (range 58-82 years))
Number of patients treated with photocoagulation	1	30 (32 eyes)	22 (23 eyes)

and size. Earlier in life the pigment content of the elevated pigment epithelium is relatively normal and the drusen may be visible only biomicroscopically using retro-illumination. Later, as the overlying pigment epithelium becomes thinned and less pigmented the drusen assume a yellowish and still later a whitish color. In later years they may fade and disappear leaving only an irregular mottling of the pigment epithelium in their wake. Visual acuity may not be affected despite significant changes in appearance of the drusen. Once detachment of the pigment epithelium and retina occurs the drusen in the area of detachment often disappear. The fading of drusen and pigment-mottling changes probably account for the fact that many early reports of disciform lesions and senile pigmentary degeneration of the macula contained little or no mention of drusen. Although some patients with macular drusen in this study experienced some visual loss in association with changes in the drusen, none lost useful central vision. The presence of varying degrees of mild nuclear sclerosis was responsible for some of the minor visual loss noted in some patients. The incidence of macular detachment and degeneration occurring in eyes with macular drusen during the course of this study was three times greater in eyes with grade II than in eyes with grade I drusen. None of the five patients with extensive peripheral and paramacular drusen and relative sparing of the central macular area lost vision. Pearce<sup>6</sup> found a good prognosis in patients with dominantly inherited drusen that were confined to the extramacular area.

The findings in this study demonstrated that significant loss of central vision in patients with macular drusen is unlikely to occur prior to the seventh decade, and that often there is a delay of at least three to four years before loss of central vision occurs in the second eye. Approximately one-third of the patients seen initially with visual loss in one eye developed macular detachment in the second eye during the course of the study. Seventy-nine of the 96 patients who developed disciform detachment and degeneration in the second eye were legally blind at an average age of 73 years when last seen. No patient was legally blind prior to age 58 years. While most of the patients who developed serous or hemorrhagic detachment of the macula experienced rapid and progressive loss of vision, some, particularly those with serous detachment of the pigment epithelium, maintained good acuity for a year or more. In the 10 per cent of the patients with geographic atrophy in one or both eyes visual loss typically progressed at a slower rate.

Friedman<sup>31</sup> studied 70 patients with senile disciform detachment over a three-year period. The average age of onset of detachment was

in the 60s (range 40 to 93 years). The detachment was bilateral in 14 patients and unilateral in 56 patients. Nine patients developed detachment in the second eye during the study.

While generally it is safe to reassure the patient that he will retain good peripheral vision, rarely he may lose, temporarily or permanently, all or part of his peripheral vision. This may be secondary to acute massive hemorrhagic detachment of the pigment epithelium and retina, extension of blood into the vitreous, rhegmatogenous retinal detachment precipitated by the vitreous blood, or chronic progressive exudative detachment of the pigment epithelium that spreads into the periphery of the eye.<sup>37</sup>

Although it was my initial impression that few patients with drusen and disciform detachment had a positive family history, more careful questioning of the patient and investigation of the few relatives available during this study has revealed a significant incidence of familial involvement. A positive family history of loss of central vision was obtained in almost 20 per cent of the patients and was confirmed by examination in 5 per cent of the patients. More intensive family investigation of this group of patients is planned and should reveal a much higher incidence of familial involvement, particularly in the patients' asymptomatic siblings and older children.

I was unable to find any unusual features concerning the number, size, shape or distribution of the drusen in the patients with a familial history. The same was true for the appearance of the disciform macular lesions. In their studies of families with dominantly inherited drusen Pearce<sup>6</sup> and Deutman et al.<sup>7</sup> stated that the finding of drusen nasal to the optic disk could be considered virtually pathognomonic for familial drusen and would serve as an important finding to distinguish these patients from those with senile drusen. If examined with the slit-lamp, most patients with macular degeneration and disciform detachment, in my experience, have drusen nasally as well as throughout the fundus. These extramacular drusen are often smaller and are more difficult to visualize because of less loss of pigment from the pigment epithelium overlying the drusen. Pearce<sup>6</sup> and Deutman et al.<sup>7</sup> described the onset of loss of central vision as usually occurring late in life and progressing rapidly in inherited drusen. Loss of vision was accompanied in their patients by coalescence of the drusen, thinning and atrophy of the retina, and atrophy and pigmentation of the choroid. While they did not describe elevated lesions indicative of disciform detachment and scarring, the fundus photographs in the report by Pearce<sup>6</sup> suggest that they were present.

Farkas and coworkers<sup>38</sup> have presented evidence that drusen formation is a pathologic autolysis of the retinal pigment epithelium initiated by lysosomal breakdown. On the basis of an electrophysiologic, histologic, electron microscopic study of two eyes, one with presumed familial drusen and the other with presumed senile drusen, Farkas et al.<sup>39</sup> postulated that patients with familial drusen have a widespread pigment epithelial abnormality probably present since birth, in contrast to patients with senile drusen in which the pigment epithelial abnormality is acquired in later life, and is localized in only certain areas. They believe that electrophysiologic studies can differentiate between familial and other drusen. Deutman,<sup>7</sup> however, found the EOG and ERG abnormal only in advanced cases of familial drusen. The ERG and EOG findings in the present study were normal in over one-half of 52 patients, including 14 patients with a positive family history. They further demonstrated that extensive subretinal or intraretinal bleeding secondary to the disciform detachment and unrecognized diabetic or other occlusive retinal vascular disease may be responsible for abnormal EOG and ERG findings in some patients. It is doubtful, therefore, if the EOG and ERG findings are of value in distinguishing dominantly inherited drusen from senile drusen, if indeed there are any differences.

Two questions served as the primary stimulus for the present study: (1) Is photocoagulation more effective than observation alone in causing resolution of macular detachment in these patients? (2) Is the frequency of macular detachment in patients with macular drusen sufficiently great to warrant the use of multiple small evenly spaced burns in the macula as a prophylactic measure to prevent macular detachment?<sup>27,29</sup> In answer to the first question, the results of photocoagulation once detachment has occurred have been partly, although not completely, discouraging. The author's indication for treatment, the techniques for treatment, the importance of preoperative photographic and angiographic evaluation, and preliminary results of treating patients with a variety of macular lesions including disciform detachment secondary to drusen have been recently reported.<sup>27,29</sup> Patients with two types of lesions appear to have favorable response to xenon photocoagulation. The patient with localized extrafoveal pigment epithelial detachment underlying a large area of serous retinal detachment that extends into the macular area is the most favorable candidate for treatment. Patients with a small extrafoveal area of neovascular ingrowth beneath the pigment epithelium are also favorable candidates, if the neovascular membrane does not extend angiographically to within one-fourth of a disk diameter of the fovea. While some large

pigment epithelial detachments extending beneath the fovea have flattened after ruby laser photocoagulation to the margin of the detachment, the results have been variable, and following successful collapse the visual acuity has not always improved. Furthermore 7 patients with serous detachment of the pigment epithelium one to two disk diameters in size have been followed without treatment and have maintained good visual acuity for periods of up to two years. The use of photocoagulation to treat lesions in which the subpigment epithelial neovascular membrane extends near or beneath the fovea is probably a fruitless exercise, and at times may destroy unnecessarily some of the paramacular retina. Jepson et al.<sup>24</sup> and Cleasby et al.<sup>28</sup> have reported some success with extensive photocoagulation of advanced hemorrhagic and exudative disciform lesions. In a series of 89 patients at least one of which had idiopathic central serous choroidopathy, only 7 patients had better than 20/200 vision one year after treatment.<sup>24</sup> Few patients appreciate the results of photocoagulation if they are unable to see better than 20/200 following treatment. In retrospect, in this study at the BPEI only 10 per cent of the 151 patients with disciform detachment and degeneration in 211 eyes were potentially good candidates for photocoagulation. This uncontrolled study does not provide the answer as to the value of photocoagulation in disciform macular detachment in patients with drusen. Patients with the most favorable lesions for treatment are also the most favorable candidates for spontaneous resolution and recovery of vision. Until a larger controlled study is done, we are left with only our clinical impressions that photocoagulation has helped to sustain central vision in some patients.

Admitting that the answer to the first question has not been settled, then perhaps it is unrealistic to consider the second question of prophylactic treatment. While this study has confirmed the general impression that patients with macular drusen are prime candidates for macular detachment and degeneration, it has also demonstrated that many of them do well for long periods of time, even after they have developed detachment in the first eye. Until we have had more experience with the treatment of symptomatic patients, I do not believe prophylactic treatment is advisable. It is hoped that the argon laser and other modalities of photocoagulation and improved techniques of angiography will improve our results. Meanwhile it is important to encourage patients with macular drusen to report promptly should they develop visual symptoms, since the best chance for therapy should come from early detection. Periodic stereo fundus photographs are helpful in following the course of the disease. Fluorescein angiography is prob-



ably necessary only when the patient develops new symptoms, or when a change in the appearance of the fundus occurs.

One may ask, does the development of geographic atrophy of the pigment epithelium, rather than serous or hemorrhagic detachment of the pigment epithelium and retina, signify some basic difference in the disease in patients with drusen? In most patients I do not believe that it does. While geographic atrophy may be bilateral, it also occurs frequently in association with disciform detachment in the opposite eye. In a few instances I have seen geographic atrophy result from collapse of a serous detachment of the pigment epithelium.<sup>35</sup> In most patients, however, it appears to develop after fading of the drusen. In one eye of a patient with drusen and geographic atrophy histopathologic examination revealed atrophy of the choriocapillaris similar to that found beneath many disciform lesions.<sup>35</sup> The relationship between these patients and those with dominantly inherited central areolar choroidal sclerosis is also not clear. I have reserved the latter term to refer to cases in which members of a family developed mottled loss of pigment epithelial pigment in the macula in young adulthood and, in the absence of drusen, begin to lose central vision secondary to geographic atrophy of the pigment epithelium usually in the third to fifth decade of life.<sup>35</sup>

While biomicroscopy, stereo fundus photography, and fluorescein angiography have provided us with considerable information concerning the gross anatomical changes and some of the physiologic changes in these patients, there are many unanswered questions concerning the pathogenesis of drusen and disciform detachment. Recent work has continued to incriminate the pigment epithelium,<sup>6,7,39,43,44</sup> Bruch's membrane,<sup>40,41</sup> and choroidal vessels,<sup>15,31,42</sup> but has not provided the final answer as to which is the primary tissue involved. While some reports favoring a retinal etiology for senile macular degeneration continue to appear,<sup>45,46</sup> they do not provide convincing evidence.

#### SUMMARY

The clinical findings and course of 200 patients with macular drusen, followed for an average period of almost four years, are presented. The presence of drusen alone did not account for significant loss of central vision. Loss of useful central vision in these patients was caused either by serous or hemorrhagic detachment of the pigment epithelium and retina, or less often by geographic atrophy of the pigment epithelium and retina. The average age of onset of loss of central vision in the first

eye was 66 years (range 51 to 81 years). The average age of onset of loss of central vision in the second eye was 70 years (range 59 to 85 years). Of 49 patients who initially had bilateral drusen 20 per cent developed loss of central vision in one eye, and 10 per cent in both eyes during an average follow-up period of almost four years. Approximately 35 per cent of 91 patients seen initially with loss of central vision in one eye developed loss of vision in the second eye during an average follow-up period of almost four years. Thirty-five per cent of the 200 patients developed 20/200 vision or less in both eyes at an average age of 73 years. None were legally blind (20/200 or less in both eyes) prior to 58 years of age. Approximately 20 per cent of the patients had a positive family history for macular degeneration. The EOG and ERG findings were normal in 50 per cent of the 52 patients, including 13 with a positive family history.

No clinical, fluorescein angiographic, or electrophysiologic criteria were found to differentiate patients with familial from those with so-called senile drusen. Probably all have the same autosomal dominant heredodegenerative disease which rarely causes significant loss of central vision prior to the sixth and seventh decades of life.

Fifty-three patients were treated with photocoagulation. The value of photocoagulation in these patients is still unknown.

#### ACKNOWLEDGMENTS

Grateful acknowledgment is made to Dr Steven T. Charles for his assistance in obtaining and interpreting the electro-oculography and retinography, and also to Dr John G. Clarkson and the many physicians who provided follow-up information.

#### REFERENCES

1. Hutchinson, J., and W. Tay, Symmetrical central choroido retinal disease occurring in senile persons, *Roy. London Ophthal. Hosp. Rep.*, 8:231, 1875.
2. Doyne, R.W., Peculiar conditions of choroiditis occurring in several members of the same family, *Trans. Ophthal. Soc. U.K.*, 19:71, 1899.
3. Doyne, R.W., A note on family choroiditis, *Trans. Ophthal. Soc. U.K.*, 30:93, 1910.
4. Holthouse, E.H., and R.D. Batten, A case of superficial choroidoretinitis of peculiar form and doubtful causation, *Trans. Ophthal. Soc. U.K.*, 17:62, 1897.
5. Forni, S., and J. Babel, Etude clinique et histologique de la maladie levantine: Affection appartenant au groupe des dégénérescences hyalines du pôle postérieur, *Ophthalmological (Basel)*, 143:313, 1962.
6. Pearce, W.G., Doyne's honeycomb retinal degeneration, clinical and genetic features, *Brit. J. Ophthal.* 52:73, 1968.

7. Deutman, A.F., and L.M.A.A. Jansen, Dominantly inherited drusen of Bruch's membrane, *Brit. J. Ophthal.*, 54:373, 1970.
8. Donders, F.C., *Beitrag zur pathologischen Anatomie des Auges*, Graefe *Arch. Ophthal.*, 1:106, 1855.
9. Oeller, J., *Atlas de Ophthalmoskopie*, Wiesbaden, J.F. Bergmann, 1893.
10. Oeller, J., *Atlas Seltener Ophthalmoskopischer Befunde*, Wiesbaden, J.F. Bergmann, 1905.
11. Junius, P., and H. Kuhnt, *Die scheibenfornige Etargung der Netzhautmitte (Degeneratio maculae luteae disciformis)*, Berlin, Karger, 1926.
12. Gifford, S.R., and B. Cushman, Certain retinopathies due to changes in lamina vitrea, *Arch. Ophthal.*, 23:60, 1940.
13. Elwyn, H., *Diseases of the Retina*, New York, Blakiston, 1953.
14. Maumenee, A.E., Serous and hemorrhagic disciform detachment of the macula, *Trans. Pacif. Coast Otophthal. Soc.*, 40:139, 1959.
15. Gass, J.D.M., Pathogenesis of disciform detachment of the neuroepithelium: iii Senile disciform macular degeneration; iv Fluorescein angiographic study of senile disciform macular degeneration, *Amer. J. Ophthal.*, 63:617 and 645, 1967.
16. Haab, O., *Erkankungen der Macula Lutea*, *Centrablat. f. pr. Augenheilk.*, 9:384, 1885.
17. Duke-Elder, S., *System of Ophthalmology*, St Louis, Mosby, 1966, ix, p. 613.
18. Behr, C., *Die Heredo-dgeneration der Makula*, *Klin. Mbl. Angenheilk.*, 65:465, 1920.
19. Klien, B.A., Heredodegeneration of the macula lutea, *Amer. J. Ophthal.*, 33:371, 1950.
20. Falls, H.F., Hereditary macular degeneration, *Amer. J. Hum. Genet.*, 1:96, 1949.
21. Wise, G.N., C.J. Campbell, P.F. Wendler, et al., Photocoagulation of vascular lesions of the macula, *Amer. J. Ophthal.*, 66:452, 1968.
22. Zweng, H.C., H.L. Little, and R.R. Peabody, Laser photocoagulation of macular lesions, *Trans. Amer. Acad. Ophthal. Otolaryng.*, 72:377, 1968.
23. Harris, G.S., Photocoagulation of macular lesions following fluorescein angiography, *Canad. J. Ophthal.*, 4:16, 1969.
24. Jepson, C.N., and P.C. Wetzig, Photocoagulation in disciform macular degeneration, *Amer. J. Ophthal.*, 67:920, 1969.
25. Little, H.L., H.C. Zweng, and R.R. Peabody, Argon laser slit-lamp retinal photocoagulation, *Trans. Amer. Acad. Ophthal. Otolaryng.*, 74:85, 1970.
26. Wessing, A., Photocoagulation in the treatment of macular lesions, in *Proceedings XXI International Congress of Ophthalmology (Mexico)*, Amsterdam, Excerpta Medica Foundation, 1970.
27. Gass, J.D.M., Ruby laser and xenon photocoagulation of macular lesions, in *Proceedings XXI International Congress of Ophthalmology (Mexico)*, Amsterdam, Excerpta Medica Foundation, 1970.
28. Cleasby, G.W., W.E. Fung, and J.V. Fiore, Jr., Photocoagulation of exudative senile maculopathy, *Arch. Ophthal.*, 85:18, 1971.
29. Gass, J.D.M., Photocoagulation of macular lesions, *Trans. Amer. Acad. Ophthal. Otolaryng.*, 75:580, 1971.
30. Patz, A., A.E. Maumenee, and S.J. Ryan, Argon laser photocoagulation, *Trans. Amer. Acad. Ophthal. Otolaryng.*, 75:569, 1971.
31. Friedman, E., E.M. Buskirk, E. Fineberg, K. Messner, and H. Schinazi, Pathogenesis of senile disciform degeneration of the retina, in *Proceedings XXI International Congress of Ophthalmology (Mexico)*, Amsterdam, Excerpta Medica Foundation, 1970.
32. Gass, J.D., R.J. Sever, D. Sparks, and J. Goren, A combined technique of

- fluorescein funduscopy and angiography of the eye, *Arch. Ophthalm.*, 78:455, 1967.
33. Arden, G.B., A. Barrada, and J.H. Kelsey, New clinical test of retinal function based on the standing potential of the eye, *Brit. J. Ophthalm.*, 46:499, 1962.
  34. Henkes, H.E., Electro-oculography as a diagnostic aid in phenothiazin retinopathy, *Trans. Ophthalm. Soc. U.K.*, 87:285, 1967.
  35. Gass, J.D.M., *Stereoscopic Atlas of Macular Diseases*, St Louis, Mosby, 1970.
  36. Gass, J.D.M., Acute posterior multifocal placoid pigment epitheliopathy, *Arch. Ophthalm.*, 80:177, 1968.
  37. Blair, C.J., and T.M. Aaberg, Massive subretinal exudation associated with senile macular degeneration, *Amer. J. Ophthalm.*, 71:639, 1971.
  38. Farkas, T.G., and V. Sylvester, The ultrastructure of drusen, *Amer. J. Ophthalm.*, 71:1196, 1971.
  39. Farkas, T.G., A.E. Krill, V. Sylvester, and D. Archer, Familial and secondary drusen: Histological and functional correlations, *Trans. Amer. Acad. Ophthalm. Otolaryng.*, 75:333, 1971.
  40. Hogan, M.J., Pathogenesis: Electron microscopy of Bruch's membrane, *Trans. Amer. Acad. Ophthalm. Otolaryng.*, 69:683, 1965.
  41. Hogan, M.J., Bruch's membrane and disease of the macula: Role of elastic tissue and collagen, *Trans. Ophthalm. Soc. U.K.*, 87:113, 1967.
  42. Friedman, E., T.R. Smith, and T. Kuwabara, Senile choroidal vascular patterns and drusen, *Arch. Ophthalm.*, 69:220, 1963.
  43. Krill, A.E., and B.A. Klein, Flecked retina syndrome, *Arch. Ophthalm.*, 74:496, 1965.
  44. Farkas, T.G., Drusen of the retinal pigment epithelium, *Survey Ophthalm.*, 16:75, 1971.
  45. Kornswieg, A.L., I. Eliasoph, and M. Feldstein, The retinal vasculature in macular degeneration, *Arch. Ophthalm.*, 75:326, 1966.
  46. Steinbach, P.D., Ueber die Beteiligung den netzhautcapillares bei der senilen maculadegeneration, *Klin. Mbl. Aegenheilk.*, 156:710, 1970.