

INDENTATION GONIOSCOPY AND EFFICACY OF IRIDECTOMY IN ANGLE-CLOSURE GLAUCOMA*

BY *Max Forbes*, MD

INDENTATION GONIOSCOPY HAS BEEN PROPOSED AS A METHOD FOR DISTINGUISHING between appositional closure and synechial closure in angle-closure glaucoma. It is a simple office procedure and, as such, a potentially valuable tool in diagnosis and management. Undoubtedly, the most compelling application of indentation gonioscopy is in the choice of operation for angle-closure glaucoma. Iridectomy, the procedure of choice by virtue of safety, functions by elimination of relative pupillary block and consequent opening of areas of appositional closure. If synechial closure is too extensive to permit iridectomy to succeed, a significantly more risky filtering procedure may be required. Clearly, if indentation gonioscopy is reasonably accurate, it should be quite useful in making surgical decisions.

This communication is a report of a ten year clinical study of primary angle-closure glaucoma based upon the aforementioned considerations. The specific purpose of the investigation was twofold. First, to determine the accuracy of indentation gonioscopy in estimating the extent of synechial closure. Second, to determine the influence of synechial closure on the efficacy of iridectomy.

HISTORICAL REVIEW

Closure of the angle of the anterior chamber by peripheral anterior synechias was first discovered by Knies^{1,2} in 1876 and Weber³ in 1877. These adhesions were found in microscopic sections of eyes enucleated after long-standing glaucoma. It was concluded that closure of the angle causes elevated intraocular pressure by obstructing aqueous humor outflow; the so-called retention theory of glaucoma. Subsequently, it became evident that synechial closure was present in the overwhelming

*From the Edward S. Harkness Eye Institute, Columbia-Presbyterian Medical Center, 635 West 165th Street, New York, New York 10032.

majority of enucleated glaucomatous eyes and these observations led to the widely held concept that virtually all cases of primary and secondary glaucoma were associated with synechial closure. This viewpoint met with acceptance in the era before gonioscopy since the status of the angle of the anterior chamber in the living eye could not be determined and inferences were necessarily based upon examination of pathological material. In 1891 Priestley Smith⁴ stated: "An eye blinded by chronic glaucoma may show during life no fault whatever in the position of the iris, and yet may present on bisection a well-marked closure of the filtration-angle. In the living eye the base of the iris is completely hidden."

Although Trantas⁵ was the first to describe observation of the living chamber angle, the foundation of clinical gonioscopy was established by Salzmann^{6,7} in 1914. Salzmann used a contact lens to overcome the optical problem of total internal reflection of light emanating from the chamber angle. In addition to providing a detailed description of the normal angle, Salzmann also reported his observations in a variety of ocular diseases. In particular, he found an open angle in some eyes with active glaucoma. The presence of an open angle in a significant percentage of cases of glaucoma was confirmed by Koepe,⁸ Troncoso,⁹ Werner,¹⁰ and other early gonioscopists. Prior concepts based solely upon peripheral anterior synechias in enucleated specimens had to be modified in the light of these revelations.

The prevailing classification, founded largely upon symptomatology, subdivided primary glaucoma into acute congestive, chronic congestive and chronic noncongestive (simple) glaucoma. Some authors preferred the designations compensated and uncompensated, or inflammatory and non-inflammatory, which were essentially synonymous with congestive and noncongestive. Troncoso¹¹ found a completely open angle in 26% of eyes with congestive glaucoma (acute and chronic) and at least partial synechial closure in 44% of eyes with chronic noncongestive glaucoma. His adherence to this older classification and his finding of some eyes with normal intraocular pressures despite almost total synechial closure led Troncoso^{11,12} to believe that closure of the angle was a secondary aggravating factor rather than a cause of glaucoma.

A new classification of glaucoma based on depth of the anterior chamber was proposed by Raeder¹³ in 1923 and supported by Rosen-gren¹⁴ in 1930. In 1938 Barkan¹⁵ accomplished a major breakthrough by the development of a classification in accordance with the gonioscopic configuration of the chamber angle. Barkan subdivided primary glaucoma into trabecular (chronic simple) glaucoma, characterized by an open-

angle, and narrow-angle or iris-block (angle-closure) glaucoma caused by mechanical closure of a previously narrow but open angle. Confirmatory evidence for the validity and effectiveness of Barkan's classification was forthcoming in the gonioscopic studies of Sugar,¹⁶ Bangerter and Goldmann¹⁷ and Kronfeld.¹⁸ Thus evolved the modern concept of angle-closure (narrow-angle or iris-block) glaucoma occurring in predisposed eyes with shallow anterior chambers and narrow angles. The disease is initiated by appositional closure which ultimately progresses to synechial closure. Symptomatically, angle-closure glaucoma may present as acute, subacute or chronic, but all cases are the result of mechanical obstruction of the angle by the root of the iris.

In 1857 Albrecht von Graefe¹⁹ reported his astounding discovery that some cases of acute (congestive) glaucoma had been cured by sector iridectomy. The operation failed in chronic glaucoma as well as in the later stages of acute (congestive) glaucoma. These results were confirmed by de Wecker,²⁰ Priestley Smith²¹ and other ophthalmic surgeons. Von Graefe suggested that iridectomy might act by causing a reduction in the rate of aqueous humor formation. De Wecker believed that successful iridectomies produced a filtering cicatrix. Weber³ ascribed the main effect to mechanical opening of a closed angle along the broad base of the iridectomy. Despite these and other theories the mechanism of action of iridectomy remained elusive for many years and the indications for this operation were not adequately delineated.

An important advance was achieved by Curran²² in 1920. His clinical observations indicated that in certain cases of glaucoma with a shallow anterior chamber there was an impediment of aqueous flow through the pupil because the iris tended to hug the anterior surface of the lens. He found that a simple peripheral iridectomy or iridotomy relieved this relative pupillary block, deepened the anterior chamber and cured the glaucoma. He concluded that iridectomy facilitated drainage from the posterior chamber into the anterior chamber permitting aqueous humor to gain free access to the normal outflow channels. In 1922 Banziger²³ described similar observations in connection with a successful peripheral iridectomy for acute glaucoma. In 1938-41 Barkan^{15,24,25} reported that his gonioscopic classification of primary glaucoma could be used for the choice of operation. In particular, he found iridectomy (multiple peripheral iridectomies) to be effective only in narrow-angle (angle-closure) glaucoma. In these cases he noted widening of the entrance to the angle which he attributed to relief of the relative pupillary block postulated by Curran. In 1952 Chandler²⁶ reviewed all aspects of angle-closure glaucoma confirming Barkan's classification and concepts. He presented a

detailed analysis of the relative pupillary block phenomenon and the effect of a single peripheral iridectomy in eliminating obstruction to flow from posterior to anterior chamber. Additional confirmation of the effectiveness of peripheral iridectomy was offered by Haas and Scheie²⁷ in the same year. In 1954 Barkan^{28,29} re-emphasized the importance of pupillary block in angle-closure glaucoma and advocated treatment by a single peripheral iridectomy. This conception of the action of iridectomy in overcoming a relative pupillary block is now appropriately designated the Curran-Barkan-Chandler mechanism.

In his original publication on iridectomy in glaucoma von Graefe¹⁹ stated: "Once the glaucomatous process has set in, the results are the more favorable and permanent the earlier the operation is performed." Curran²² found that iridectomy without a filtering cicatrix was useless in cases with total synechial closure. Nevertheless, he favored peripheral iridectomy or iridotomy over filtering operations in suitable cases because "no one is justified in taking a greater risk when a lesser one may be successful." Barkan²⁵ recommended iridectomy in the early stage of acute or chronic angle-closure glaucoma whereas he preferred cyclodialysis in the late stage where "the angle has been obliterated in large part or totally by permanent adhesions."

During the past thirty years a number of investigators have attempted to determine the maximum extent of synechial closure compatible with a successful iridectomy. A closely associated clinical problem is to estimate the extent of synechial closure before surgery as an aid in the choice of operation for angle-closure glaucoma.

In 1944 Kronfeld and McGarry³⁰ defined the problem of distinguishing between appositional closure and synechial closure preoperatively by stating that: "Even after complete clearing of the cornea this distinction between contact and synechia can not be made with certainty." They found that synechial closure could be identified 10 to 14 days after iridectomy: "At this time attachment of any portion of the iris to any portion of the anterior angle wall practically always means an irreparable synechia." Clearly, after iridectomy has eliminated relative pupillary block and thereby widened the chamber angle, appositional closure is largely reversed and only synechial closure remains.

In 1957 Shaffer³¹ reported that it was feasible to elicit this information immediately after iridectomy by performing gonioscopy with a Koeppe lens under sterile conditions in the operating room. At that point, if extensive anterior synechias were seen, the operation was resumed and synechialysis or cyclodialysis was performed. Conversion of the iridectomy to an iridenclesis was also possible. If most of the angle was found to

have opened by virtue of the iridectomy, the operation was terminated. Chandler^{32,33} also advocated operating room gonioscopy but proposed a different maneuver for deepening the anterior chamber. He evacuated the anterior and posterior chambers through a beveled Wheeler knife incision in the lower cornea and then injected an excess of saline into the anterior chamber. Gonioscopy after deepening of the anterior chamber permitted an accurate determination of the extent of peripheral anterior synechia formation and a proper choice of operation. Chandler and Simmons³⁴ offered a detailed description of this procedure and compared the results of gonioscopy with a Koeppel lens before and after chamber deepening in 53 eyes. In many of these eyes a larger extent of angle was found to be open after chamber deepening. A similar procedure for gonioscopy in connection with surgery for angle-closure glaucoma was reported by Ogino.³⁵ Operating room gonioscopy after deepening of the anterior chamber clearly offers an accurate method for detection of peripheral anterior synechias. The observations of Chandler and Simmons suggest an added therapeutic benefit of breaking recently formed adhesions although this is somewhat difficult to prove. It has the disadvantage of increasing operative manipulation and it can only be performed at the time of surgery.

The angle of the anterior chamber may be widened sufficiently by medical therapy to permit areas of appositional closure to open. Under these conditions gonioscopy might permit identification of peripheral anterior synechias. The miosis of pilocarpine certainly opens part or all of the circumference in some eyes.^{18,36} Lowe³⁷ has found that acetazolamide, in large doses, frequently deepens the anterior chamber in acute angle-closure glaucoma. He believes this action to be due to a temporary suspension of relative pupillary block brought about by hyposecretion and reduction of pressure in the posterior chamber. Weiss, Shaffer and Wise³⁸ reported deepening of the anterior chamber in angle-closure glaucoma following intravenous administration of mannitol. Available evidence strongly suggests that this effect of hyperosmotic agents is a consequence of dehydration and shrinkage of the vitreous.³⁹ Gonioscopy should certainly be performed after the administration of any agent which may cause some degree of opening of a previously closed angle since additional useful information may be obtained.

In 1966 the author⁴⁰ described a technique of gonioscopy with corneal indentation for distinguishing between appositional closure and synechial closure. A Zeiss four-mirror indirect gonioscopic lens with relatively flat corneal surface, which rests directly on the cornea, is used at a slit-lamp. The lens is manipulated by a special holding fork (after Unger). When the

lens is pressed directly against the cornea it produces an indentation and a displacement of aqueous humor to the periphery of the anterior chamber with consequent widening of the chamber angle. This change in angle configuration occurs under visualization. Areas of appositional closure are readily opened whereas peripheral anterior synechias are exposed. This indentation technique is a simple office procedure. Its usefulness in angle-closure glaucoma has been confirmed by Gorin and Posner,⁴¹ Etienne,⁴² Krasnov,⁴³ Kolker and Hetherington,⁴⁴ and Hoskins.⁴⁵ Indentation gonioscopy can be accomplished with other lenses⁴⁶ and Gorin⁴⁷ prefers the Goldmann lens for this purpose. Nakamura⁴⁸ developed a modified Koeppe lens to facilitate direct indentation gonioscopy and used this lens to detect synechias in a series of patients with angle-closure glaucoma.⁴⁹

Concerning the influence of synechial closure on the outcome of iridectomy in angle-closure glaucoma, Troncoso's¹¹ gonioscopic observations led him to conclude that reopening of a closed angle, although beneficial, is not essential for a successful result. Sugar⁵⁰ studied 14 eyes in which the tension had been normalized by iridectomy and found that eight eyes had partial opening of the angle whereas six eyes had completely obliterated angles. Of the latter group, five eyes had filtering cicatrices and the sixth had undergone lens extraction after iridectomy. On the basis of this evidence Sugar concluded that iridectomy is unsuccessful after dense adhesions have formed except in the presence of a filtering bleb. In 1944 Kronfeld and McGarry³⁰ evaluated 18 eyes treated by iridectomy for acute congestive (angle-closure) glaucoma. Only seven eyes were successfully controlled and postoperative gonioscopic examinations demonstrated that synechial closure was incomplete in the successful group. The maximum extent of synechial closure compatible with normal intraocular pressure was 75 to 80% in this very small series. In 1952 Chandler²⁶ and Haas and Scheie²⁷ indicated that iridectomy, while extremely successful in early cases, was not appropriate for advanced angle-closure glaucoma with extensive peripheral anterior synechia.

The success rate of iridectomy can be improved by long-term postoperative medical management of the residual glaucoma. Barkan^{24,29} pointed out that "miotics become markedly more effective following adequate peripheral iridectomy." Chandler and Trotter⁵¹ advocated peripheral iridectomy plus continued use of miotics in moderately advanced cases of angle-closure glaucoma. Epinephrine⁵² and strong miotics⁵³ such as isofluorophate, echothiophate iodide, and demecarium bromide are known to aggravate or even precipitate angle-closure in susceptible eyes. These agents, which are contraindicated in unoperated

angle-closure glaucoma, may be safely employed after elimination of pupillary block by iridectomy.^{54,55} Acetazolamide can also be used after iridectomy, if needed.⁵⁶ In essence, residual post-iridectomy angle-closure glaucoma may be treated with the full range of medical therapy that is available for chronic simple glaucoma.

In 1962 Chandler⁵⁷ analyzed the relationship between extent of synechial closure and outcome of iridectomy. He found that iridectomy was successful in the range 0-33% peripheral anterior synechias, doubtful in the range 33-50% peripheral anterior synechias, and unsuccessful beyond 50% peripheral anterior synechias. The same guidelines were re-stated by Chandler,³³ Chandler and Grant⁵⁸ and Chandler and Simmons.³⁴ In 1963 Kronfeld⁵⁹ indicated that iridectomy would be ineffective after permanent irreparable closure of more than half of the chamber angle. In 1964 it was reported that iridectomy could be successful in some cases of advanced angle-closure glaucoma, acute or chronic, with 40-80% synechial closure if supplemented by intensive long-term postoperative medical therapy.⁵⁴ Nose⁶⁰ recently studied 120 eyes of 80 patients with chronic angle-closure glaucoma and was able to achieve good control whenever there was less than 80% peripheral anterior synechias. In this series iridectomy alone was sufficient for 0-50% peripheral anterior synechias but miotic therapy was required for 50-80% peripheral anterior synechias.

In recent years virtually all investigators have agreed on the following points concerning primary angle-closure glaucoma: (1) The efficacy of iridectomy diminishes with increasing synechial closure. (2) Iridectomy is preferable to all other operations if synechial closure is not too extensive to preclude success. There has been notable divergence of opinion, however, regarding the outcome of iridectomy in eyes with more than 33-50% peripheral anterior synechias.

MATERIALS AND METHODS

A prospective study of patients undergoing iridectomy for primary angle-closure glaucoma was begun in 1963. This communication represents a ten year accumulation of the results achieved in 227 eyes of 151 patients.

Cases of acute, subacute, and chronic angle-closure glaucoma were included in the study. Pre-glaucomatous fellow eyes as well as asymptomatic eyes with positive dilatation provocative tests were also included and were designated as incipient angle-closure glaucoma. The 227 eyes were subdivided as follows: 72 acute, 29 subacute, 86 chronic,

and 40 incipient. This subdivision according to presenting symptomatology does not necessarily yield a breakdown into mutually exclusive categories. It should be noted that some acute attacks develop in eyes with pre-existing chronic angle-closure glaucoma and, conversely, some chronic cases develop after an initiating acute attack is broken.⁶¹

In each case the diagnosis was based on gonioscopic demonstration of a narrow closed angle concurrent with elevated intraocular pressure. For diagnostic purposes it is essential not to use indentation gonioscopy until after routine gonioscopy without indentation (static gonioscopy⁴⁷) has established the true configuration of the angle. Indentation gonioscopy alone, especially when used inadvertently, can be misleading since narrow angles are made to appear wide and appositionally occluded angles are made to appear open.^{40,46,63} If preoperative gonioscopy without indentation revealed a significant degree of the angle to be open at a time when the pressure was elevated, that eye was considered to have an underlying open-angle glaucoma and was excluded from the study.

The decision to perform an iridectomy required a firm diagnosis of primary angle-closure glaucoma and represented a clinical judgment based on all of the many relevant factors under consideration. In each case paramount concern was given to the best interest of the patient. During the period of the study iridectomy was not performed on all eyes with angle-closure glaucoma. A few were treated medically and had no surgery whatever. In others with cataracts of appropriate density, the primary operative procedure was cataract extraction. In some severe uncontrollable cases a filtering operation was performed rather than an iridectomy. Hence, this study represents a survey of eyes selected for iridectomy on the basis of clinical judgment rather than a randomized controlled series.

Before surgery, intensive medical therapy was employed in an effort to lower the intraocular pressure. The agents most frequently used were pilocarpine, acetazolamide, oral glycerol, and intravenous mannitol in various combinations as needed. In cases of acute angle-closure glaucoma with associated congestion and inflammation an effort was made to break the attack medically and allow the involved eye to "quiet down" for one or two days in the hospital prior to operation. Subacute and chronic cases did not require a cooling off period. They were simply given sufficient medical therapy to normalize the pressure preoperatively and especially at the time of surgery. Eyes with incipient angle-closure glaucoma were generally maintained on pilocarpine until iridectomy was performed.

With regard to the choice of operation, iridectomy was performed whenever an acute attack could be broken and whenever the pressure in

subacute and chronic cases responded favorably to pilocarpine and acetazolamide. If an acute attack rebounded promptly after decay of the temporary hyperosmotic effect (that is the attack failed to break), a filtering procedure was usually chosen although iridectomy was attempted in a few such instances. Subacute and chronic eyes which responded poorly to pilocarpine and acetazolamide were frequently subjected to a filtering procedure, especially in the presence of established optic nerve damage. Iridectomy was chosen without regard to other factors whenever preoperative indentation gonioscopy demonstrated less than 65% peripheral anterior synechias. In essence, all favorable cases were treated by iridectomy, most of the doubtful cases were treated by iridectomy and most, but not all, unfavorable cases had filtering operations.

A standard surgical technique involving an ab externo incision and a McLean suture was used for all iridectomies whether peripheral or sector.⁶² Wound closure was tight and there was rapid restoration of the anterior chamber on the operating table in all eyes in this series. If iridectomy is not to cause an increase in synechial closure, rapid reformation of the anterior chamber is essential. Postoperative wound leak sufficient to cause a flat chamber was not encountered but a few filtering blebs were unintentionally produced. Although these blebs helped to control the glaucoma, they were excluded from the study because the beneficial effect was not entirely due to the iridectomy.

Peripheral iridectomy was the procedure of choice and sector iridectomy was reserved for special situations where a large pupil was desired for optical reasons. In this series of 227 iridectomies, 199 were peripheral and 28 were sector.

After surgery there was periodic evaluation for evidence of recurrent glaucoma. Medical therapy was prescribed when needed in an arbitrary sequence of graded increments until the intraocular pressure was brought under control. Initially, either pilocarpine or epinephrine was started with subsequent routine adjustments in concentration and frequency of instillation. The second increment was to combine pilocarpine and epinephrine. If still more intensive treatment was needed the third increment involved either substitution of echothiophate iodide for pilocarpine or addition of acetazolamide to the combination of pilocarpine and epinephrine. In the fourth and final increment both echothiophate iodide and acetazolamide were used with continuation of epinephrine.

If adequate control of intraocular pressure could not be achieved by means of medical therapy then further surgery was seriously considered; usually some type of filtering operation. Cataracts were encountered frequently in the years after iridectomy and were extracted in accordance

with the usual visual indications. Thus far, 33 cataract extractions have been performed.

This report deals only with eyes which were followed for a minimum of three years after iridectomy except in the case of failures which were included without regard to duration. Only four failures were followed for less than three years. The follow-up periods are listed in Table 1.

TABLE 1 DURATION OF FOLLOW OF 227 EYES AFTER IRIDECTOMY										
YEARS	1	2	3	4	5	6	7	8	9	10
NQ.OF EYES	2	2	28	36	48	35	25	21	21	9

ACCURACY OF INDENTATION GONIOSCOPY

Preoperative indentation gonioscopy was performed at a slit-lamp using a Zeiss four-mirror gonioscopic lens. Every effort was made to perform this examination under optimal conditions of corneal clarity and lowered intraocular pressure. All areas of appositional closure were opened by indentation and an estimate of the extent of synechial closure was made according to the percentage of the total circumference that was observed to be involved. This quantity was designated the peripheral anterior synechia ratio or simply % peripheral anterior synechias. Each of the four quadrants of the angle, superior, nasal, inferior and temporal, represents 25% of the total circumference and can therefore contribute a portion of the total peripheral anterior synechia ratio between 0% and 25%. An estimate was made for each quadrant using 5% as the incremental unit. Addition of the estimates for the four quadrants provided the estimated peripheral anterior synechia ratio for the entire angle. Adhesions that did not appear high enough to occlude the filtration portion of the trabecular meshwork overlying the canal of Schlemm were excluded from the estimate.^{58,64} Thus, synechias in the angle recess up to the scleral spur were discounted. Only those synechias judged to extend up to the upper border of the trabecular pigment band (approximately one-half to two-thirds of the distance from the scleral spur to Schwalbe's line) or higher were counted.

Using these criteria, repeated preoperative measurements of the peripheral anterior synechia ratio on the same eye were found to be in fairly close agreement although not necessarily identical. More than half of these repeated measurements differed by no more than $\pm 5\%$ and

virtually all were within $\pm 10\%$. The technique involves gonioscopic manipulation plus visual estimates of the height and width of adhesions. It is not sufficiently precise to produce identical repetitive results.

After iridectomy there was significant widening of the majority of angles with opening of most areas of appositional closure. It was therefore easier to measure the peripheral anterior synechia ratio postoperatively and these gonioscopic determinations were judged to be reliable and accurate. They served as a standard for evaluation of the accuracy of the preoperative estimates based on indentation gonioscopy.

EFFICACY OF IRIDECTOMY

After iridectomy, some eyes required no treatment whereas others had residual glaucoma and did require treatment. In these latter eyes an effort was made to achieve an adequate status of control. For this study, adequate control was arbitrarily defined as an intraocular pressure consistently below 22 mm Hg plus stabilization of the optic disc and visual field. Most of the eyes with nerve damage were maintained at pressures below 20 mm Hg but this could not be accomplished in all instances. Intraocular pressures were measured by Goldmann applanation tonometry.

An eye which could not be adequately controlled on medical therapy was classified as a failure. Most of the failures required additional glaucoma surgery. All failures were included in this study even when the follow-up period was less than three years.

An eye which was adequately controlled after iridectomy was classified as a success. Only successes followed for a minimum of three years after iridectomy were included in this study. The successes were subdivided into five groups in accordance with the medical regimen required to achieve adequate control.

The groups are defined as follows:

- Group O — No medical therapy.
- Group A — Pilocarpine or epinephrine.
- Group B — Pilocarpine and epinephrine.
- Group C — Echothiophate iodide or acetazolamide.
- Group D — Echothiophate iodide and acetazolamide.

Within these groups certain substitutions were permitted. In groups A and B, carbachol was accepted as a substitute for pilocarpine. In groups C and D, demecarium bromide and isofluorophate were accepted as substitutes for echothiophate iodide, and other carbonic anhydrase inhibitors were accepted as substitutes for acetazolamide. Within each group there was considerable variation in concentrations, dosages, and frequencies of administration of the medications listed.

Each eye was assigned to that group appropriate for the medical therapy required at the most recent examination although a change in group after the first year was quite unusual. As mentioned previously, successes with unintentional filtering blebs were excluded from the study.

RESULTS

ACCURACY OF INDENTATION GONIOSCOPY IN DETERMINING EXTENT OF SYNECHIAL CLOSURE.

Before surgery most of the eyes in this series had partially or totally occluded angles. Indentation gonioscopy was required to distinguish between appositional and synechial closure and thereby determine the peripheral anterior synechia ratio. Postoperative determinations of the peripheral anterior synechia ratio are regarded as the true values for the purposes of this investigation. A comparison of the preoperative and postoperative determinations was made in order to assess the accuracy of indentation gonioscopy.

The results are shown in Figure 2, a scattergram of all 227 eyes in the series with ordinate peripheral anterior synechia ratio (% peripheral anterior synechias determined preoperatively by indentation gonioscopy) and abscissa peripheral anterior synechia ratio (% peripheral anterior synechias determined postoperatively). Whenever two or more eyes had identical pairs of values the point on the scattergram was encircled. The

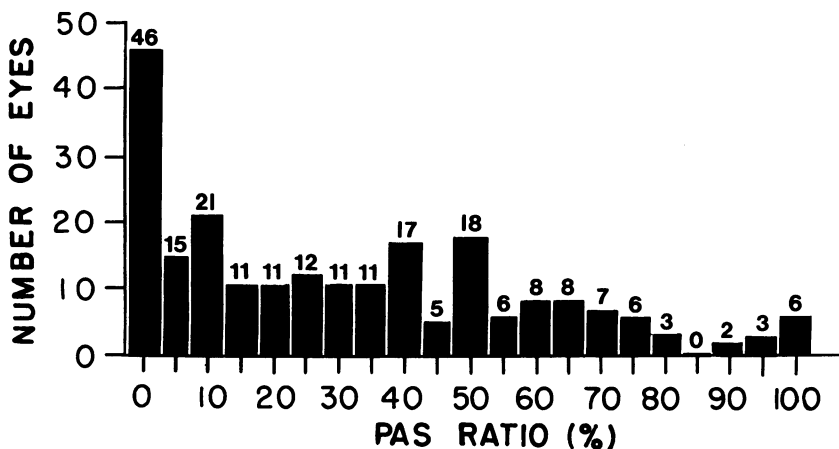


FIGURE 1

Distribution of peripheral anterior synechia ratio in this series. Ratio determined by gonioscopy after iridectomy.

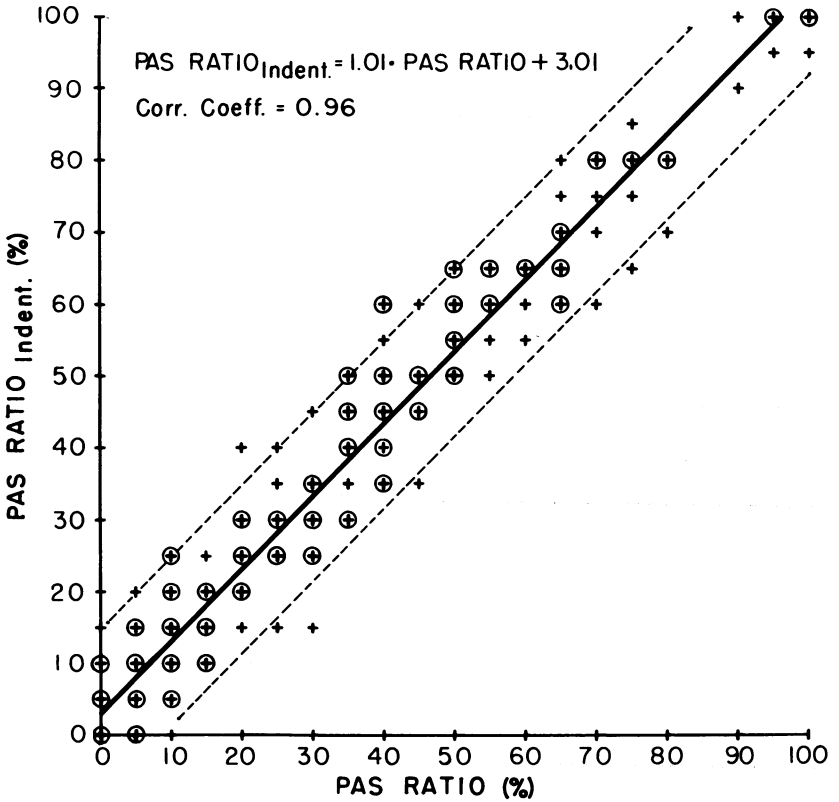


FIGURE 2

Relation between peripheral anterior synechia ratio determined preoperatively by indentation gonioscopy (ordinate) and ratio determined postoperatively (abscissa). Each encircled point represents two or more eyes. Interrupted lines represent the 95% confidence limits about the regression line.

solid line is the regression line of ordinate on abscissa and the interrupted lines indicate the 95% confidence limits. Inspection of the scattergram reveals a strong correlation between the two determinations. The coefficient of correlation was 0.96. It is evident that indentation gonioscopy was quite accurate in distinguishing between appositional closure and synechial closure before surgery.

The same data are displayed in Figure 3 as a frequency distribution of the differences between the peripheral anterior synechia ratio determined preoperatively by indentation gonioscopy and the peripheral anterior synechia ratio determined postoperatively, (% PAS_{INDENT.} minus % PAS). Inspection of the histogram reveals a high frequency of agreement

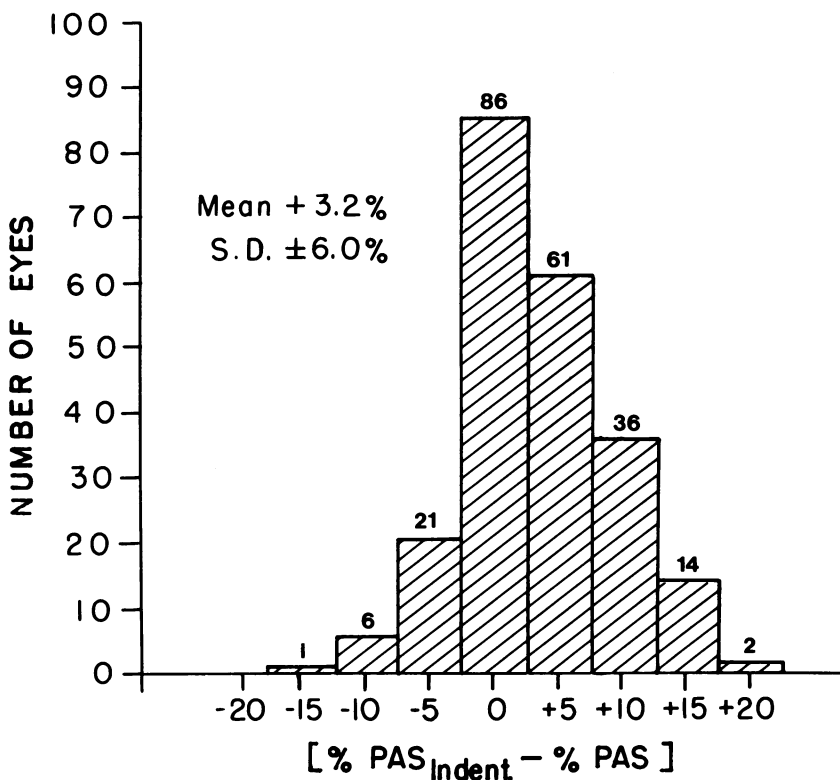


FIGURE 3

Distribution of differences (% peripheral anterior synechias determined preoperatively by indentation gonioscopy *minus* % peripheral anterior synechias determined postoperatively).

or near agreement. Virtually all of the differences were in the range between a preoperative underestimate of -10% peripheral anterior synechias and a preoperative overestimate of +15% peripheral anterior synechias.

The preoperative determination by indentation gonioscopy resulted in an overestimate in 113 eyes, an underestimate in 28 eyes and an exact agreement with the postoperative determination in 86 eyes. The mean of the differences (% PAS_{INDENT.} *minus* % PAS) was +3.2% peripheral anterior synechias with standard deviation $\pm 6.0\%$ peripheral anterior synechias. There was a definite trend toward overestimation of synechial closure by preoperative indentation gonioscopy. This small overestimate was statistically significant (P less than 0.001 using the t-test) but rarely of clinical importance. The preponderance of overestimates and exact

agreement supports the clinical impression that an iridectomy with tight wound closure and rapid restoration of the anterior chamber does not cause an increase in peripheral anterior synechia formation.

INFLUENCE OF EXTENT OF SYNECHIAL CLOSURE ON EFFICACY OF IRIDECTOMY.

For this analysis five ranges of synechial closure were considered: 0%, 5-25%, 30-50%, 55-75% and 80-100%. Figure 4 shows the actual numbers of successes and failures in each of the five ranges of synechial closure. The successes requiring medical therapy are distinguished from those requiring no therapy. Figure 5 displays the same results in percentages. The overall success rate was high throughout the four ranges encompassed within 0-75% peripheral anterior synechias. At 0% peripheral anterior synechias success without medical therapy was predominant. As the peripheral anterior synechia ratio increased from 0% peripheral an-

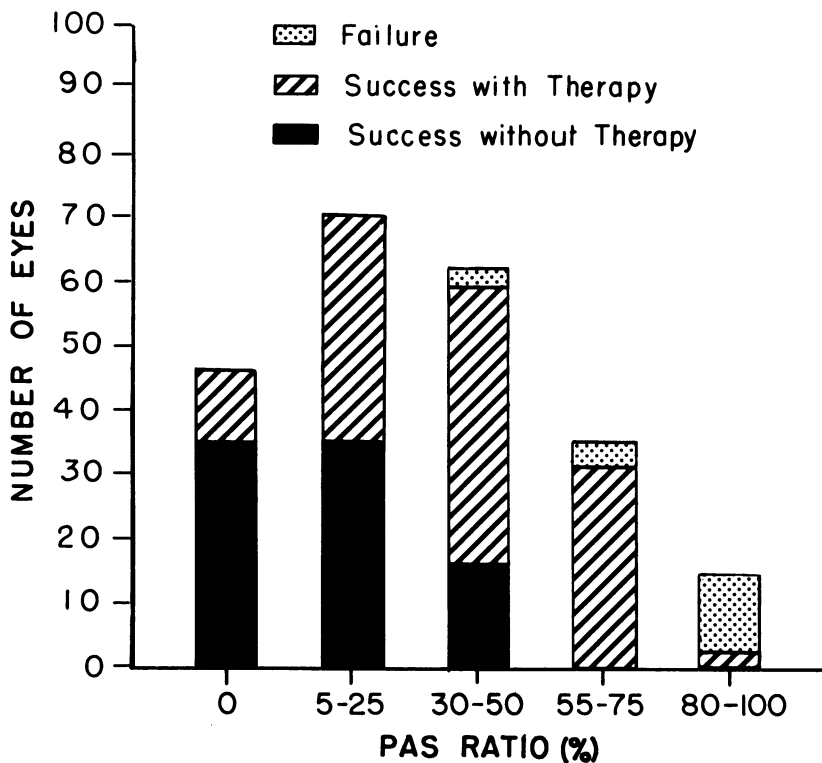


FIGURE 4

Results of iridectomy according to range of postoperative peripheral anterior synechia ratio.

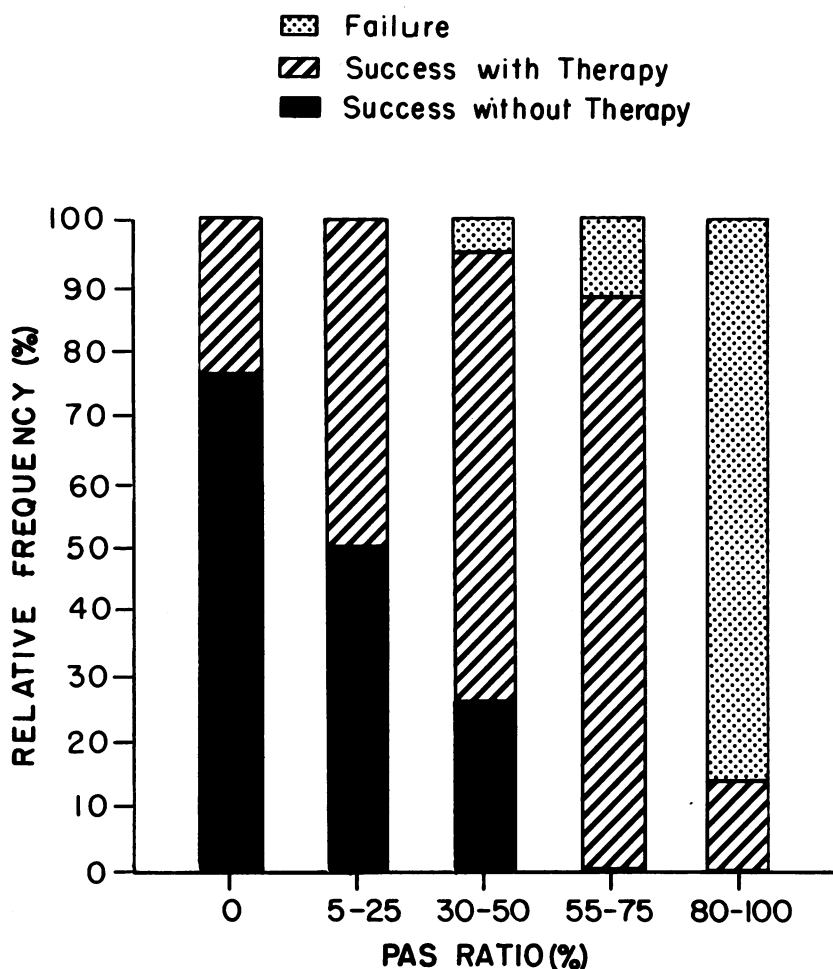


FIGURE 5

Relative frequencies of results of iridectomy according to range of postoperative peripheral anterior synechia ratio.

terior synechias to 75% peripheral anterior synechias there was a progressive increase in the proportion of eyes with residual glaucoma requiring medical therapy. There were no successes without medical therapy above 50% peripheral anterior synechias. Failures were first encountered in the range 30-50% peripheral anterior synechias, became more frequent in the range 55-75% peripheral anterior synechias and dominated the range 80-100% peripheral anterior synechias.

These data are presented in greater detail in Table 2 which further subdivides the successes with residual glaucoma according to intensity of the medical regimen required to achieve an adequate status of control. As the extent of synechial closure increased there was, among these successes, a definite need for more intensive medical therapy. For example, the percentage of eyes needing echothiophate iodide or acetazolamide (Groups C and D) progressed steadily from 4% in the range 5-25% peripheral anterior synechias to 51% in the range 55-75% peripheral anterior synechias.

With increasing synechial closure there was an associated increase in the severity of the residual glaucoma and, ultimately, an increase in the rate of failure. Despite this evident trend there was considerable individual variability. For example, in the range 30-50% peripheral anterior synechias, 26% of the eyes were controlled without medical therapy, and yet, 5% were total failures. Hence, the extent of synechial closure, although a very good indicator of the efficacy of iridectomy, is not an absolute determinant.

TABLE 2 INFLUENCE OF PAS RATIO ON EFFICACY OF IRIDECTOMY							
PAS Ratio (%)	No. of Eyes	Success Without Therapy	Success With Therapy				Failure
			A	B	C	D	
0	46	35 (76%)	9 (20%)	2 (4%)	0 (0%)	0 (0%)	0 (0%)
5-25	70	35 (50%)	23 (33%)	9 (13%)	2 (3%)	1 (1%)	0 (0%)
30-50	62	16 (26%)	23 (37%)	10 (16%)	10 (16%)	0 (0%)	3 (5%)
55-75	35	0 (0%)	6 (17%)	7 (20%)	14 (40%)	4 (11%)	4 (12%)
80-100	14	0 (0%)	0 (0%)	0 (0%)	1 (7%)	1 (7%)	12 (86%)

A= PILOCARPINE or EPINEPHRINE

B= PILOCARPINE and EPINEPHRINE

C=ECHOTHIOPHATE IODIDE or ACETAZOLAMIDE

D=ECHOTHIOPHATE IODIDE and ACETAZOLAMIDE

COMMENT

The data presented herein demonstrate that indentation gonioscopy can provide a reasonably accurate estimate of the extent of synechial closure in angle-closure glaucoma before surgery. The errors inherent in the technique tend to cause a small overestimate which is usually not of clinical importance. This overestimate is presumably due to failure of indentation to open all areas of appositional closure in all eyes.

In this connection a word of caution must be added regarding the use of indentation gonioscopy when the intraocular pressure is high. Under these circumstances indentation may be relatively, or totally, ineffective in opening areas of appositional closure thereby leading to a gross overestimate of the percentage of angle closed by peripheral anterior synechias. This phenomenon was first encountered by the author in September 1966.

CASE 1

A 69 year old man presented with typical acute angle-closure glaucoma of his right eye of less than 24 hours duration by history. The tension was 56 and the cornea was steamy. The anterior chamber was shallow and the pupil was semi-dilated and fixed. After clearing of the cornea with topical glycerin, gonioscopy revealed a reasonably good view of a totally occluded angle. Indentation gonioscopy definitely widened the approach to the angle in all quadrants but the angle itself remained totally closed. It was concluded that there was 100% synechial closure, presumably due to previously asymptomatic chronic angle-closure glaucoma. Pilocarpine and intravenous mannitol were administered with a favorable response. Four hours later the tension was down to 12. At that juncture, indentation gonioscopy revealed opening of almost the full circumference with only 10% synechial closure. A peripheral iridectomy produced a successful result without need for medical therapy.

COMMENT

Other authors^{41,45} have called attention to the potential ineffectiveness of indentation gonioscopy at high pressure levels and correctly cautioned about the possibility of misleading results. Although indentation gonioscopy has occasionally been effective at high pressures, it is clearly preferable to use this technique under optimal conditions after the pressure has been lowered. At high pressures, areas that fail to open by indentation are not necessarily closed by adhesions.

The author has used indentation gonioscopy for a period of 15 years. Experience is required before the technique can be mastered. The degree of accuracy reported in this study cannot be achieved until such skill is acquired.

In his paper on chronic angle-closure glaucoma Nose⁶⁰ described a series of eyes in which indentation gonioscopy was performed before and after iridectomy. His results indicate good correlation, but surprisingly, there was a tendency to underestimate the extent of synechial closure before surgery. In a few instances, this underestimation was serious. Since the major problem before surgery is to detect areas of appositional closure which are capable of opening, one would anticipate overestimates. It is difficult to account for large underestimates unless adhesions developed as a result of surgery in such cases.

Operating room gonioscopy after the anterior chamber deepening procedure is undoubtedly the most accurate method for detection of synechial closure. This study demonstrates that indentation gonioscopy is capable of providing sufficiently adequate preoperative information in the majority of eyes to obviate extra manipulation in the operating room. A series comparing the results obtainable by the two methods would be of great interest, especially in acute angle-closure glaucoma where it has been suggested that the anterior chamber deepening procedure may cause separation of fresh adhesions.³⁴ Indentation gonioscopy has, thus far, not been observed to break synechias and is certainly less likely to do so.

In the view of the author, gonioscopy after anterior chamber deepening should be used in cases where the pressure cannot be lowered sufficiently before surgery to permit adequate indentation gonioscopy. It is presumed that most of these cases will be found to have extensive synechial closure. For patients too weakened by an acute attack to sit at a slit-lamp, direct indentation gonioscopy⁴⁸ can be performed at the bed side. Operating room gonioscopy should be used for the occasional patient who is unable to submit to routine gonioscopic examination.

As an office procedure indentation gonioscopy also serves as an aid in diagnosis and affords an opportunity to monitor the peripheral anterior synechia ratio during a course of medical therapy for angle-closure glaucoma. As mentioned previously, indentation gonioscopy should not be used to supply supplementary diagnostic information until after the narrow-angle configuration has been established by routine gonioscopy. If an eye with early angle-closure glaucoma, seemingly well controlled on medical therapy, is found by indentation gonioscopy to be developing progressive synechial closure, an iridectomy should be performed promptly.

This study provides data to support the widely held view that the severity of residual post-iridectomy angle-closure glaucoma is closely related to the extent of synechial closure. This relationship is consistent

with Barkan's concept of a normal filtration apparatus which is capable of normal outflow function when not obstructed by the root of the iris. The tonographic studies of Grant⁶⁵ and others^{66,67} have supported Barkan's concept by demonstrating a normal facility of outflow in early angle-closure glaucoma at times when the angle is open. Exclusion from the present study of eyes with preoperative evidence of an impaired outflow apparatus (elevated pressure despite a partially open angle) undoubtedly tended to strengthen the relationship that was observed.

Despite these considerations the relationship between synechial closure and severity of residual glaucoma is statistical rather than absolute. The outcome in a specific case, especially regarding the need for long-term medical therapy, cannot be predicted with certainty solely on the basis of the peripheral anterior synechia ratio. Several factors must be considered in attempting to account for this variability. Some peripheral anterior synechias may bridge the angle and adhere to Schwalbe's line without obstructing outflow. It would be extremely difficult to detect such bridge synechias by gonioscopy. In 1954, Barkan²⁹ suggested that prolonged or repeated appositional closure might cause damage to the trabecular meshwork leading to a secondary open-angle glaucoma which would persist after iridectomy. Chandler⁶⁸ has supported this hypothesis although he has admitted that it is difficult to distinguish such a process from an underlying pre-existing chronic simple glaucoma. In any event, an underlying open-angle glaucoma of whatever type would certainly distort the relationship between the peripheral anterior synechia ratio and efficacy of iridectomy as determined in this study. Despite careful precautions, it would be virtually impossible to unmask all such cases prior to surgery and it is reasonable to assume that some were included. In this connection, it is of interest that 24% of the eyes without peripheral anterior synechias required medical therapy. Haas⁶⁹ found that only 5% of eyes with early angle-closure glaucoma required miotics after iridectomy. The result obtained in the present series was unexpectedly high and the reason for this discrepancy is not evident. On the other hand, these eyes were all easily controlled without resorting to strong miotics or acetazolamide.

The use of long-term intensive medical therapy considerably enhances the effect of iridectomy. A success rate of 88% was achieved in the range 55-75% peripheral anterior synechias but all of these eyes required medical therapy and 51% required echothiophate iodide or acetazolamide or both. When this study was initiated in 1963, the potential beneficial effect of strong miotics in treating residual glaucoma after iridectomy seemed well worth exploring. It had been shown that all miotics produce a

considerable increase in facility of outflow in normal eyes.⁷⁰ This ability of miotics to improve the action of the normal outflow system is consistent with their effect in post-iridectomy angle-closure glaucoma where most, if not all, of the areas of open-angle are believed to be undamaged. The initial enthusiasm for strong miotics was dampened considerably in 1966 when Axelsson and Holmberg⁷¹ reported that echothiophate iodide can induce the development of cataracts. Since 1966, strong miotics have been used less frequently in this series thereby forcing an increased usage of acetazolamide and an associated increase in the problem of systemic side effects. Nevertheless, strong miotics have been used when all other measures proved inadequate and they have been effective in some of these difficult situations.

Echothiophate iodide was the cause of a complication in one case in this series.

CASE 2

A 46 year old man had chronic angle-closure glaucoma in his right eye treated by a peripheral iridectomy in January 1964. This eye had 50% peripheral anterior synechias and required medical therapy. The residual glaucoma was well controlled on pilocarpine and epinephrine until April 1966 when the intraocular pressure rose to 28 mm Hg. Echothiophate iodide was started. Two days later the patient returned with a flat anterior chamber and a tension of 45 mm Hg. Echothiophate iodide was stopped and a regimen of phenylephrine-atropine was started. There was prompt restoration of the anterior chamber. During the ensuing ten months echothiophate iodide was not used and the intraocular pressure could not be adequately controlled. An uneventful cataract extraction with sector iridectomy was performed in February 1967. Afterward, echothiophate iodide was well tolerated and the intraocular pressure was normalized. The patient was followed until November 1970.

COMMENT

Echothiophate iodide precipitated an episode of malignant glaucoma two years after iridectomy. The response to mydriatic-cycloplegic therapy⁷² was favorable. Malignant glaucoma may recur after lens extraction⁷³ but it did not do so in this case, even in connection with the resumption of echothiophate iodide. Although this eye was adequately controlled after cataract extraction, it had not been adequately controlled after iridectomy and was classified as a failure. It was the only case of malignant glaucoma in this entire series.

In 1957 Chandler⁵⁶ stated: "After operation for angle-closure glaucoma there may be a certain amount of residual glaucoma. Operation has opened all portions of the angle not permanently closed by synechias and

no further closure will take place. The residual glaucoma is now a permanent state and will not become significantly worse or better as time passes. In some cases further operation is required, but in many instances the residual glaucoma can be controlled by medical means." The results of the present study are in accord with Chandler's hypothesis regarding the residual glaucoma after iridectomy. The peripheral anterior synechia ratio of each eye was determined every one to two years after iridectomy and it was found, as expected, that there was no further increase in synechial closure. Furthermore, in most of the eyes requiring medical therapy, no increase in the regimen was required after the first year or two. This stability of the residual glaucoma is consistent with the concept of a normal outflow system underlying the iris block in the majority of patients with primary angle closure glaucoma.

Although the information provided by this study can be applied to the management of patients with angle-closure glaucoma, there are certain limitations to the conclusions which can be drawn from the available data. The results obtained are not necessarily representative of the entire spectrum of the disease since some of the very early cases were treated medically and some of the advanced cases with more than 60% peripheral anterior synechias had a filtering procedure. If iridectomy had been performed on all eyes without selection, the failure rate would undoubtedly have been higher in the 55-75% peripheral anterior synechias range. Nevertheless, it has been established that iridectomy can succeed in a number of eyes with 55-75% peripheral anterior synechias if the patient is willing and able to use long-term intensive medical therapy. Beyond 75% peripheral anterior synechias, success is extremely unlikely. In the range 0-50% peripheral anterior synechias, the success rate is quite favorable although medical therapy may be needed.

The choice of operation in angle-closure glaucoma should not be based on the peripheral anterior synechia ratio alone. A sound clinical judgment requires consideration of other factors such as the degree of optic nerve damage, the responsiveness to medical therapy before surgery, the duration of an acute attack and the ability of the patient to follow a medical regimen after surgery. Iridectomy is more likely to succeed when these factors are favorable and more likely to fail when they are unfavorable.

In general, an attack of long duration or a poor response to medical therapy would suggest the presence of extensive synechial closure. However, exceptions to such rules of thumb are not unusual and it is preferable to determine the peripheral anterior synechia ratio by indentation gonioscopy or operating room gonioscopy rather than by inference. This

approach is aimed at increasing the frequency of use of iridectomy as opposed to other operations.

Measurement of the facility of outflow by tonography can also be helpful in the choice of operation. In 1958 Becker and Thompson⁷⁴ found that iridectomy had a 96% success rate when the preoperative outflow facility was greater than 0.15, an 81% success rate when the outflow facility was in the range 0.11-0.15, and only a 23% success rate when the outflow facility was less than 0.11. These authors concluded that iridectomy should not be performed at preoperative outflow facilities less than 0.11. However, this viewpoint was revised in 1964 when it was asserted that abnormal tonographic findings may be primarily due to appositional closure rather than synechial closure and should not be interpreted as a contraindication to iridectomy.⁵⁴ The revised opinion has recently been re-stated by Podos and Becker.⁷⁵ In essence, a good preoperative outflow facility (C greater than 0.15) is a favorable indicator but a poor preoperative outflow facility may be an inconclusive finding in the presence of a closed angle.

A report on the efficacy of iridectomy requires some consideration of the other surgical procedures which may be used in angle-closure glaucoma. Synechialysis combined with iridectomy was advocated for a time but it has been abandoned because of complications³⁴ and experimental evidence that freeing of long-standing peripheral anterior synechias does not significantly improve the facility of outflow of enucleated eyes.⁷⁶ Much the same can be said of cyclodialysis. Among the usual filtering operations, iridencleisis and thermal sclerostomy⁷⁷ are generally regarded as the safest and most suitable for eyes with shallow anterior chambers. The complications of filtering operations are familiar to all ophthalmic surgeons.⁷⁸ Guarded thermal sclerostomy⁷⁹ has been introduced in an effort to circumvent the problem of the postoperative flat chamber which is particularly troublesome after filtering surgery for angle-closure glaucoma. Trabeculectomy,⁸⁰ a microsurgical procedure designed to facilitate drainage of aqueous humor into the canal of Schlemm, can be used in angle-closure glaucoma with preliminary separation of any adhesions that may be present at the operative site.⁸¹ It is becoming evident, however, that trabeculectomy functions largely by subconjunctival filtration and therefore represents a new variation of the standard filtering operations. Further developments in microsurgery of the anterior segment will undoubtedly have an impact on the surgery of angle-closure glaucoma in the years ahead.

To date, iridectomy remains the best operation for angle-closure glaucoma whenever it has a reasonable chance for success. The peripheral

anterior synechia ratio is the single best indicator of what is likely to be achieved by iridectomy. The choice of operation should also be based on consideration of all other relevant factors, especially when the peripheral anterior synechia ratio is greater than 50%. An appropriate filtering operation or trabeculectomy can be used secondarily in the event of failure of iridectomy.

SUMMARY

Iridectomy was performed on 227 eyes of 151 patients with primary angle-closure glaucoma and the patients were followed for a period of three to ten years after surgery. This series of selected cases was used to test the accuracy of preoperative indentation gonioscopy and to determine the influence of the extent of synechial closure on the efficacy of iridectomy.

An estimate of the extent of synechial closure was made by indentation gonioscopy before surgery. Postoperative gonioscopic findings after elimination of pupillary block served as the standard for comparison. The results confirmed the accuracy of indentation gonioscopy in distinguishing between appositional closure and synechial closure. There was a small preoperative overestimate of synechial closure. The mean of the differences (% peripheral anterior synechias determined preoperatively by indentation gonioscopy minus % peripheral anterior synechias determined postoperatively) was +3.2% peripheral anterior synechias with standard deviation $\pm 6.0\%$ peripheral anterior synechias. This overestimate is statistically significant, but rarely of clinical importance.

The outcome of iridectomy was analyzed according to the extent of synechial closure. Success was predominant in the range 0-75% peripheral anterior synechias and failure was predominant in the range 80-100% peripheral anterior synechias. At 0% peripheral anterior synechias most of the successes did not require medical therapy. As synechial closure increased from 0% peripheral anterior synechias to 75% peripheral anterior synechias there was a progressive decline in the rate of success without medical therapy and a progressive increase in the intensity of the regimen required to control the residual glaucoma. In the range 55-75% peripheral anterior synechias all eyes had residual glaucoma and half of them needed strong miotics or acetazolamide or both. Failures first appeared in the range 30-50% peripheral anterior synechias and increased in frequency thereafter.

It is concluded from this analysis that determination of the extent of synechial closure provides a useful prognostic indicator of the efficacy of

iridectomy. The outlook for success is favorable for eyes with 0-50% peripheral anterior synechias and unfavorable for eyes with 80-100% peripheral anterior synechias. In the intermediate range 55-75% peripheral anterior synechias the outlook is uncertain and all other relevant factors must be considered before arriving at a surgical decision. In equivocal situations it may be preferable to try the safer iridectomy first with an understanding that a secondary operation might be needed afterward.

REFERENCES

1. Knies M: Ueber das glaucom. *Albrecht von Graefes Archiv fur Ophthalmologie* 22:163-202, 1876.
2. Knies M: Ueber das glaucom II. *Albrecht von Graefes Archiv fur Ophthalmologie* 23:62-78, 1877.
3. Weber A: Die ursache des glaucoms. *Albrecht von Graefes Archiv fur Ophthalmologie* 23:1-91, 1877.
4. Smith P: *On the Pathology and Treatment of Glaucoma*. London, J. & A. Churchill, 1891, p. 83.
5. Trantas A: Ophthalmoscopie de la région ciliare et retrociliare. *Arch Ophthalmol (Paris)* 27:650-672, 1907.
6. Salzmann M: Die ophthalmoskopie der kammerbucht. *Z Augenheilkd* 31:1-19, 1914.
7. Salzmann M: Die ophthalmoskopie der kammerbucht. *Z Augenheilkd* 34:26-70, 1915.
8. Koeppel L: Das stereo-mikroskopische bild des lebenden kammerwinkels an der nernstspaltlampe beim glaucom. *Klin Monatsbl Augenheilkd* 65:389-391, 1920.
9. Troncoso MU: Gonioscopy and its clinical applications. *Am J Ophthalmol* 8:433-449, 1925.
10. Werner S: Gonioskopische untersuchungen bei glaucoma primarium *Acta Ophthalmol (Kbh)* 10:427-563, 1932.
11. Troncoso MU: Closure of the angle of the anterior chamber: Its bearing on operations for the relief of hypertension. *Arch Ophthalmol* 14:557-586, 1935.
12. Troncoso MU: *A Treatise on Gonioscopy*. Philadelphia, F. A. Davis Co., 1947, pp. 211-214.
13. Raeder JC: Untersuchungen über die lager und dicke der linse im menschlichen auge bei physiologischen und pathologischen zuständen, nach einer neuen methode gemessen. II. Die lage der linse bei glaucomatösen zuständen. *Albrecht von Graefes Archiv fur Ophthalmologie* 112:29-63, 1923.
14. Rosengren B: Studien über die tiefe der vorderen augenkammer mit besonderer hinsicht auf ihr verhalten beim primären glaucom: Eine untersuchung mit dem Lindstedtschen apparat: I. Die kammertiefe des normalen auges. *Acta Ophthalmol (Kbh)* 8:99-136, 1930.
15. Barkan O: Glaucoma: Classification, causes and surgical control: Results of microgonioscopic research. *Am J Ophthalmol* 21:1099-1117, 1938.
16. Sugar HS: The mechanical factors in the etiology of acute glaucoma. *Am J Ophthalmol* 24:851-873, 1941.
17. Bangerter A, Goldmann H: Kammerwinkelstudien beim Primären glaucom. Operationswahl nach dem winkelbefund. *Ophthalmologica* 102:321-350, 1941.
18. Kronfeld PC: Gonioscopic correlates of responsiveness to miotics. *Arch Ophthalmol* 32:447-455, 1944.
19. von Graefe A: Ueber die iridectomie bei glaucom und über den glaucomatösen process. *Albrecht von Graefes Archiv fur Ophthalmologie* 3:456-555, 1857.

20. de Wecker L: *Ocular Therapeutics*. Forbes, L. (trans.), London, Smith, Elder & Co., 1879, pp. 269,275.
21. Smith P: *Glaucoma: Its Causes, Symptoms, Pathology, and Treatment*. London, J. & A. Churchill, 1879, pp. 198-215.
22. Curran EJ: A new operation for glaucoma involving a new principle in the aetiology and treatment of chronic primary glaucoma. *Arch Ophthalmol* 49:131-155, 1920.
23. Banziger T: Die mechanik des akuten glaukoms und die deutung der iridektomie — wirkung bei demselben. *Ber Dtsch Ophthalmol Ges* 43:43-48, 1922.
24. Barkan O: An operative procedure for glaucoma of shallow chamber type. *Arch Ophthalmol* 21:331-345, 1939.
25. Barkan O: Choice of operation in glaucoma *Am J Ophthalmol* 24:768-778, 1941.
26. Chandler PA: Narrow-angle glaucoma. *Arch Ophthalmol* 47:695-716, 1952.
27. Haas JS, Scheie HC: Peripheral iridectomy in narrow angle glaucoma. *Trans Am Acad Ophthalmol Otolaryngol* 56:589-595, 1952.
28. Barkan O: Narrow-angle glaucoma: Pupillary block and the narrow-angle mechanism. *Am J Ophthalmol* 37:332-350, 1954.
29. Barkan O: Iridectomy in narrow-angle glaucoma. *Am J Ophthalmol* 37:504-519, 1954.
30. Kronfeld PC, McGarry HI: Results of surgical treatment of acute congestive glaucoma *Quarterly Bulletin, Northwestern University Medical School*. 18:203-214, 1944.
31. Shaffer RN: Operating room gonioscopy in angle-closure glaucoma surgery. *Trans Am Ophthalmol Soc* 55:59-66, 1957.
32. Chandler PA, in discussion on Shaffer RN: Operating room gonioscopy in angle-closure glaucoma surgery. *Trans Am Ophthalmol Soc* 55:66-67, 1957.
33. Chandler PA: Indications for operation in open-angle glaucoma. *Trans Ophthalmol Soc U K* 83:211-220, 1963.
34. Chandler PA, Simmons RJ: Anterior chamber deepening for gonioscopy at time of surgery. *Arch Ophthalmol* 74:177-190, 1965.
35. Ogino N: On the angle of the anterior chamber in closed-angle glaucoma with the anterior chamber deepening method by injection of saline solution. *Acta Soc Ophthalmol Jap* 65:1673-1681, 1961.
36. Sugar HS: Gonioscopy and glaucoma. *Arch Ophthalmol* 25:674-717, 1941.
37. Lowe RF: Acute angle-closure glaucoma: Acetazolamide therapy. *Aust J Ophthalmol* 1:24-26, 1973.
38. Weiss DI, Shaffer RN, Wise BL: Mannitol infusion to reduce intraocular pressure. *Arch Ophthalmol* 68:341-347, 1962.
39. Robbins R, Galin, MA: Effect of osmotic agents on the vitreous body. *Arch Ophthalmol* 82:694-699, 1969.
40. Forbes M: Gonioscopy with corneal indentation: A method for distinguishing between appositional closure and synechial closure. *Arch Ophthalmol* 76:488-492, 1966.
41. Gorin G, Posner A: *Slit-lamp Gonioscopy*, ed. 3. Baltimore, Williams & Wilkins, 1967, p 120.
42. Etienne R: *Les Glaucomes*. Marseille, Diffusion Generale De Librairie, 1969, pp 182-184.
43. Krasnov MM: Microsurgery of glaucoma: Indications and choice of techniques. *Am J Ophthalmol* 67:857-864, 1969.
44. Kolker AE, Hetherington J Jr.: *Becker-Shaffer's Diagnosis and Therapy of the glaucomas*, ed 3. St. Louis, C.V. Mosby Co., 1970, pp. 15-19, 352-353.
45. Hoskins HD: Interpretive gonioscopy in glaucoma. *Invest Ophthalmol* 11:97-102, 1972.
46. Schirmer KE: Gonioscopy and artefacts. *Br J. Ophthalmol* 51:50-53, 1967.
47. Gorin G: Re-evaluation of gonioscopic findings in angle-closure glaucoma. *Am J Ophthalmol* 71:894-897, 1971.
48. Nakamura Y: An attempt of contact lens for direct indentation gonioscopy. *Jap J Clin Ophthalmol* 23:795-799, 1969.

49. Nakamura Y, Nose H, Kitazawa, Y: Examination of peripheral anterior synechia by indentation gonioscopy. *Jap J Clin Ophthalmol* 25:1701-1707, 1971.
50. Sugar HS: Gonioscopy and glaucoma. *Arch Ophthalmol* 25:674-717, 1941.
51. Chandler PA, Trotter RR: Angle-closure glaucoma: Subacute types. *Arch Ophthalmol* 53:305-317, 1955.
52. Weekers R, Prijot E, Gustin J: Recent advances and future prospects in the medical treatment of ocular hypertension. *Br J Ophthalmol* 38:742-746, 1954.
53. Leopold IH: Ocular cholinesterase and cholinesterase inhibitors. *Am J Ophthalmol* 51:885-919, 1961.
54. Forbes M, Becker B: Iridectomy in advanced angle-closure glaucoma. *Am J Ophthalmol* 57:57-62, 1964.
55. Lowe RF: Primary angle-closure glaucoma: Postoperative tests with 1-epinephrine base. *Am J Ophthalmol* 58:581-583, 1964.
56. Chandler PA: Use and misuse of acetazolamide (Diamox) in the treatment of glaucoma. *Arch Ophthalmol* 57:639-643, 1957.
57. Chandler PA: Just to be sure (editorial). *Arch Ophthalmol* 67:395-396, 1962.
58. Chandler PA, Grant WM: *Lectures on Glaucoma* Philadelphia, Lea & Febiger, 1965, pp. 75, 175.
59. Kronfeld PC: Indications for surgery in glaucoma: Angle-closure glaucoma (symposium). *Trans Am Acad Ophthalmol Otolaryngol* 67:476-482, 1963.
60. Nose H: Choice of surgery in primary angle-closure glaucoma. *Jap J Clin Ophthalmol* 26:173-181, 1972.
61. Lowe RL: The natural history and principles of treatment of primary angle-closure glaucoma. *Am J Ophthalmol* 61:642-651, 1966.
62. Becker B, Shaffer RN: *Diagnosis and Therapy of the Glaucomas*. St. Louis, The C. V. Mosby Co., 1961, pp. 243-248.
63. Becker SC: Unrecognized errors induced by present-day gonioscopes and a proposal for their elimination. *Arch Ophthalmol* 82:160-168, 1969.
64. Shaffer RN: *Stereoscopic Manual of Gonioscopy*. St. Louis, The C. V. Mosby Co., 1962, pp. 35-39.
65. Grant WM: Clinical measurements of aqueous outflow. *Arch Ophthalmol* 46:113-131, 1951.
66. Weekers R, Prijot E: Measurement of the resistance to the aqueous flow by the electronic tonometer: Results in cases of congestive glaucoma before and after treatment. *Br J Ophthalmol* 36:511-517, 1952.
67. Becker B, Friedenwald JS: Clinical aqueous outflow. *Arch Ophthalmol* 50:557-571, 1953.
68. Chandler PA, in discussion on Shaffer RN: A review of angle-closure glaucoma, in Newell, F. W. (ed.): *Glaucoma: Transactions of the First Conference*. New York, Josiah Macy Jr. Foundation Publications, 1956, pp. 64-65.
69. Haas JS: Surgery for angle-closure glaucoma, in Clark WB (ed.): *Symposium on Glaucoma* St. Louis, The C. V. Mosby Co., 1959, pp. 204-208.
70. Becker B, Gage T, Kolker AE, Gay AJ: The effect of phenylephrine hydrochloride on the miotic-treated eye. *Am J Ophthalmol* 48:313-321, 1959.
71. Axelsson U, Holmberg A: The frequency of cataract after miotic therapy. *Acta Ophthalmol (Kbh)* 44:421-429, 1966.
72. Chandler PA, Grant WM: Mydriatic-cycloplegic treatment in malignant glaucoma. *Arch Ophthalmol* 68:353-359, 1962.
73. Shaffer RN: The role of vitreous detachment in aphakic and malignant glaucoma. *Trans Am Acad Ophthalmol Otolaryngol* 58:217-231, 1954.
74. Becker B, Thompson, HE: Tonography and angle-closure glaucoma: Diagnosis and therapy. *Am J Ophthalmol* 46:305-310, 1958.
75. Podos SM, Becker B: Tonography — current thoughts (editorial). *Am J Ophthalmol* 75:733-735, 1973.

76. Grant WM: Experimental aqueous perfusion in enucleated human eyes. *Arch Ophthalmol* 69:783-801, 1963.
77. Scheie HG: Retraction of scleral wound edges as a fistulizing procedure for glaucoma. *Am J Ophthalmol* 45:220-228, 1958.
78. Leopold, IH: Fistulizing operations for glaucoma: Their complications. *J Int Coll Surg* 33:171-180, 1960.
79. Shaffer RN, Hetherington J Jr., Hoskins HD Jr.: Guarded thermal sclerostomy: A preliminary report. *Trans Am Ophthalmol Soc.* 69:140-146, 1971.
80. Cairns JD: Trabeculectomy: Preliminary report of a new method. *Am J Ophthalmol* 66:673-679, 1968.
81. Watson PG: Surgery of the glaucomas. *Br J Ophthalmol* 56:229-306, 1972.