

## DELAYED MUSTARD GAS KERATITIS (DICHLORO-DIETHYL SULFIDE). A REPORT OF TWO CASES

WALTER S. ATKINSON, M.D.

Watertown, N. Y.

No report of delayed mustard gas keratitis among United States veterans of World War I appeared in the literature until the recent review of Scholz and Woods.<sup>1</sup>

However, many such cases have been reported in the British, French and German literature,<sup>2</sup> so that the condition is a well-recognized entity.

Goulden<sup>3</sup> states that 51 men from the British Army were blinded and 180 received pensions because of visual disability due to mustard gas in World War I.

There may not have been as many gas casualties in the Army of the United States as there were in the British Army. However, a report<sup>4</sup> from the Office of the Surgeon General of the United States Army estimates that there were 52,889 mustard gas casualties admitted to hospitals. The corneas of some of them undoubtedly were seriously affected, as were the 2 cases reported in this paper, which are typical of those reported abroad, so add nothing to our knowledge of the lesion.

The purpose of this communication is to review briefly the signs and symptoms of delayed gas keratitis so that more cases may be recognized and the service connection of their lesions established. Lack of recognition prevents a veteran, so disabled in World War I, from receiving the proper consideration. This was true of the 2 cases herein reported. Time passed and considerable correspondence took place before the service connection of their disability was established.

The case reported by McKellar<sup>5</sup> of recurring keratoconjunctivitis 10 months after exposure to mustard gas, and

often referred to, should probably be considered as an exacerbation of the acute stage rather than the type of lesion referred to as delayed keratitis, which develops 8 or more years after exposure to the mustard gas.

Mann and Pullinger<sup>6</sup> state that many of the pathologic changes observed in cases of delayed mustard gas keratitis may be induced by agents other than mustard gas. The diagnosis rests in a combination of the nonspecific lesions with the typical vascular and degenerative changes in a definite time relationship and at a definite anatomic site. They found that mustard gas lesions which were produced experimentally in rabbits had a marked similarity to those that occur in the human cornea.

The most characteristic signs given by Mann and Pullinger to identify the keratitis caused by mustard gas are the ulceration of the superficial cholesterol deposits, the peculiar varicosities and the blood islands. These signs, they state, have not been induced in rabbits by any other means, nor observed in man in conditions other than mustard gas keratitis.

Mustard gas, dichlorodiethyl sulfide, was first employed by the German Army in July, 1917, after which there were numerous casualties due to the gas. A beautifully illustrated description of the early effects of mustard gas on the eyes was given by Derby<sup>7</sup> at a meeting of this Society in 1919.

The course in all cases is quite similar. After exposure to mustard gas, the action is delayed 2 to 6 hours. The early symptoms are irritation of the eyes, nose and throat, with sneezing and sometimes vomiting. The inflammation of the mucous membrane and skin increases and may be followed by blistering. Respiratory symptoms increase, with severe bronchitis, and secondary pneumonia frequently develops. The severity of the eye and general symptoms depends upon the amount of exposure and susceptibility of the individual.

Whiting<sup>8</sup> classes those affected with the gas as follows: All had photophobia and blepharospasm. Class 1, amounting to

about 75%, had comparatively mild symptoms without corneal involvement. In Class 2, totaling about 15%, the eyes were moderately affected; the corneas were a little rough but did not stain. In Class 3, fortunately only about 10%, the eyes were badly affected, both the cornea and the conjunctiva being involved. The area of the palpebral fissure was severely burned and presented a solid white edema of the conjunctiva. The epithelium of the exposed cornea, involving the lower  $\frac{1}{2}$  or  $\frac{2}{3}$ , was gray and stained with fluorescein. It is from this 10% in Class 3 that "delayed keratitis" developed 8 or more years later. If the eyes of 10% of the 50,000 mustard gas casualties admitted to hospitals of the United States Army were similarly affected, then several thousand United States veterans might be expected to have delayed mustard gas keratitis with defective vision.

Lister<sup>9</sup> reported the following early pathologic changes which were observed in eyes burned with mustard gas. The corneal epithelium was denuded, with flattening of the remaining cells. The white appearance of the conjunctiva noted in the early stages of the more severely burned was due to coagulation and arrest of circulation in the conjunctival vessels. The substantia propria showed round-celled infiltration in some cases. Later, the appearance was reversed, the exposed area was injected and the vessels remained permanently enlarged, while the rest of the conjunctiva appeared normal.

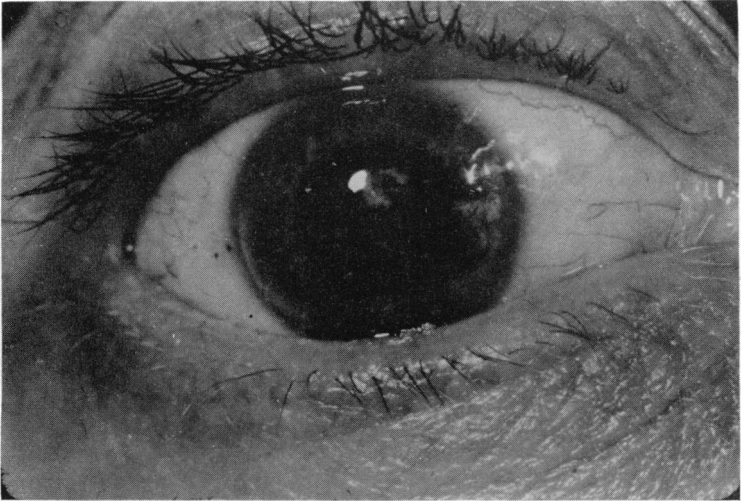
Phillips,<sup>10</sup> who collected 70 cases, called attention to the similarity in histories in those who developed delayed keratitis due to mustard gas. They were unable to open their eyes for about a week due to the marked photophobia and blepharospasm which was accompanied by profuse lacrimation. After being confined to the hospital 4 to 6 months or longer, they were comparatively free from symptoms for 10 to 14 years. The onset of the delayed keratitis is marked by one or all of the following symptoms: photophobia, lacrimation and failing vision. The lower  $\frac{1}{3}$  of the cornea is affected

most. Superficial ulceration occurs and the sensibility of the cornea is less than normal. Phillips described gray branching lines in the substantia propria seen with the slit lamp which he compared to "skate marks on fresh ice." The pale triangular patches on either side of the cornea he spoke of as "marbling." In these patches there is an absence of small conjunctival and episcleral vessels, leaving large areas of the sclera bare and here and there a large distended vessel, which is more tortuous as it nears the limbus and ends in a small corkscrewlike vessel.

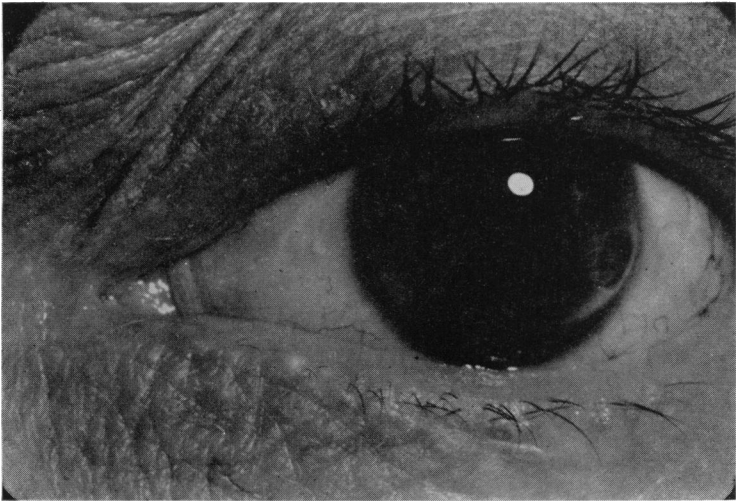
This brief clinical account of the condition corresponds closely with the mustard gas lesions produced experimentally in rabbits by Mann and Pullinger<sup>6</sup> who consider the "late keratitis" a slow degenerative process, seen in man up to 20 years after exposure to mustard gas.

#### CASE REPORTS

CASE 1.—D. O., aged 47 years. When seen in February, 1939, the signs and symptoms of "delayed gas keratitis" were well established. He had been examined by me in 1917 prior to his entrance into the service and at that time his eyes were normal, with vision of 20/15 in each eye. On October 4, 1918, while asleep in a cellar, a gas shell burst near him. Although he felt all right, he reported to the first-aid station, where he slept the rest of the night. On awakening in the morning, he was nauseated and found it difficult to open his eyes, due to photophobia. He was hospitalized for 8 months. His lungs were also affected. In 1919 he was next examined by me, at which time he said that his eyes felt irritated and sensitive to light at times. Except for a small hyperopic astigmatism, his eyes appeared normal. In 1928, a faint corneal opacity was first observed down and temporally in the left eye and a faint, almost imperceptible haze of both corneas was observed. Photophobia had increased, but his vision was still 20/15 in each eye. In February, 1939, failing vision and photophobia were more marked, so that he wore an eyeshade at his work and avoided bright light. His corrected vision was right eye 20/25 and left eye 20/20. There was now a definite, faint, superficial haze involving the lower  $\frac{2}{3}$  of both corneas; the right was more dense than the left. Although sensitive to light, the sensitivity of the cornea was less than normal. In



**Fig. 1.**



**Fig. 2.**

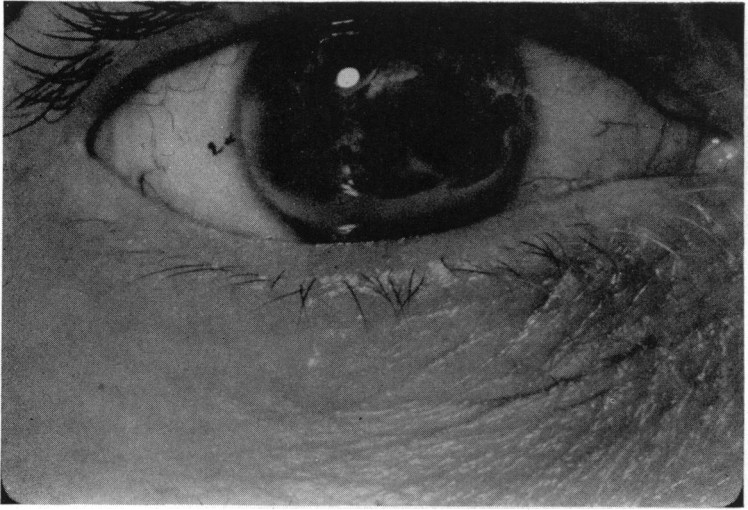


Fig. 3.

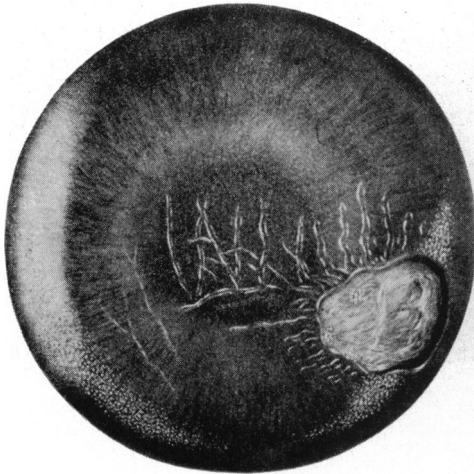


Fig. 4.

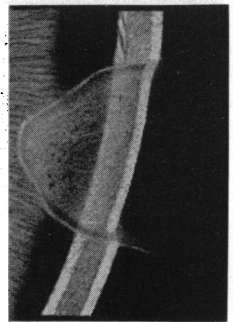
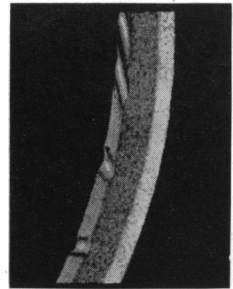


Fig. 5.

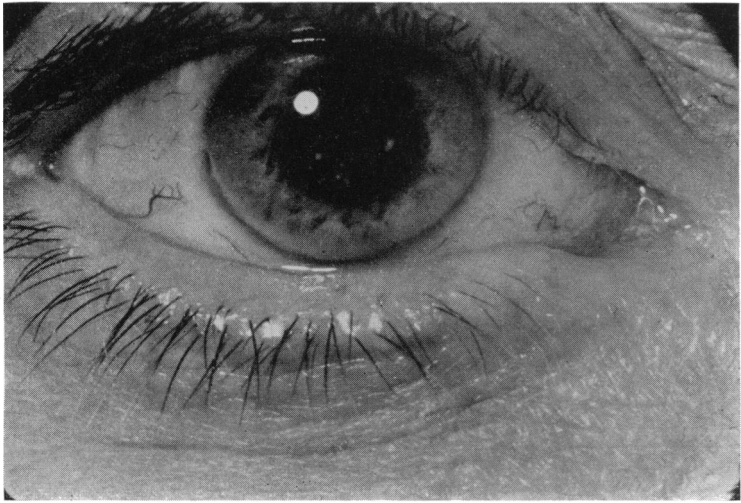


Fig. 6.

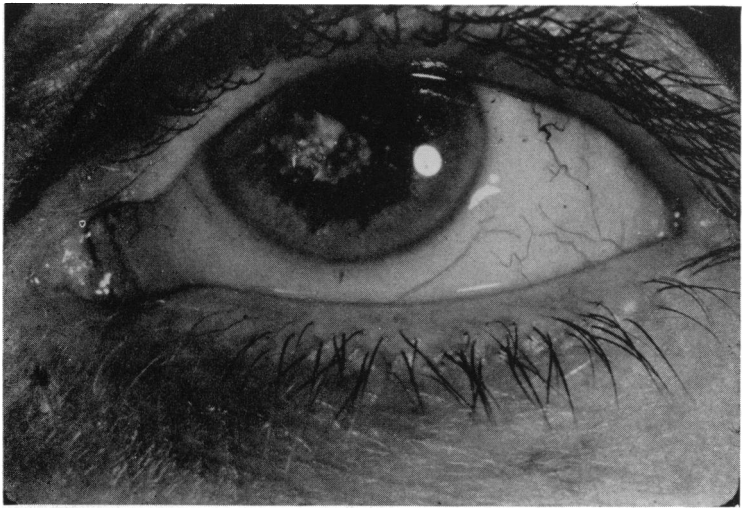


Fig. 7.

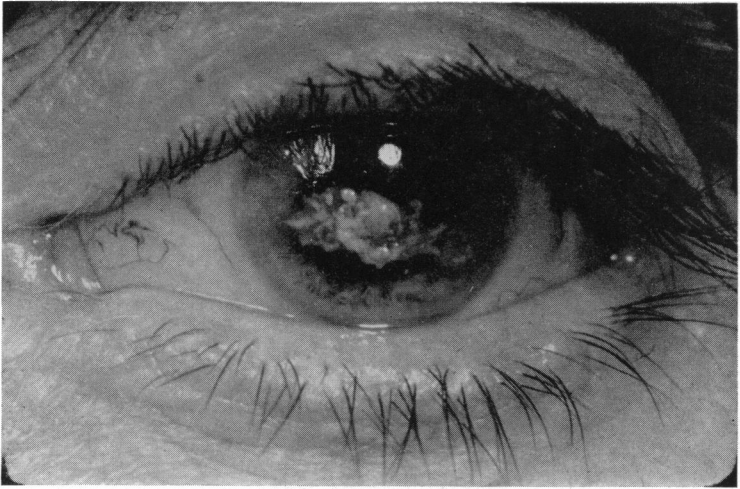


Fig. 8.

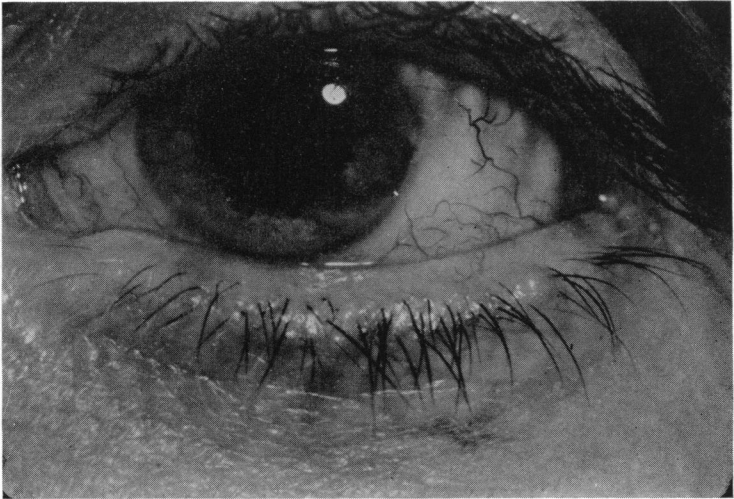


Fig. 9.



October, 1939, 21 years after being gassed, his symptoms had increased in severity and his corrected vision was reduced to right eye 20/40 and left eye 20/25-2. The corneal haze was more dense in each eye and there were striae in the substantia propria of the right eye and vertical folds of Descemet's membrane. Pale triangular areas on either side of both corneas were now more apparent. The triangles on the right side of both corneas were larger than those on the left. A few tortuous vessels were seen in these areas, and there were a few scattered cholesterin deposits. The epithelium first began to break down a year later in July, 1940. The right eye was affected first and the cornea stained in several places. There were many recurrences in the right eye with progressive degenerative changes. A heaping up of yellowish crusts of degenerated tissue on the cornea caused considerable irritation and were removed. The vessels in the triangles, particularly the temporal one in the right eye, became larger and more tortuous, and the vision in the right eye was reduced to 20/100. On March 12, 1943, pictures (Figs. 1, 2) of both eyes showed the degenerative changes to be more advanced and corrected vision was right eye 6/200 and left eye 20/25. On February 26, 1944, the vessel in the temporal triangle of the right eye was larger and more tortuous as it approached the corneal margin. Adjacent to it, in the superficial layers of the substantia propria of the cornea, there was an intra-corneal hemorrhage. In March, 1946, the corrected vision was reduced in the right eye to 3/200 (Fig. 3) and in the left eye to 20/60. The photophobia and lacrimation were increased, but the epithelium was intact. Folds of Descemet's membrane appeared in the left cornea and there were a few striae in the substantia propria similar to those in the right cornea (Figs. 4, 5). In February, 1947, there was less photophobia and vision had improved a little in the right eye to 20/200. This vision was not improved with glasses. The left eye remained the same, 20/60 with correction. The improvement in vision was thought to be due to a few clear spots where the crusts had been removed. Contact lenses were advised.

CASE 2.—R. M., aged 42 years, was first examined by me on May 21, 1938, 20 years after he had been exposed to a gas-shell barrage. The shelling began about 11:00 P.M. on the night of June 14, 1918, and he had had his mask on and off during the night. In the morning his eyes began to smart and tear and were tightly closed by the time he reached the first-aid station. He was in the hospital for about 2 months and his eyes were bandaged for about a month. His lungs were also affected. Following discharge from the

army he had no eye symptoms until a few months before he consulted me, when he noticed that the vision of his left eye was blurred and that there was a spot on it similar to those which later appeared in the right cornea and are shown in Figure 6. His vision was right eye 20/15-2 and left eye 20/15-4. Both corneas were hazy in the area of the palpebral fissures. The haze, which somewhat resembled a lacy web, appeared to be located just under the epithelium. It was interspersed with small, irregular, white deposits tinged yellow with branchlike projections. Some appeared to have coalesced. The condition was more pronounced in the left eye. Pale triangular areas on each side of both corneas were present in which were scattered a few similar yellow deposits and a few tortuous, irregularly shaped vessels. The condition progressed slowly and the deposits became larger and more of them coalesced and formed a large, yellowish, irregular elevation (Figs. 7, 8). The sensibility of the left cornea was less than the right, and both were less than normal. The elevation was removed, but there were still many deposits left in the cornea. He was comfortable until the summer of 1945 when a similar elevation, which caused considerable irritation, developed on the same cornea. The right cornea was a little more hazy, with vision of 20/20, and in the left eye the vision was reduced to 20/200. A keratectomy was done, removing the thin strip of cornea which contained most of the cholesterol deposits. One month after the operation his vision was 20/200, the same as before the operation. In March, 1946, both eyes had been comfortable since the last examination and his vision in the right eye was still 20/20, but vision in the left eye was reduced to 8/200 not improved with glasses. Both eyes were quiet and in the left eye there was a moderately clear horizontal band corresponding to the site of the keratectomy (Fig. 9).

#### COMMENT

Late corneal lesions develop more frequently in cases with greater exposure to mustard gas and in those who are more susceptible to it.

The condition is aggravated if the eyes are bandaged during the acute stage after exposure to the mustard gas. Derby<sup>7</sup> mentioned one case in which both eyes were seriously affected by bandaging. Duke-Elder<sup>11</sup> warns against the use of bandages in the acute stage after exposure to the gas and

suggests bland symptomatic treatment. It is generally conceded that active treatment in the acute stage is contra-indicated.

Following recovery from the acute symptoms, which last in the severe cases from 2 to 8 months, sometimes longer, they are practically symptom-free for 8 or more years.

Photophobia, lacrimation and failing vision mark the onset of the late corneal lesions. Superficial haze of the cornea just beneath the epithelium in the area of the palpebral fissure, lines or striae in the substantia propria (Figs. 4, 5) and folds in Descemet's membrane may precede the formation of deposits of cholesterin and fat. These deposits increase in size and break through the epithelium, producing an exacerbation of the symptoms of irritation. Later there is a heaping up of hard degenerative tissue on the cornea. As these increase in size, they cause more and more irritation until they are cast off or removed, leaving rather clear, irregular, depressed spots. The scarred cornea is so irregular that the vision is improved very little with glasses. However, with contact lenses an astonishing improvement is reported by Mann.<sup>6</sup> In one case in which there was no improvement with glasses, vision was improved from 6/36 to 6/6. In a later report, Mann<sup>12</sup> reviews 84 cases of delayed gas keratitis that were fitted with contact lenses. Besides the great improvement in vision recorded, which in one case was improved from counting fingers to 6/12, the lenses are tolerated well due to decreased sensibility of the cornea. They also afford some protection against minor injuries and the recurrence of ulceration is less frequent. Yet a letter<sup>13</sup> from the Regional Office of our Veterans Administration states that contact lenses are issued only to veterans who are unable to wear ordinary frames due to wounds or scars which affect the temples or nose, and that it is unable to approve the issuance of contact lenses for veterans whose vision has been reduced by delayed mustard gas keratitis.

No reports of successful corneal transplants for this condition have been found in the literature.

Other important diagnostic signs are pale, triangular, atrophic-looking patches on either side of the cornea in the area of the palpebral fissures. In the triangles there is an absence of conjunctival and episcleral vessels with an occasional distended, tortuous, varicose type of vessel. There are also a few scattered deposits of cholesterolin. These areas have somewhat the appearance of those produced by surface application of Beta radiation. Intracorneal hemorrhages occur and appear to arise from the large varicose vessels that extend up to the limbus.

### CONCLUSION

Recognition of the late effects of mustard gas on the cornea is important in order to establish the service connection of the disability, so that claims of veterans, so disabled in World War I, may be justly handled.

I am indebted to Dr. James E. McAskill for the excellent photographs of these cases.

### BIBLIOGRAPHY

1. Scholz, R. O., and Woods, A. C.: *Arch.Ophth.*, **37**, No. 2:139, February, 1947.
2. Mann, I., and Pullinger, B. D.: *Brit.J.Ophth.*, **26**:503-507, November, 1942; Mann, I.: *Proc.Roy.Soc.Med.*, **35**:236-244, 1942; Mann, I.: *Brit.M.J.*, **1**:353-354, 1942; Neame, H.: *Proc.Roy.Soc.Med.*, **22**:25, 1928; Neame, H.: *Brit.J.Ophth.*, **29**:102, February, 1945; Heckford, F.: *Proc.Roy.Soc.Med.*, **30**:949, 1937; Moore, R. F., and Heckford, F.: *Brit.M.J.*, **1**:497-498, 1929; Whiting, M. H.: *Proc.Roy.Soc.Med.*, **33**:225-236, 1940; de Courcy, T. L.: *Brit.J.Ophth.*, **27**:54-60, February, 1943; Anglade, M., and Imbert, G. G.: *LeFrancois, Paris*, 1939, p. 43; Genet, L., and Delord, E.: *Bull. Soc.d'opht.de Paris*, pp. 521-527, 1936; Lyon méd., **158**:216-221, 1936; Genet, L.: *Bull.Soc.d'opht.de Paris*, **49**:409-412, 1937; Lyon méd., **160**:229-231, 1937; Bonnet, P.: *Bull. Soc.d'opht.de Paris*, **51**:407-409, 1939; Parlange, J. A. A.: *Arch.d'opht.*, **46**:87-119, 1929; Pesme, P.: *Arch.d'opht.*, **41**:278-283, 1924; Sourdille, G. P.: *Bull.Soc.d'opht.de Paris*, pp. 799-801, 1936; Villard, H., and Dejean, C.: *Arch.Soc.d.sc.méd.et biol.de Montpellier*, **14**:16-19, 1933; Weill, G.: *Bull.Soc.d'opht.de Paris*, **51**:281-282, 1939; Worms, G., and Bolotte: *Bull.Soc.d'opht.de Paris*, pp. 133-136, 1926; Worms, G.: *Soc.de méd.mil.franç.*, *Bull.mens.*, **20**:229-235, 1926; Muntsch, O.: *5.Aufg. Leipzig, Thieme*, 1939; *Cornea*, pp. 112-113; Roese, H. F.: *Zentralbl.f.d.ges.Ophth.*, **28**:513-528, 1932-1933; *Rohrschneider, W. Klin.Monatsbl.f.Augenh.*, **99**:447-455, 1937.
3. Goulden, C. B.: *Proc.Roy.Soc.Med.*, **235**, 1940.
4. Personal Communication.
5. McKellar, J. H.: *Am.J.Ophth.*, **3**:309, 1920.

6. Mann, I., and Pullinger, B. D.: *Am.J.Ophth.*, **26**:1253, 1943.
7. Derby, G. S.: *Tr.Am.Ophth.Soc.*, **17**:90, 1919; also, *Am.J.Ophth.*, **49**:119, 1920.
8. Whiting, M. H.: *Proc.Roy.Soc.Med.*, **33**:225-229; *Sect.Ophth.* p. 5.
9. Lister, Wm.: *Hist. Great War, Med.Services, Surg. of the War.*
10. Phillips, T. J.: *Proc.Roy.Soc.Med.*, **229**, 1940.
11. Duke-Elder, W. S.: *Textbook of Ophthalmology*, **2**:1714, St. Louis, C. V. Mosby Co., 1938.
12. Mann, I.: *Brit.J.Ophth.*, **28**:441, 1944.
13. Personal Communication.

## DISCUSSION

DR. JOHN W. BURKE, Washington, D. C.: In opening the discussion on Dr. Atkinson's paper, I should like to report one case of delayed keratitis following mustard gas burn in the First World War which is one of the first seen in this country. The most striking feature of this case was the utter lack of knowledge of what processes were going on.

Many men present saw the case and, at the time, our knowledge was not sufficient to give us any clue with what pathologic process we were confronted. Necessarily, the report has to be sketchy as he was the patient of Dr. Thomason in Richmond and I only saw him at intervals.

A brief history is as follows: T. G., aged 43, was first seen November 10, 1938. He had been through the First World War, having been gassed by mustard while serving in the British Army. He was invalided home and was hospitalized for about six months. He did not return to combat duty. After discharge from the army, he became a golf professional and for a number of years had followed his profession in this country, his eyes giving him no trouble.

Eleven months before he was first seen, he had had an ulcer of the cornea of the left eye, lasting two months, which had been apparently cured, allowing him to continue his work.

At the time of the first visit, the vision in the right eye was 20/20 and the left eye was 20/70+ with correction. Slit lamp examination at this time showed: O.D. Fine infiltration of the cornea, generally diffuse in the substantia. Scarring concentrated at 3 and 9 o'clock. O.S. identical with O.D. except infiltration in cornea was much denser. He was given proper glasses and put on dionin 1 per cent.

In June, 1939, he was seen again, his left eye having flared up again a few days before. Dr. Thomason had cauterized an ulcer in this eye with iodine. Examination showed an indolent ulcer with clean edges 3 by 4 mm. in diameter at the nasal limbus. Center of

the ulcer did not stain, though the crescentic ring did. The remainder of the cornea was clear.

He was seen October 4, with the report of repeated healing and breaking down of the cornea O.S. during the summer. Slit lamp study at this time showed much loss of corneal tissue, scafold areas partially denuded of epithelium. Little vascularization, with many areas of what seemed to be fat globules in the whole nasal quadrant. Process resembled Mooren's ulcer, though devoid of overhanging edges. Lid margins were denuded and lids sewed together. On November 20, adhesions had separated and lids were resutured. The second suturing held well. Tuberculin was begun but was discontinued in May as it seemed to have no effect. Lids were now reopened. Vision in each eye was light perception.

Several consultants saw him and suggested the following treatment: x-ray; calcium gluconate intramuscularly; 2½ per cent solution of prontosil; and vitamin A dropped in the eye. These were all tried with no appreciable effect.

In September, three thermophore treatments were given O.D. but were discontinued because of pain. Patient was put on B. A. ointment t.i.d. and patch. O.S. at this time was beginning to clear. O.D. showed fairly dense infiltration of cornea at 3 o'clock, faint staining of the left edge. O.S. No staining of cornea, eye quiet, superficial vascularization. Cornea clearing rapidly.

In November, only one small ulcer remained in cornea O.D. Large yellowish mass in cornea at nasal side. Center of cornea beginning to clear. O.S. Cornea clearing, iris beginning to be seen.

February, 1941, seen again. Vision O.D. fingers 2 ft. Large yellowish mass in cornea at nasal side slightly thinner in center. Soft area at periphery still stained. Vision O.S. 20/200. Cornea regaining transparency. Pattern of iris being well seen. Some superficial vascularization, no staining. Patient at this time was given dionin 2 per cent and hot compresses.

Patient last seen, May 13, 1947. Vision O.D. 20/70+. O.S. 20/20-. Slit lamp examination showed: O.D. old cicatrix in cornea extending through all layers. Denser portions seem to have some pigment granules scattered throughout and cornea of irregular thickness. Cornea much thinner than normal, from ½ to ⅓ of normal thickness. Iris shows some broken-down pigment and posterior synechia at lower pole. O.S. same irregular thinning of cornea though not so much as O.D., the central scarred portion being thicker than surrounding clear areas. No synechia in this eye. Tension O.U. 17 (Schiötz). The lens is uninvolved.

The man is now back at work, using eyes comfortably and I anticipate no further trouble. The two striking features at present are the abnormal irregular thinning of the cornea and the lack of vascularization.

Dr. Atkinson speaks of 53,000 cases, reported from the Surgeon General's Office, of mustard gas burns of the eye admitted to the hospitals with a percentage of 75 of apparently mild symptoms without corneal involvement, 15 per cent where the eyes were moderately involved and 10 per cent in which the corneas and conjunctivas were badly involved.

I happened to be stationed in two gas hospitals during World War I. Gas Hospital Number I was on the St. Mihiel salient where many gassed cases were expected. The largest number of patients we ever had at one time was seven. The second Gas Hospital was Number IV, at Rarécourt in the Argonne. For two days we had no cases and then were overwhelmed. I saw no cases of mustard; they were all phosgene. Because there was an order for all gassed cases to be sent back, the men, who were exhausted, reported they were gassed. With a night in bed and a couple of hot meals, they were ready to be returned to duty; but, because of the order, they were sent farther back as stretcher cases and were classified as gassed. So, I feel that the so-called 5,000 serious mustard gas cases with potential delayed keratitis do not really exist; and, while we may get more of such cases and should be aware of this possibility, not a great many more will appear.

DR. ALEXANDER E. MACDONALD, Toronto, Canada: I want to congratulate Dr. Atkinson on working out his cases so well. I think that the men should be pensioned, even providing that part of the present condition may be the result of overtreatment. In the battalion where I served as Medical Officer it was considered somewhat of a disgrace for a man to leave the unit as a gas case. I have had to treat fifty gas cases in one day, men who had to be led into the dressing station as a result of swollen, closed lids and marked photophobia, lacrimation and edema of the conjunctiva. This condition was caused by gas being evaporated by the warm sun after shelling on a cold night. I instilled oleum ricini frequently into the conjunctival sac. None of these men left the unit, in fact they were ready for light duty in 24 to 48 hours after treatment. The officer commanding approved of this, for it was known that men who left the area often were permanently lost to the unit. I now admit that severe complications might have resulted.

SIR STEWART DUKE-ELDER, London, England: I think this is a very important matter largely from the point of equity and pensions. I think in England we must have many more cases than you have here, or else the subject has been brought up more fully before this. Up to three months ago we have had 105 cases at a Hospital in London which I think are all definitely delayed mustard gas keratitis. As Dr. Atkinson has told you, they were all gassed in 1917-1918, and the first case I saw was in 1929. I did not of course recognize it as mustard gas poisoning. One thought it was an odd kind of recurrent ulcer, but our cases began to come in about 1933 to 1936, and by 1937, by dint of hammering at officialdom, we got them to recognize the condition, and in England now we take care of the patient and provide him with contact lenses and the renewal of contact lenses when it is required. The pictures that Dr. Atkinson has shown are quite typical. The curious thing about the history is that there is a story of the ordinary mustard gas poisoning, and then always 10 years of complete freedom, usually more, fifteen sometimes, and even twenty years of complete freedom from any kind of symptoms. Then generally the first thing that happens in our experience is a slight irritability and photophobia and a curious change in the reflex, being an increase in the horizontal cylinder, and then recurrent ulcers begin to appear and reappear more often until the patient's life becomes rather miserable. The pictures which you saw just now are typical of the kind of thing we get in England. I think the most typical things are these ampullaform dilatations of the blood vessels, very often with these intracorneal hemorrhages. These changes are quite typical of mustard gas poisoning, apart from radiation. These, and the avascular scarred area in the conjunctiva, some ulcerations, and eventually superficial deposits which we can easily scrape up, and the thinning of the cornea are the typical appearance. We found that with contact lenses the condition improves enormously, and very curiously these patients can wear contact lenses happily and in a much higher proportion than ordinary folk because of the relative insensitivity of the cornea itself. I think the longest case I know of wearing a contact glass is ten years, and he has had, as most of them do, occasional relapses, but not very serious ones. What will happen to them one does not know. Whether in time, as the condition gets worse, the contact lenses will not help we do not know. I think you will see that type of case here too.

DR. WALTER S. ATKINSON, closing: I would like to thank the discussers and, in particular, Sir Stewart for emphasizing the advantages of using contact lenses.