

Rönne: Quoted by de Schweinitz.

Schaeffer: *Anat. Record*, 1924, xxviii, p. 243.

de Schweinitz: *Tr. Ophth. Soc. U. Kingdom*, 1923, xliii, p. 12.

de Schweinitz and Carpenter: *J. A. M. A.*, 1905, xlv, p. 81.

Traquair: *Edinburgh M. J.*, 1913, xi, p. 197.

Traquair: *Brit. J. Ophth.*, 1917, i, p. 216; p. 281; p. 337.

Traquair: The Doyne memorial lecture, *Tr. Ophth. Soc. U. Kingdom*, 1923, xliii, p. 480.

Walker and Cushing: *Arch. Ophth.*, 1916, xlv, p. 407.

Wilbrand and Saenger: *Die Neurologie des Auges; ein Handbuch für Nerven- und Augenärzte*, J. F. Bergmann, Wiesbaden, 1915, vi, p. 292.

---

## ON THE ORIGIN AND DISPOSITION OF THE CELLS IN ENDOPHTHALMITIS\*

J. A. MACMILLAN, M.D.

Montreal, Canada

While engaged in a systematic study of infected eyeballs, I observed a tendency on the part of the inflammatory cells to arrange themselves in a distinctive linear manner, and my theory is that the explanation of the development and disposition of the exudate in endophthalmitis is to be found in part in this linear arrangement of the cells.

The phenomenon is not seen in all cases. In severe inflammations it is hidden by the profusion of cells, or lost through necrosis, while in long-standing inflammations it is obliterated by the organization of the exudates. One must also note that in many cases the sections are of little or no value in a study of endophthalmitis owing to loss of vitreous at the moment of sectioning the globes for embedding. Nevertheless, in most cases the lines can be made out in some part of the exudate, and by examining a large series of cases one sees that the arrangement holds not only for every part of the vitreous, but that, by combining the several findings, one gets a composite outline of the exudates in endophthalmitis.

A synthetic picture of the cellular distribution in endoph-

\* Candidate's thesis for membership accepted by the Committee on Theses.

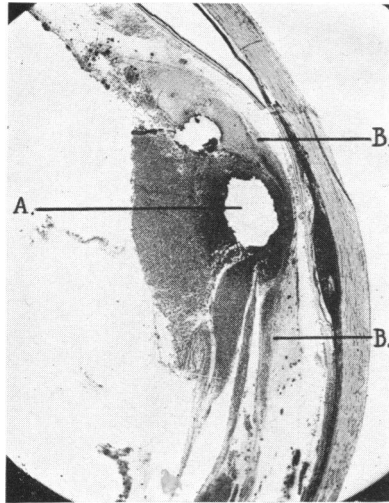


Fig. 1.—A., Site of foreign body. B.,  
B., Extension in lines along the retina.

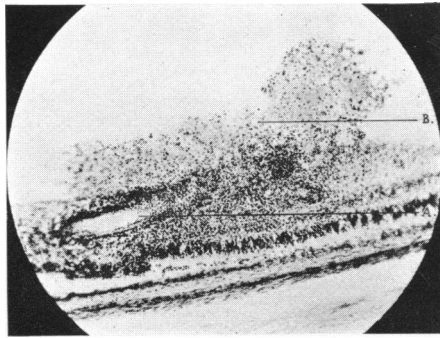


Fig. 2.—A., Retinal vessel. B., Heaping of  
cells on the retina.

thalmitis, as I see it from a histologic study of 70 cases collected from the ophthalmic service of the Royal Victoria Hospital, Montreal, is as follows: Over the posterior portion of the orbiculus ciliaris, from the ora serrata to a point from one and one-half to two millimeters in front of it, there is a large deposit of cells. From this deposit the cells, in linear arrangement, follow two main paths. The greater number extend into the interior of the vitreous in the direction of its center, while the remainder have a course directed backward along the retina, with offshoots into the interior of the vitreous.

Immediately anterior to the deposit on the orbiculus just described there is a second mass of cells, about one millimeter in diameter, without special arrangement; but from this very definite and distinct lines of extension are again found. These proceed forward over the zonulae and posterior surface of the lens, to be continuous with the same linear arrangement on the opposite side.

In the posterior part of the globe the cells lying free in the vitreous are disposed in irregular and ill-defined banks; but in numerous instances where the masses rest on the retina one again observes characteristic linear extensions forward and backward along the surface of the retina. This arrangement was noted especially in one case of foreign body in the eye lying close to the retina (fig. 1). There the greatest collection of cells was, of course, immediately surrounding the foreign body; but from this collection lines of extension seemed to spread forward and backward along the course described above.

Although it is difficult to determine where inflammatory cells in the vitreous originate, it would appear, from the size and location of the deposit over the posterior part of the ciliary body, immediately in front of the ora serrata, that the underlying orbiculus is the site of origin. At this point the vitreous is attached to the ciliary body, so that cells escaping

from the orbiculus are necessarily thrown directly into the vitreous. Farther forward along the orbiculus the escaping cells would be picked up by the aqueous, as the posterior chamber extends backward to within two millimeters of the ora serrata. Cells are undoubtedly also supplied by the retinal vessels. Several of my sections (fig. 2) clearly show cellular heaps on the internal limiting membrane immediately over a retinal vessel, while few or no cells can be found elsewhere on the retina.

I will add here that the polymorphonuclear leukocyte was almost invariably the type of cell encountered.

I had previously thought that the reason for the linear arrangement of the cells along the back of the lens, which is found so frequently in cases of iridocyclitis, and also in more severe infections of the posterior segment, was probably due to a migration of the cells following along the posterior lenticular space from the posterior chamber. But when one considers the obstruction caused by the ligamentum hyaloideo-capsulare, it becomes increasingly difficult to believe that the cells could follow from the posterior chamber into the posterior lenticular space.

On further study it seemed that a more nearly correct explanation of the linear arrangement of the cells in this situation and throughout the whole body of the vitreous lay in a migration of cells along the vitreous fibers having the arrangement described by Salzmann.\*

The structure of the vitreous, according to Salzmann, is as follows: It is fixed to the papilla, and less firmly to the inner surface of the retina, but most firmly, however, at the ora serrata and the ciliary epithelium in a zone some one and one-half millimeters broad immediately adjacent to the ora serrata. Even severe injuries do not tear this attachment. He calls this the "base of the vitreous." In front of this

\*Salzmann: *The Anatomy and Histology of the Human Eyeball*, translated by E. V. L. Brown, 1912.

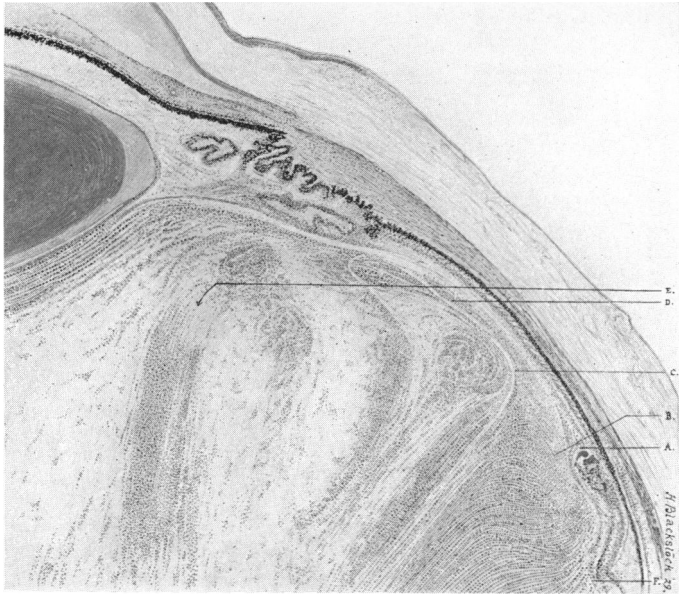

Fig. 3.—Drawing of section from our collection: A., Ora serrata. B., Base of vitreous, showing linear arrangement of cells toward the center of the vitreous. C., Mass of cells without linear arrangement corresponding to the zonular cleft. D., Linear arrangement proceeding forward over the orbiculus ciliaris and back of the lens, corresponding to the anterior border layer of the vitreous. E., Offshoots running into the interior of the vitreous. F., Cells proceeding backward corresponding to the posterior border layer.

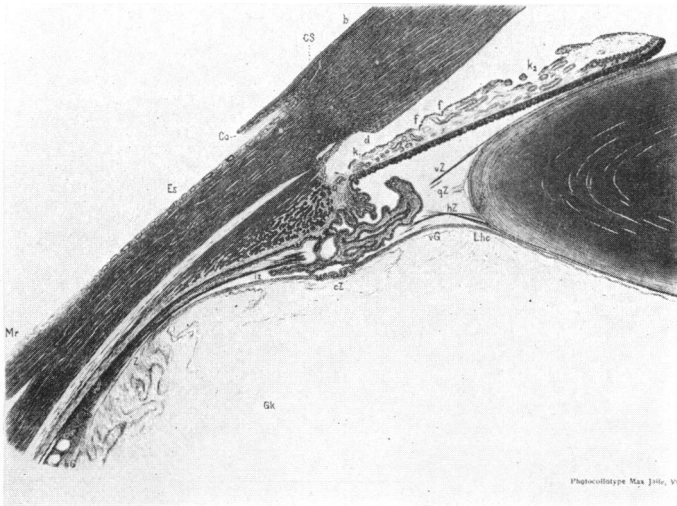


Fig. 4.—Illustration from Salzmann. Gb, Base of the vitreous. hG, Posterior border layer. vG, Anterior border layer. Z, Zonular cleft. Lhc, Ligamentum hyaloideo-capsulare.

base the vitreous borders on the posterior chamber, and its attachment is much less secure, as it is attached to the ciliary body only here and there by delicate processes and zonular fibers. Where the vitreous joins the lens a firmer union is again present in the form of a ring eight or nine millimeters in diameter which is concentric with the lens border. This attachment is called the ligamentum hyaloideo-capsulare. The portion of the vitreous inside this ligament is not attached to the lens, but is separated by a capillary space—the post-lenticular space of Berger. Salzmann further states, in regard to the nature of the vitreous, that it consists of a framework of firmer substances and fluid which fills out its meshes. The whole framework of the vitreous goes out from the base, and from this framework a thick layer is separated and extends backward along the retina. This is called the posterior border layer, and it is thickest at the ora serrata. As the posterior border layer proceeds backward, fibers are constantly turning off into the interior of the vitreous. The portion which does not enter the posterior border layer radiates in the interior of the vitreous, broadening out like a fan, and forms the body of the vitreous. In front of the base of the vitreous the zonular cleft, which is about one and one-half millimeters wide, is free from the border layer; but in front of this the anterior border layer begins, and it extends over the whole of the anterior limits of the vitreous. It separates the vitreous from the posterior chamber and the lens, and is thinner than the posterior border layer. As it is bordered off from the vitreous it appears more like a membrane, and it is responsible for what many call the membrana hyaloidea.

If, now, one compares my description of the cellular arrangement as previously given (fig. 3) with Salzmann's description of the arrangement of the fiber structure of the vitreous (fig. 4), one cannot fail to be struck by the marked similarity. This resemblance is so striking as to suggest that

there is here an explanation of the distribution and of the linear arrangement of the cells in posterior infections of the eyeball. The similarity can be explained by assuming that the vitreous fibers guide the cells after their escape into the vitreous. Especially is this marked over the ciliary body and the back of the lens, where the anterior border layer of the vitreous courses direct from the base of the vitreous forward. It appears that the cells follow this path and so become arranged in lines. It is true there is a gap in the border layer which Salzmann calls the zonular cleft; but it seems to act more or less like a reservoir from which the cells proceed forward.

That the vitreous fibers guide the cells is further substantiated by the findings in sections where prolapse of the vitreous has occurred, especially through a corneal wound. Then one sees, at the periphery of the prolapse, linear arrangement of the cells up to the wound (figs. 5 and 6). This corresponds with what one would expect to find; namely, that the border layer would form the periphery of the prolapse, and it is fair to assume that the cells have come forward along this border structure. Further, in cases where the lens capsule has been injured and cells invade the lens, these cells advance in lines between the lens fibers, giving a picture similar to the arrangement under discussion (fig. 7).

Another point of interest in this study was the part played by the diaphragm in inflammations of the anterior and posterior segments of the eye. The diaphragm which separates these two segments is usually described as formed solely by the zonulae and the lens. It strikes me, however, that the anterior vitreous border must play a very important part in its construction. If the zonulae, particularly those going to the posterior surface of the lens, were in the form of a membrane, in place of being a series of fibers with intervening spaces, one could easily understand that it would form the line of separation. But with the intervening spaces




Fig. 7.—Linear arrangement of cells invading the lens between the fibers.

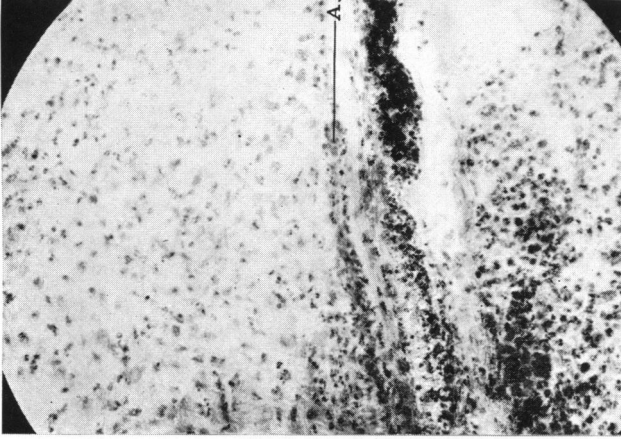


Fig. 6.—Higher magnification of figure 5, taken at point "B" in the section. A., shows the linear arrangement.

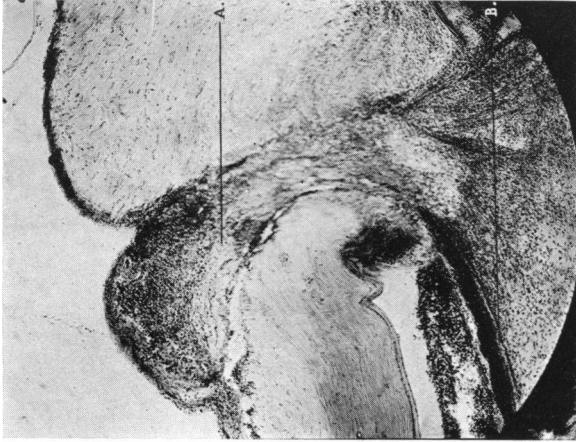


Fig. 5.—A., Prolapse of vitreous. B., Linear arrangement at the border of the prolapse.



one can hardly attribute the entire diaphragm effect to it alone. On the other hand, as the anterior border layer contains much finer fibers with narrower intervening spaces, its importance can hardly be neglected.

In infections limited to the anterior segment of the eye the picture seen is well known. The cells are found along the ciliary processes throughout the posterior chamber, as well as in the anterior chamber, on the anterior surface of the iris, and on the back of the cornea. But in many cases the vitreous remains free. There evidently was enough resistance in the vitreous surface to prevent the cells migrating backward, and one finds no linear arrangement on the back of the lens.

In mild cases of posterior infection, where the cells invade the vitreous, I am inclined to believe that the flat portion of the ciliary body corresponding to the base of the vitreous must supply the cells for battle, while in mild anterior cases these cells are supplied by the corona ciliaris, with perhaps the anterior portion of the orbiculus ciliaris, or that part of the ciliary body bordering on the posterior chamber, and from the iris. If the infection is severe, however, the whole ciliary body, together with the iris and retinal vessels, is responsible for the output of the cells, and one finds involvement of both the posterior and the anterior segments.

Corroboration of the correctness of this theory is to be found in examination by the direct method, for, with the slit-lamp, one sees in some cases cellular exudate in the aqueous with the vitreous free from such exudation, while in others the vitreous may be invaded with cells and the aqueous remain normal.

In a search of the literature I was unable to find any mention of what I have described in this paper. Fuchs, in a paper on the anatomy of endophthalmitis,\* says that the cells wandering from the posterior part of the orbiculus find

\* Fuchs: Graefe's Arch. f. Ophth., 1924-1925, cxv, p. 387.

themselves in the adjacent vitreous, which is firmly attached to the orbiculus. They extended from here, and in three cases formed a beginning vitreous abscess; but he does not mention the vitreous fibers as a guiding factor.

I am well aware that in infections from foreign bodies which enter the globe the site of the lesion from which the toxins spread is likely to attract the maximum number of cells; but in this paper it is the manner in which these cells reach that focus that is of interest, and this is my reason for trying to explain the similar courses and arrangements which they follow.

#### CONCLUSIONS

1. The distribution of the inflammatory cells in the vitreous is determined by the distribution of the vitreous fibers.

2. The arrangement of the cells in my series followed the course of the vitreous fibers, as described by Salzmann, and would appear to confirm Salzmann's description of the arrangement of the fibers of the vitreous body.

3. The importance of the anterior border layer of the vitreous as a component part of the diaphragm should be more strongly stressed, as well as its rôle in delimiting cellular migration and influencing the clinical picture in endophthalmitis and iridocyclitis.

4. The cells which invade the vitreous come chiefly from that portion of the ciliary body to which the base of the vitreous is attached, and from the retinal vessels. The cells which invade the anterior segment of the eye come from that portion of the ciliary body which is washed by aqueous; *i. e.*, the anterior portion of the orbiculus ciliaris, corona ciliaris, and the iris itself. In severe infections, where both the anterior and the posterior segments are involved, the whole ciliary body, together with the iris and retina, supplies the cells.

I am deeply indebted to Dr. W. Gordon M. Byers for having suggested this study, and for the interest he has taken in the work.